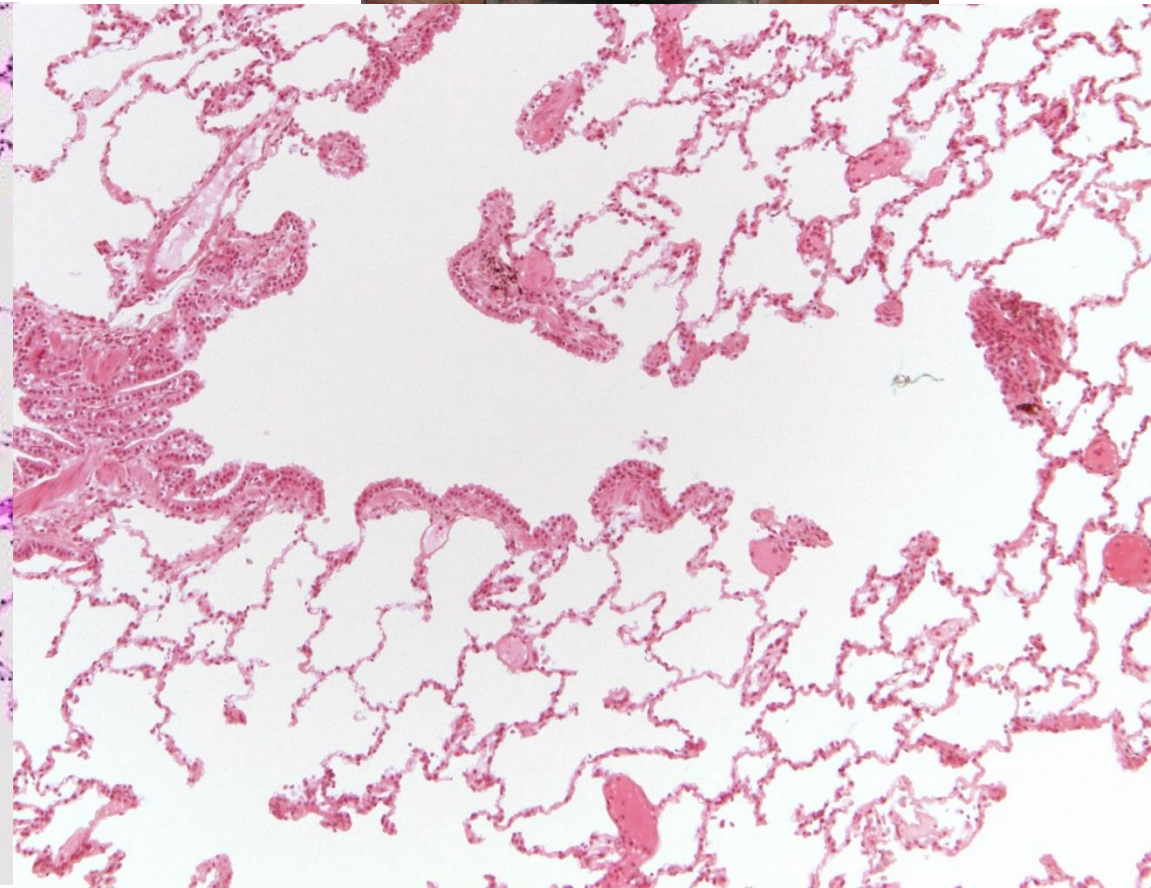
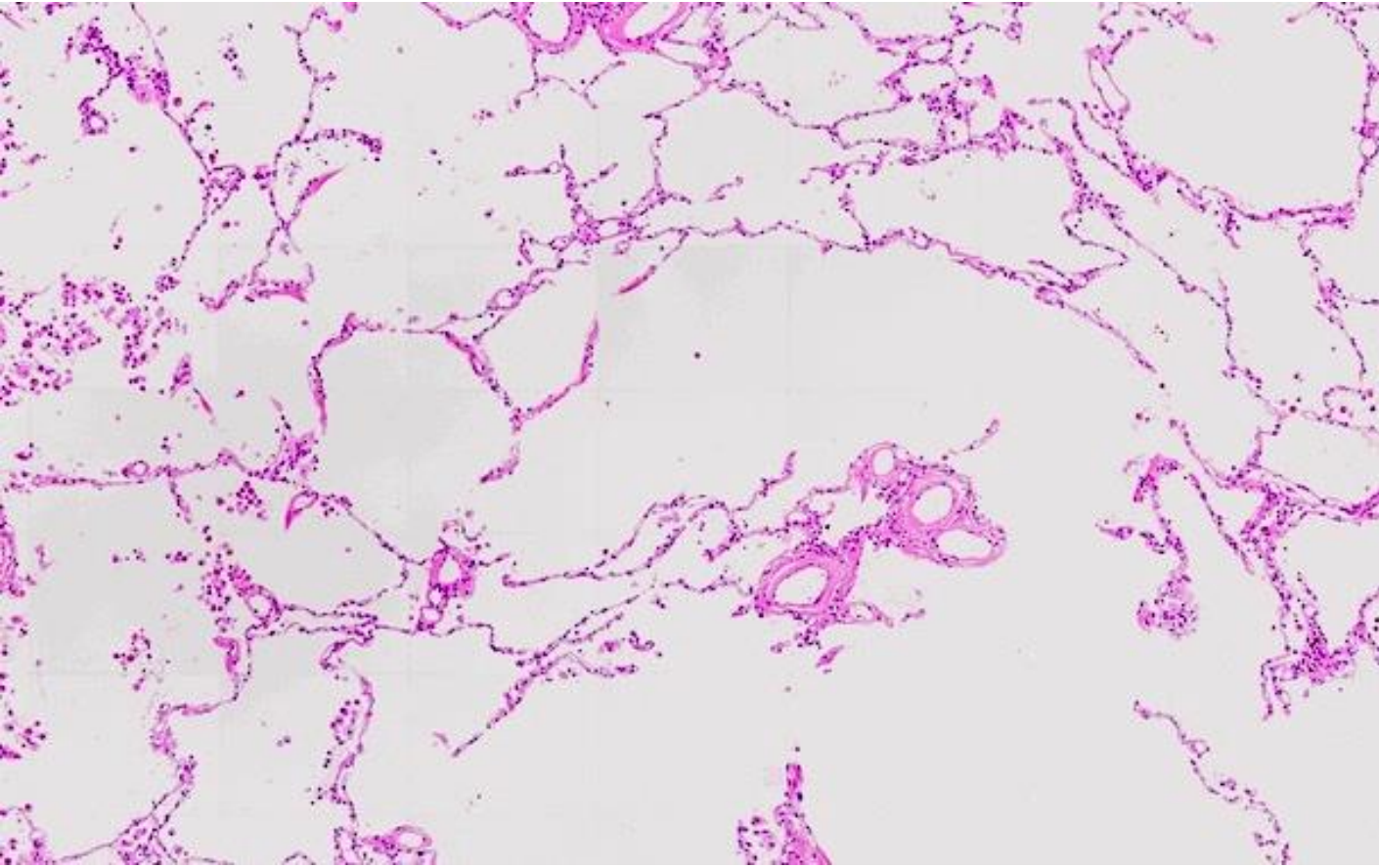
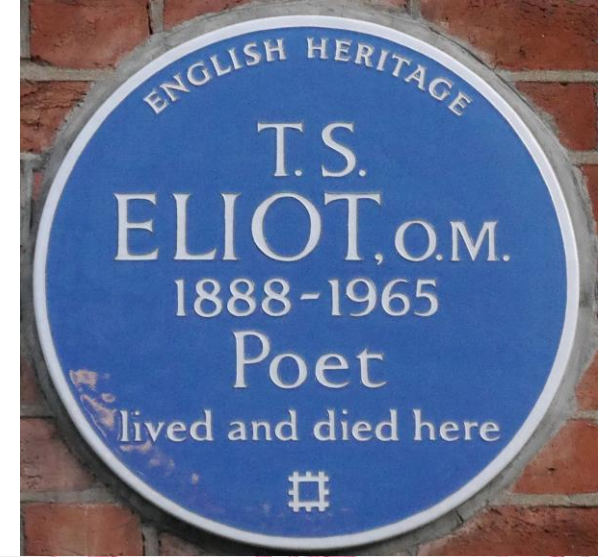

Nervous system

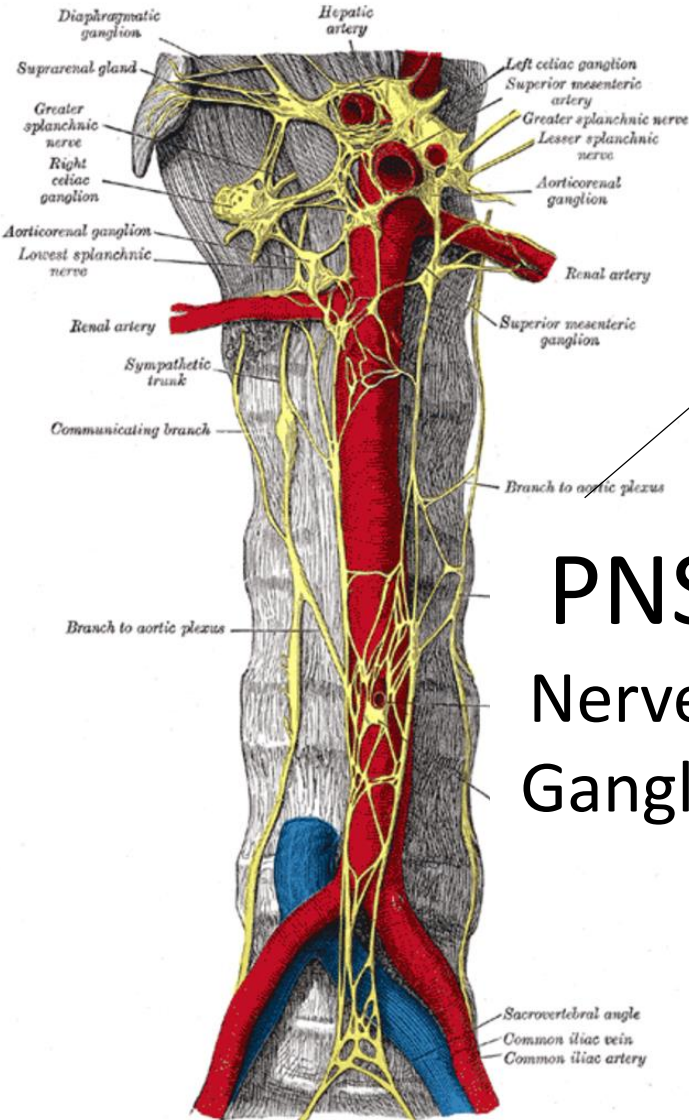
MUDr. Pavel Rořtok

„April is the cruelest month“

<https://www.pathologyoutlines.com/topic/lungnontumoremphysema.html>

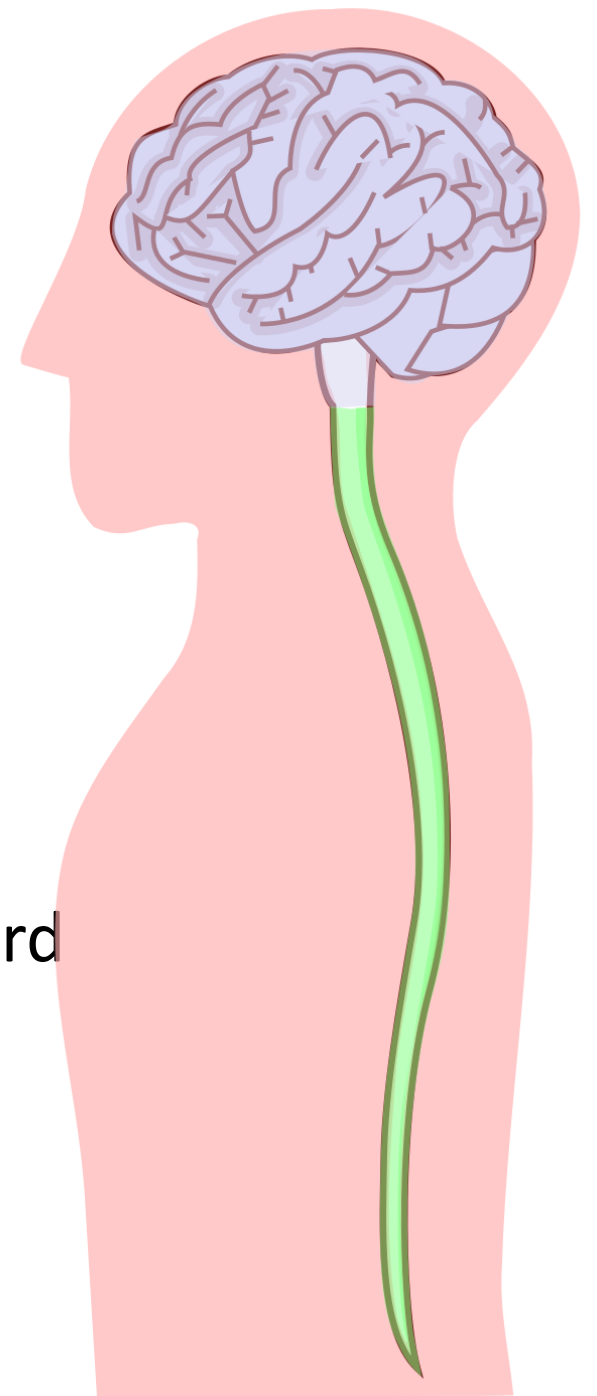


Nervous system



PNS
Nerves
Ganglia

CNS
Brain
Spinal cord



Connect the corresponding statements to the terms

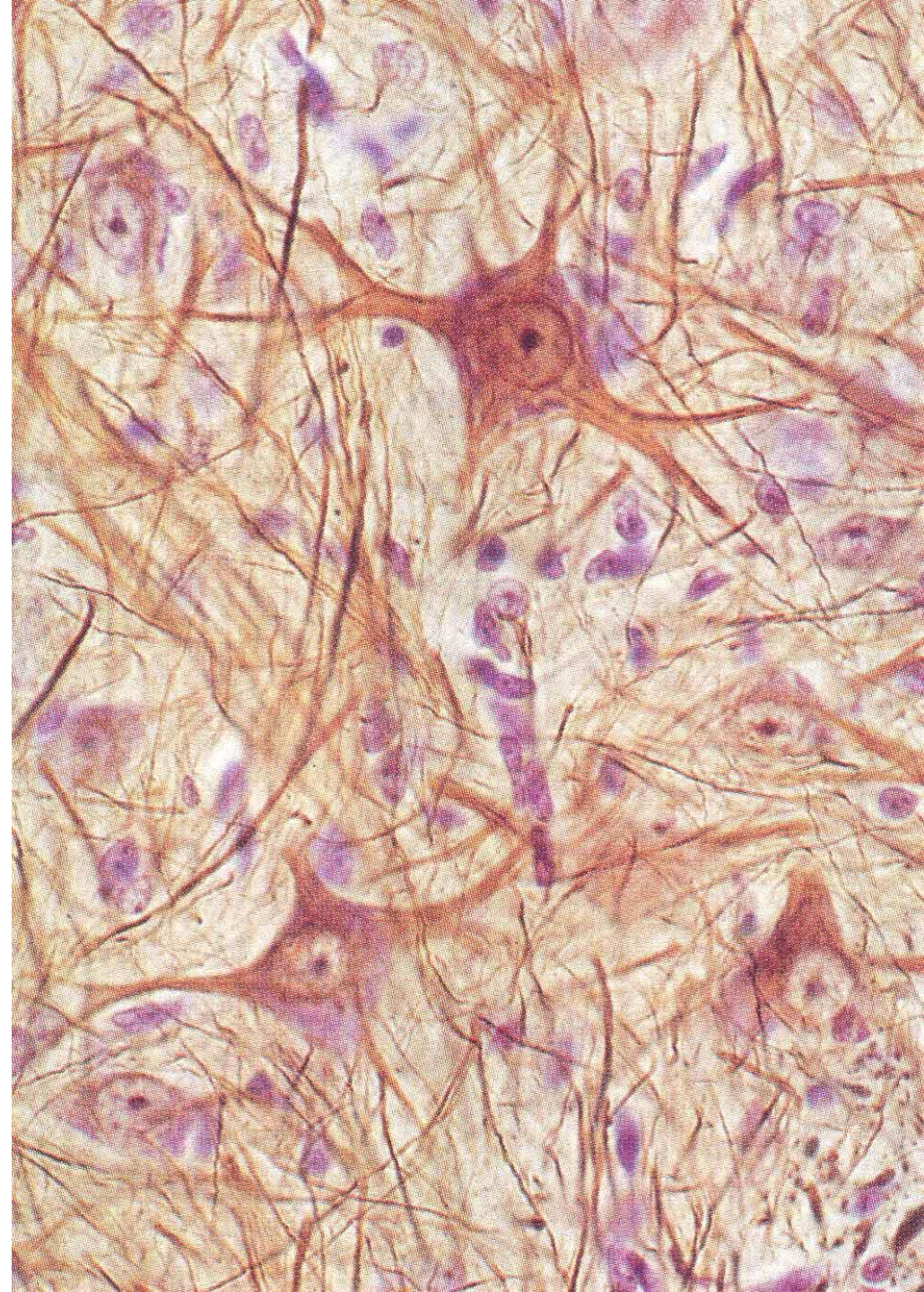
- | | |
|-----------------|---|
| 1. White matter | a) Can be myelinated and unmyelinated |
| 2. Grey matter | b) Contains primarily the processes of the neurons |
| 3. Dendrite | c) Network of glial and neuronal processes in the grey matter |
| 4. Axon | d) Contains bodies and processes of neurons |
| 5. Myelin | e) Neuronal process that is unmyelinated |
| 6. Neuropil | f) Lipid-rich sheath that improves the signal conduction along the axon |

1b; 2d; 3e; 4a; 5f; 6c

-
- | | |
|-----------------|---|
| 1. White matter | a) Can be myelinated and unmyelinated |
| 2. Grey matter | b) Contains primarily the processes of the neurons |
| 3. Dendrite | c) Network of glial and neuronal processes in the grey matter |
| 4. Axon | d) Contains bodies and processes of neurons |
| 5. Myelin | e) Neuronal process that is unmyelinated |
| 6. Neuropil | f) Lipid-rich sheath that improves the signal conduction along the axon |

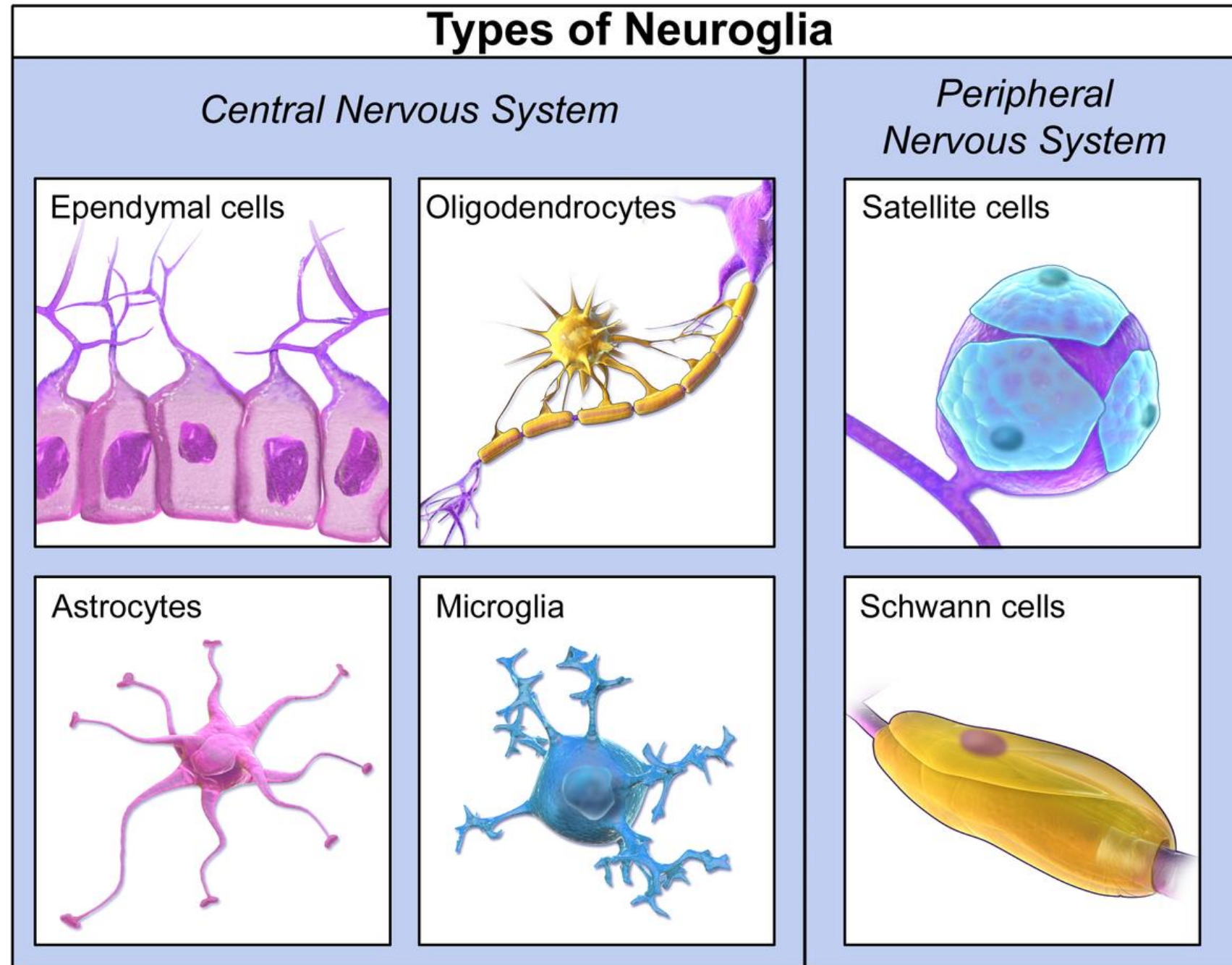
Nervous tissue composition

- Cells
 - Neurons (very heterogenous, generate impulses)
 - Glia (supporting cells)
- Extracellular matrix
 - Low amount

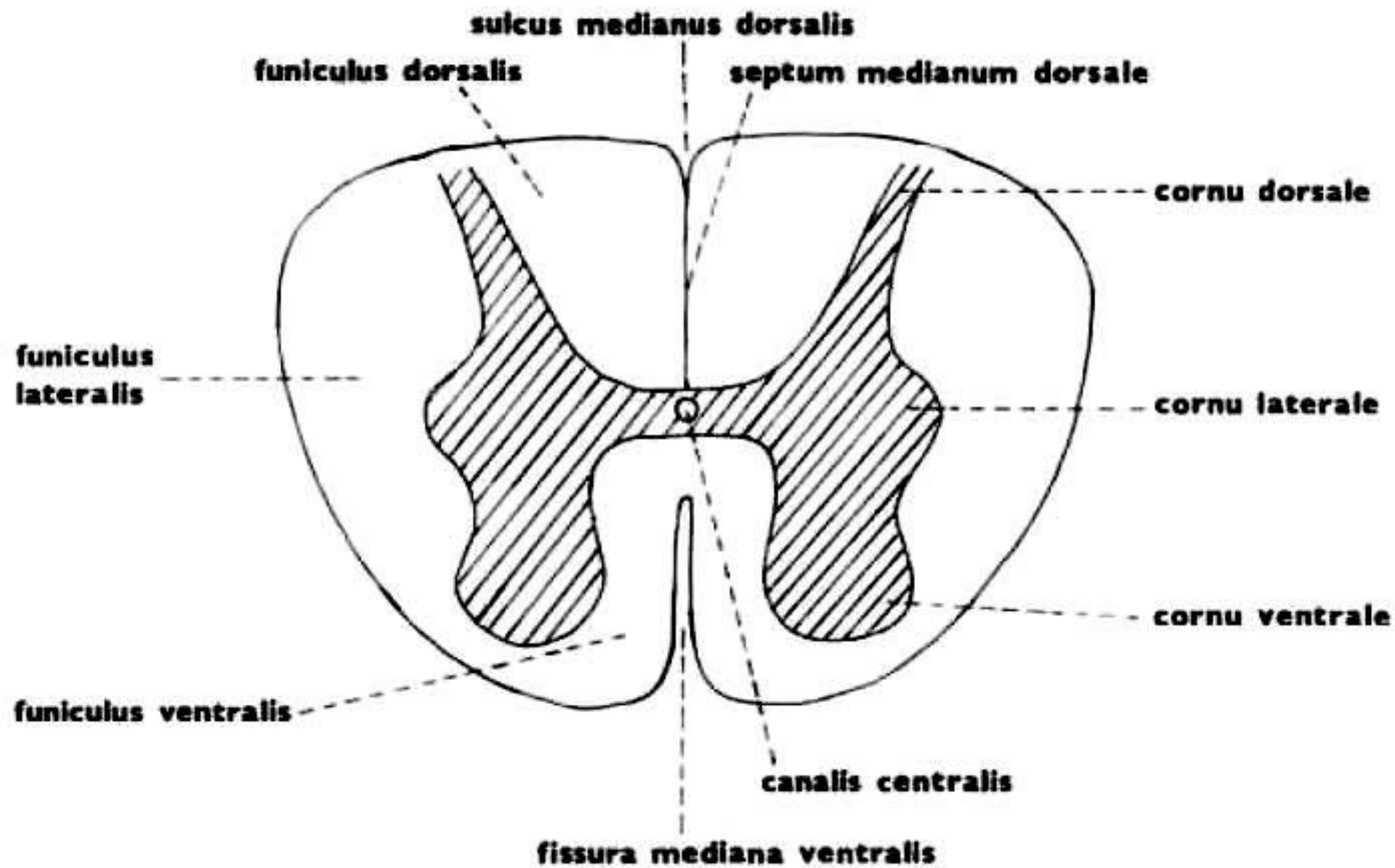


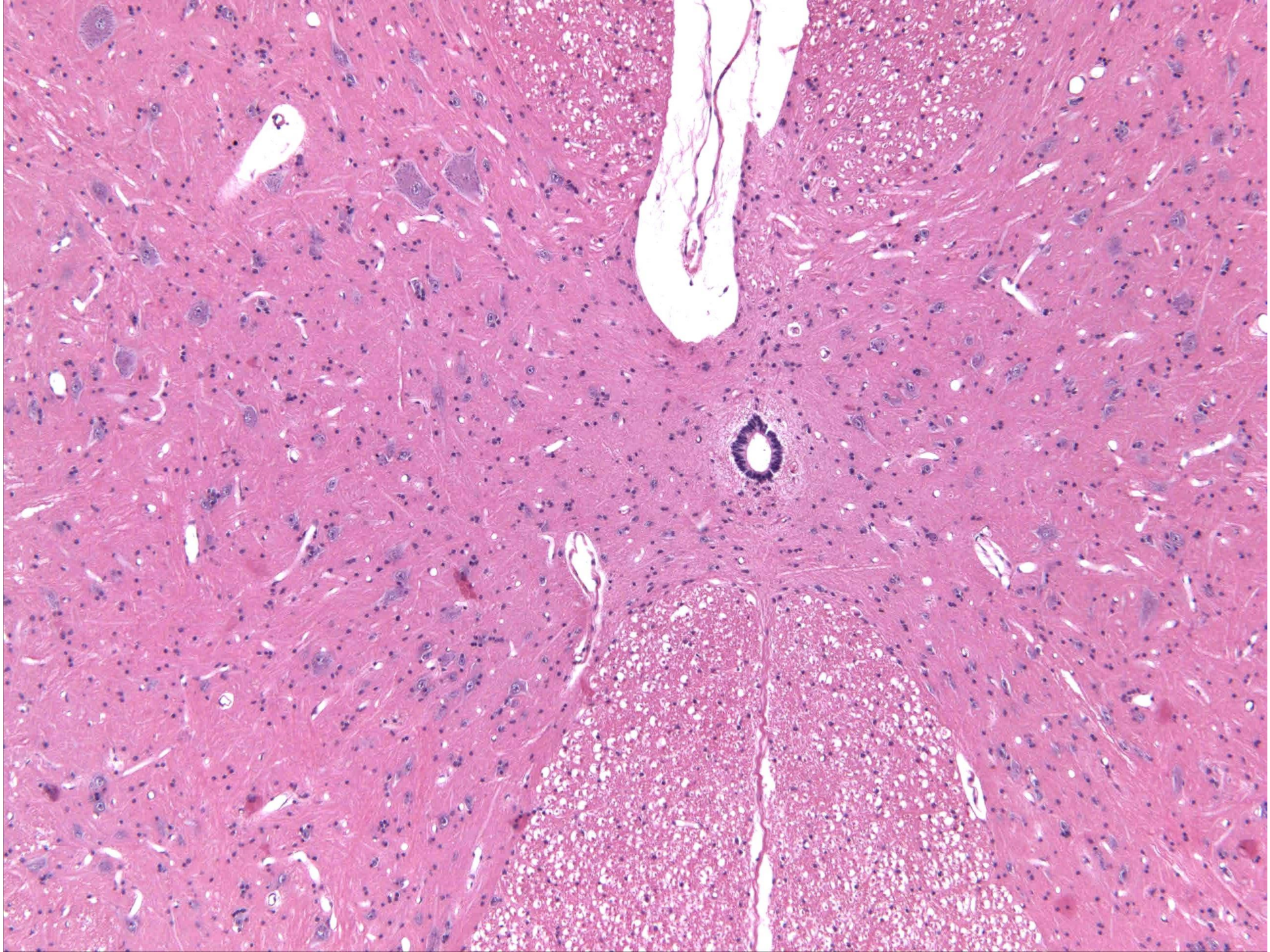
Neuroglia

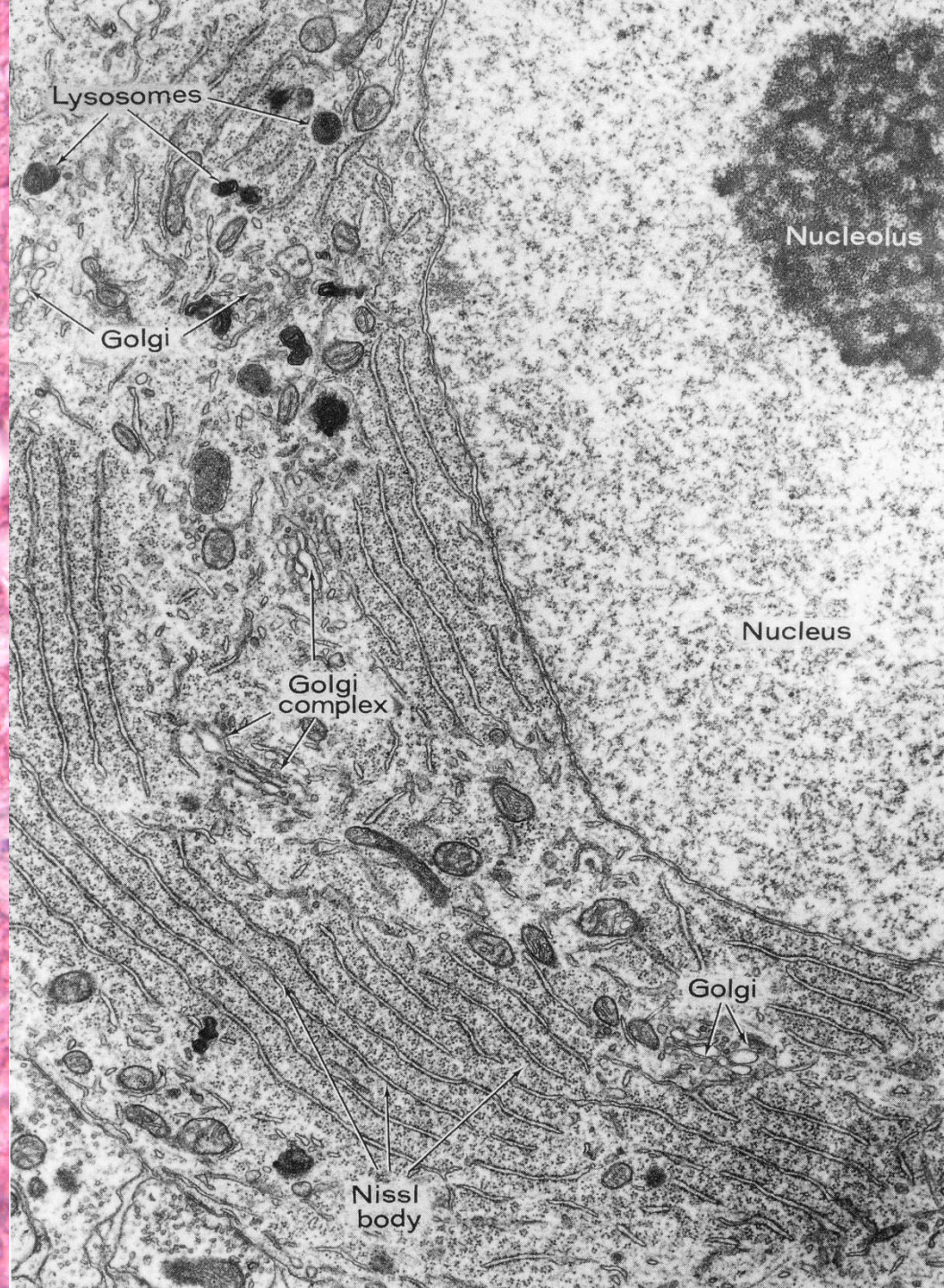
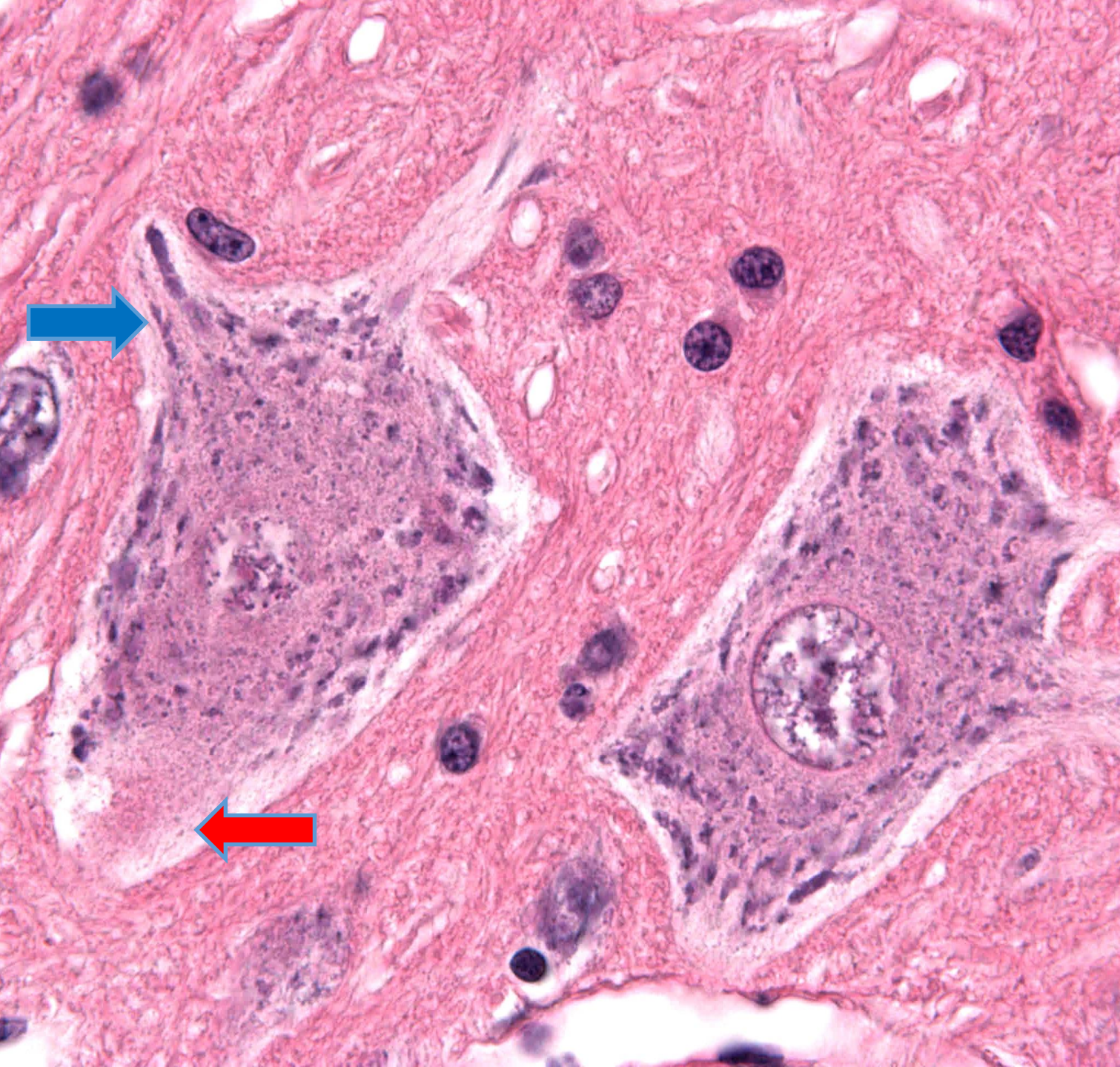
- CNS
 - Astrocytes
 - Fibrillar (white matter)
 - Plasmatic (grey matter)
 - Oligodendrocytes
 - Microglia
 - Ependymal
- PNS
 - Schwann
 - Satellite

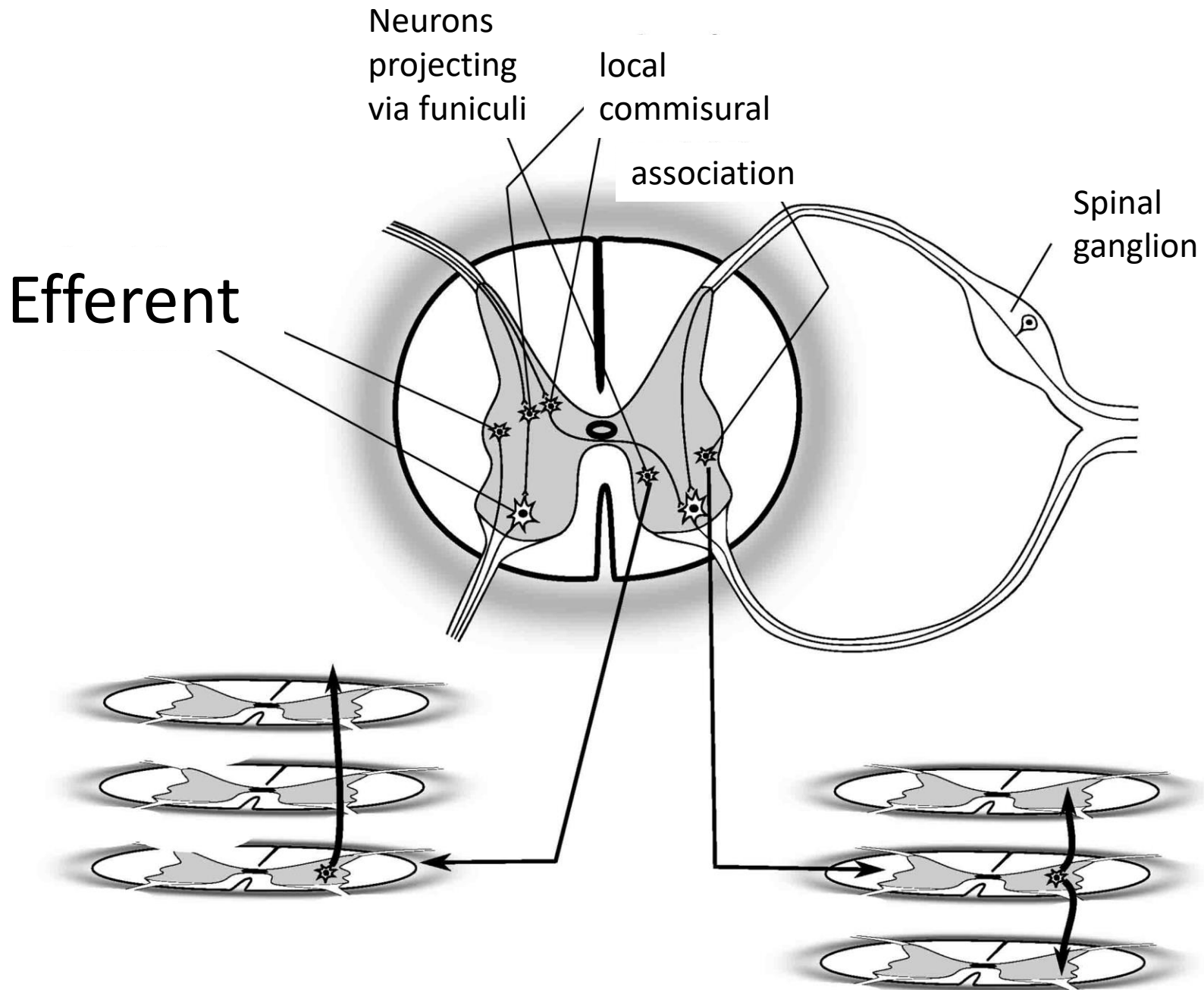


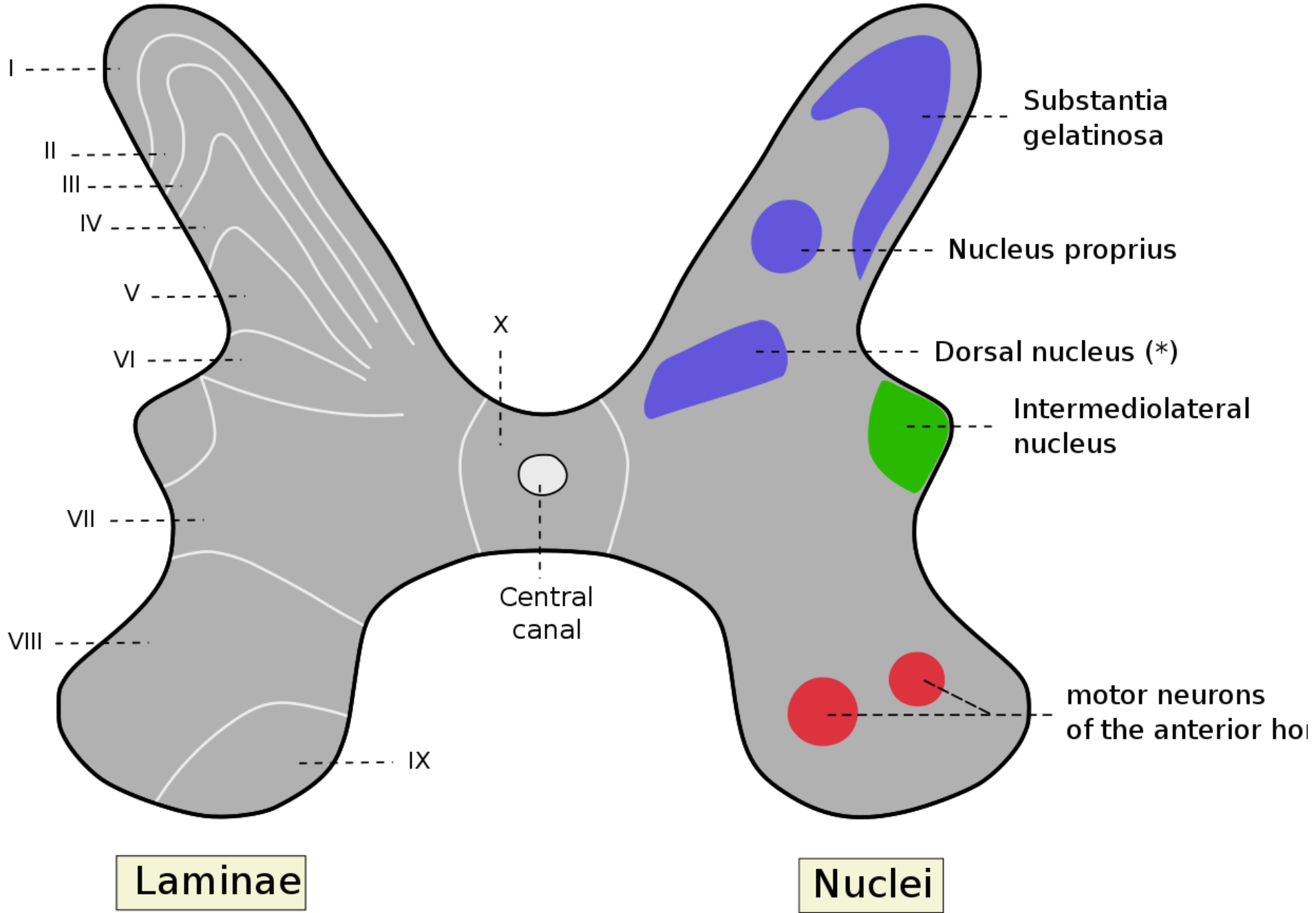
MEDULLA SPINALIS











* Posterior thoracic nucleus or Column of Clarke

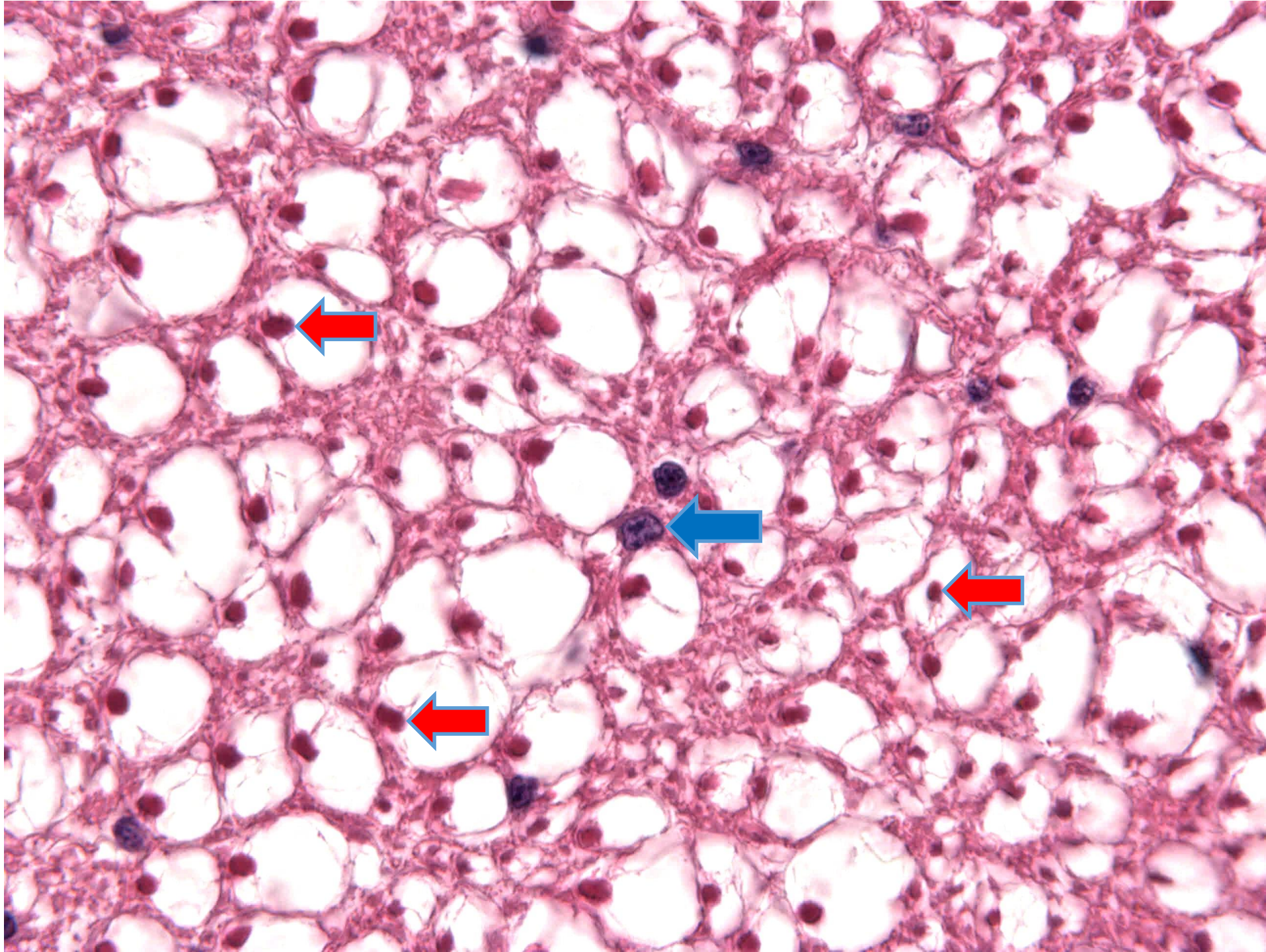
Questions

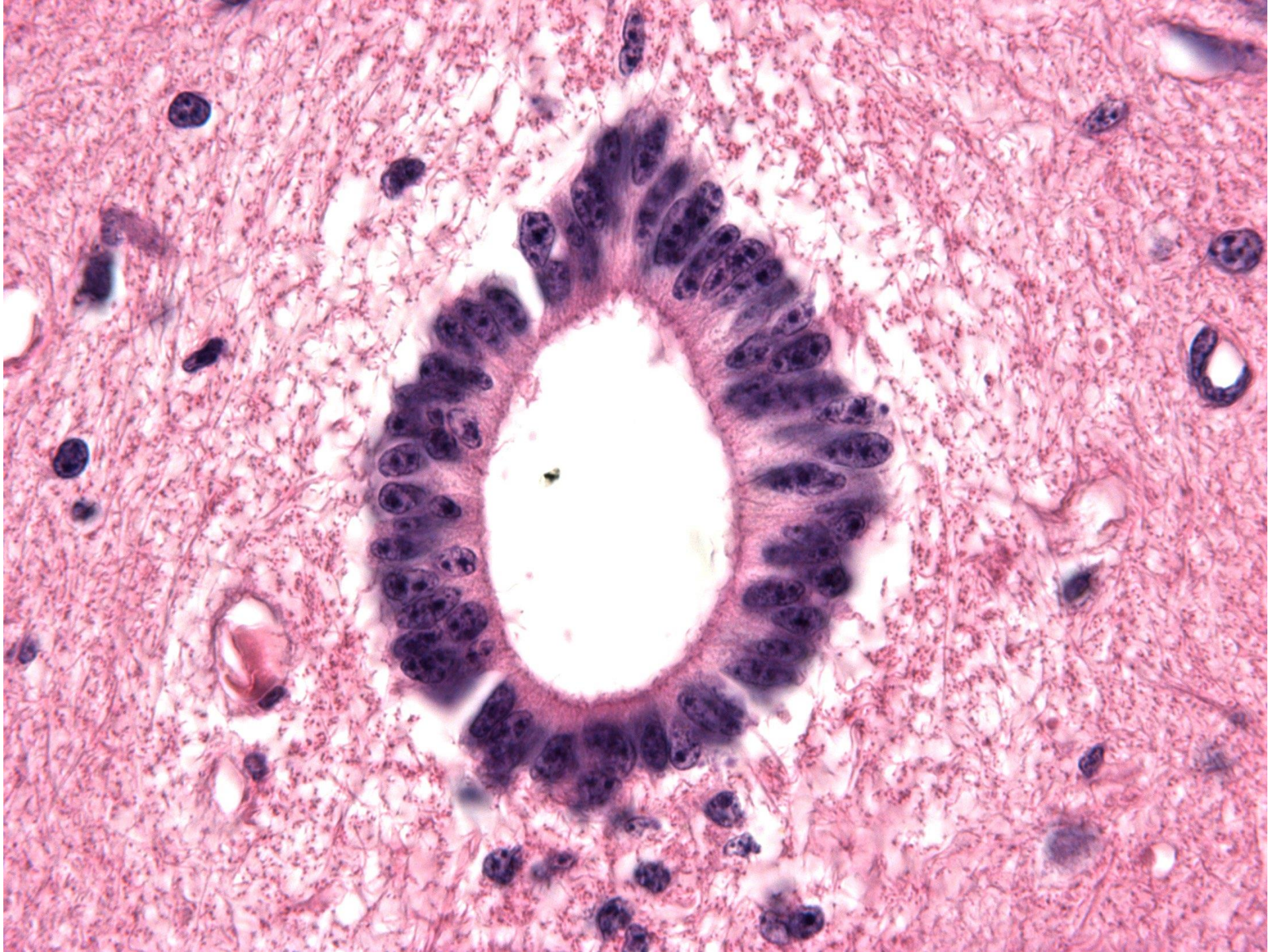
1. Do you know what viral disease affects motor neurons? Do we encounter it often?
2. What two neurons are involved in the simplest spinal reflexes?
3. What part of the spinal cord and brain is affected by multiple sclerosis? Do you know which of the cranial nerves is often affected?

Questions

1. Poliomyelitis (polio) is a viral disease with fecal-oral transmission, the most severe form of which causes paralysis. The disease has been almost eradicated by vaccination.
2. The simplest reflex arcs (e.g., patellar) consist of a pseudounipolar neuron of the dorsal spinal ganglion and an alpha-motoneuron. In the more complex ones, interneurons are also involved.
3. MS is an autoimmune inflammatory demyelinating disease affecting mostly the white matter of the CNS (grey matter can also be affected) and very often affecting the optic nerves. A similar disease with a different pathophysiological basis is neuromyelitis optica (Devic's disease).

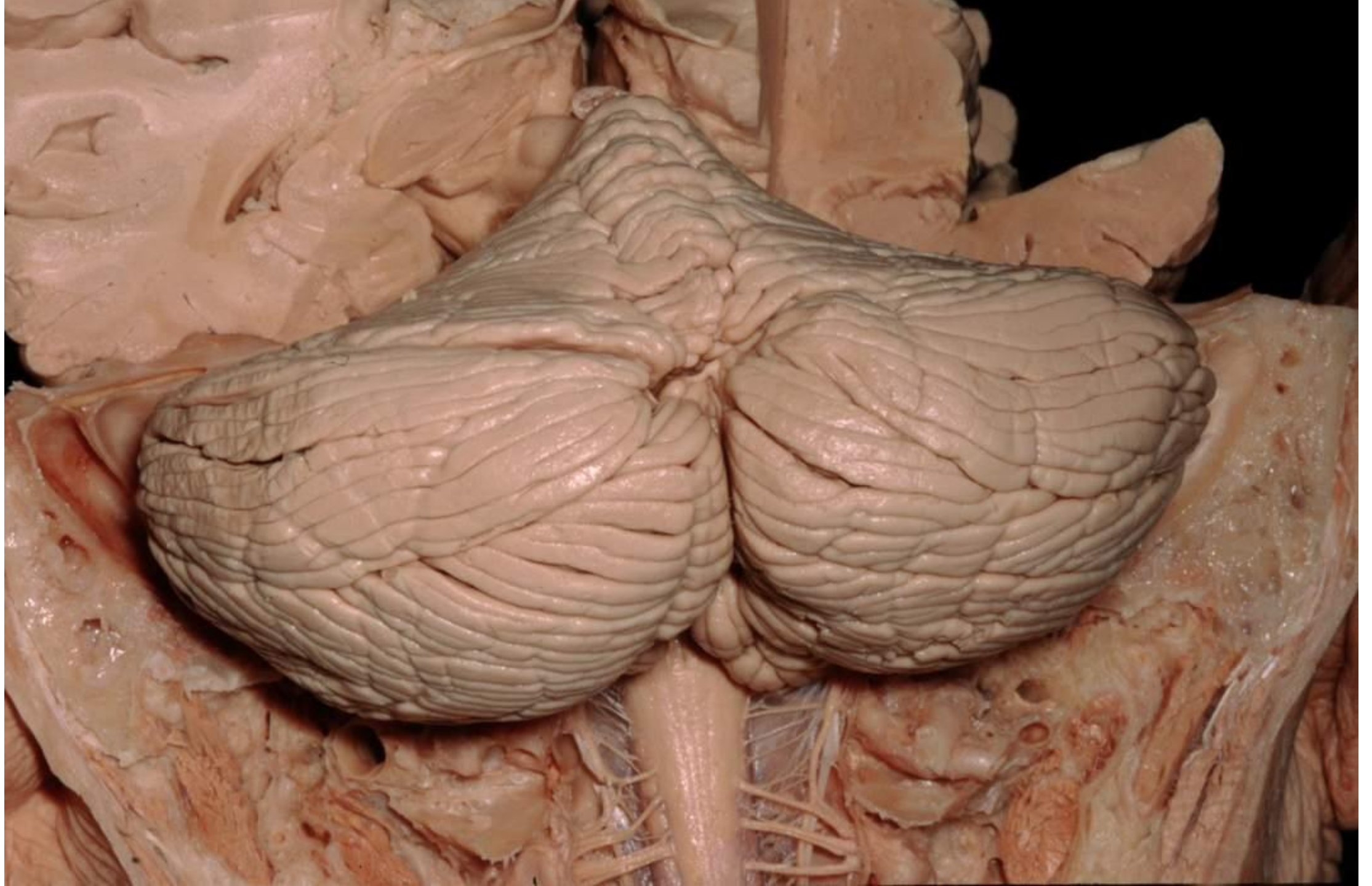
Red (axons)
Blue (oligodendrocyte)

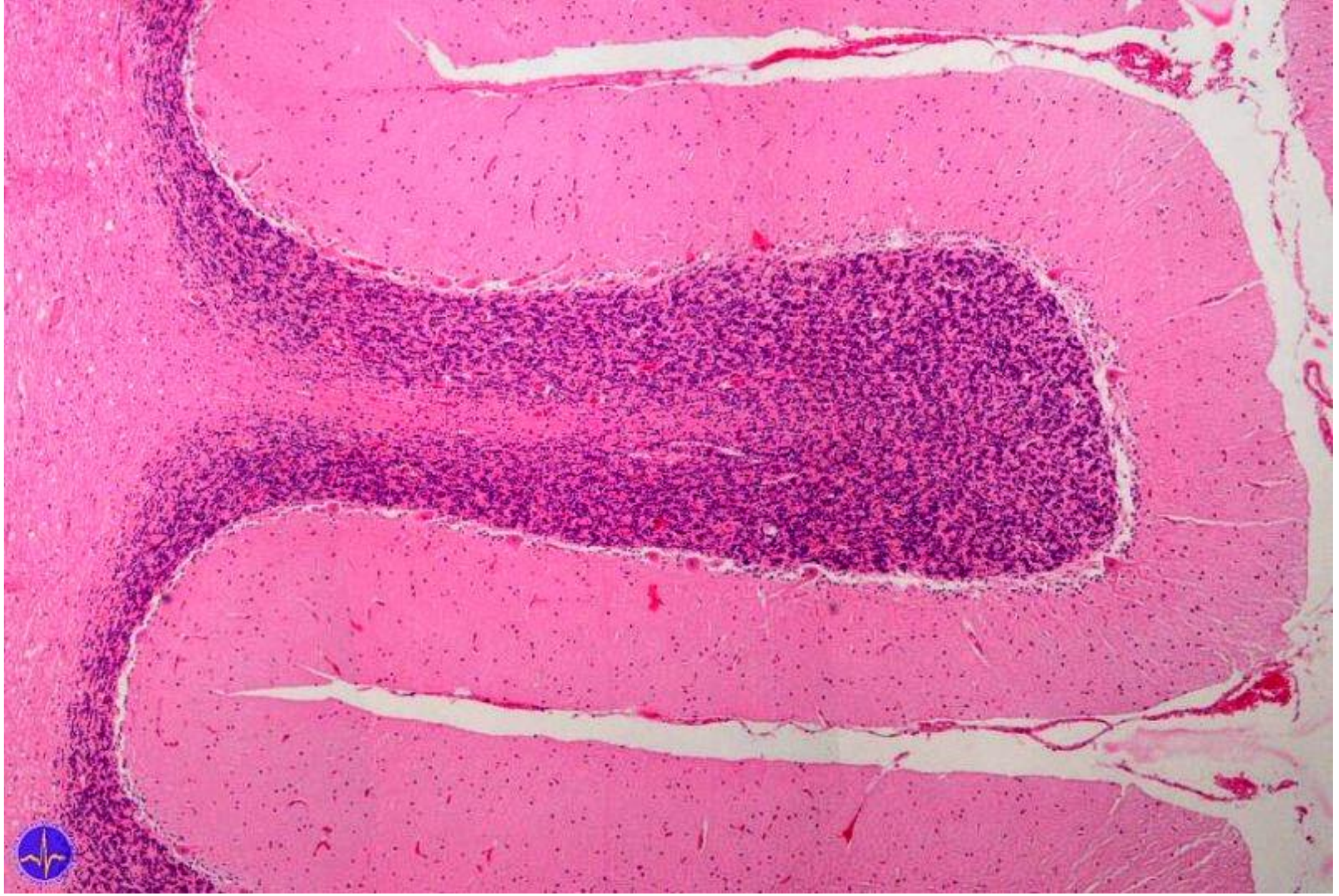

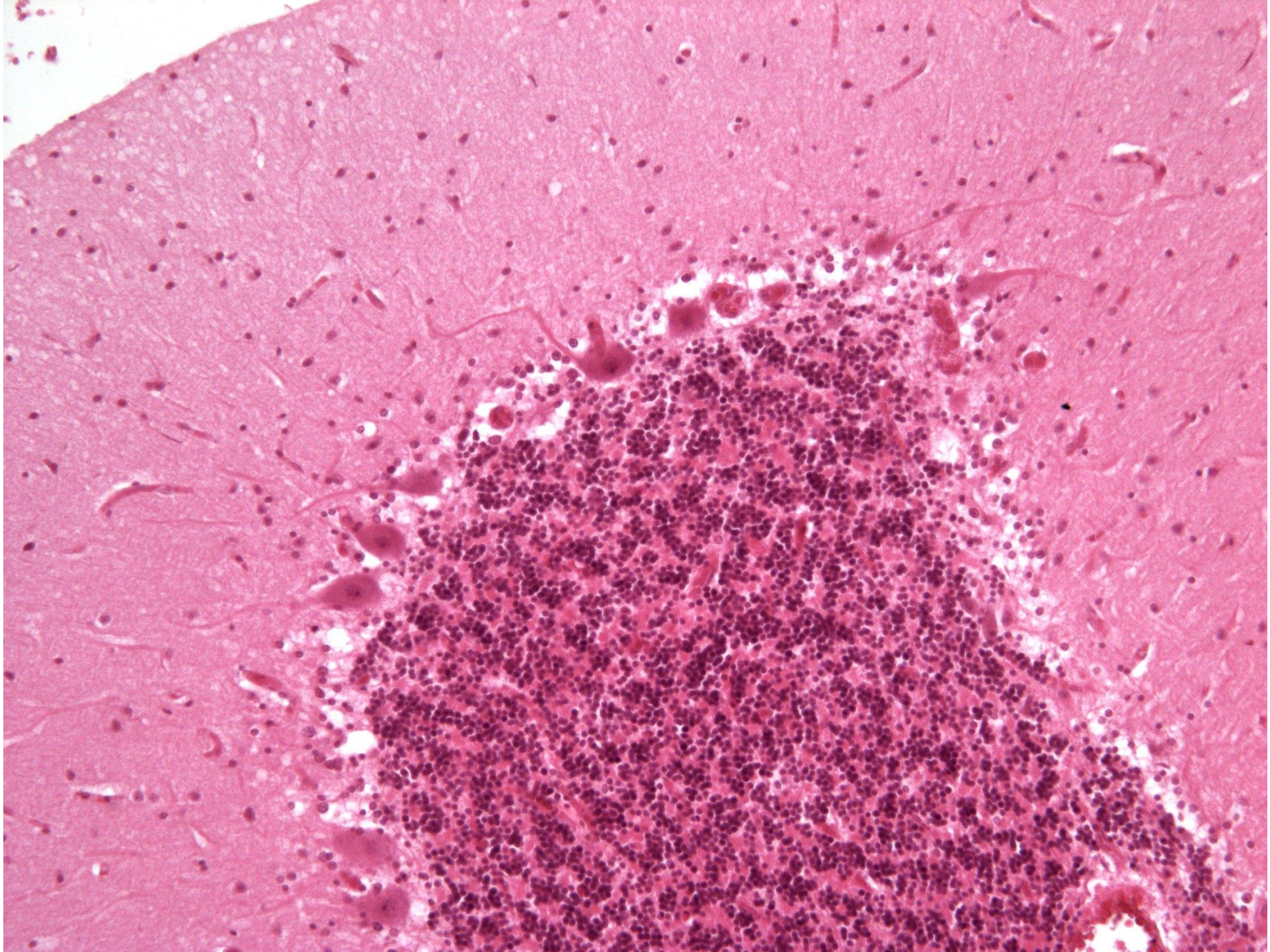


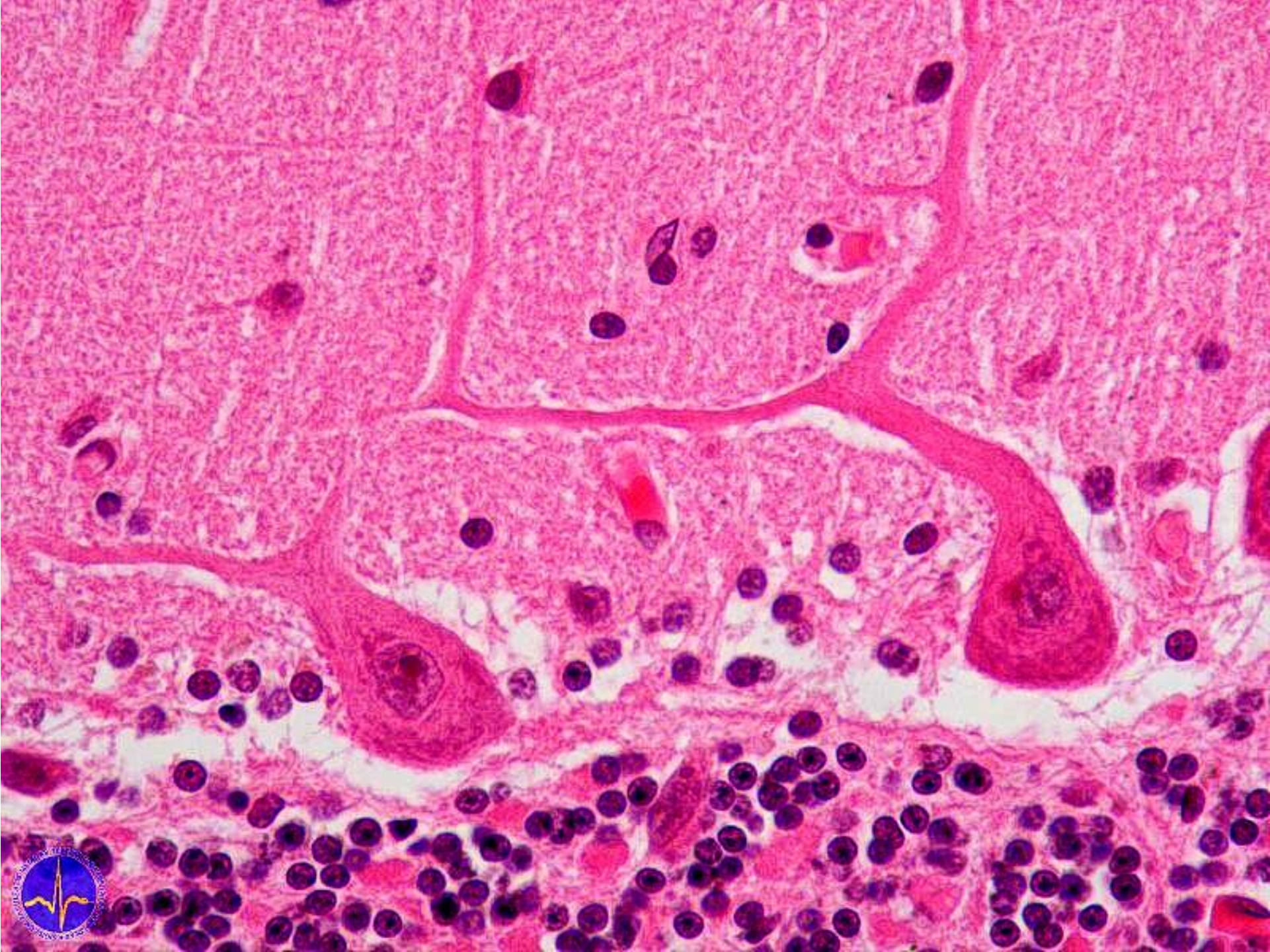
Spinal cord

- The **white matter** of the spinal cord is divided by the course of spinal root axons into **funiculi** dorsales, laterales and ventrales
- The **grey matter** contains the bodies of neurons, both motor neurons and various interneurons; the anterior, posterior and lateral horns and the commusurae griseae are described here; Rexed's laminae or spinal nuclei can also be described
- **Interneurons** perform a variety of functions, e.g. they are involved in spinal reflexes, provide coordination of muscle groups or transmit sensory information to the brain (e.g. tractus spinothalamicus), thus they are divided into connecting (associative, commissural and local)
- The **central canal** is lined with ependymal cells, which resemble the epithelium in their arrangement, but differ in many ways from the epithelium, e.g. they do not have a basal lamina



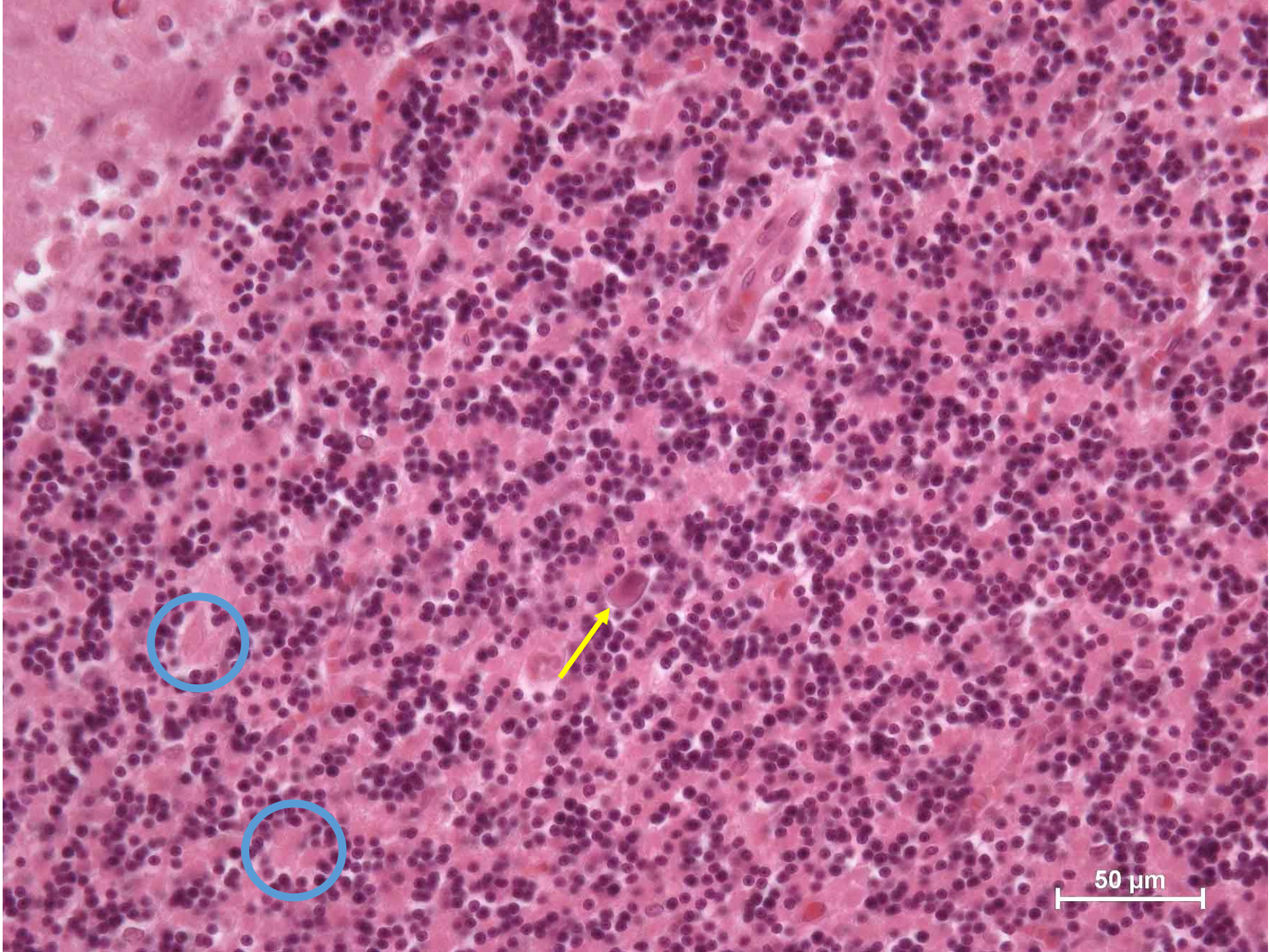






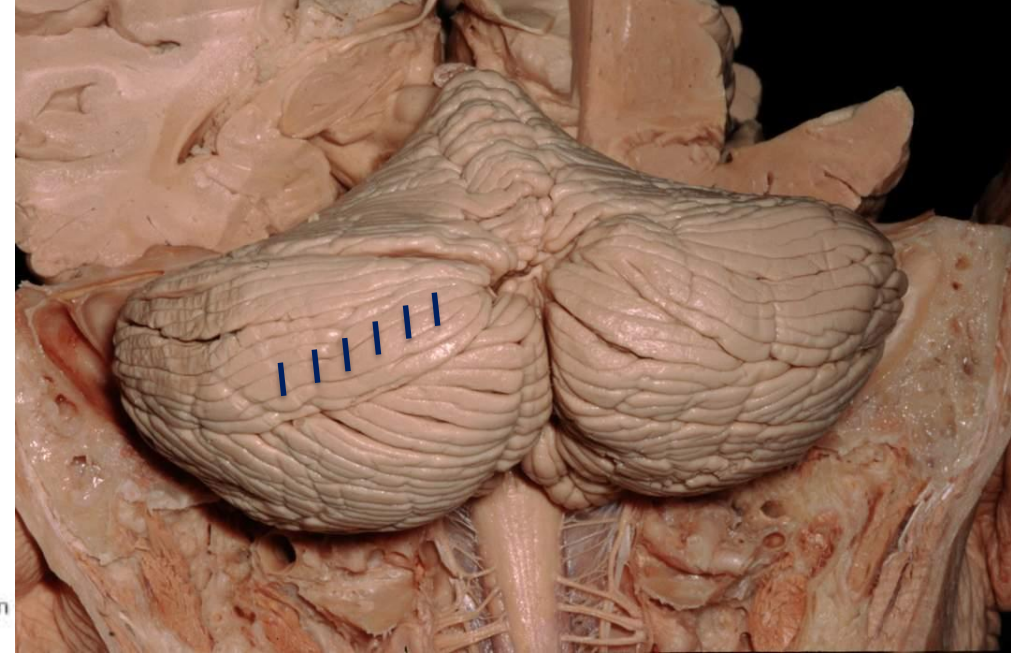
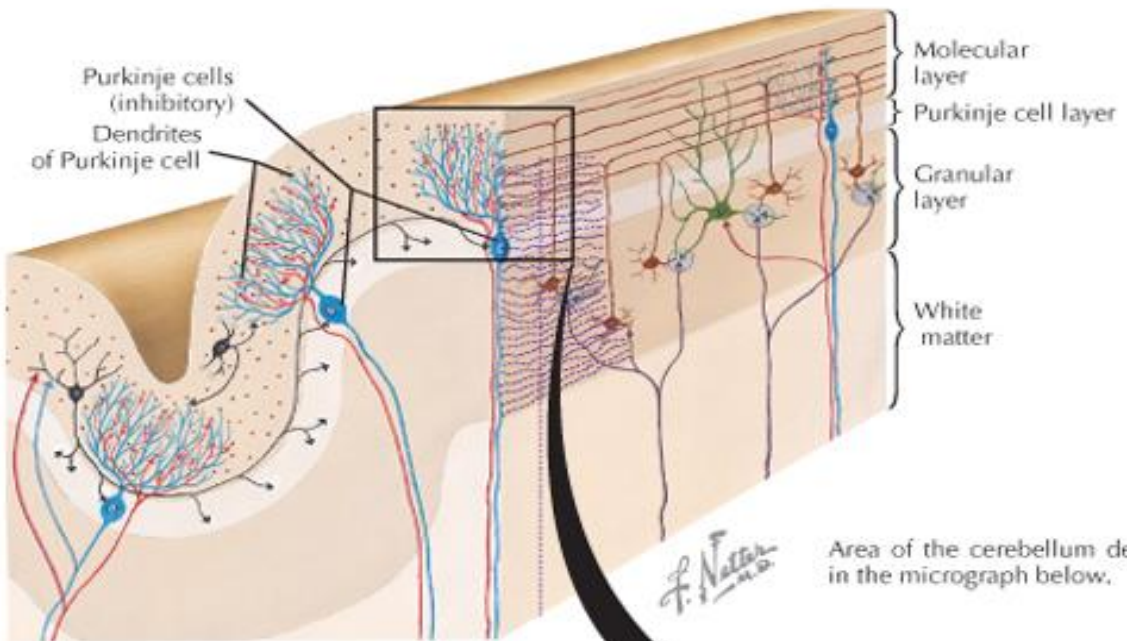
Golgi
neuron
(yellow)

Cerebellar
glomeruli
(blue)



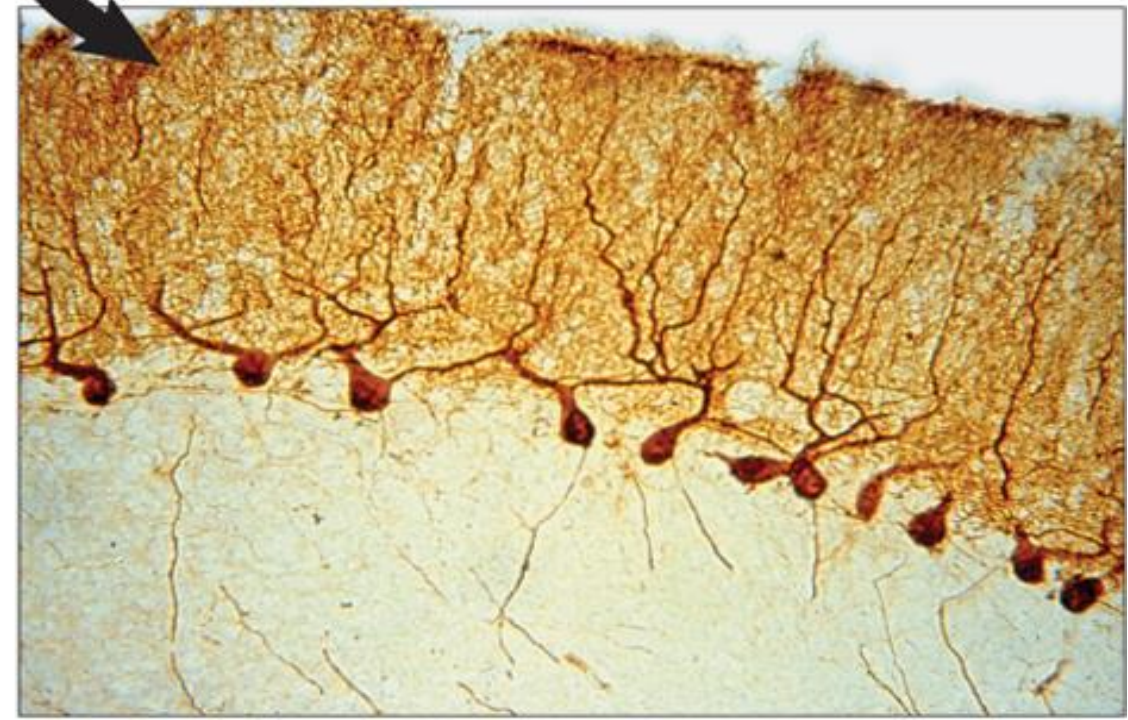50 μ m

Types of neurons in the cerebellar cortex.



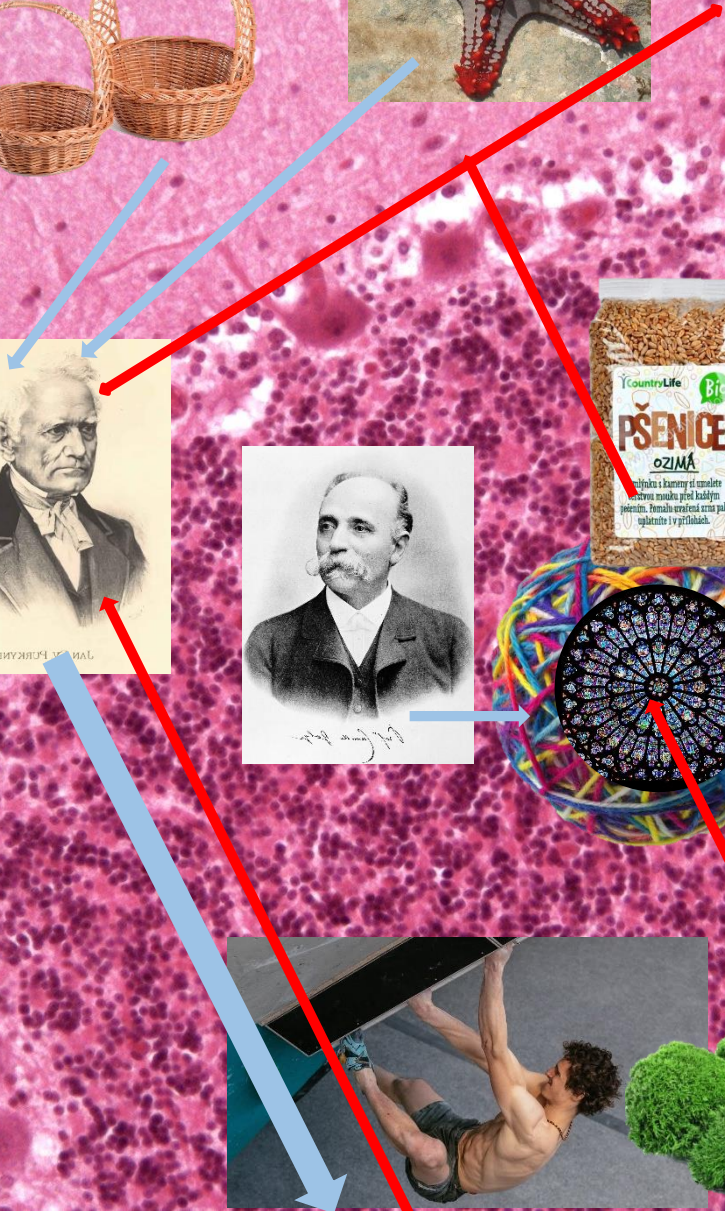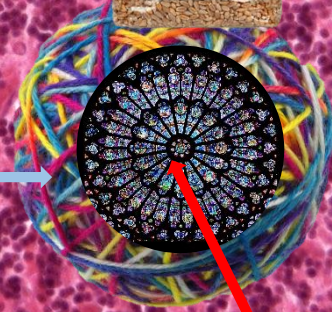


F. Netter M.D.

Area of the cerebellum delineated by the rectangle is seen in the micrograph below.



► **Immunocytochemical staining of Purkinje cells in the cerebellar cortex.** An antibody to parvalbumin selectively labels Purkinje cells, so that their cell bodies, basal axons, and elaborate apical fan-like dendritic tree are clear. 135x. Immunoperoxidase-diaminobenzidine. (Courtesy of Dr. K. G. Bainbridge)





Cerebellum

Cortex

- Stratum **moleculare** – basket cells, stellate cells
- Stratum **gangliosum** – Purkinje cells
- Stratum **granulare** – Golgi cells, granular neurons

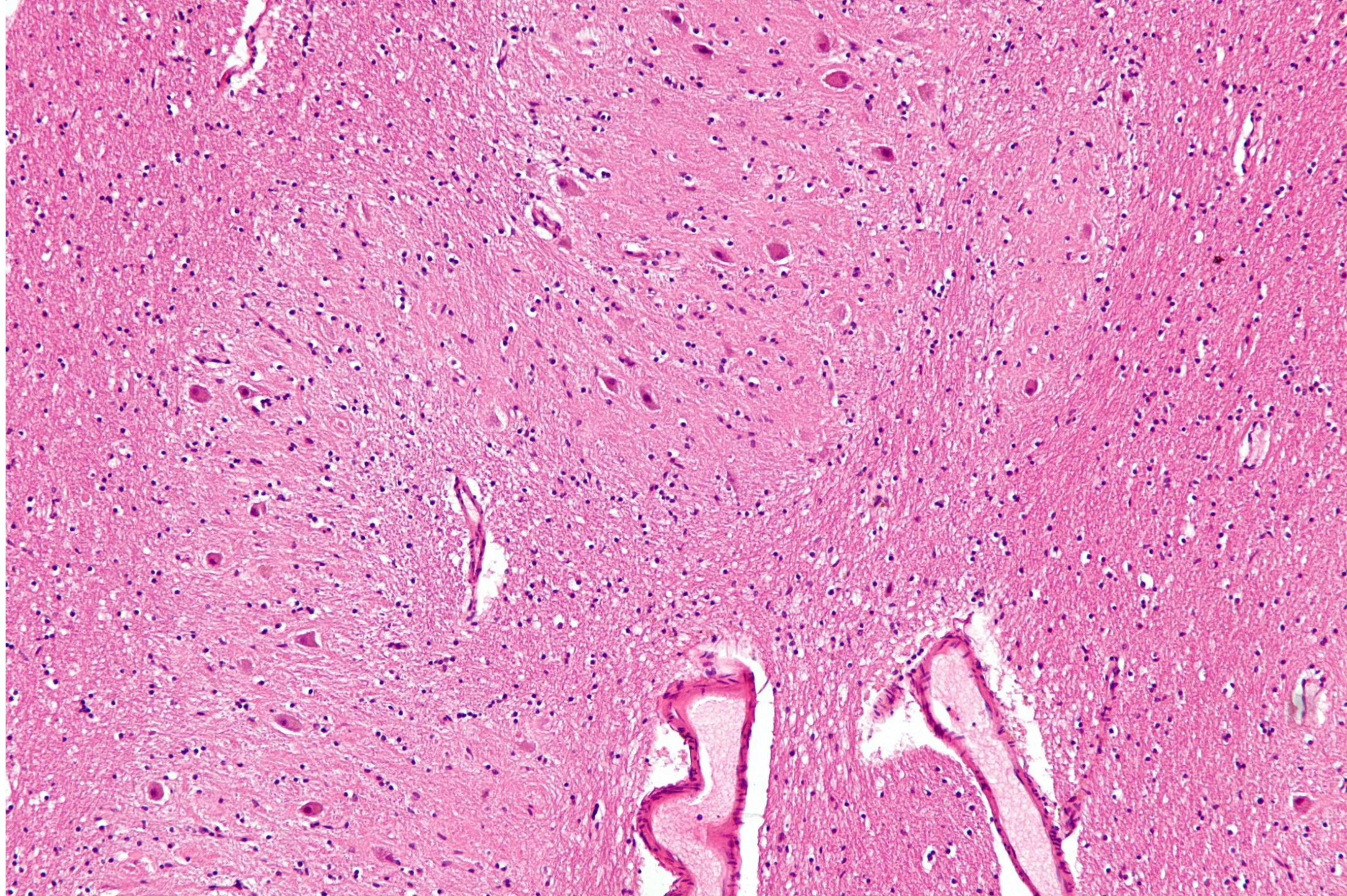
White matter

- **Mossy fibers** (e.g. from nuclei pontis) and **climbing fibers** (from oliva inferior)
- **Axons of Purkinje cells** ending in nuclei cerebelli
- Axons from the nuclei cerebelli

Nuclei cerebelli

- Nucleus fastigii, nc. emboliformis, nc. globosus, nc. dentatus

5 neurons, 4 nuclei, 3 layers, 2 fibers, 1 output

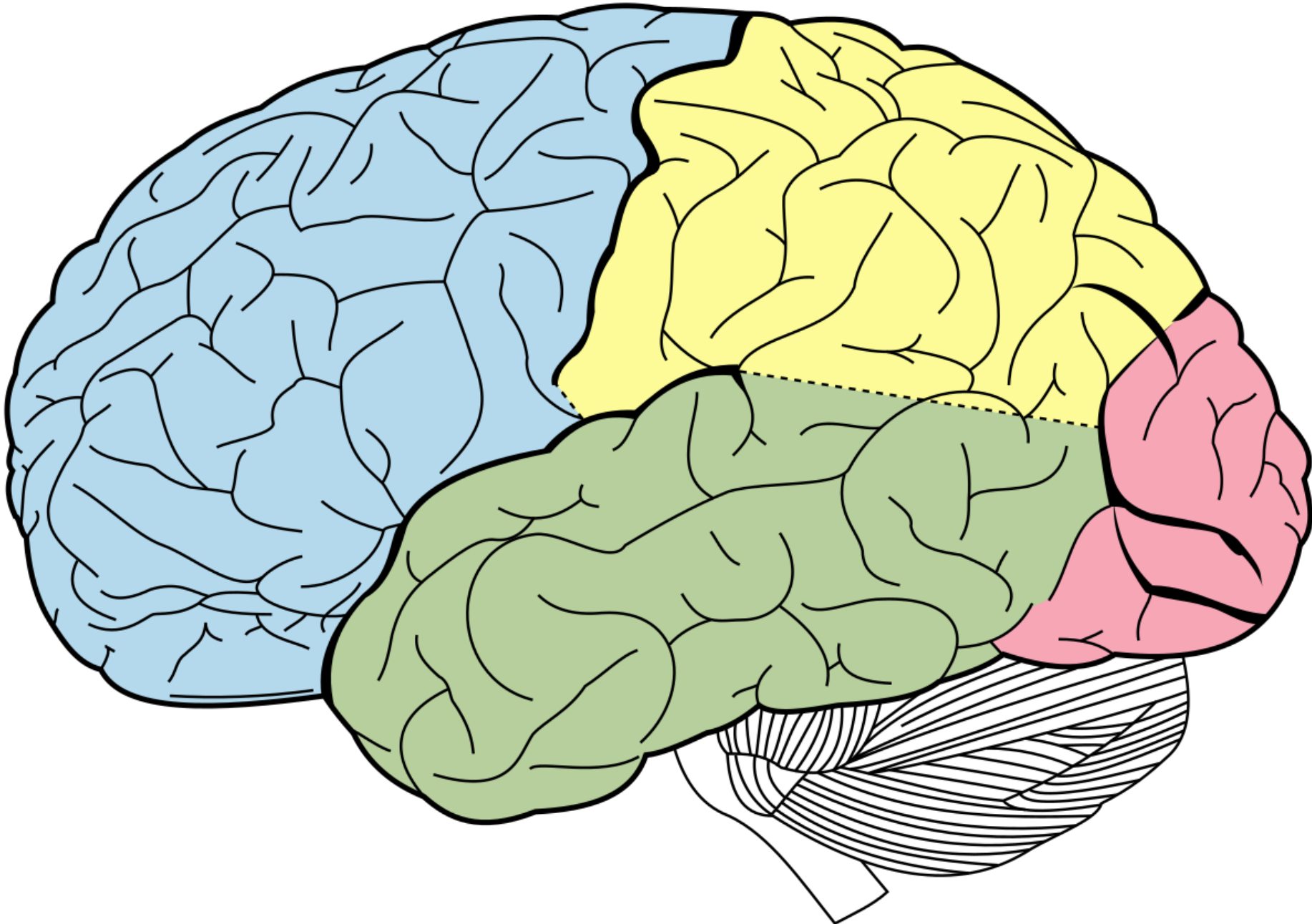


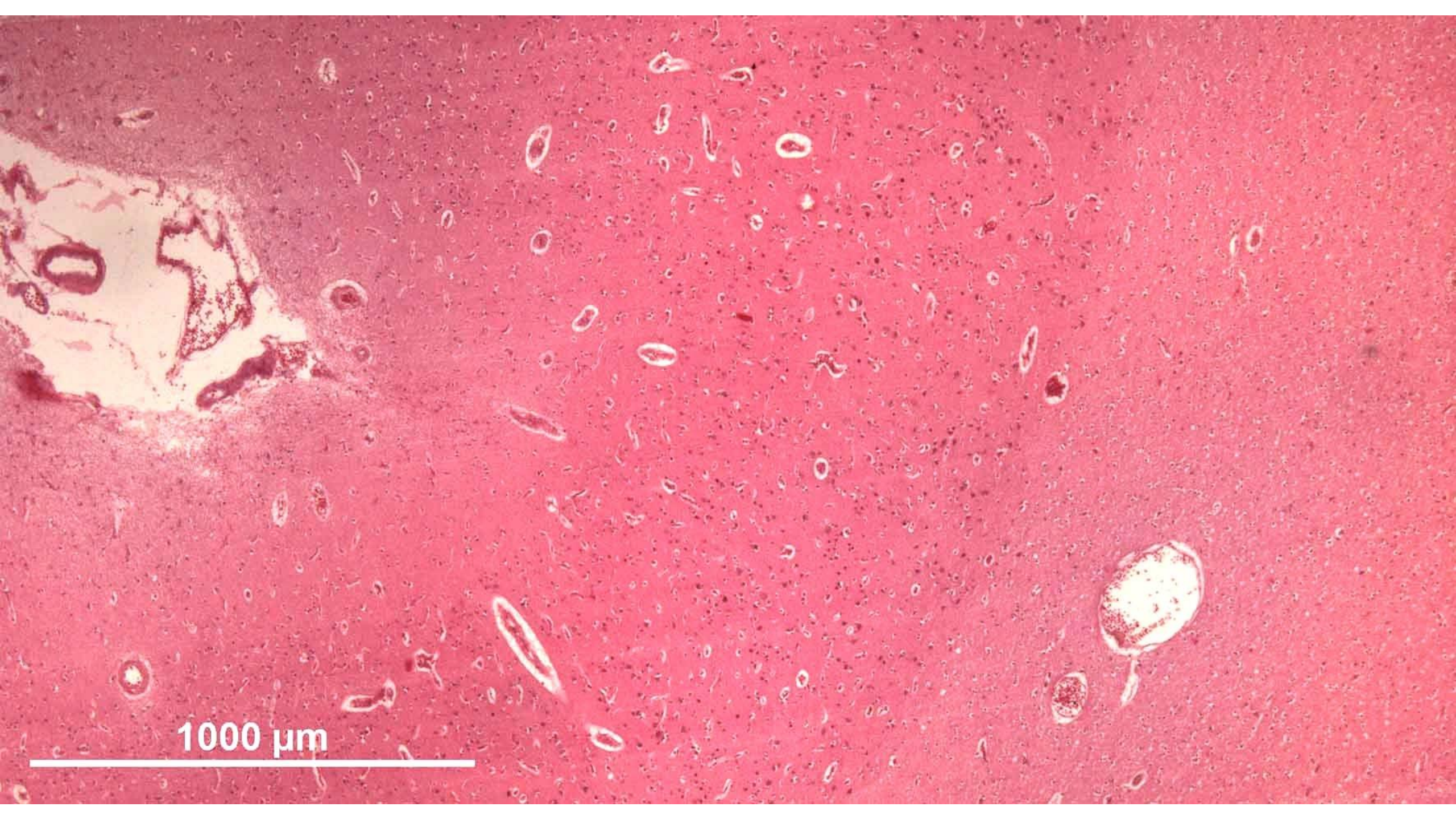
Tasks and questions:

1. Rank the following structures in ascending order of the number of Purkinje cells with which they make synaptic contacts: climbing fibers, basket cells, mossy fibers, parallel fibers
2. How does damage to the cerebellum manifest itself? Do you know what frequently used addictive substance causes cerebellar syndrome?
3. What do the words glomus and glomerulus mean? Try to list the structures of the human body with this name.

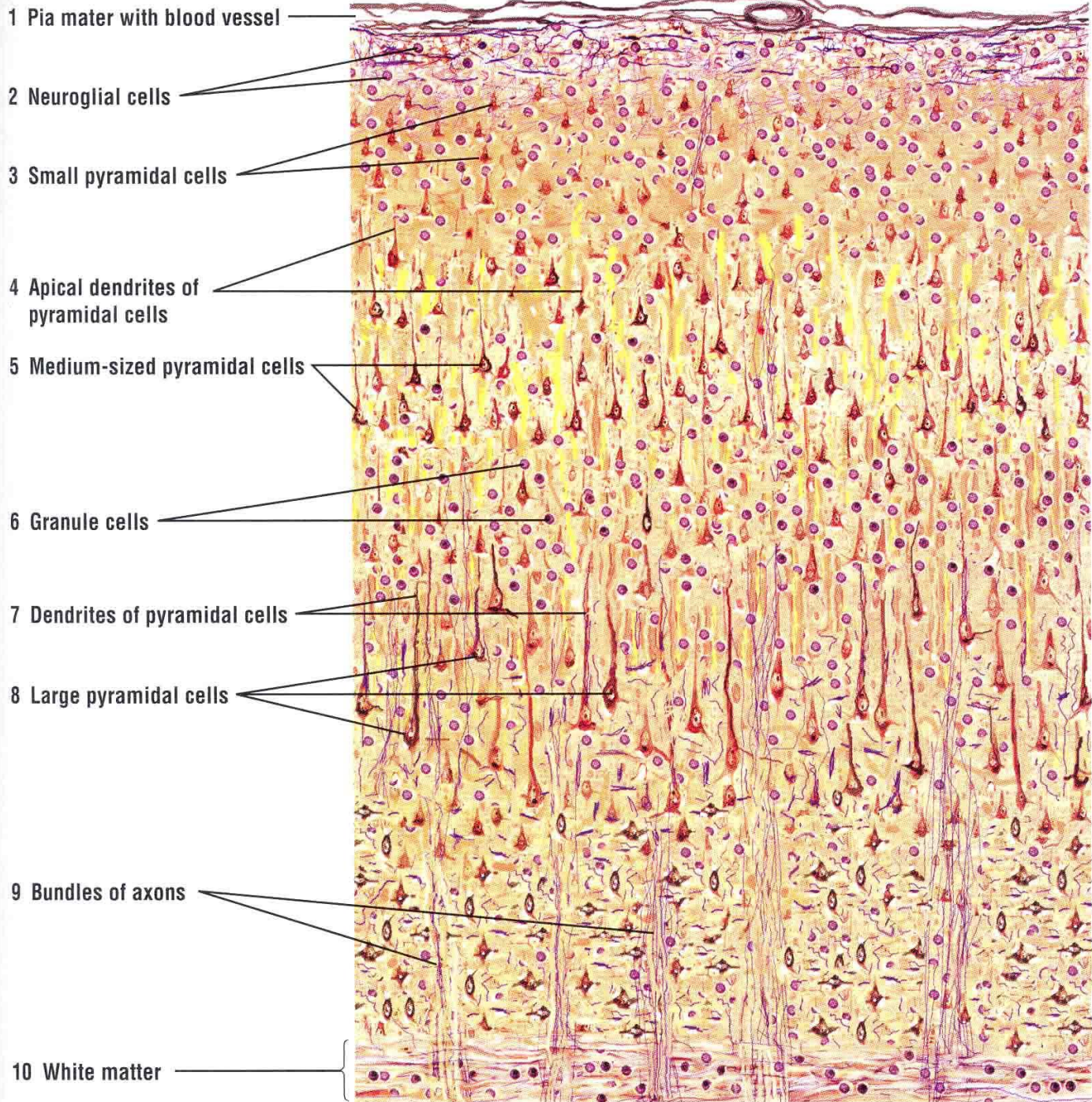
Tasks and questions:

1. Mossy fibres (0), climbing fibres (1), basket cells (10-12), parallel fibres (up to 500)
2. Damage to the cerebellum is manifested by impaired stability, imbalance, impaired coordination of movements (symptoms include ataxia, adiadochokinesis, rebound phenomenon, tremor, dysarthria...). Alcohol has a negative effect on the cerebellum both in acute intoxication and in long-term use.
3. Ball (of yarn), e.g., glomus caroticum (chemoreceptor in the arteria carotis), renal glomerulus, cerebellar glomerulus, glomerulus olfactorius (contact of axons of olfactory sensory neurons and mitral cells in the bulbus olfactorius)





1000 μm



1 Pia mater with blood vessel

2 Neuroglial cells

3 Small pyramidal cells

4 Apical dendrites of pyramidal cells

5 Medium-sized pyramidal cells

6 Granule cells

7 Dendrites of pyramidal cells

8 Large pyramidal cells

9 Bundles of axons

10 White matter

molecularis

granularis externa

pyramidalis externa

granularis interna

pyramidalis interna

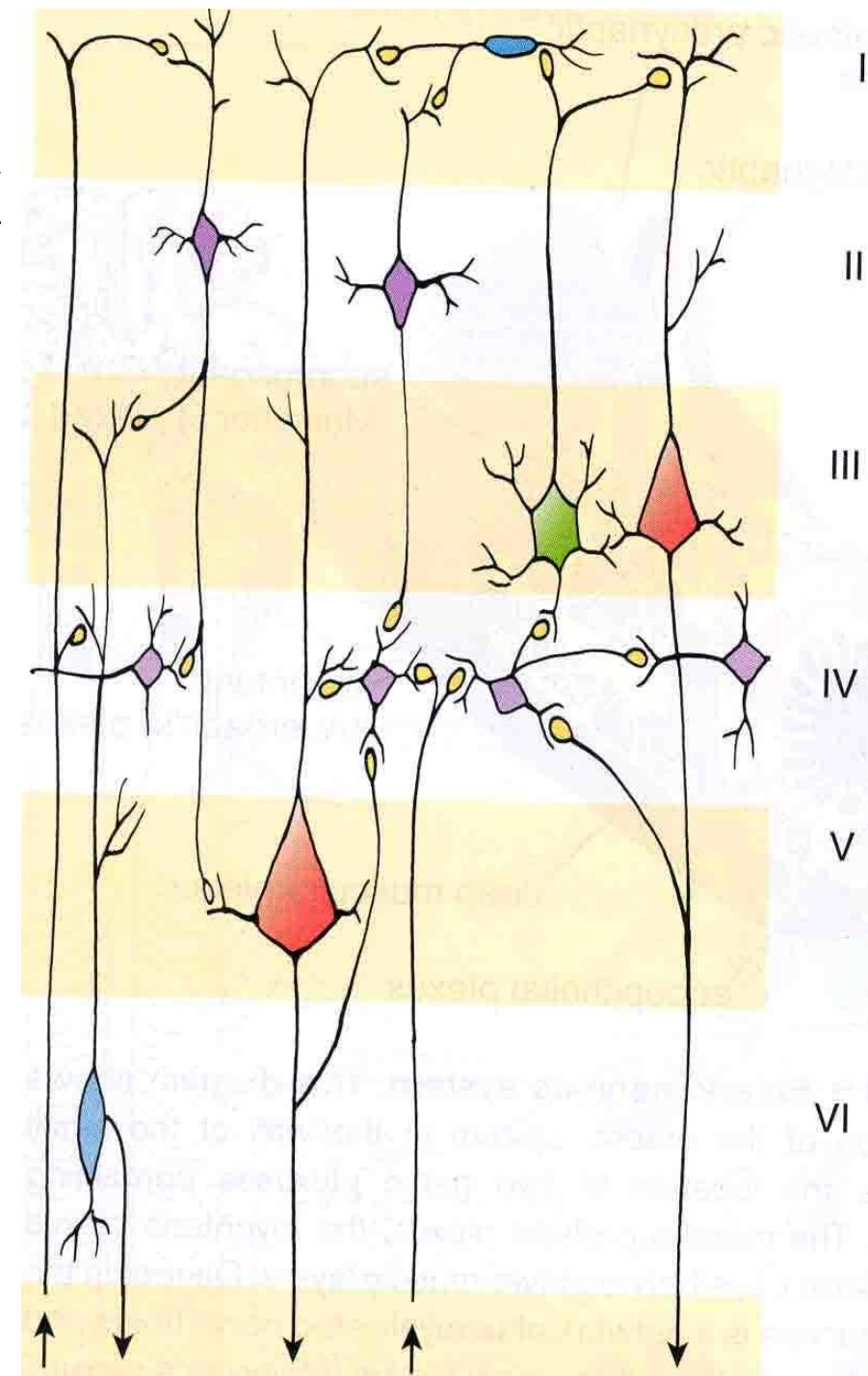
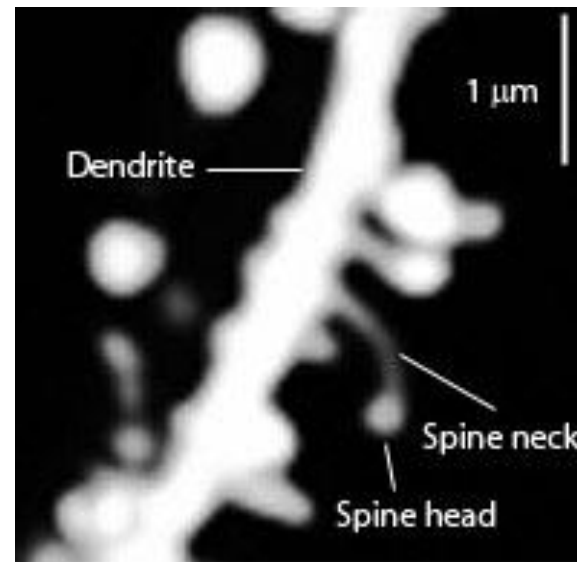
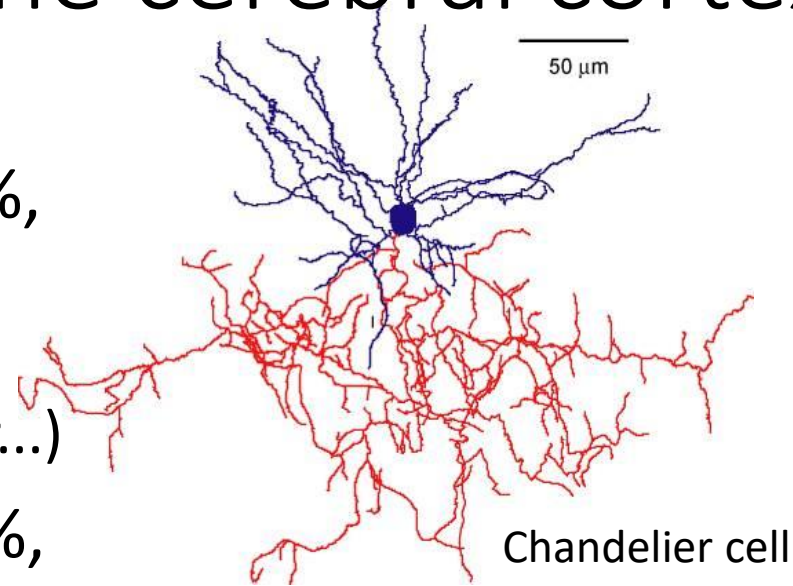
multiformis

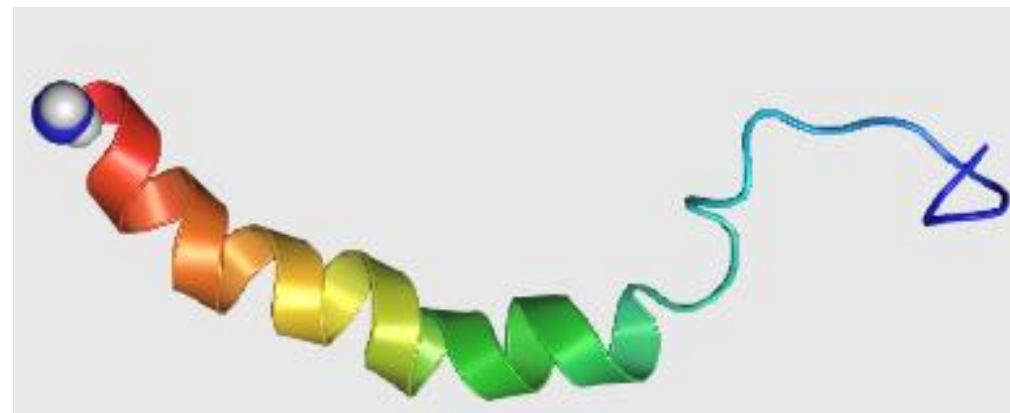
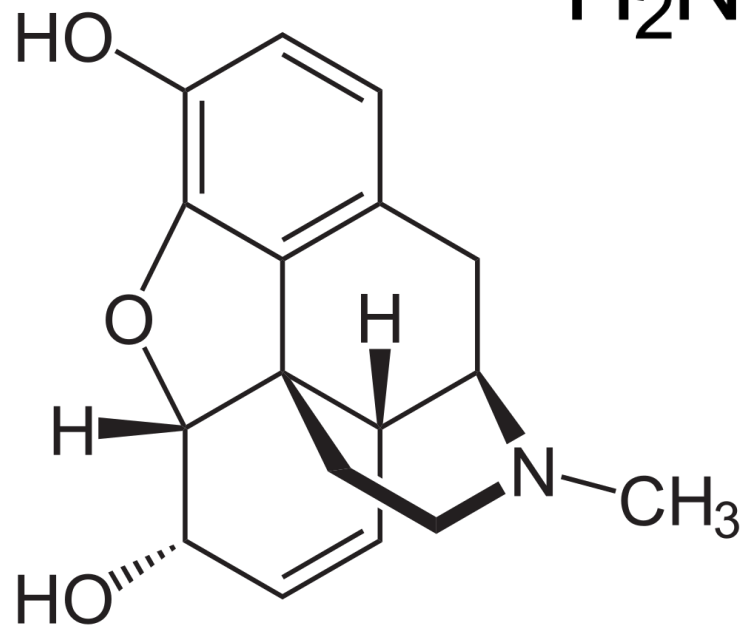
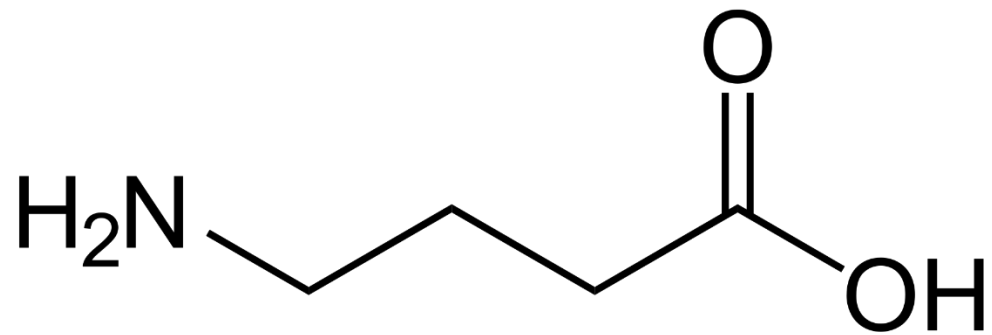
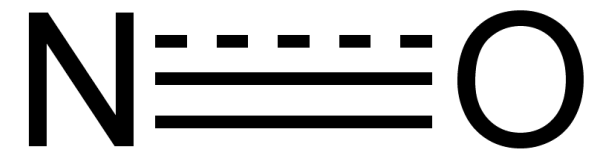
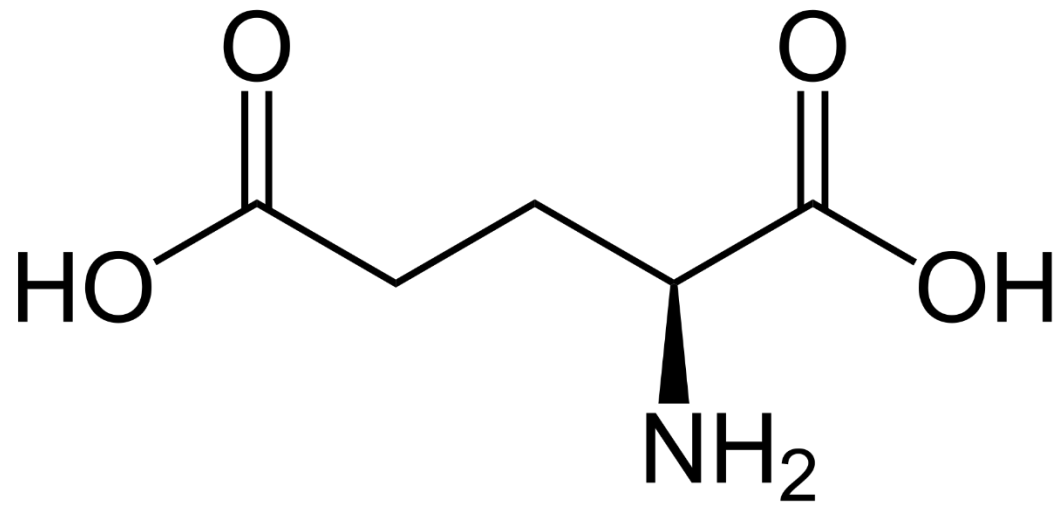
**Cortex
(grey matter)**

White matter

Neurons of the cerebral cortex

- Inhibitory (20 – 30%, **GABA**)
 - Multitude of types (basket, chandelier...)
- Excitatory (70 – 80%, **glutamate**)
 - Pyramidal
 - Stellate with dendritic spines



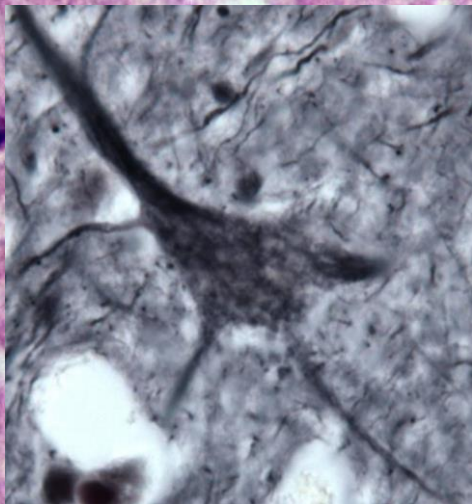
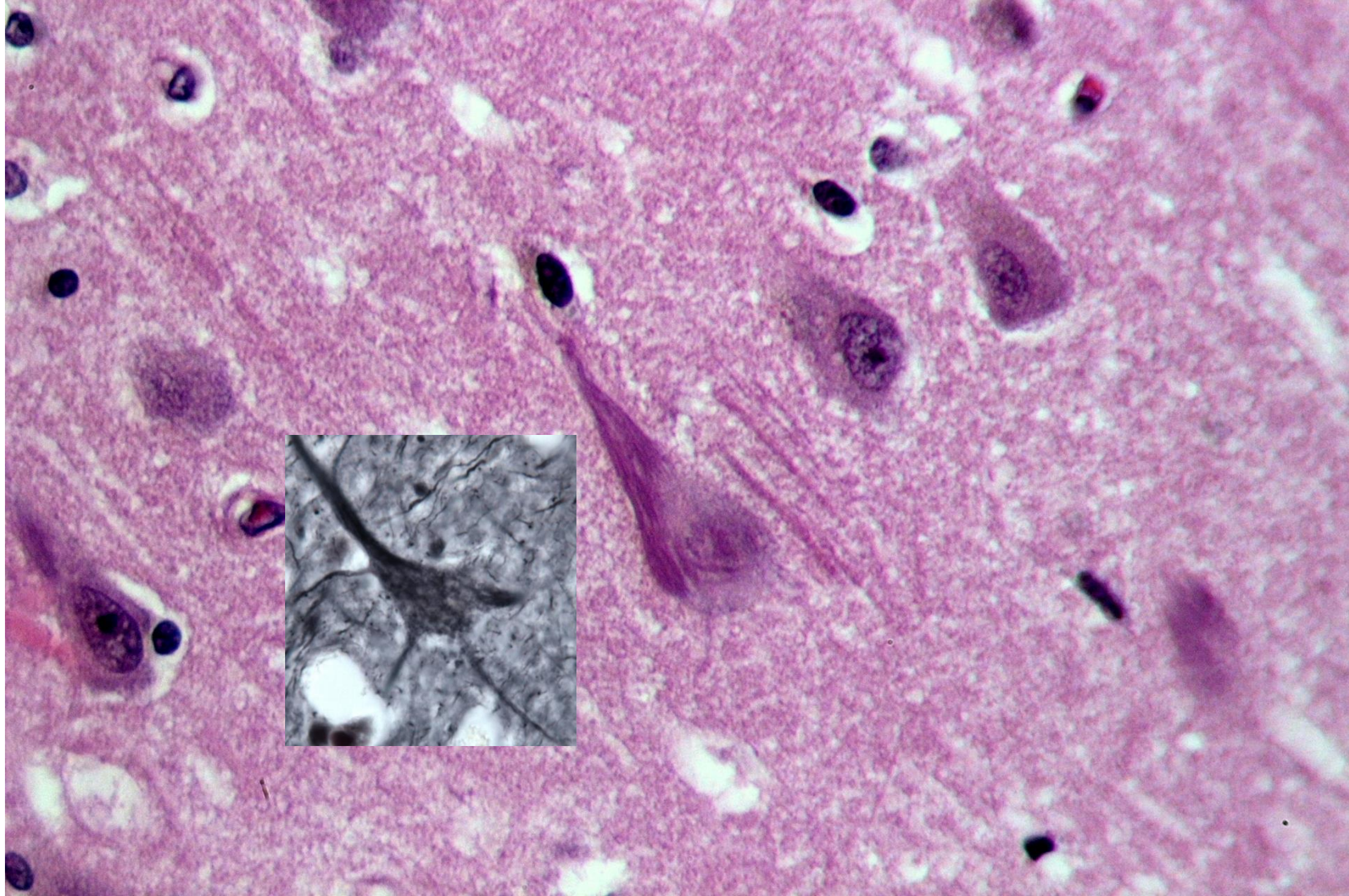


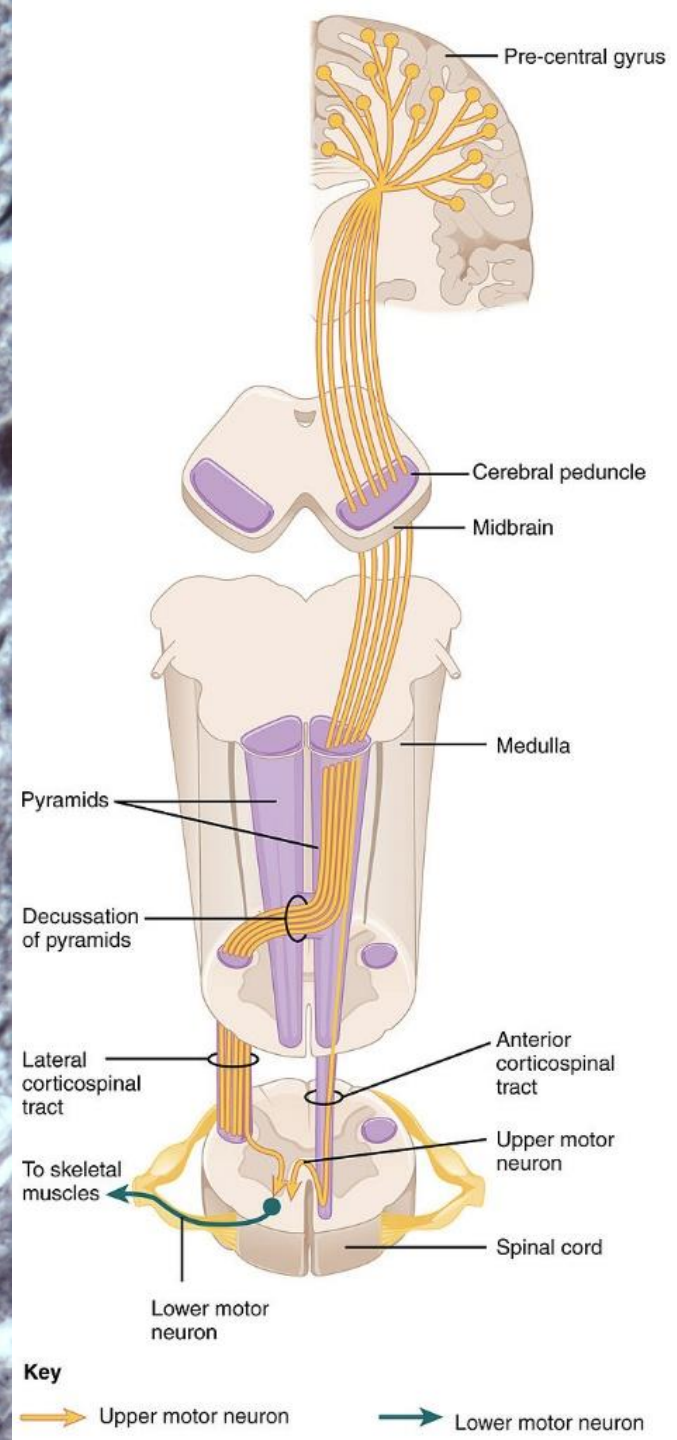
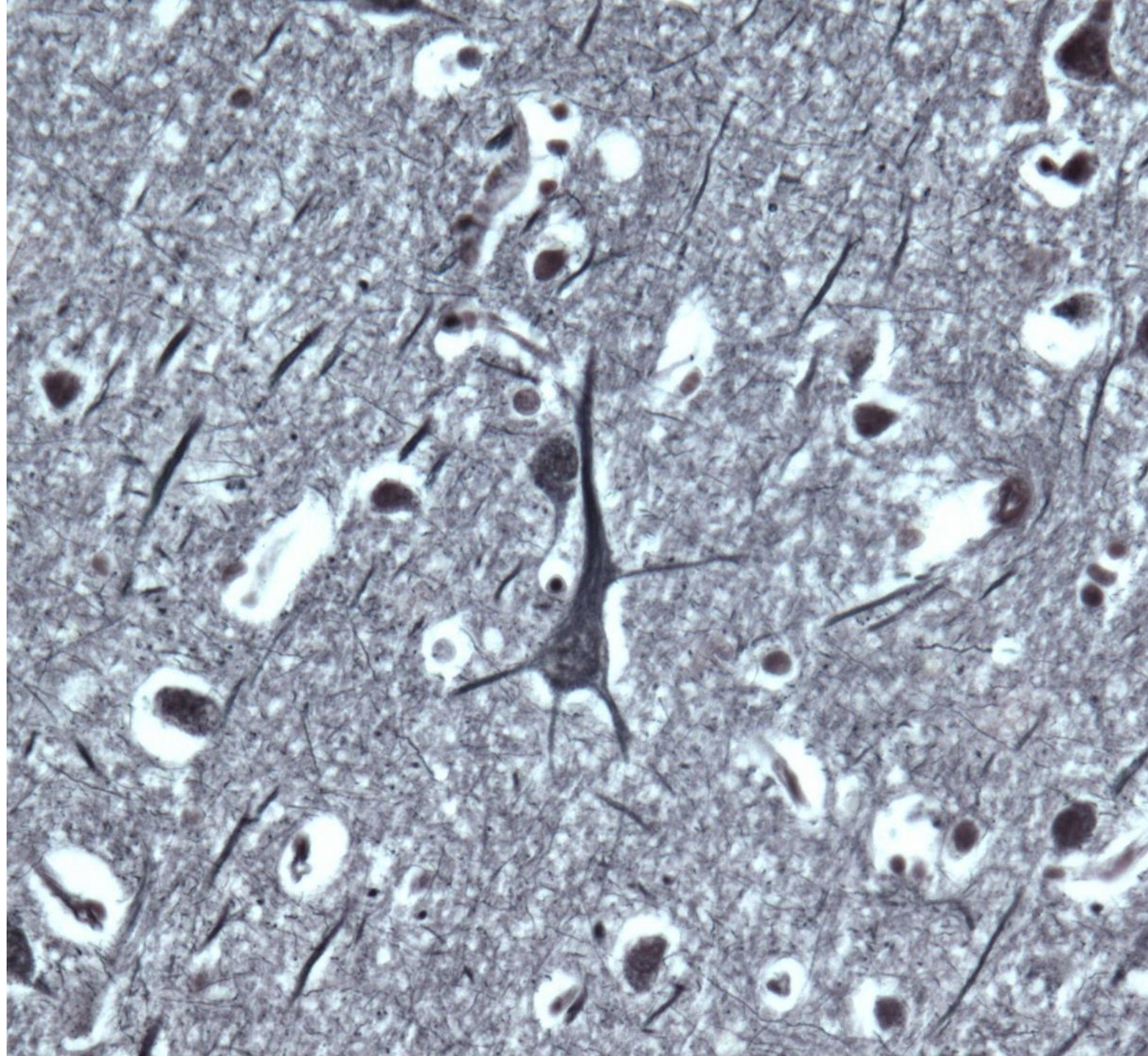
Questions:

1. What do you think is the ratio of excitatory to inhibitory neurons in the mouse? Are there more or fewer inhibitory neurons than in humans?
2. What is the function of the basket cells in the cerebellum? In which layer are they located?
3. Are pyramidal neurons found in layers other than the lamina pyramidalis externa et interna?
4. What is the main output of the cerebral cortex towards the other parts of the CNS and other cortical areas?

Questions:

1. The proportion is usually reported to be around 15 percent in the mouse, but in primates the proportion is generally between 20 and 30 percent, and in some specific parts up to around 40 percent of inhibitory neurons have been found.
2. They inhibit several Purkinje cells and thus modulate their function. They are located in the stratum moleculare.
3. Yes, the smaller pyramidal neurons are found in both the granular lamina and the lamina multiformis.
4. Projections to other parts of the CNS are mainly axons of large pyramidal cells in lamina V and VI, while connections with other cortical areas (association or commissural) come most often from lamina II and III.





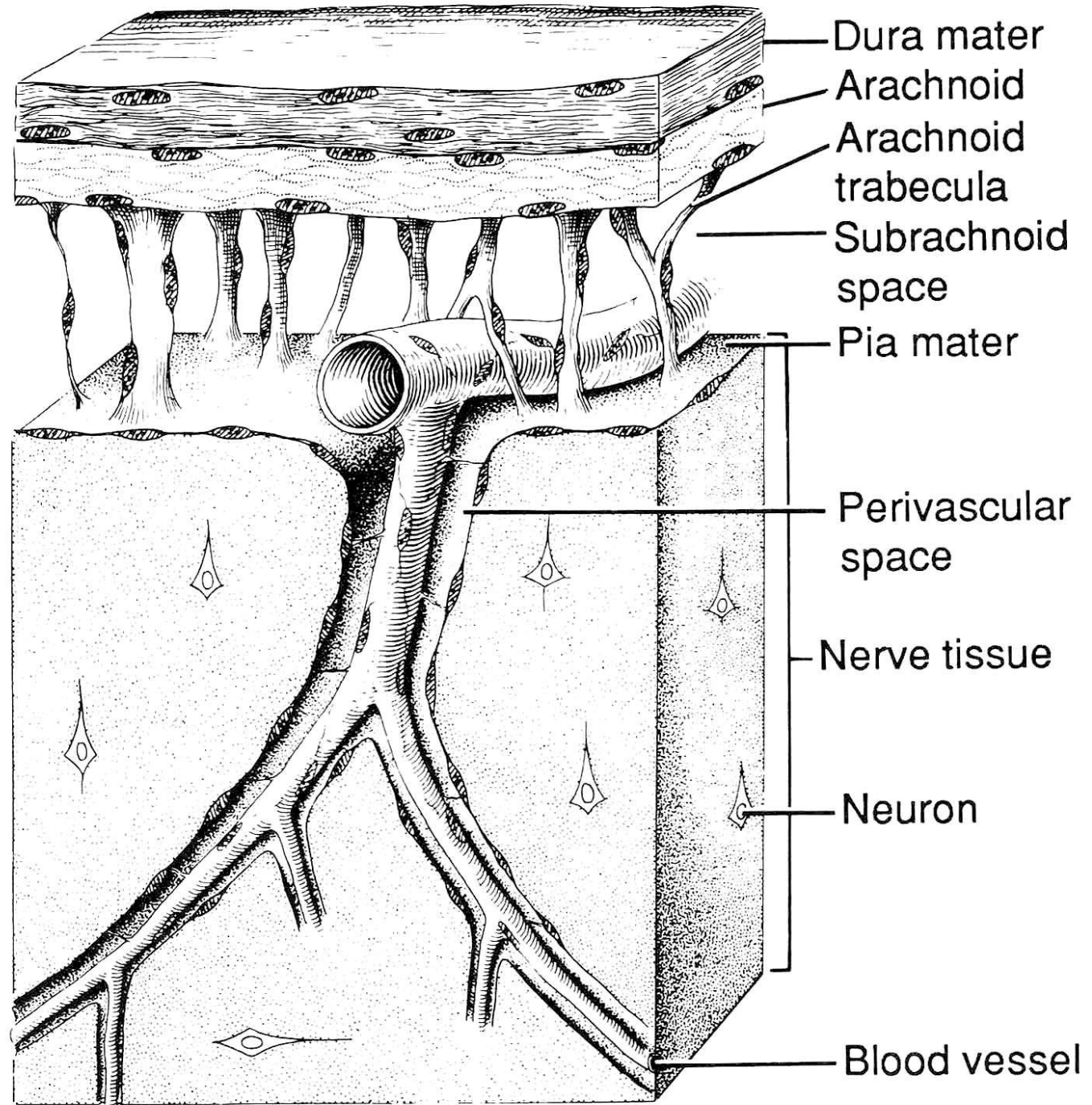
Cerebral cortex

- It is located on the surface of the brain and is divided into the palaeocortex and archicortex, which consist of three layers, and the six-layered neocortex, so the structure varies considerably from one cortical region to another

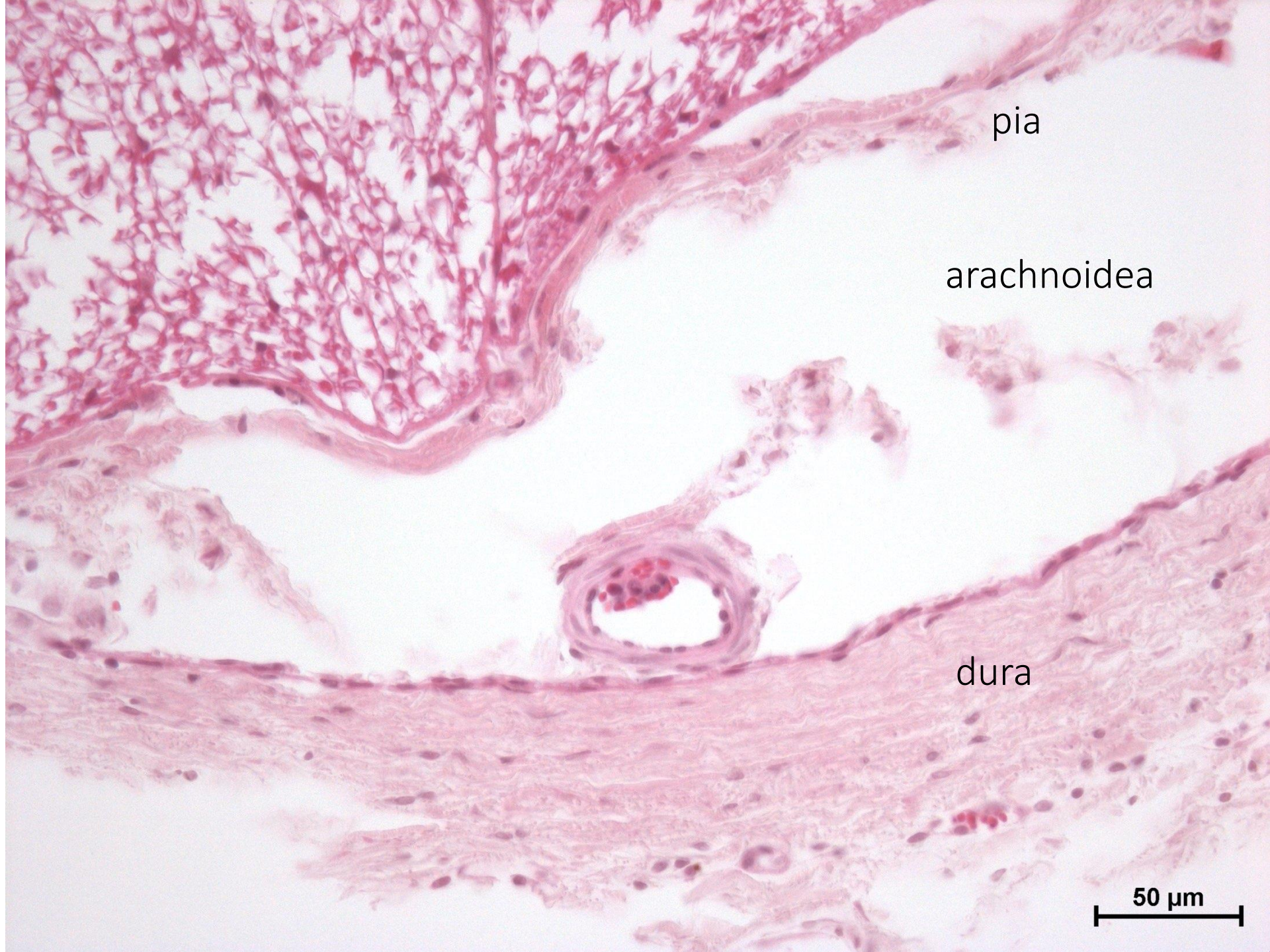Neocortex is divided into 6 layers, all of them contain a very diverse population of cells:

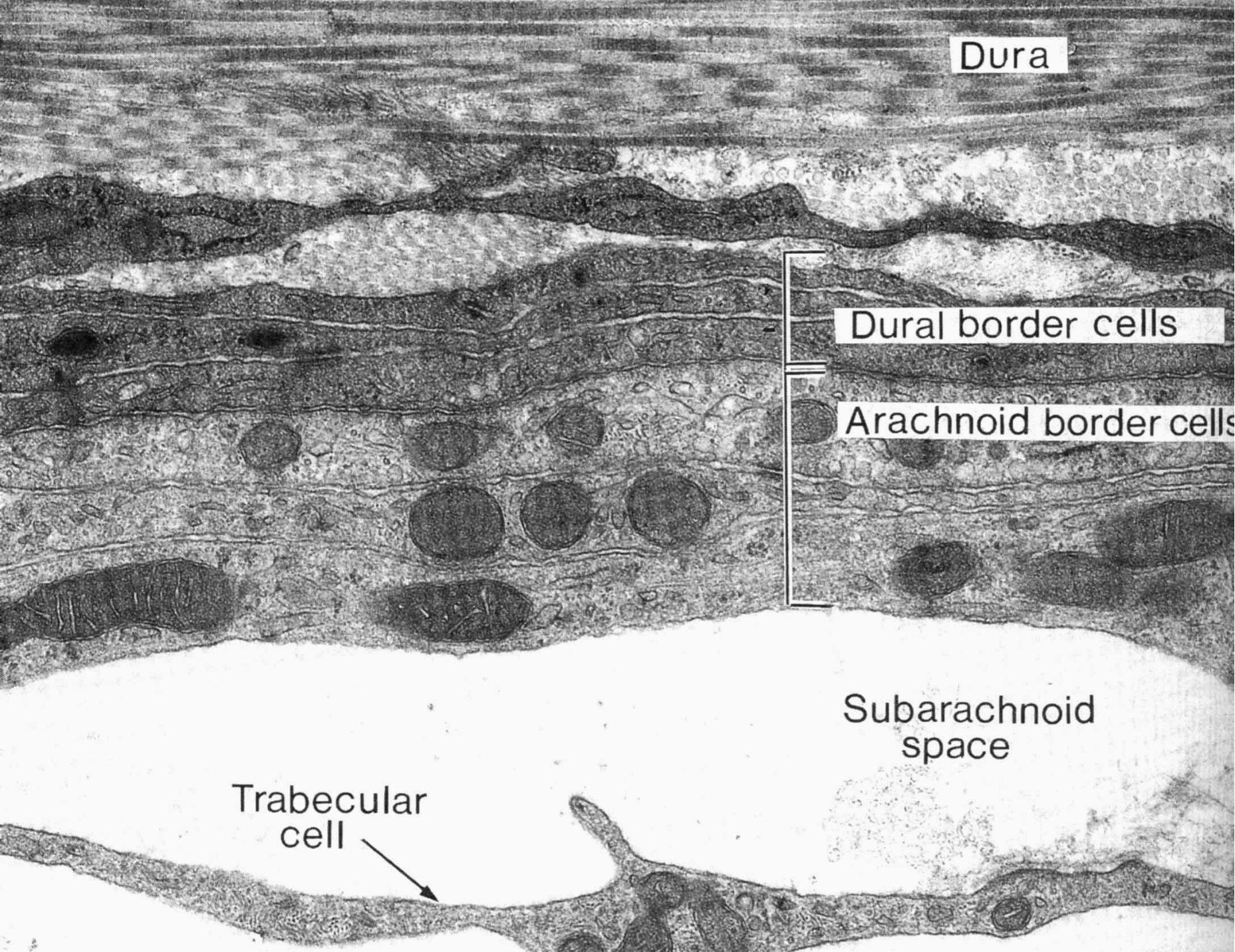
- Lamina **molecularis**: relatively few cells in the outer layer, but contains numerous processes
- Lamina **granularis externa**: small cells
- Lamina **pyramidalis externa**: medium-sized pyramidal cells are dominant
- Lamina **granularis interna**: small neurons both excitatory and inhibitory
- Lamina **pyramidalis interna**: up to 100 micrometer large pyramidal neurons of Betz (their axons form pyramidal tracts)
- Lamina **multiformis**: a mixture of many neuronal types
- Both granular layers are characterized by the presence of neurons of smaller size
- Note that pyramidal cells are not exclusively found in the pyramidal layers
- MGP GPM

Meninges



Spinal cord





Dura

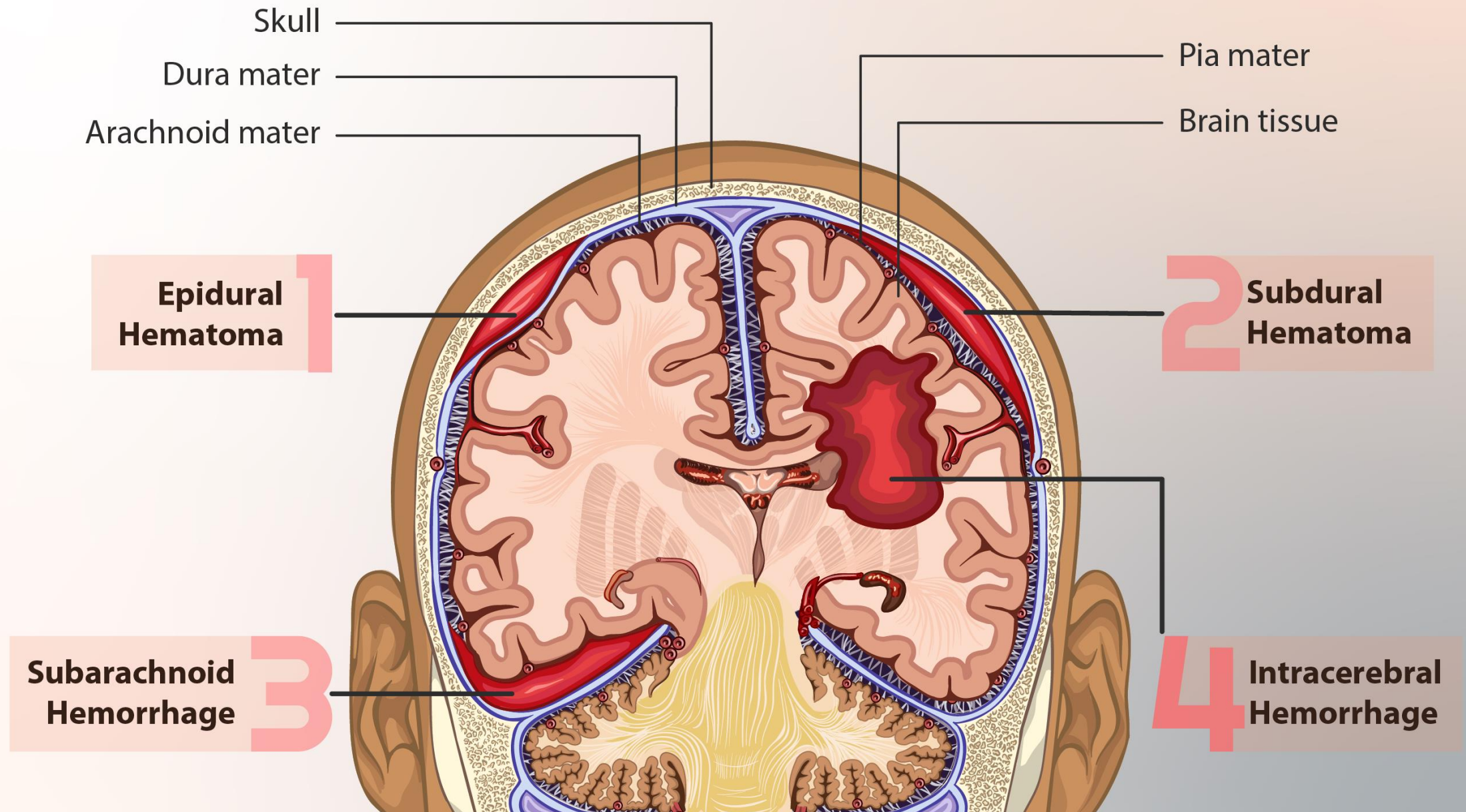
Dural border cells

Arachnoid border cells

Subarachnoid space

Trabecular cell

Types of brain hemorrhage



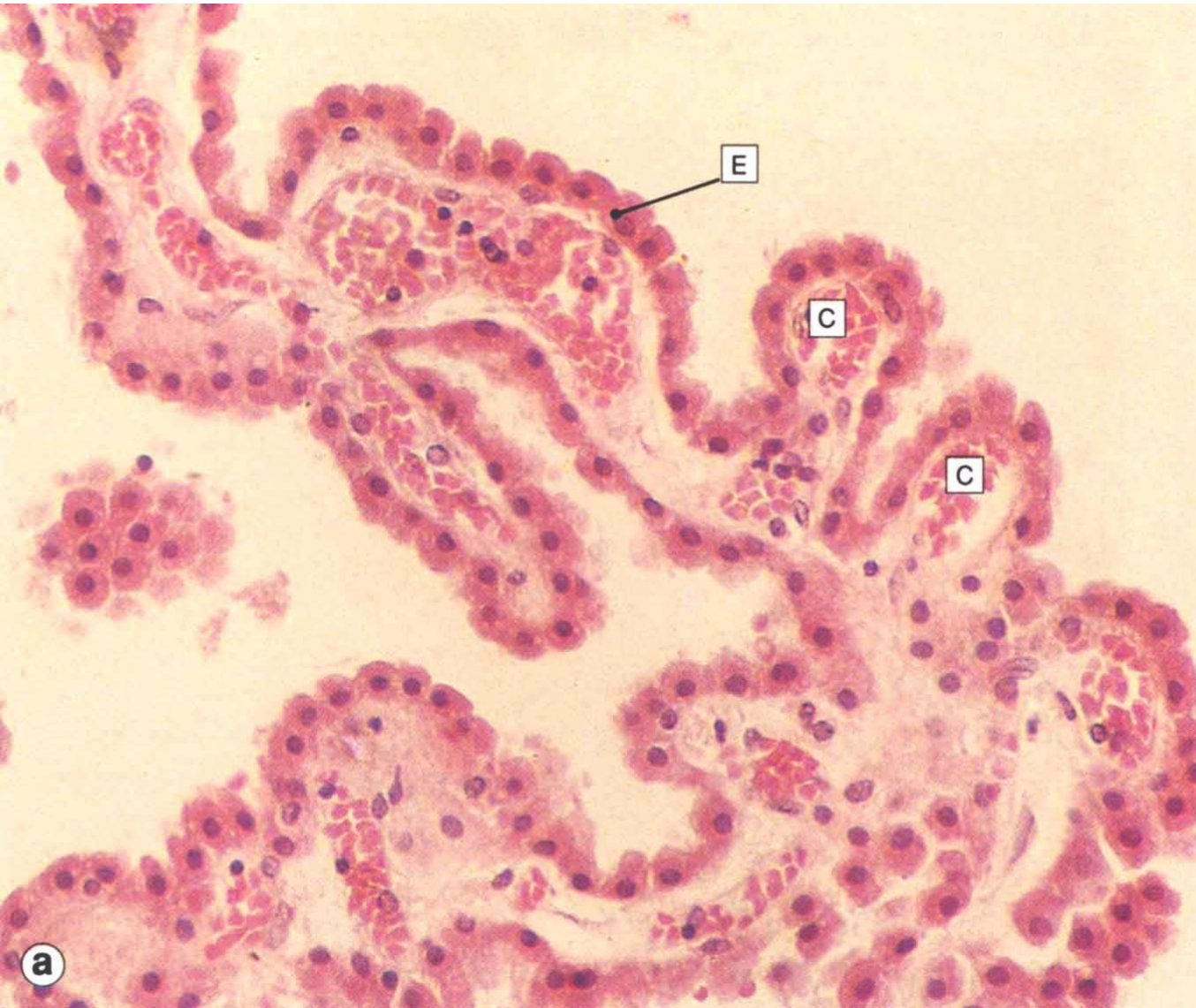
Questions:

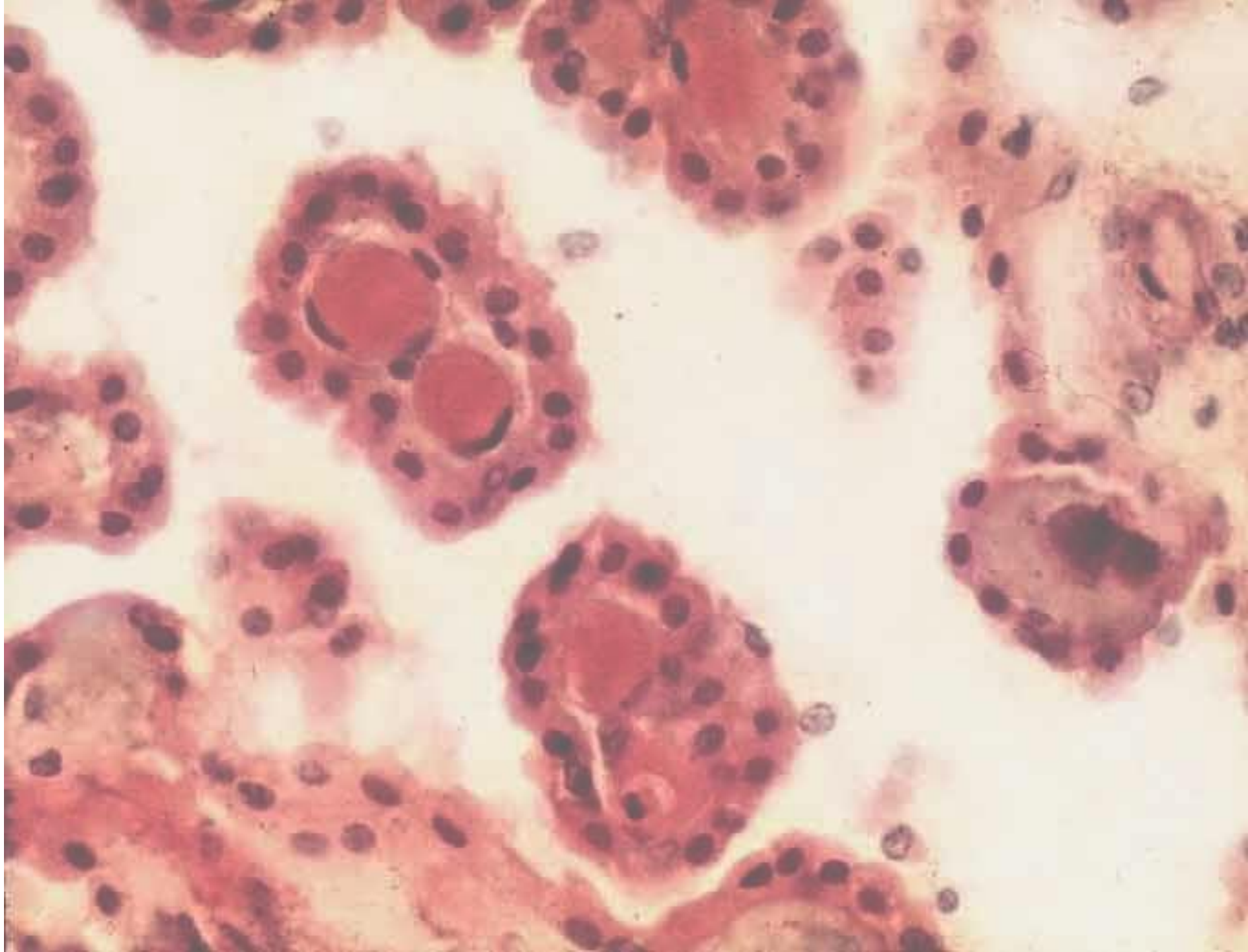
1. What is meningitis? How does it manifest itself?
What can cause it?
2. Do you know how subarachnoid hemorrhage manifests itself?
3. Try to guess which groups of people are most susceptible to subdural haemorrhage? Why?

Questions:

1. It is an inflammation of the meninges manifested, for example, by neck stiffness, headache, fever or photophobia. It can be caused by a number of pathogens, both viral and bacterial. Vaccines against some of these pathogens have been developed (e.g. *Streptococcus pneumoniae*, *Neisseria meningitidis*, *Haemophilus influenzae*).
2. Sudden onset headache typically leading to loss of consciousness, often following an increase in abdominal pressure (lifting heavy objects, coughing, defecation).
3. The elderly are particularly susceptible as they combine a greater risk of falling and brain atrophy, which strains the blood vessels in the subdural space. Other groups include athletes, people with bleeding disorders, alcoholics and abused children.

Plexus chroideus





Questions:

1. What constitutes the blood-CSF barrier? Compare the permeability of this barrier with the blood-brain barrier.
2. Describe the circulation of the CSF. Which structure is responsible for the absorption of the CSF back to the blood? What happens when the circulation of the CSF is obstructed?
3. Do you know what a lumbar puncture is? What parameters are monitored in this procedure?

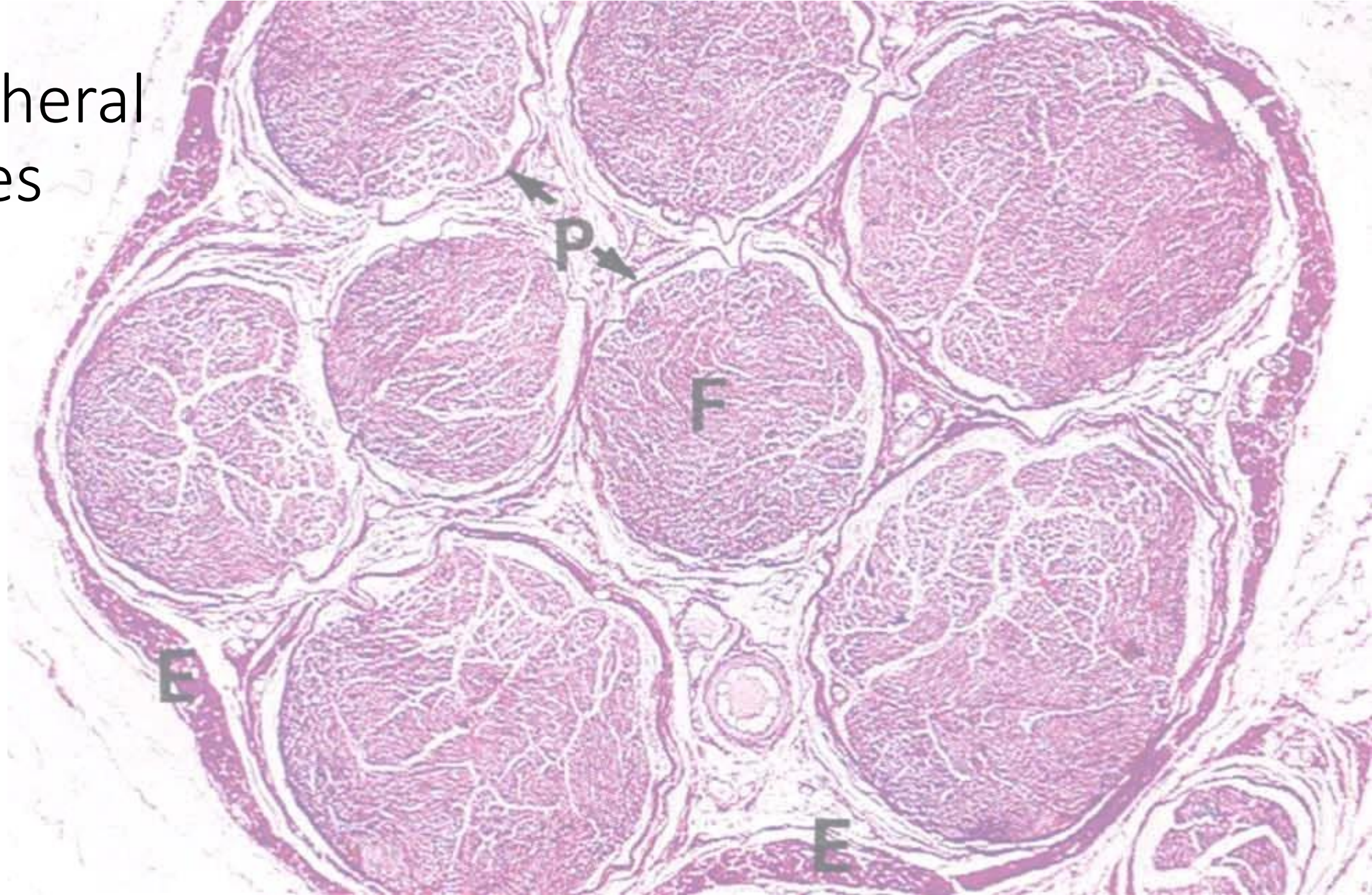
Questions:

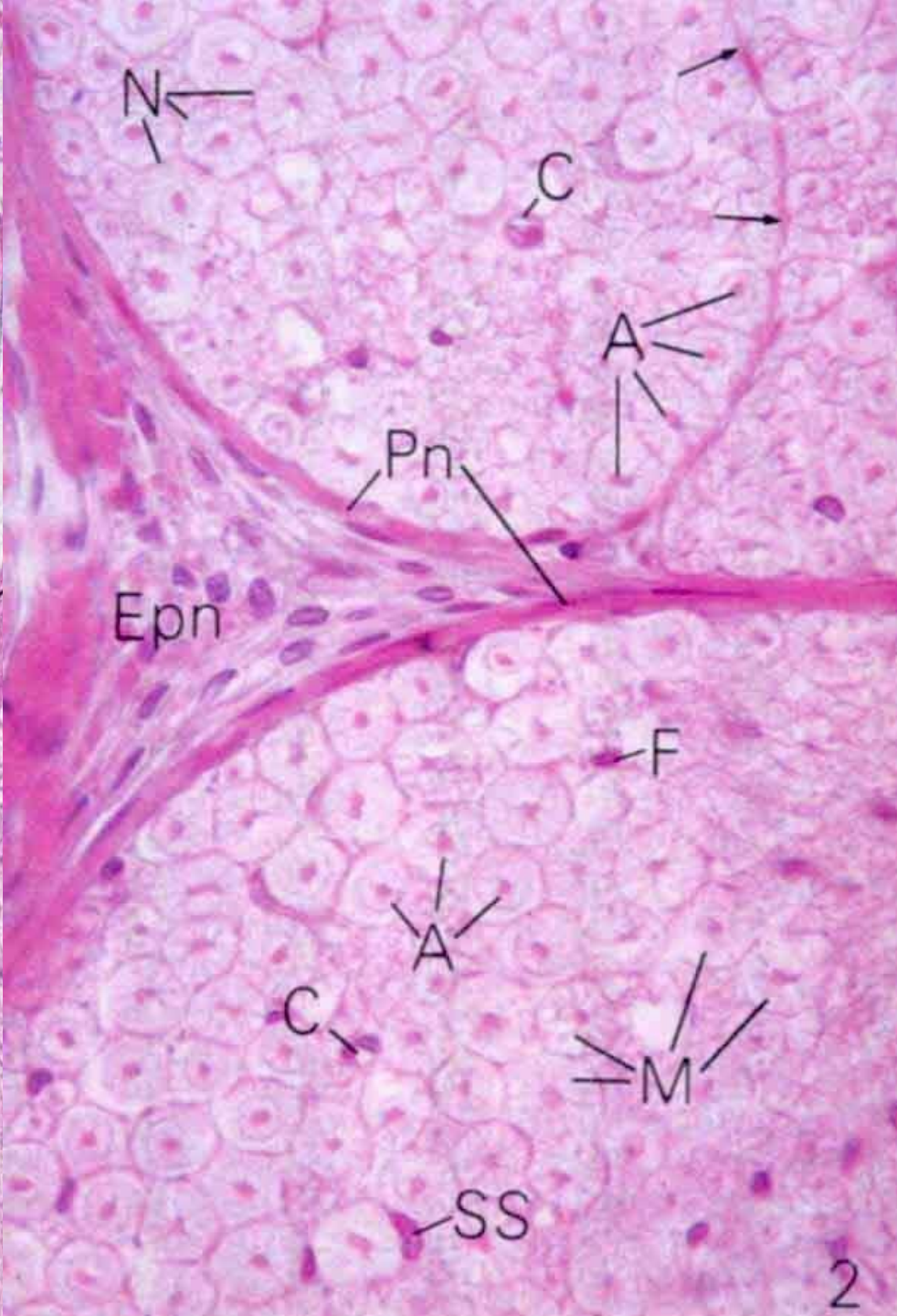
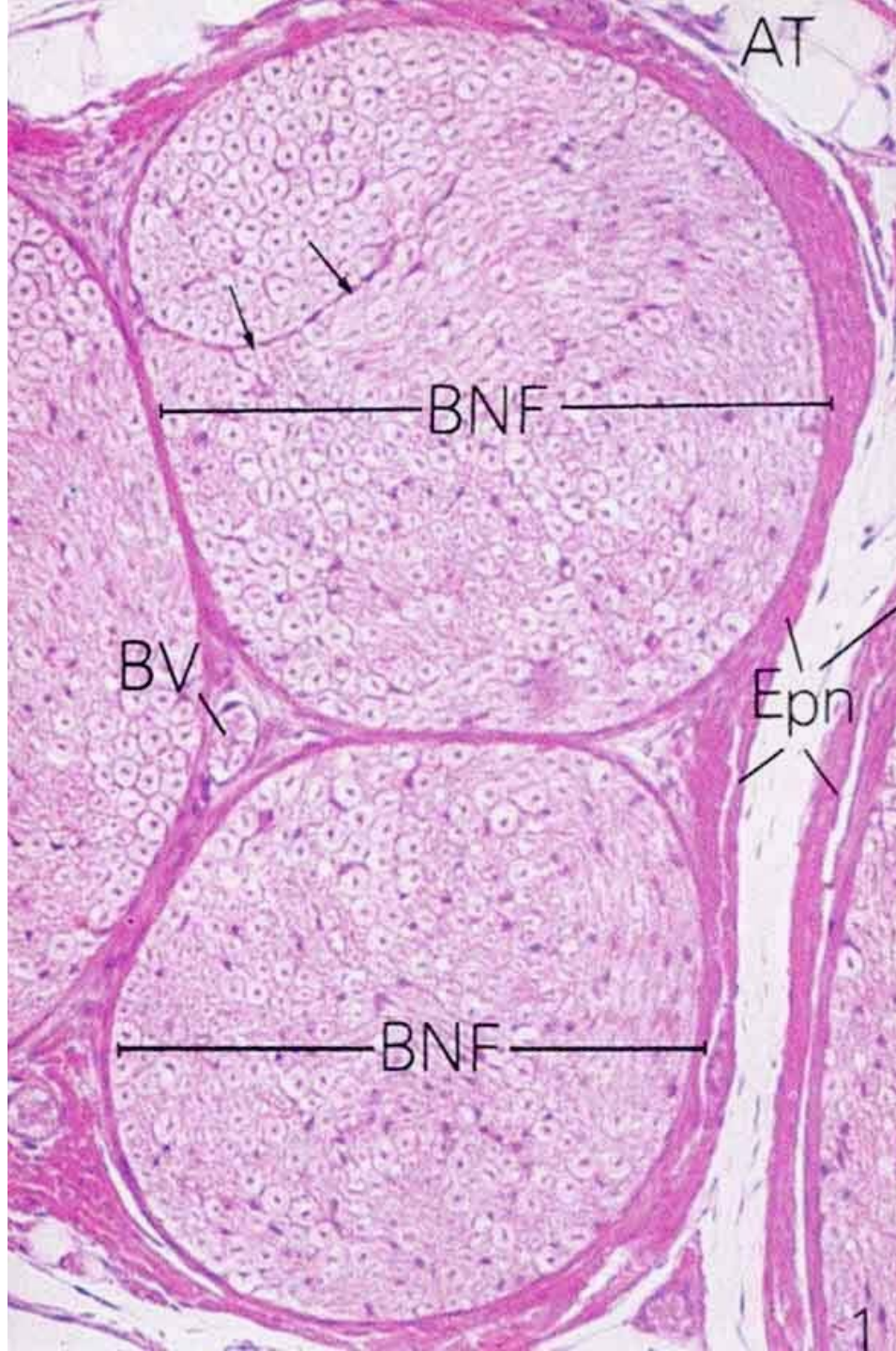
1. The blood-CSF barrier is mainly provided by the cellular junctions between the epithelial cells of the choroid plexus. It is more permeable than the blood-brain barrier.
2. After production in the choroid plexus of the lateral ventricles, the liquor moves through the foramina Monroi to the third and through the canalis Sylvii to the fourth cerebral ventricle, and from there it passes through the foramen Magendii and foramina Luschkae to the subarachnoid space, where it is absorbed into the blood by Pacchioni granules. Hydrocephalus may develop when the CSF circulation is compromised.
3. Puncture of the spinal canal for the purpose of collecting fluid. It is examined mainly cytologically, microbiologically and biochemically.

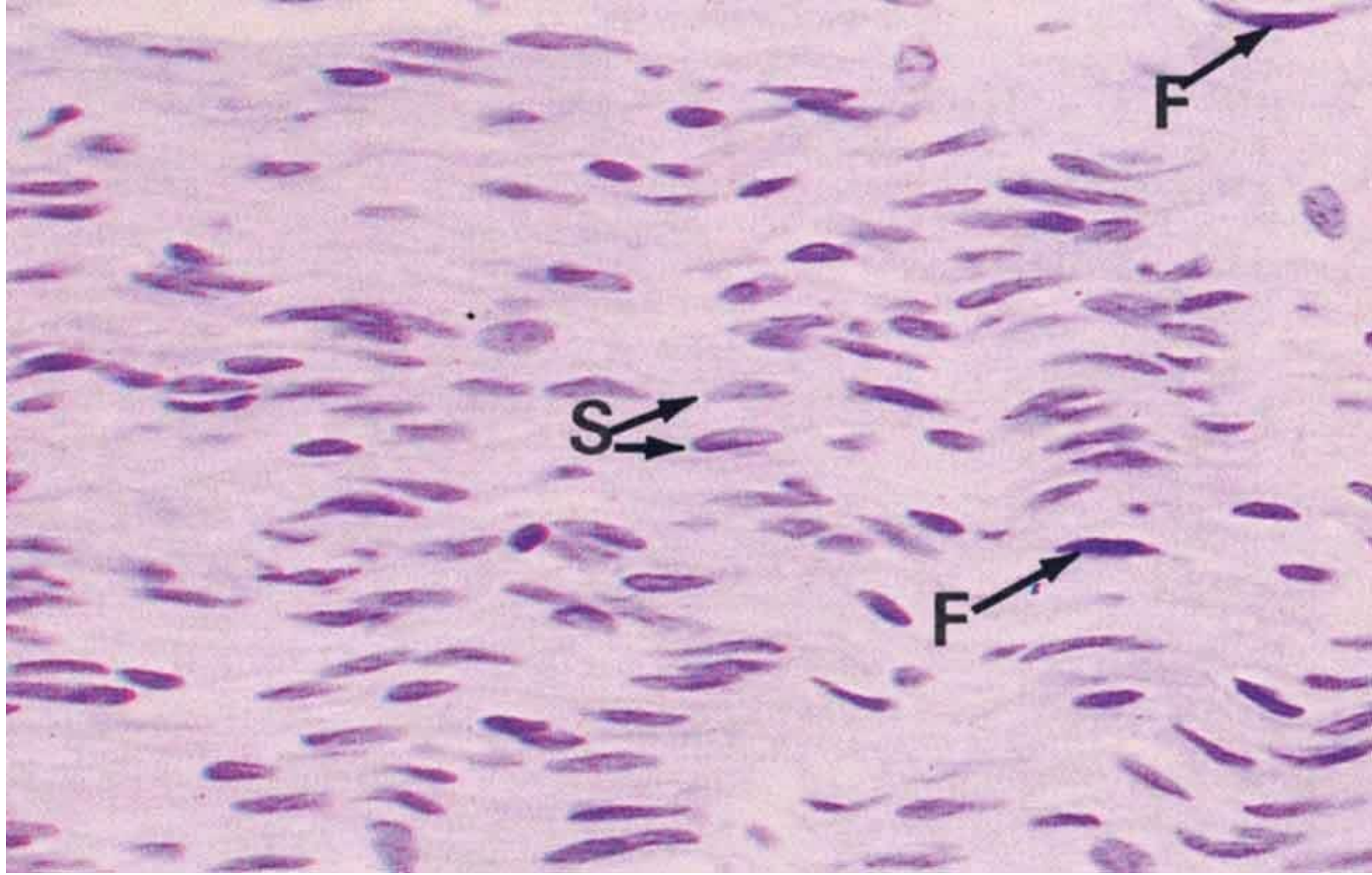
Meninges and choroid plexus

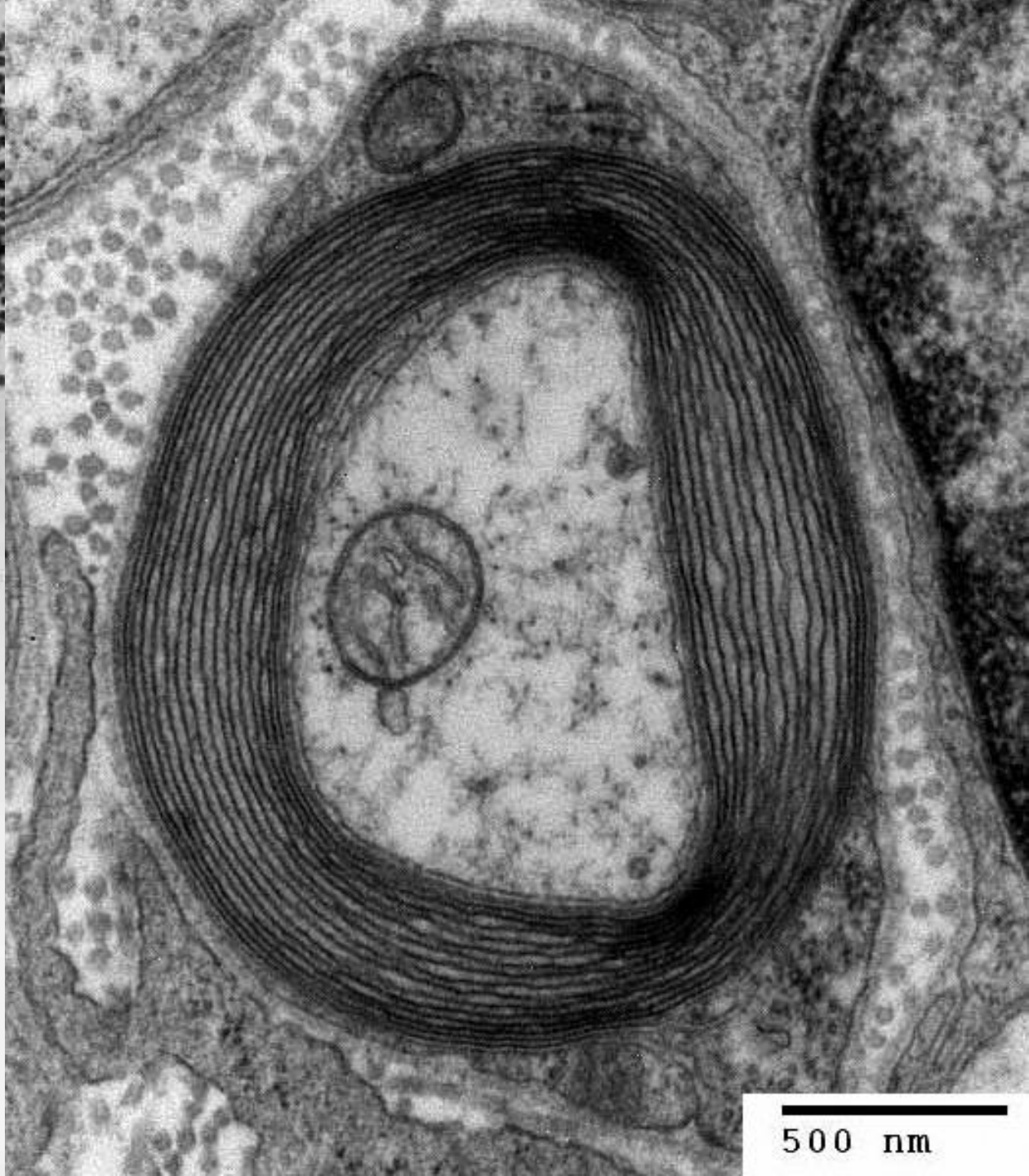
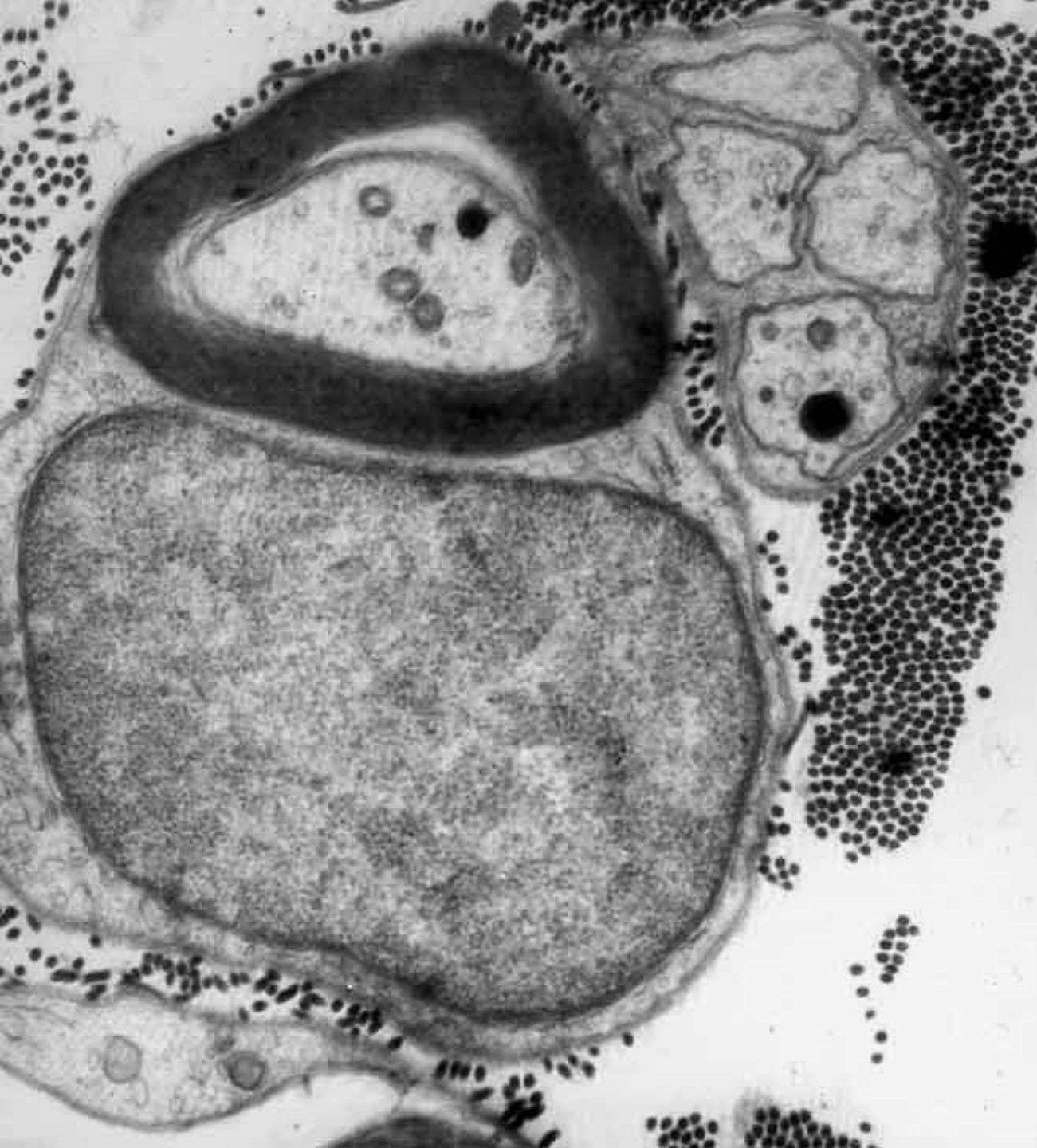- The **dura mater** is composed of **dense irregular connective tissue** and an inner layer of flat dural border cells
- In the skull, it transitions smoothly into the periosteum of the cranial bones and contains **venous sinuses**; an **epidural space** containing fat and vascular plexuses is formed in the region of the spinal canal
- The **arachnoid** is composed of non-vascularized connective tissue, it contains arachnoid marginal cells at the border with the dura mater, below this thin layer the **trabecules** extend towards the pia mater
- The **pia mater** is located on the surface of the CNS and also follows the course of the blood vessels, it is separated from the CNS by the **lamina limitans gliae superficialis**, it consists of **richly vascularized loose connective tissue**
- **Plexus choroideus** is a pia mater outgrowth into the cerebral ventricles composed of **loose connective tissue** with numerous capillaries, on the surface we find a **simple cuboidal to low columnar epithelium**

Peripheral
nerves



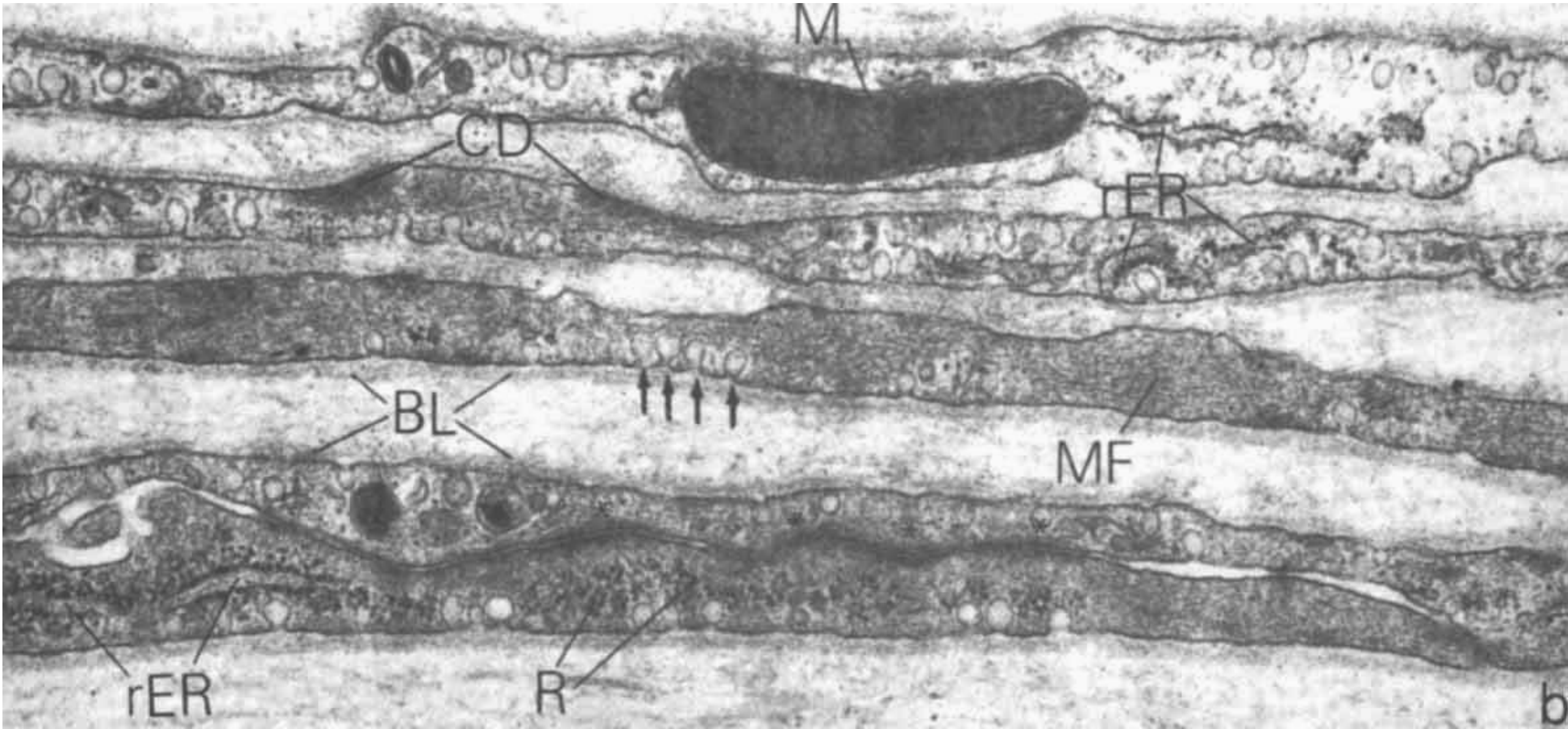






500 nm

Perineurium



Questions

1. What happens to neurons when a nerve is damaged?
Can regeneration occur? What happens to an innervated muscle?
2. What is a schwannoma? Which cranial nerve is typically affected?

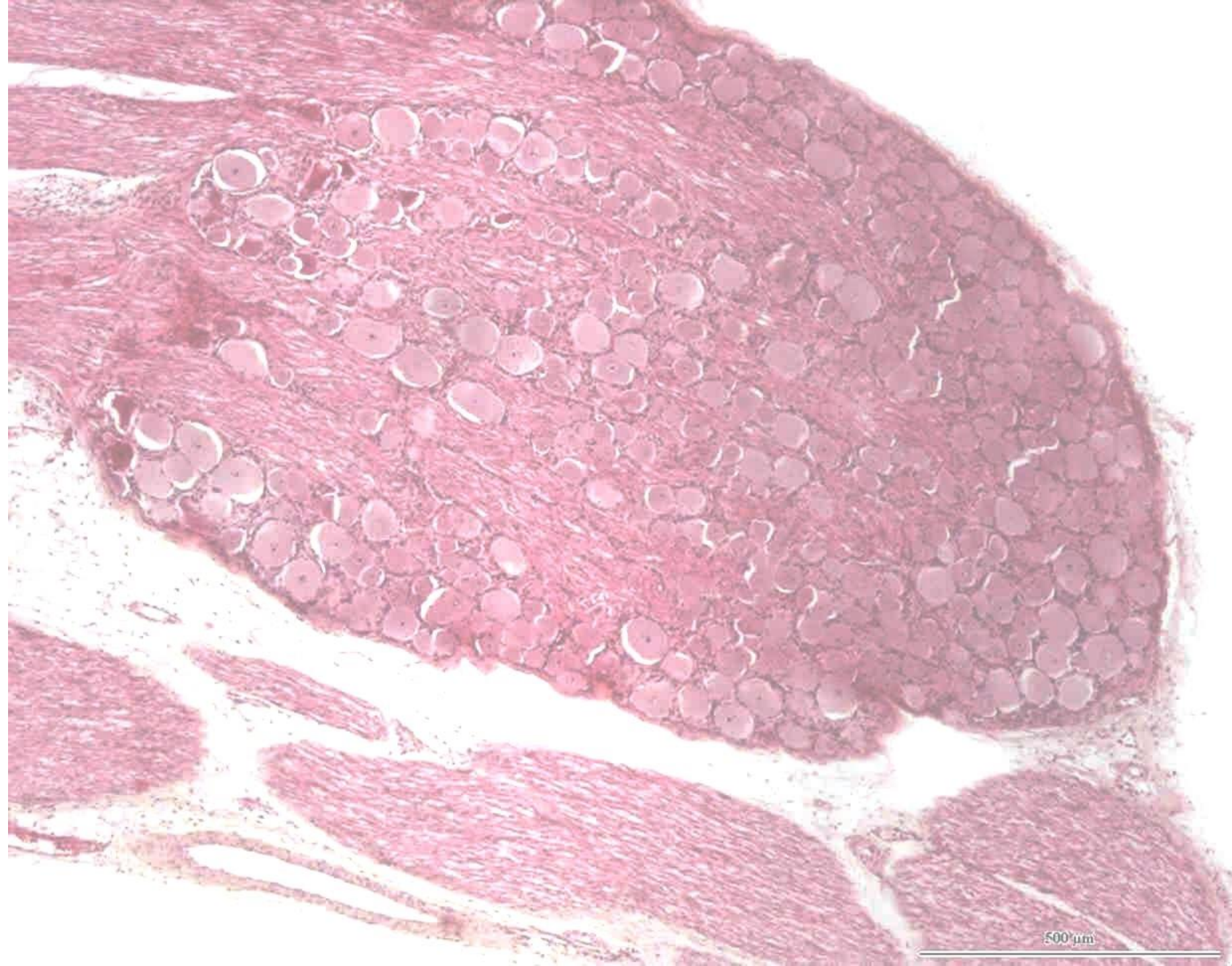
Otázky a úkoly

1. When the axon is damaged, so-called **Wallerian degeneration** occurs. The cytoskeleton of the axon and myelin sheath disintegrate. There are also changes in the soma such as chromatolysis (loss of Nissl substance). Schwann cells form a pathway through which protrusions from the proximal axon stump grow at a rate of about 3 mm/day. The innervated muscle atrophies.
2. It is a **benign Schwann cell tumor**. The most typical is a vestibular schwannoma affecting the VIIIth cranial nerve. It may be associated with a genetic disease - neurofibromatosis type 2.

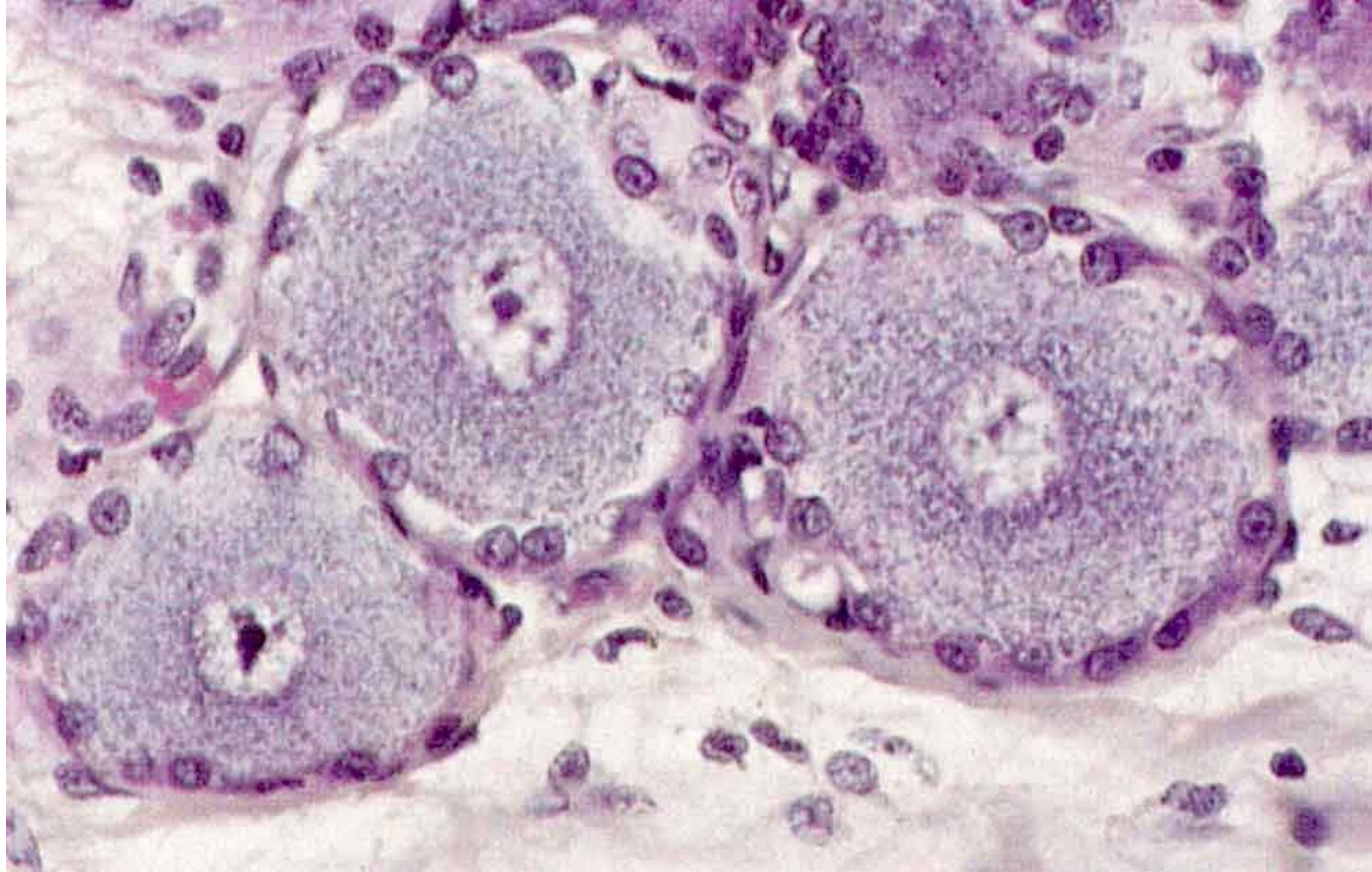
Nerves

- They consist of **bundles of axons** accompanied by **Schwann cells** and sheaths
- Peripheral nerve axons can be both **myelinated** and **unmyelinated**, peripheral myelin is different from the one found in the CNS
- Neuronal bodies are in the CNS or ganglia, their bodies are not found in peripheral nerves (unless you are observing a ganglion), the nuclei observed belong to other cells
- Inside the individual axonal bundles are the **endoneurium** (reticular fibers and amorphous material) and are surrounded by the **perineurium** (several layers of special cells with features of both epithelium and resident cells of the connective tissue, together with fibroblasts and extracellular matrix including collagen and reticular fibers)
- The **epineurium** is located on the surface of the nerve and between the individual nerve fibre bundles, it is composed of **connective tissue** and contains blood vessels

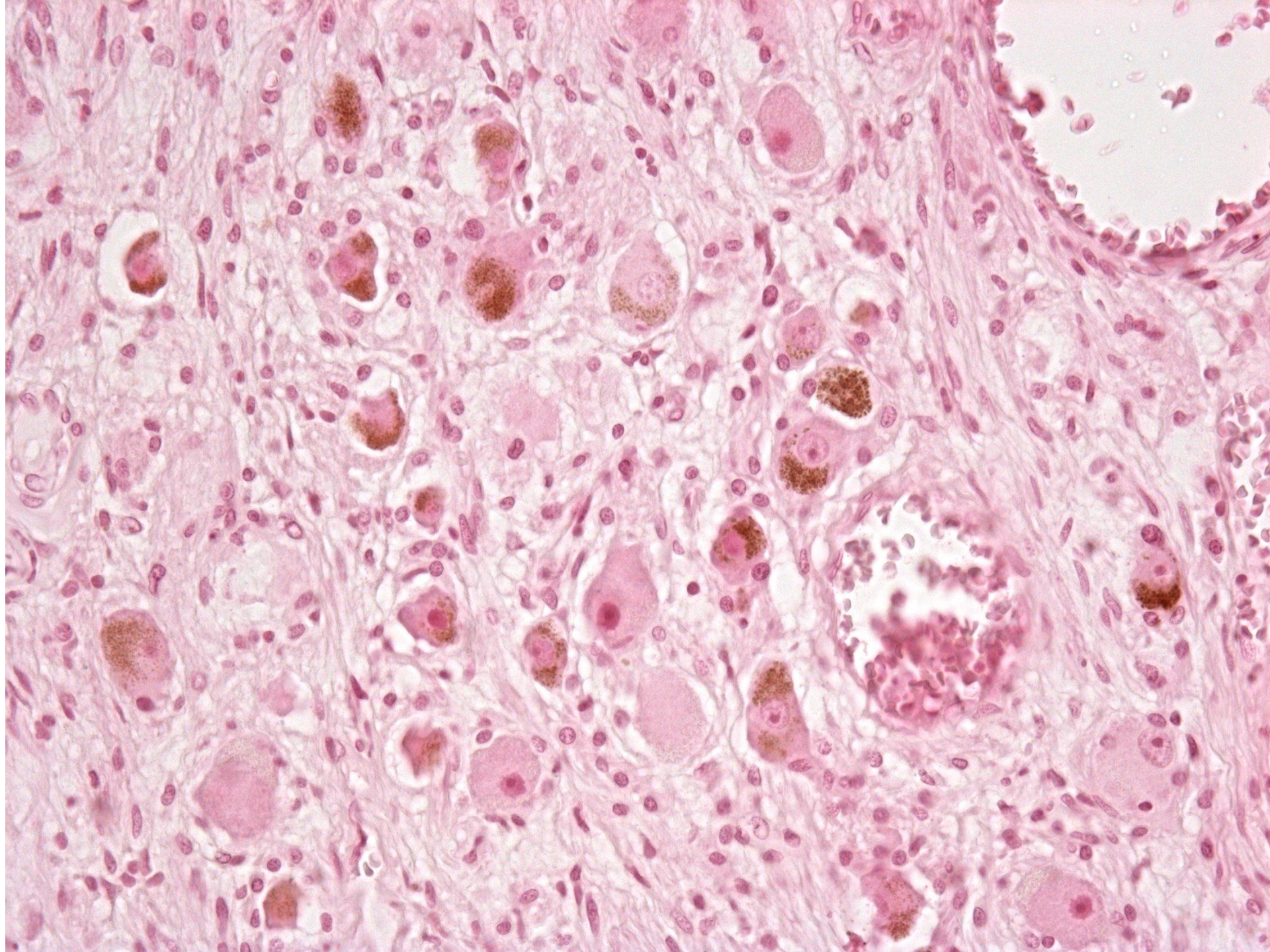
Spinal ganglion



500 μ m



Autonomous ganglion



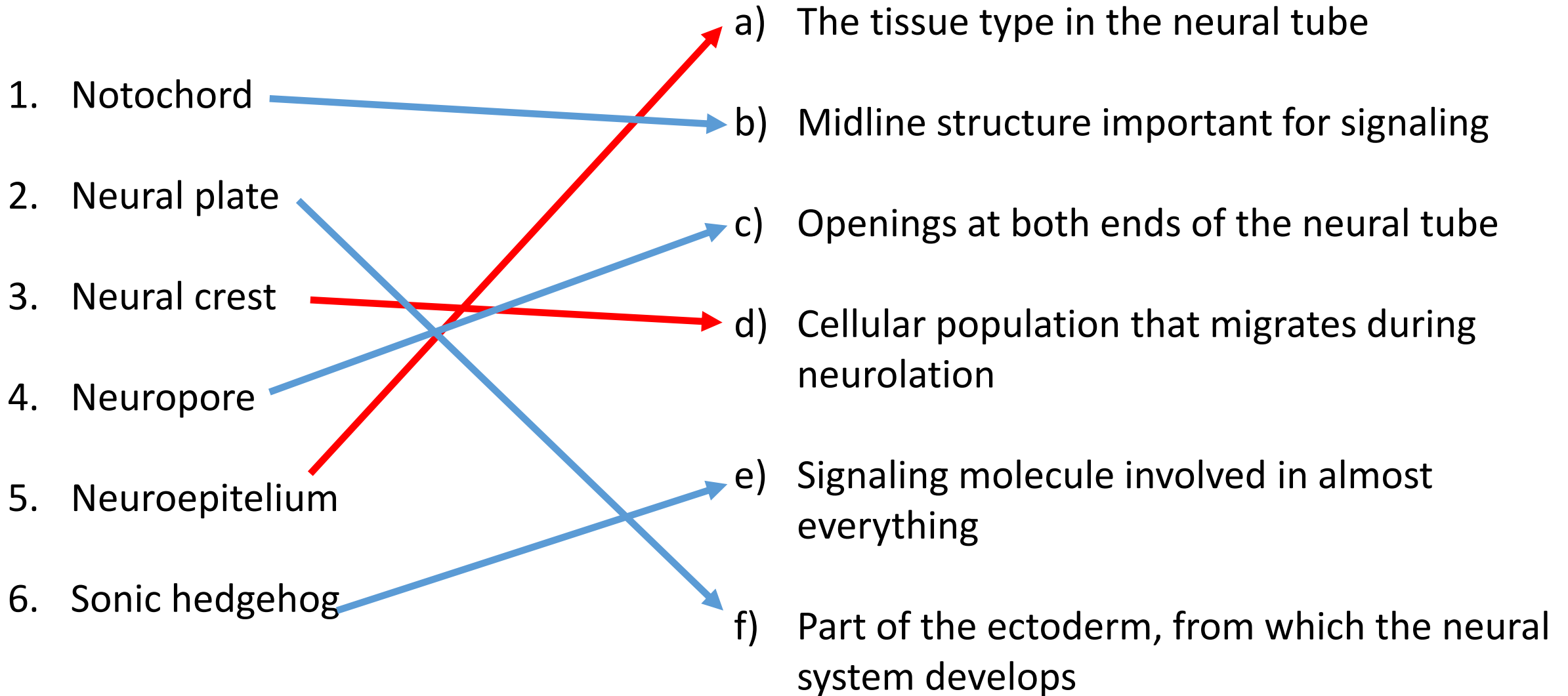
Ganglia

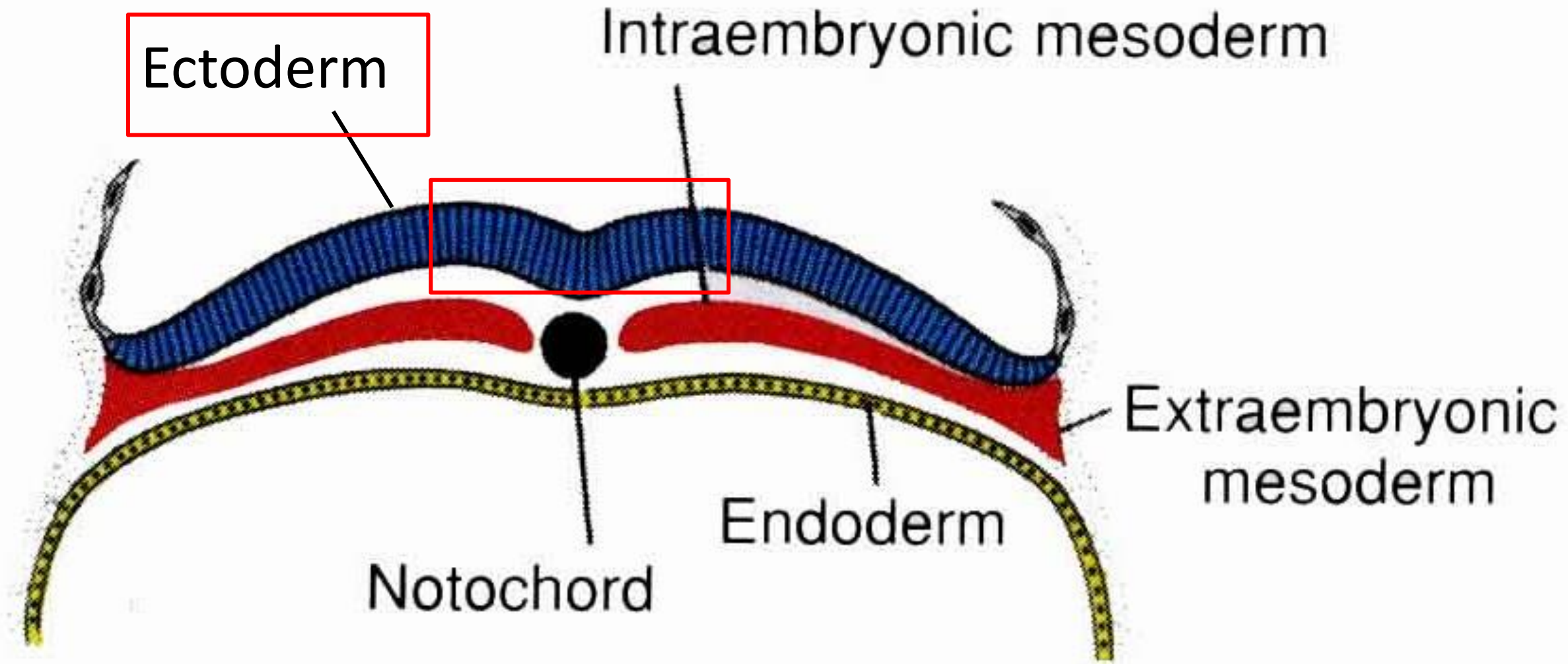
- Encapsulated structures along the course of a peripheral nerve containing **groups of neurons outside of the CNS**
- Neuron bodies are surrounded by special glial cells called **satellite cells**
- **Sensory ganglia** contain afferent pseudounipolar neurons and are located in the foramina intervertebralis at the posterior spinal roots, or along the course of the cranial nerves
- Ganglia of the VIIIth nerve contain bipolar neurons
- **Autonomic ganglia** contain efferent multipolar neurons
- **Sympathetic** ganglia are larger and located **near the spine (paravertebral and prevertebral)**
- **Parasympathetic** ganglia are located in the cephalic part during the course of nervi craniales **III, VII, IX, X**. Other small ganglia are located **near the target organs**, often even **intramurally**
- A large **enteric nervous system** is sometimes distinguished as a separate part of the ANS

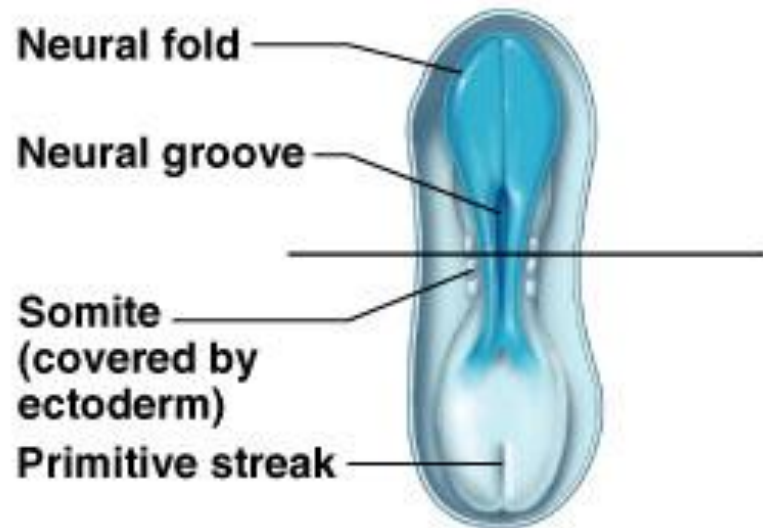
Embryology revision

1. Notochord
 2. Neural plate
 3. Neural crest
 4. Neuropore
 5. Neuroepithelium
 6. Sonic hedgehog
- a) The tissue type in the neural tube
 - b) Midline structure important for signaling
 - c) Openings at both ends of the neural tube
 - d) Cellular population that migrates during neurulation
 - e) Signaling molecule involved in almost everything
 - f) Part of the ectoderm, from which the neural system develops

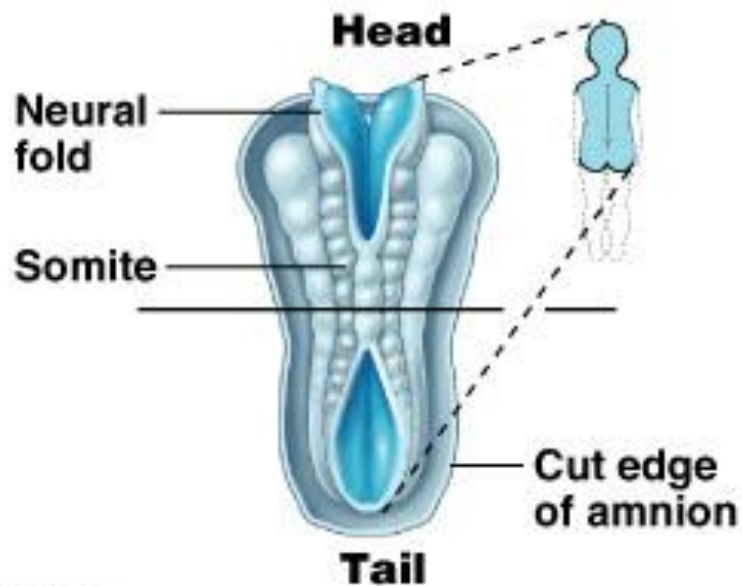
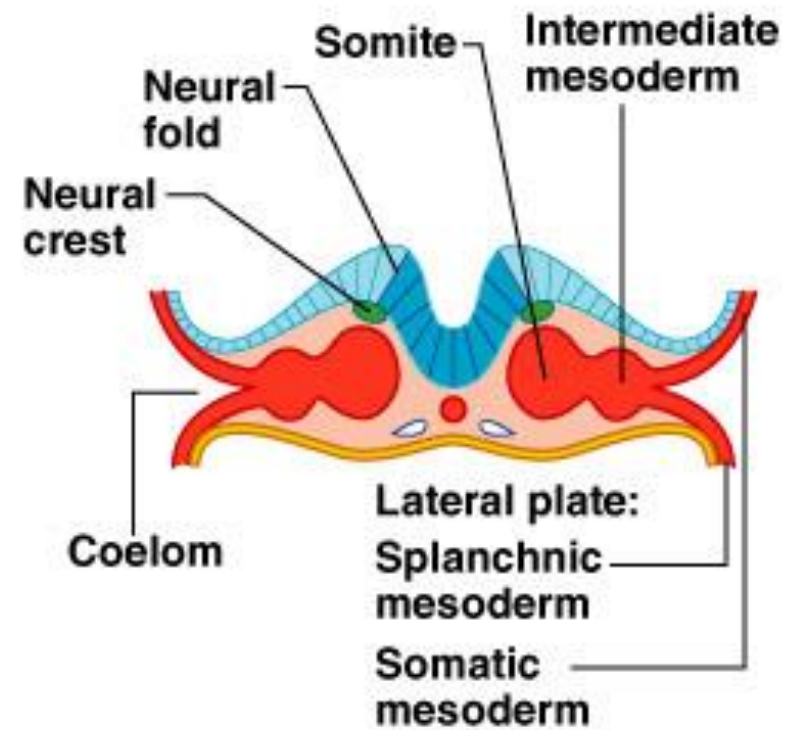
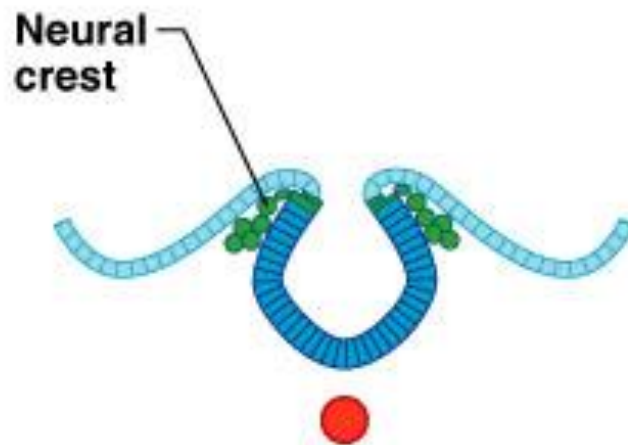
1b; 2f; 3d; 4c; 5a; 6e



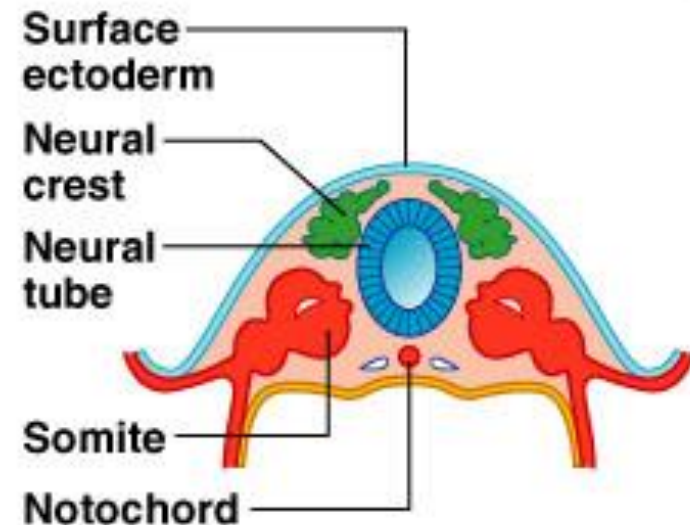
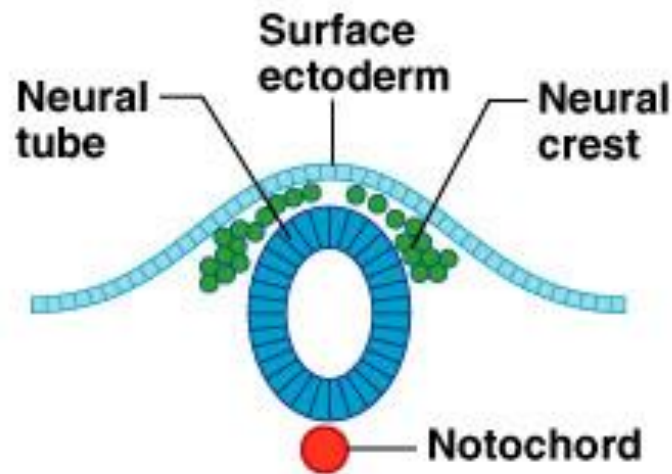




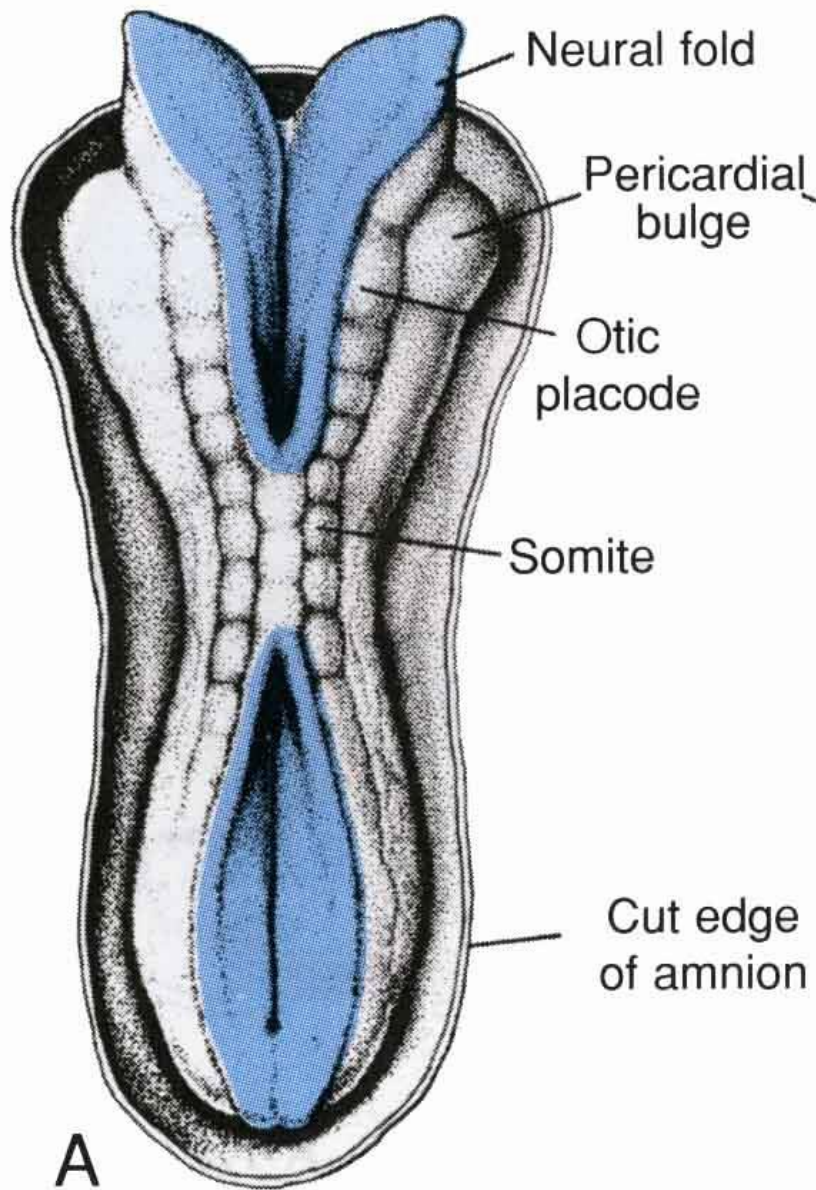
(c) 20 days



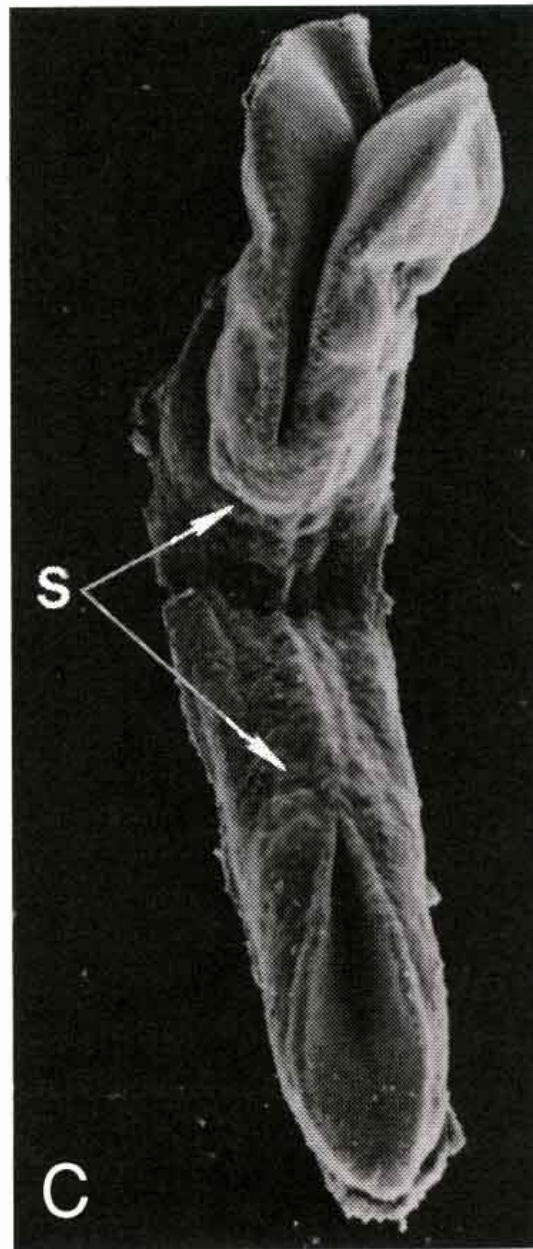
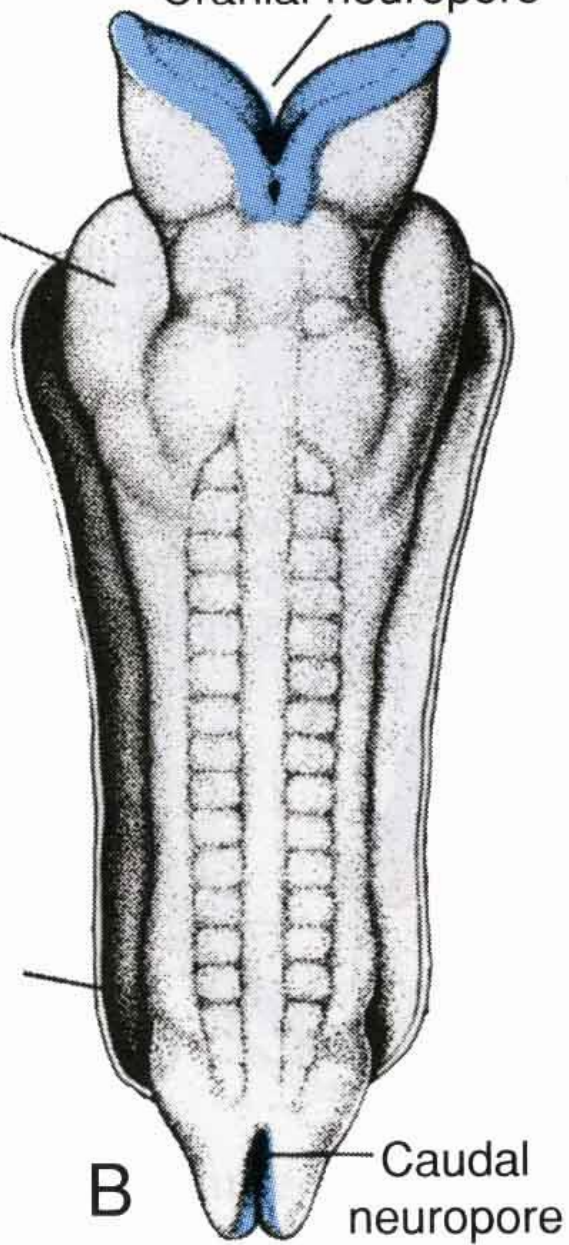
(d) 22 days



Closing on day 24 – 25

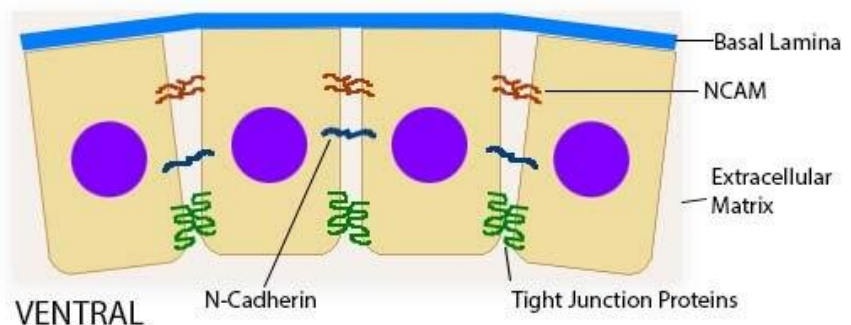


Cranial neuropore



Closing on day 26 – 28

DORSAL

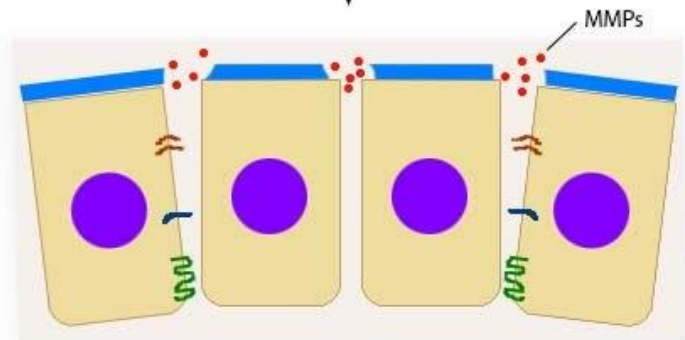


VENTRAL

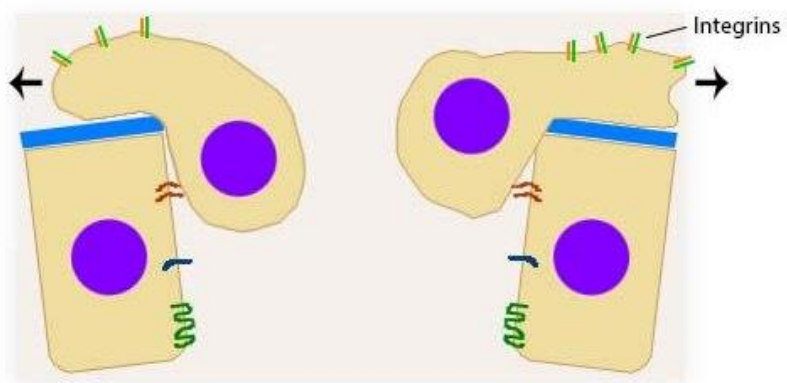
N-Cadherin

Tight Junction Proteins

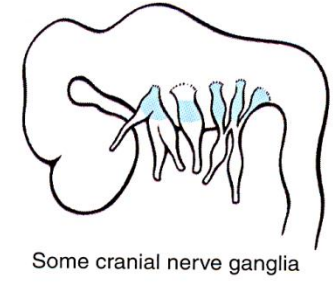
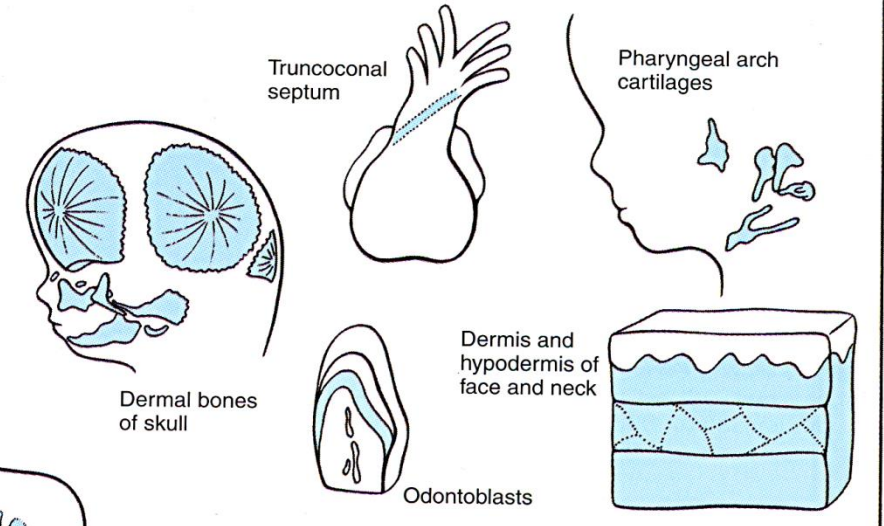
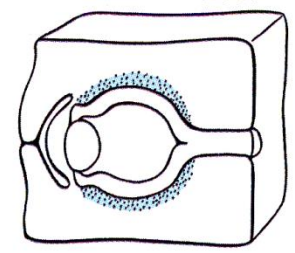
Downregulation of CAMs and tight junction proteins and secretion of MMPs to degrade basal lamina



Completion of epithelial-mesenchymal transition leads to delamination and migration

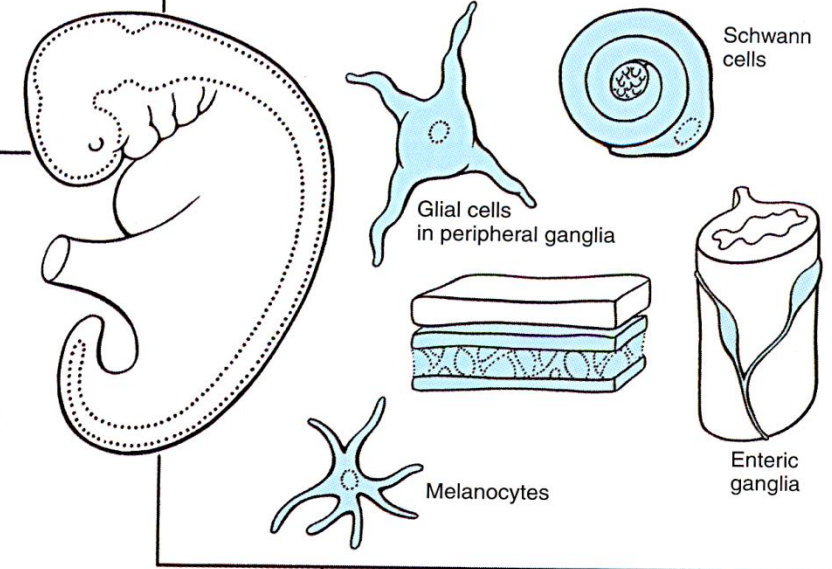


Cranial neural crest

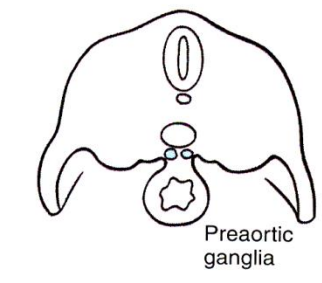


Some cranial nerve ganglia

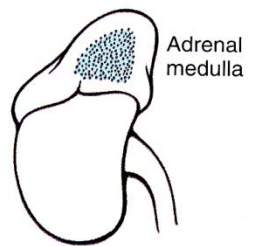
Cranial and spinal neural crest



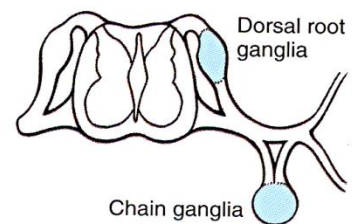
Spinal neural crest



Preaortic ganglia



Adrenal medulla



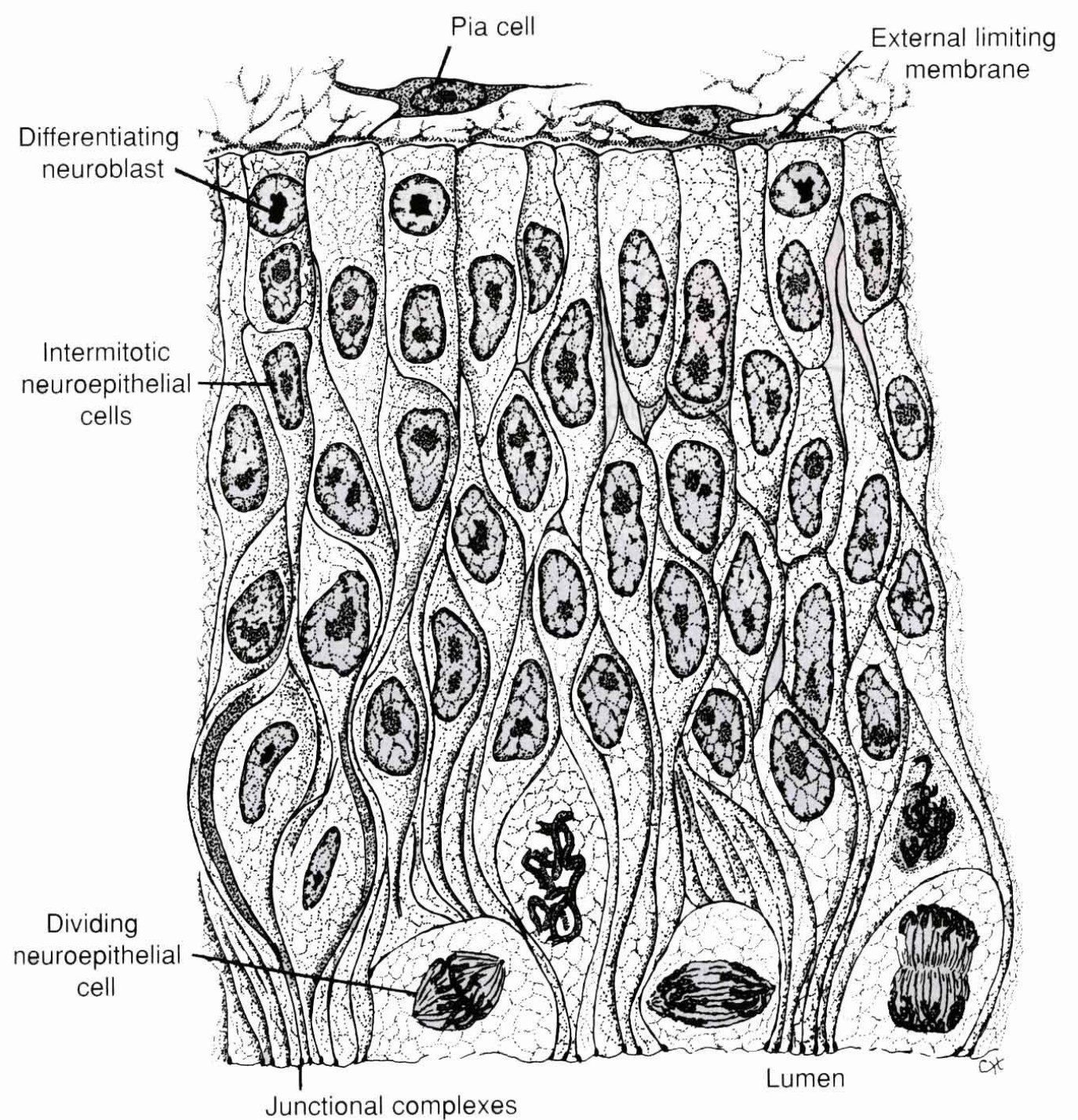
Dorsal root ganglia

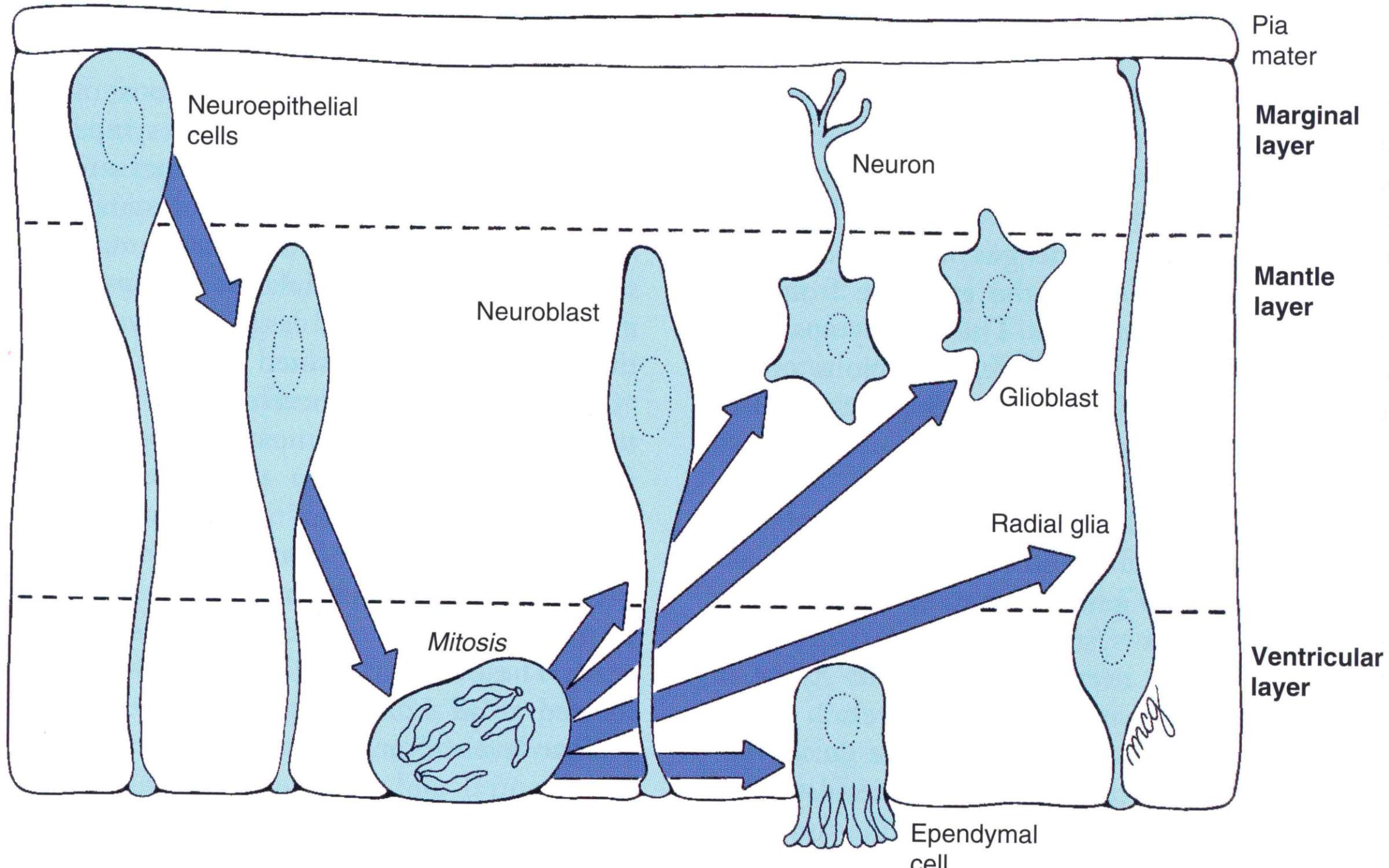
Chain ganglia

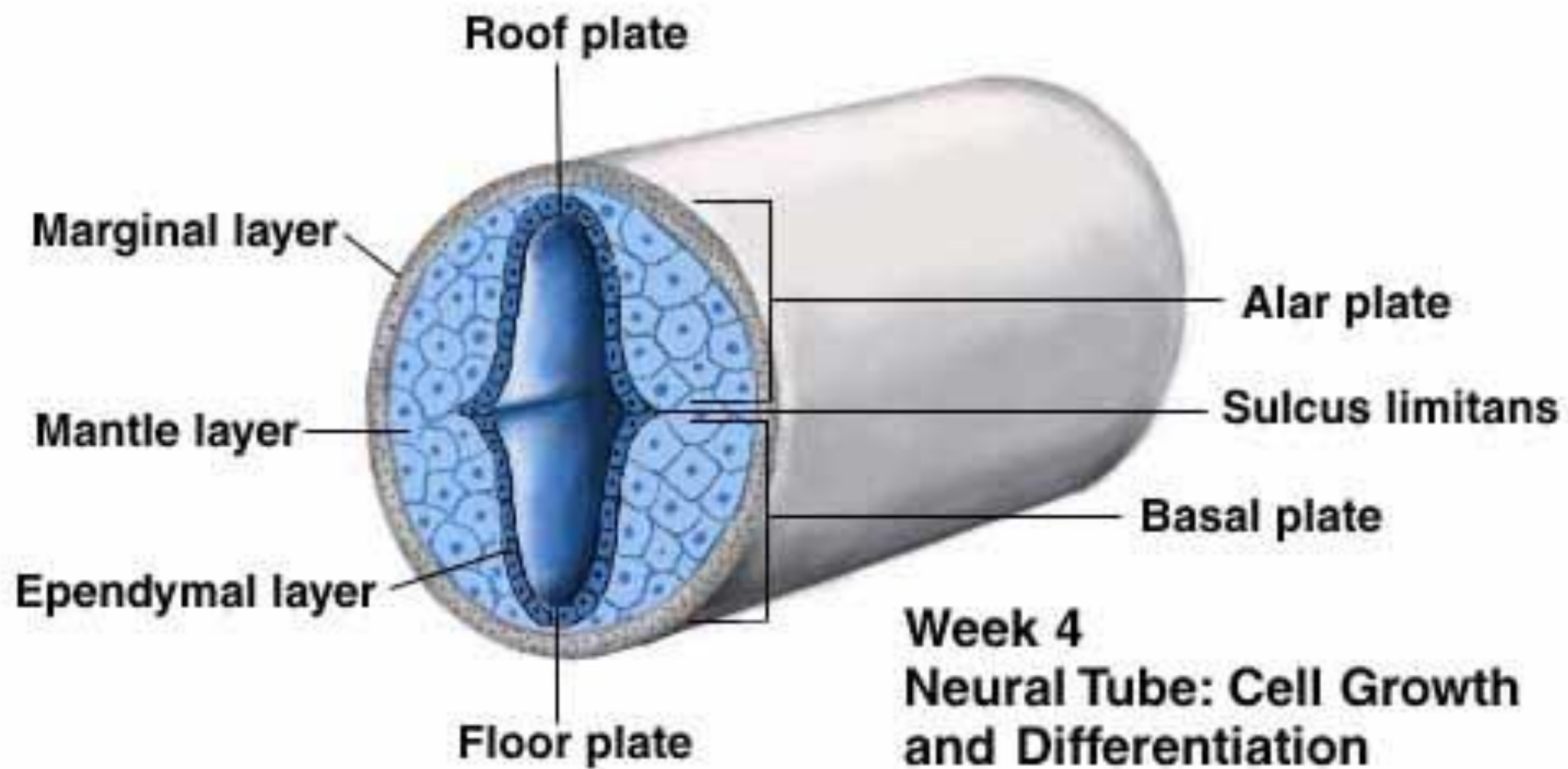
Forming the neural tube - **neurulation**

- After gastrulation, the part of the ectoderm close to the midline differentiates into a neural plate
- The lateral edges of the neural plate bulge to form **neural folds**, while the **neural groove** deepens in the centre
- This process continues until the neural folds fuse dorsally, forming the **neural tube**
- First closure occurs in the occipitocervical region (rhombencephalon and cervical spinal cord), then the closure spreads caudally and cranially, with the caudal neuroporus closing last (days 26-28)
- Some of the cells of the neural folds undergo epithelial-mesenchymal transformation to form the **neural crest**, this important population then contributes to PNS, head and neck connective tissue, cardiac septation, odontoblasts, skin melanocytes, adrenal medulla...

Histogenesis of the nervous system - neuroepithelium

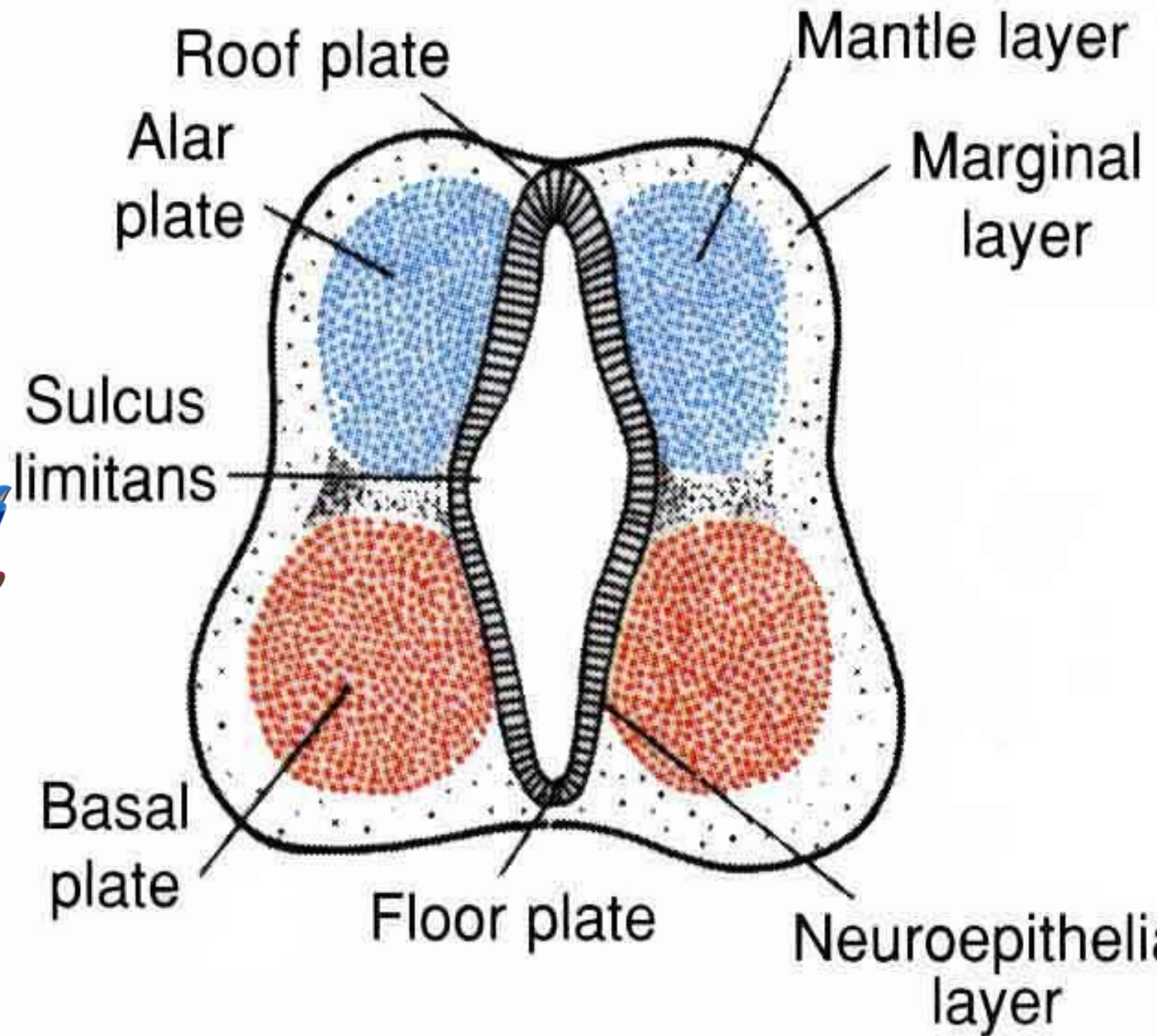
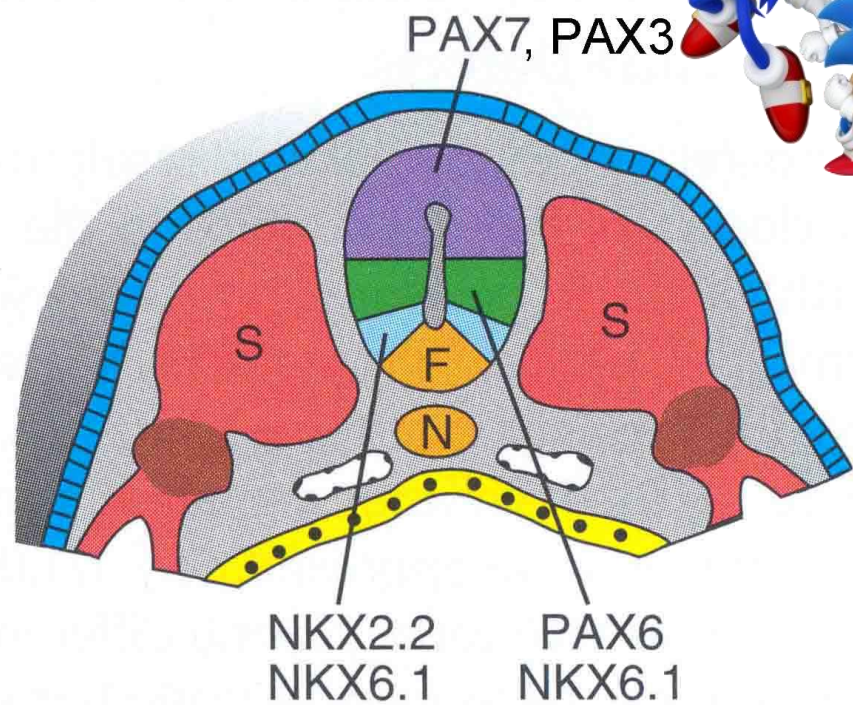
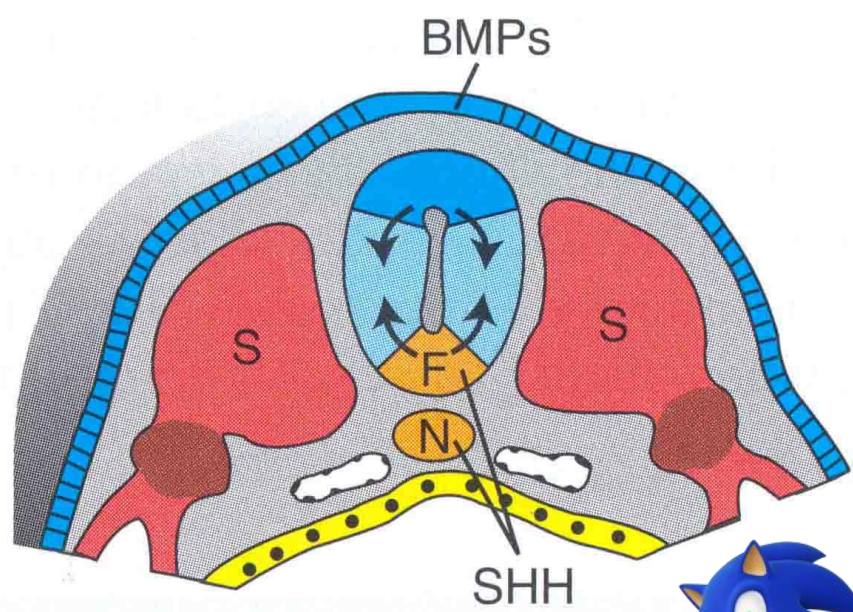






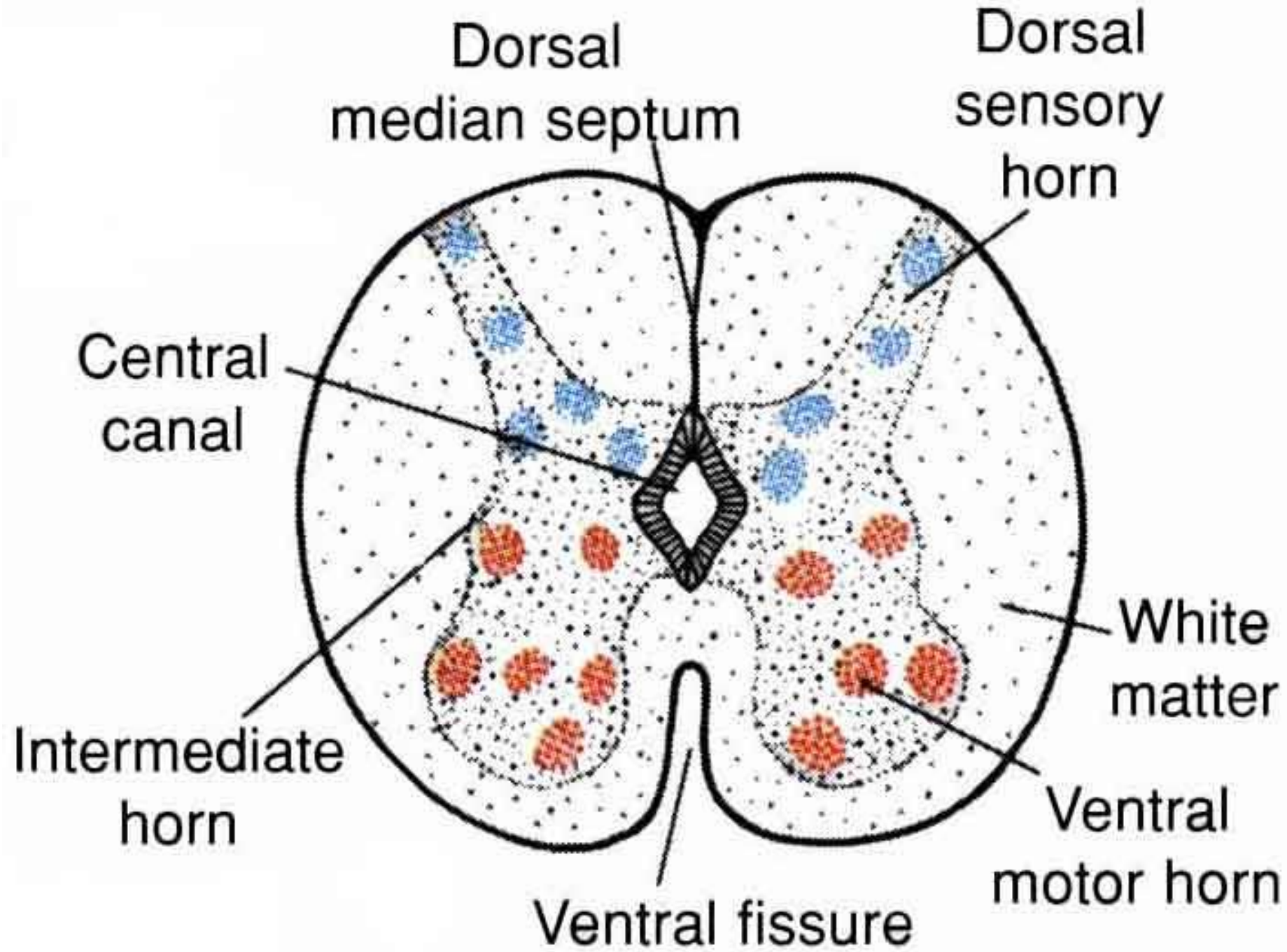
Cytodifferentiation in CNS

- Begins after the neural tube closes (the junction of the cervical and occipital regions closes first)
- The wall of this tube is initially composed of a layer of neuroepithelium
- Mitosis takes place in the **ventricular zone** (inner zone close to the central canal)
- The first newly formed population are **neuroblasts** (young neurons) migrating into the mantle zone, which is the precursor of the grey matter
- Neuroblasts further create the **marginal zone** with their processes, which eventually develops into white matter
- The migration of neurons is facilitated by the **radial glia**
- The next (i.e. later-forming) population is the **glioblasts**, which give rise to oligodendrocytes and astrocytes
- **Microglia** are cells related to macrophages, so do not arise from neuroepithelial cells

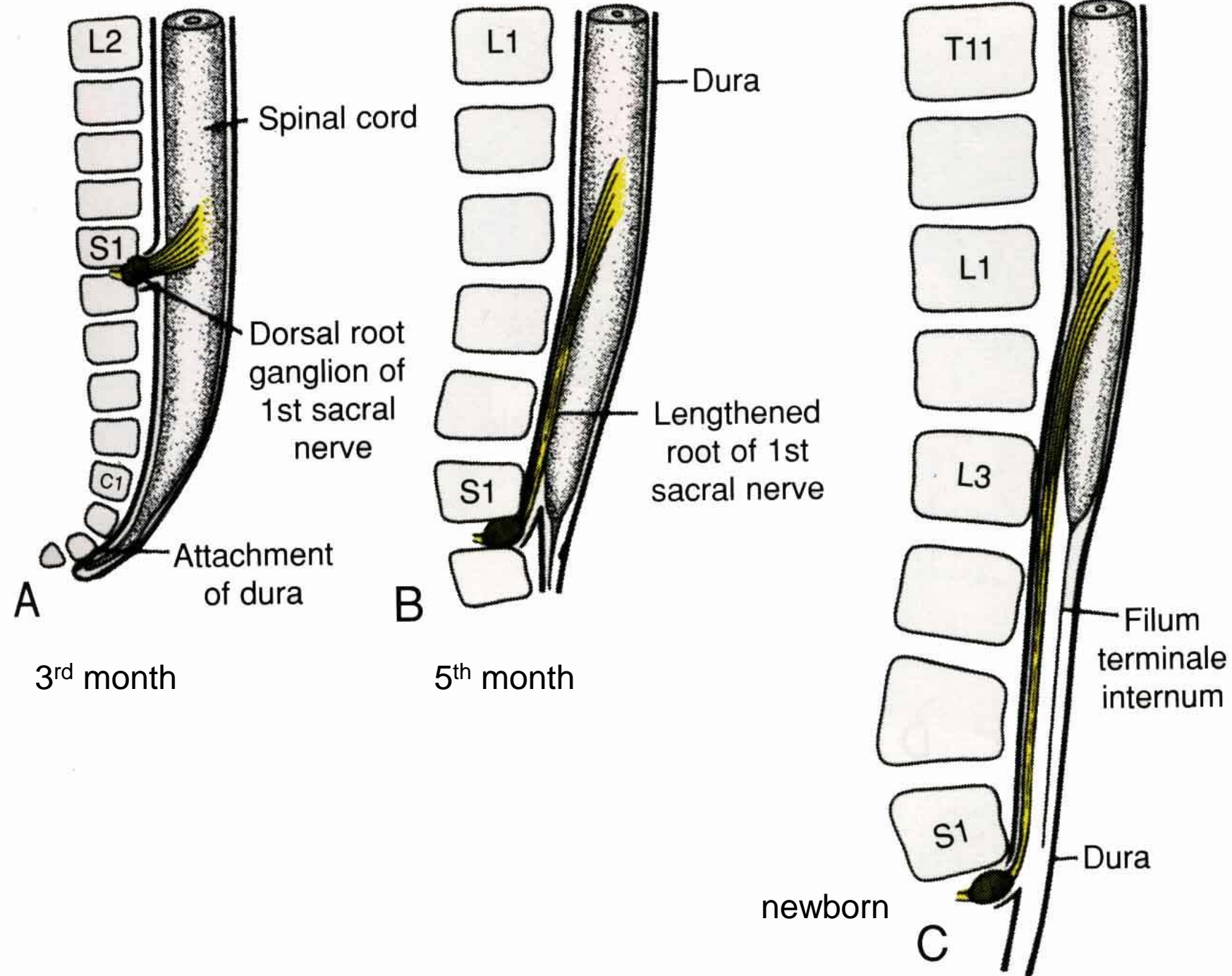


A

B



Spinal cord and vertebral column



Spinal cord development

- At the end of the 4th week, the neurons of the mantle zone divide into paired **basal** (ventral) and **alar** (dorsal) plates, which are separated by the sulcus limitans
- Dorsally, the neural tube is closed by the roof plate, ventrally by the floor plate
- Motor neurons develop from the basal plate, its more dorsal part gives rise to efferent sympathetic and parasympathetic neurons in the thoracolumbar and sacral regions, respectively
- The alar plate develops into interneurons
- Thus, in simplified terms, the posterior spinal cord horns arise from the alar, while the anterior spinal cord horns arise from the basal plate
- The white matter arises from the marginal zone and contains neuronal processes

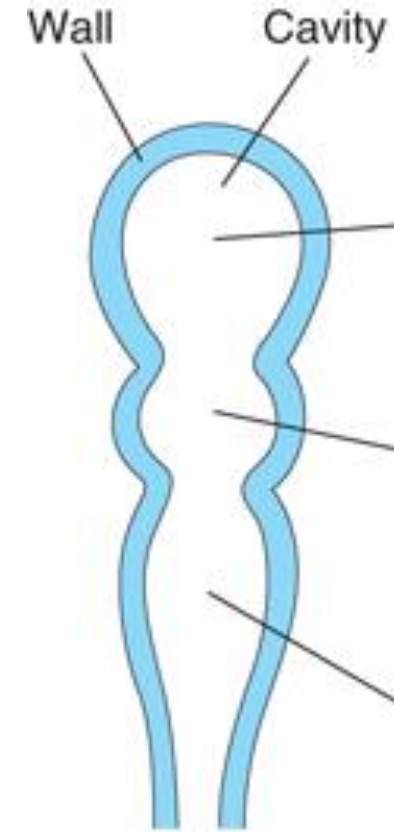
3 Primary vesicles

5 Secondary vesicles

Adult derivatives of

Walls

Cavities



Forebrain
(prosencephalon)

Midbrain
(mesencephalon)

Hindbrain
(rhombencephalon)

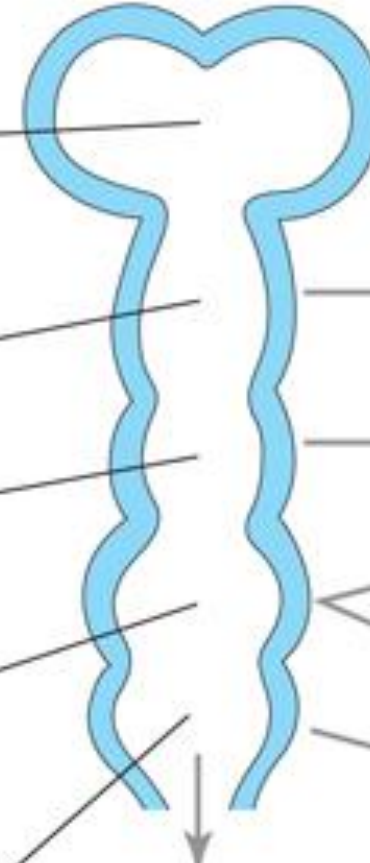
Telencephalon

Diencephalon

Mesencephalon

Metencephalon

Myelencephalon



Cerebral
hemispheres

Thalami, etc.

Midbrain

Pons

Cerebellum

Medulla

Lateral ventricles

Third ventricle

Aqueduct

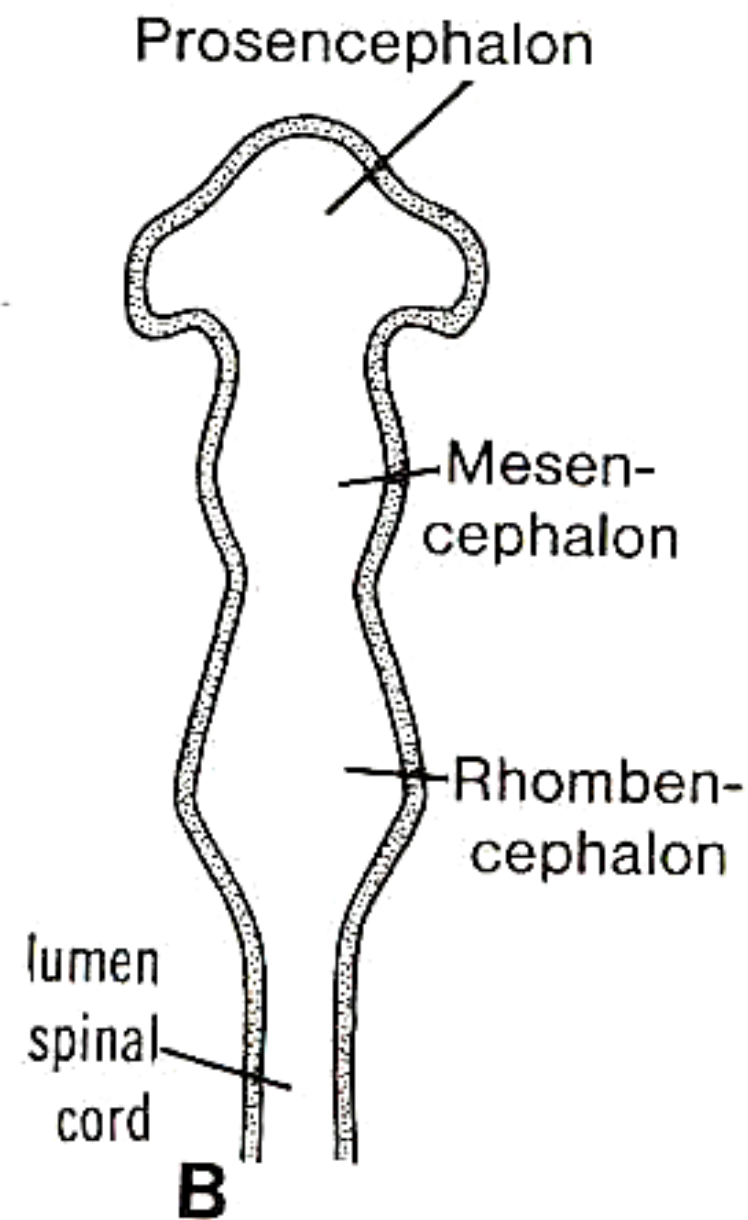
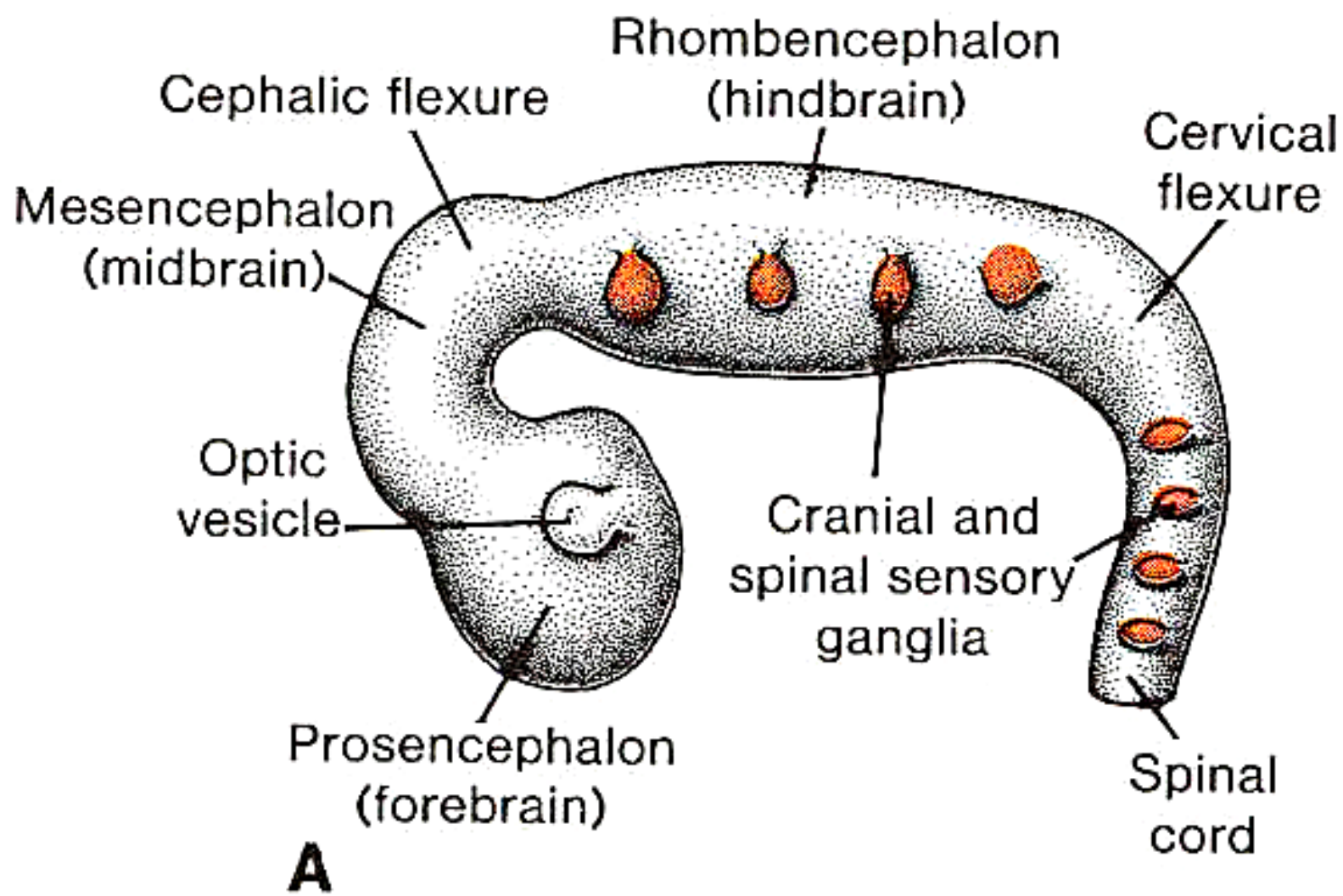
Upper part of
fourth ventricle

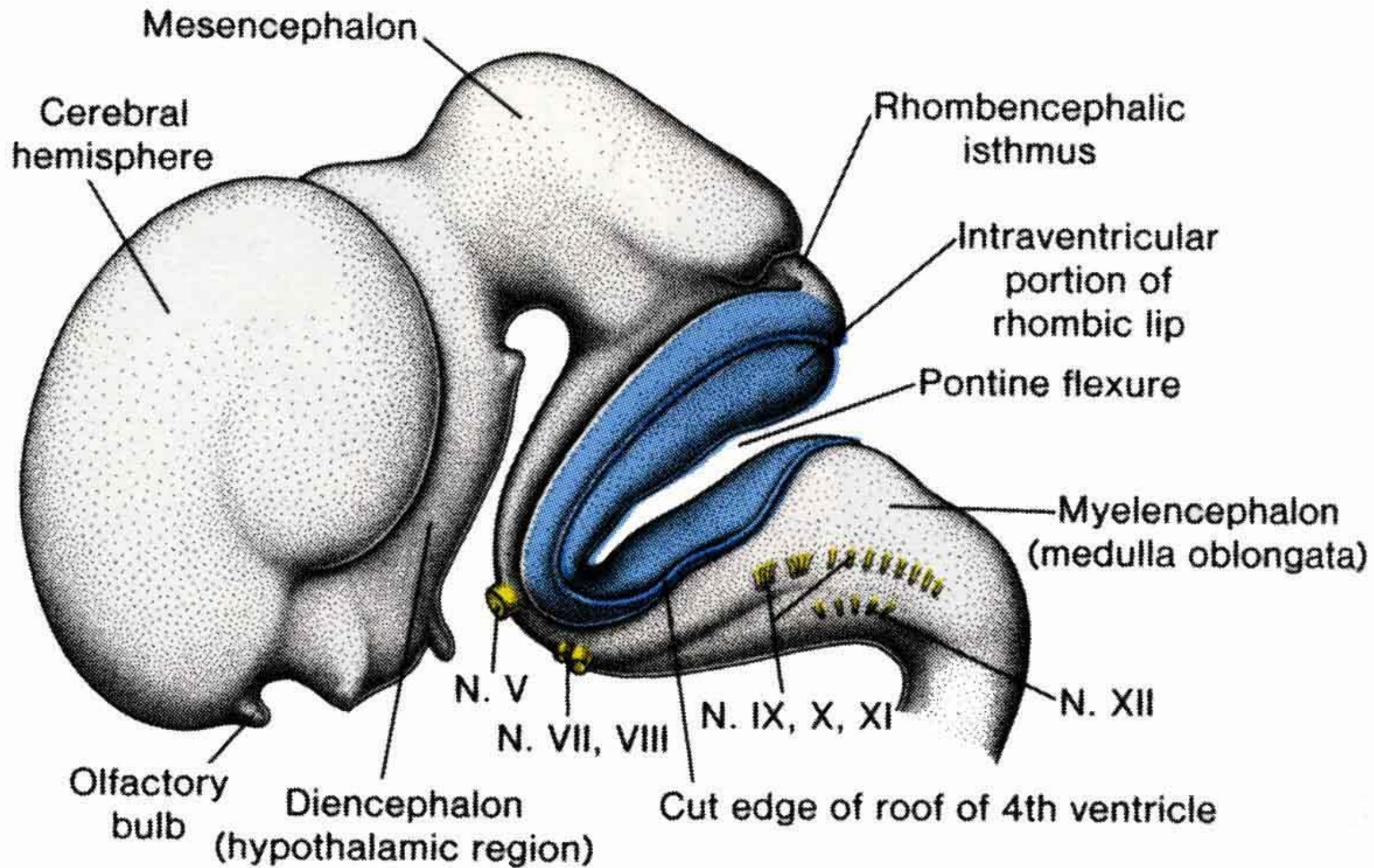
Lower part of
fourth ventricle

Spinal cord

4th week

5th week





Lateral ventricle

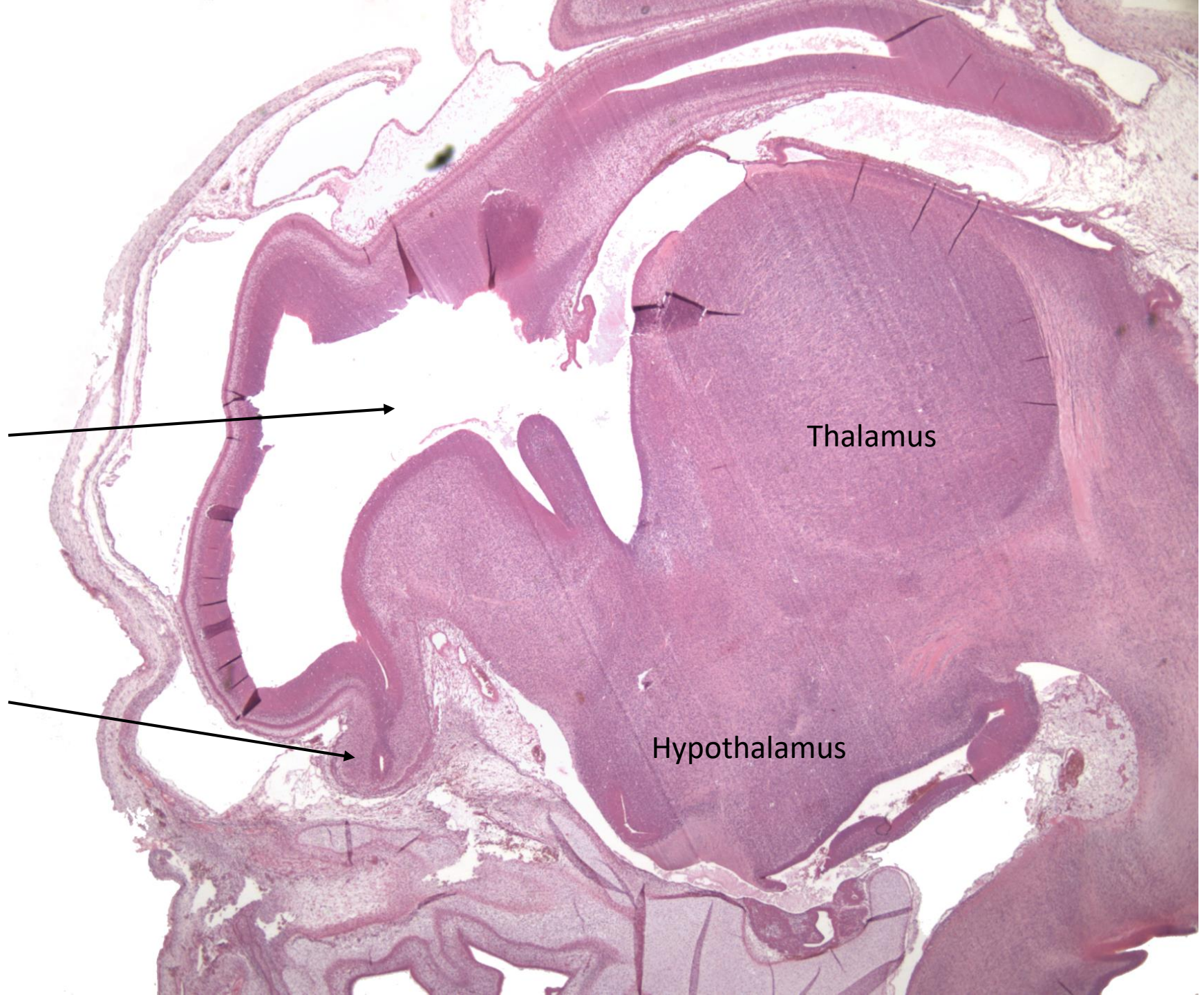


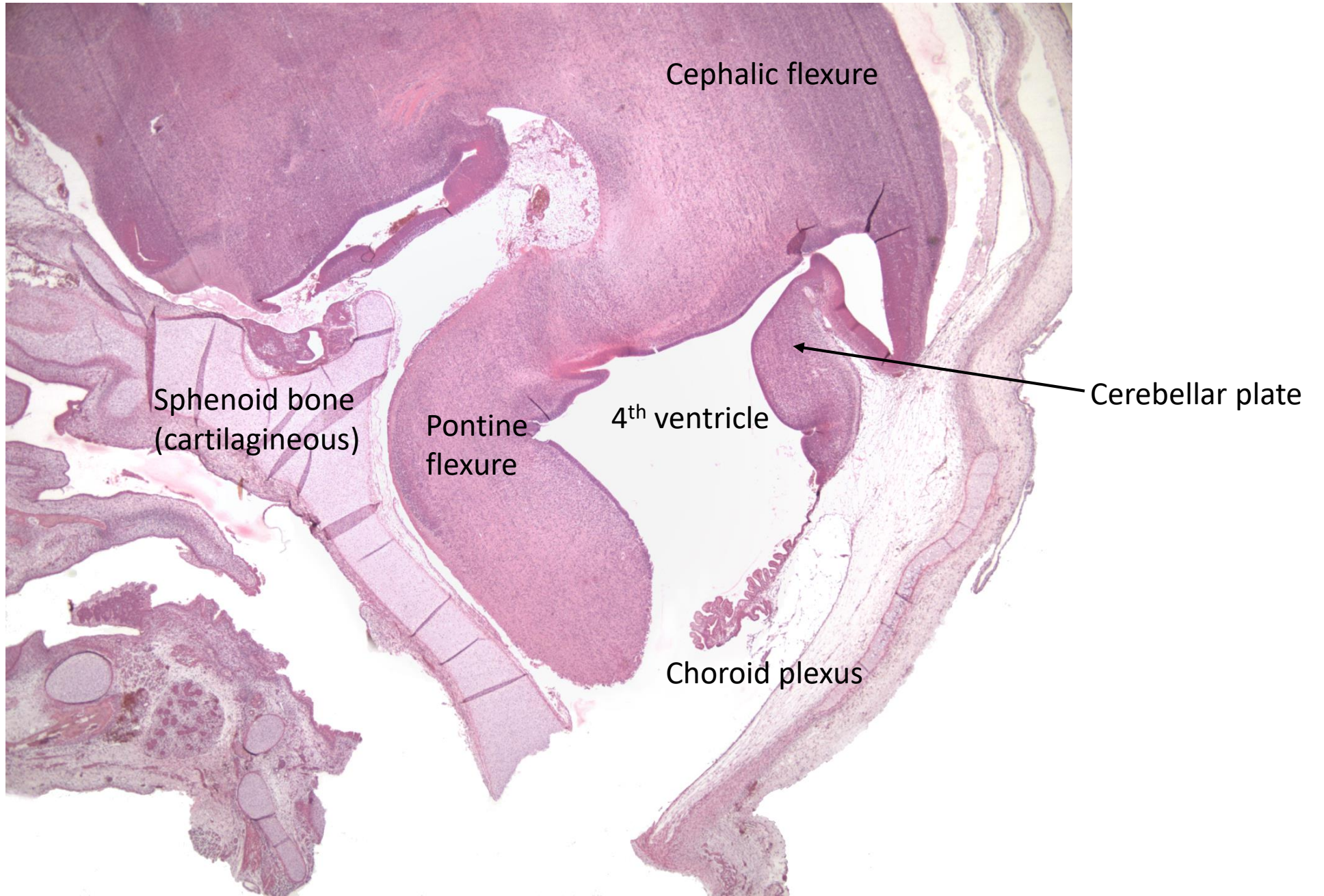
Olfactory bulb

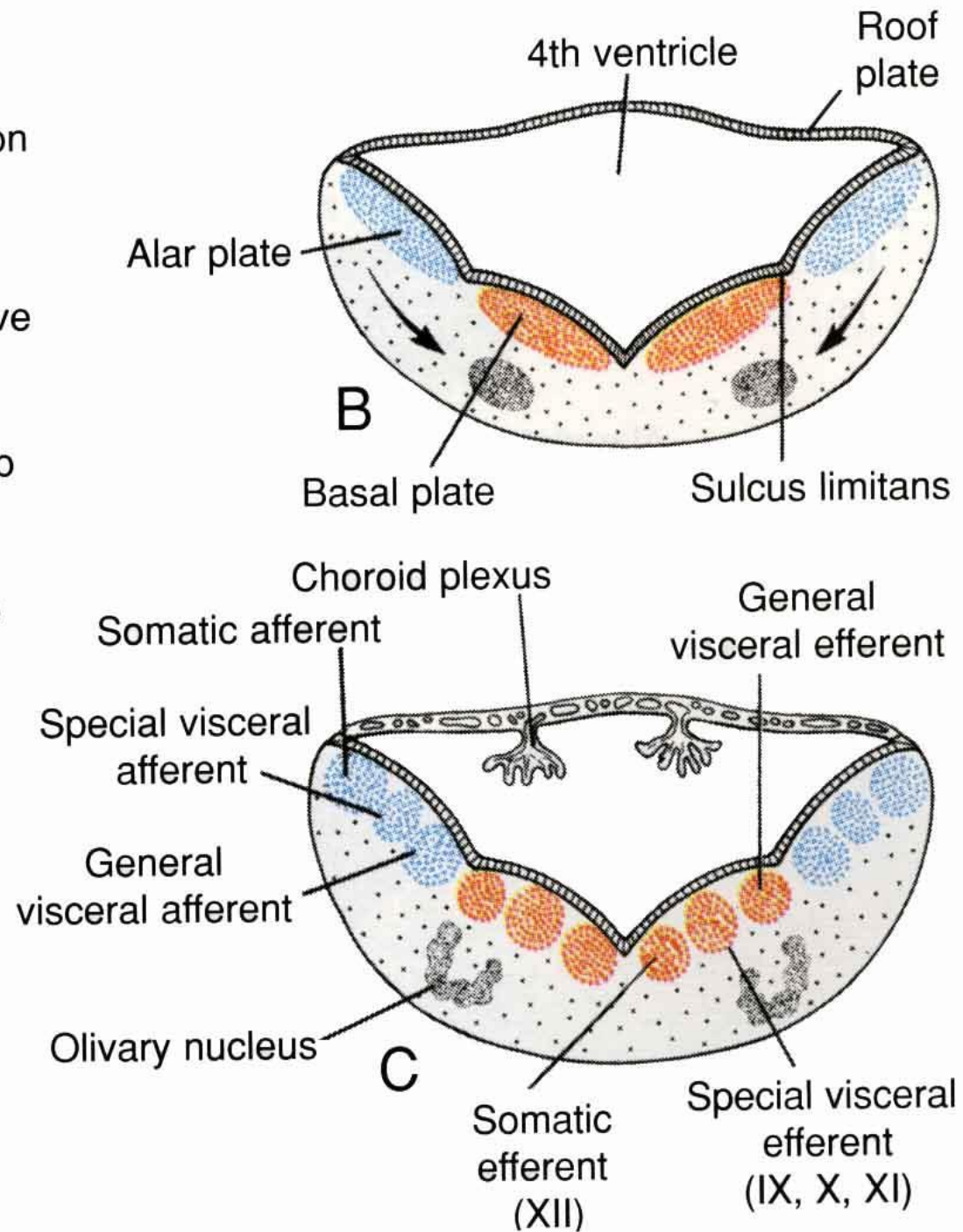
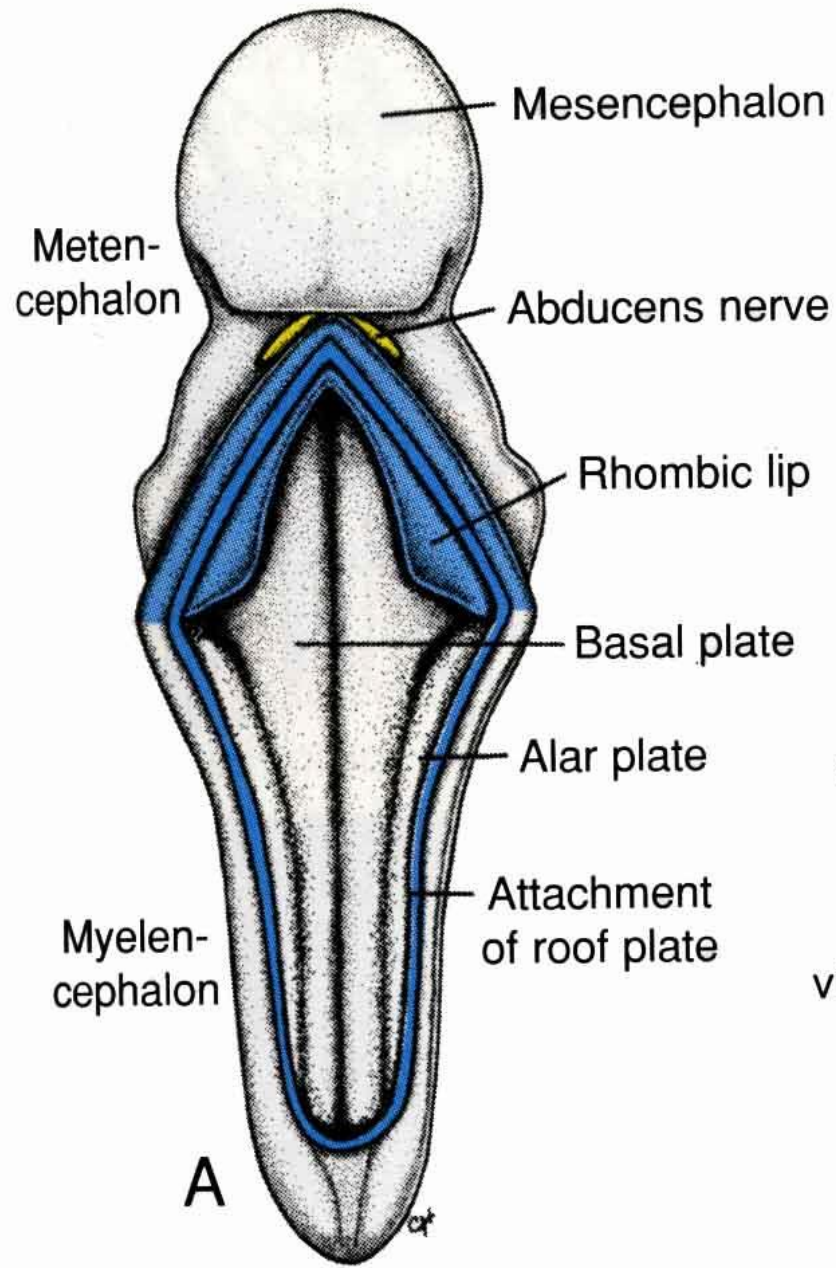


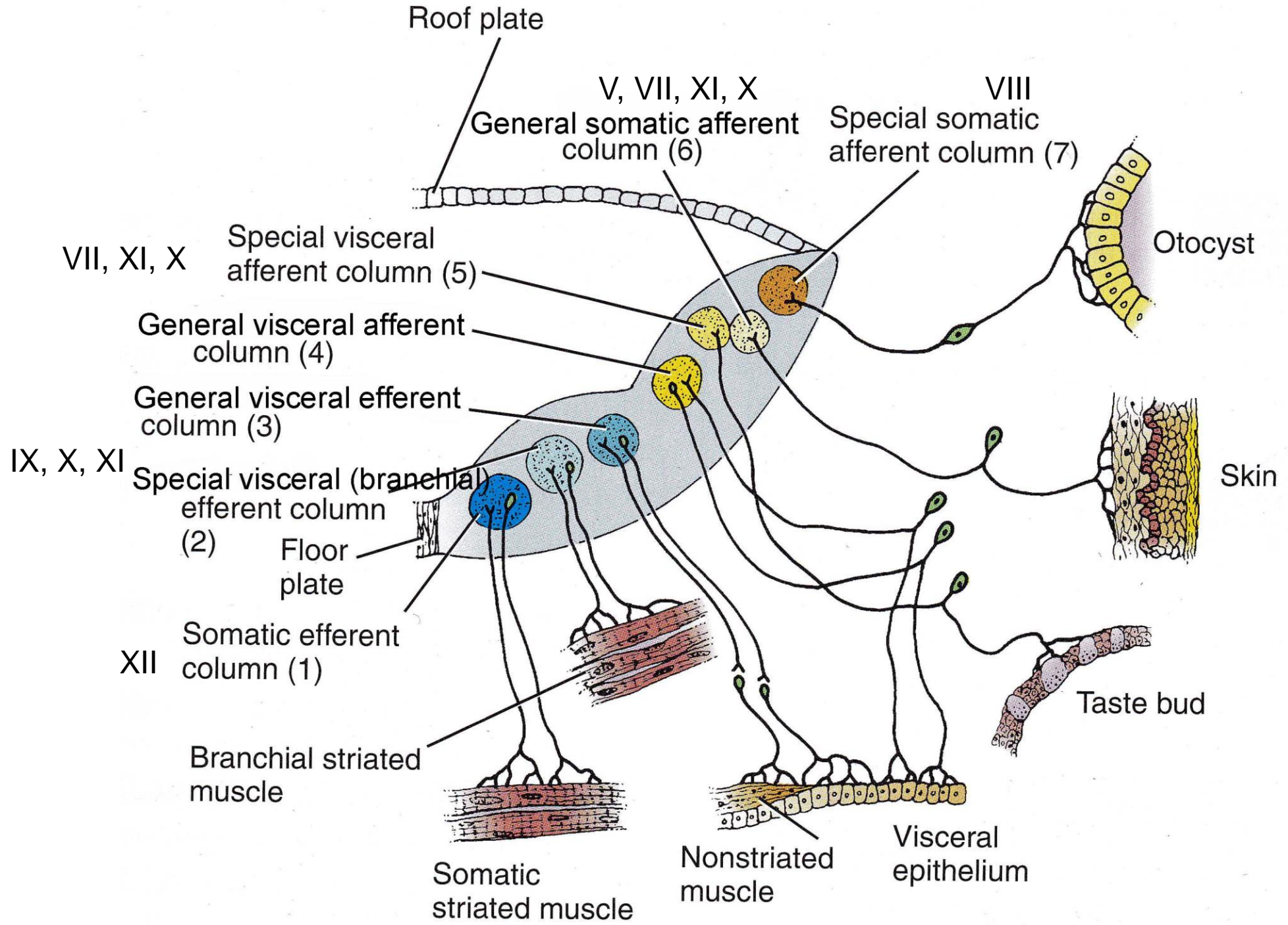
Thalamus

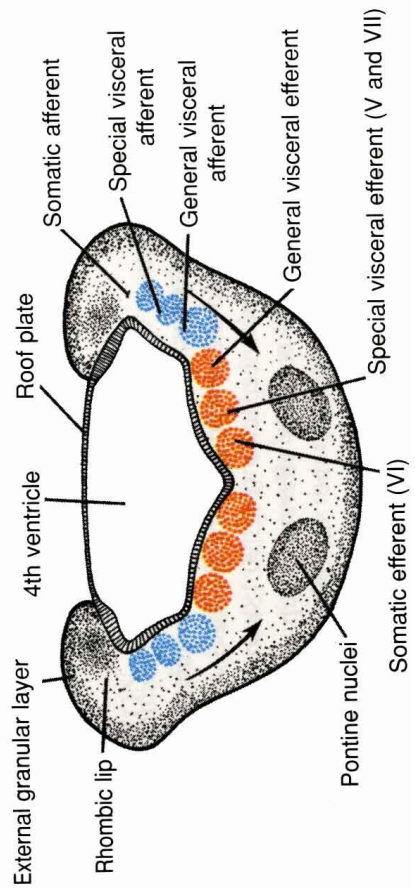
Hypothalamus











THE BATTLE OF CANNAE

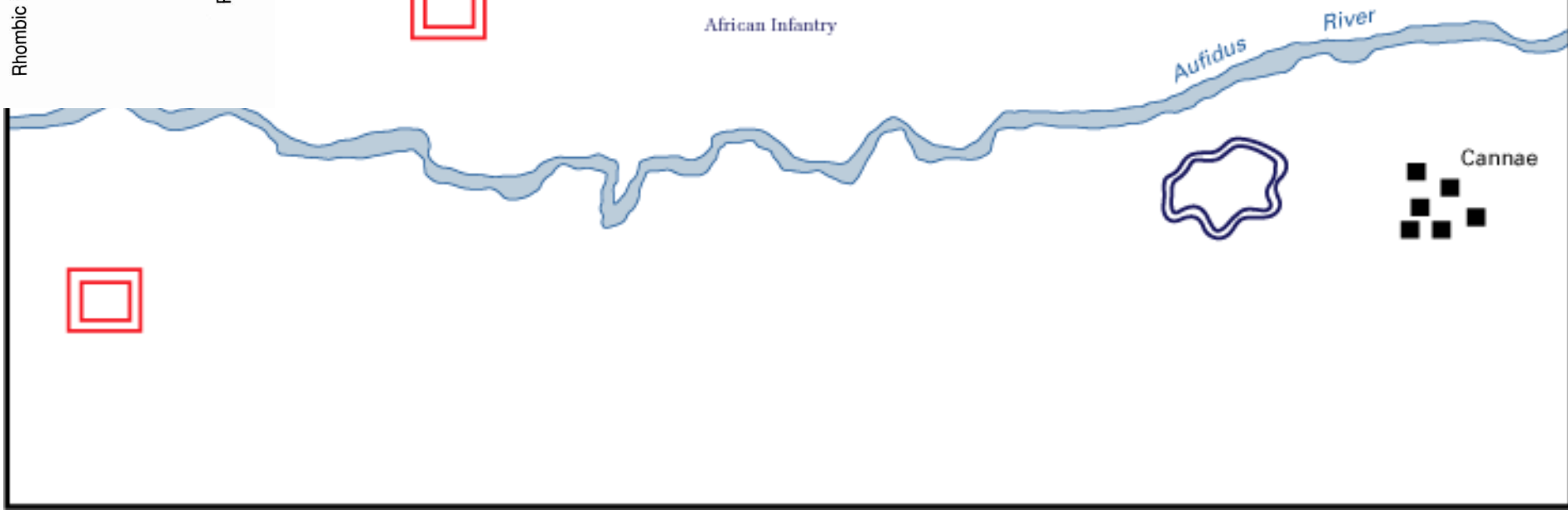
215 B.C.

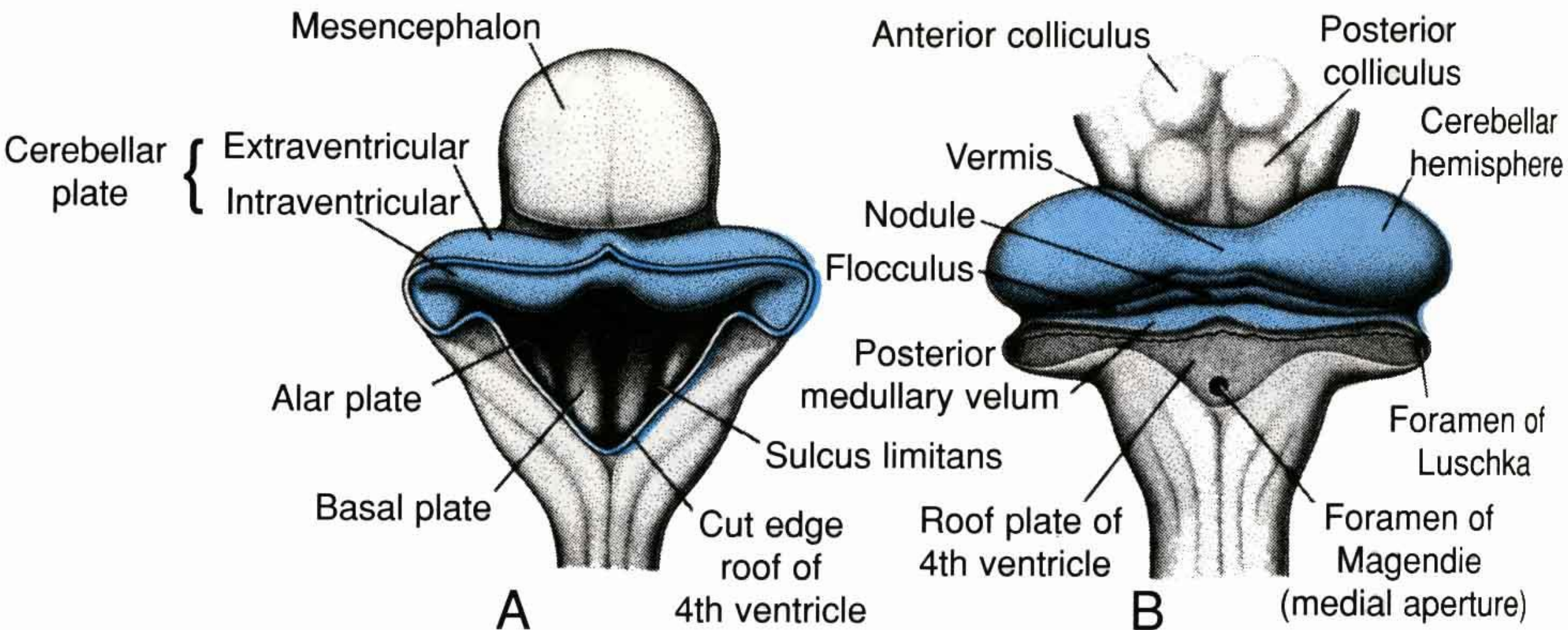
Destruction of the Roman Army

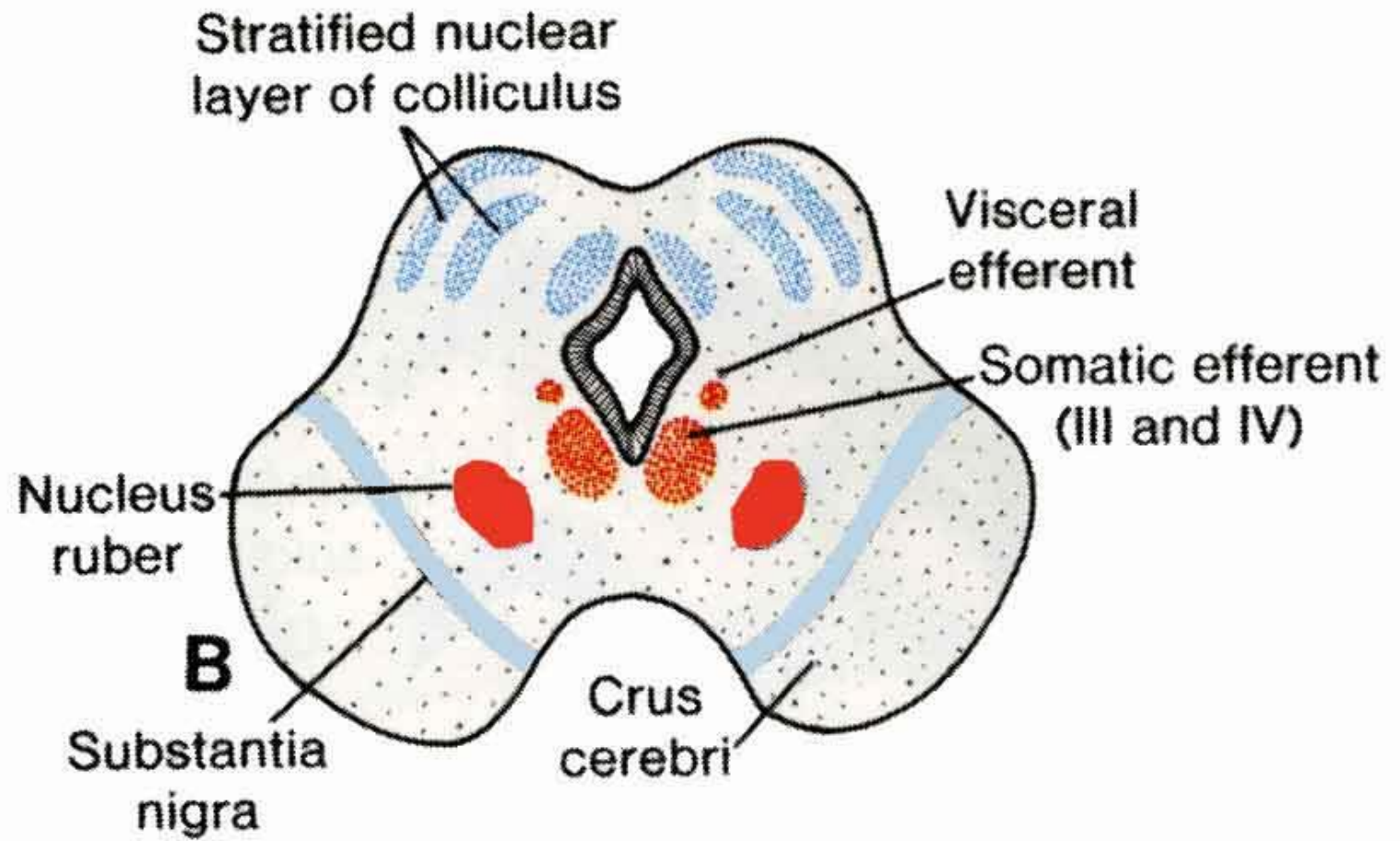
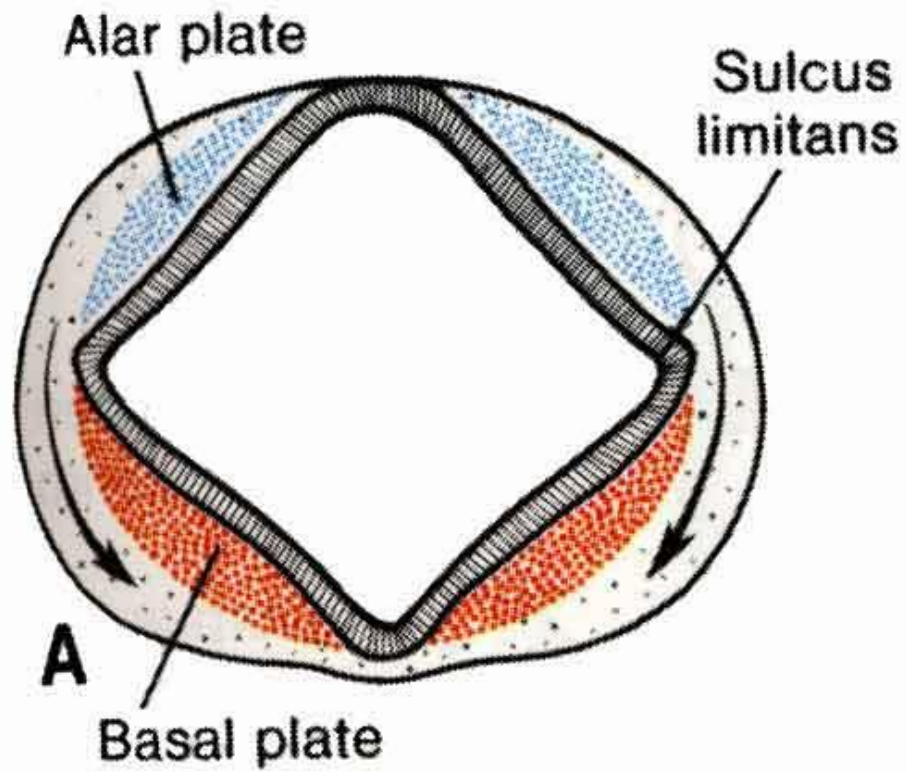
N

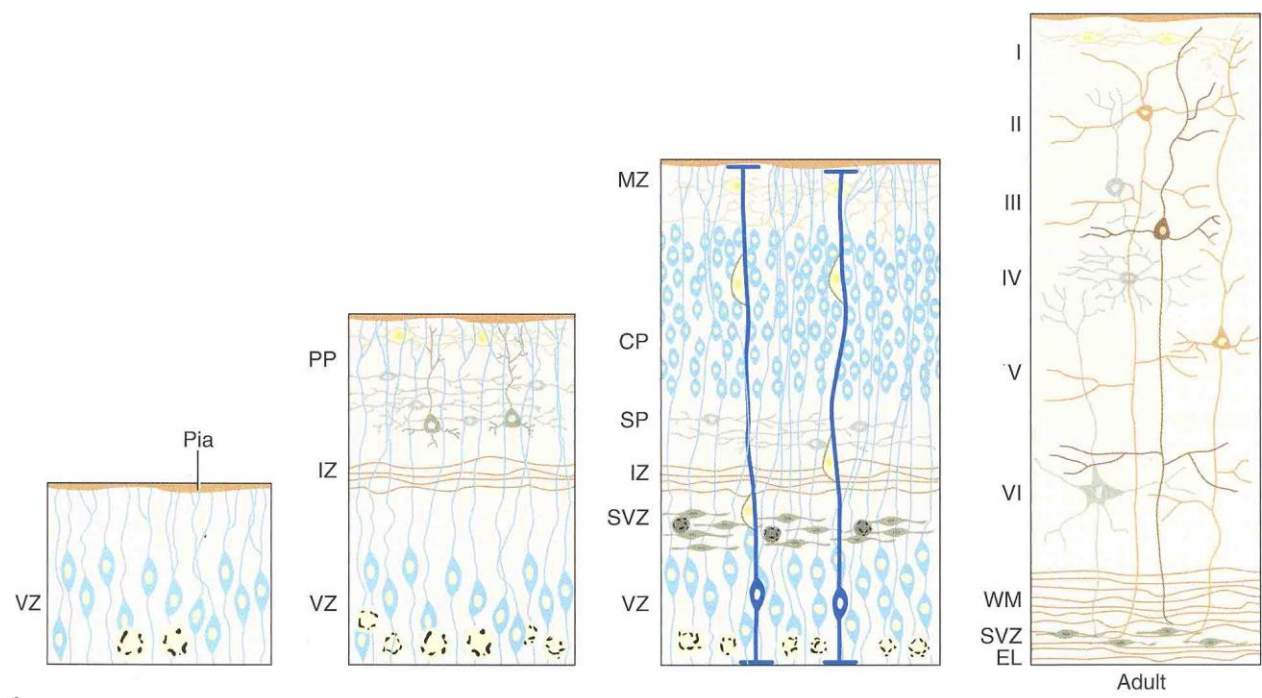
SCALE OF MILES

0 1/2 1

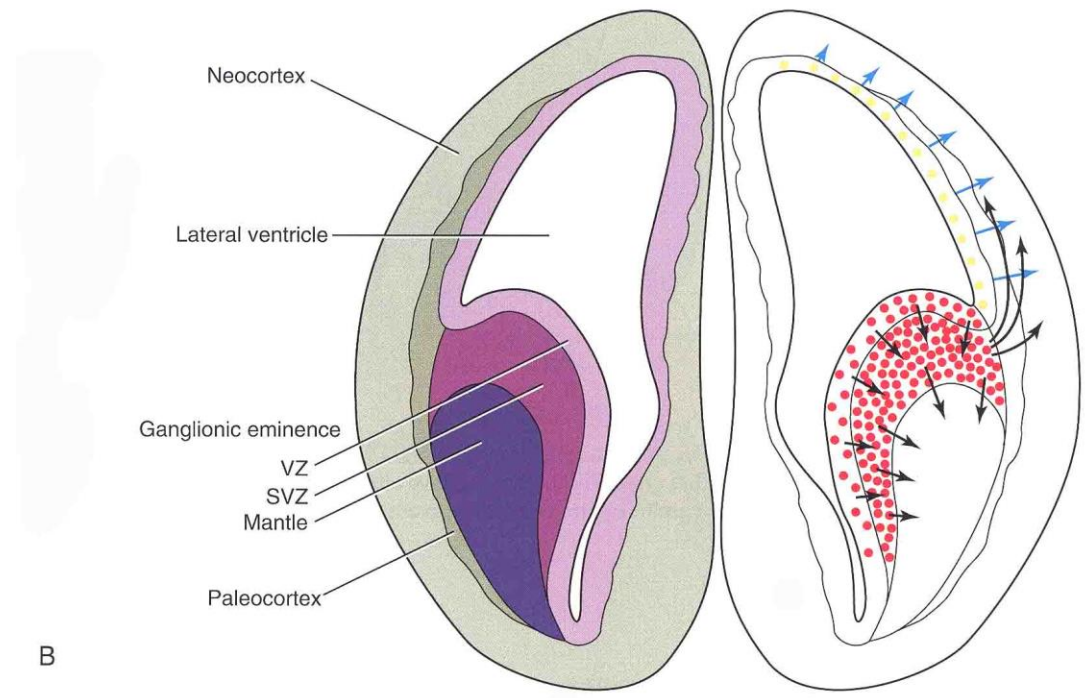




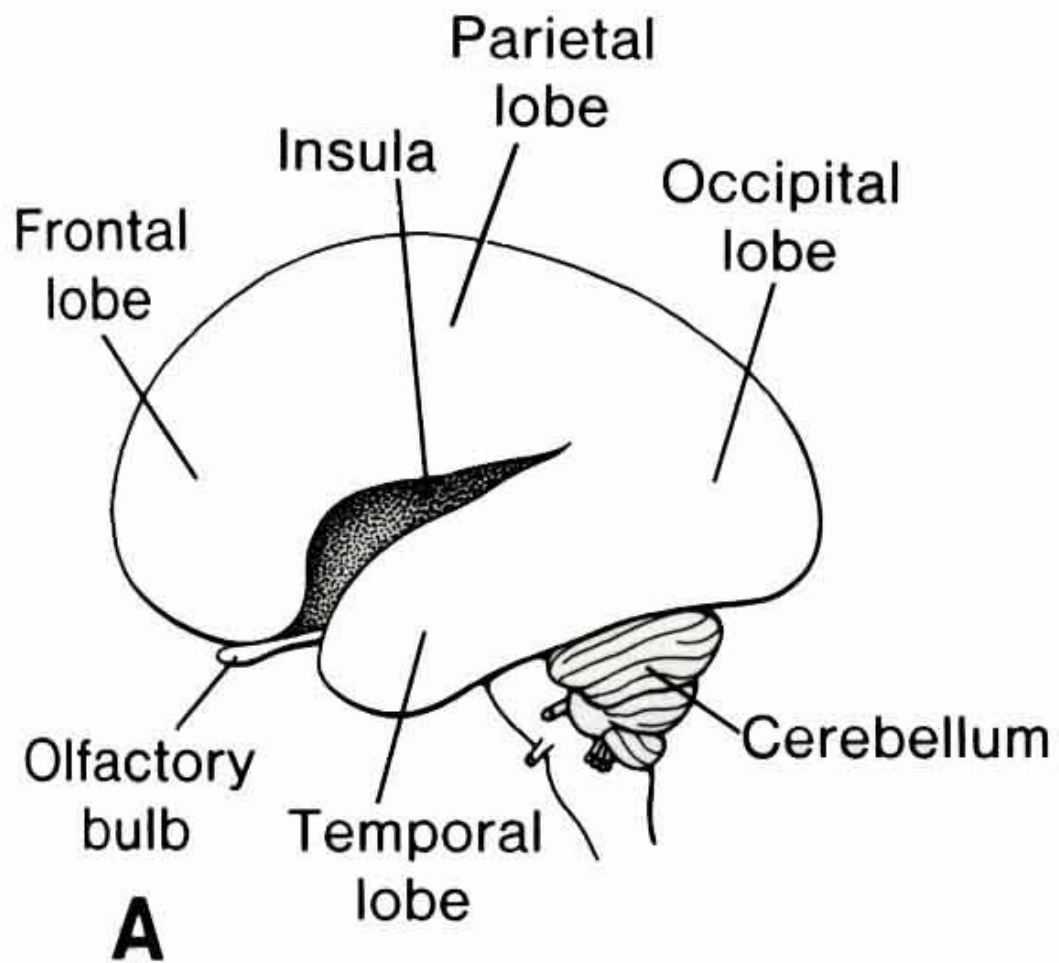




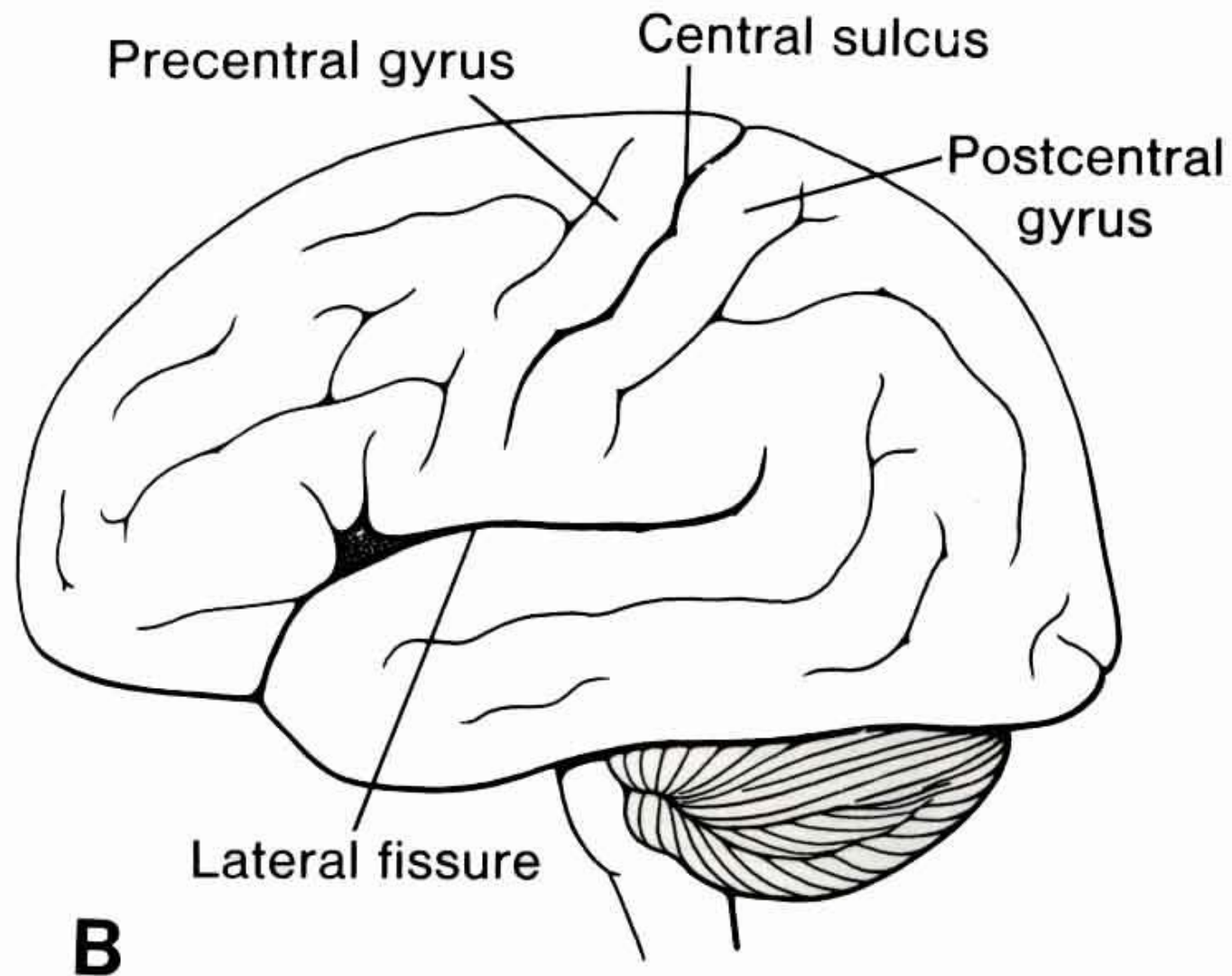
A



B



7 months



9 months

Brain development - an overview

- The 3 primary brain vesicles (rhombencephalon, mesencephalon and prosencephalon) divide into 5 secondary brain vesicles (myelencephalon, metencephalon, mesencephalon, diencephalon, telencephalon)
- The flexura cervicalis and the flexura cephalica are also formed, while flexura pontina is formed later

Rhombencephalon

- The roof plate of the rhombencephalon forms the broad roof of the fourth ventricle
- The myelencephalon corresponds to the medulla oblongata, the basal and alar plate each become 3 groups of neurons that become the foundations of the respective cranial nerve nuclei and association nuclei
- The metencephalon is divided into the pons, which has a similar architecture to the medulla oblongata, and the cerebellum, which is a derivative of the alar plate and gradually grows over the roof plate

Mesencephalon

- In the mesencephalon, the basic division into derivatives of the basal and alar plates is approximately preserved
- The tegmentum develops from the basal plate, containing the somato- and visceromotor nuclei of the nerves III and IV
- The alar plate develops into the tectum with two pairs of colliculi (corpora quadrigemina)

Prosencephalon

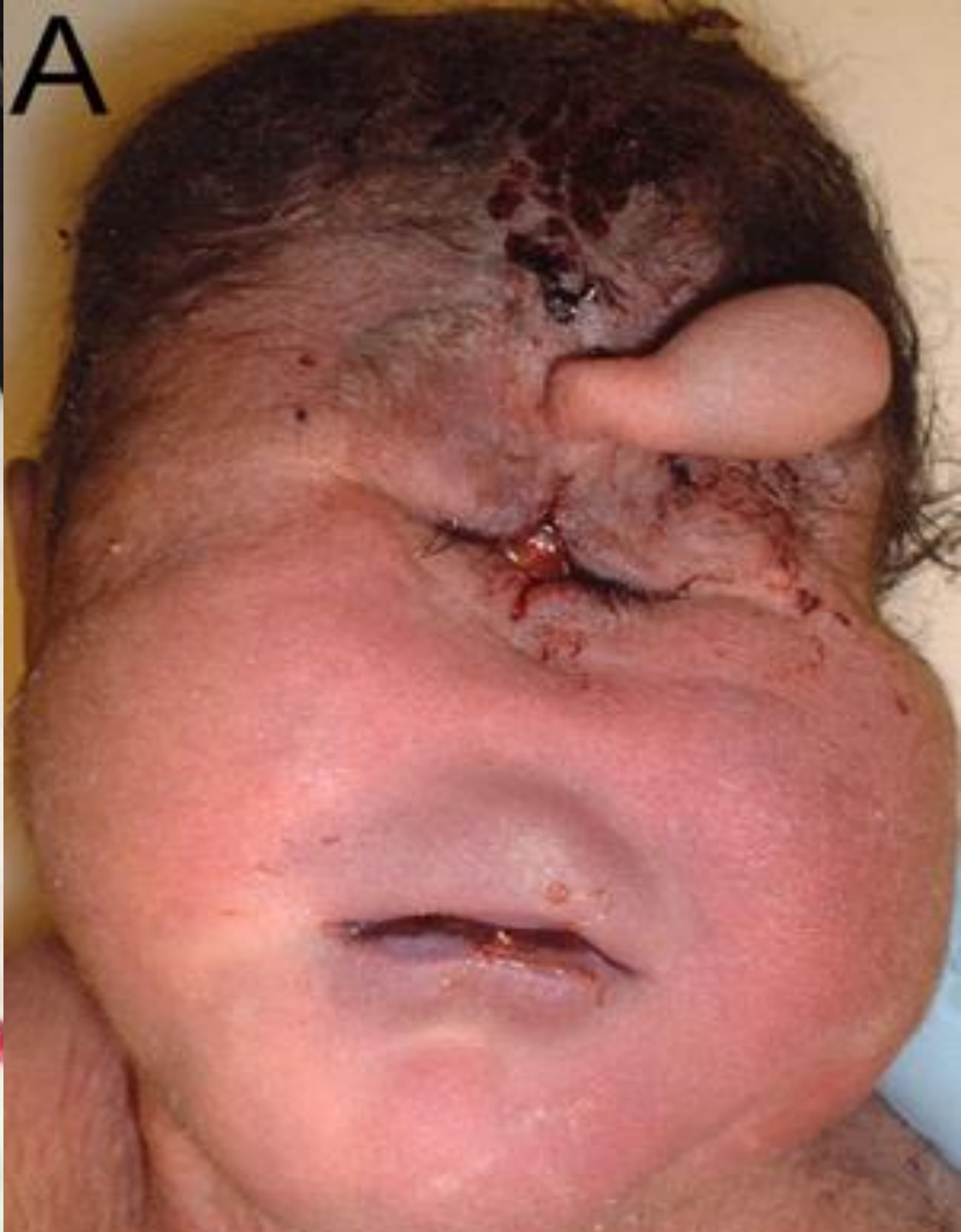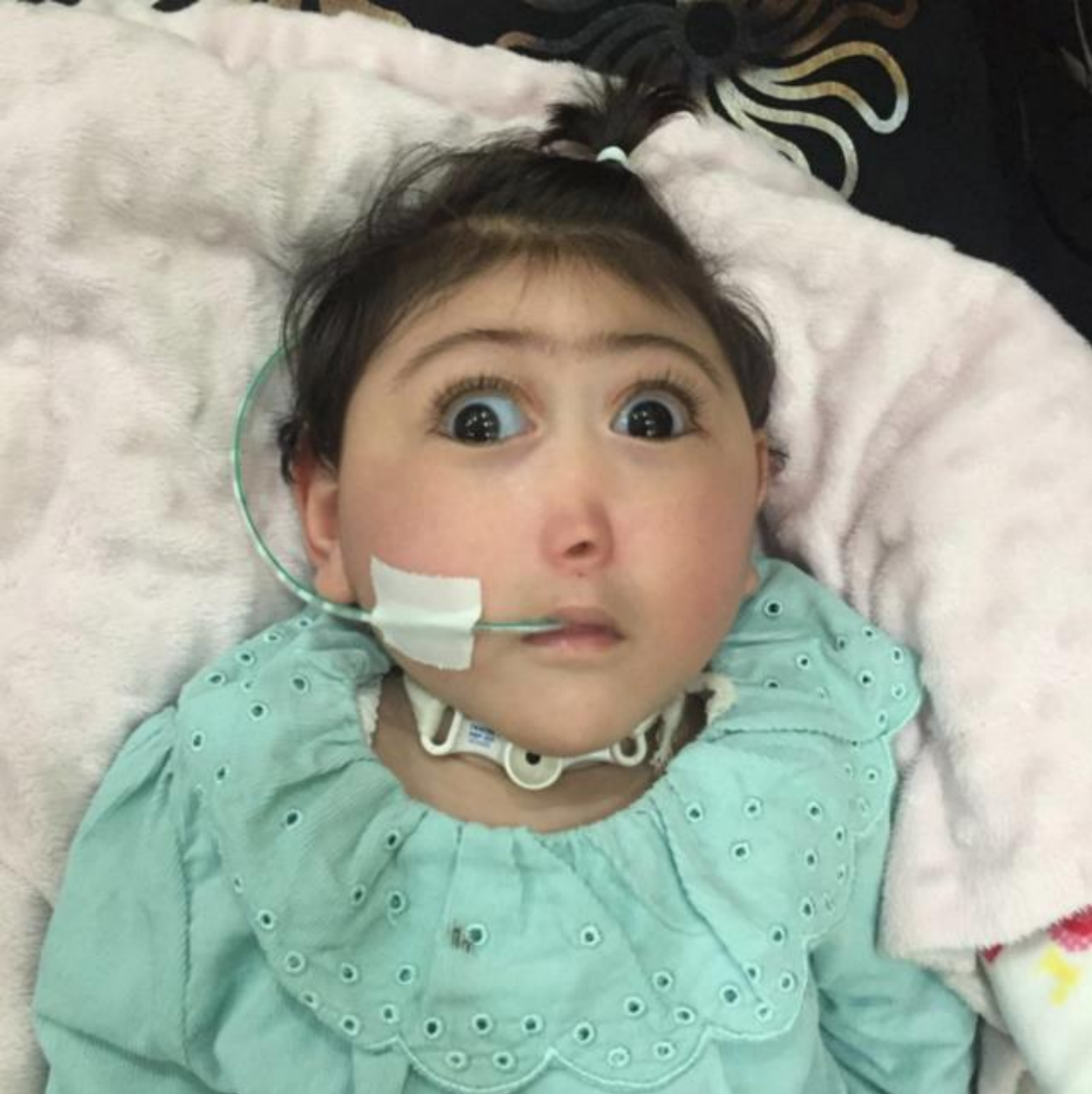- The prosencephalon is thought to be a derivative of the alar plate without a significant contribution of the basal plate

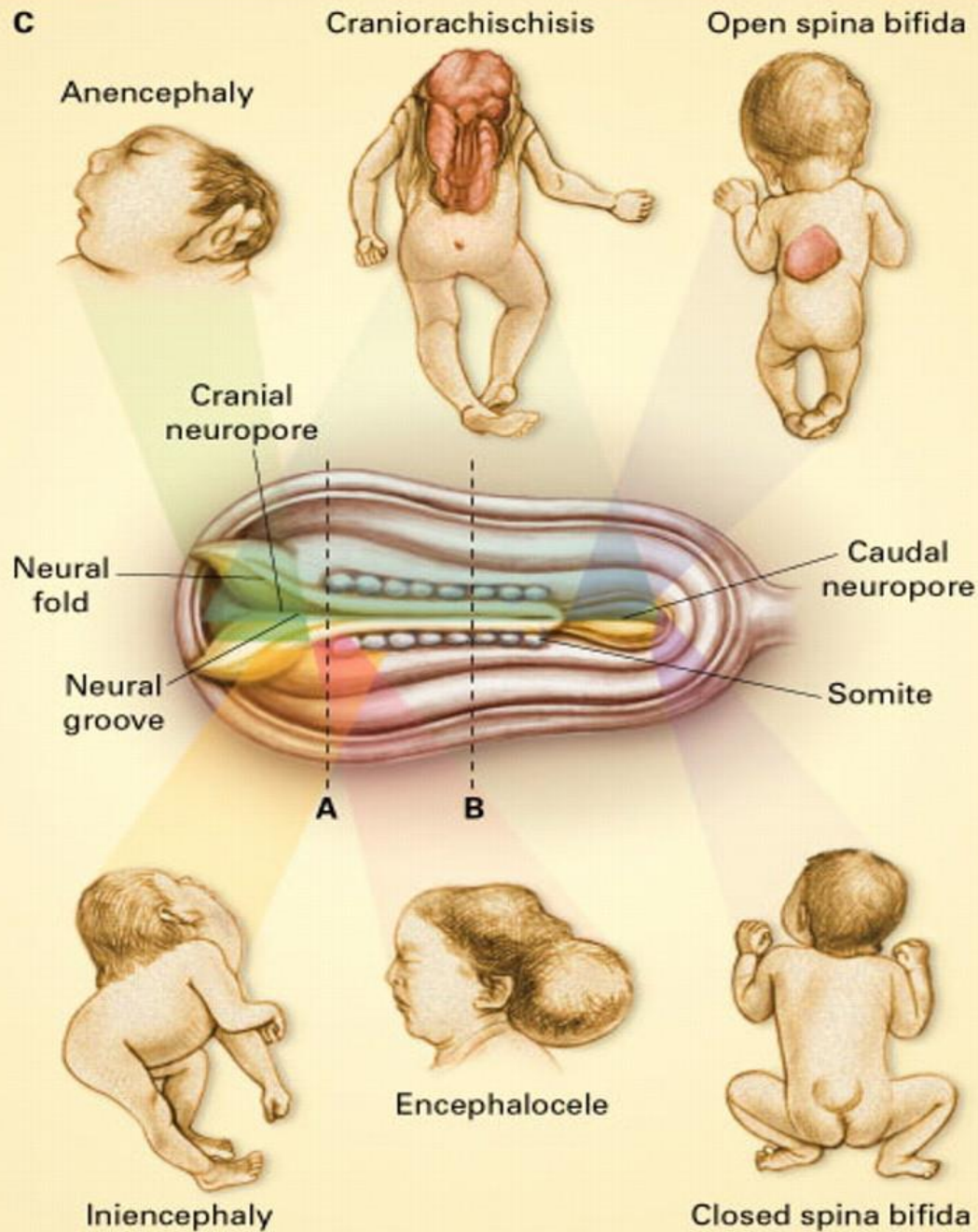
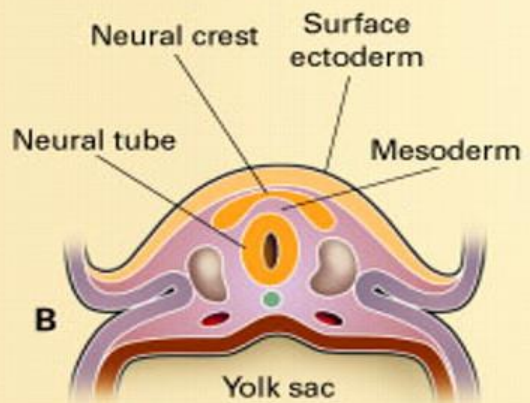
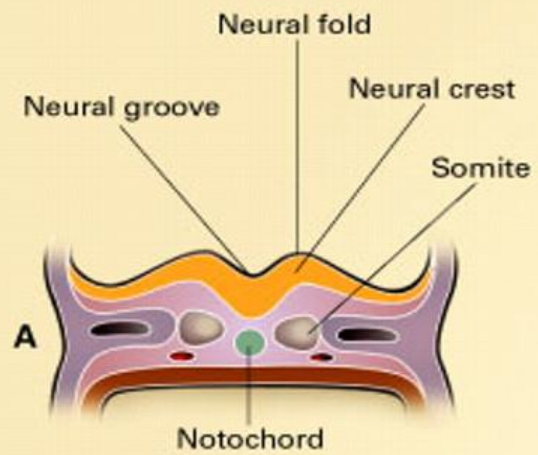
Diencephalon

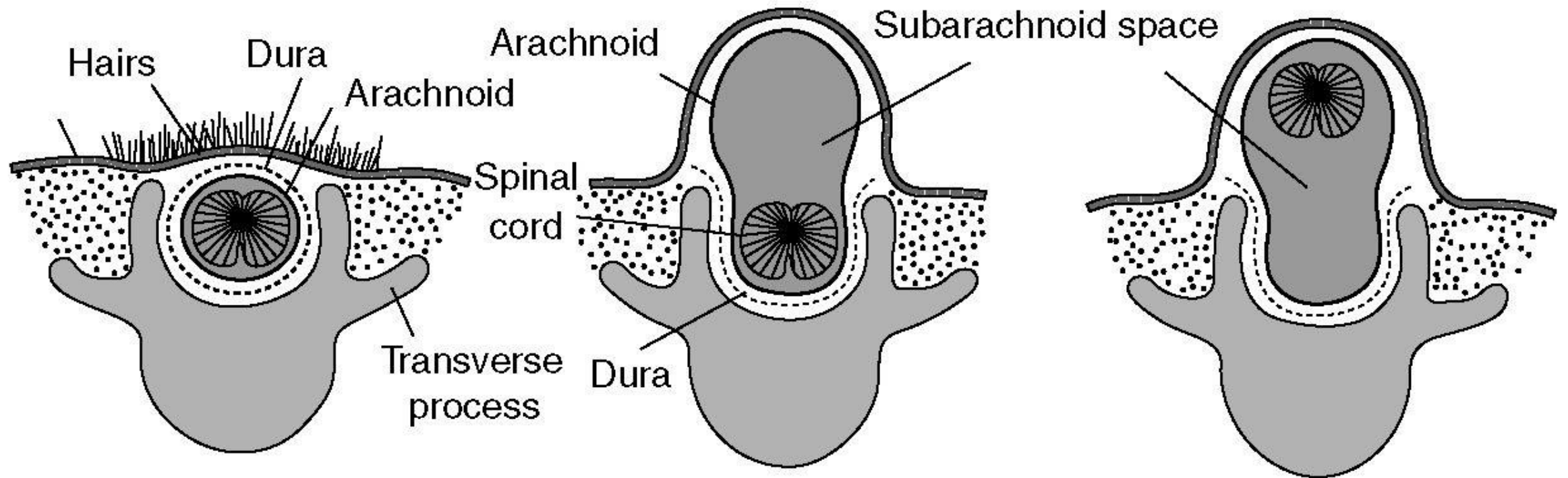
- The rostral part of the **diencephalon** gives rise to the hypothalamus, behind which develop the thalamus and epithalamus (including glandula pinealis)
- The thalamus grows the largest of all these parts, the opposite masses even join together by so-called thalamic adhesions (massa intermedia)
- The diencephalon also gives rise to the two optic cups (the origin of the retina) and to the infundibulum - the origin of the neurohypophysis, which joins with the Rathke's pouch of the stomodeum - the origin of the adenohypophysis

Telencephalon

- The **telencephalon** arises from two spherical swellings on the sides of the prosencephalon, which gradually outgrow the diencephalon to become the cerebral hemispheres
- Lateral cerebral ventricles initially occupy most of the volume of the hemispheres, but their proportion decreases as the telencephalon grows
- The fissura choroidea remains on the medial side of the hemisphere, where the pia mater inserts into the plexus choroideus of the lateral ventricle
- Histogenesis of the cortex cerebri is a complex process involving several migratory waves from the ventricular and subventricular zones towards the surface of the hemisphere guided by the radial glia, to which are added additional neurons migrating from ganglionic eminences located on the ventral side of the hemisphere
- By the 7th month, the hemisphere is already in the lobated and in the following months the hemispheres further gyrate, the brain grows to its final size at about 7 years



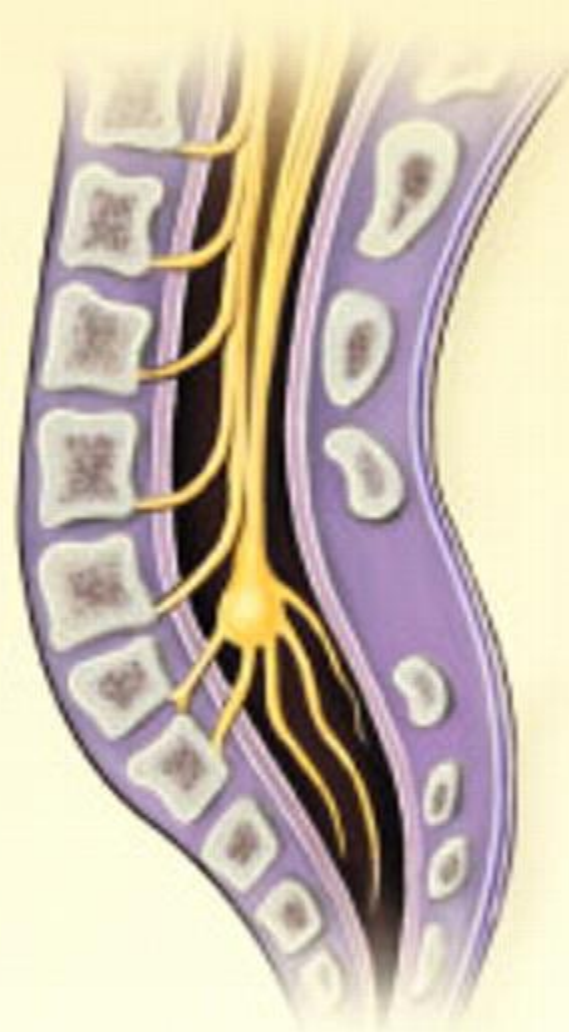



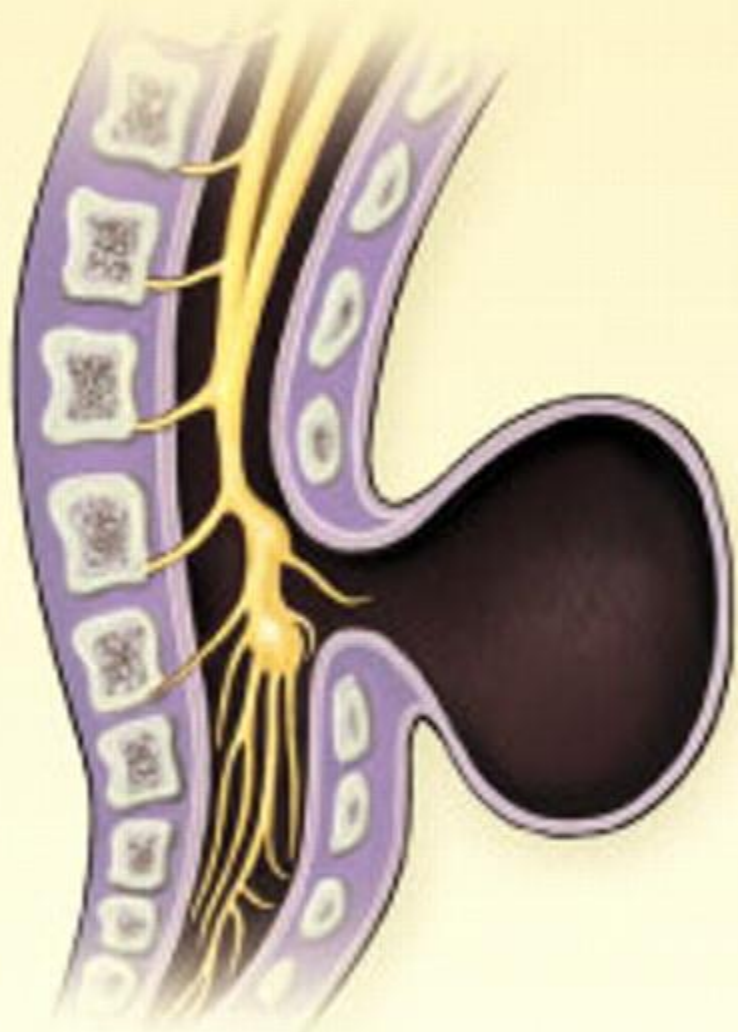
(a) Spina bifida occulta

(b) Meningocele

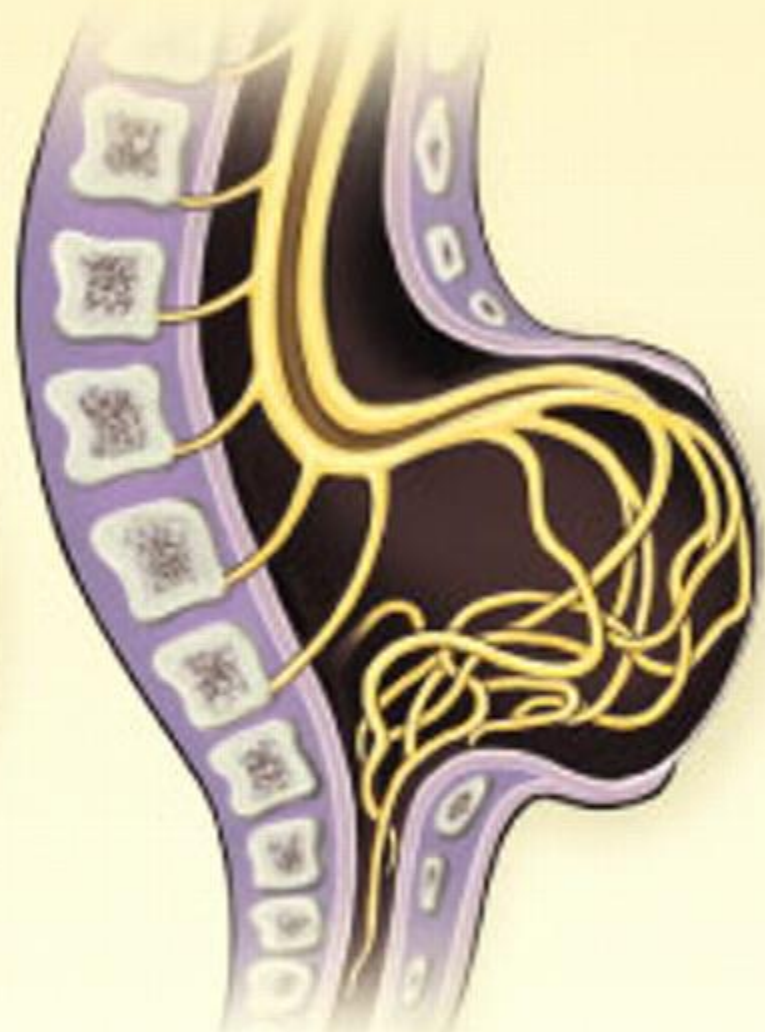(c) Meningomyelocele



Spina bifida occulta



Meningocele

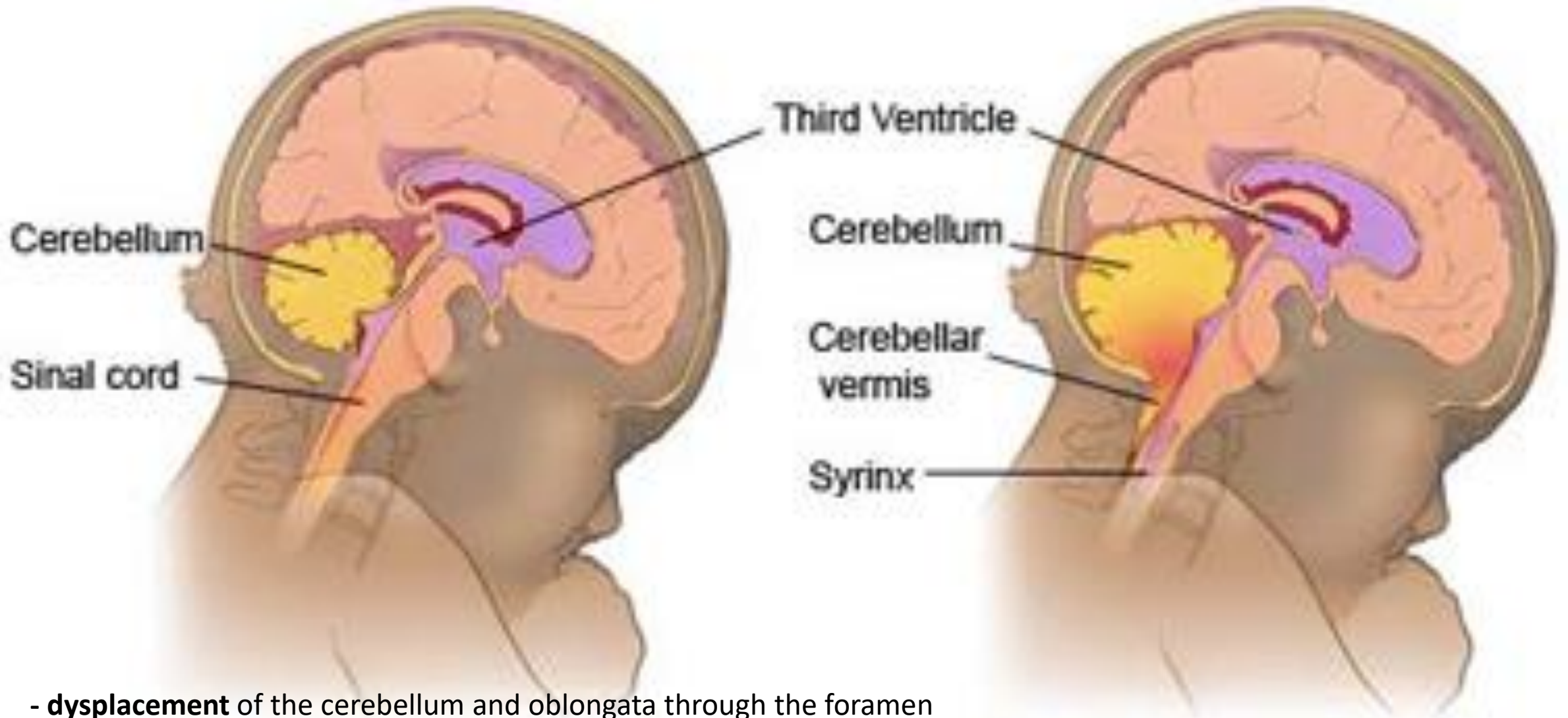


Myelomeningocele

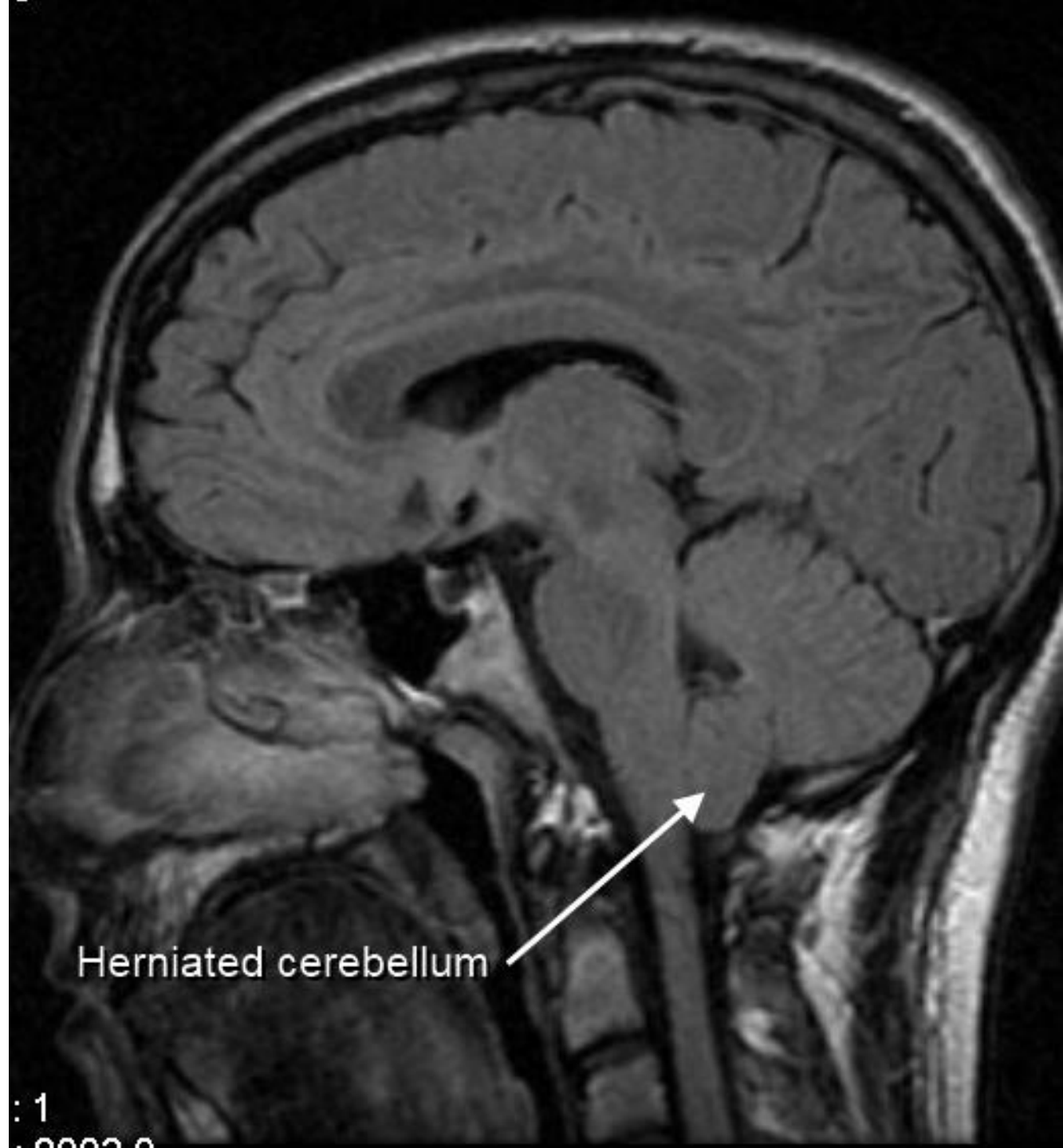Normal Brain

Chiari (Arnold-Chiari) malformace

Chiari Malformation



- **dysplacement** of the cerebellum and oblongata through the foramen magnum, that can cause hydrocephalus



Herniated cerebellum

: 1
: 0000 0

Developmental defects of the nervous system – neural tube closure defects

- Anencephaly, craniorachischisis and myeloschisis form a group of neural tube closure defects, are very severe and survival is severely limited
- Another defect is spina bifida, where the spinal canal is not closed and the spinal cord or just its meninges in the form of meningomyelocele or meningocele penetrate to the surface; these defects are usually associated with neurological disability of varying degrees
- Encephalocele is a herniation of the brain through a defect in the skull; the prognosis here also depends on the size of the defect
- Spina bifida occulta is a defect in which the defect of the spinal canal is only slightly visible, in the area of the lesion we can find the so-called neurocutaneous signs (pigmentation, hair, angioma, retracted skin...), it occurs in up to 2% of people

Developmental defects of the nervous system - holoprosencephaly

- Holoprosencephaly is caused by the failure of the prosencephalon to divide into two halves, manifested by neurological deficit and craniofacial malformations (cyclopia, synophthalmia, proboscis), death occurs in most cases in the first year of life
- There are also milder variants with incomplete hemispheric division and milder craniofacial malformations, here the prognosis is better, but with severe neurological and cognitive deficits
- The frequency of the defect is reported to be around 1:10000 births, but up to 1:250 in spontaneous abortions

Developmental defects of the nervous system – Chiari malformation

- Chiari malformation is characterized by herniation of the cerebellar tonsils and sometimes part of the brainstem into the foramen magnum, often accompanied by hydrocephalus or syringomyelia
- There are several anatomically and clinically distinct subtypes, often accompanied by other defects (e.g. meningomyelocele)

