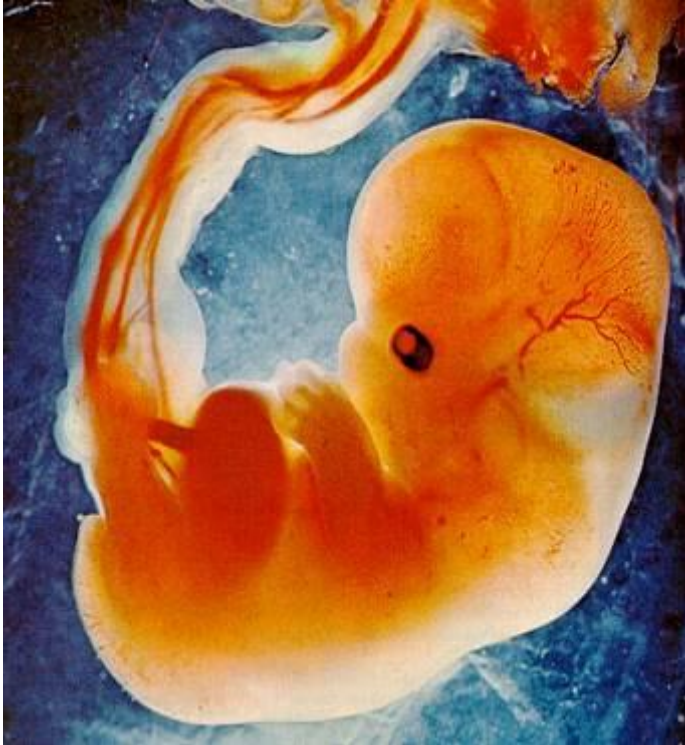
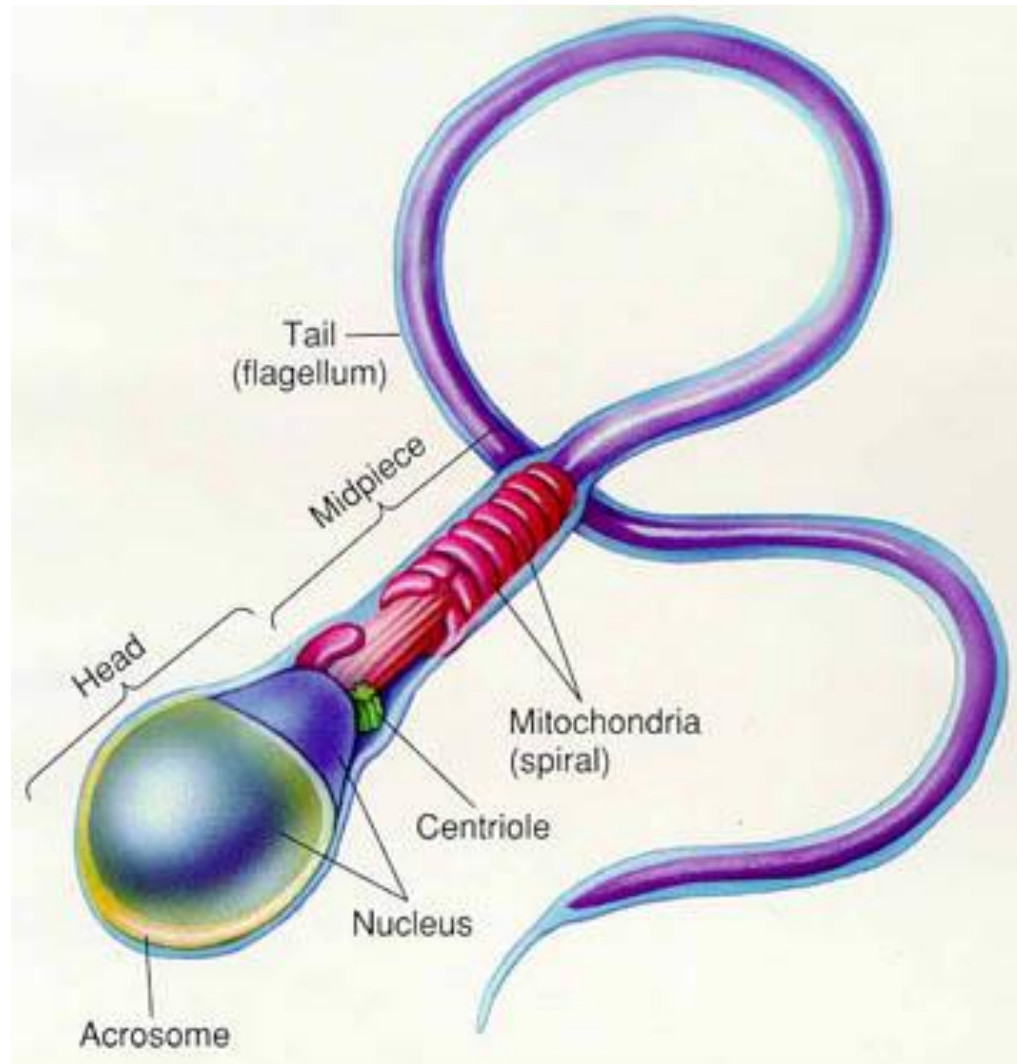


Nutrition of embryo and fetus

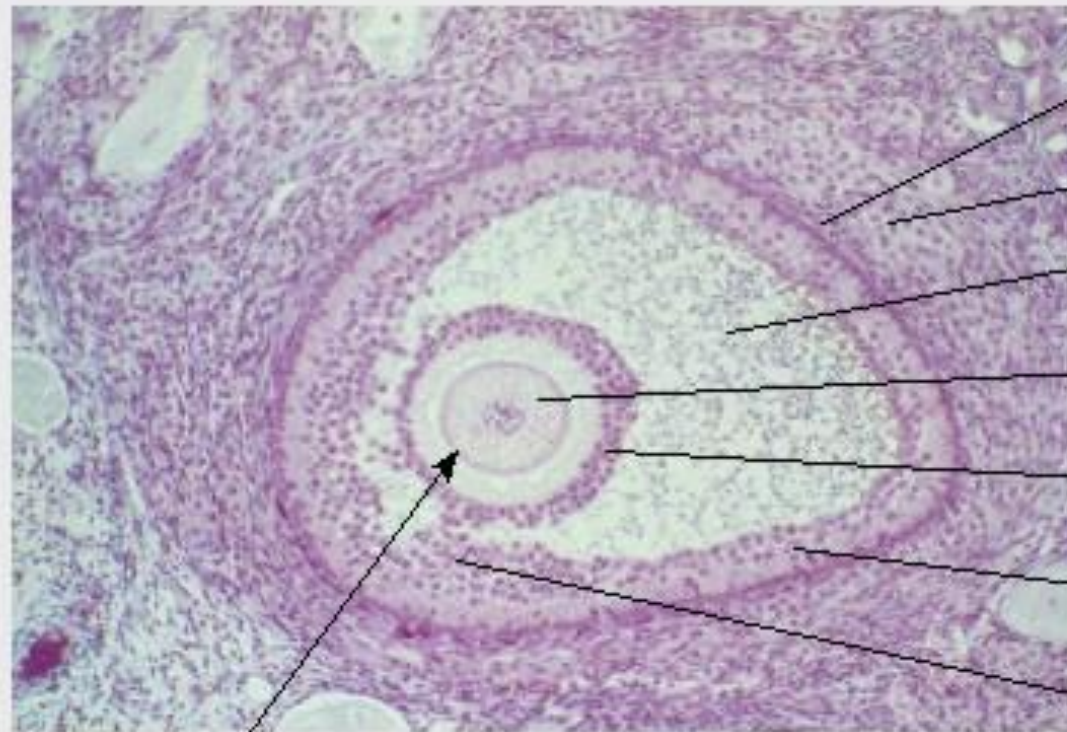


Sperm (*Spermatozoon*)



Ovum (*Ootidium*)

Mature (Vesicular) Follicle



Theca interna

Theca externa

antrum

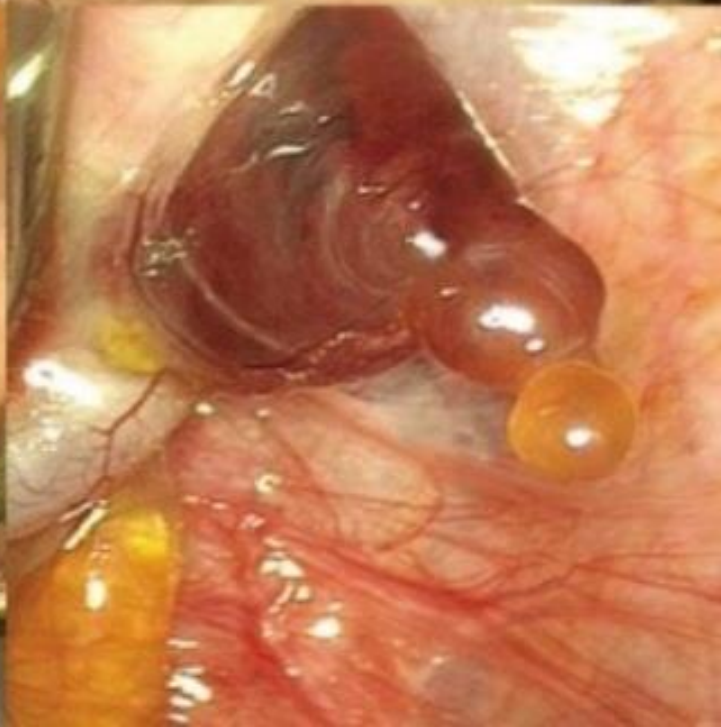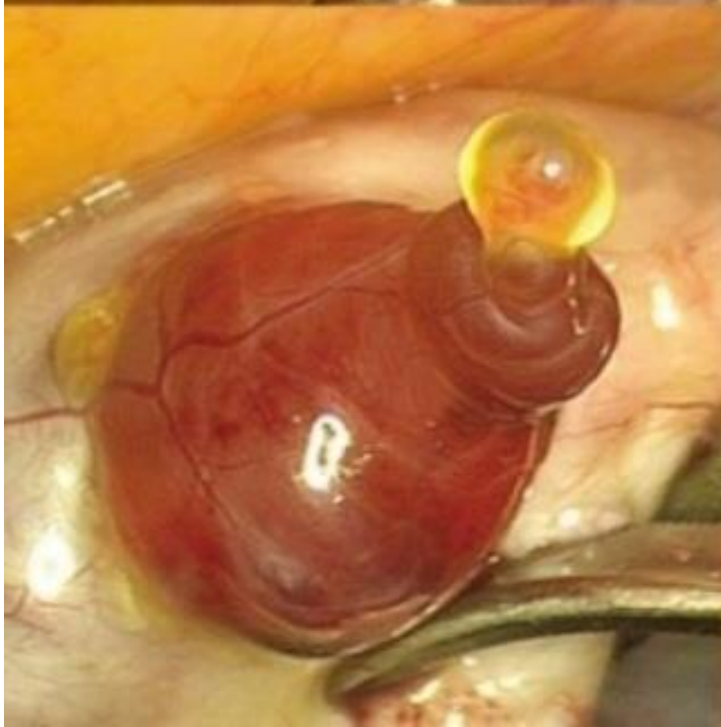
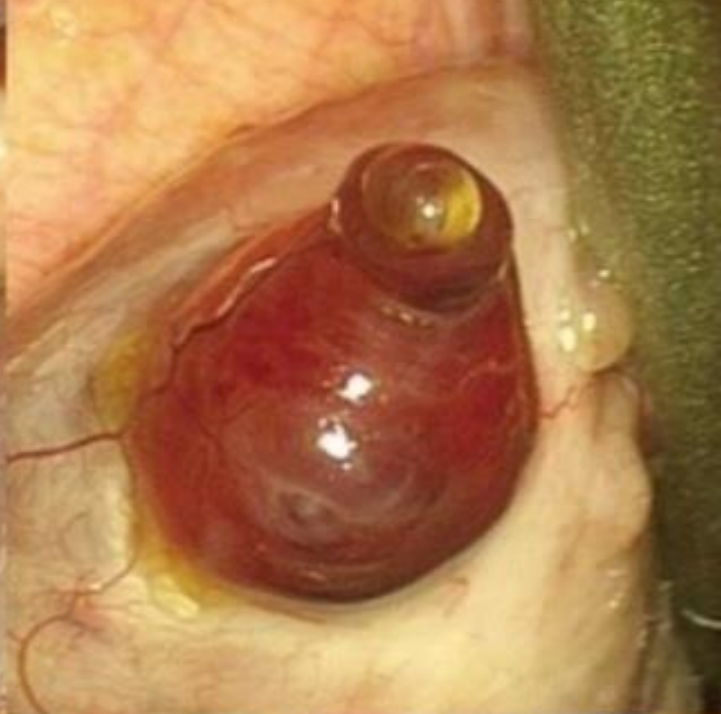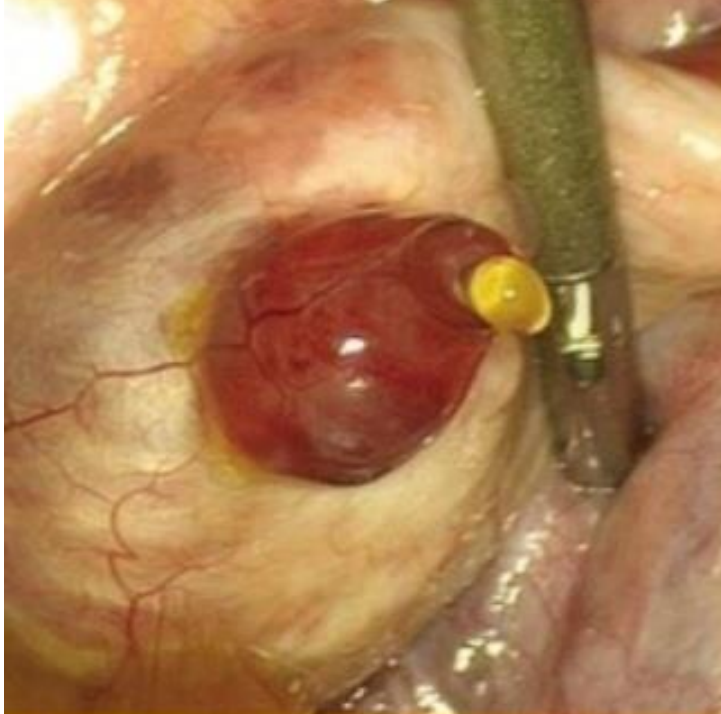
Secondary oocyte

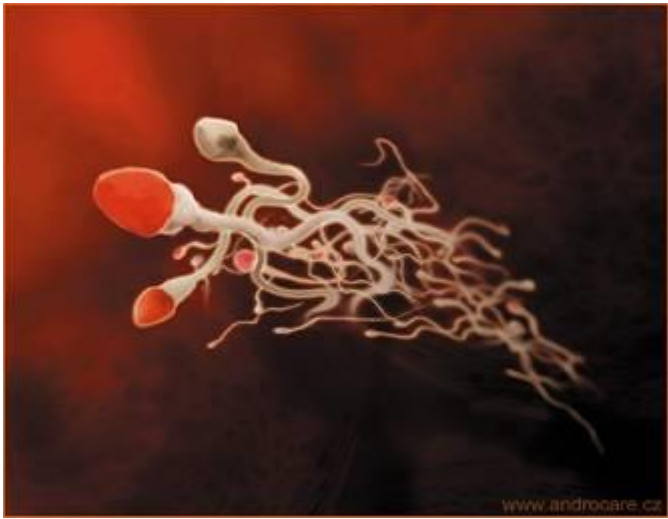Corona radiata

Granulosa cells

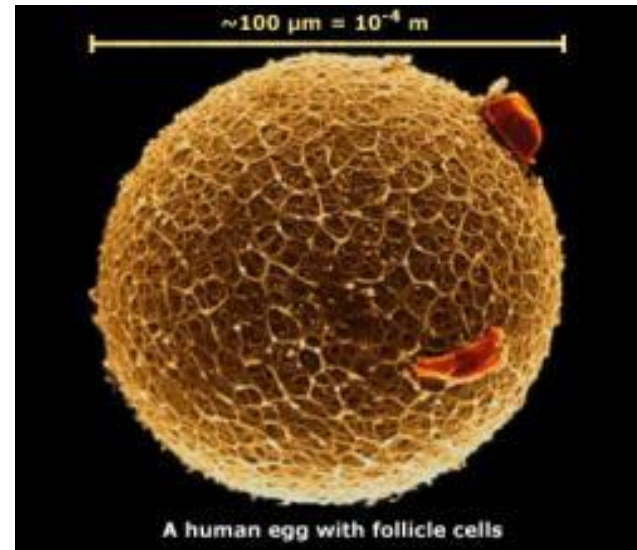Cumulus
oophorus

Zona pellucida





+

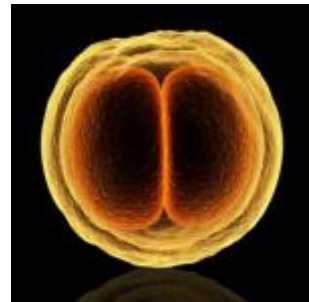

=



Fertilization (*Fertilisatio*)

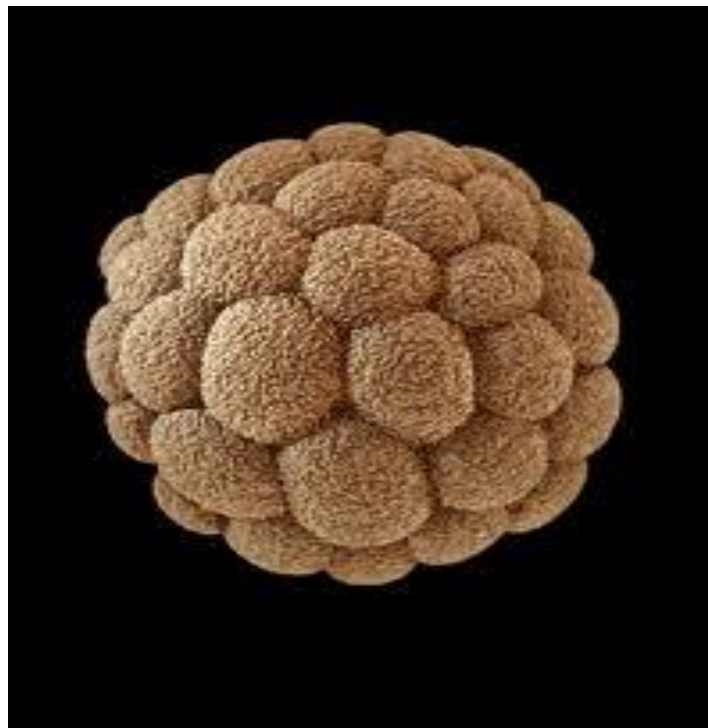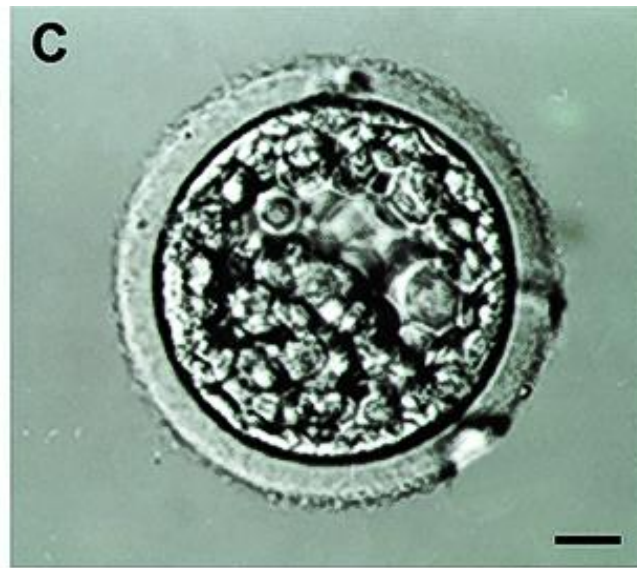
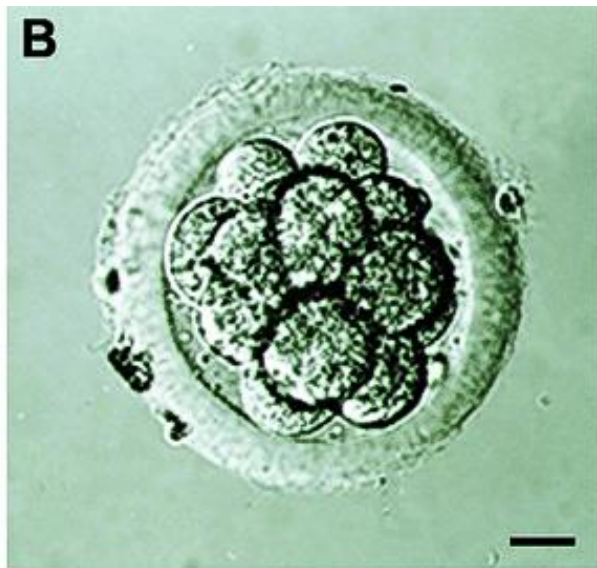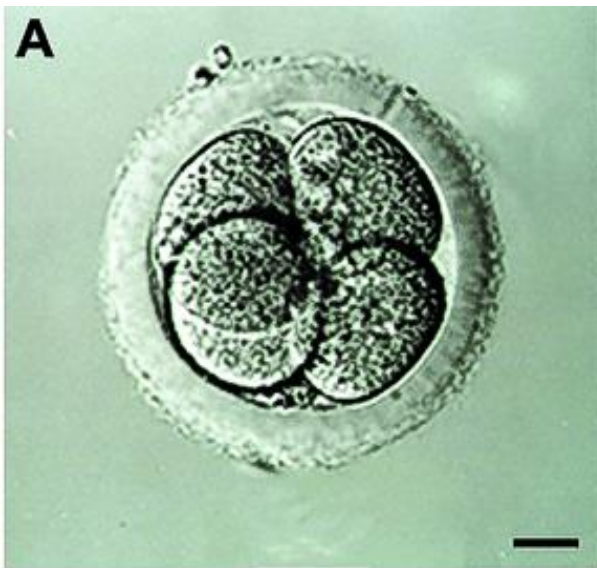
- usually within ampulla tubae uterinae
- sperm passes :
 - corona radiata – hyaluronidase
 - zona pellucida – akrosin, neuraminidase, zonal reaction
- merging of membranes of ovum and sperm (St.1)
- termination of ovum maturation + female pronucleus
- male pronucleus
- membranes of pronuclei disappear → **zygota**
(zygotum)
 - (zygon = yoke)
 - St. 2



Cleavage of zygote

- 30 hodin after fertilization: zygote undergoes repetitively rapid mitotic divisions („cleavage“)
→ **blastomeres** (equipotential cells)
 - (blastos = germ)
- thanks to **zona pellucida** blastomeres get smaller after each division
- close contact between blastomeres enables **compactization** (primitive intercellular interactions)
- 12-15 blastomeres = **morula**
 - (mulberry)

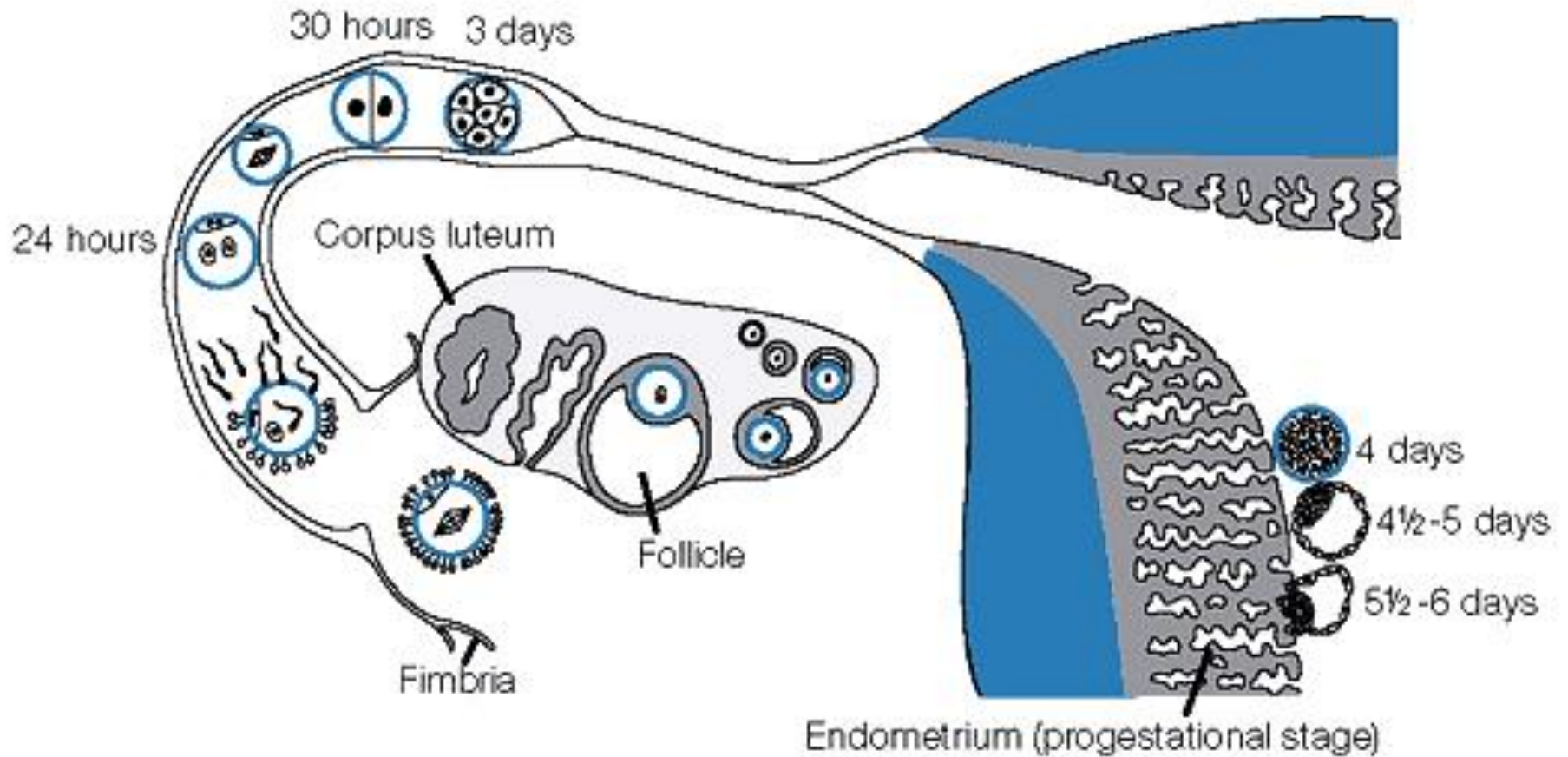




Blastocyst (St.3-5)

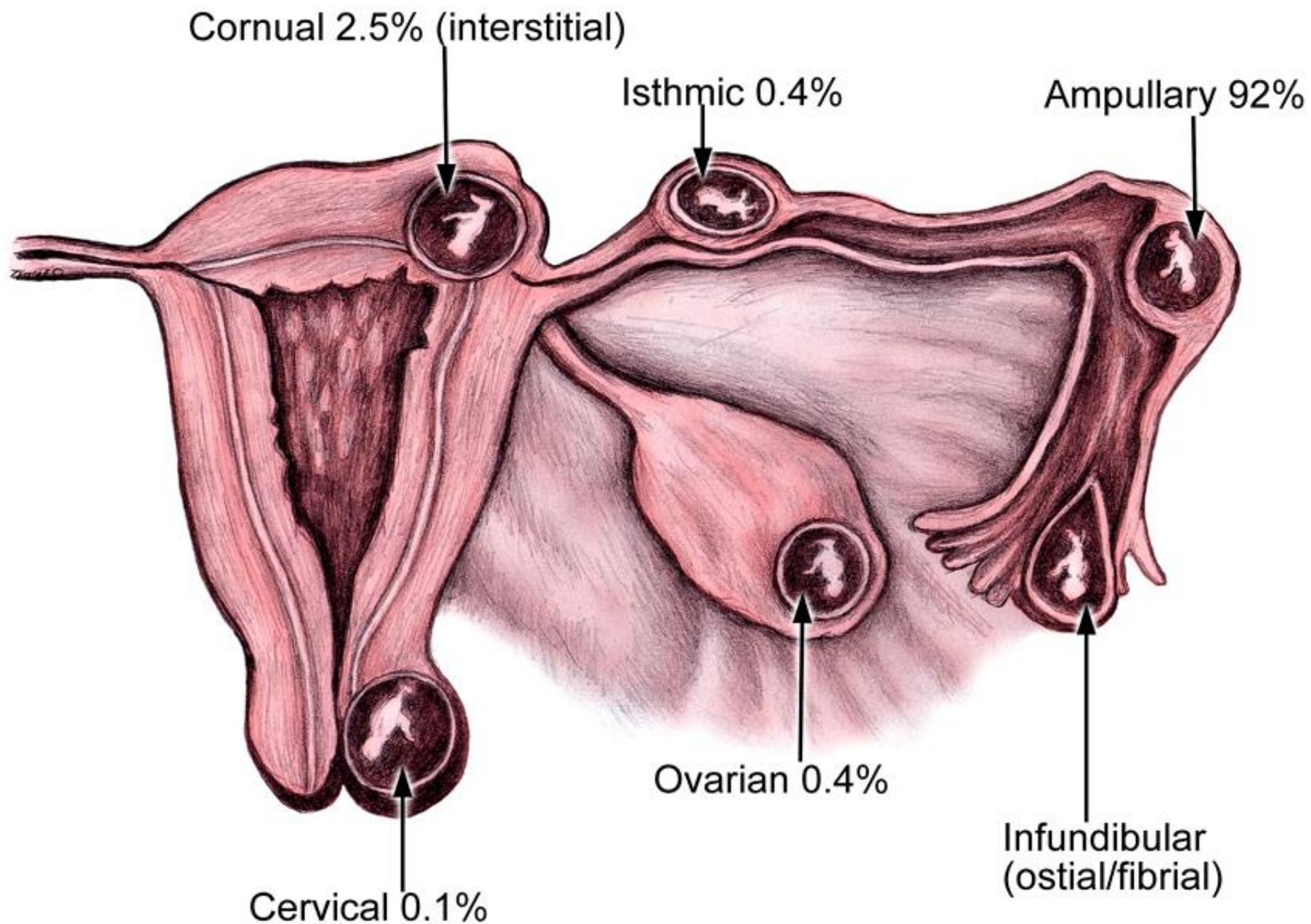
- 4D after fertilization: morula enters uterine cavity
- formation of small cavities filled with fluid → merge into **blastocystic cavity** = *cavitas blastocystica* (blastocoel)
 - blastocysta libera (St. 3)
 - blastocysta adherens (St. 4)
 - blastocysta implantata (St. 5)
- 6D: blastomeres divide into 2 parts:
 - **trophoblast (outer cell mass)** – base for **embryonal part of placenta**
 - **embryoblast (inner cell mass)** – base for **proper embryo**
- whole structure is called ***blastocysta (unilaminaris)***

Blastocyst formation (Blastulation)



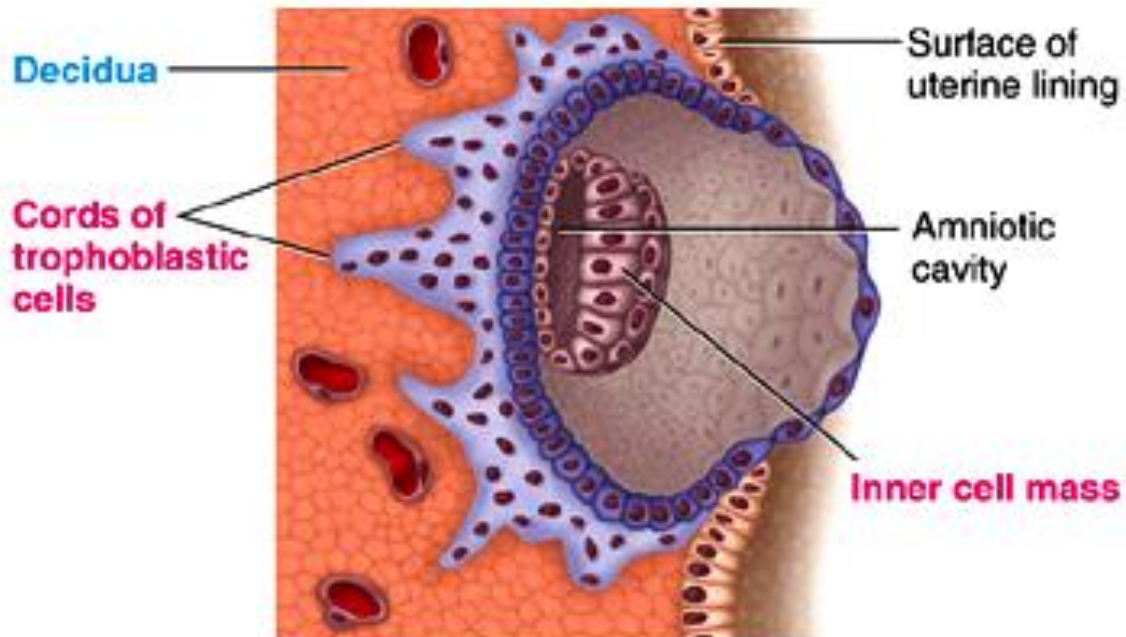
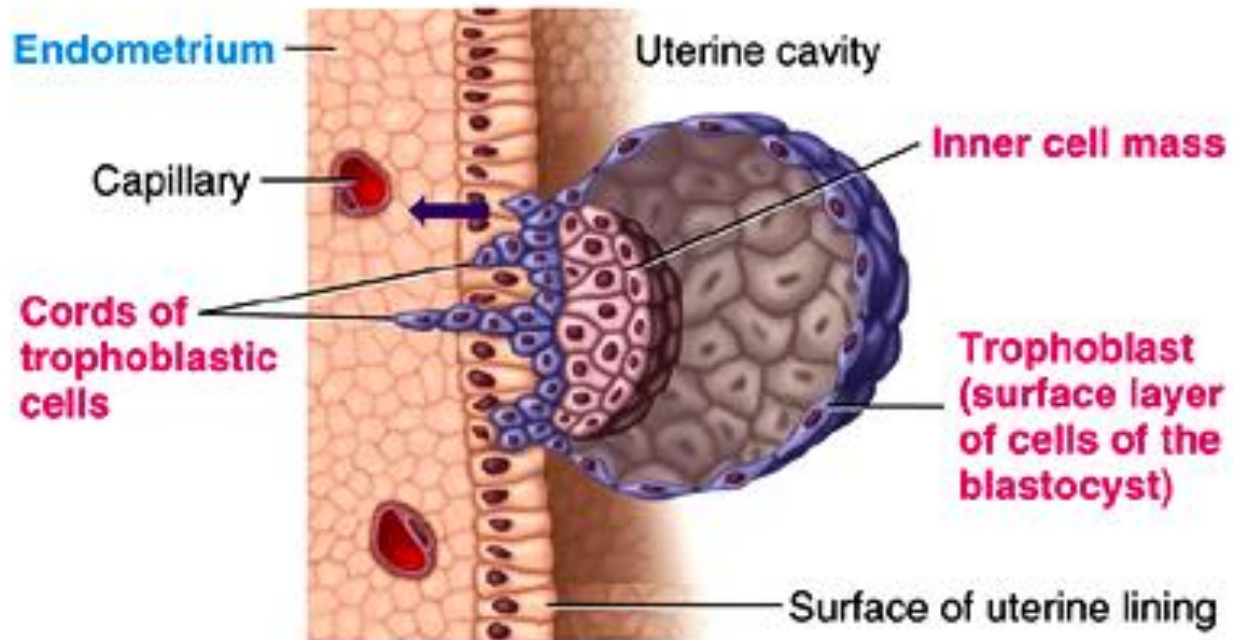
Implantation (*Implantatio*) = Nidation

- 4-6D: degeneration of zona pellucida – blastocyst continues to grow
- **6D:** blastocyst adheres with its embryonic disc to endometrium = **implantation (*implantatio*; nidation)**
 - (nidus = nest)
 - usually in the **dorsocranial part of uterus**
- **extrauterine gravidity (*graviditas extrauterina*)**
 - implantation within tuba uterina or cavitas peritonealis
 - further growth endangers life of the mother – e.g. bleeding after rupture of tuba uterina



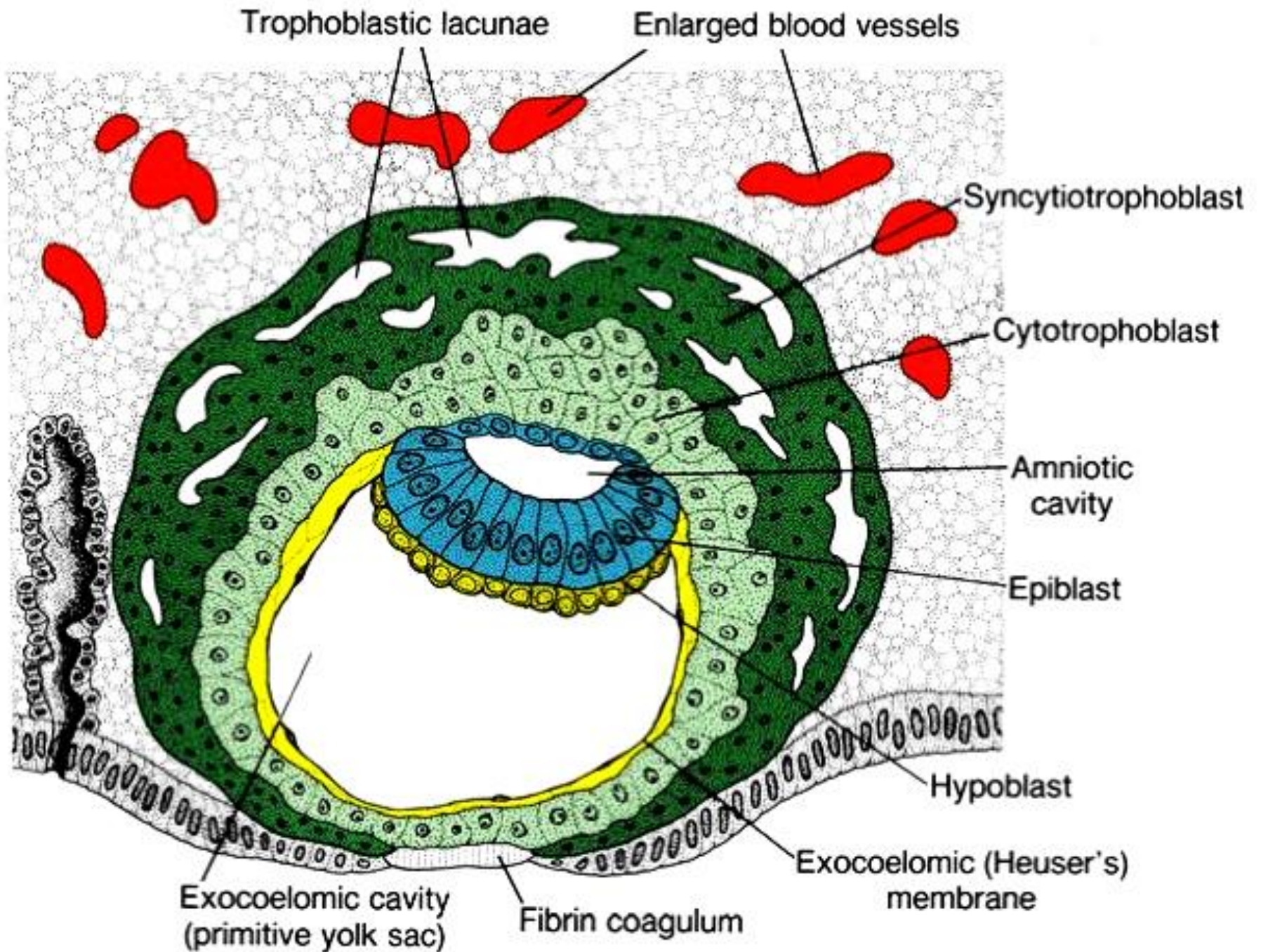
Implantation (*Implantatio*) = Nidation

- conceptus villosus (St. 6)
- **embryo** (St. 7-23)
- trophoblast divides into 2 layers:
 - **cytotrophoblast** – internal layer with well distinguishable cells
 - **syncytiotrophoblast** – external layer consists of many fused cells originating from cytotrophoblast
 - produce enzymes, which penetrate and resorb endometrium
 - embryo submerges deeper and gets nutrition from disintegrated tissue
- **7D**: embryoblast produces a layer of cells called **hypoblast** → **blastocysta (bilaminaris)**



Blastocysta bilaminaris

- **8D**: division of embryoblast into 2 unlayered plates (= **bilaminar blastoderm**)
- **EPIBLAST** – high cells on cytotrophoblastic side of embryonal disc
- **HYPOBLAST** – low cells on blastocystic side of embryonal disc
- oval shape
- at the same time a cavity appears between cells of epiblast = **amniotic cavity (*cavitas amniotica*)**
- some cells of epiblast → **amnioblasts** → surround amniotic cavity



Yolk sac origin

- **9D**: cells of hypoblast separate and line the cavitas blastocystica → extraembryonal endoblast = **exocoelom Heuser's membrane** (Chester H. Heuser – U.S. embryologist 1885-1965)
- → exocoeloma = **primary yolk sac (*vesicula umbilicalis primaria*)**
- cells of yolk sac give rise to loose connective tissue which invades between amnion/yolk sac and cytotrophoblast = **extraembryonal mesoblast (mesoderm)**

Implantation - termination

- **9-10D**: embryo is fully implanted within the endometrium
 - defect of endometrium is covered with fibrin at first
- **12D**: defect recovered with new epithelium (simple columnar epithelium) – *operculum deciduale*
- syncytiotrofoblast grows and erodes capillaries, sometimes causing **mild bleeding into the uterus** = corresponds to menstruation phase and can cause **false estimation of the delivery term**

Human chorionic gonadotropin (hCG)

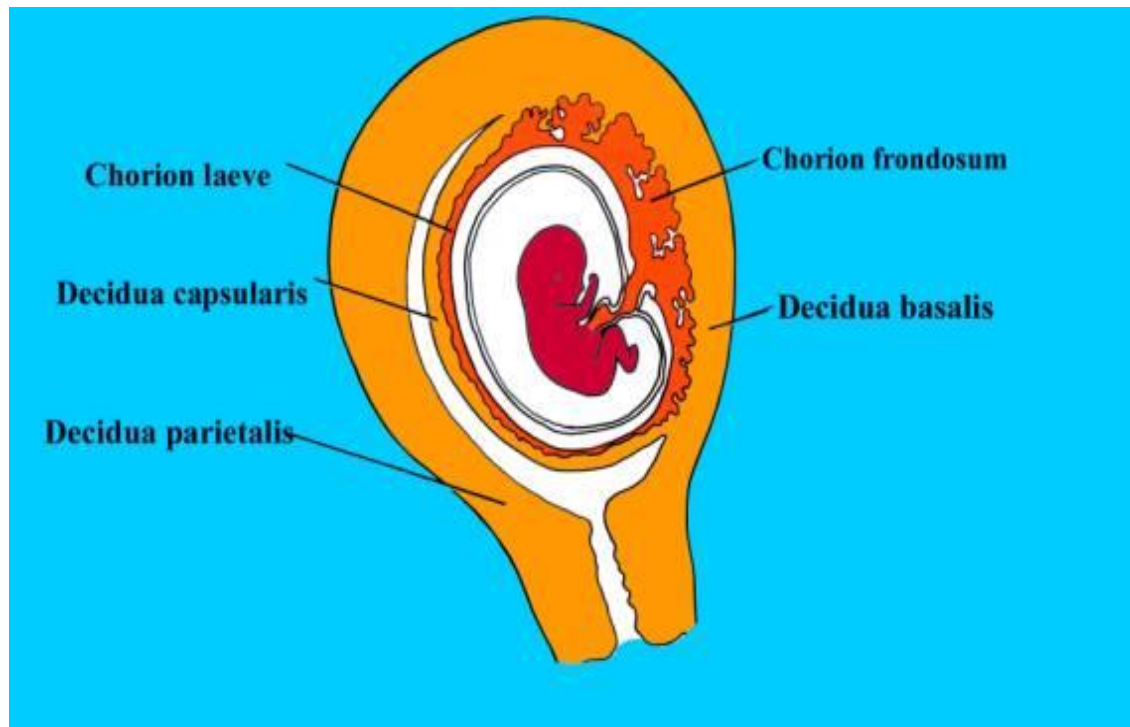
- produced by syncytiotrophoblast just after implantation (8D)
- until 6th month **keeps corpus luteum in function**
- **14D: can be detected in urine**
- pregnancy test – detection of hCG beta subunit
- its synthetic form used in assisted reproduction
- excluding pregnancy – hCG is a marker of trophoblastic tumors

Decidual reaction

- (deciduus = falling off)
- **decidua** – endometrium at the end of secretory phase of menstruation cycle and then during the whole pregnancy
- decidual cells (*cellulae deciduales*)
 - cells of endometrial connective tissue respond to the presence of syncytiotrophoblast with decidual reaction
 - change of the shape (fusiform → polyhedral)
 - accumulation of **lipids** and **glycogen**
 - cells in the immediate vicinity of syncytiotrophoblast are successively absorbed to feed the embryo

Decidua

- **decidua basalis** – in depth of the implantation site, forms maternal part of placenta
- **decidua capsularis** – covers conceptus
- **decidua parietalis** – other free part

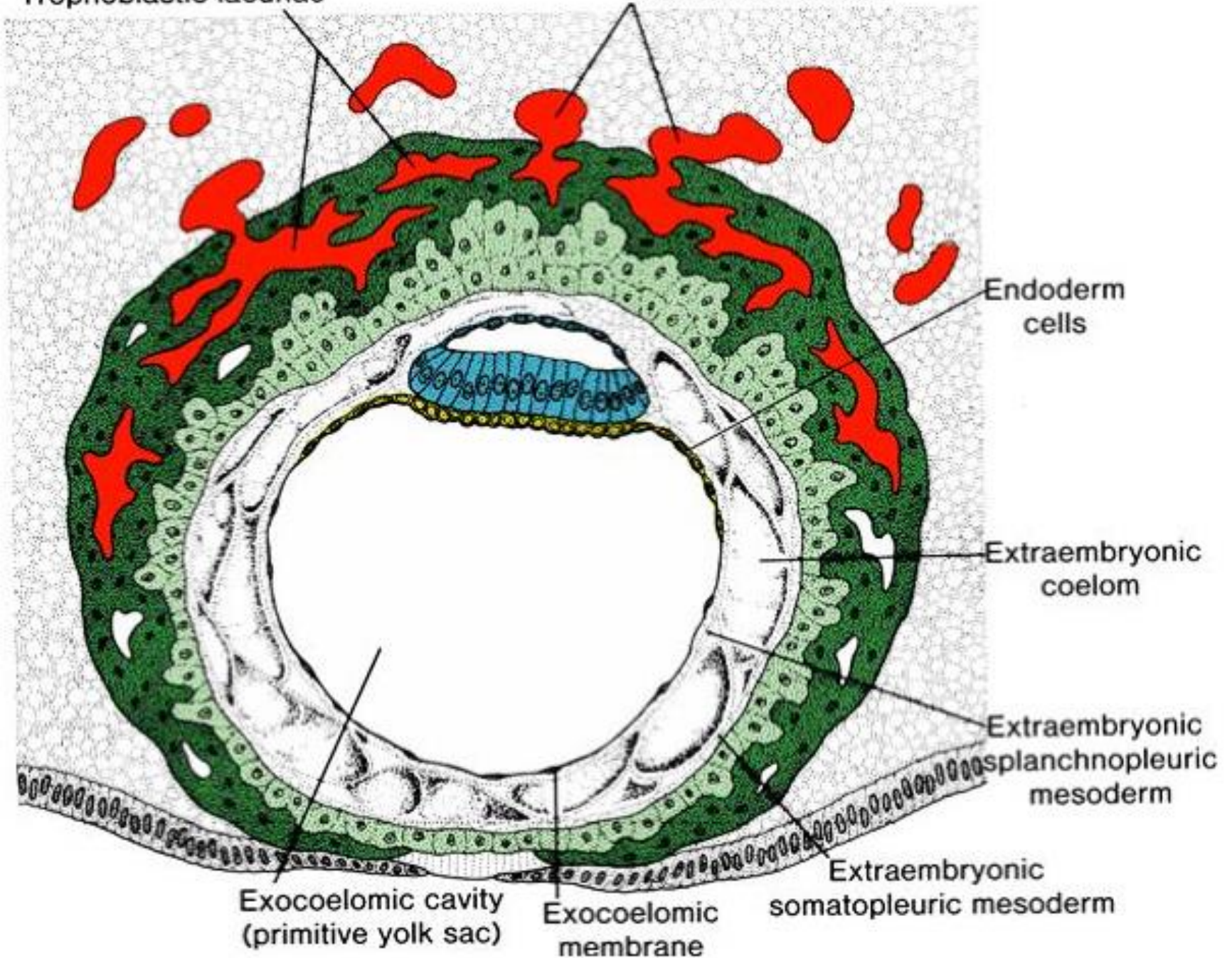


Beginning of uteroplacental circulation

- capillaries of endometrium enlarge and change into **sinusoids**
- sinusoids are eroded with progressive syncytiotrophoblast
- **9D**: blood flows into trophoblastic **lacunae**
- blood is conducted via **aa. spirales** into lacunae
- brought nutrients are accessible for conceptus, metabolic waste can be flown away
- lacunae fuse into **lacunar networks** and serve as a base for future intervillous spaces of placenta

Trophoblastic lacunae

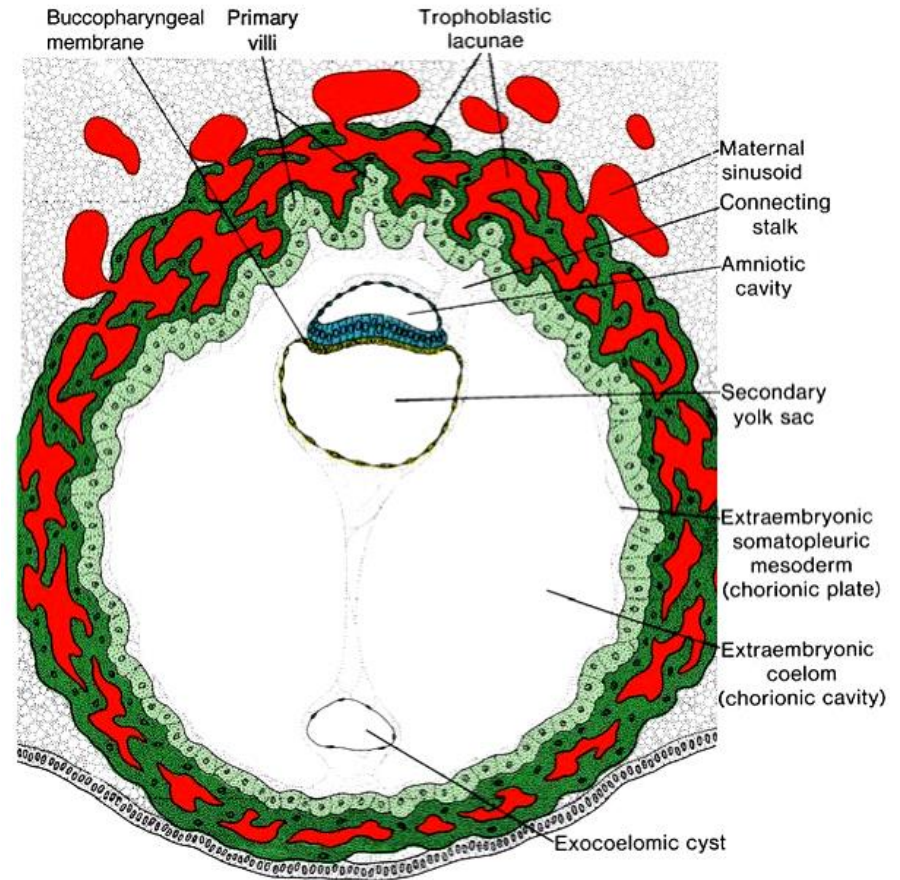
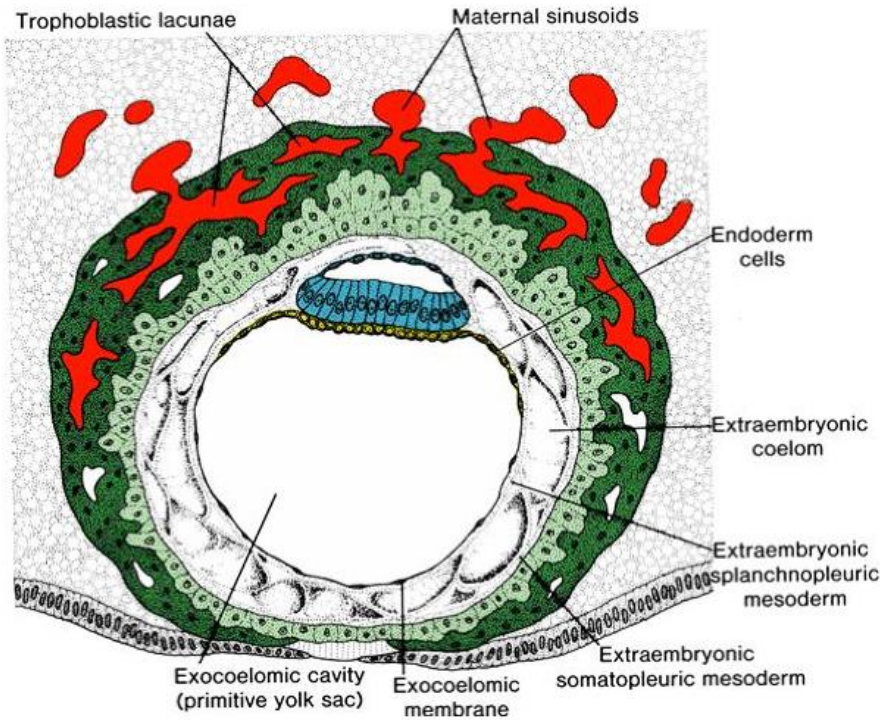
Maternal sinusoids



Chorionic cavity (Extraembryonal coelom)

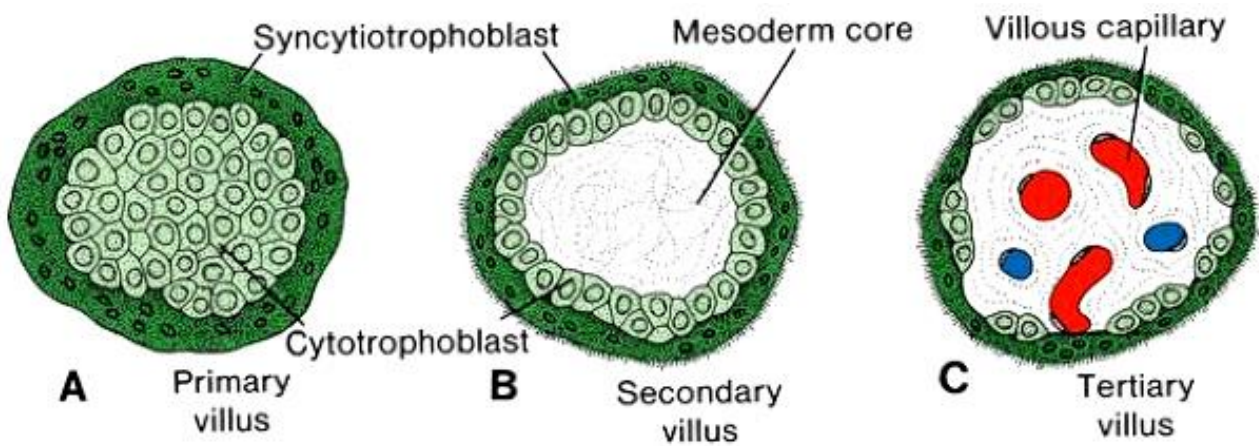
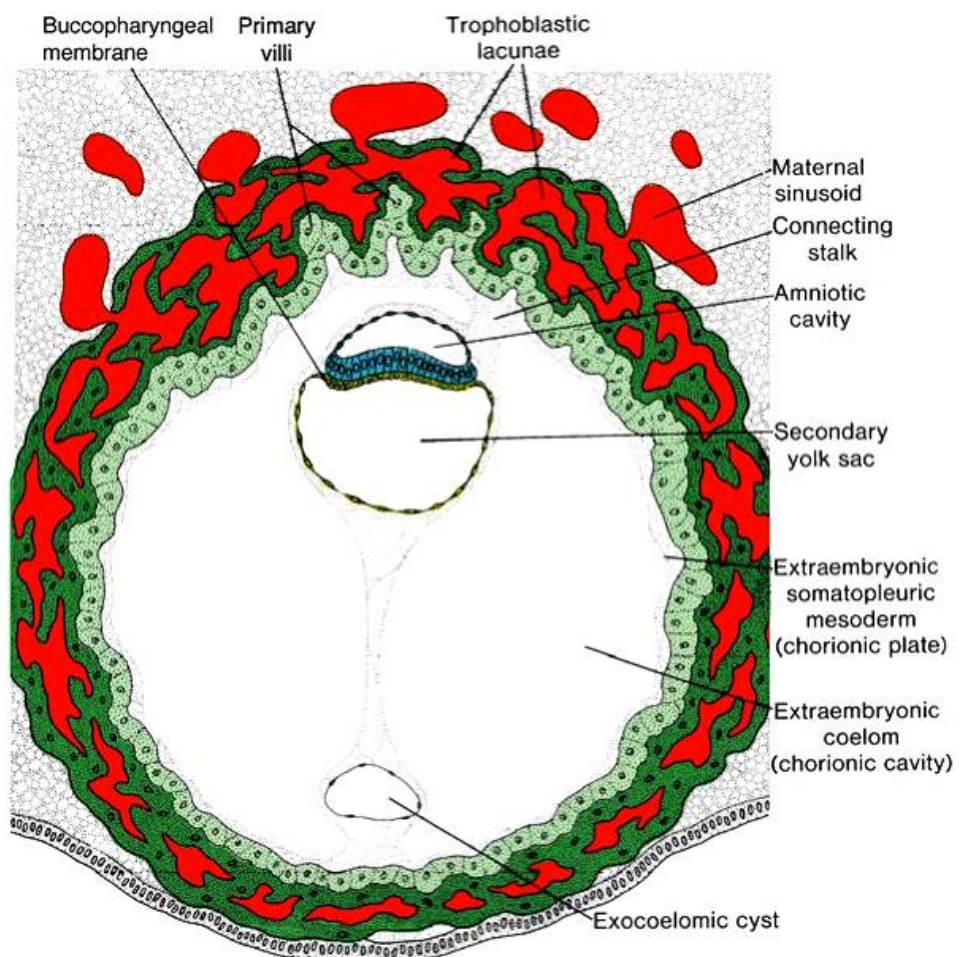
- cavities arise inside extraembryonal mesoblast (mesoderm) → successively fuse → **chorionic cavity (extraembryonal coelom; *cavitas chorionica*)**
- in small area around amniotic cavity: no fusion → **connecting stalk (*pedunculus connectans*)**
 - embryo „hangs“ on it inside chorionic cavity
- part of primary yolk sac is separated by growing chorionic cavity and fuse with its wall
- the remaining part is smaller and called **secondary yolk sac (*vesicula umbilicalis secindaria*)**

Chorionic cavity (Extraembryonic coelom)



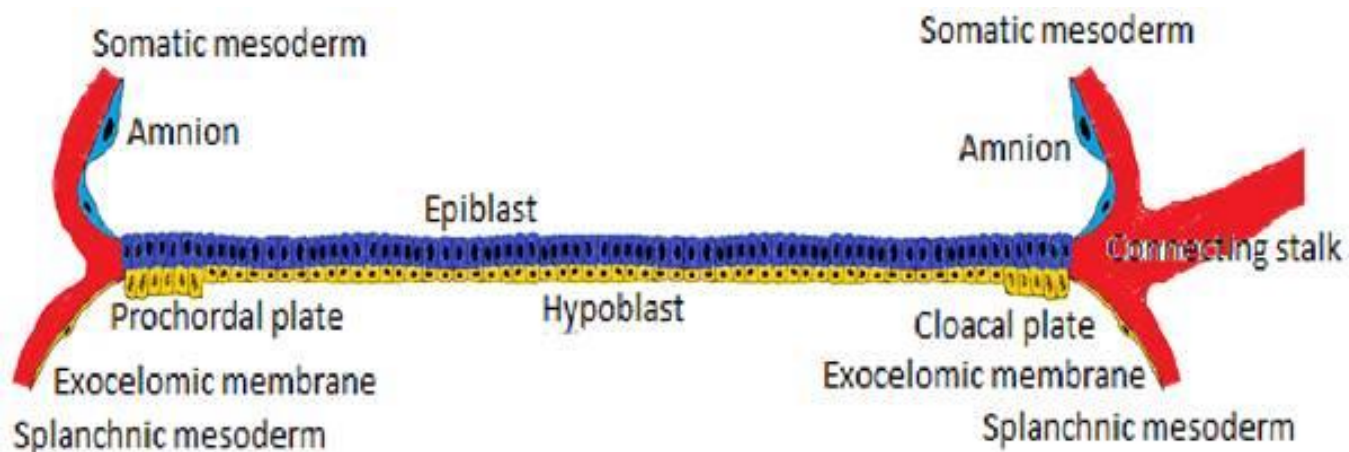
Chorionic sac (*Saccus chorionicus*)

- extraembryonal mesoblast (mesoderm) does not disappear →
 - **extraembryonal somatic mesoderm**
 - on internal surface of chorionic cavity and external surface of amniotic cavity
 - **extraembryonal splanchnic mesoderm**
 - on external surface of secondary yolk sac
- **13-14D:** induced by extraembryonal somatic mesoderm – growth of **primary chorionic villi**
 - by means of proliferation of cytotrophoblast cells into syncytiotrophoblast
- **chorionic sac (*saccus chorionicus*)** is lined:
 - internally with extraembryonal somatic mesoderm
 - externally with trophoblast



Prechordal plate (*Lamina prechordalis*)

- in cranial part of embryo: transformation of smaller population of cells of **hypoblast**
→ columnar cells → **prechordal plate** → formation of bases of **head part of embryo**



Fetal membranes

Membranae fetales (Adnexa fetalia)

Chorion

Amnion

Allantois

Vesicula
umbilicalis



Protection

Nutrition

Respiration

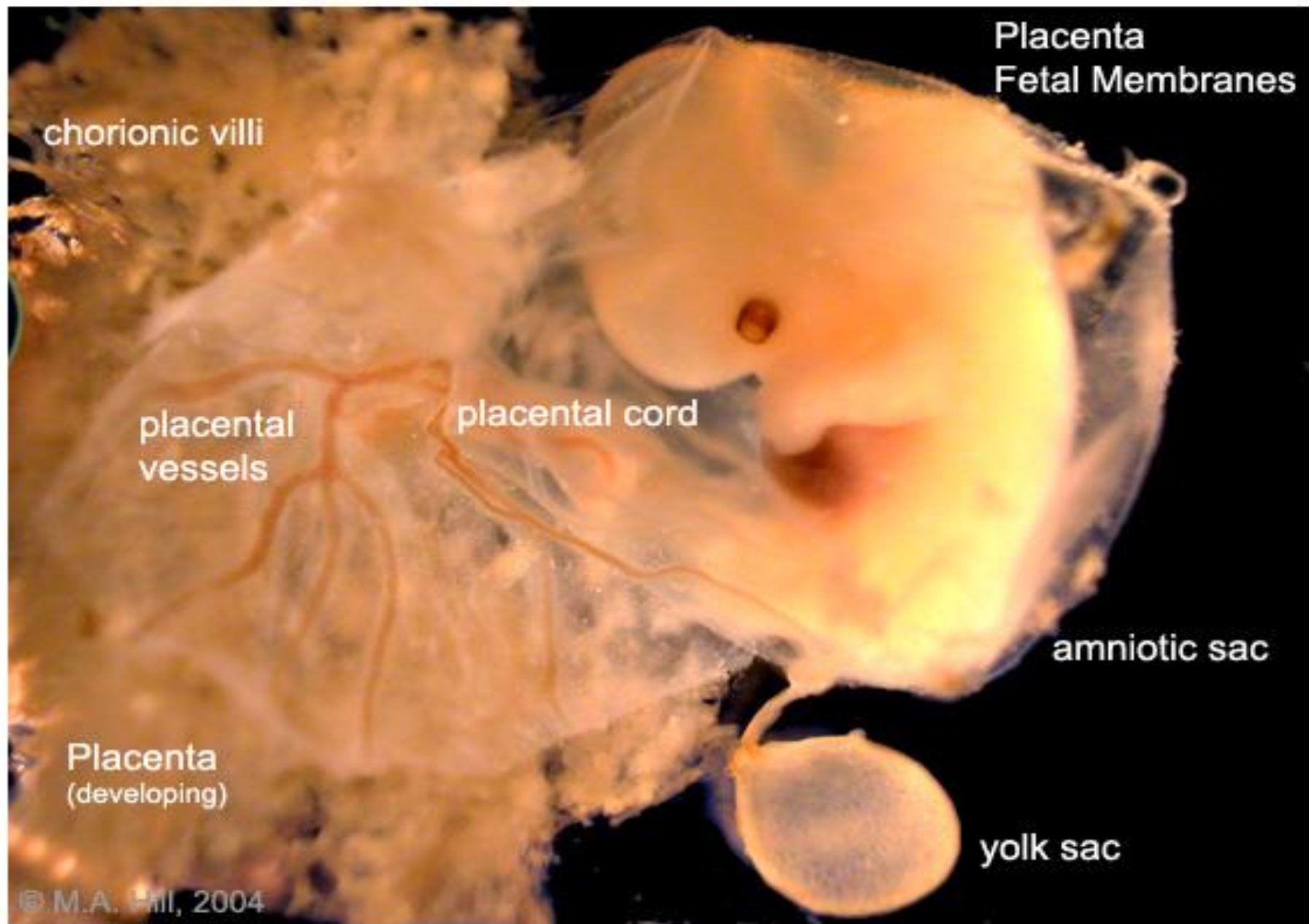
Excretion

Hormones

Fetal membranes

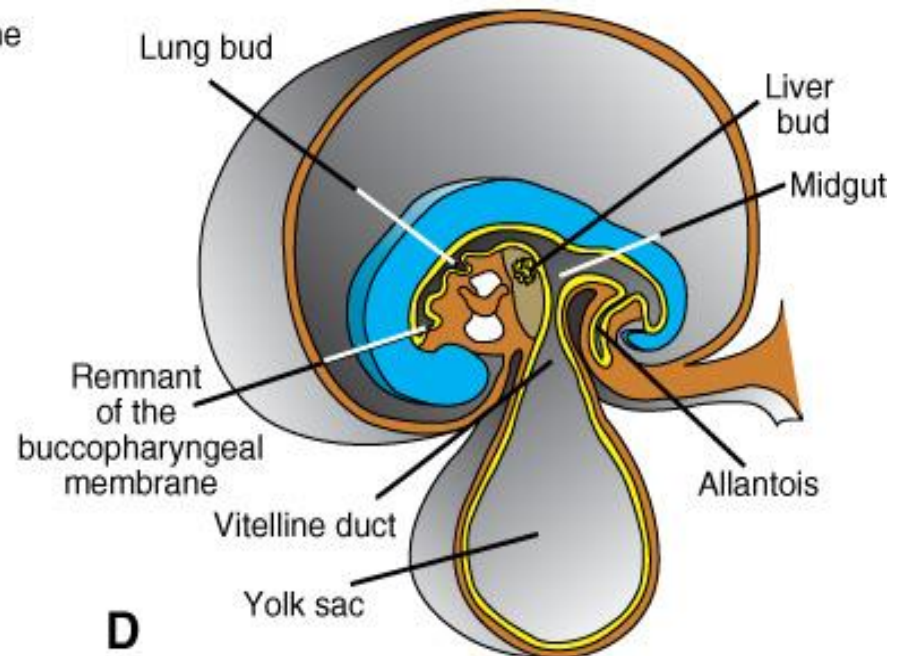
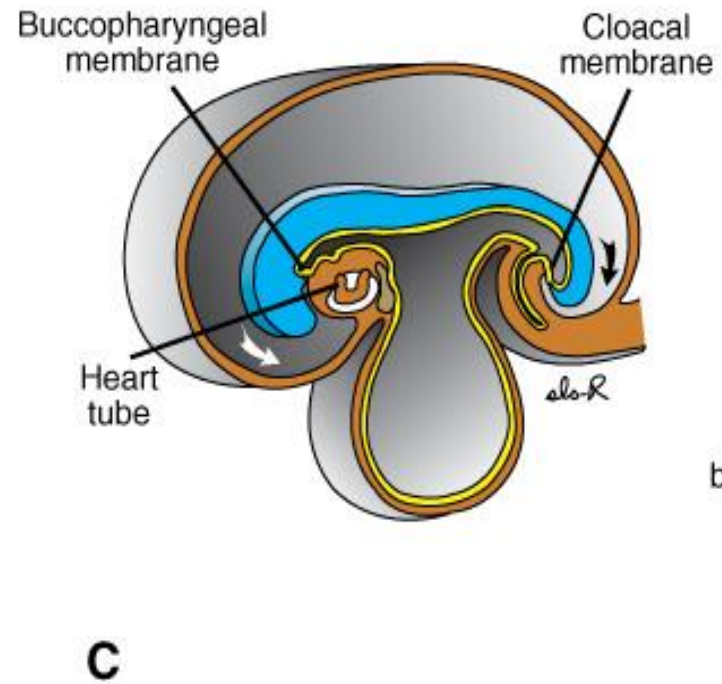
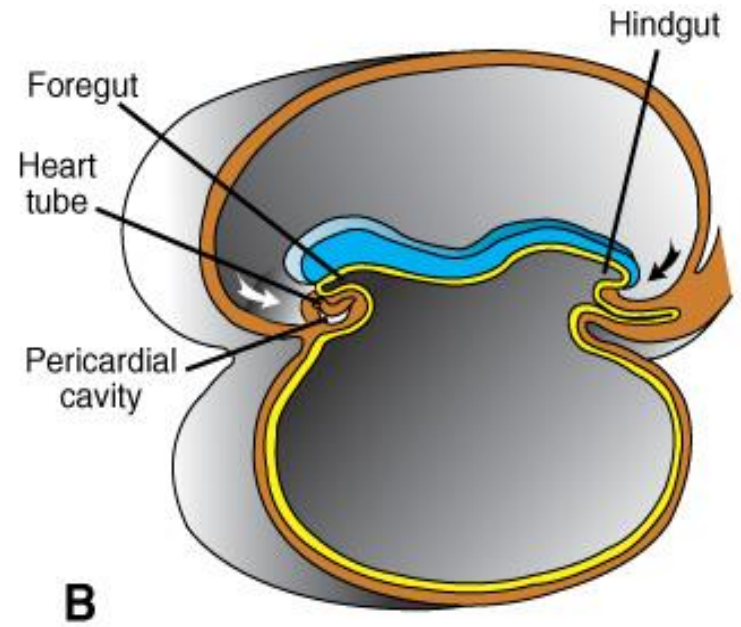
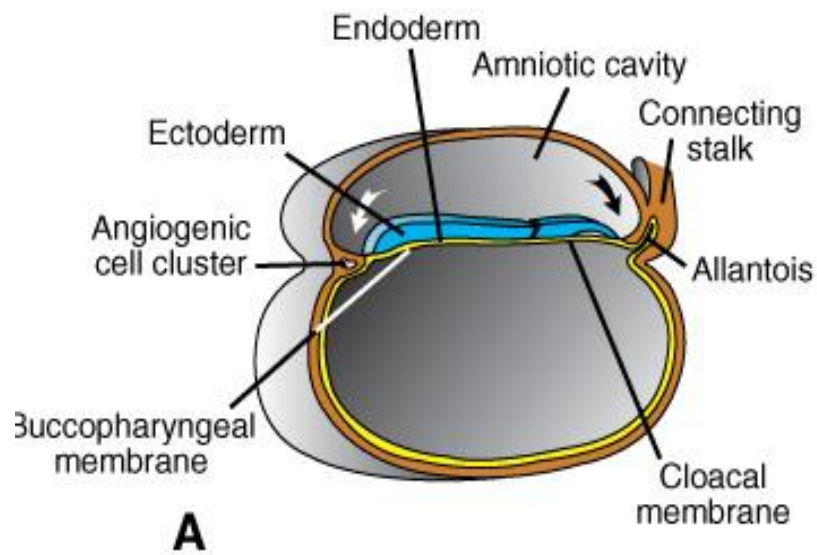
(Membranae fetales)

- appear during **2nd week** from zygote
- are not part of embryo
- do not contribute to embryo formation!
 - exception: parts of yolk sac and allantois
- in early phase of pregnancy: quicker growth than that of embryo



Allantois (idis, f.)

- (allas = sausage)
- *gemma alloenterica* – common base of primitive gut and allantois
- pouch of caudal part of yolk sac wall (*pedunculus allantoicus*)
- growth into the connecting stalk
- *canalisatio*
 - pars proximalis → murus ventralis mesenteri
 - pars distalis → diverticulum allantoicum
- later its opening moves to cloaca
- fades out



Allantois

- **3-5T: hematopoiesis**
 - vasa allantoica → **vasa umbilicalia**
 - to feed the conceptus from placenta
- intraembryonal part → urachus + pars vesicalis sinus urogenitalis → **part of vesica urinaria**
- **urachus** → ligamentum umbilicale medianum (= chorda urachi) after birth

Amnion (i, n.)

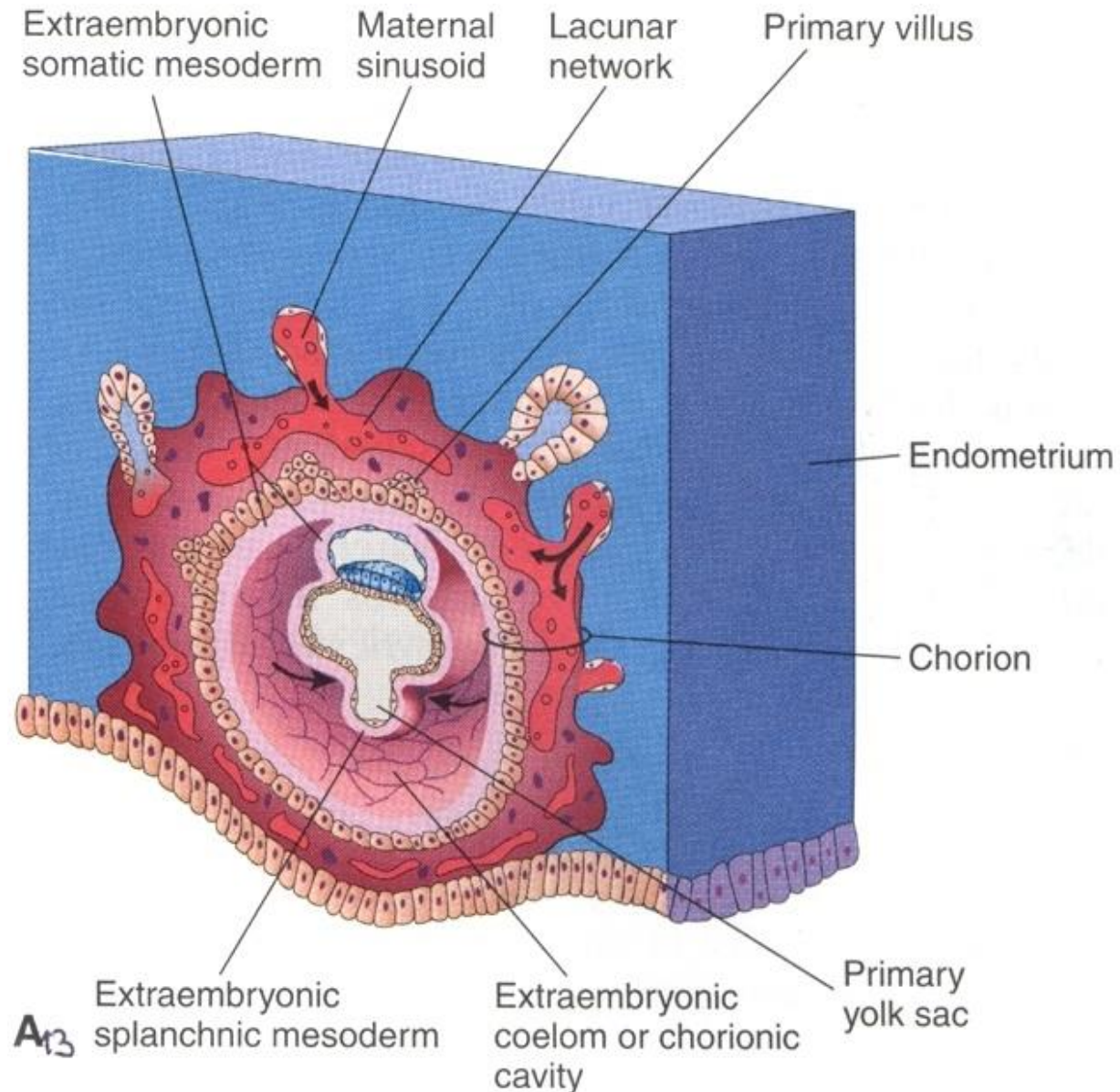
- (amnos = lamb in Greek; agnus in Latin)
- membranous sac encompassing and protecting the conceptus
- **8D**: cavities appear within the epiblast of blastocystis bilaminaris
- narrow slit between embryoblast a trophoblast
- amniotic cavity (*cavitas amniotica*)
- amniotic fluid (*liquor amnioticus*)
- amnioblasts – simple cubic epithelium
- extraembryonal ectoderm
 - mesenchyma amnioticum
 - mesothelium amnioticum

Amnion

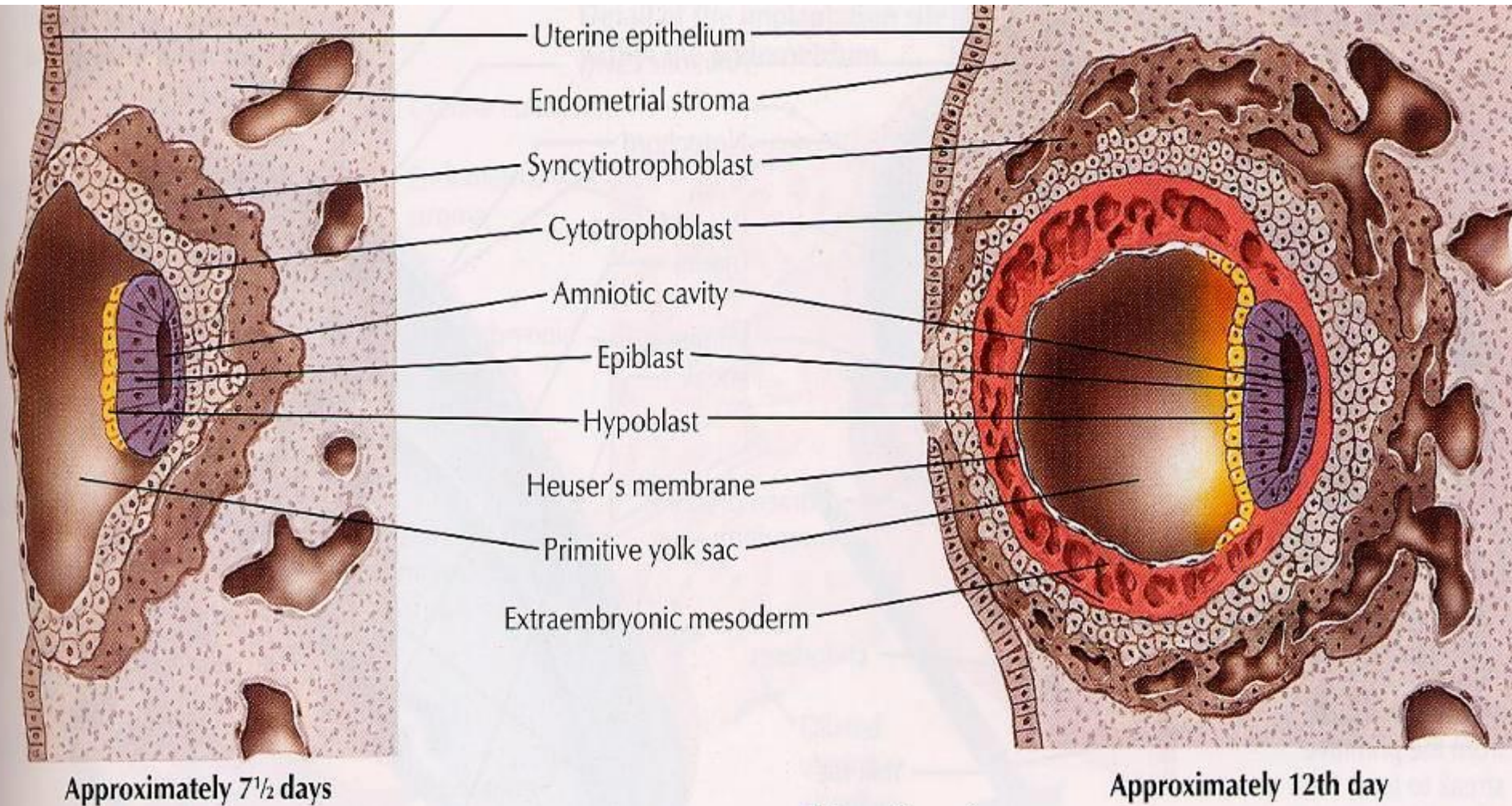
- wall of amniotic cavity
 - floor = epiblast
 - inner walls = simple cuboidal epithelium (amnioblasts)
 - outer walls = extraembryonal somatic mesoderm (= extraembryonal somatopleura)
- from 4W: enlarging with the growth of embryo
- connection with embryo - amnioblasts covering umbilical cord

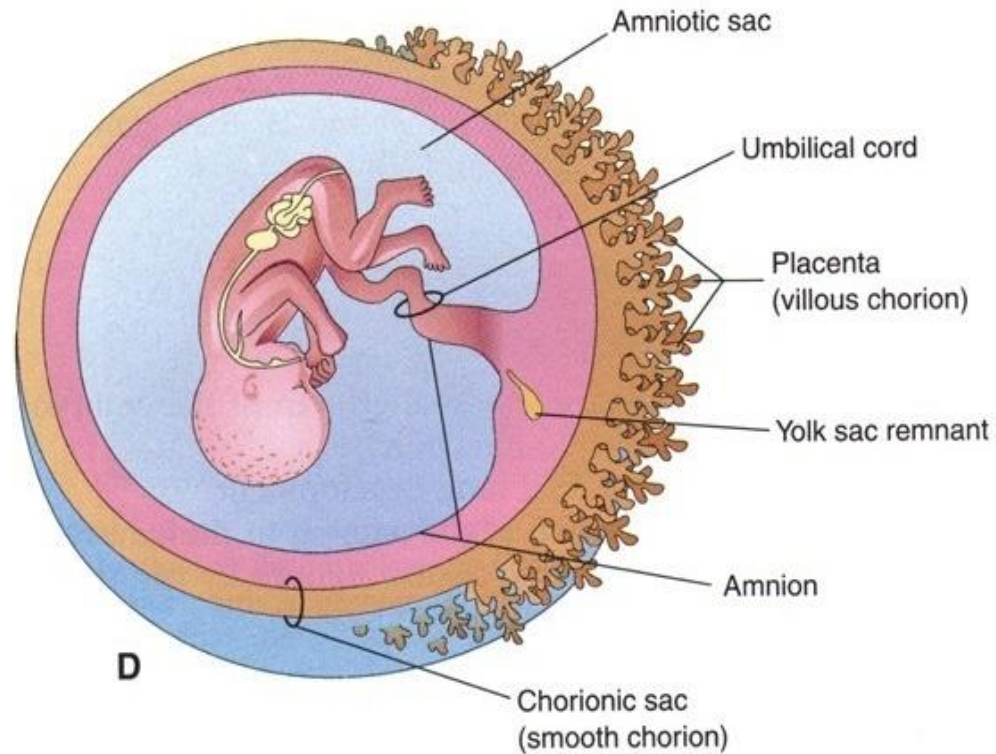
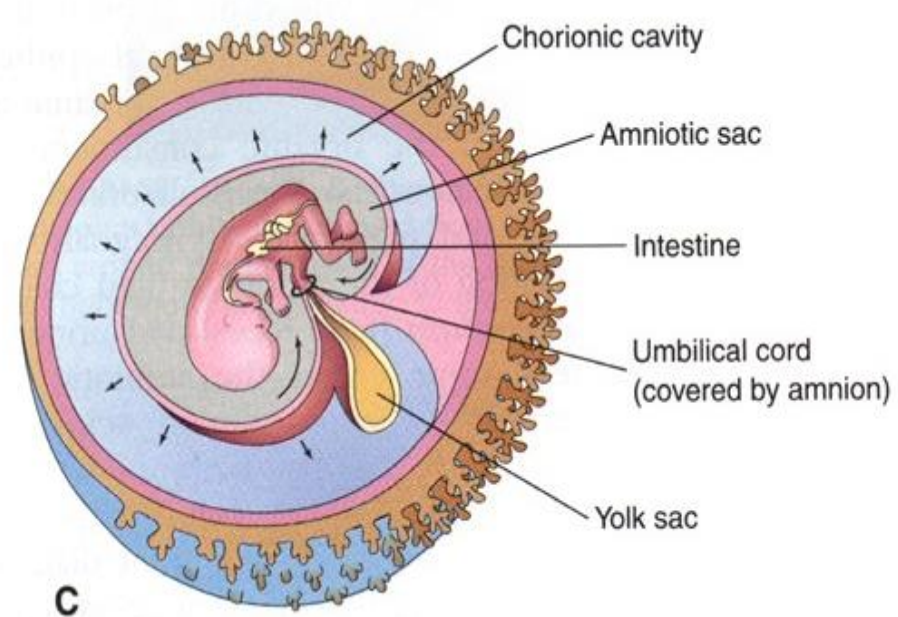
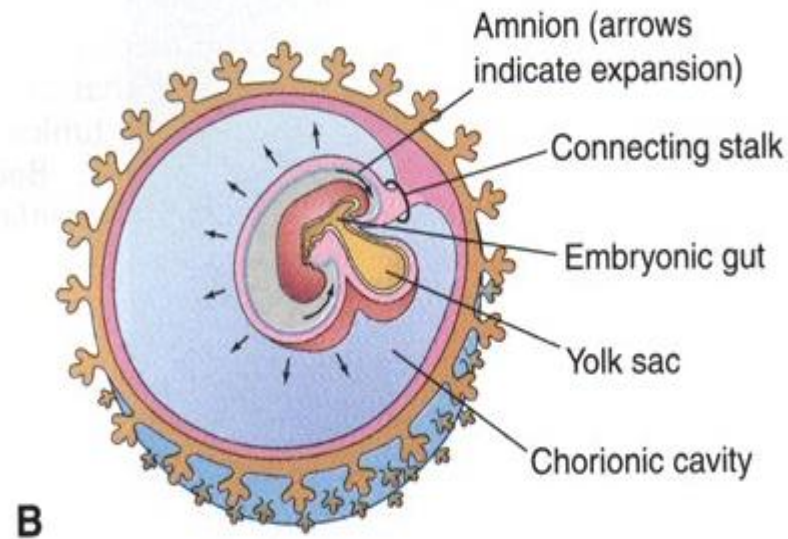
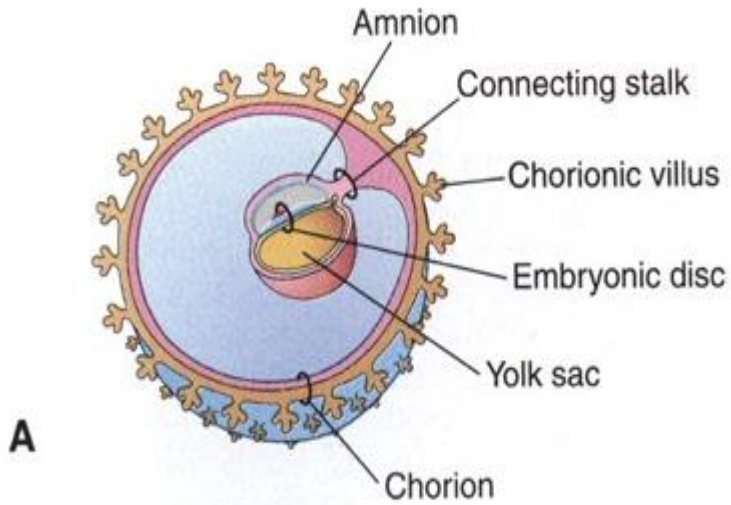
Amnion

- cavity in embryoblast
- fluid
- enlarges and compresses chorionic sac
- encompasses and covers umbilical cord



Amnion





Amniotic fluid (*Liquor amnioticus*)

content of amniotic cavity

- at first produced by amnioblasts
- then mainly by diffusion through *amniochorion* from *decidua parietalis*
- finally by diffusion from maternal blood (from *spatia intervillosa placentae*)
- flows into fetal respiratory and digestive tract

circulation inside the fetus:

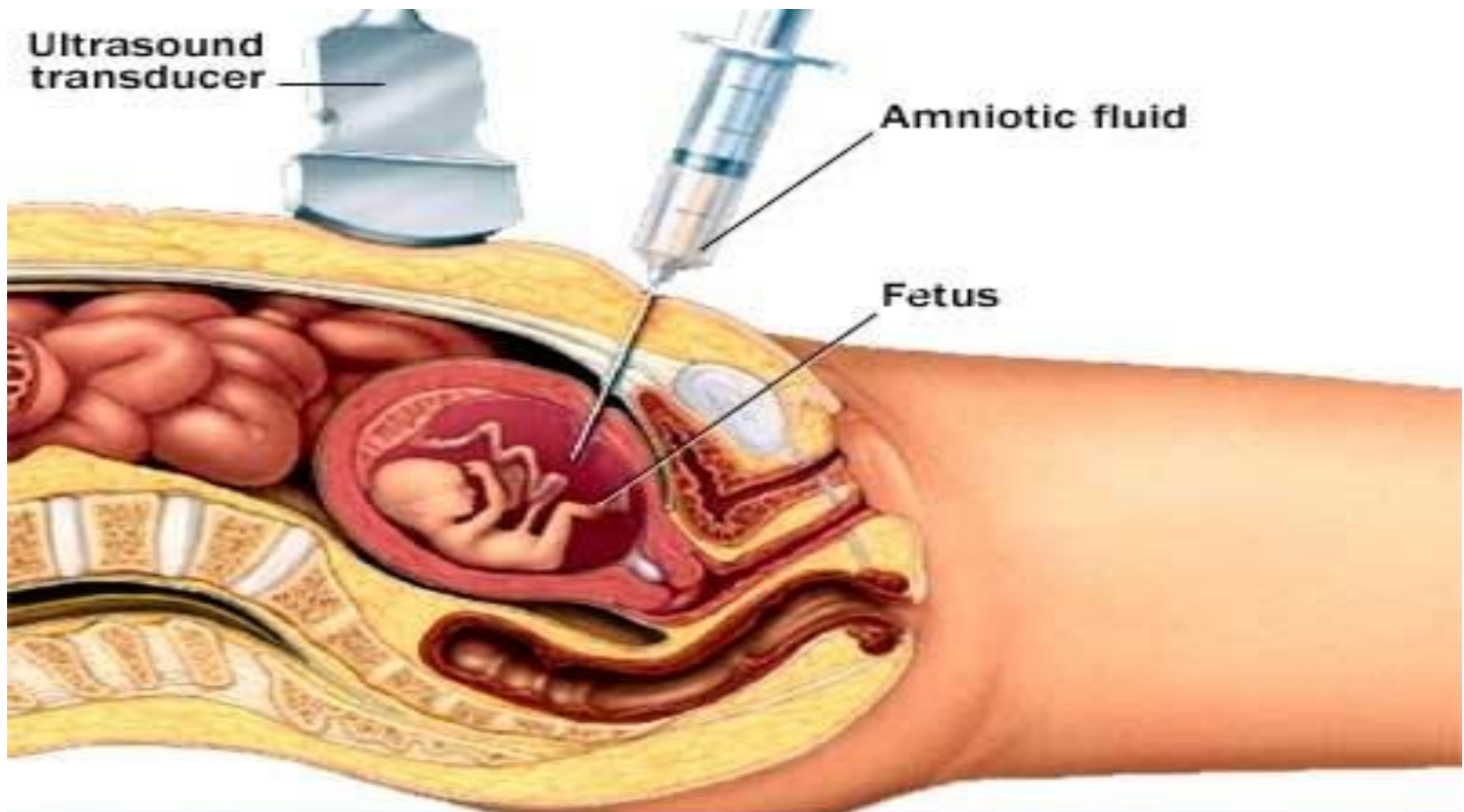
- **from 11W:** excretion of urine
- swallowing (at the end of 3rd trimester – 400 ml per day)
- composition: 99% water

Function of amniotic fluid

- symmetrical growth of conceptus
- barrier against infection
- development of lungs
- mechanical protection („pillow“)
- termoregulation
- enables movements of conceptus
- *amniocentesis*

Amniocentesis

- Week 16-20
- Risk of spontaneous abortion $< 0,5\%$



Amniocentesis

- sex of conceptus
- chromosomal abberation
 - trisomia 21 = Down, trisomia 13,18
- fetal cells
 - DNA diagnostic of other hereditary diseases
- high level of AFP = alfa-fetoprotein
 - heavy defects of neural tube
- low level of AFP
 - hereditary disorders
- spina bifida
- *therapy of polyhydramnion*

Chorion (i, n.)

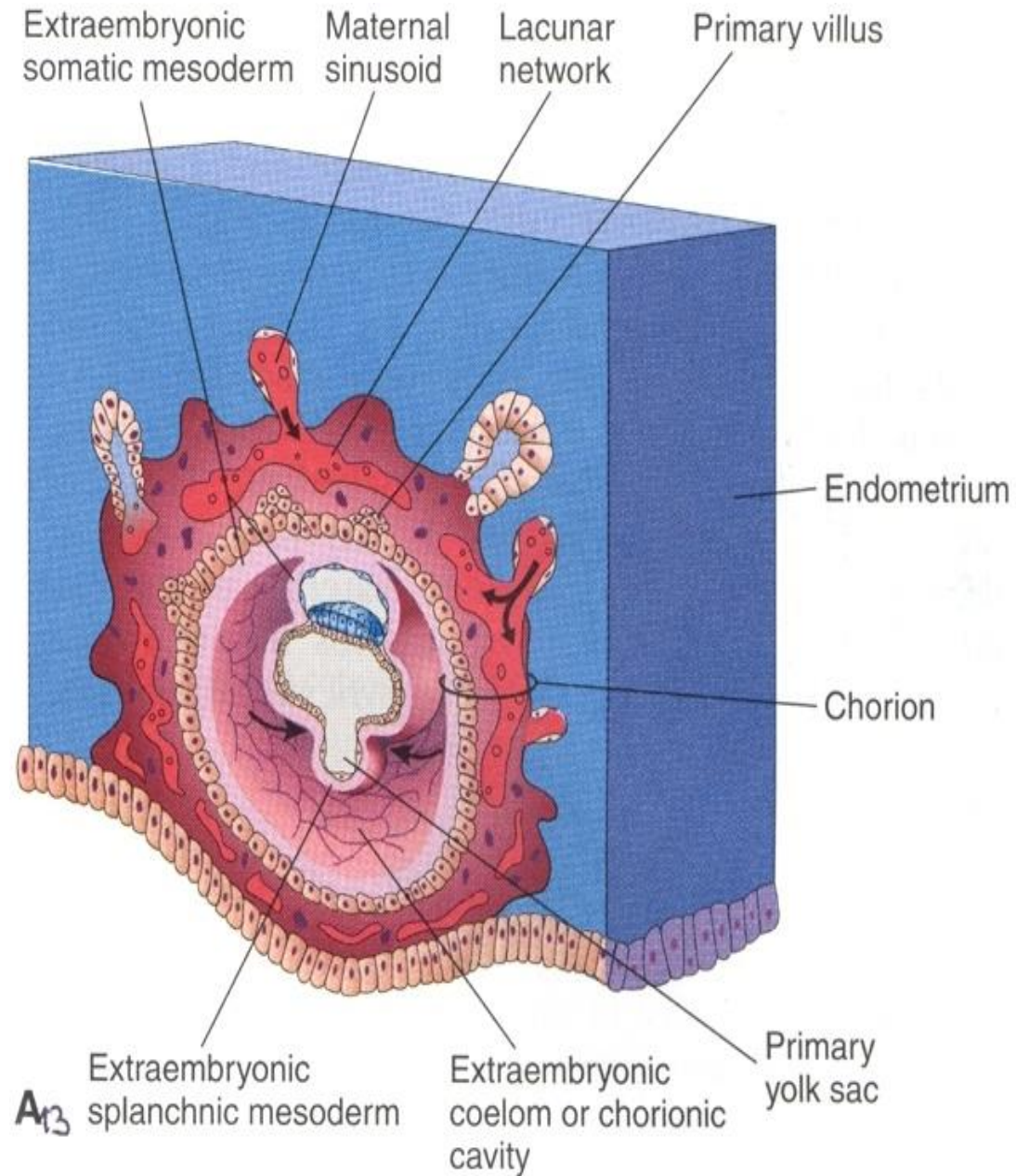
- *vesicula chorionica*
 - chorionic cavity = extraembryonal coelom
- chorionic sac (*saccus chorionicus*)
 - *cavitas chorionica = coeloma extraembryonicum*

Chorion

- development from trophoblast during implantation
- layers:
 - syncytiotrophoblast
 - cytotrophoblast
 - extraembryonal somatic mesoderm
- fusion of cavities within extraembryonal mesoderm
→ **extraembryonal coelom = chorionic cavity**
(*cavitas chorionica*)
 - filled with fluid
- connecting stalk (*pedunculus connectans*) - on connection between embryo and trophoblast

Chorion

- syncytiotrophoblast
- cytotrophoblast
- extraembryonic somatic mesoderm



Development of chorionic villi

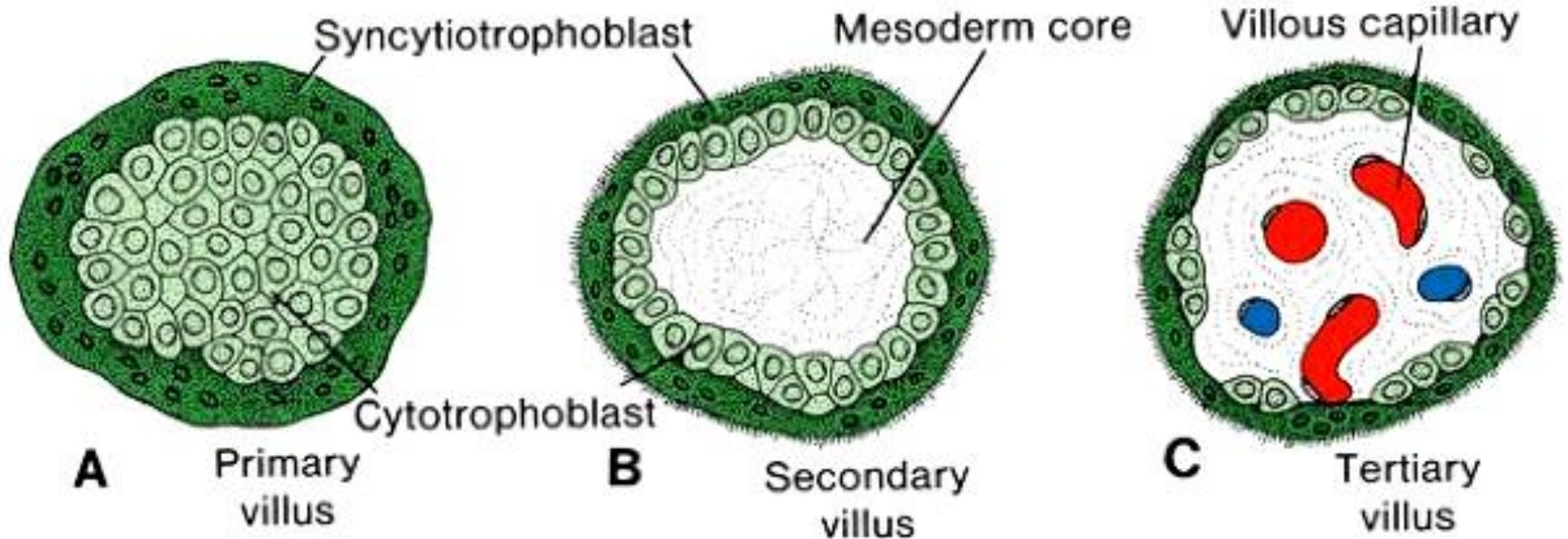
- mesenchyma chorionicum – wall of chorionic sac
- mesothelium chorionicum – internal wall of chorionic cavity
- end of 2W: syncytiotrophoblast (lacunar stage)
 - lacunae separated with trabeculae
 - fuse into labyrinth = future intervillous space
 - a column of cytotrophoblast invades inside the trabeculae
 - = **primary chorionic villus (*villus primarius*)**
 - (induction of adjacent extraembryonal somatic mesoderm)

Development of chorionic villi

- from 3W: further development of **primary chorionic villi**
- ingrowth of mesenchyme = **secondary chorionic villi**
- secondary villi cover whole surface of chorionic sac
- whole chorion is covered with secondary villi as late as 8W

- development of vessels inside the mesenchyme of villi = **tertiary chorionic villi**
- vessels of tertiary villi are connected with fetal circulation = nutrition and waste cleaning

Development of chorionic villi

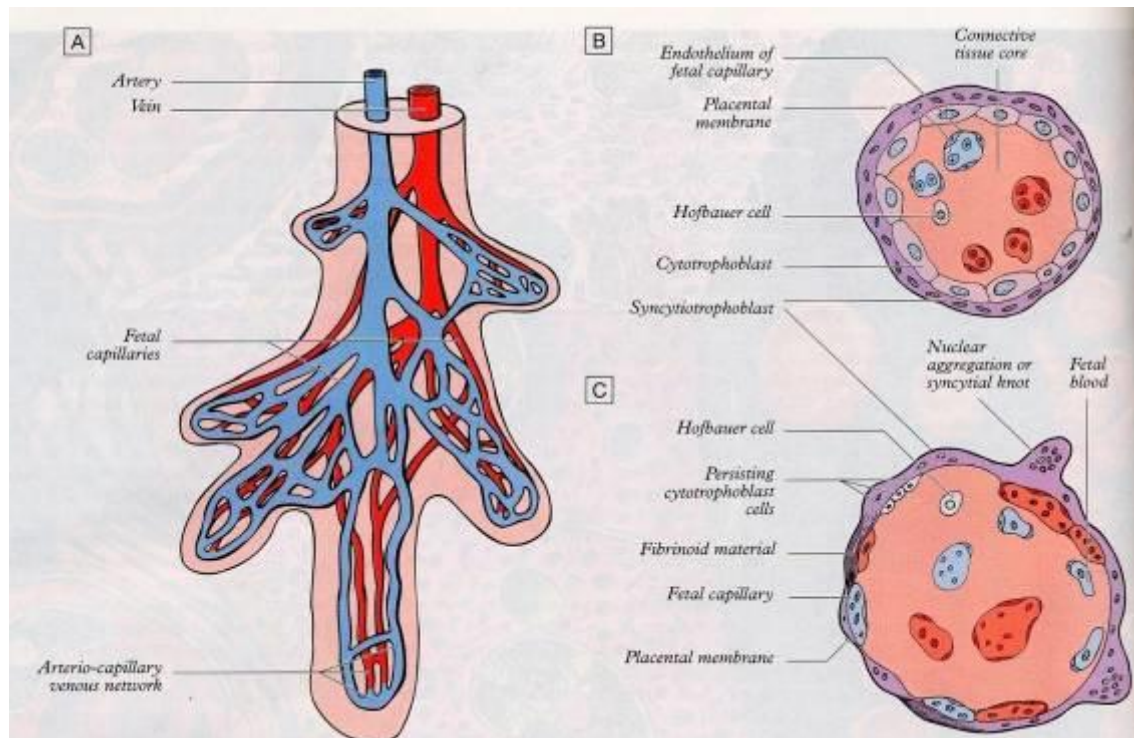


intensive proliferation of cytotrophoblast, which penetrates syncytiotrophoblast = **cytotrophoblastic shell**
- fixes chorionic sac to the endometrium

Villus secundarius x Villus tertius

- syncytiotrophoblast
- cytotrophoblast
- extraembryonal mesoderm

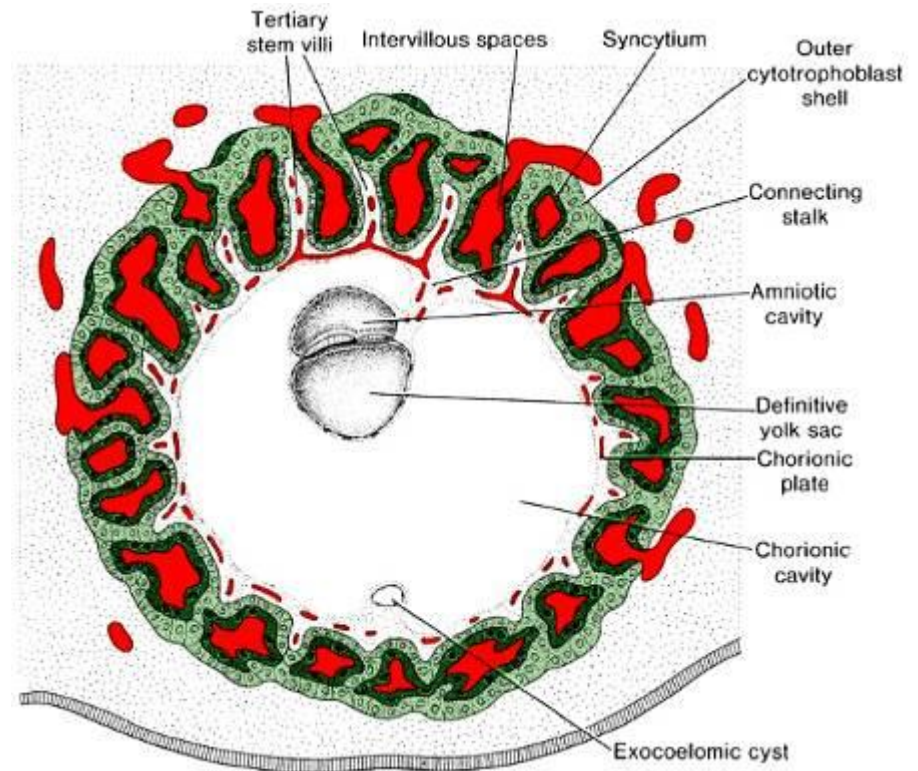
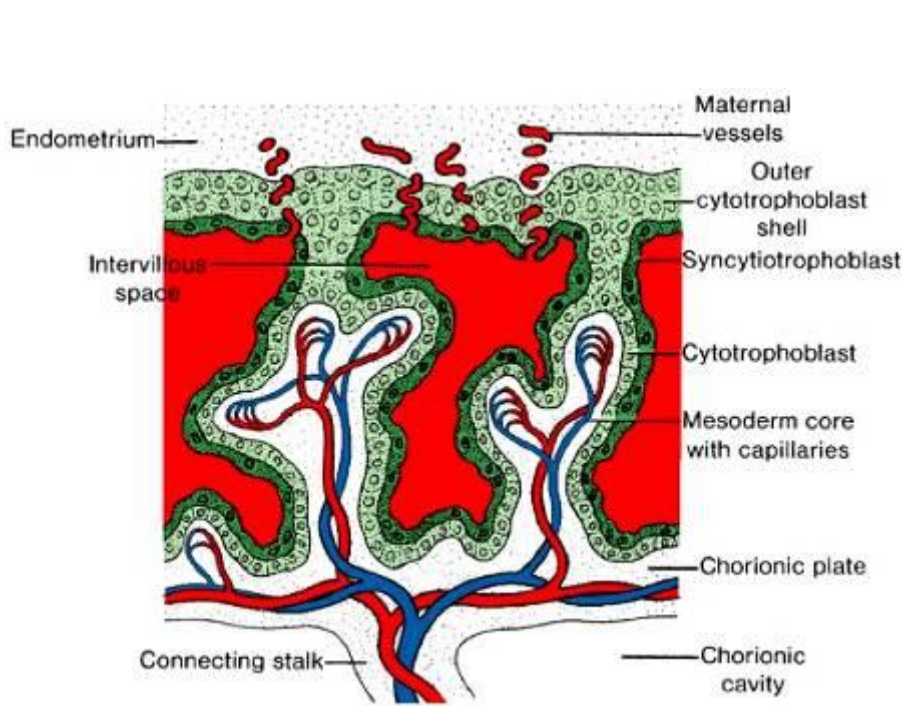
- syncytiotrophoblast
- (only islets of cytotrophoblast)
- extraembryonal mesoderm
- vessels



Development of chorionic villi

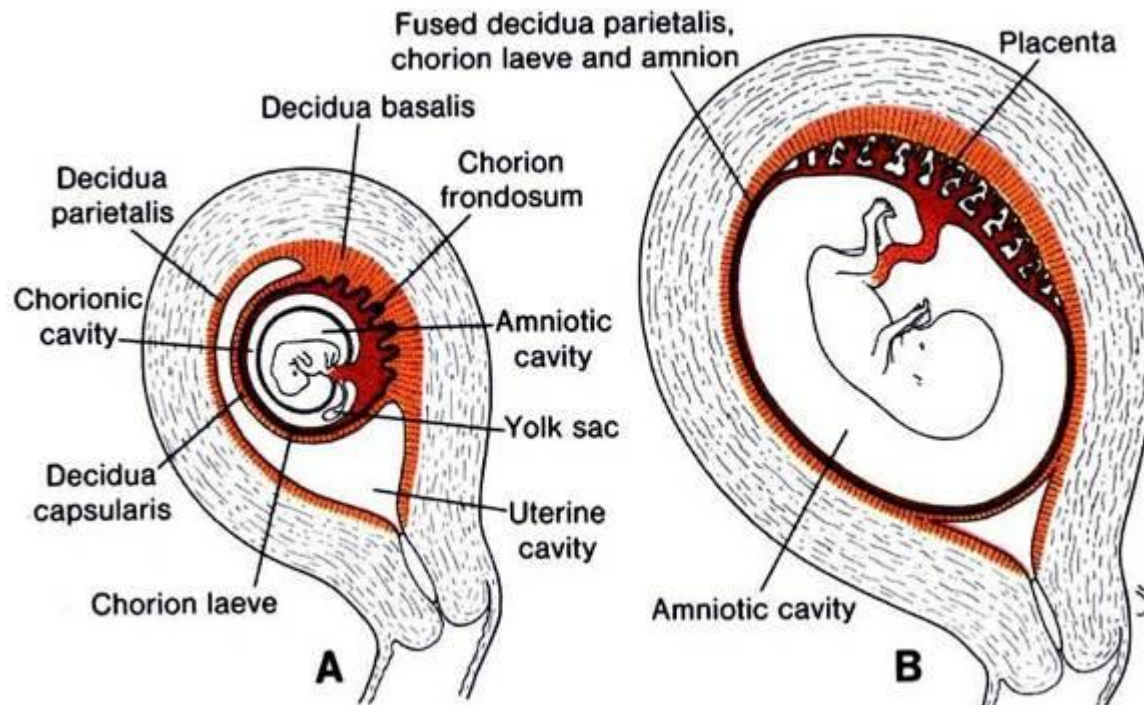
- towards the end of pregnancy:
syncytiotrophoblast degenerates in some spots →
fibrin storage (from maternal blood) → fibrinoid
- 3 structural types of villi:
 - **anchoring villus** (*villus ancorans*) – connected to decidua basalis
 - **ramified villus** (*villus ramosus*) – ramifying inside intervillous spaces
 - **free villus** (*villus liber*) projects into intervillous spaces
 - separation of maternal and fetal connective tissue – cytotrophoblastic shell

Development of chorionic villi



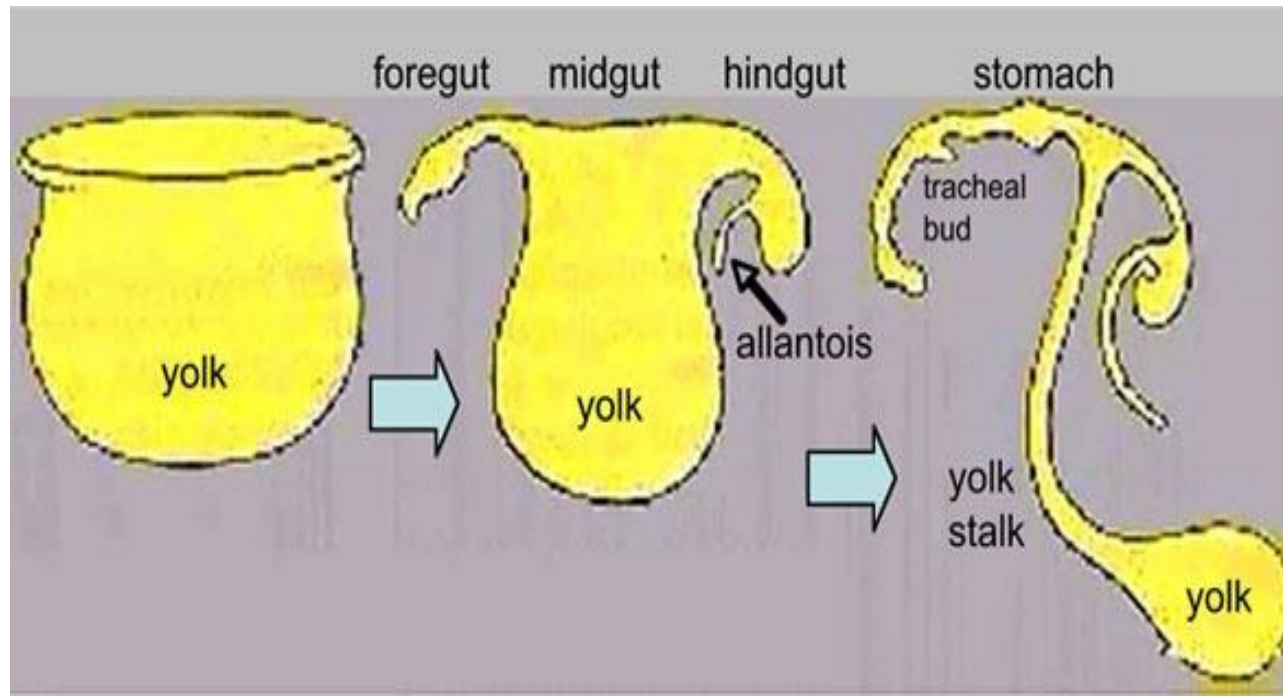
Chorion

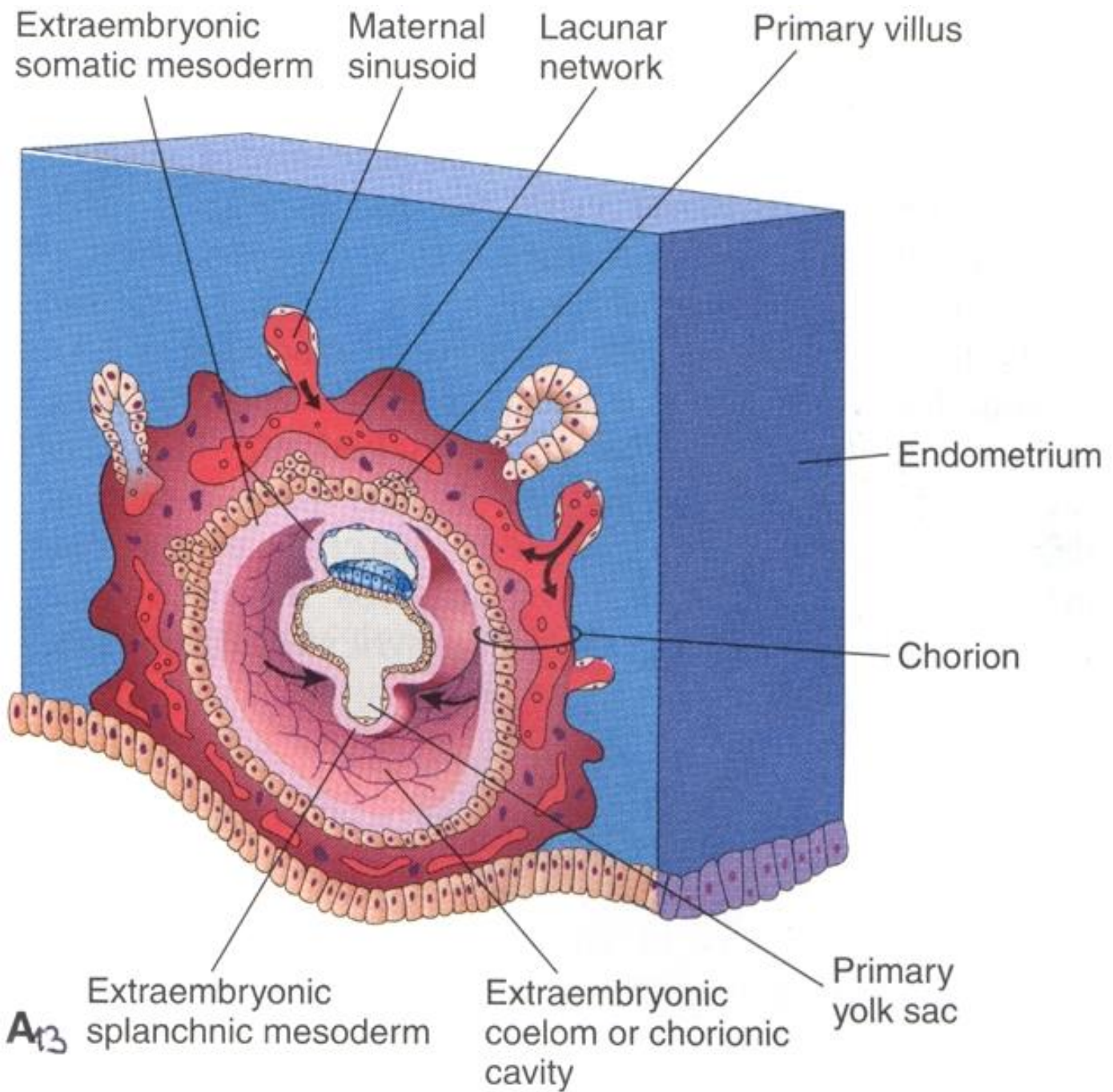
- decidua capsularis compresses villi in its vicinity → they degenerate → **chorion laeve** (smooth chorion)
- in area of decidua basalis: the villi multiply → **chorion frondosum**



Vesicula umbilicalis (Saccus vitellinus) = Yolk sac

- blastocystic cavity → exocoelom = **vesicula umbilicalis primaria** (primary yolk sac)
 - cavity connected with primitive gut
 - by growth of chorionic cavity: yolk sac separated and fades out





Vesicula umbilicalis (Saccus vitellinus) = **Yolk sac**

- endoderma extraembryonicum vesiculae umbilicalis
 - 13D: cellulae germinales precursoriae (primordial germ cells)
 - migrated here from caudal part of epiblast
- mesenchyma extraembryonicum vesiculae umbilicalis
 - 3-6T: hematopoiesis

Vesicula umbilicalis (Saccus vitellinus) = **Yolk sac**

vesicula umbilicalis secundaria (secondary/definitive yolk sac)

- formed by cells of extraembryonal endoderm (from hypoblast)
- pedunculus vesiculae umbilicalis
 - vasa omphaloenterica (vitellina)
 - ductus omphaloentericus (vitellinus)

Vesicula umbilicalis (Saccus vitellinus) = Yolk sac

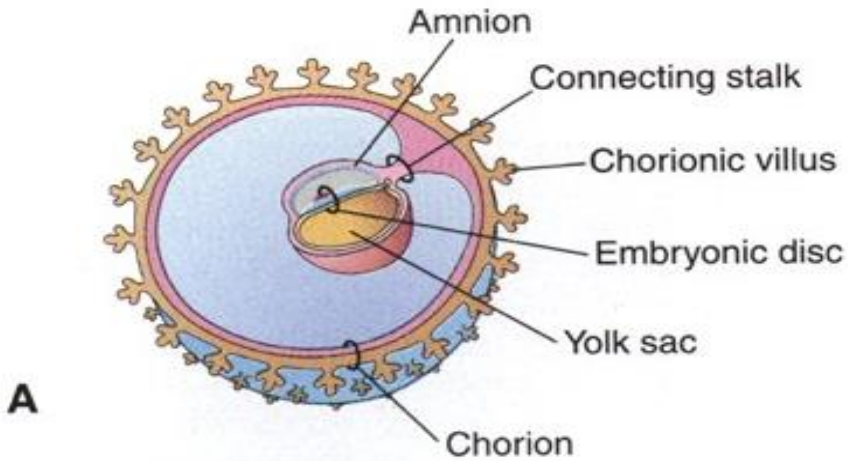
- primary = blastocystic cavity → exocoelom
- definitive = wall form cells derived from hypoblast → from exocoelom membrane
- temporary structure, fades out with folding of embryo
- part is used for gut development (4W)
- part can survive as: **diverticulum ilei Meckeli (2 %)**

function:

- 2-3W: selective transport of fluids and nutrients to embryo
- **13D: primordial germ cells**
- **vasa omphaloenterica → veins form some of hepatic circulation and v. portae**
- **3-6T: first hematopoiesis ever !**

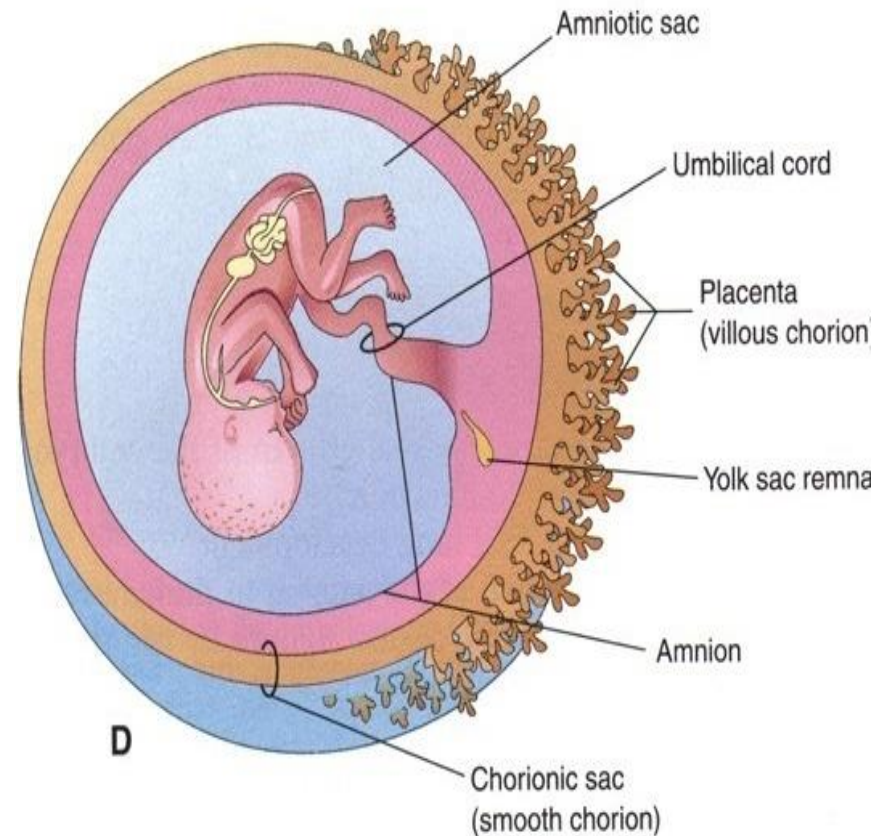
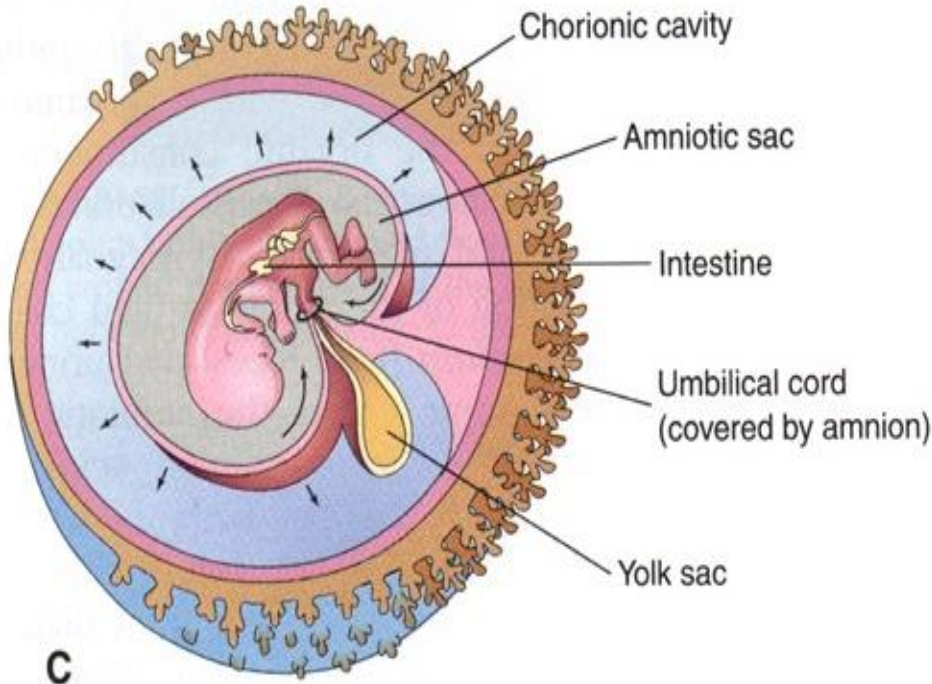
32D: velký

Vesicula umbilicalis (Saccus vitellinus) = Yolk sac



- 20T: malinký

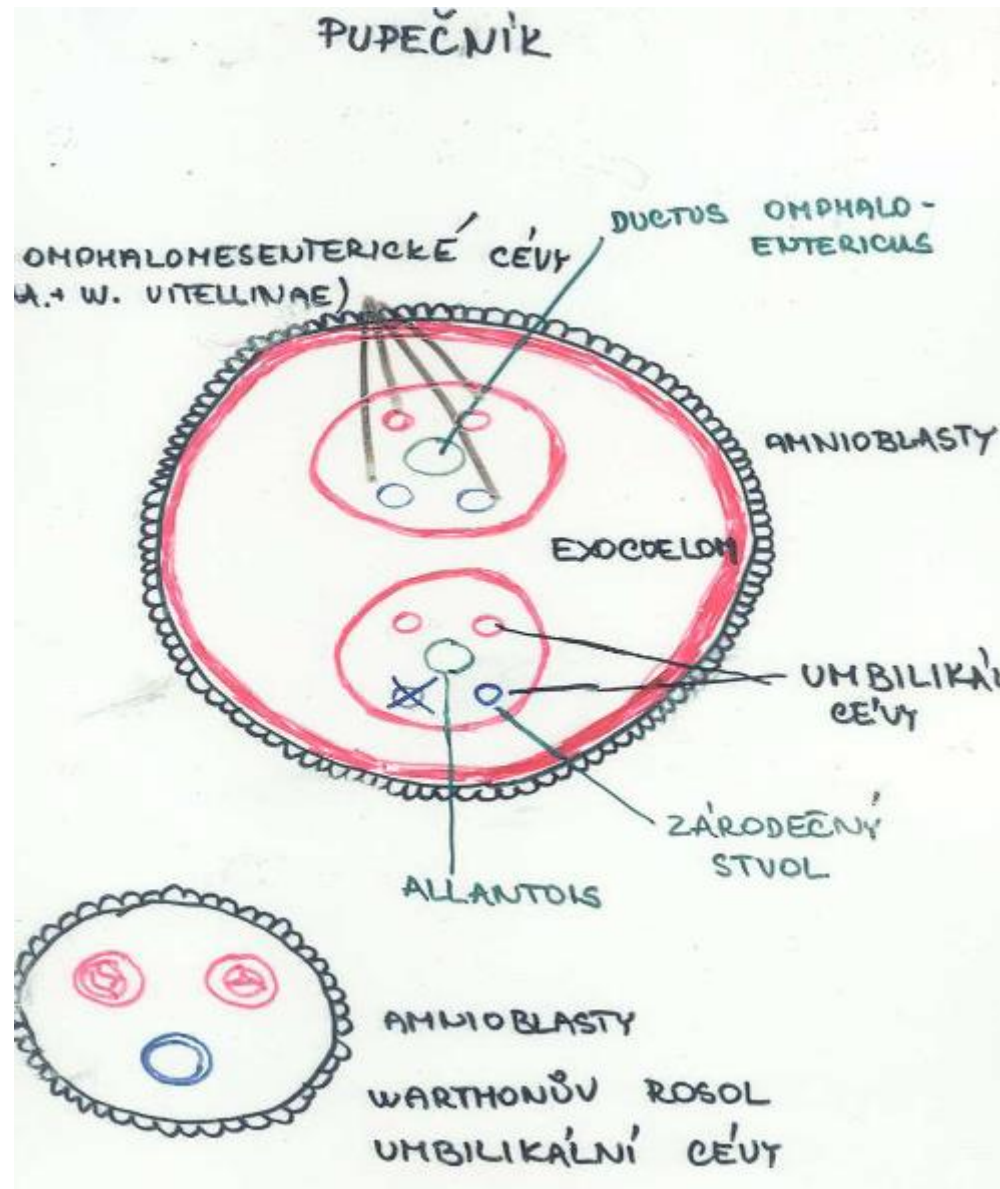
10T: menší – ductus omphaloentericus

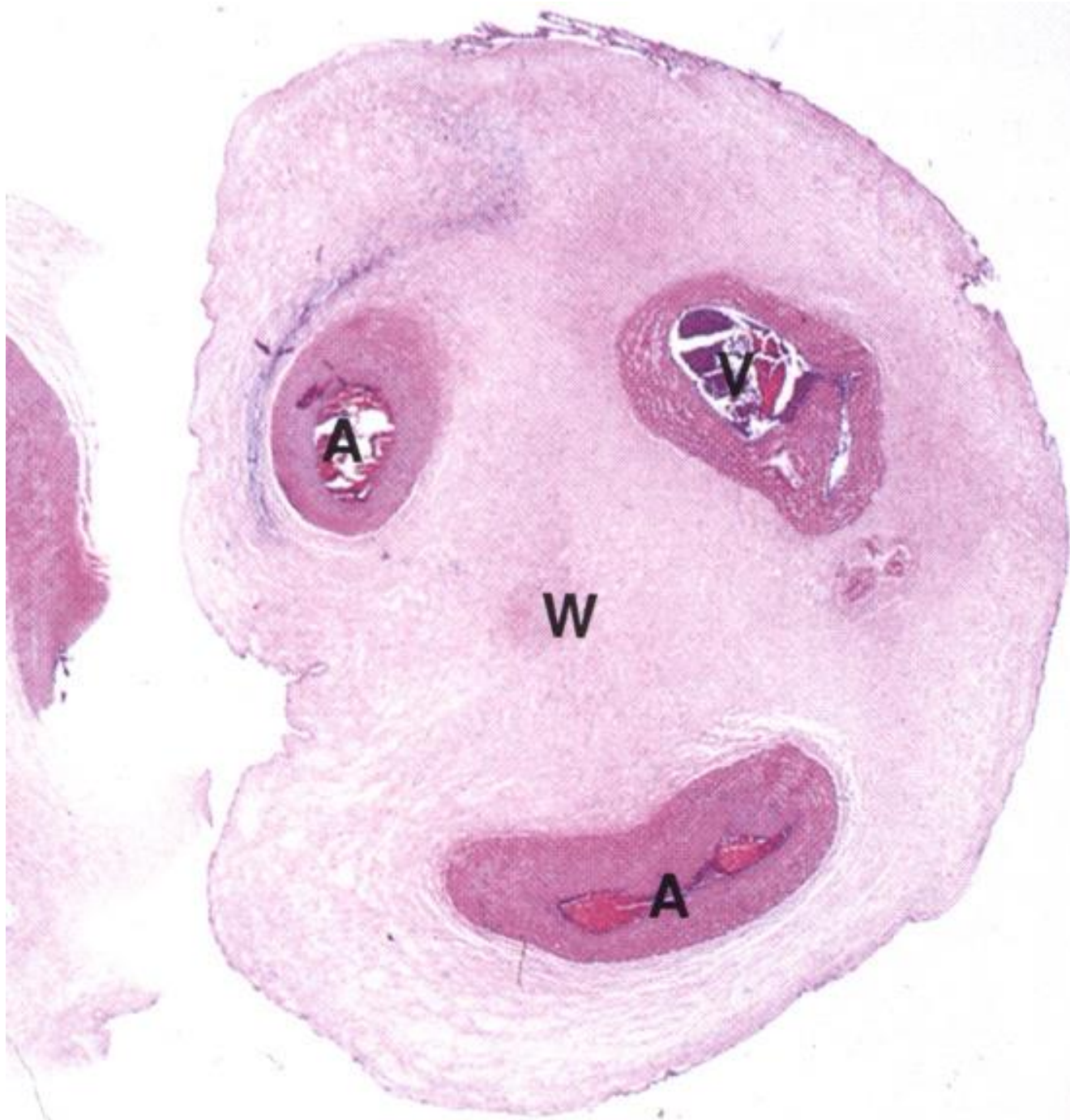


Funiculus umbilicalis = umbilical cord

- amniochorion (epithelium on its surface)
- aa. + vv. umbilicales
 - anastomosis interarterialis transversa Hyrtl
 - right vein fades out → v. umbilicalis impar
- **6-10W**: ansa umbilicalis intestini (physiological herniation of intestine)
- **3M**: ductus omphaloentericus (vitellointestinalis) – fades out
- vesicula umbilicalis - fades out
- diverticulum allantoicum - fades out
- (coeloma umbilicale – fades out by growth of amnion around umbilical cord)
- Wharton's jelly (Thomas Wharton – English anatomist 1614-1673)

Funiculus umbilicalis = umbilical cord

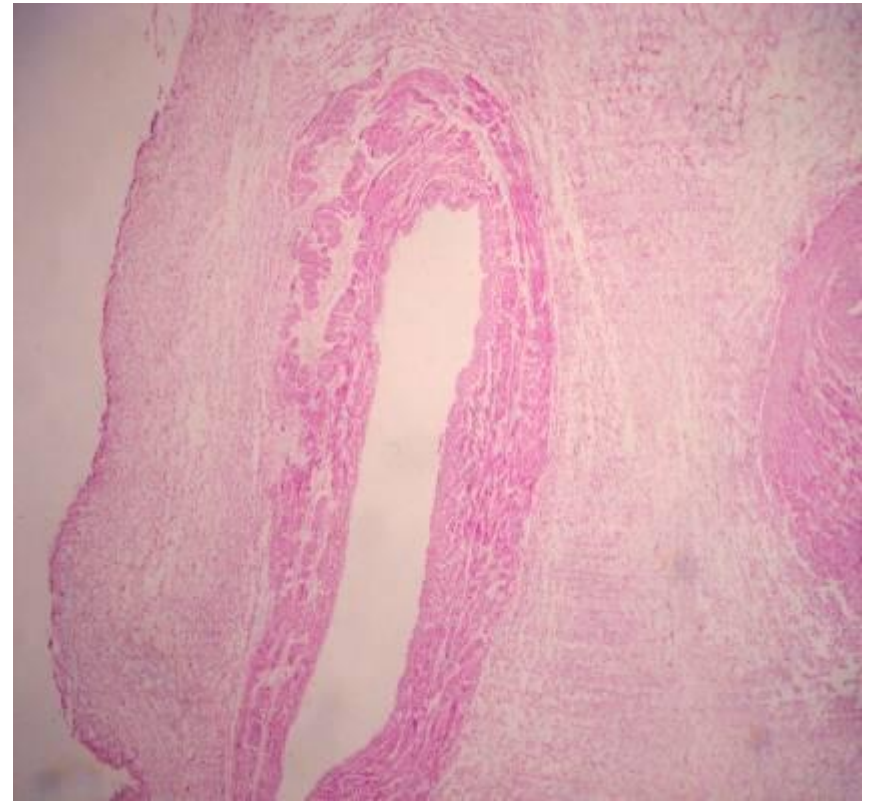
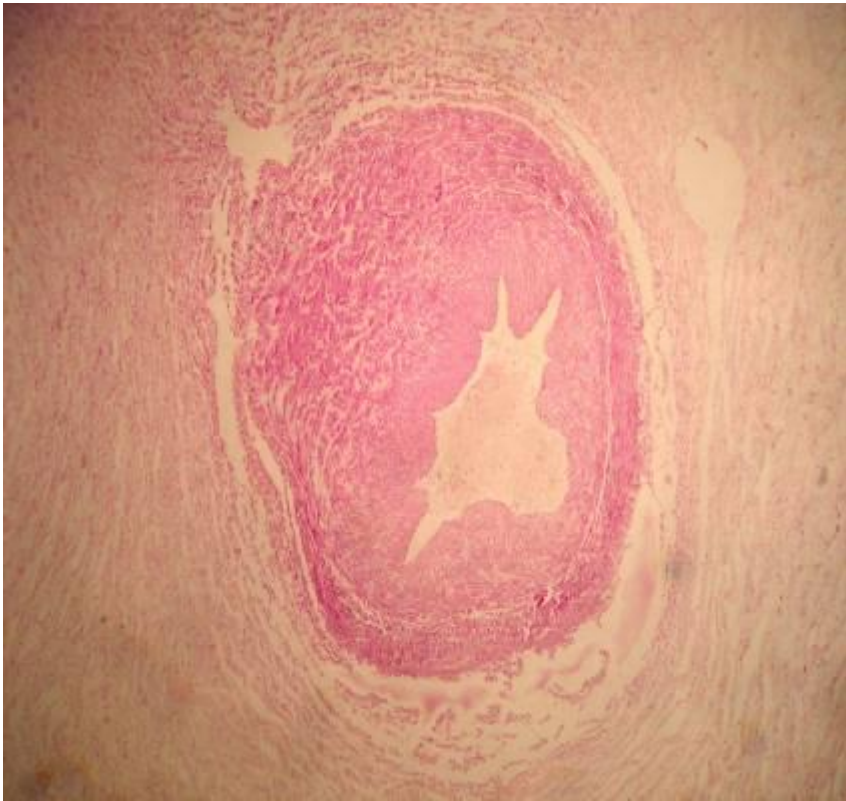



Aa. et v. umbilicales

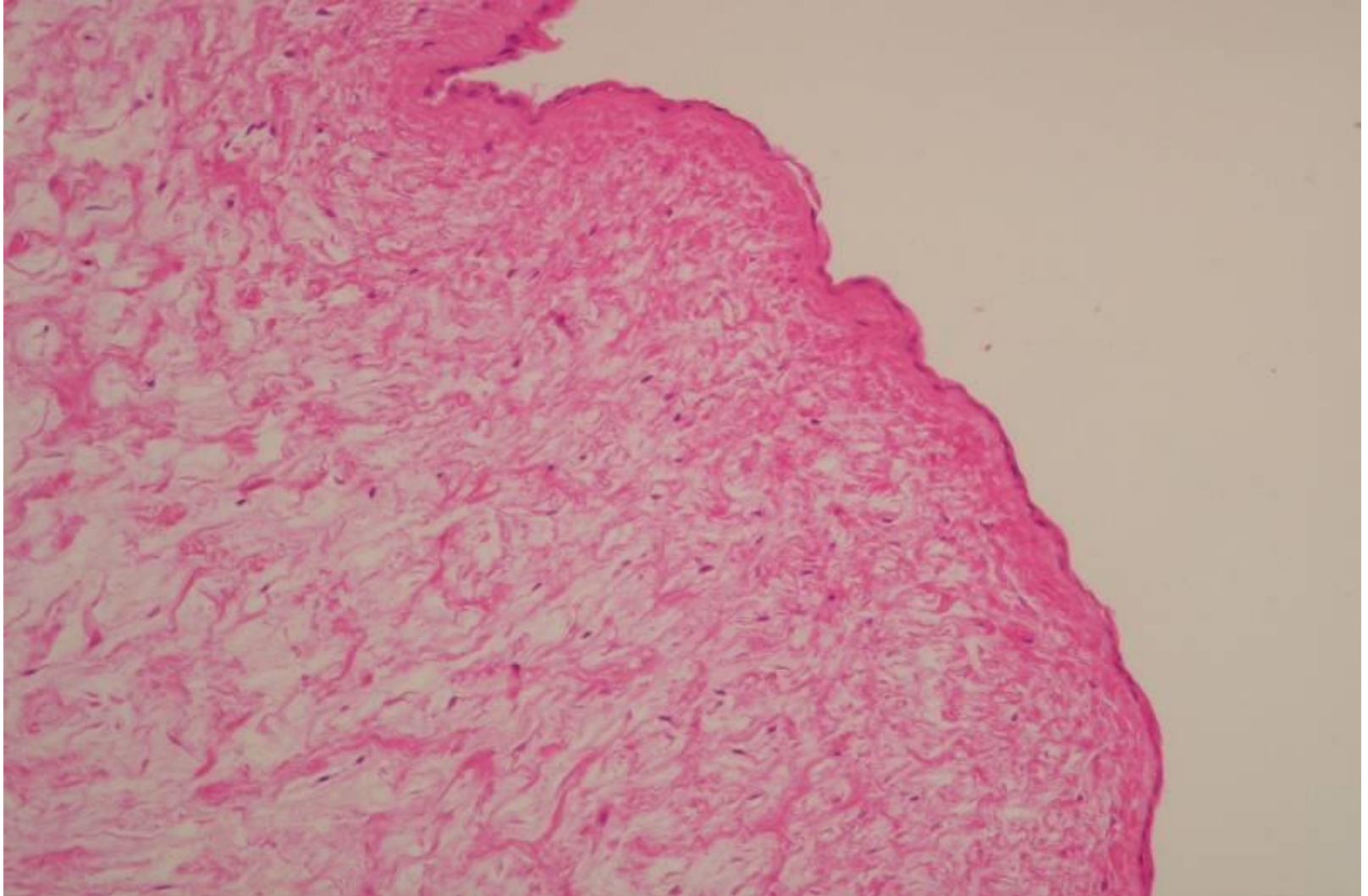
2 aa. umbilicales
CO₂ from fetus to
placenty

1 v. umbilicalis
O₂ from placenta to
fetus



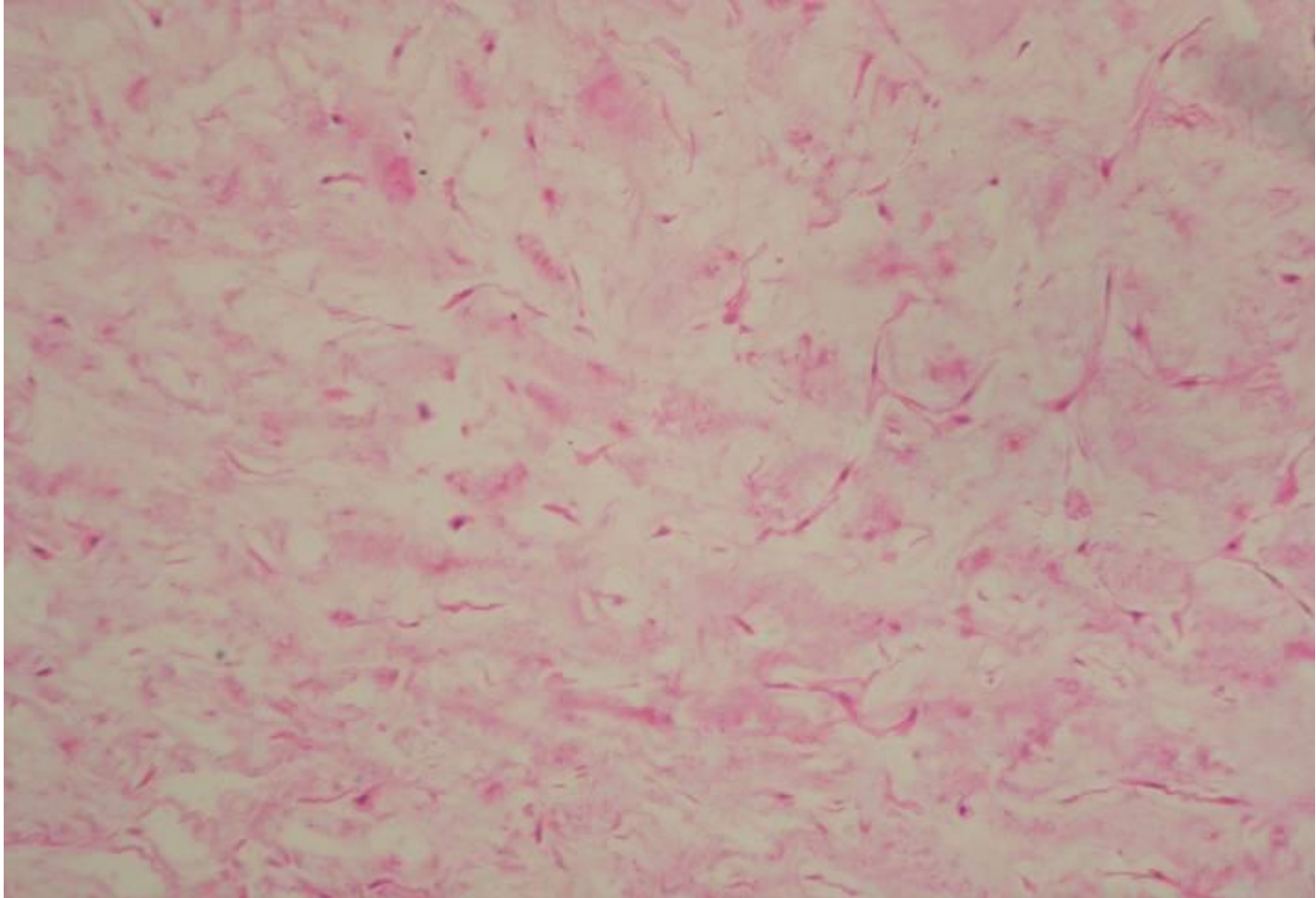
Funiculus umbilicalis

amnioblasts on outer surface



Funiculus umbilicalis

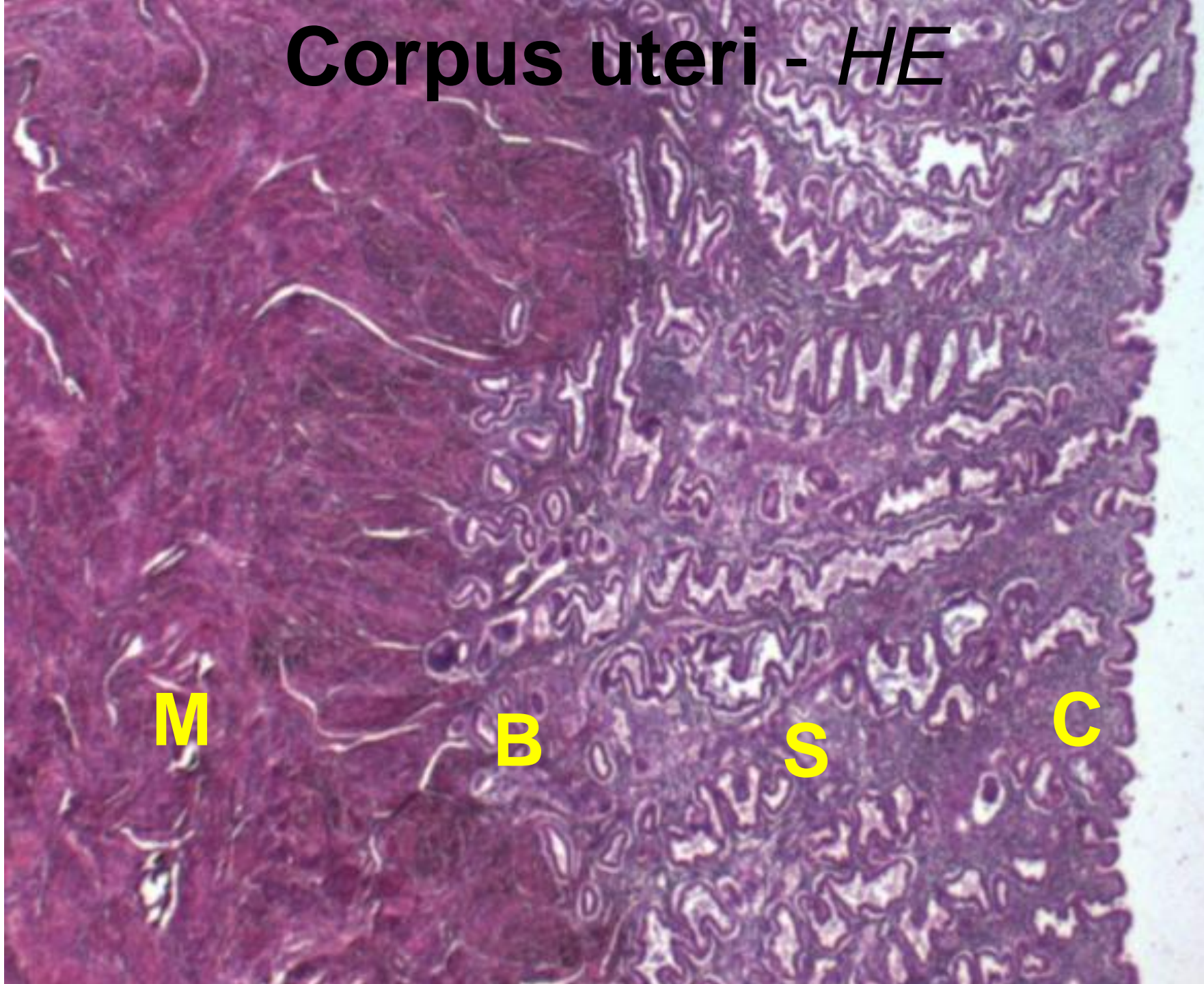
Wharton's jelly



Endometrium

- epithelium: simple columnar
- glandulae uterales – tubulous
- stratum basale – richer in cells, more reticular fibers, vessels
- stratum functionale – separates in menstruation
 - stratum spongiosum
 - stratum compactum
- stromal cells = decidual

Corpus uteri - *HE*



M

B

S

C

Maternal parts of fetal membranes

Partes maternae membranarum

- endometrium basale
 - decidual reaction (*reactio decidualis*)
 - margo syncytiodecidualis
 - oedema + toothlike arrangement of glands in stratum spongiosum
 - transformation of stromal cells (fibroblasts) into decidual cells (higher content of glycogene and lipids) + transformation of vasclar supply
 - cellulae deciduales
 - under **progesterone influence**
- decidua
 - transformation of zona functionalis only

Decidua

- **Decidua basalis**

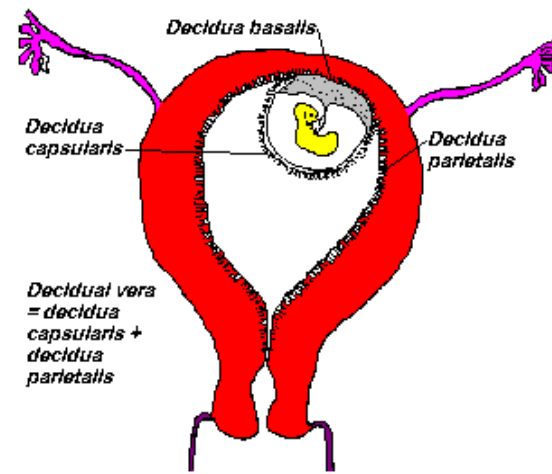
- cryptae endometrii
- glandulae endometrii
- septa placentae + insulae cellularum placentae (mixed origin from both mother and embryo)
- zona limitans decidualis (in contact with cytotrophoblast shell)
- substantia fibrinoidea (at the end of pregnancy – marks of degeneration)

- **Decidua capsularis**

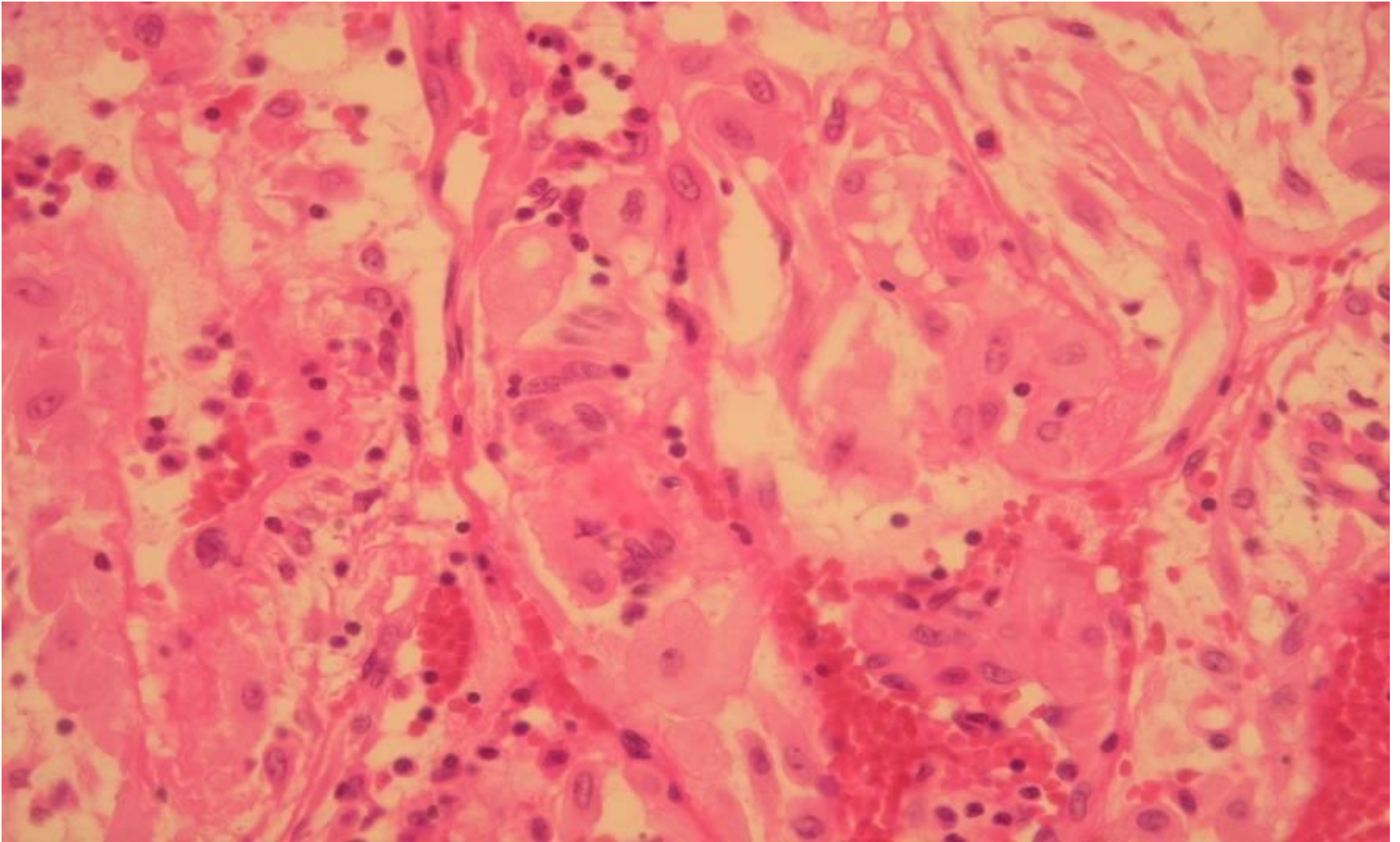
- operculum deciduale

- **Decidua parietalis**

- obsolete term: „decidua vera“

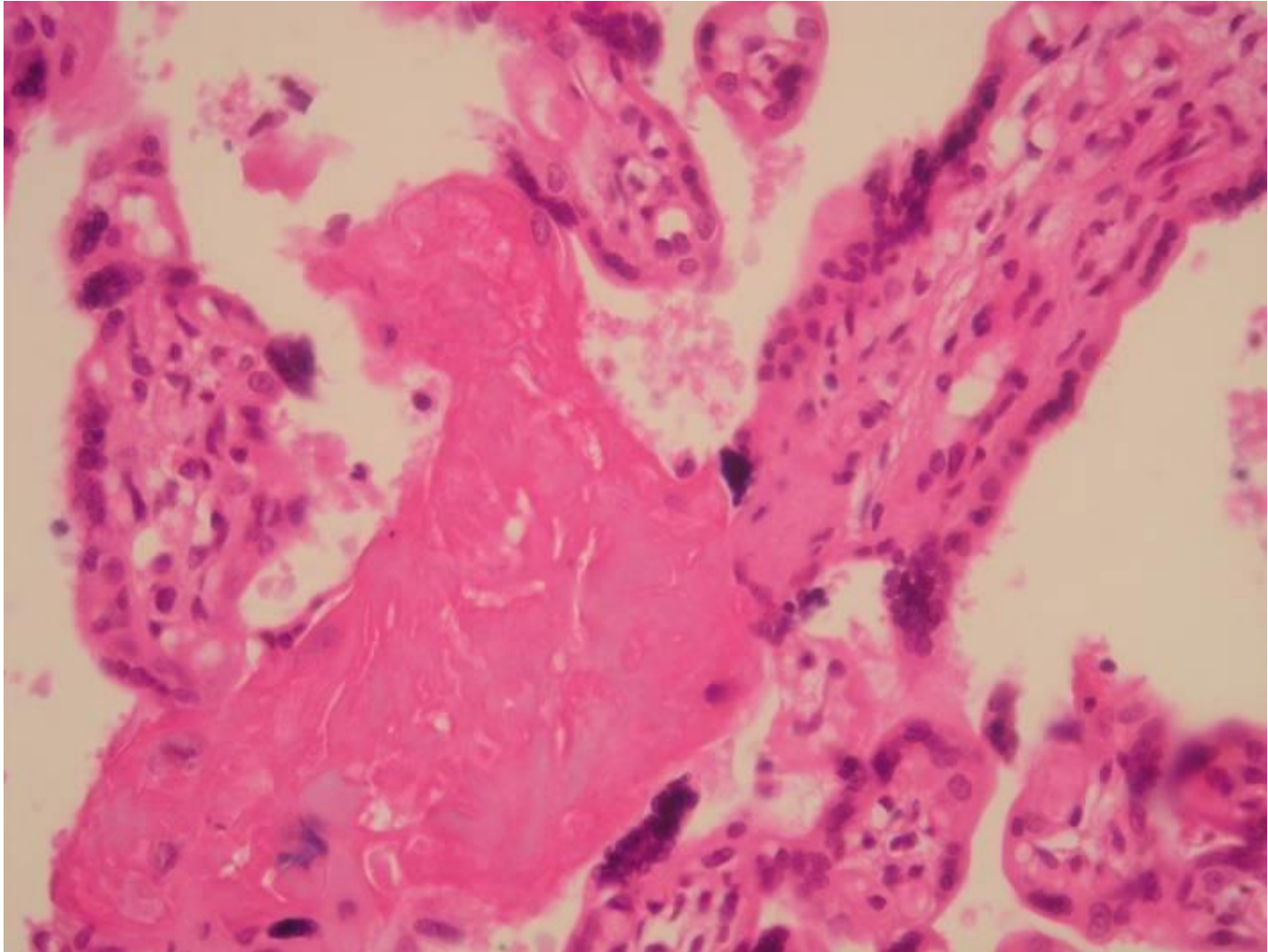


Decidua



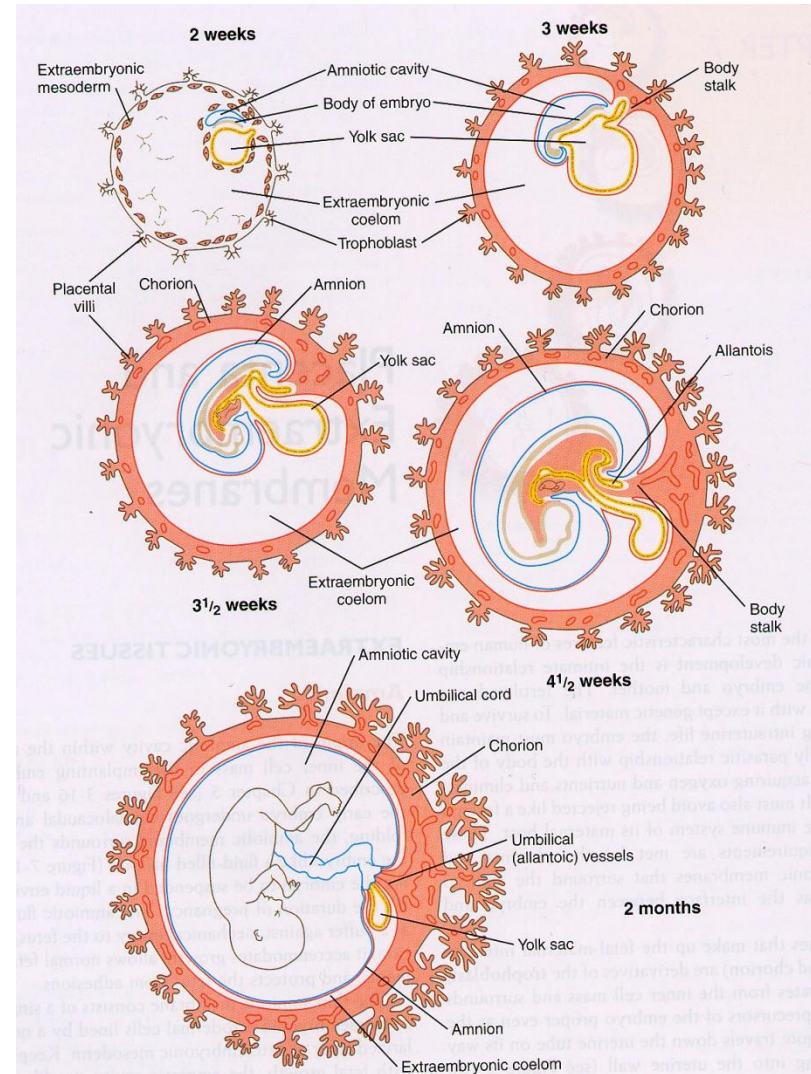
Placenta

fibrinoid = result of immune reaction

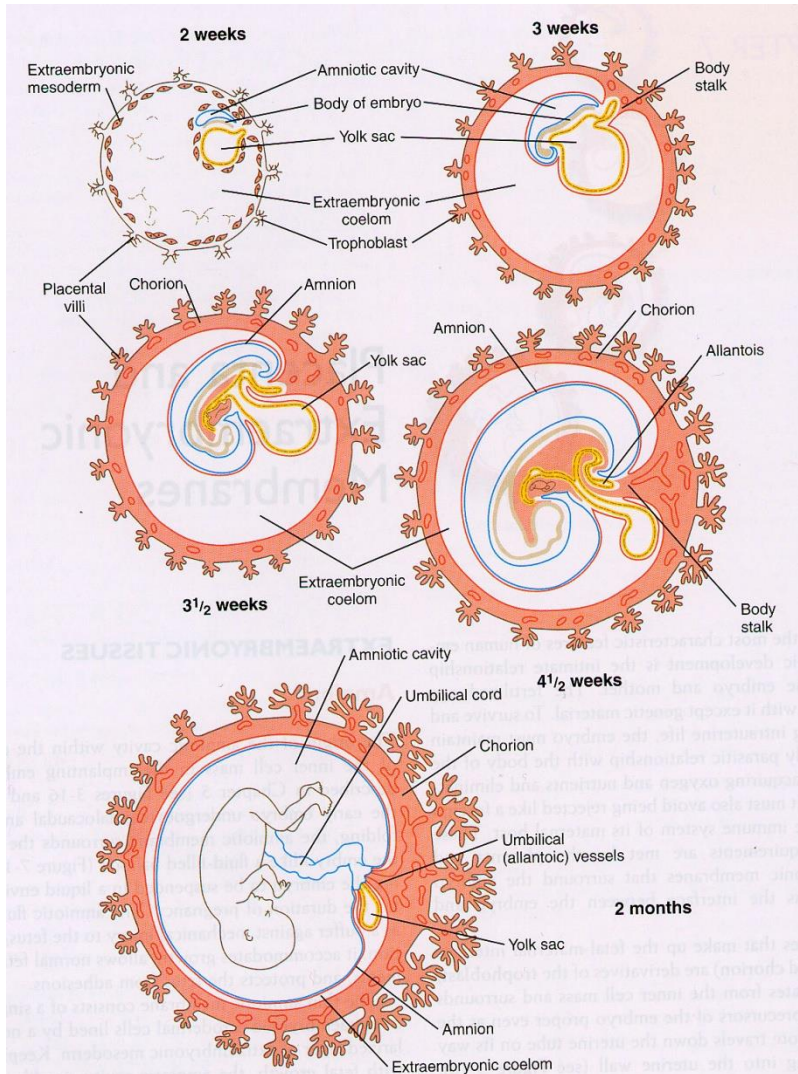


Membranae fetales definitivae (*Definitive fetal membranes*)

- Amnion
- Chorion
- Amniochorion
- Decidua
- Placenta



Membranae fetales definitivae = (*Definitive fetal membranes*)



- 8T: growth of embryo in amniotic cavity → chorionic cavity fades out → **amniochorion**
- amniotic epithelium inside
- chorionic villi outside
- further growth: → *cavitas uteri* fades out + fusion of *decidua capsularis et parietalis*
- further growth: → amniochorion fuses with decidua → **fetal sac**

Membranae fetales definitivae (*Definitive fetal membranes*)

Plodové obaly

Amnion – epitel amnia (amnioblasty)
- mesoderm amnia

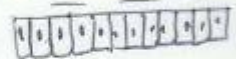


Dutina extraembryonálního coelomu obliteruje během 8. týdne

Chorion – mesoderm choria
- cytotrofoblast
- syncytiotrofoblast

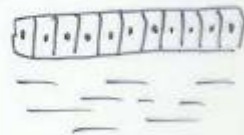

Decidua capsularis – lamina propria
- epitel



Dutina děložní obliteruje na konci 2. trimestru

Decidua parietalis – epitel
- lamina propria

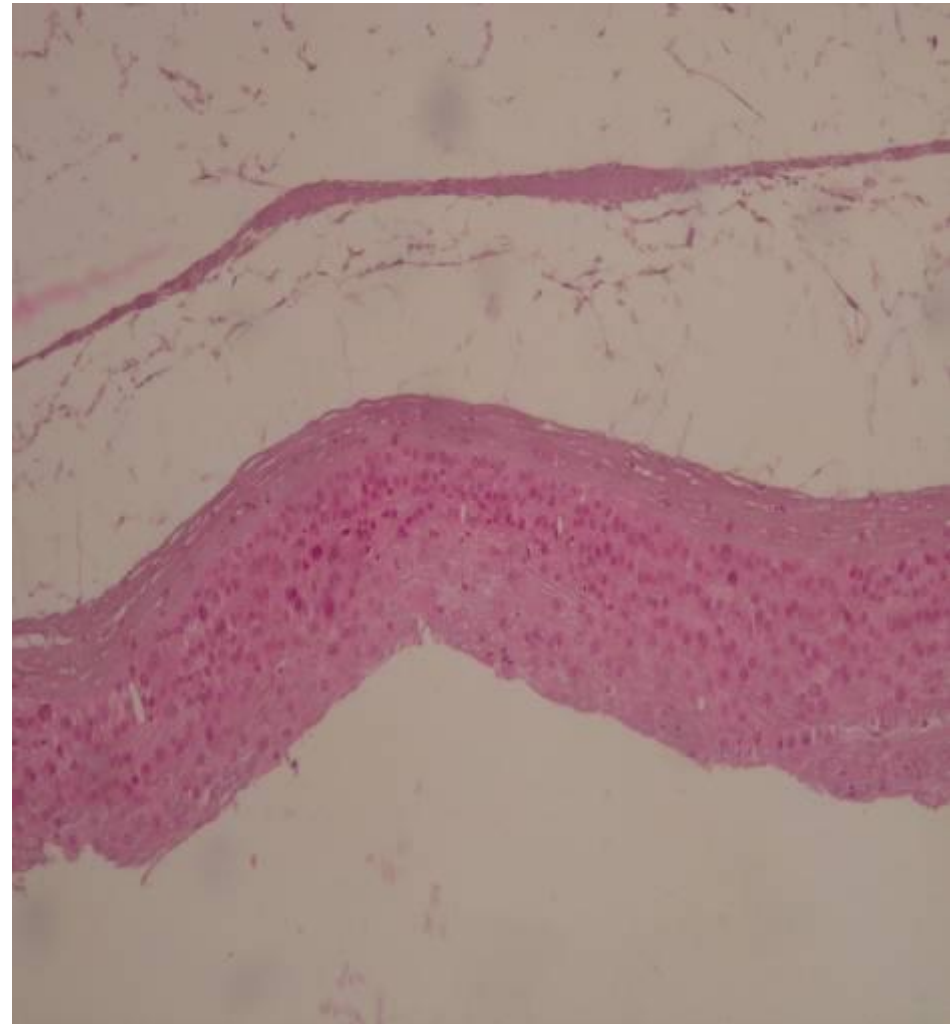


AMNIOBLASTY

MESODERM A+CH

CYTOTROFOBLAST

DECIDUA PARIETALIS

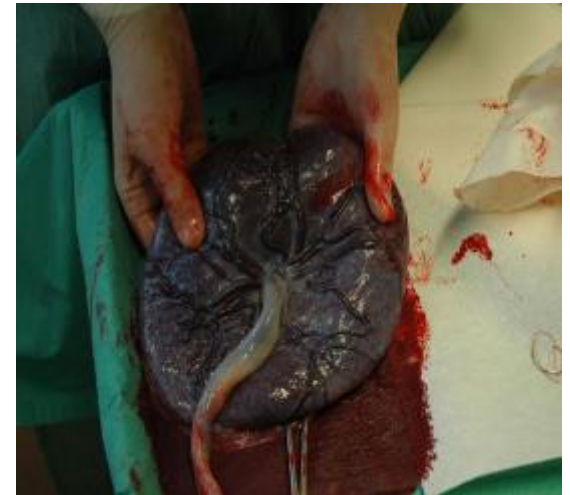

Placenta

- (plaukos)

Insignia placentae humanae = features of human plcenta

- placenta deciduata
- placenta discoidea
- vascularisatio chorioallantoica
- membrana haemochorialis
- gradus formationis placentae
 - gradus villosus initialis → labyrintheus → villosus definitivus
- insertio centralis funiculi umbilicalis



Placenta

- site of gas and nutrients exchange
- size: 15-20 cm
- thickness: 2,5 cm
- weight: approx. 500 g
- composed of 2 parts:
 - fetal part = chorion frondosum
 - maternal part = decidua basalis (changed endometrium)

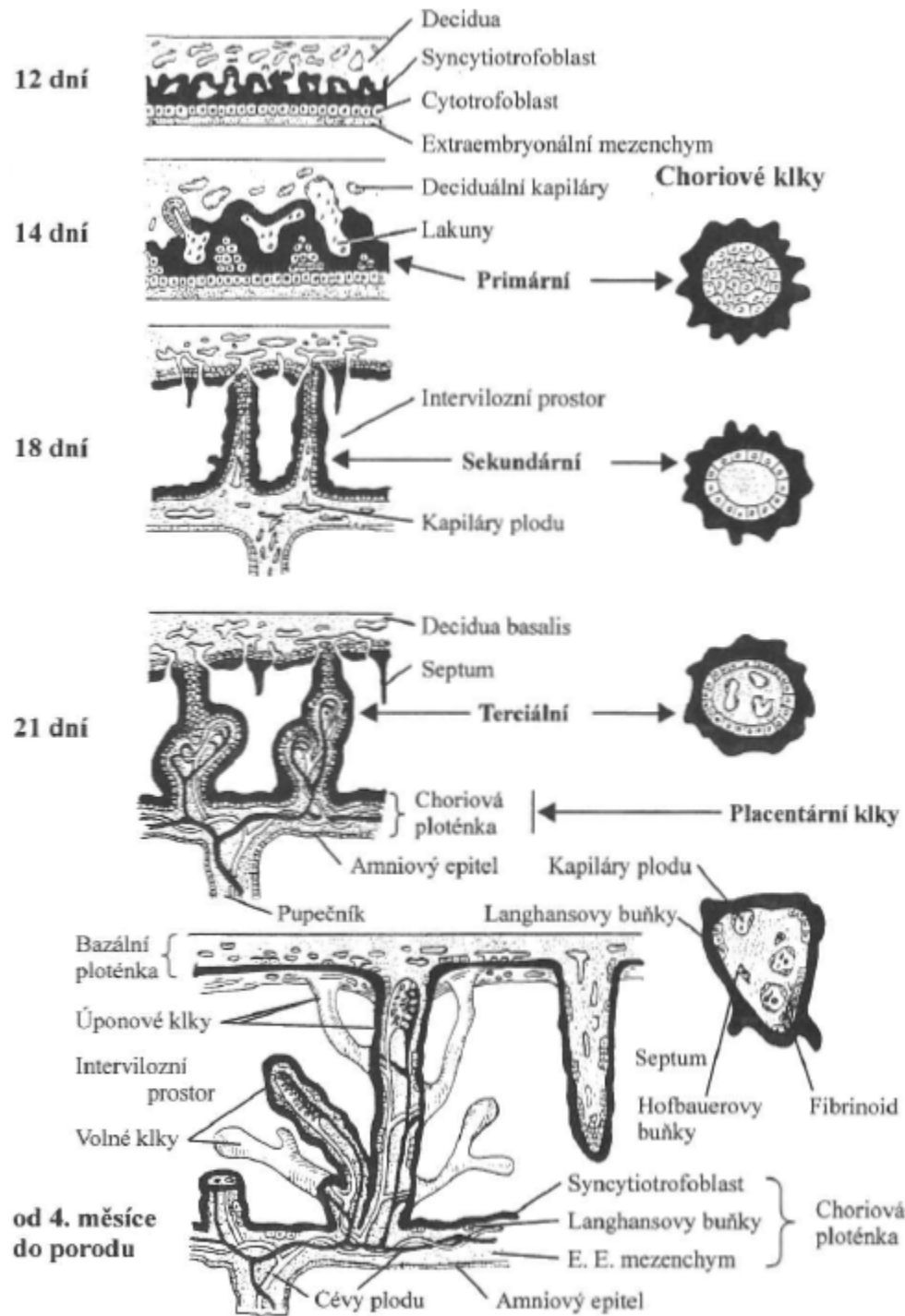
Placenta

Maternal part

- endometrium –
decidual reaction
- **decidua basalis**
(basal plate)
 - contains maternal
vessels =
uteroplacental
circulation
- decidua capsularis,
parietalis

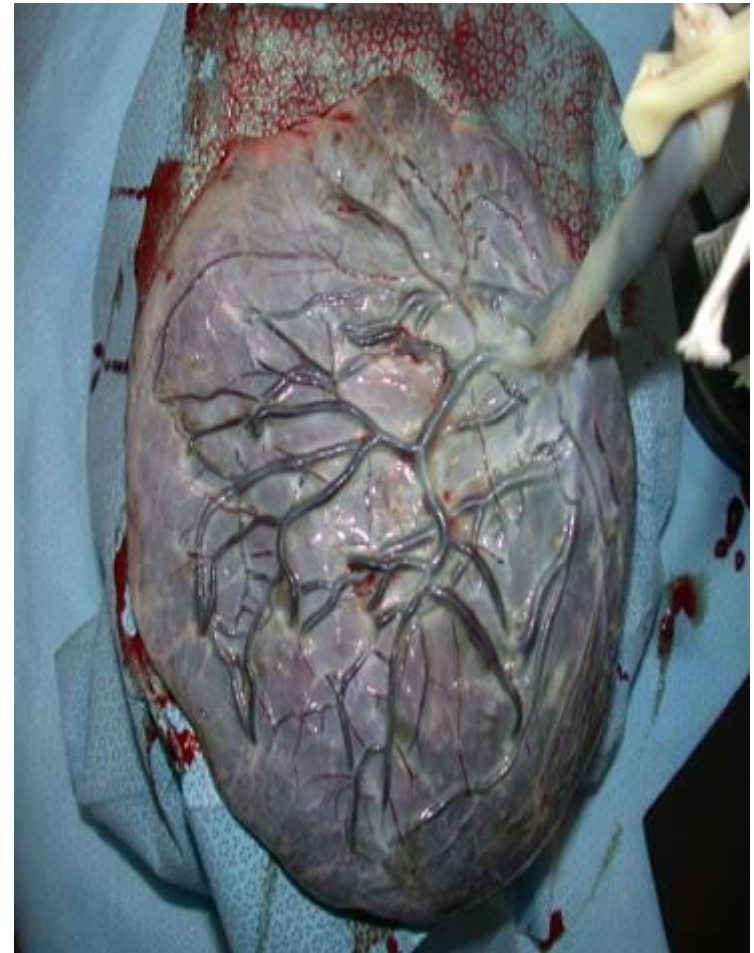
Fetal part

- chorionic plate
- chorionic villi
- **chorion frondosum**
- chorion laeve



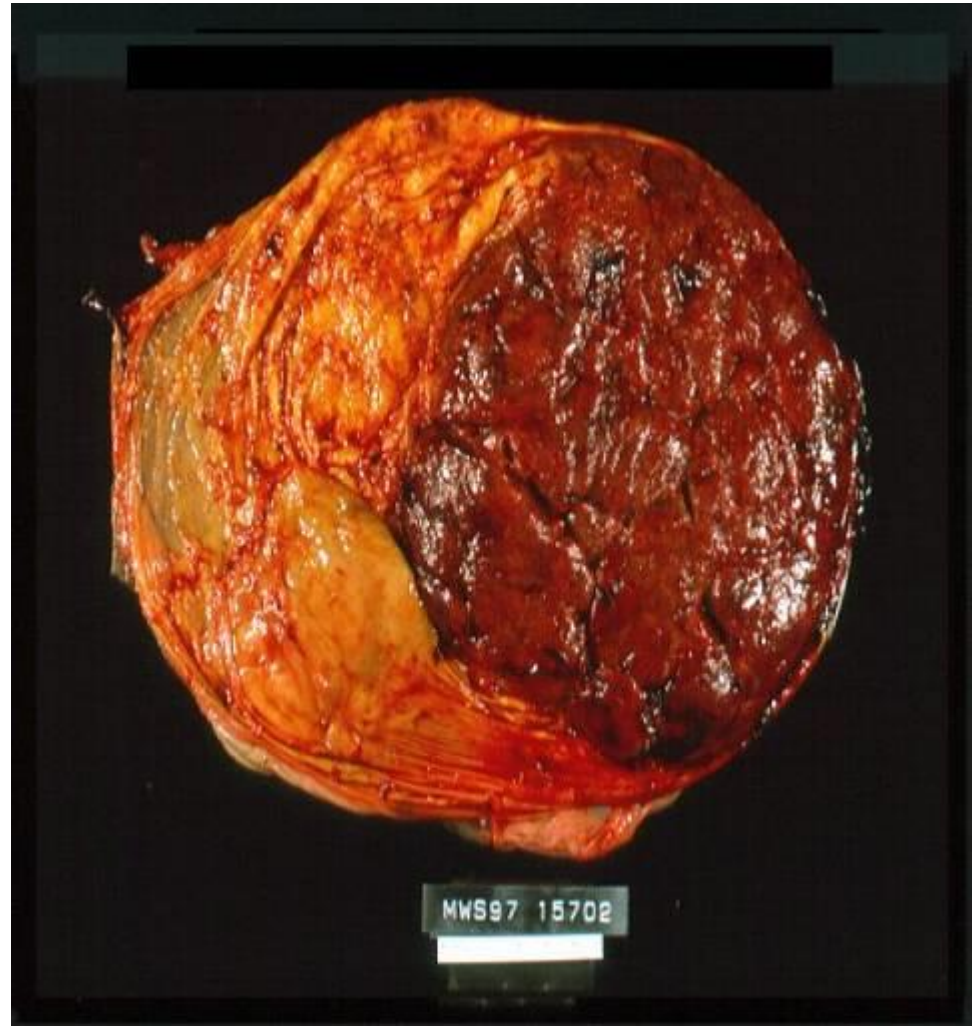
Fetal surface

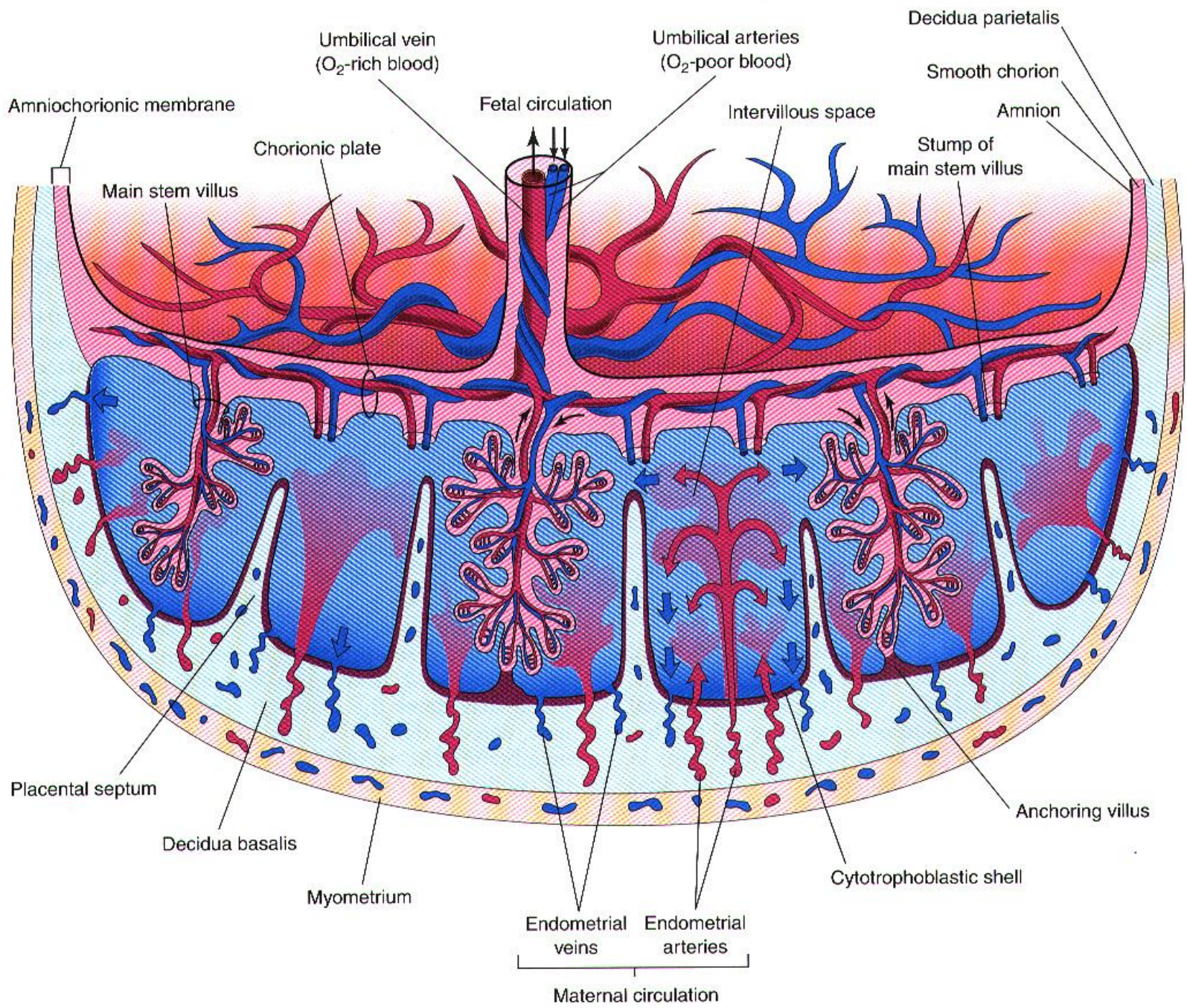
- amnion
- funiculus umbilicalis
- vasa umbilicalia
 - ramify into vessels of chorion



Maternal surface

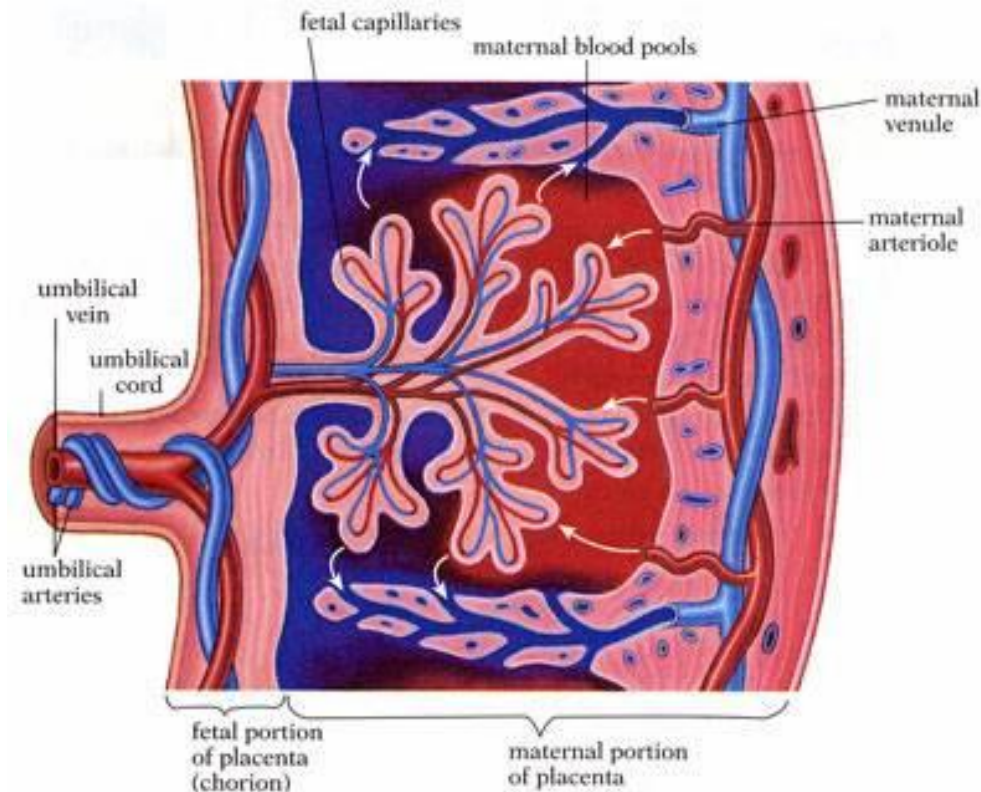
- rough, spongy
- decidua basalis is replaced with cotyledons (end of 4M)
- cotyledons separated with grooves (sooner filled with placental septa)





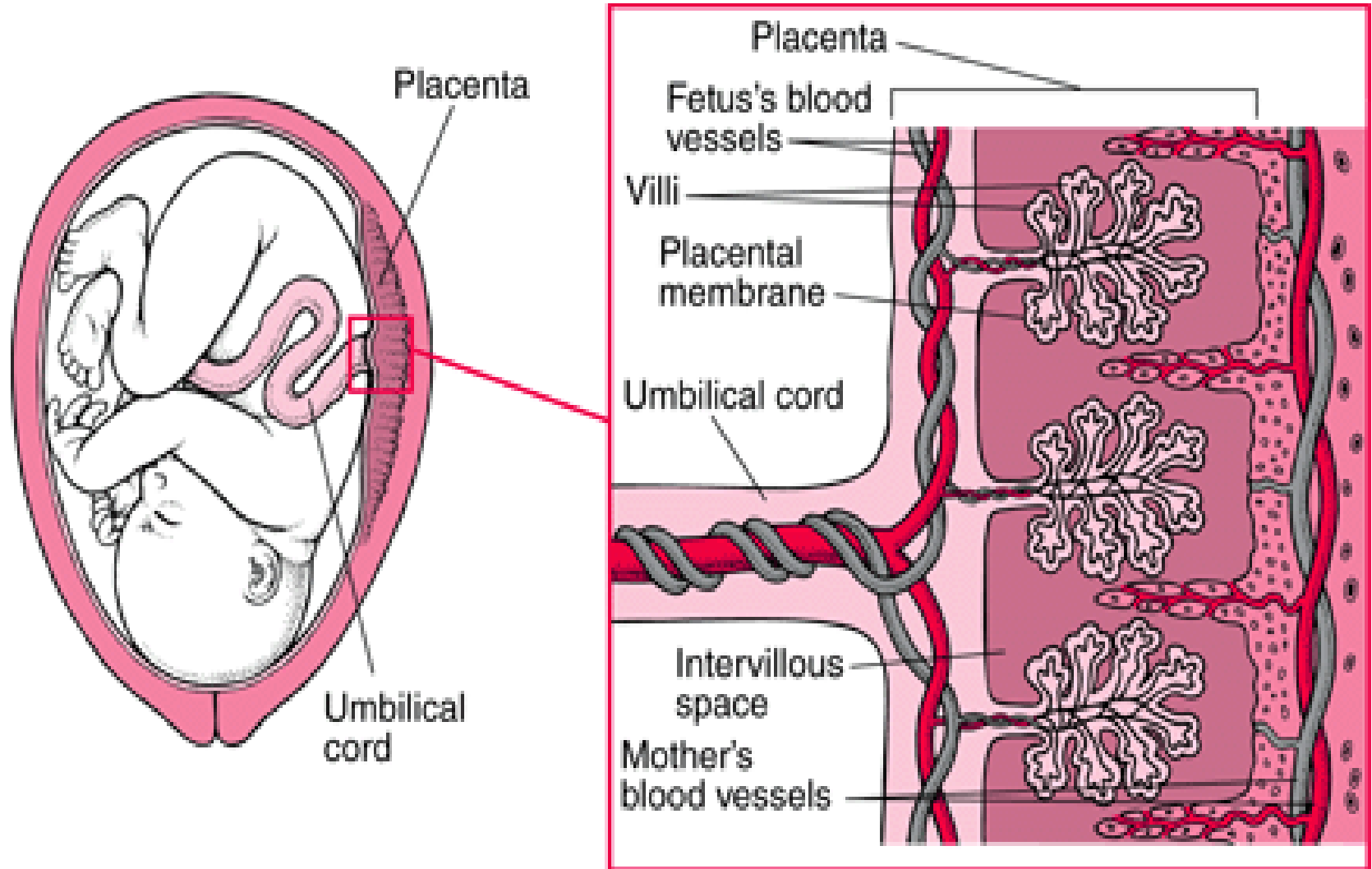
Cytotrophoblastic shell

- outer layer of trophoblast cells line the maternal surface of placenta
- slits in its surface: aa. spirales open into intervillous space



Spatium intervillosum

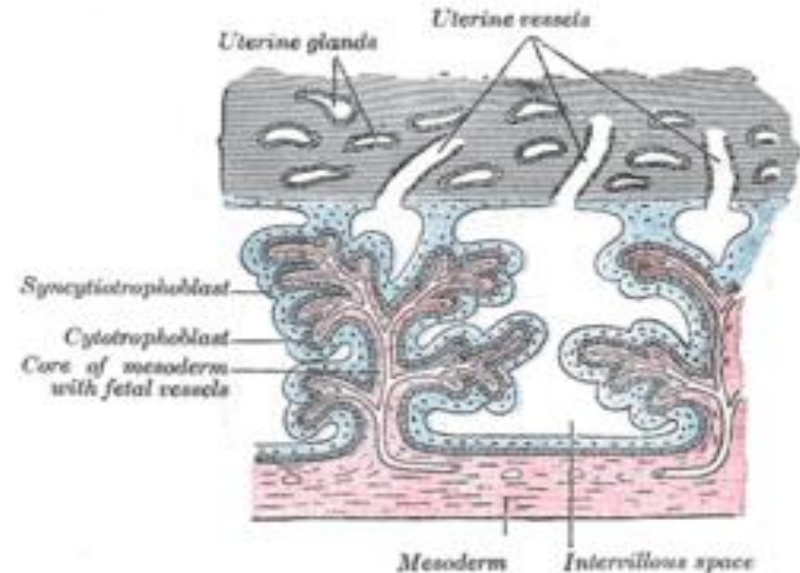
Intervillous space



Spatium intervillousum

Intervillous space

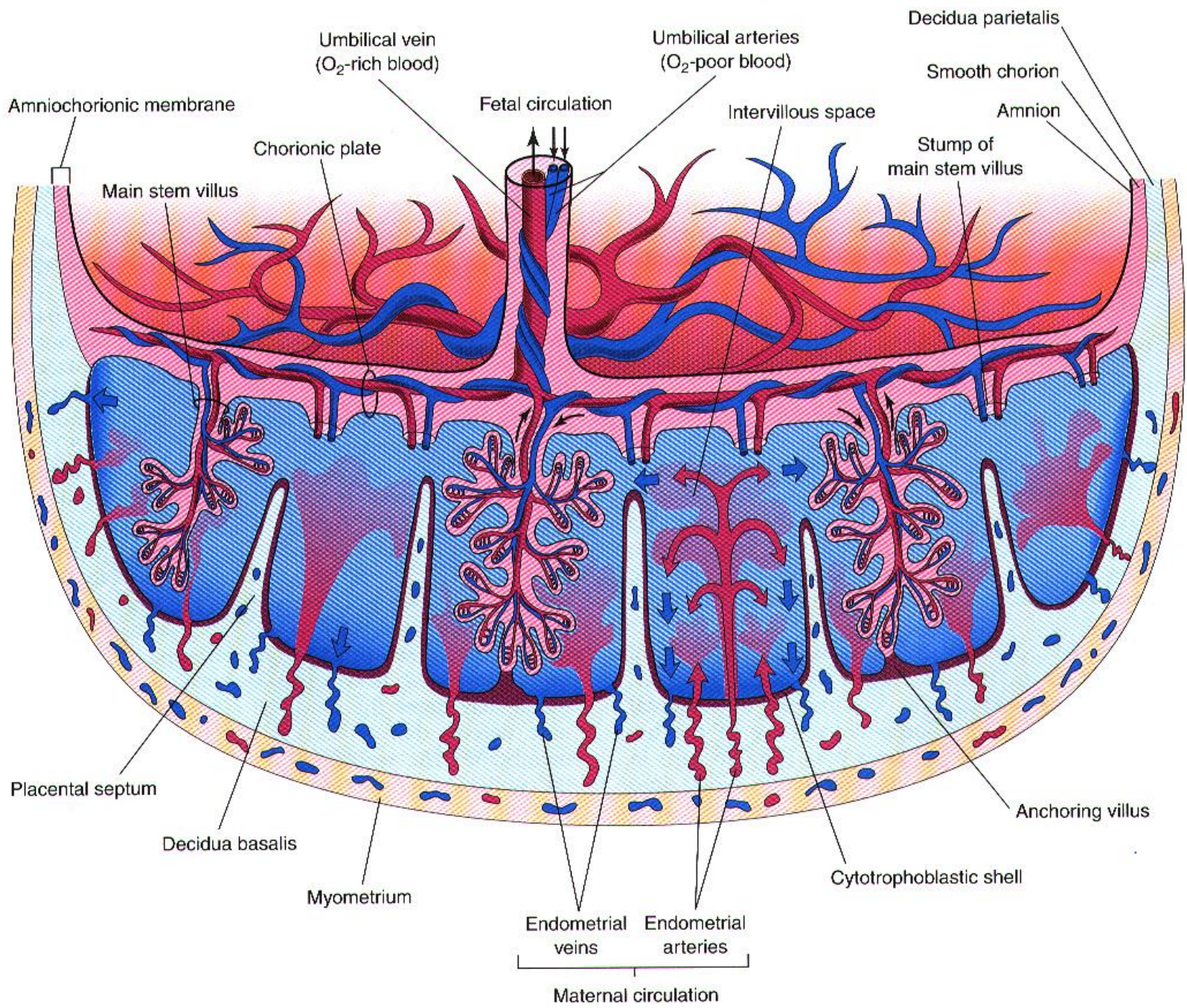
- space derived from lacunae (2nd week)
- contains maternal blood – from aa. spirales
- separation with placental septa
 - incomplete – septa do not reach chorionic plate
- villi are in immediate contact with maternal blood
- exchange of gases and nutrients



Placental membrane

- claustrum placentae
- *selective permeabile membrane*

- endothelium of fetal capillaries
- extraembryonal mesoderm
- lamina basalis subepithelialis
- cyto- + syncytiotrophoblast
- *successively reduced: mesoderm and cytotrophoblast fade out*

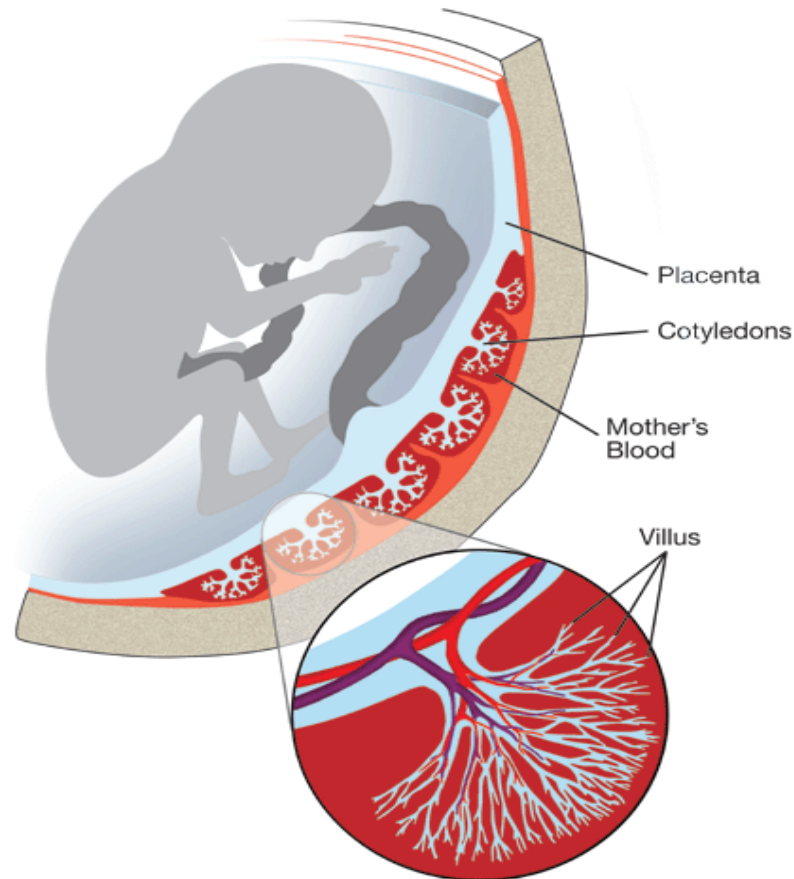


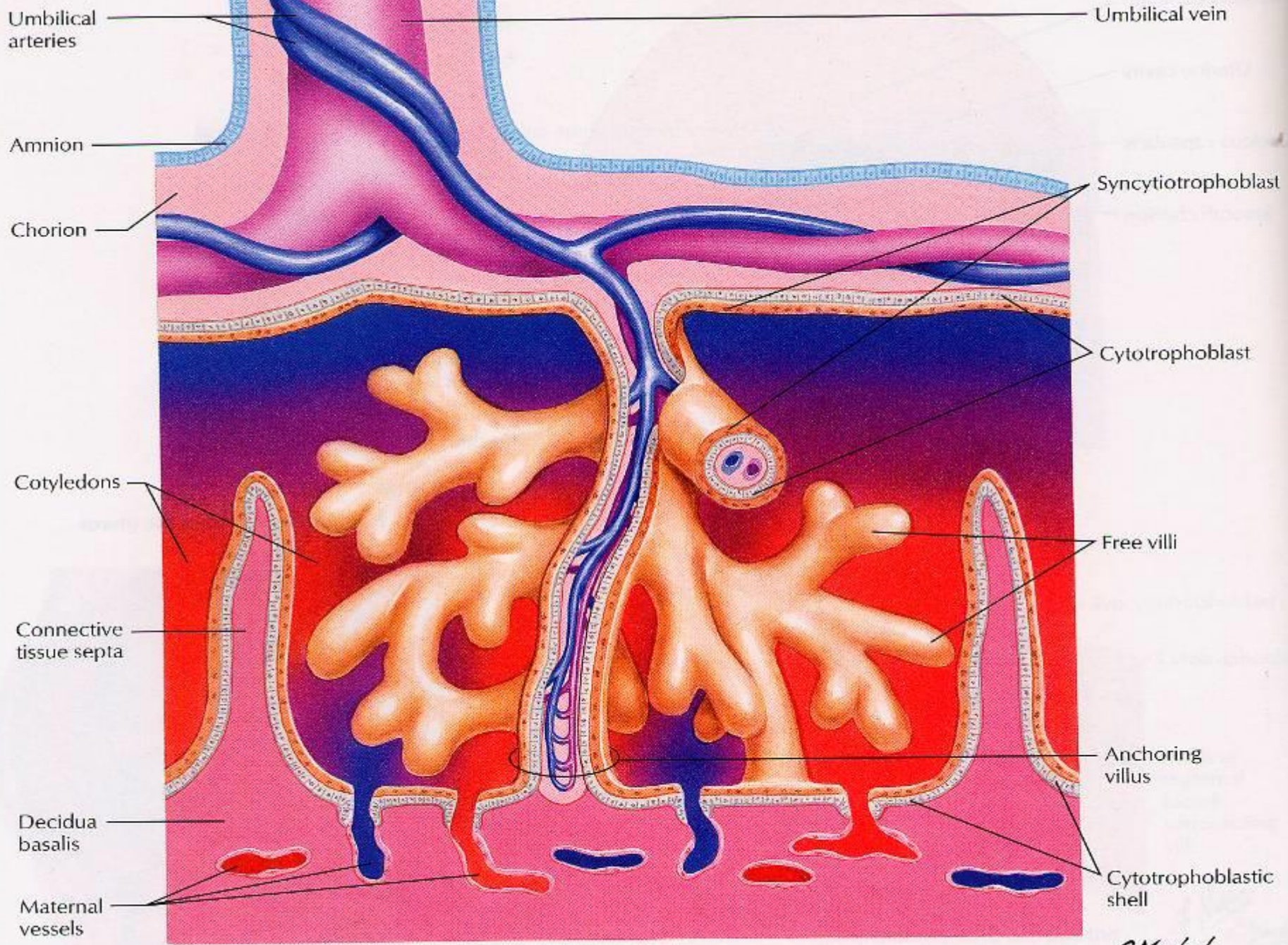
Cotyledo

- (kotyle = cup, disk)
- cotyledo /onis, f.,/ (=lobulus)
- *functional unit of placenta*
- **cotyledo maternalis (10-30) = cotyledon**
- cotyledo fetalis (40-60) = main stem villus
 - has 1 main stem villus (*villus peduncularis major = truncus chorii*) and 1 a. spiralis
 - ramified in more smaller villi (*villus peduncularis*) with one artery/arteriole and vein/venule
 - ramified in more intermediate villi (*villus intermedius*)
 - ramified in plenty of *villi terminales* (with capillary loops)

Cotyledons

- *functional unit of placenta*
- separated with placental septa
- each maternal cotyledon has 2-4 stem villi





Umbilical arteries
 Amnion
 Chorion
 Cotyledons
 Connective tissue septa
 Decidua basalis
 Maternal vessels

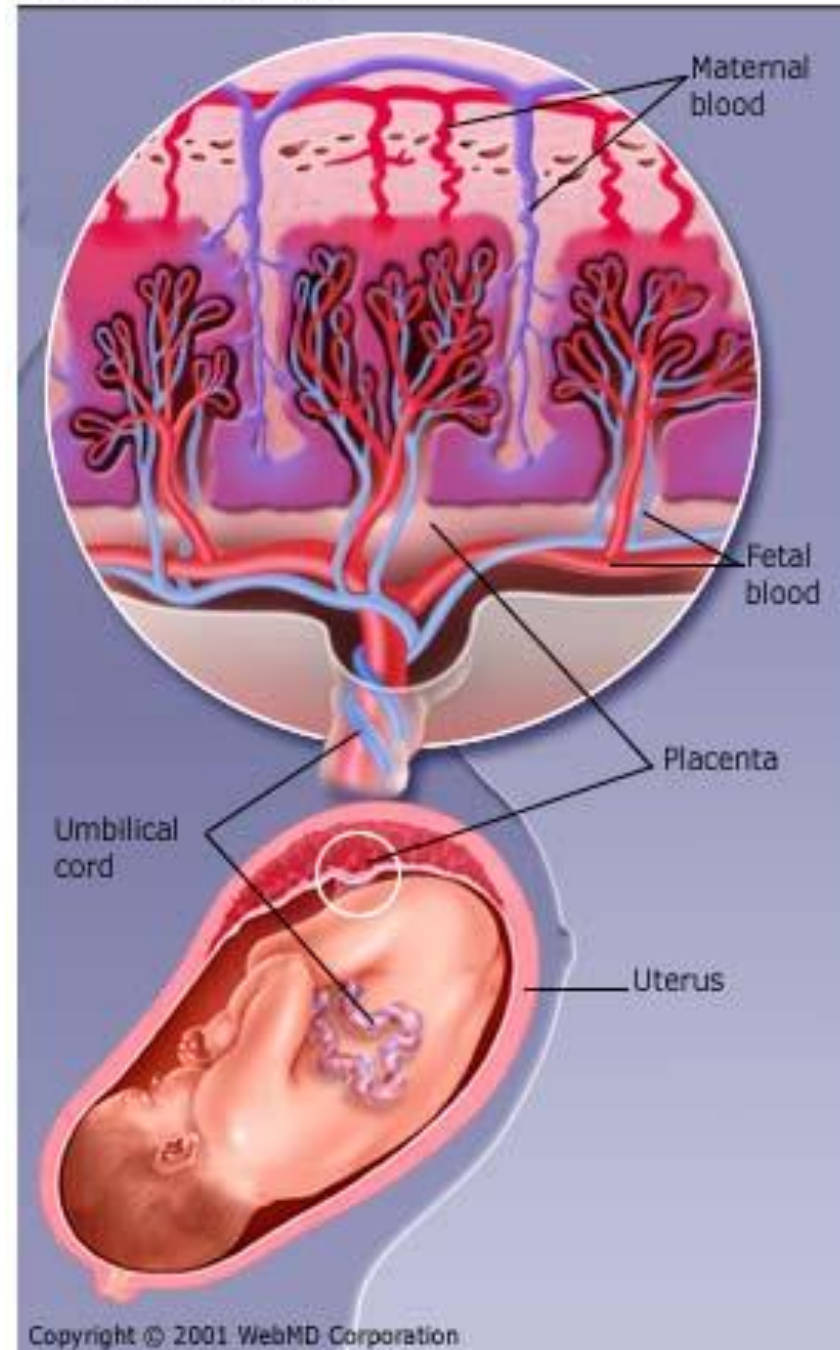
Umbilical vein
 Syncytiotrophoblast
 Cytotrophoblast
 Free villi
 Anchoring villus
 Cytotrophoblastic shell

Placental circulation

2 separated and independent systems:

- **uteroplacental**
- **fetoplacental**

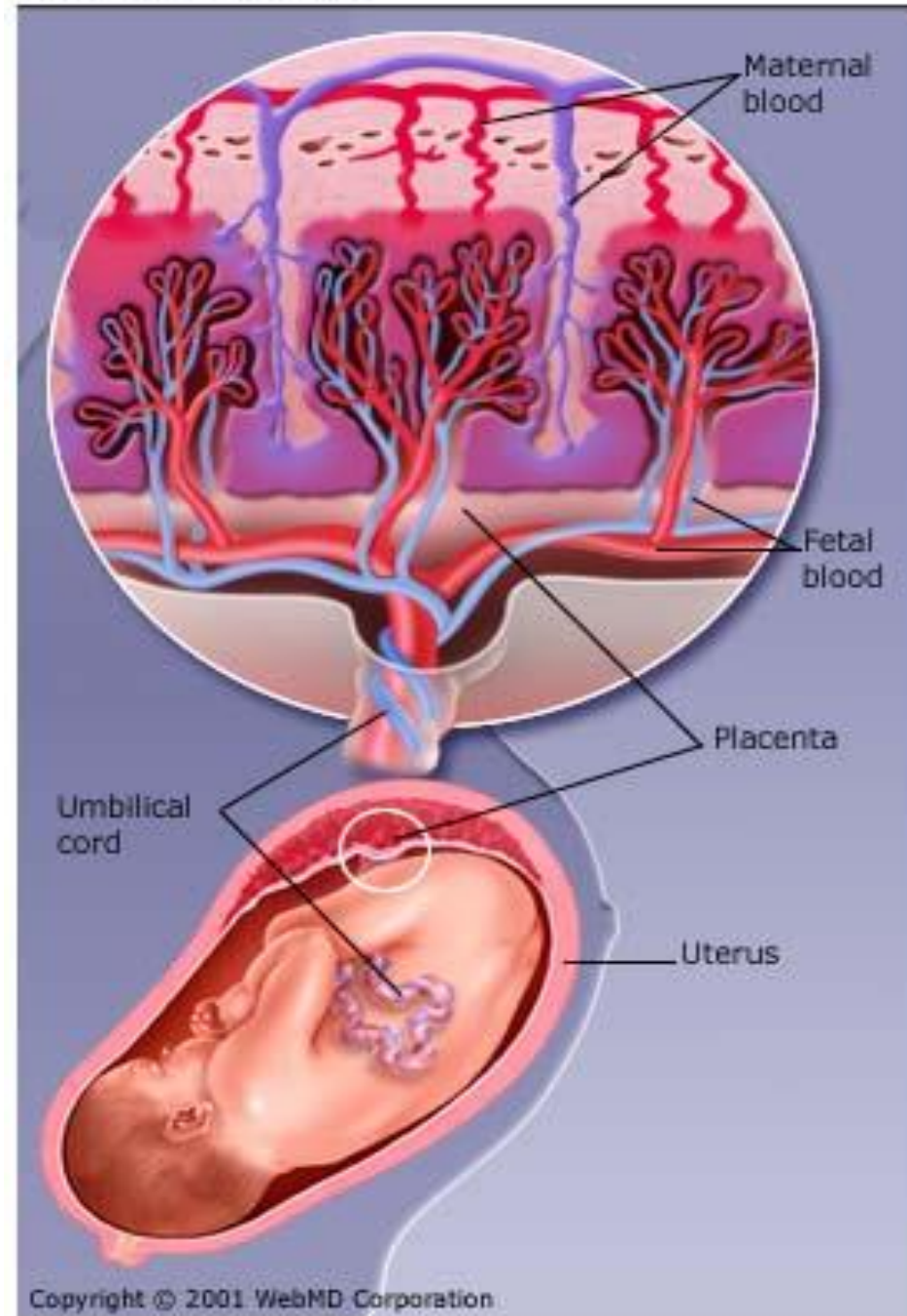
Normal Placenta



Uteroplacental circulation

- 2 aa. uterinae → 120-200 aa. spirales opening into intervillous space → vv. spirales → plexus uterinus → vv. uterinae
- volume of blood within intervillous space - 150 ml

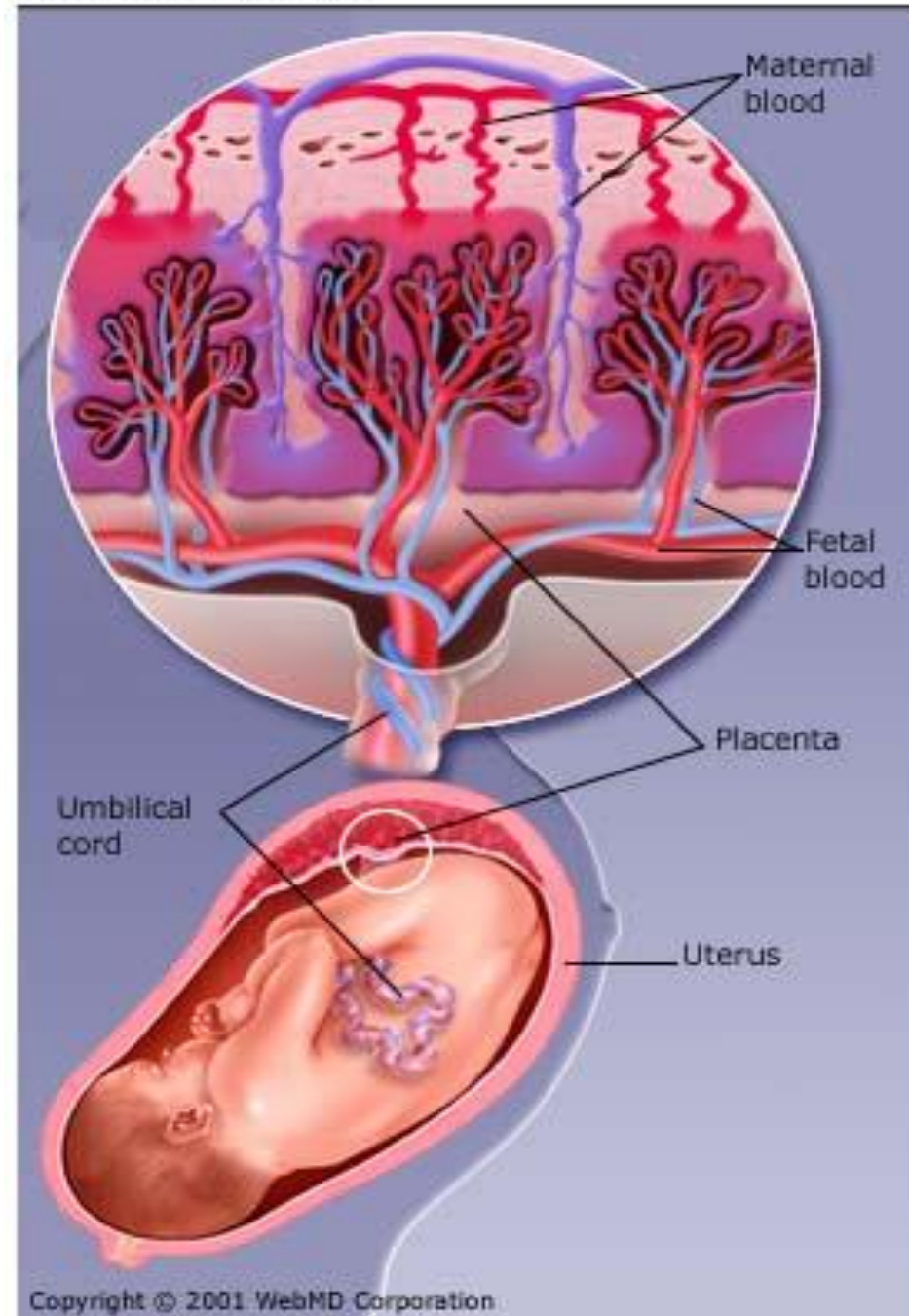
Normal Placenta



Fetoplacental circulation

- aa. iliacae internae →
2 aa. umbilicales →
chorionic arteries →
capillaries in villi →
1 v. umbilicalis →
ductus venosus →
v. cava inferior
- O₂ saturation of blood:
 - aa. umbilicales: 50-60%
 - v. umbilicalis: 70-80%
- **blood flow: 400 ml/min**

Normal Placenta



Paraplacenta

- chorion laeve
- decidua capsularis
- possible little feto-maternal exchange

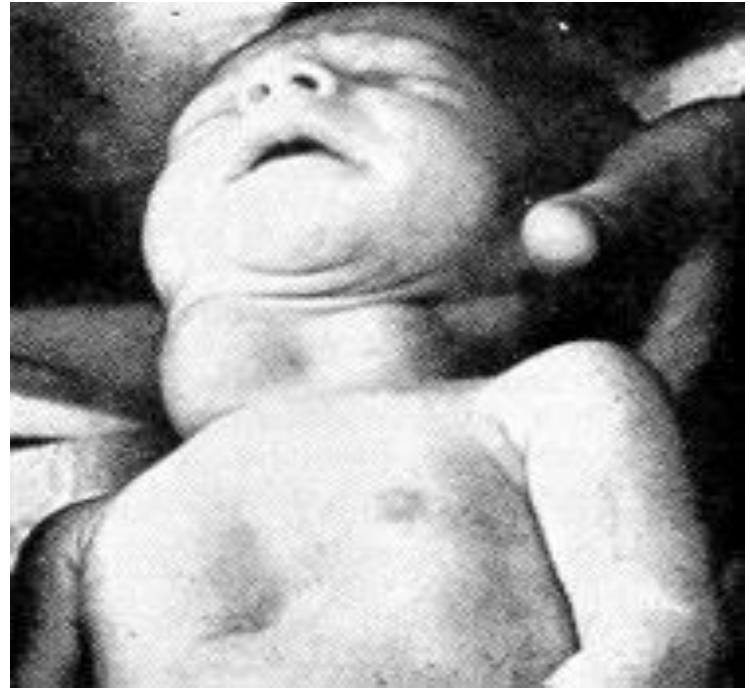Functions of placentas

- metabolic
 - synthesis of glycogen, cholesterol, fatty acids
- placental transport
- barrier between maternal and fetal blood
- passive immunity: IgG
- endocrine function
 - hCG, hPL, hCT, hCACTH + progesterone and estrogens

Substance passing placenta

- hormones
- thyroxin (T4) + T3
- testosterone
- synthetic progestines

- drugs
- fetal alcohol syndrome
 - mental retardation, lower height, facial deformities
- *not passing: heparin, IGM...*



Infection passing placenta

- **CMV** (Cytomegalovirus)
- **Rubella virus**
- **Coxsackie virus**
- **Varicella zoster virus** (virus of chickenpox and herpes zoster)
- **Poliomyelitis** (Poliovirus)
- **Spirochetes** – bacteria (e.g. syphilis – *Treponema pallidum*)
- ***Toxoplasma gondii*** (parasitic protozoan)

Developmental defects

Anomaliae membranarum fetalium

- varieties of placental site
- varieties of placental form
- varieties of umbilical cord insertion
- umbilical cord anomalies
- amniotic fluid anomalies
- placental separation anomalies

Varieties of placental site

Varietates situs placentae

- Situs dorsalis placentae
- Situs lateralis placentae
- Situs ventralis placentae
- Situs fundalis placentae
- Situs cornualis placentae

- **Placenta praevia**
- Placenta praevia centralis
- Placenta praevia lateralis
- Placenta praevia marginalis
- Situs cervicalis placentae

Varieties of placental form

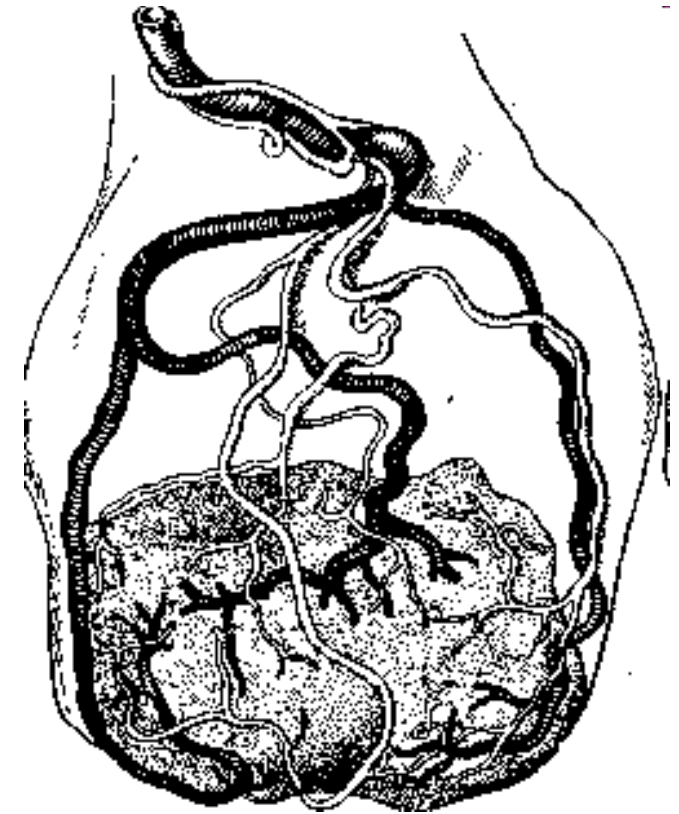
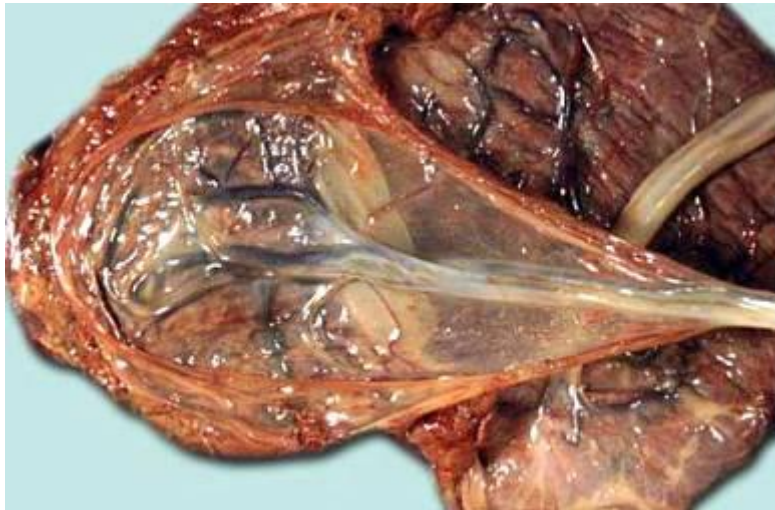
Formae placentae

- placenta discoidea
- placenta accessoria; placenta succenturiata
- placenta anularis
- placenta lobata
- placenta bilobata; placenta bipartita
- placenta trilobata
- placenta multilobata
- placenta membranacea
- placenta vallata; placenta circumvallata

Varieties of umbilical cord insertion

Varietates insertionis funiculi umbilicalis

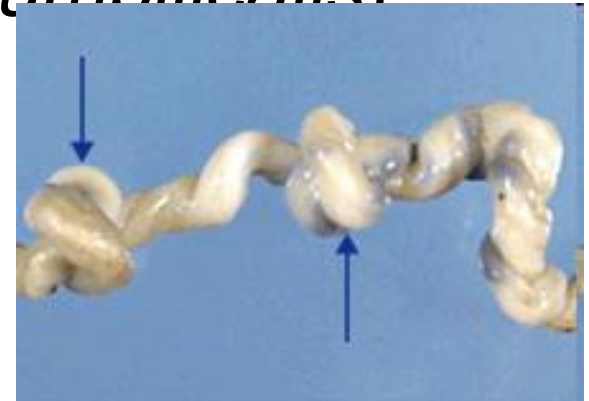- insertio centralis
- insertio marginalis
- insertio velamentosa



Umbilical cord anomalies

Anomaliae funiculi umbilicalis

- *a. umbilicalis singularis*
- looped umbilical cord (*funiculus umbilicalis glomeratus*)
- *strangulatio*
- *amputatio*
- false node (*nodus spurius funiculi umbilicalis*)
- true node (*nodus verus funiculi umbilicalis*)
- *vesicula allantoica*



Amniotic and amniotic fluid anomalies

Anomaliae amnii et liquoris amniotici

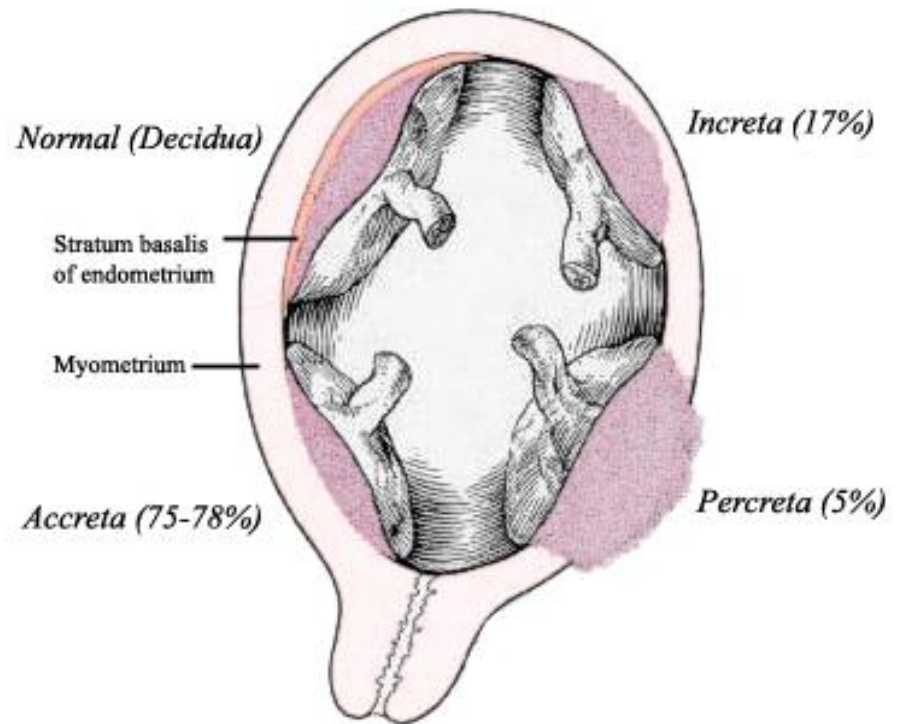
- Oligohydroamnion
 - premature rupture of amniochorionic membrane
 - agenesis of kidneys → no urine excretion
- Polyhydramnion
 - atresia oesophagei → insufficient resorption
 - grave developmental defects of neural tube
- Adhaesio amnii
- Taenia amniotica

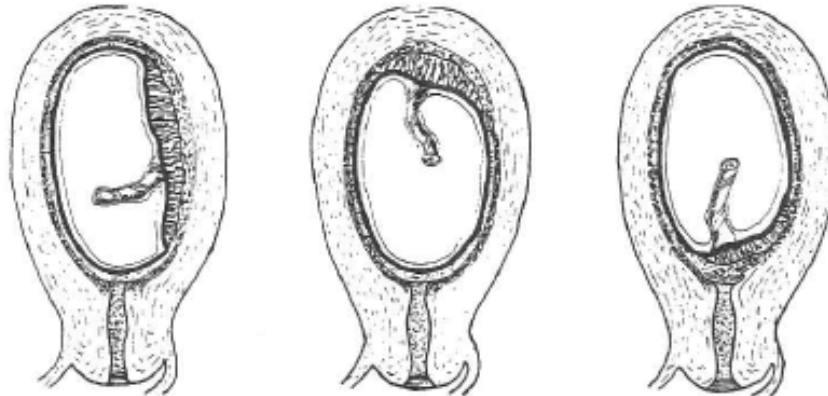
Developmental defects of placental separation

Anomaliae placentae

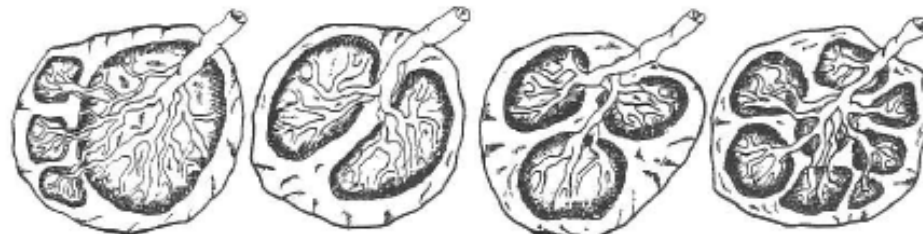- placenta adhaerens
- placenta accreta
- placenta increta
- placenta percreta

- placenta extrachorialis
- placenta fenestrata
- placenta incarcerata
- placenta panduriformis

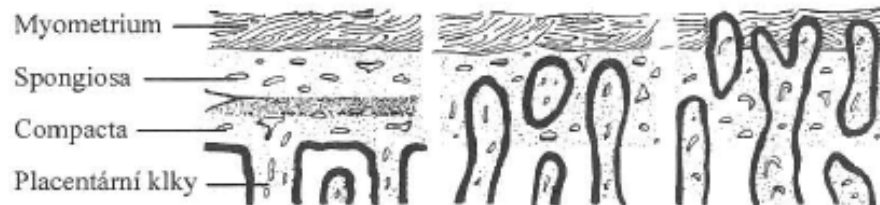



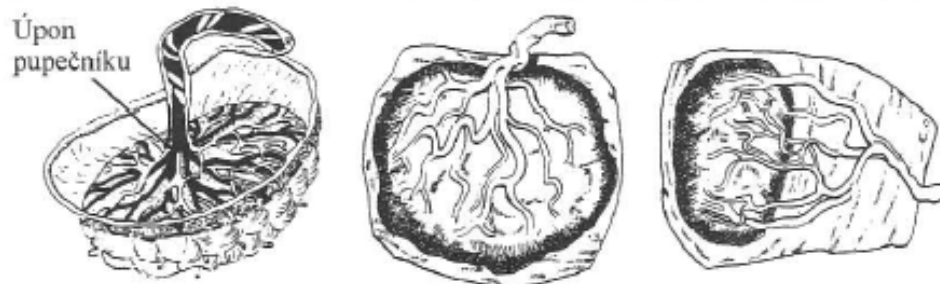
Umístění: Běžné Na fundu Placenta praevia



Počet: Placentae succenturiatae Bipartita (duplex) Tripartita Multilobata



Uchytení: Normální Placenta accreta Placenta increta



Insertio: Centralis Marginalis Velamentosa

First birth (labour) stage dilation

- begins when contractions are more frequent than 10 minutes
- ends with total dilation of cervix uteri
- *longest stage*
- length depends on number of deliveries (nullipara / multipara)

Second birth (labour) stage fetal expulsion

- begins with total dilation of cervix uteri
- ends with expulsion of child

- multipara - 20 min
- nullipara - 50 min

Third birth (labour) stage delivery of placenta

- begins with expulsion of child
- duration: approximately 15 min
- **ends with expulsion of placenta and fetal membranes**

- separation is maintained with compression of abdomen
- placenta + membranes = *secundinae*

Fourth birth (labour) stage

- **begins with expulsion of placenta and membranes**
- duration: approximately 2 hours
- ends with constriction of aa. spirales uteri

Multiple birth

twins 1 % (0,85 %)

triplets 0,01 % (100x less)

IVF – different !

Multiple birth

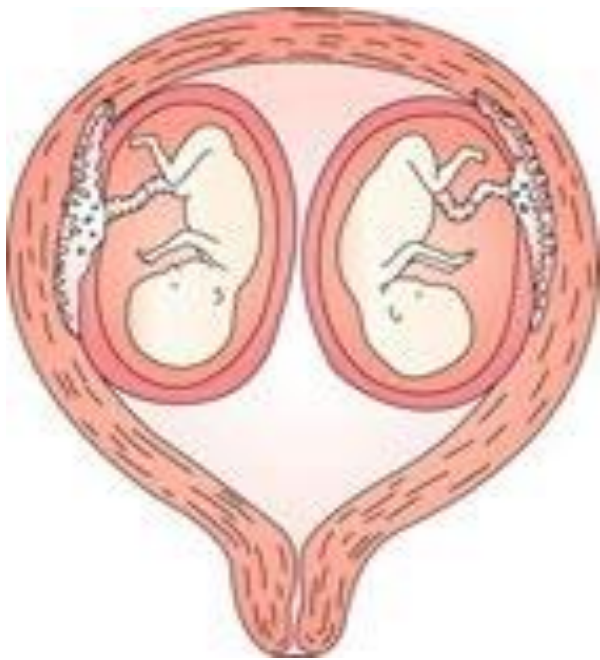
- **Dizygotic twins**
 - 2/3 of all twins
 - fertilization from 2 male and 2 female gametes
 - 2 zygotes develop
 - 2 amnion and 2 chorion
 - different phenotype, possibly different sex
- **Monozygotic twins**
 - fertilization of 1 ovum
 - always identical sex and phenotype
 - depending on time of twins separation → different stage of membranes separation

Twins (*Gemini*)

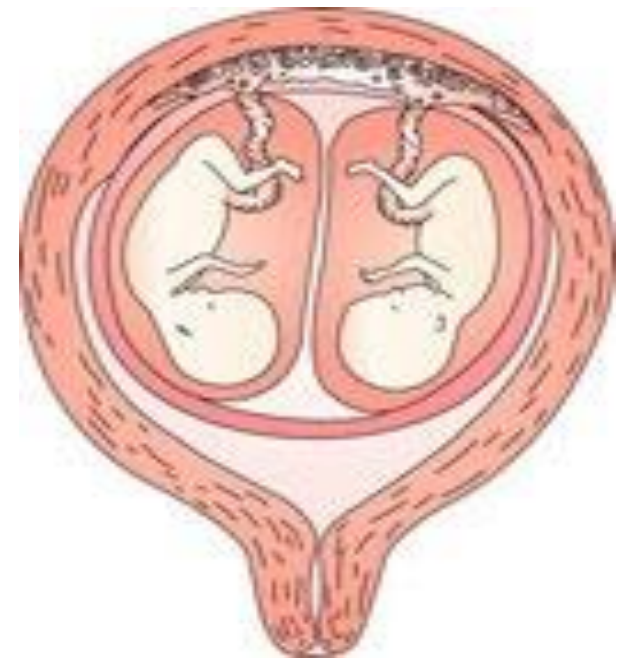
- dichorionic x monochorionic
- diamniotic x monoamniotic
- siam twins



Origin

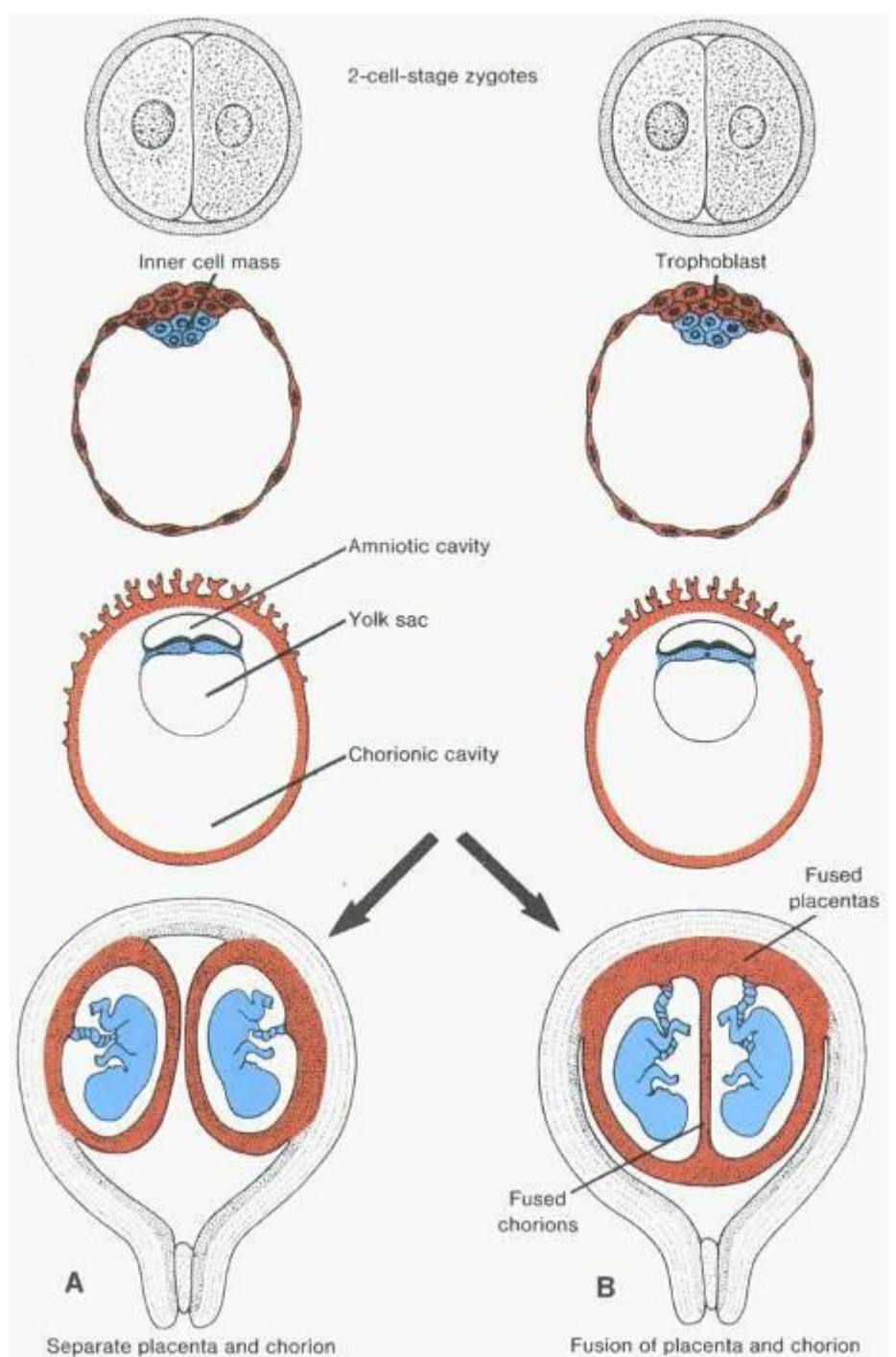


- from 2 zygote = **dizygotic twins**
- **always** 2 amnia + 2 choria

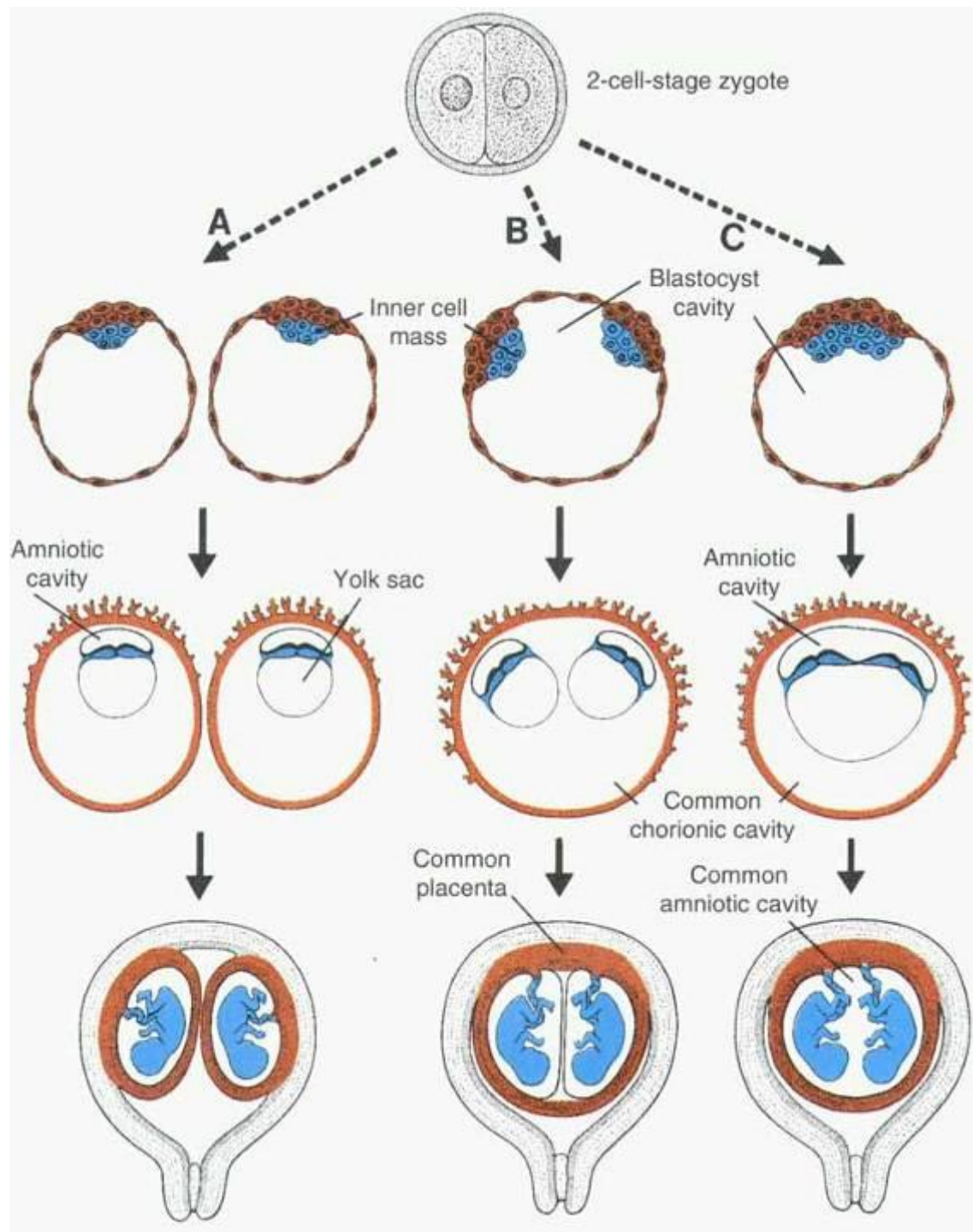


- from 1 zygote = **monozygotic twins**)
- always identical sex and genom

Dizygotic twins



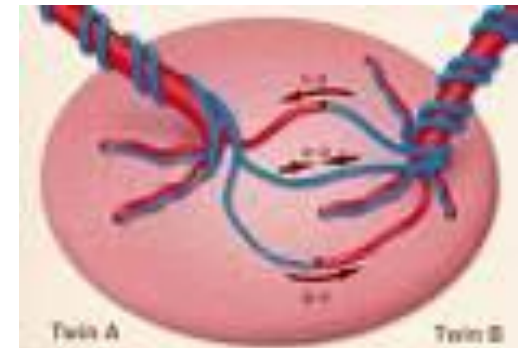
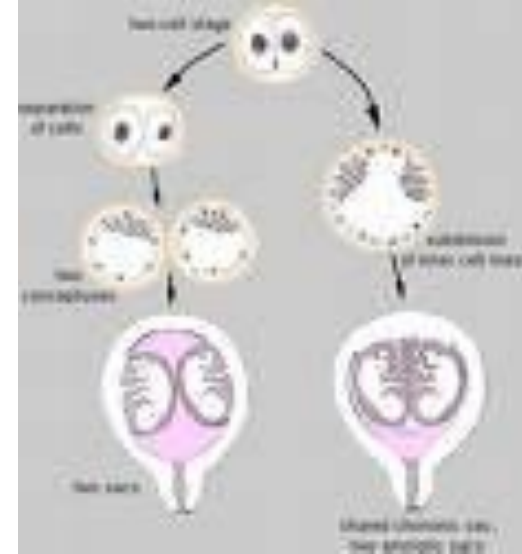
Monozygotic twins



Monozygotic twins

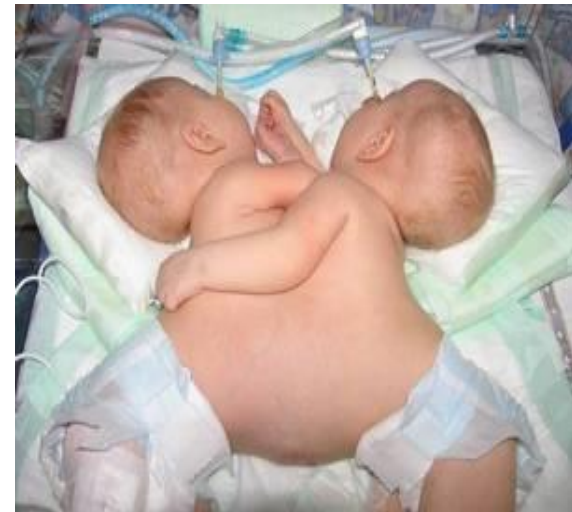duplication:

- during **2-8-cell stage**
 - each has its own amnion, chorion, placenta
= *biamniati, bichoriati*
- during **blastocystogenesis**
 - each has its own amnion, but they share chorion and placenta =
biamniati, monochoriati
 - *danger of restriction of growth of one twin owing to preferred twin in blood supply!*
- during **totogenesis**
 - shared amnion, chorion, placenta
= *monoamniati, monochoriati*
 - *danger of conjoined twins*

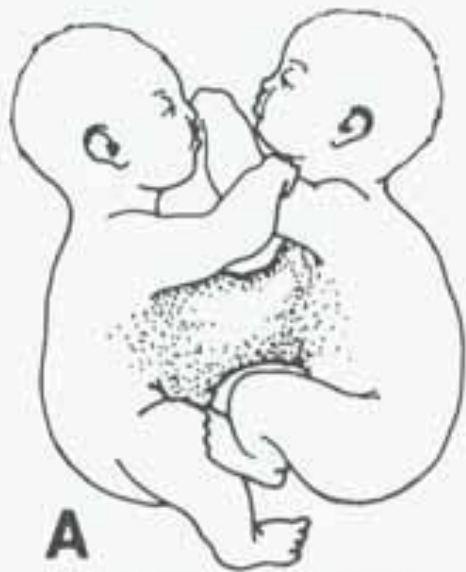

Monoamniati

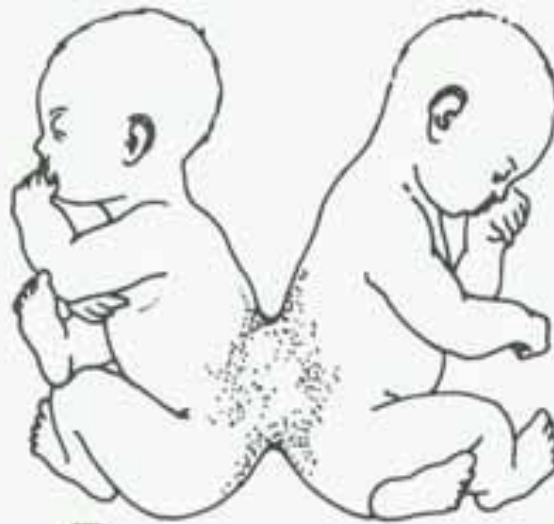- danger of incomplete division of embryoblast → conjoined twins
- symmetrical
 - thoracopagus
 - craniopagus
 - dicephalus
 - dipygus
- asymmetrical (parasitic twin)
 - thoracopagus parasiticus, ...



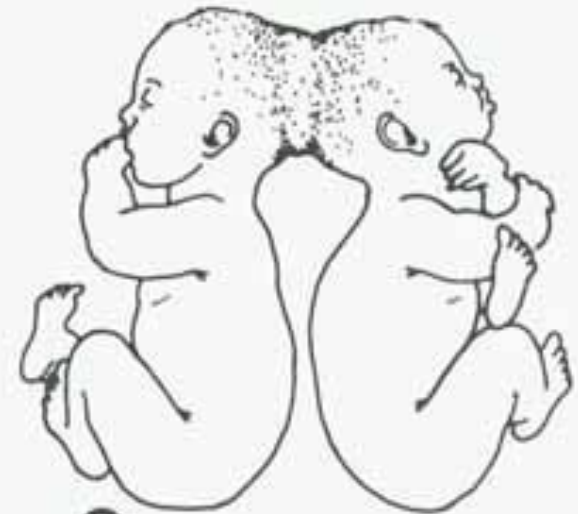Symmetric conjoined twins „siamese“



Thoracopagus



Pygopagus

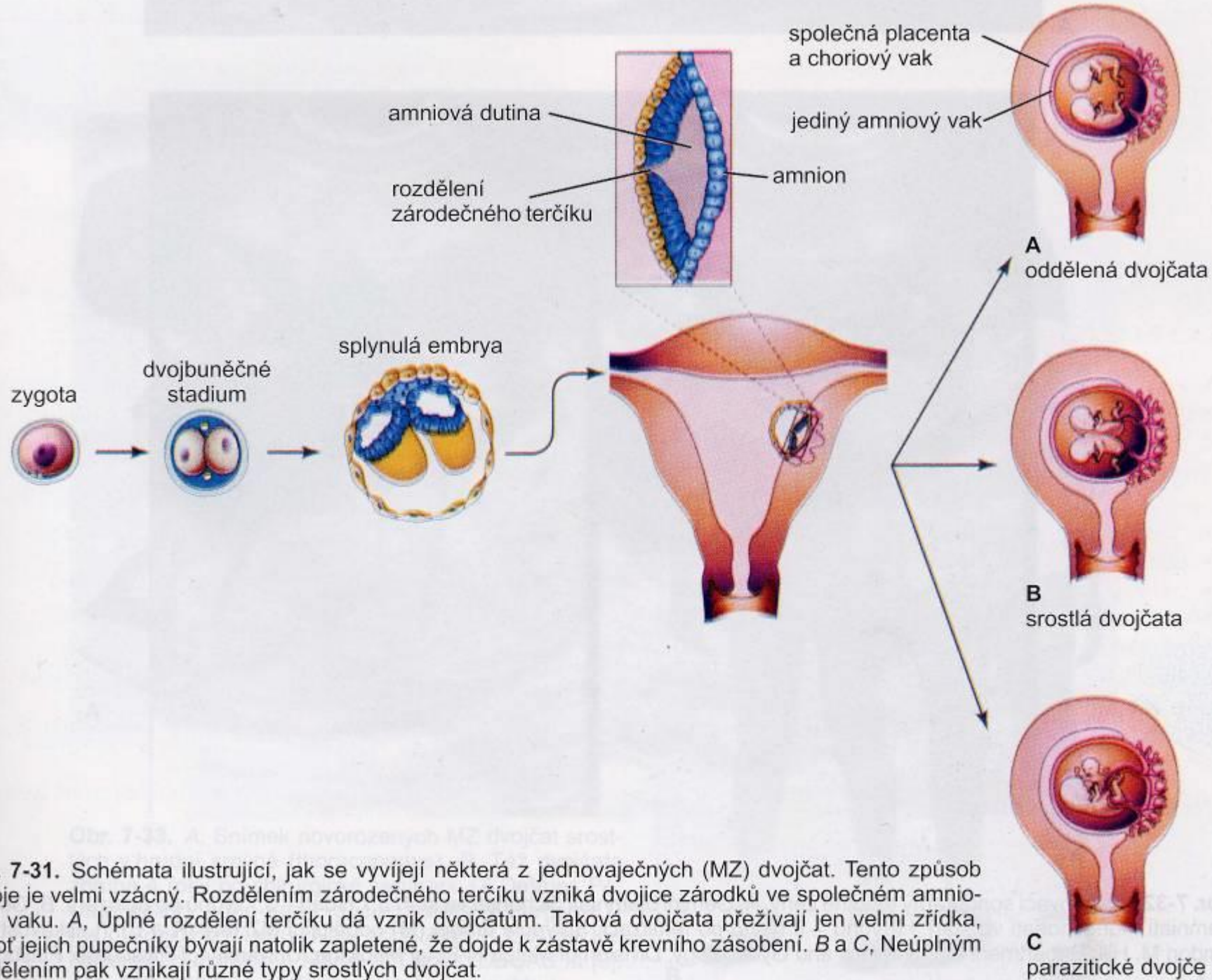


Craniopagus

Figure 7.15. Thoracopagus, pygopagus, and craniopagus twins. Conjoined twins can be separated only if they have no vital parts in common.

Clinical consequences of wrong placentation

- defects in fetus growth
- preeclampsia (EPH gestosis)
 - 4-8 % pregnancies
 - EPH (oedema, proteinuria, hypertension)
 - **hypertension** (>140/90)
 - **proteinuria** (0,5 g/24 hours)
 - **oedema**
- eclampsia - cramps
- premature separation of placenta (abruption) → silent death of fetus



Obr. 7-31. Schémata ilustrující, jak se vyvíjejí některá z jednovaječných (MZ) dvojčat. Tento způsob vývoje je velmi vzácný. Rozdělením zárodečného terčíku vzniká dvojice zárodků ve společném amniotickém vaku. **A**, Úplné rozdělení terčíku dá vznik dvojčatům. Taková dvojčata přežívají jen velmi zřídka, neboť jejich pupečníky bývají natolik zapletené, že dojde k zástavě krevního zásobení. **B** a **C**, Neúplným rozdělením pak vznikají různé typy srostlých dvojčat.

Signs of maturity of newborn

- weight - approximately 3000 g
- length - approximately 50 cm
- skin - pink
- nails extend beyond finger tips
- in male: testis are in scrotum
- in female: labia majora cover labia minora
- sucking reflex present
- bones of skull are hard
- grooves of skin in palm and sole