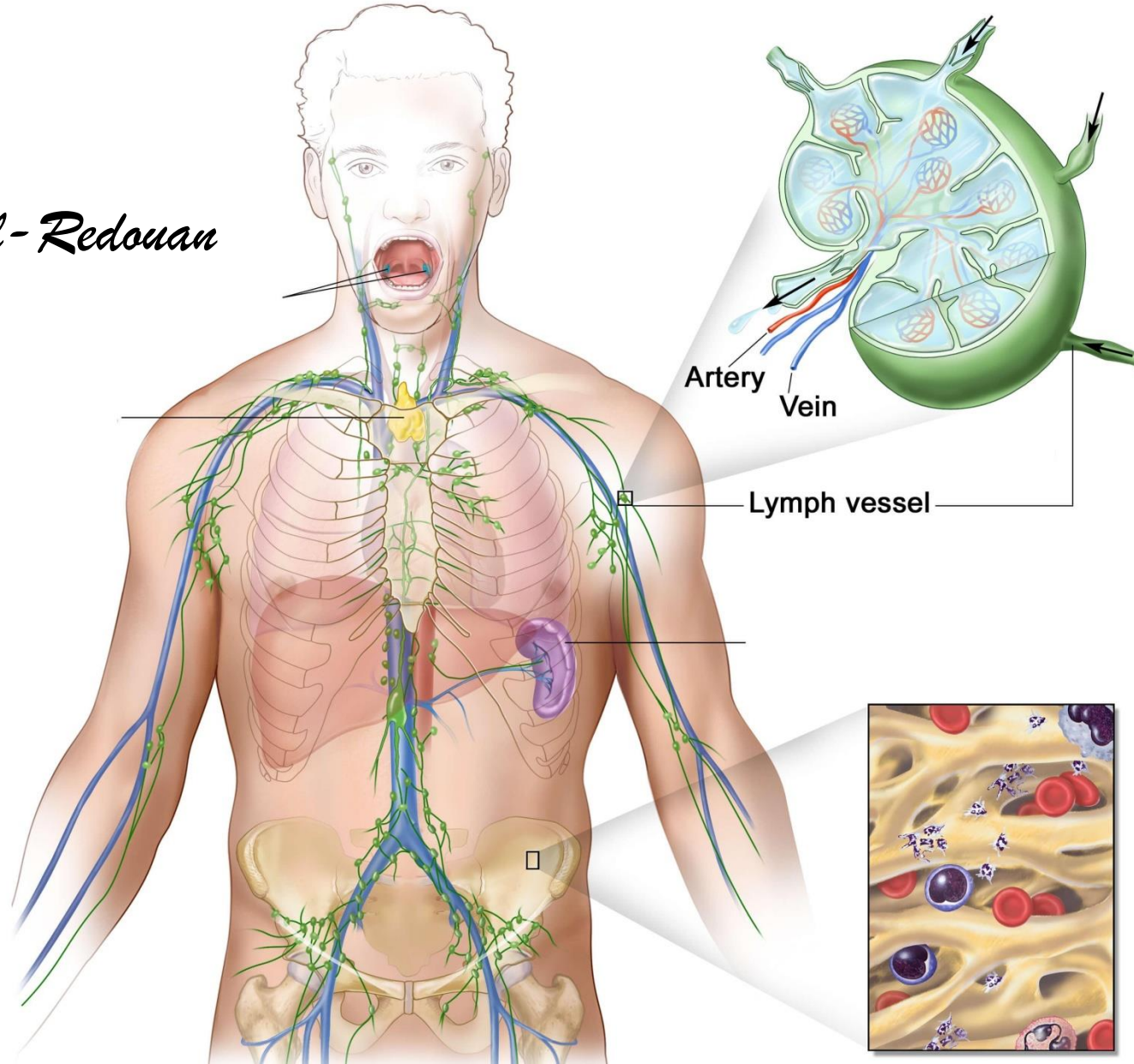


LYMPHATIC SYSTEM

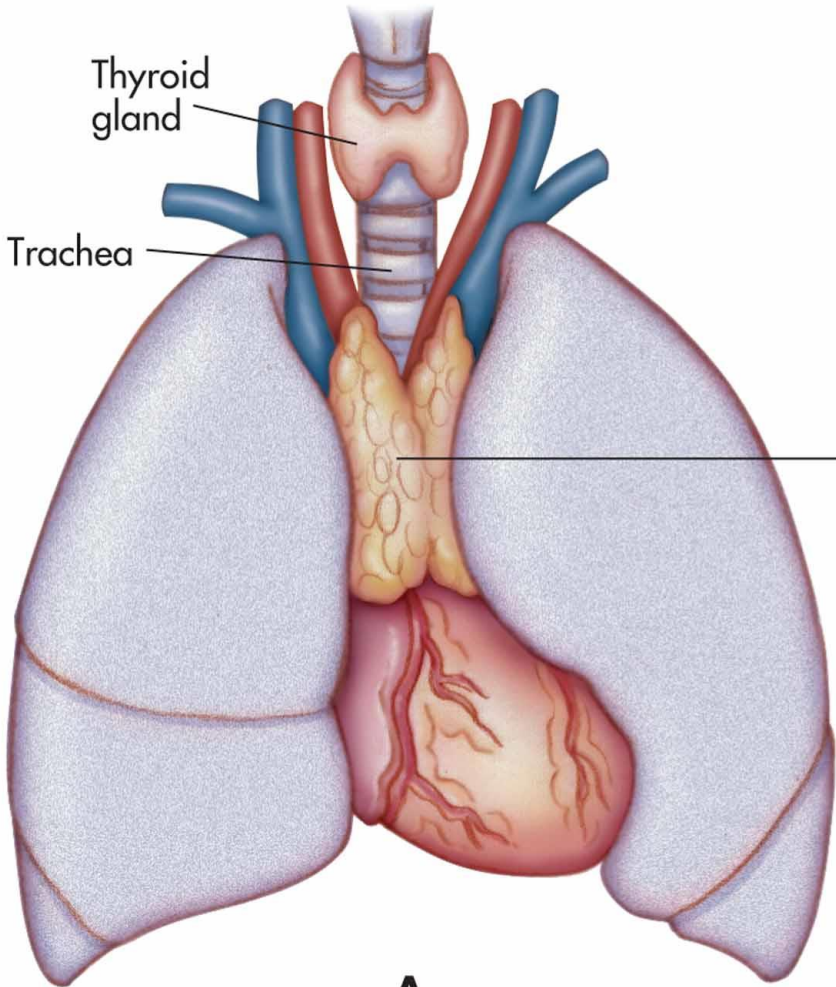
MUDr. Azzat Al-Redouan

Jan.2022

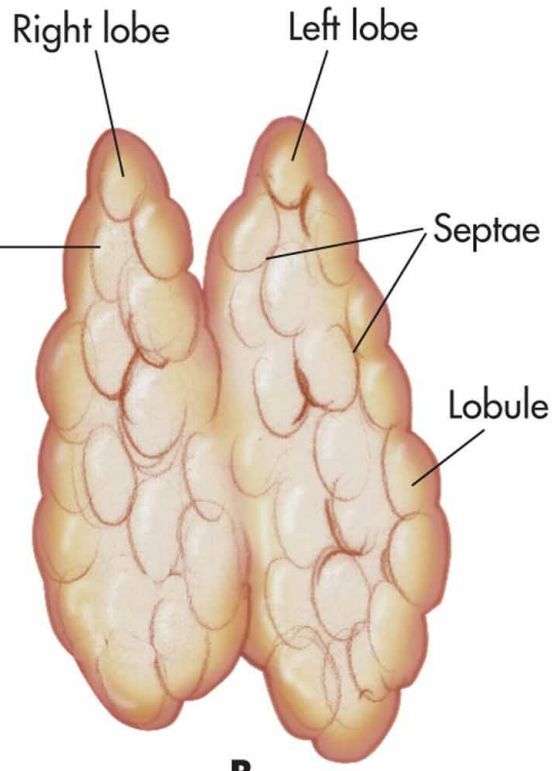


Organs

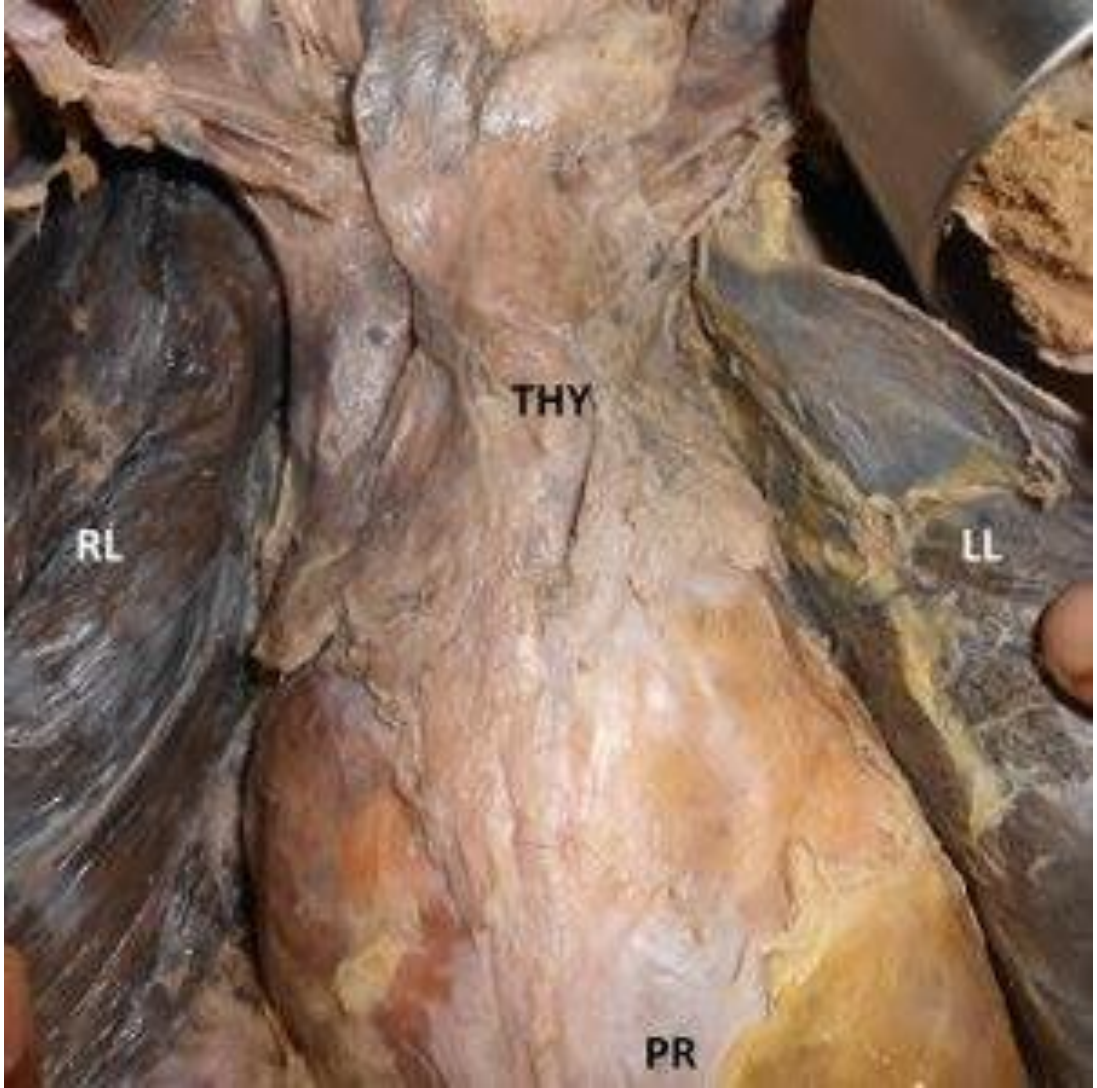
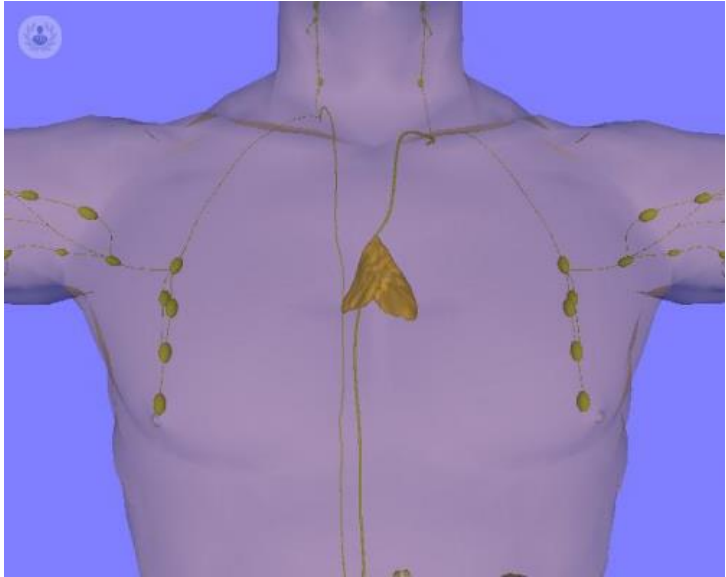
Thymus



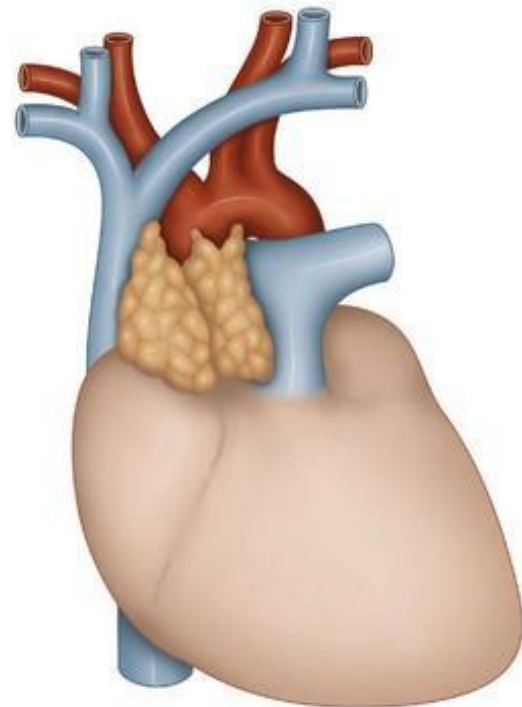
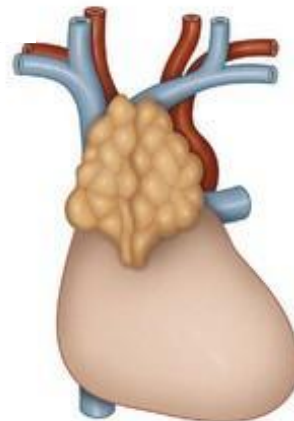
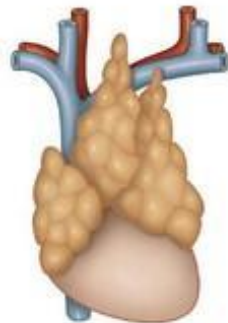
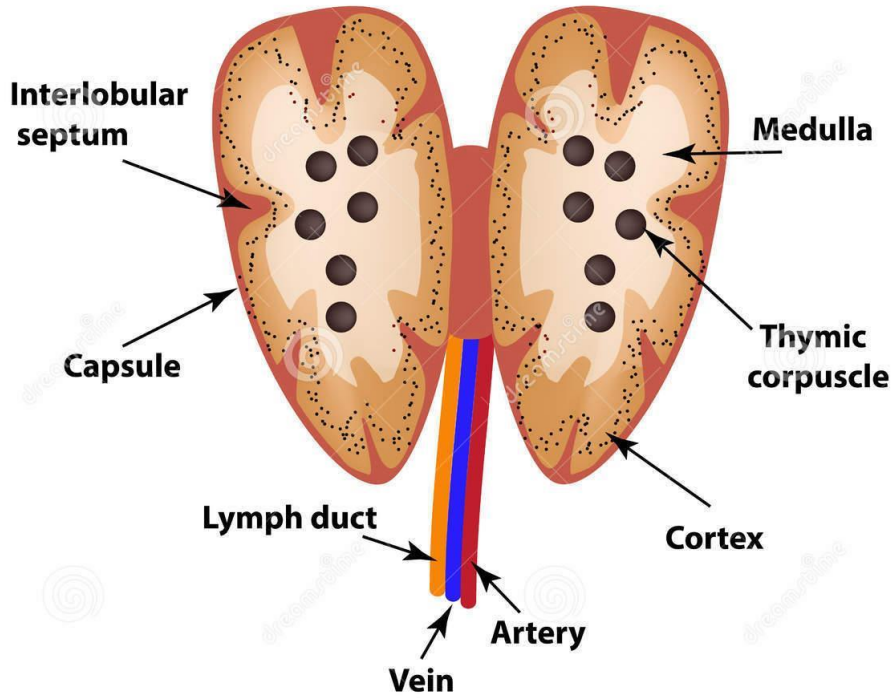
A

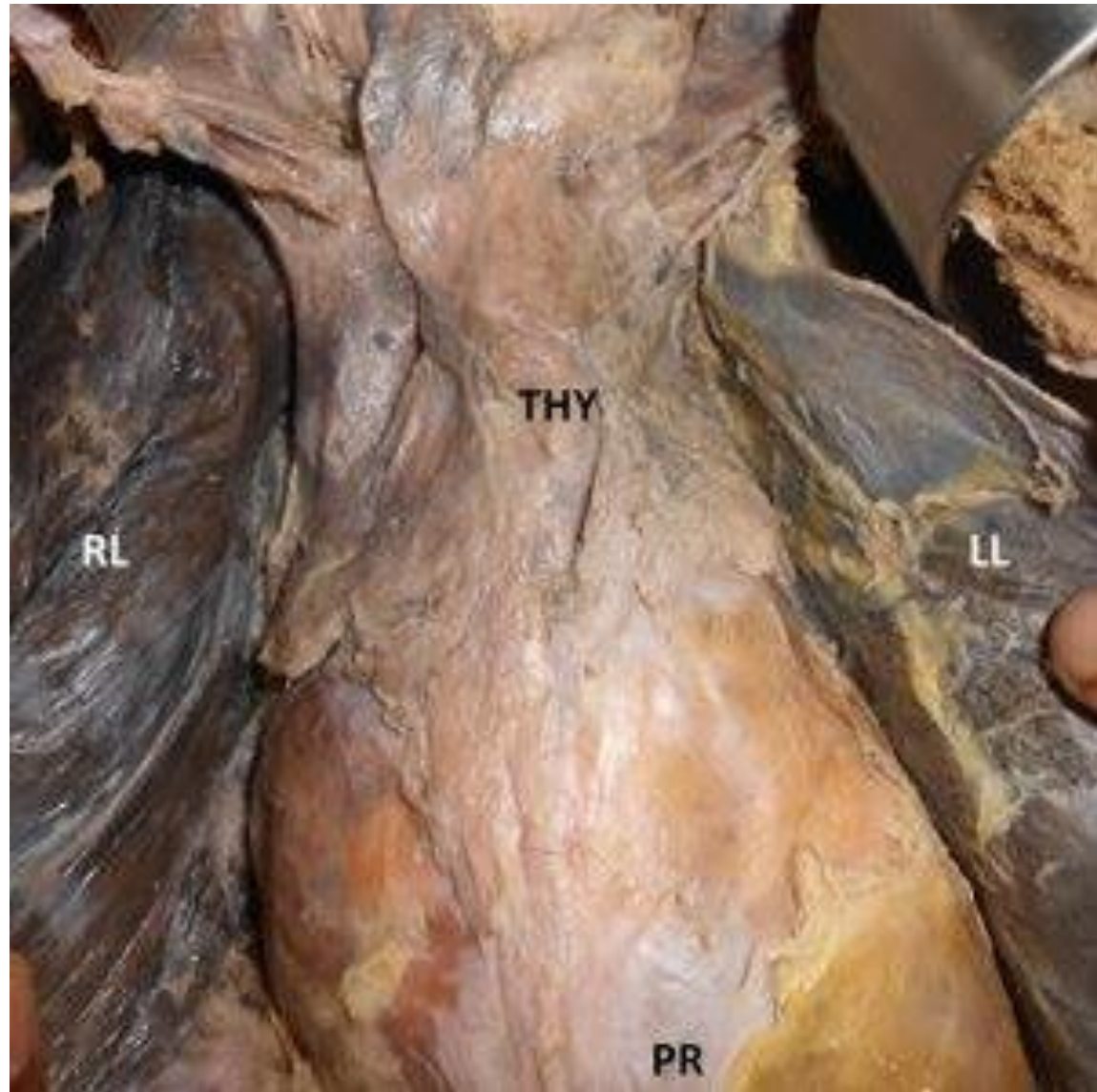
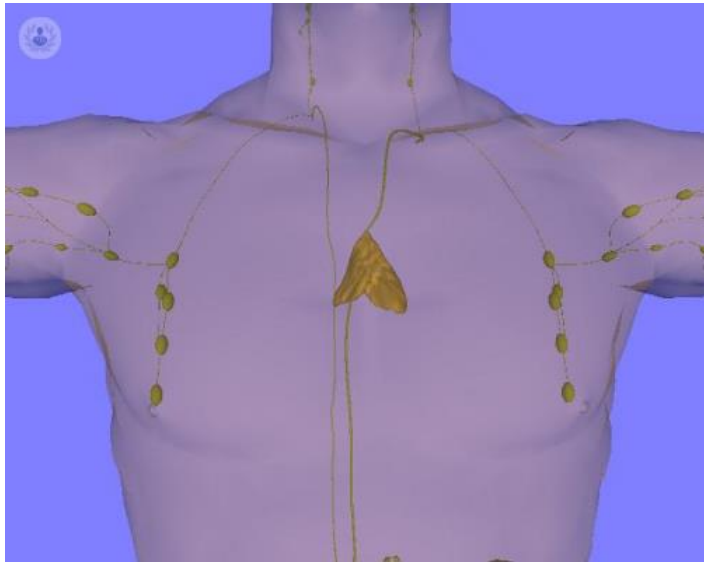


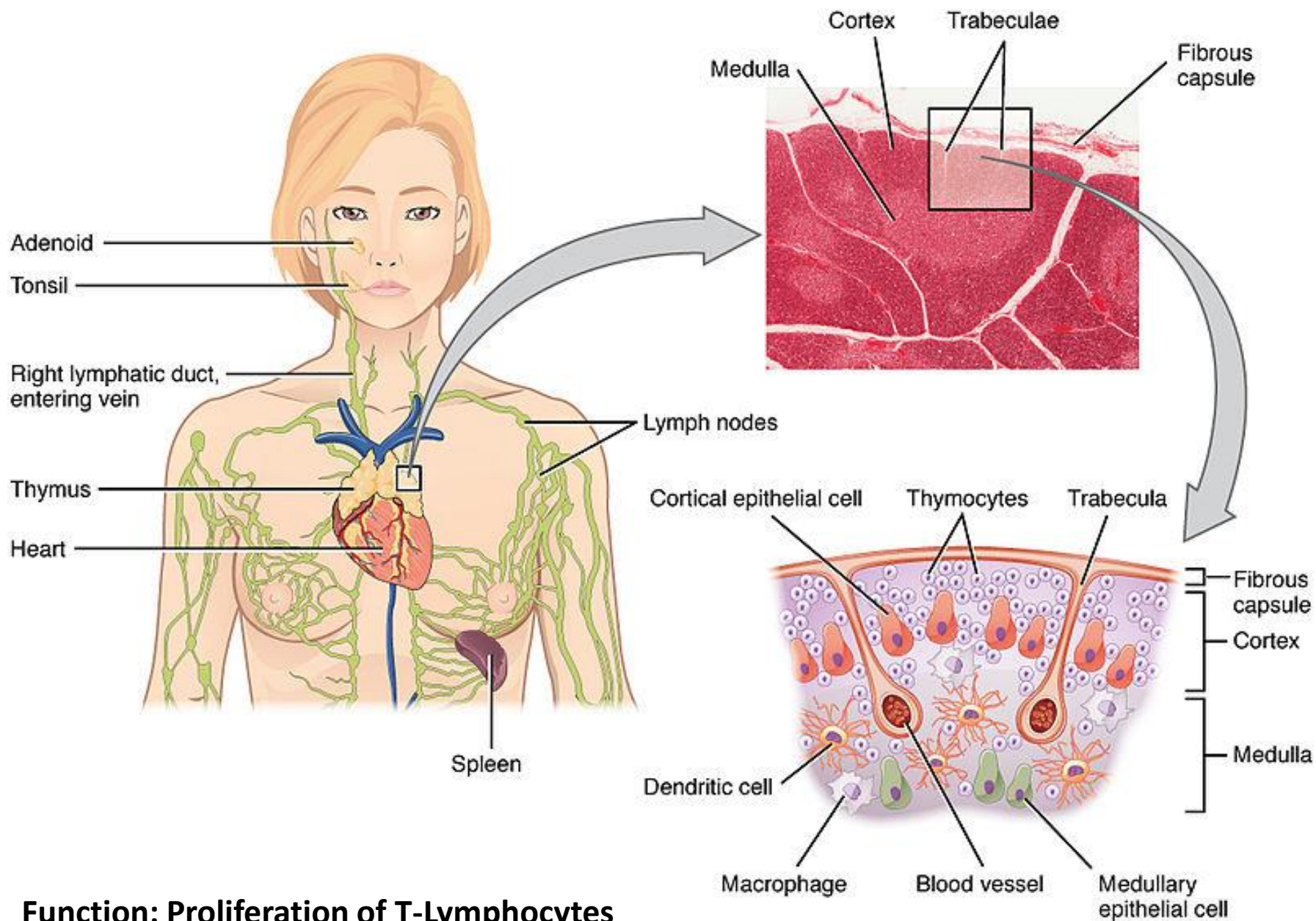
B



STRUCTURE OF THE THYMUS

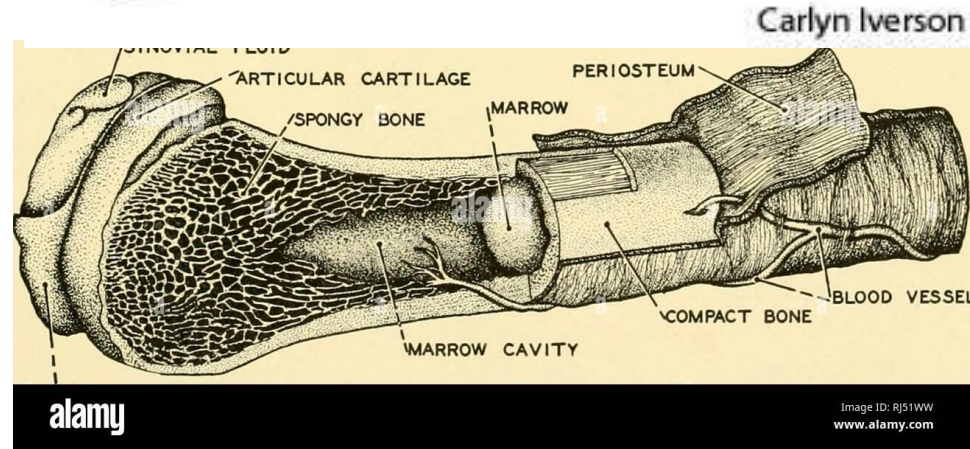
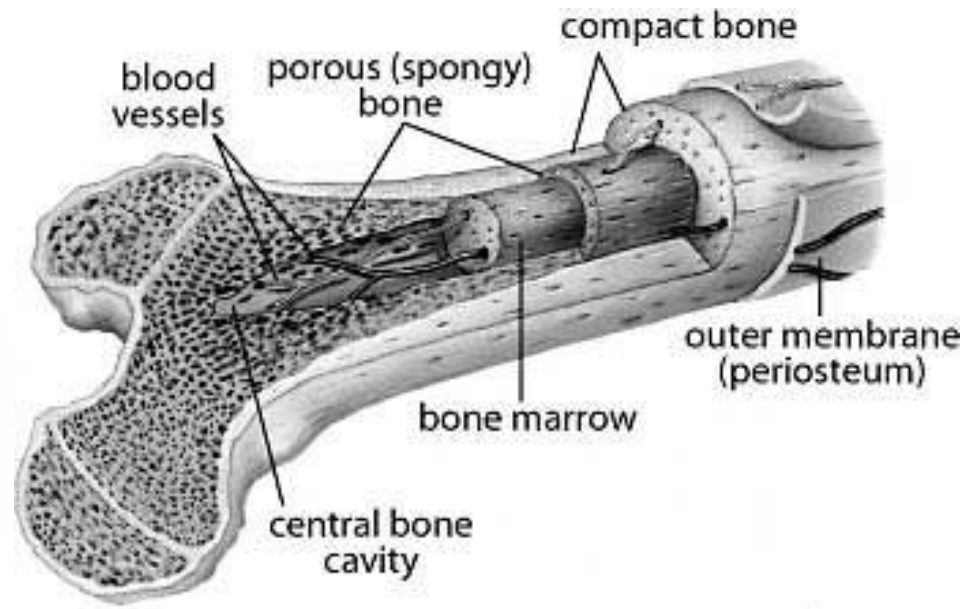
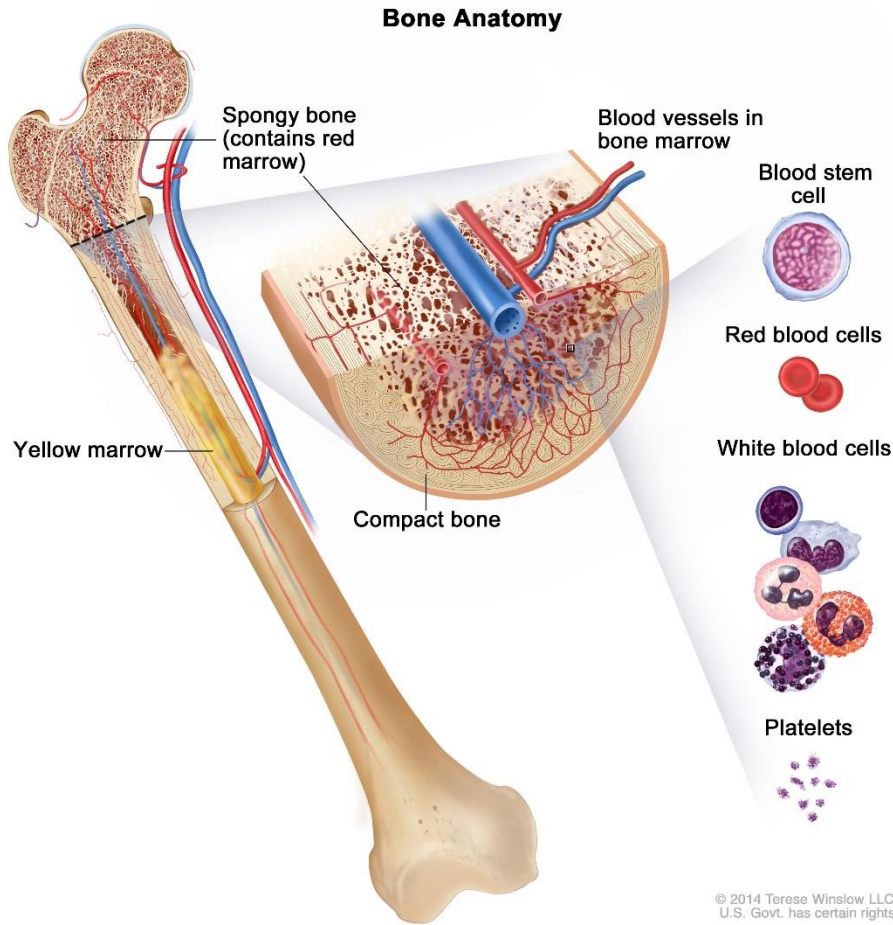






Function: Proliferation of T-Lymphocytes

Bone Marrow

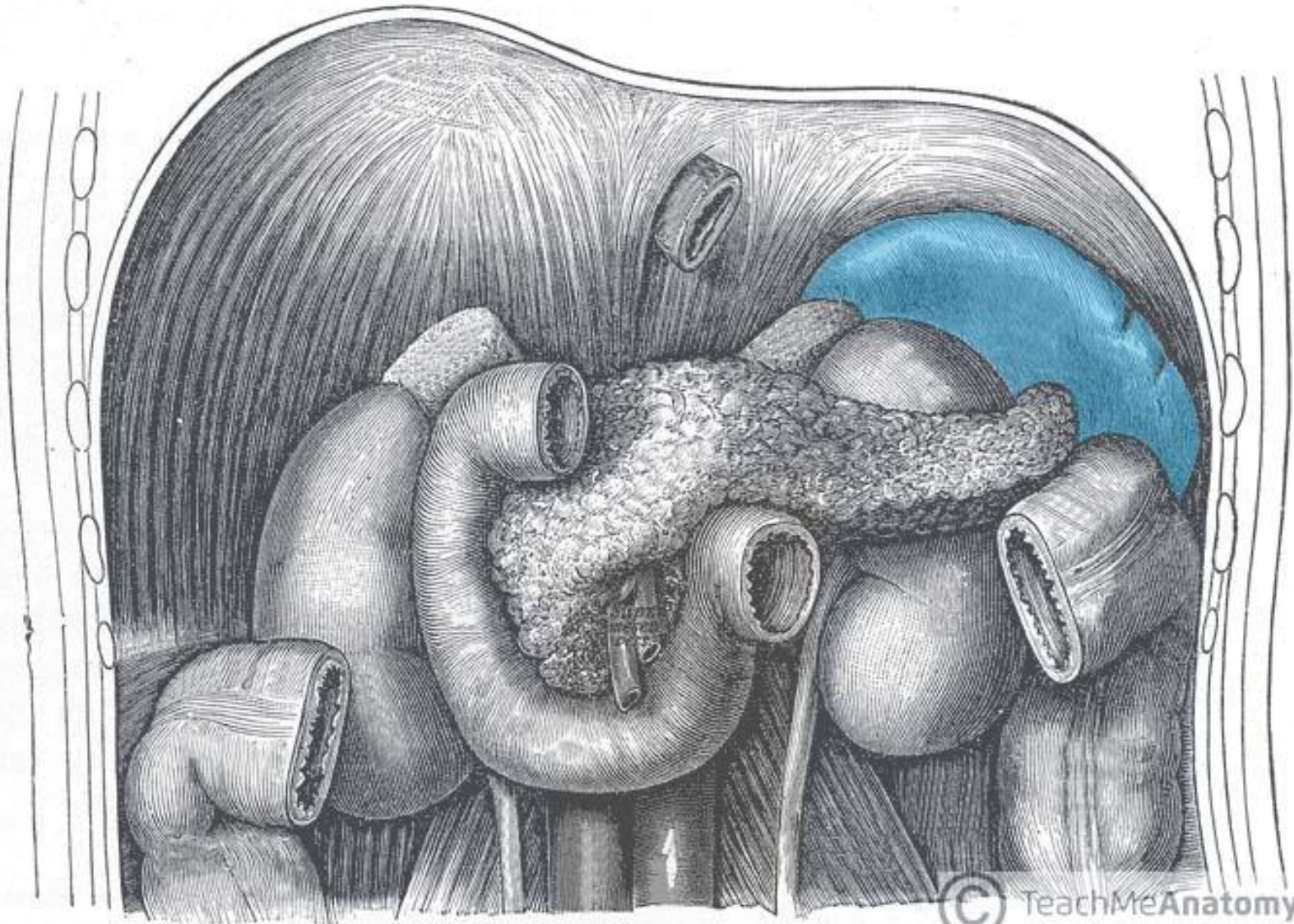


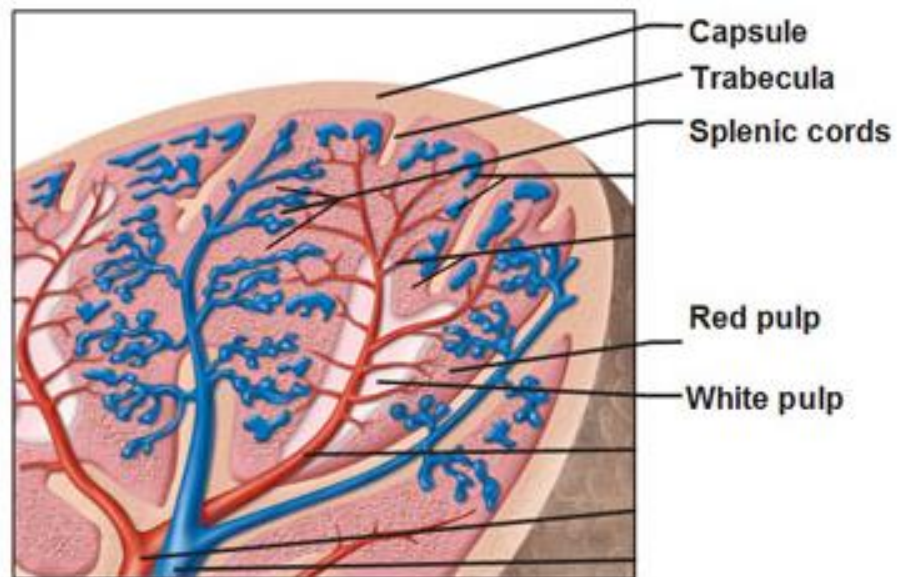
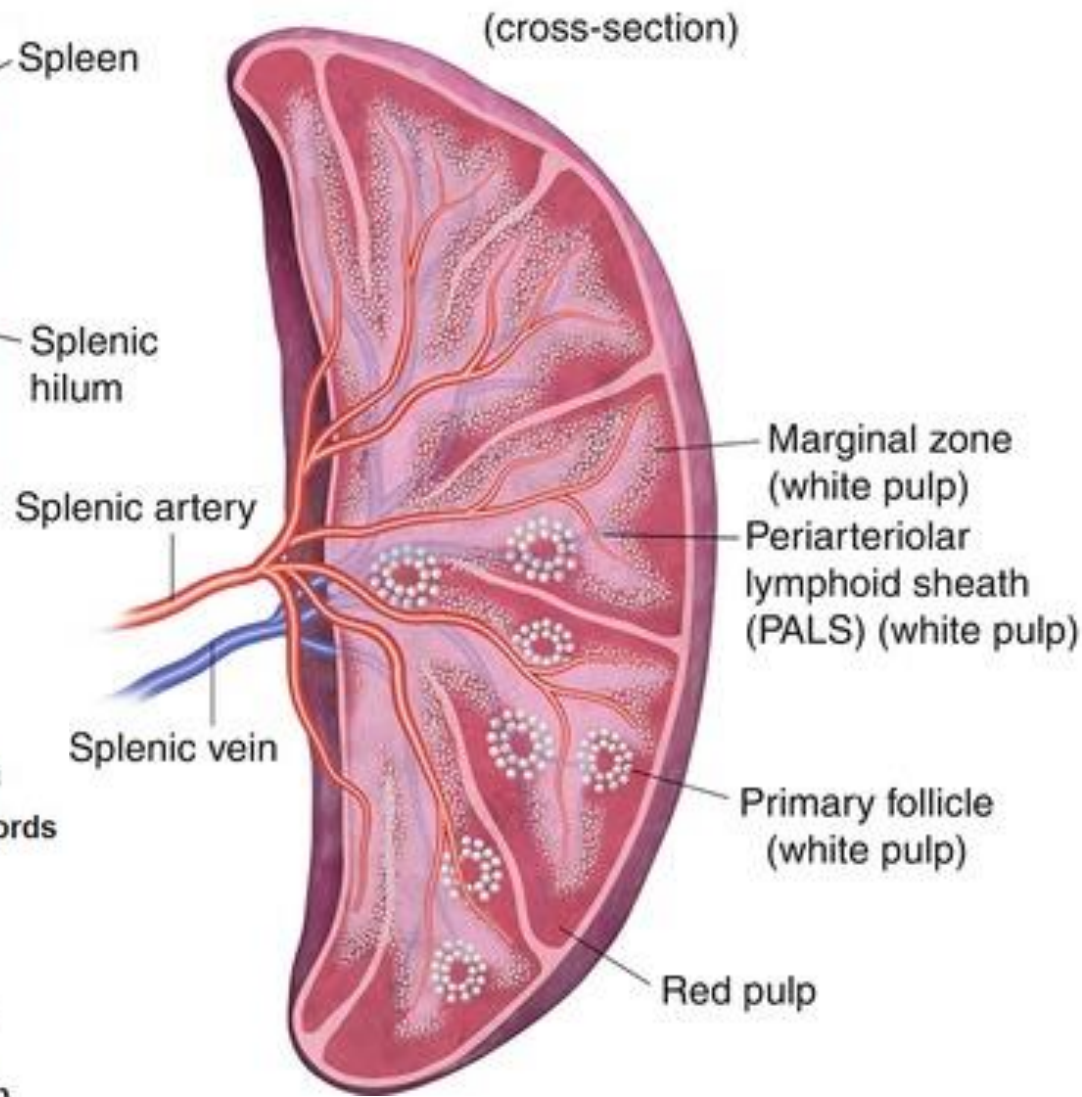
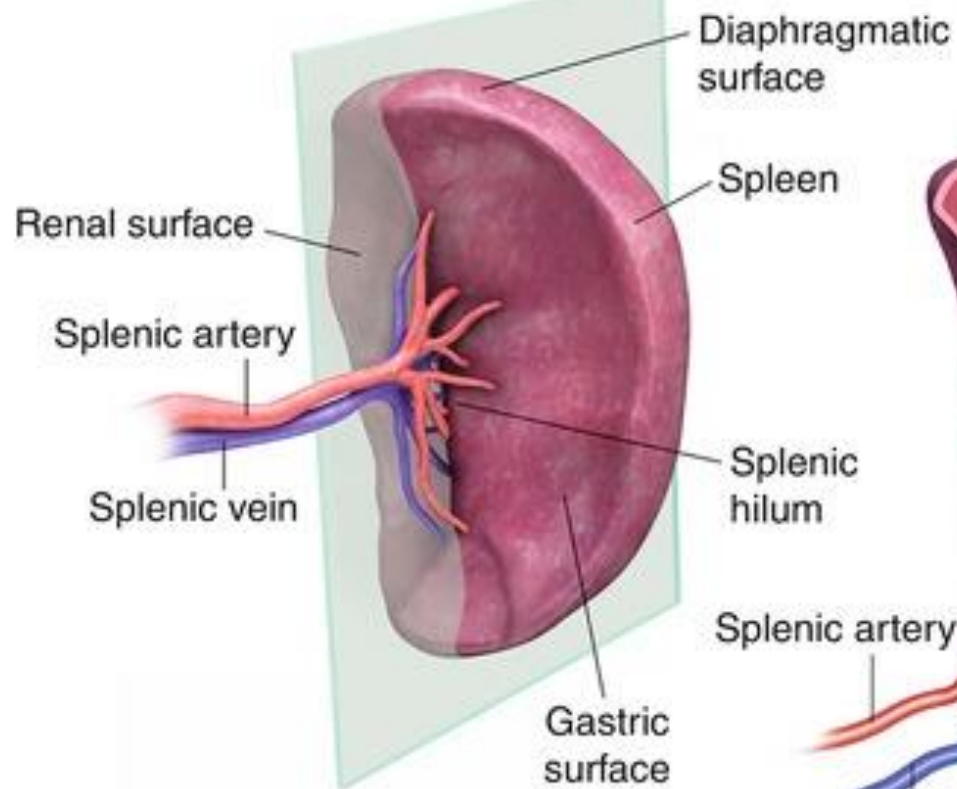
© 2014 Terese Winslow LLC
U.S. Govt. has certain rights

Image ID: RJ51WW
www.alamy.com

Function: hematopoiesis

Spleen

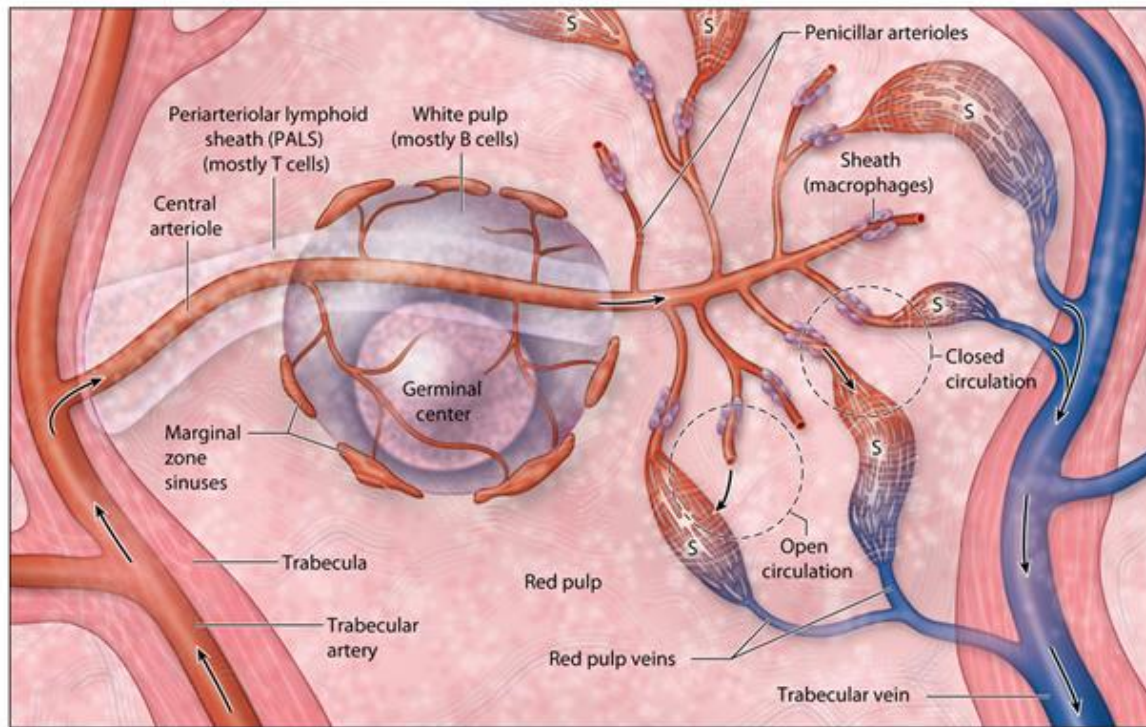




Spleen Functional Anatomy

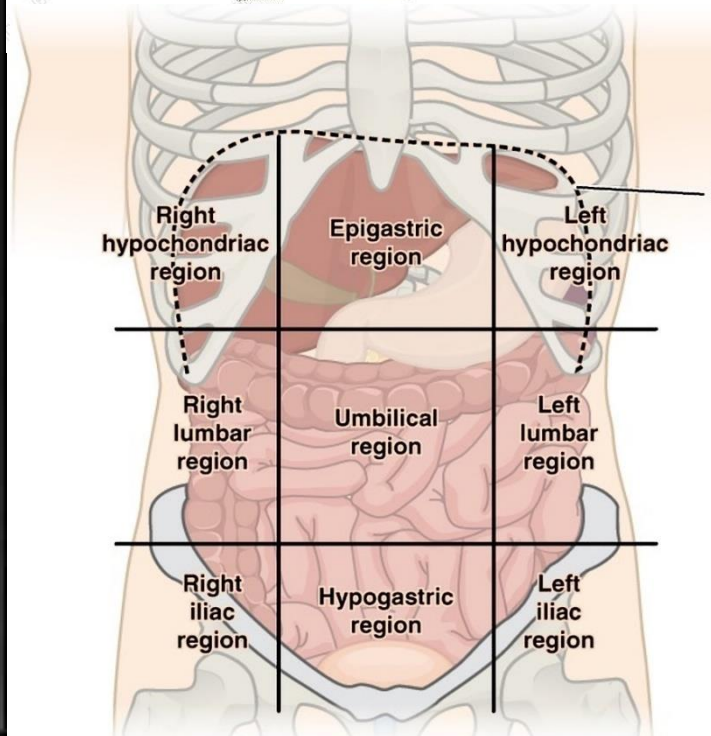
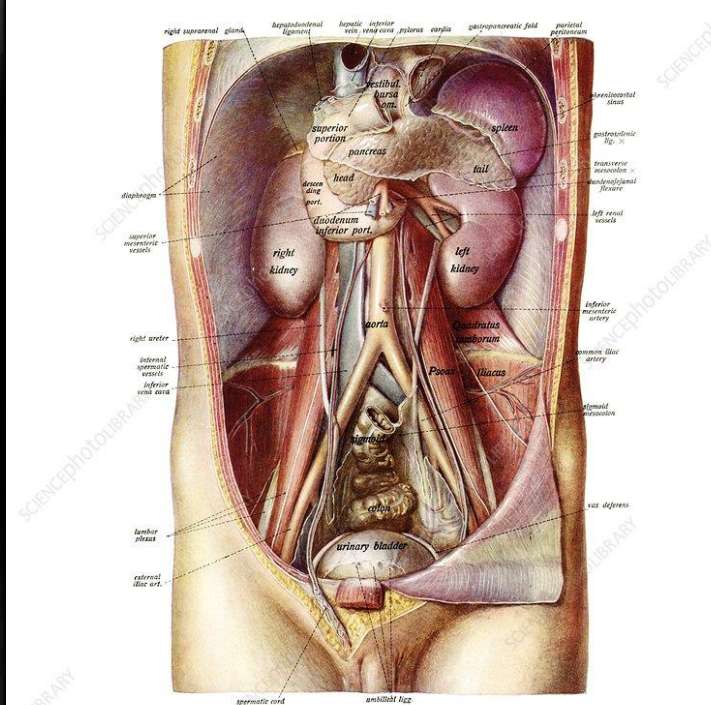
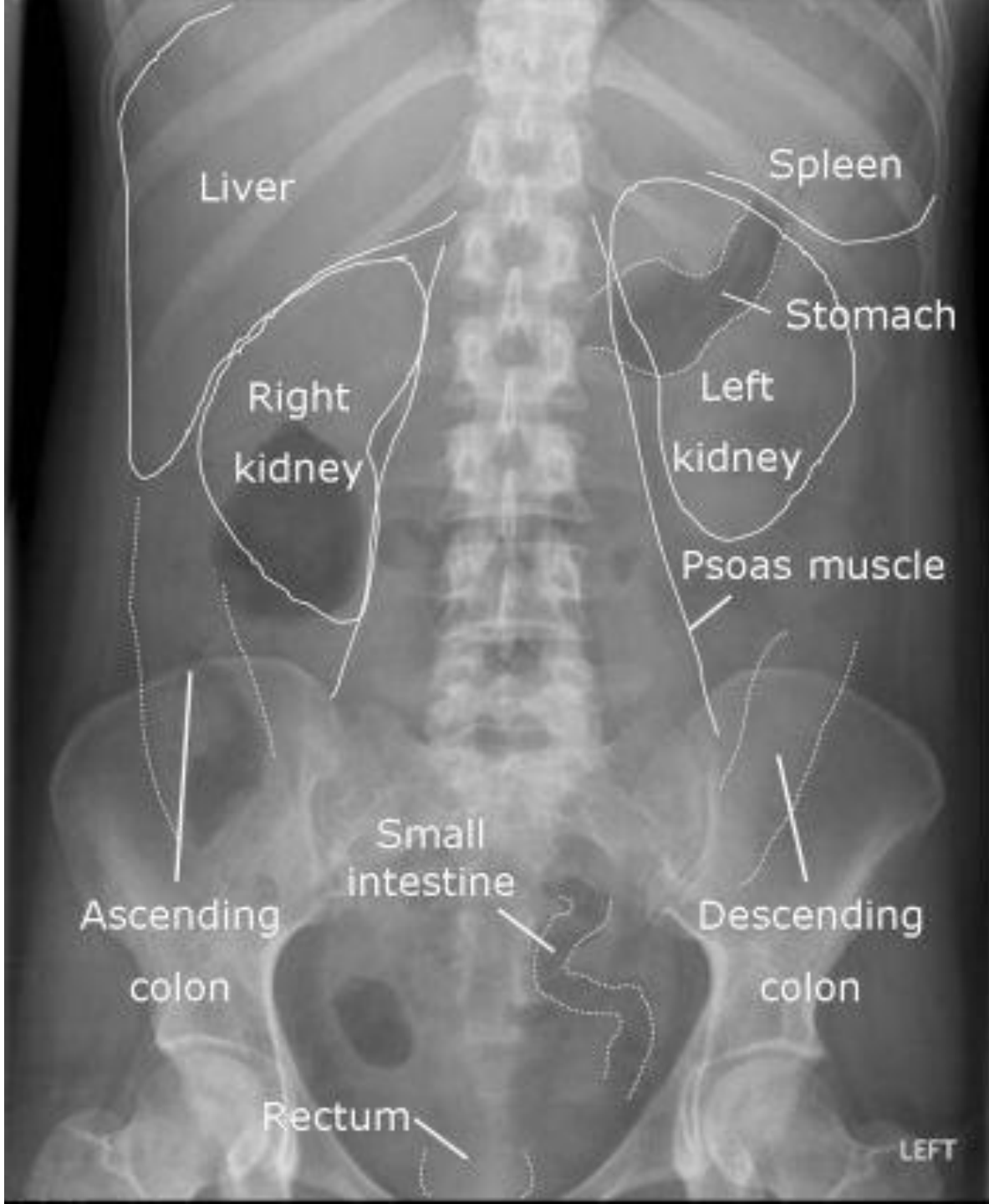
White pulp → B-lymphocytes & T-lymphocytes maturation by antigen stimulation

Red pulp → Blood filtration of debris & destroyed RBC.

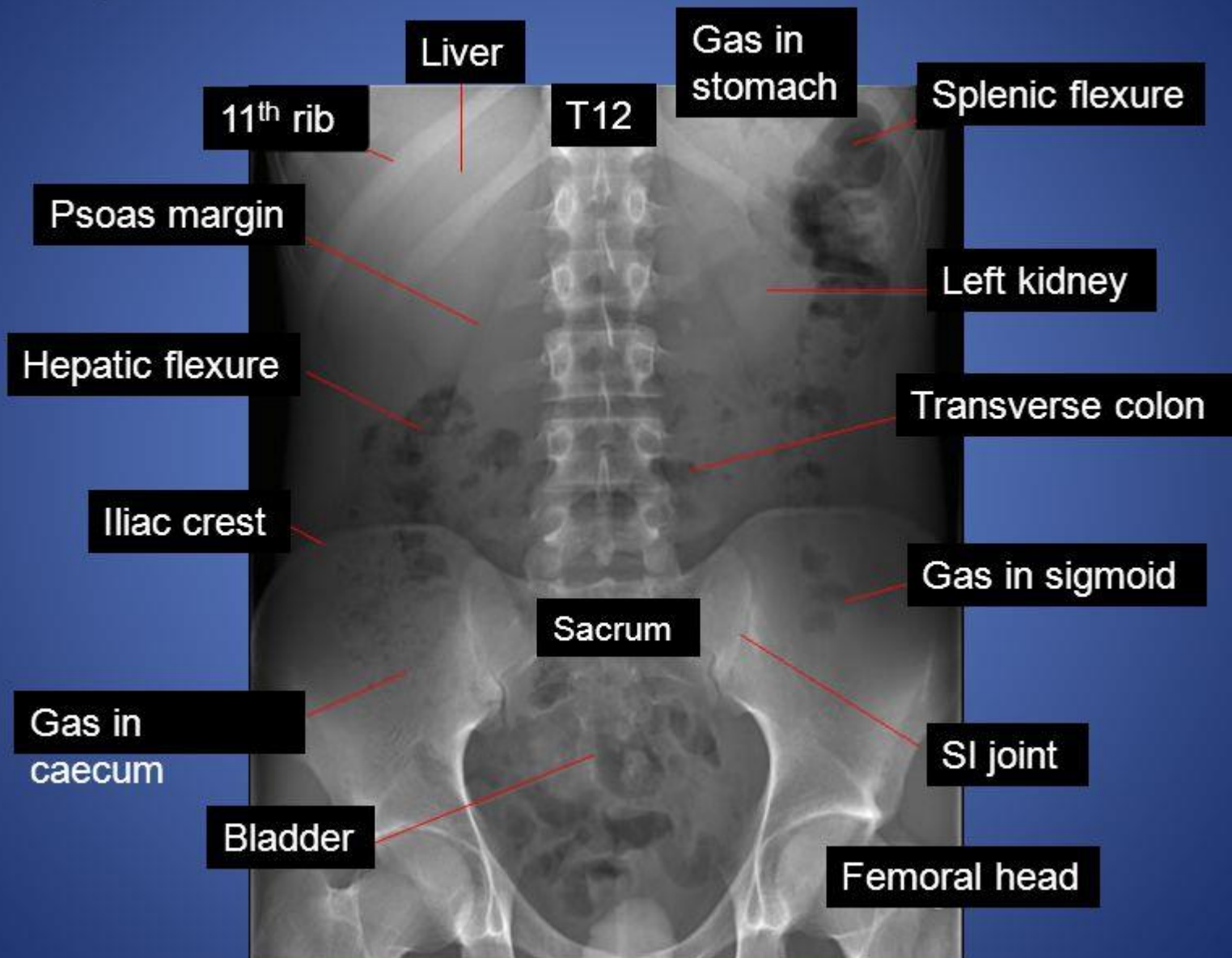


- Trabecular arteries:
Branch from the hilum
- Central arterioles:
Surrounded by PALS
- Penicillar arterioles:
Open into capillaries
- Sinusoids:
In the red pulp
Stave cells
- Red pulp veins
- Trabecular veins

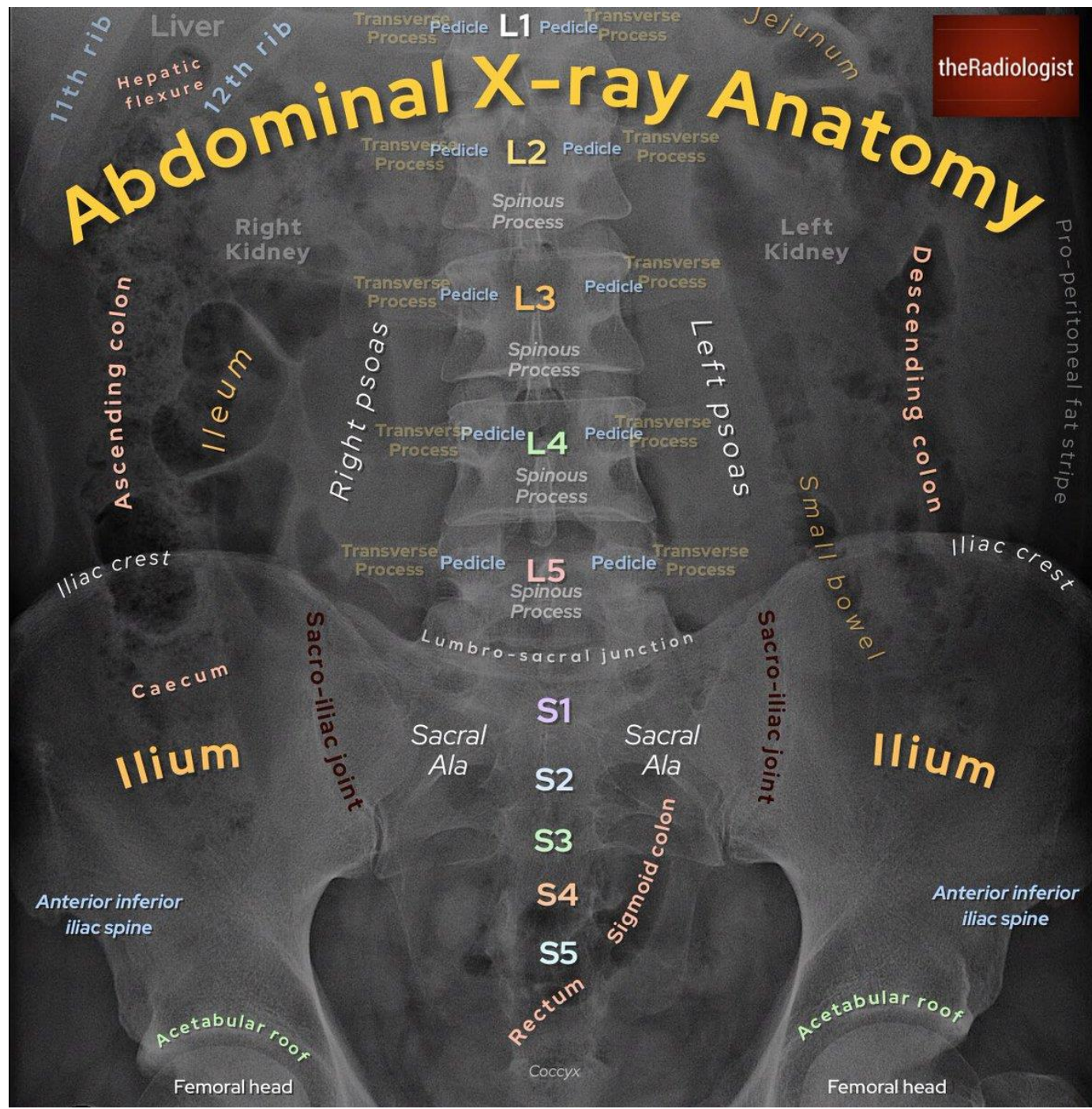
No HEVs!

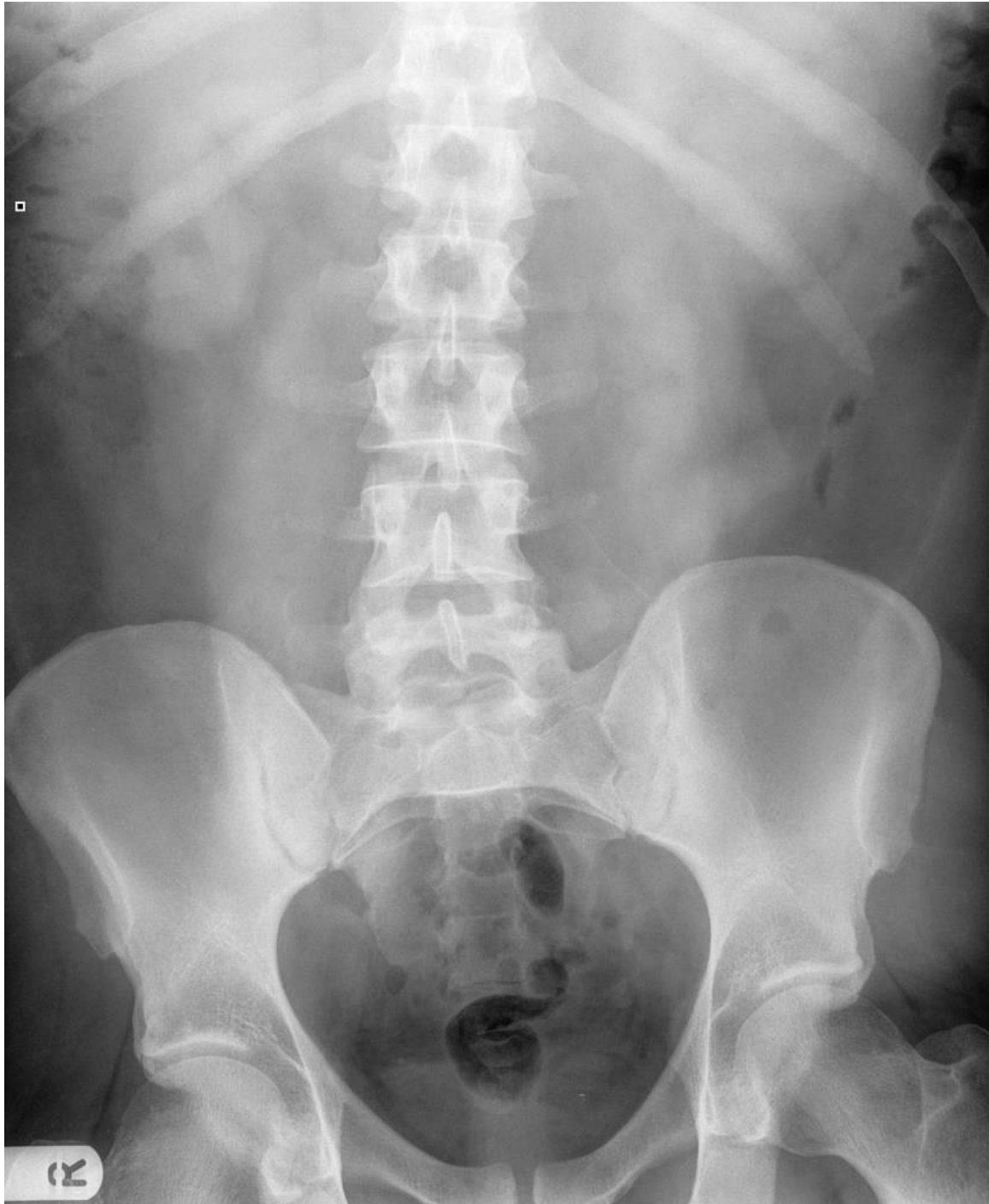

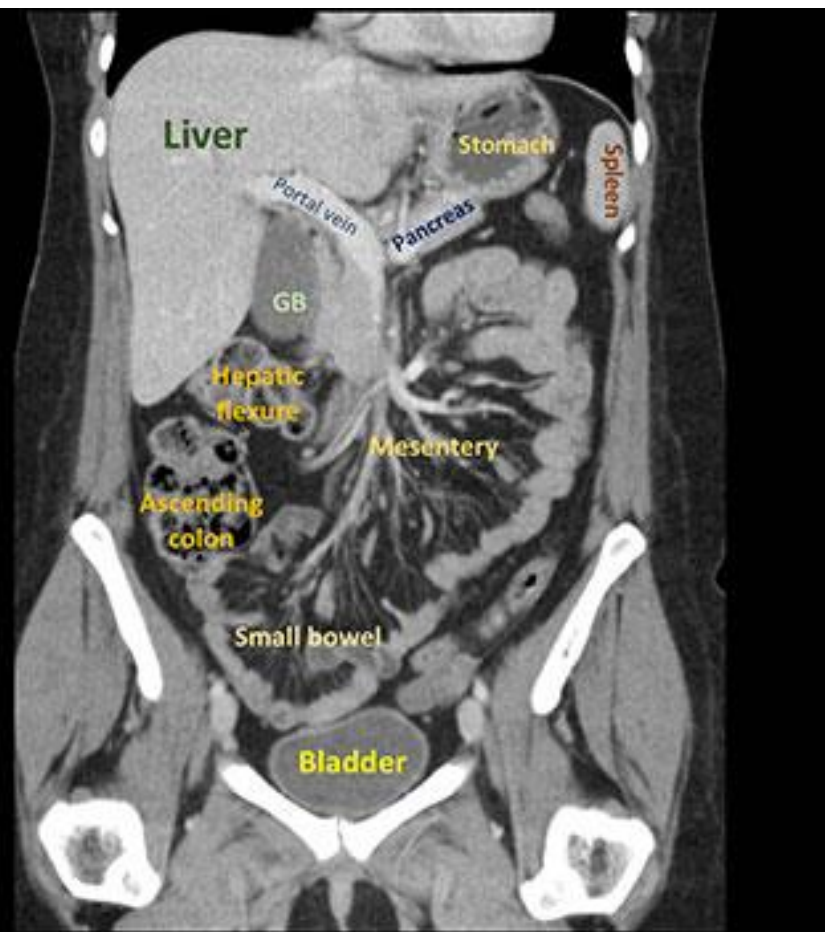
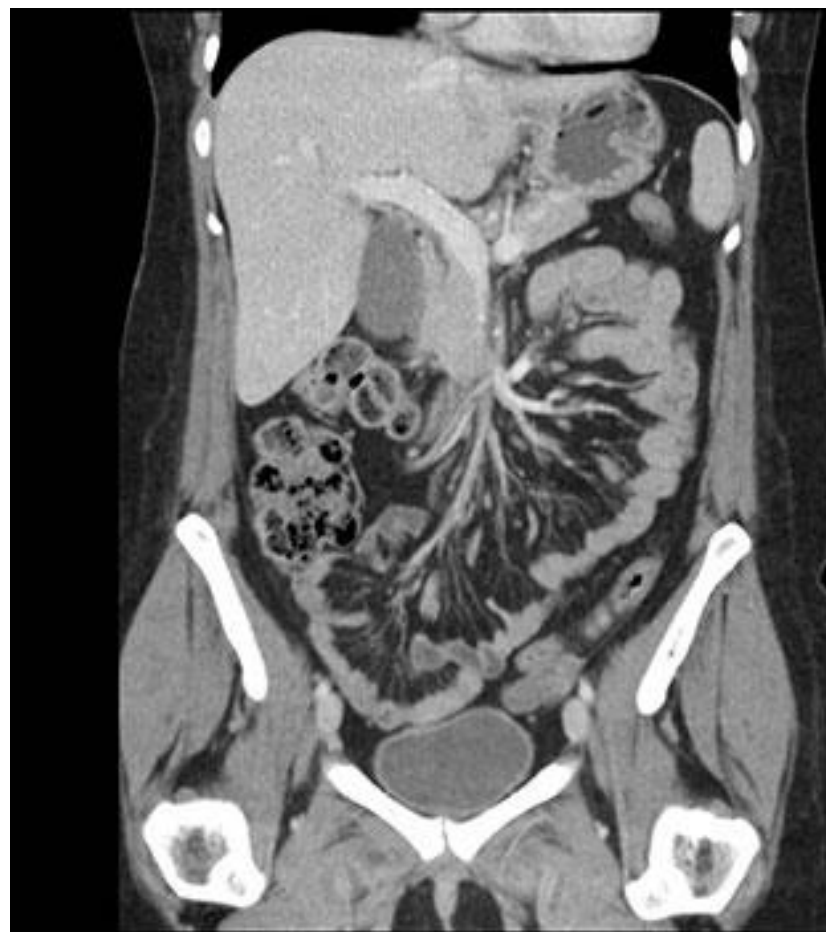Normal AXR



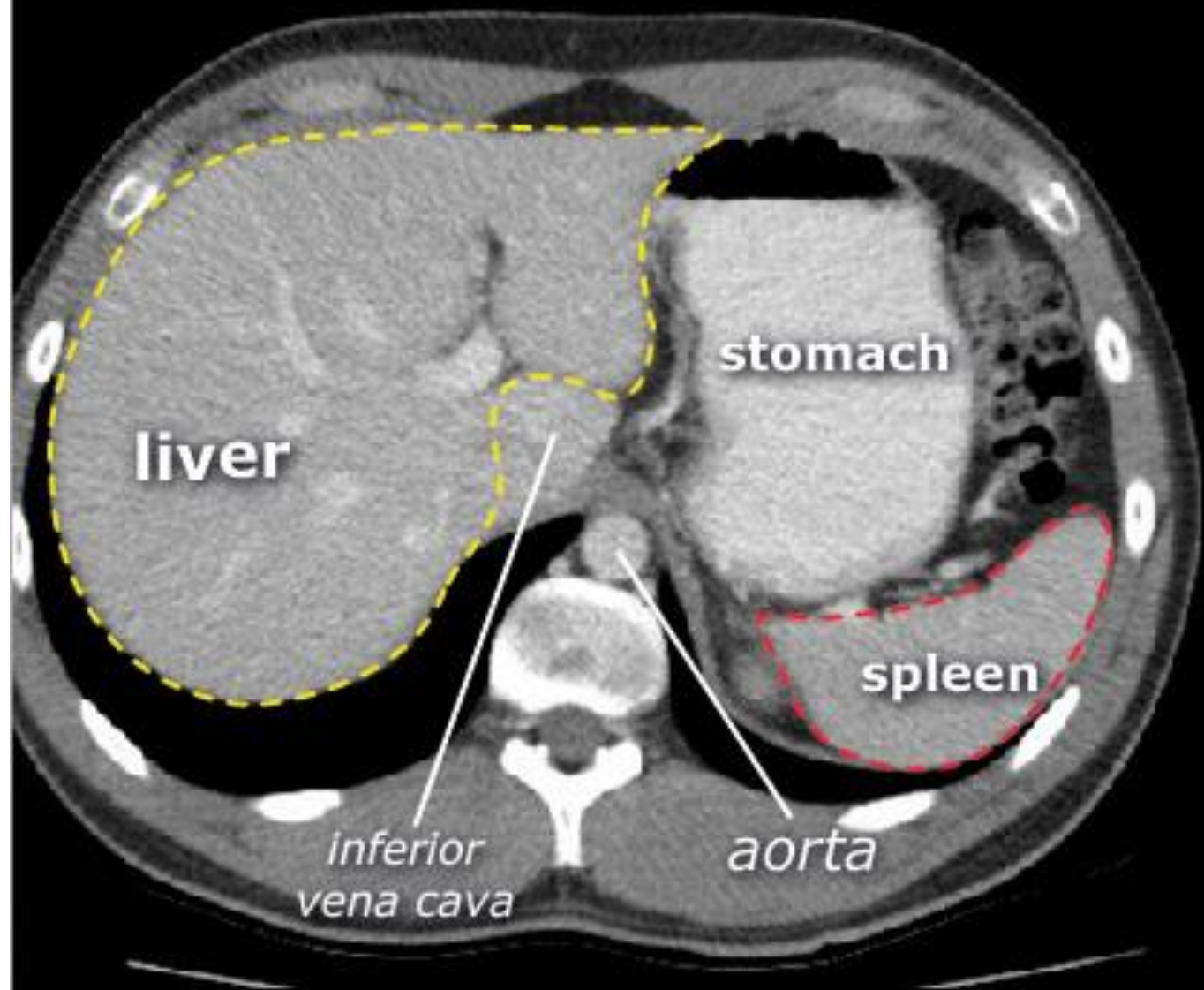
Abdominal X-ray Anatomy



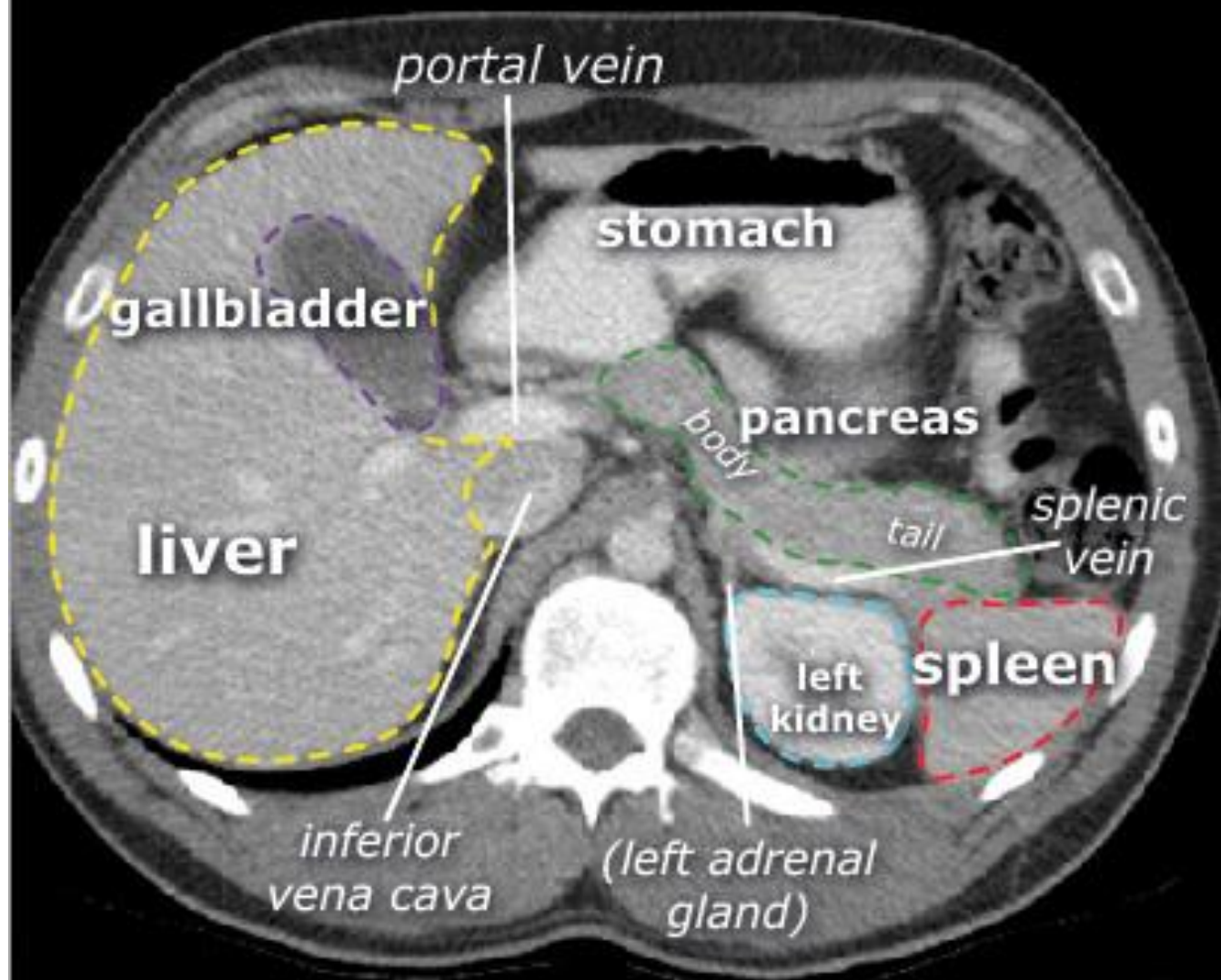


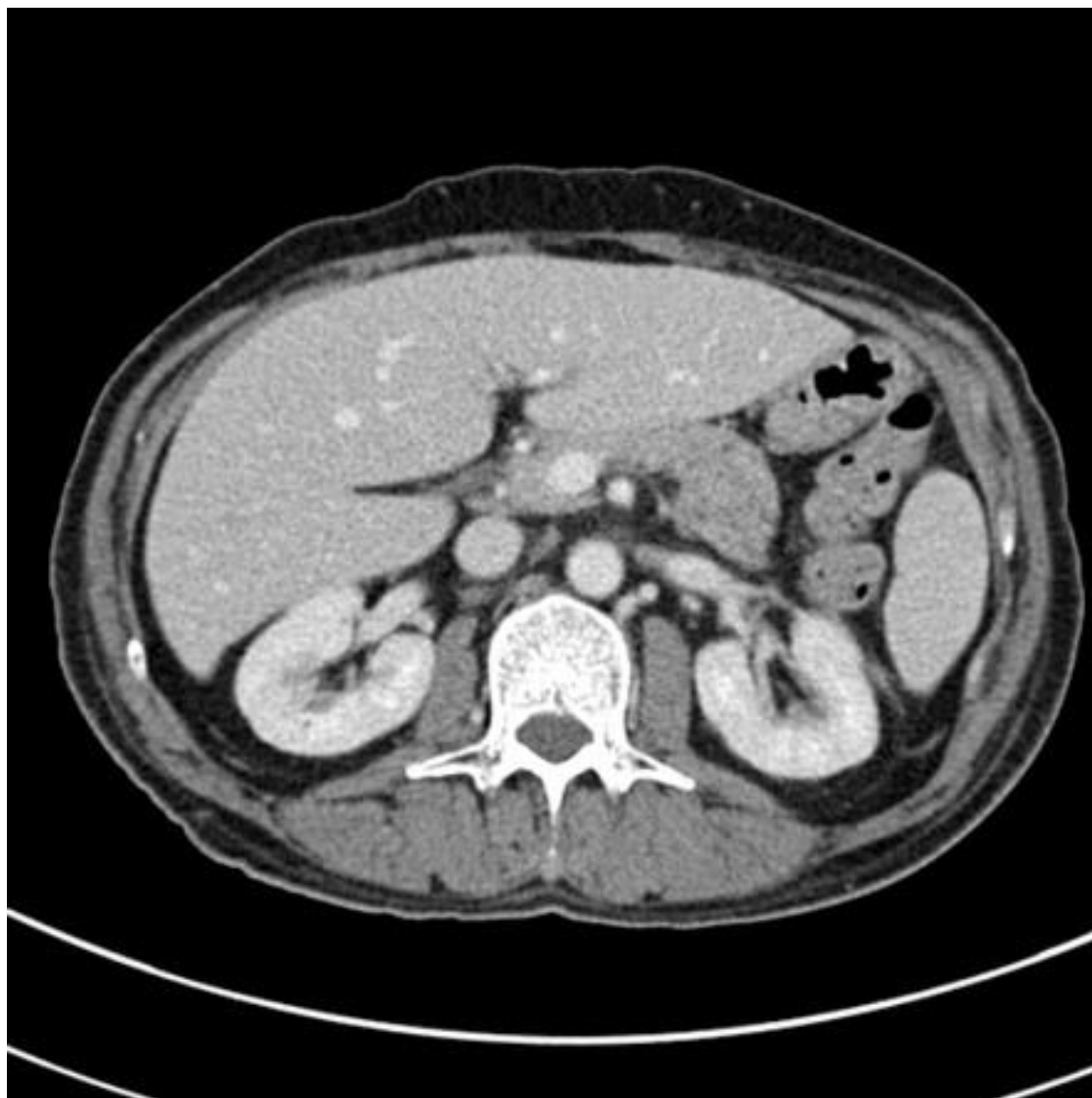


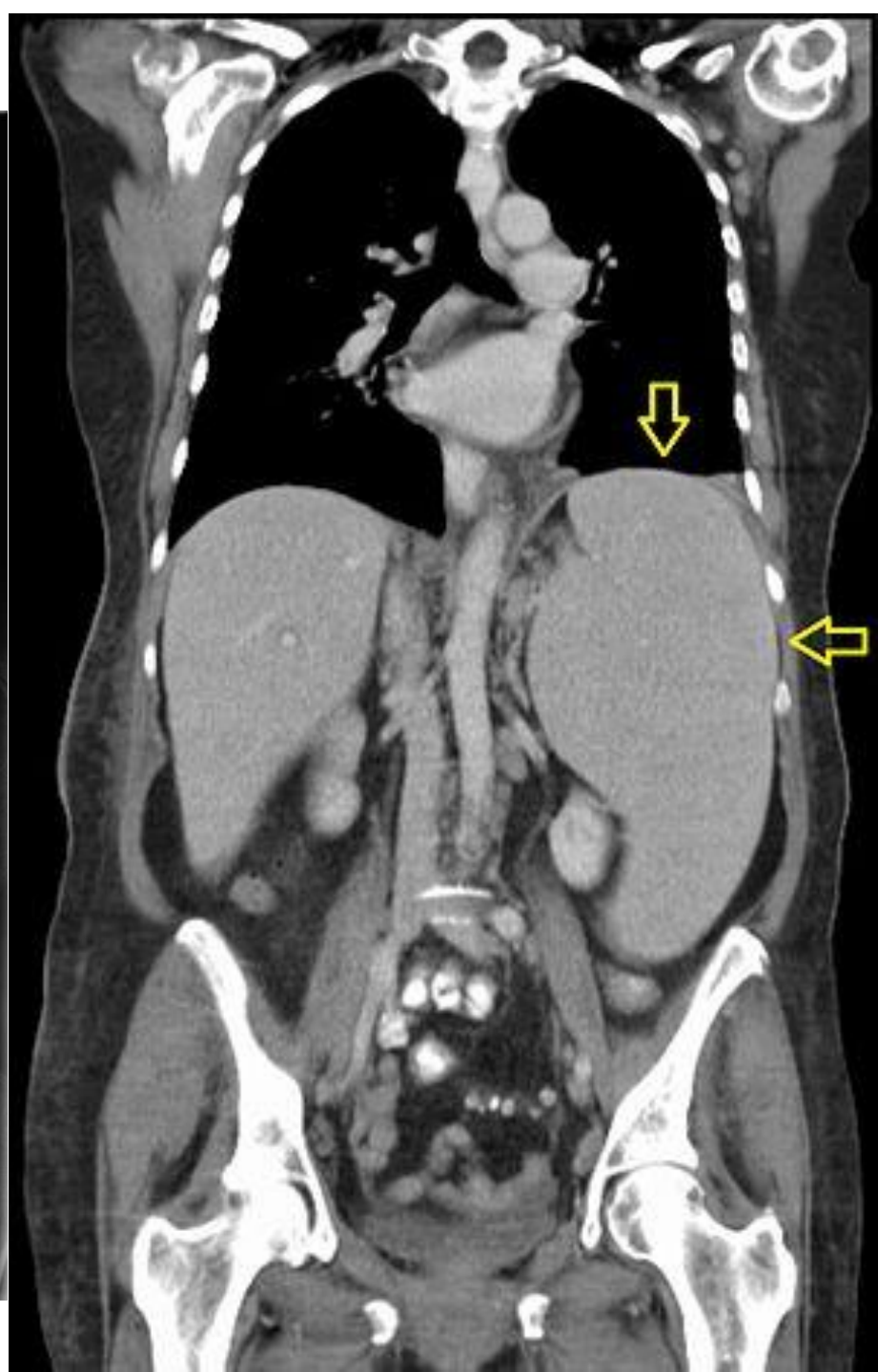
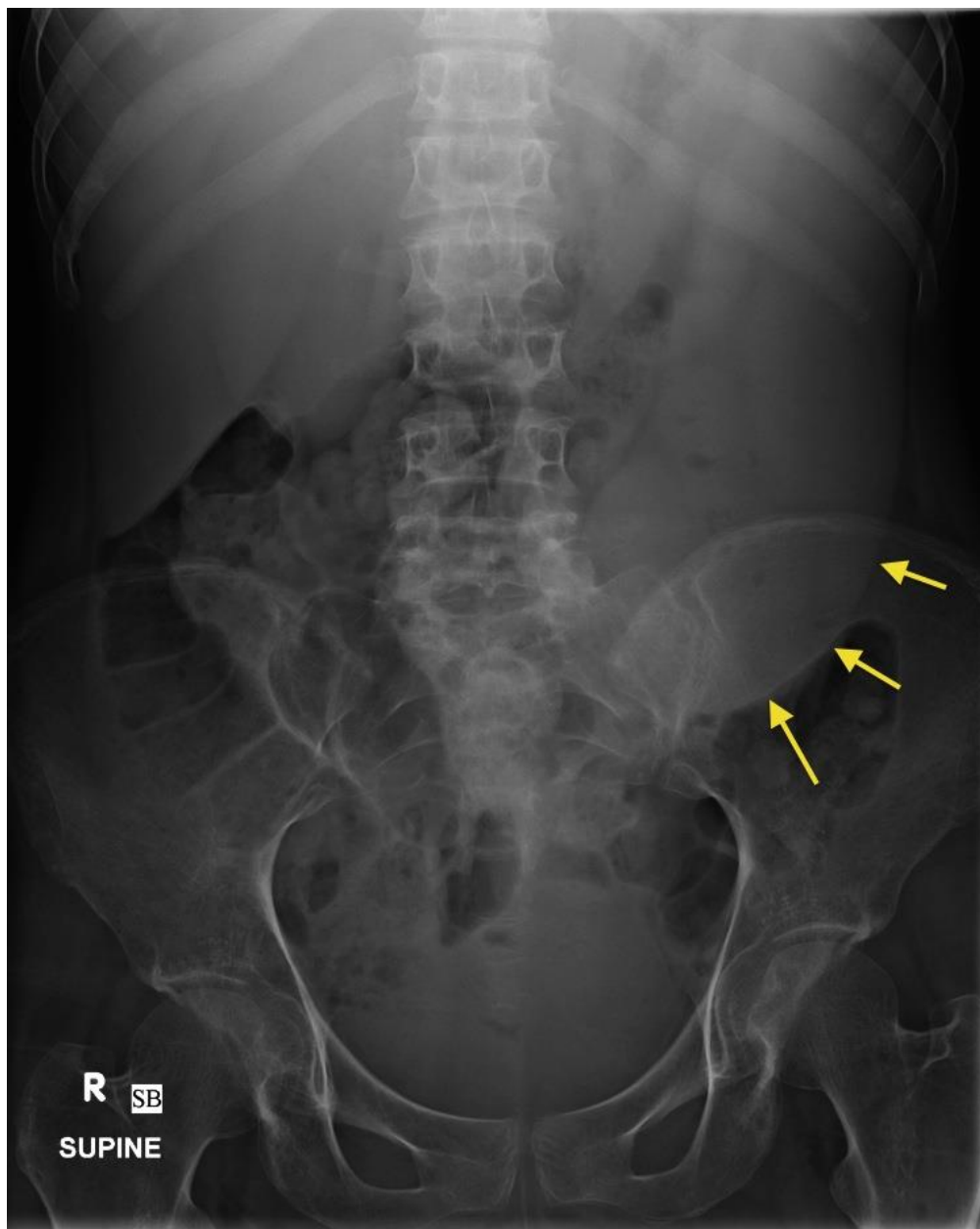
Normal abdominal CT



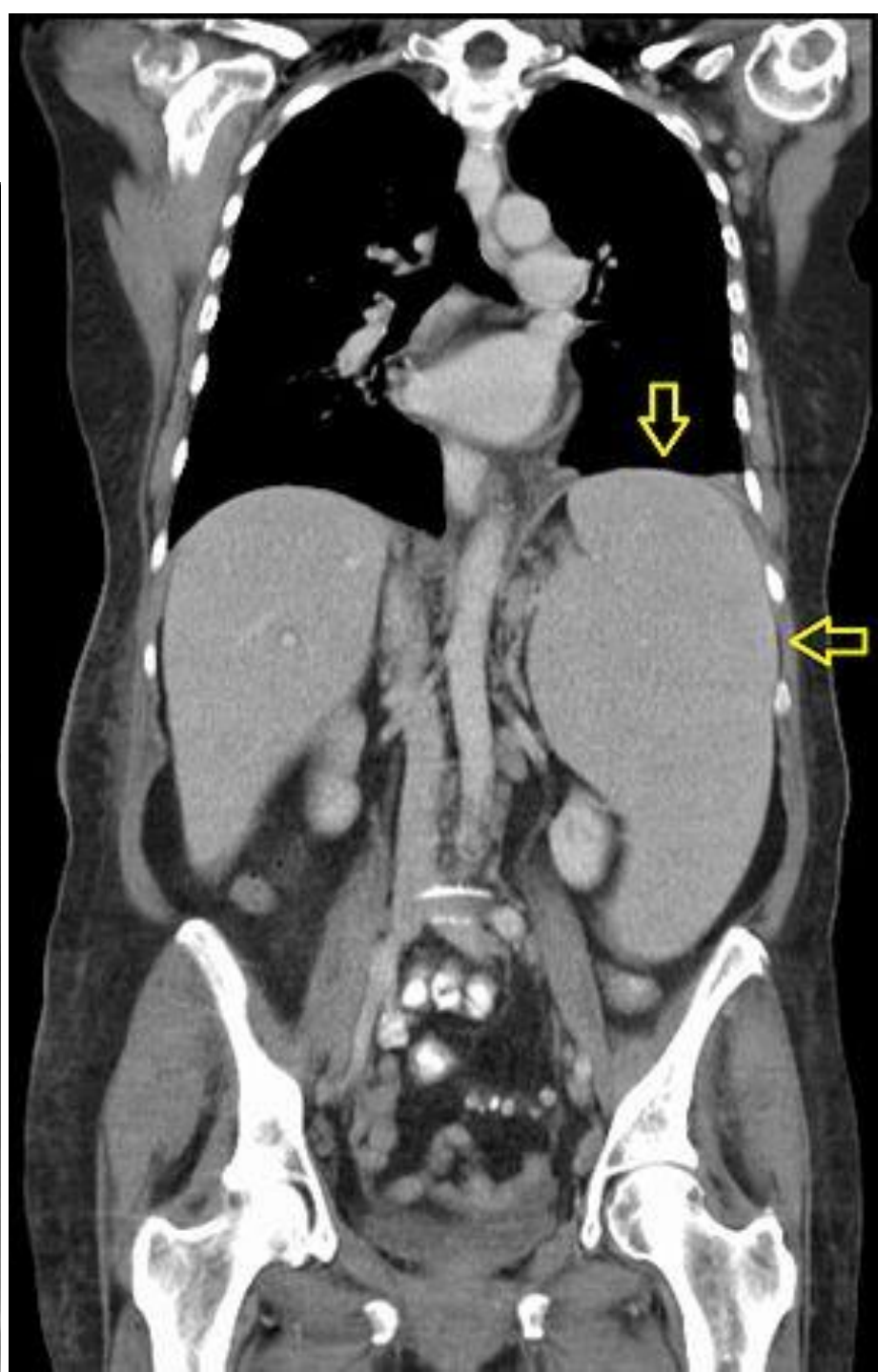
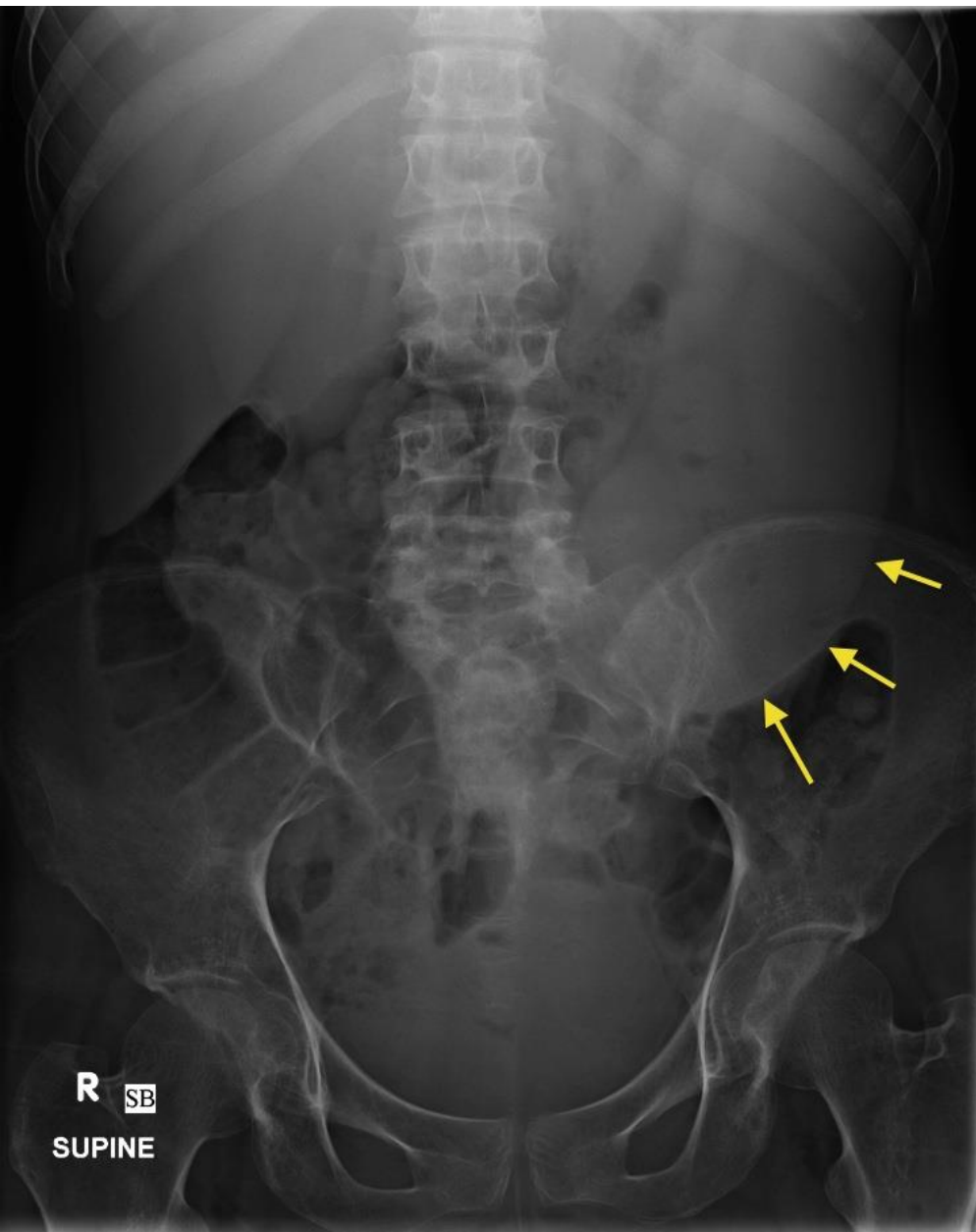
Normal abdominal CT

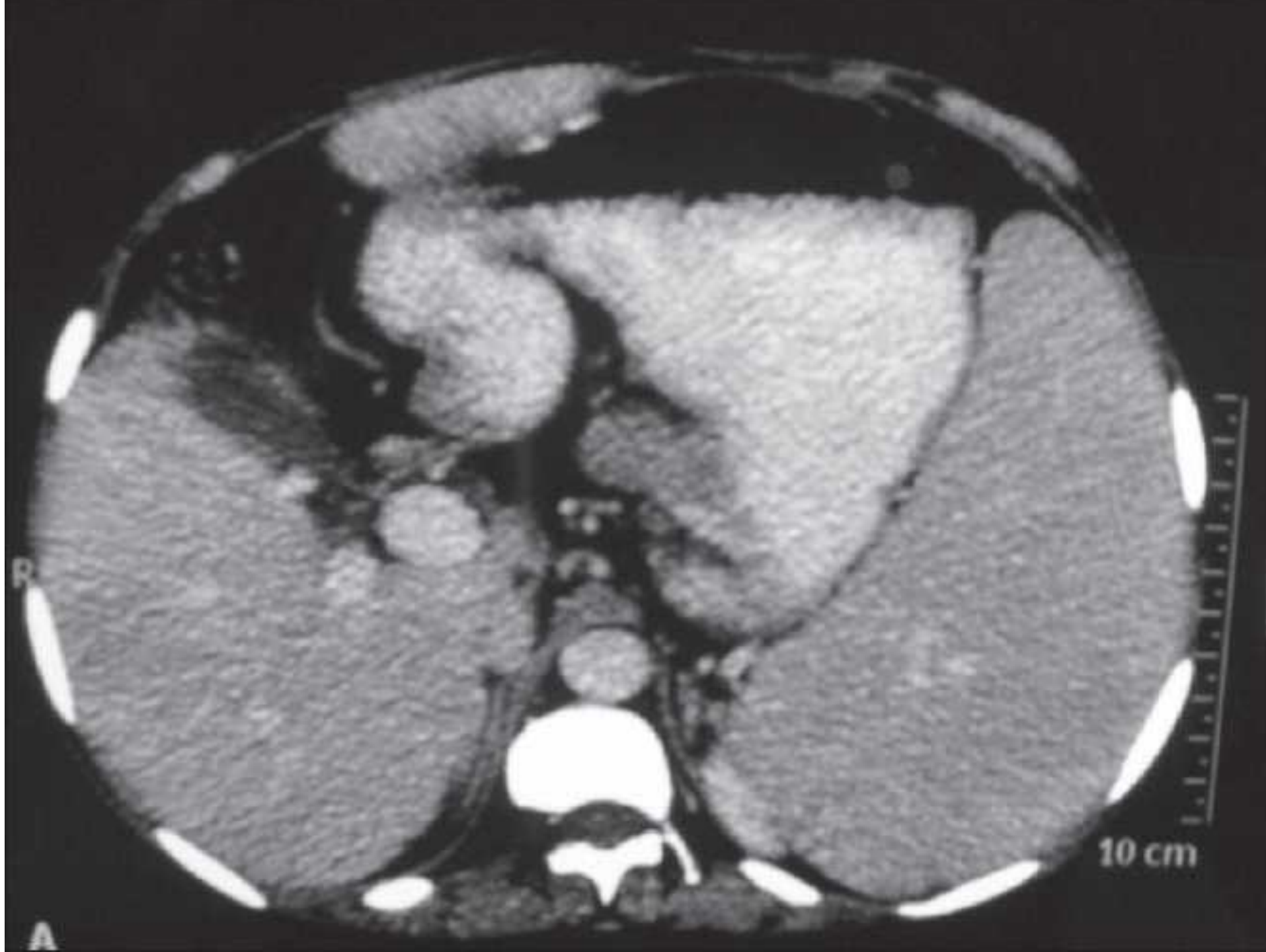

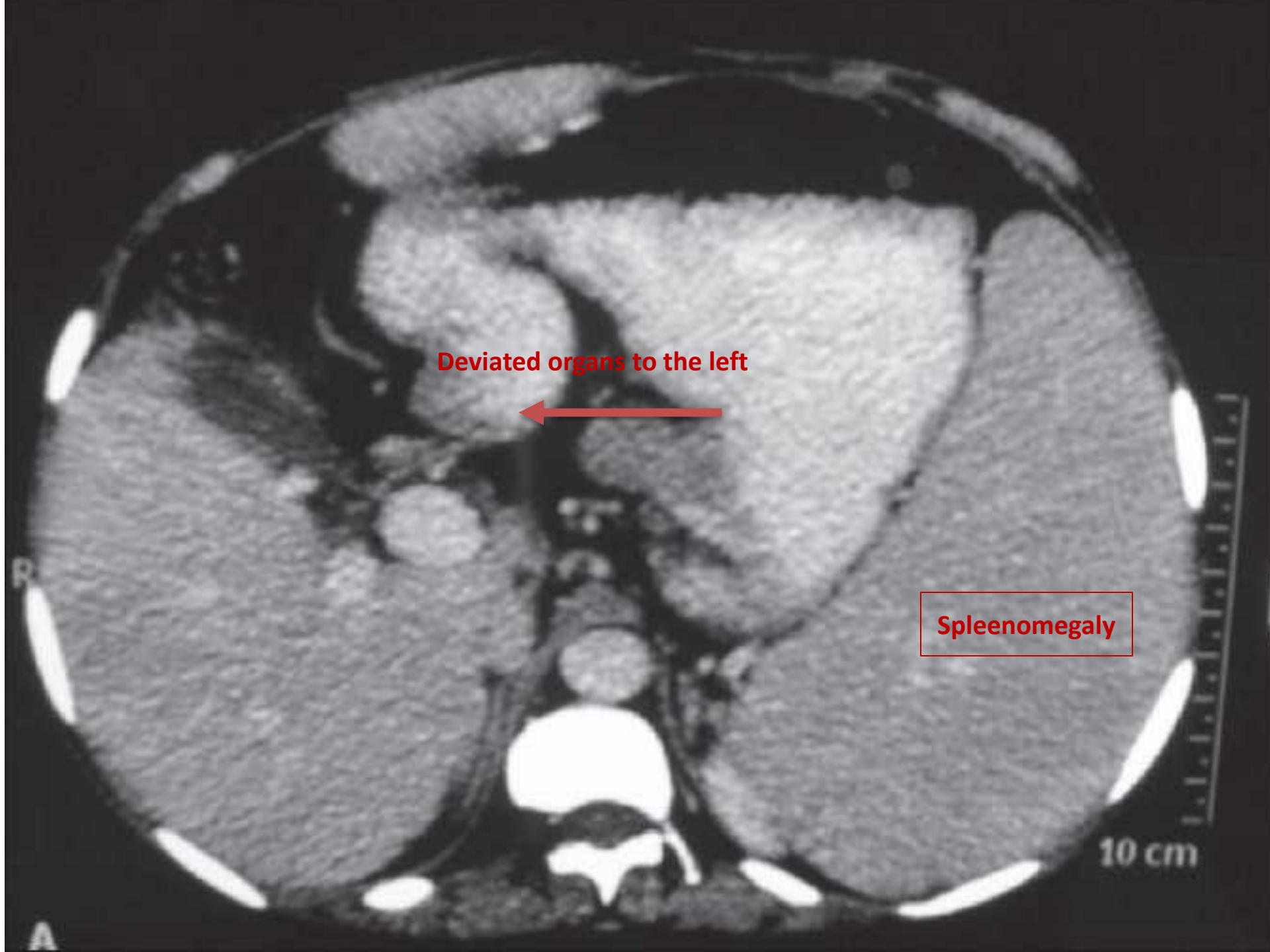




Splenomegaly







Deviated organs to the left

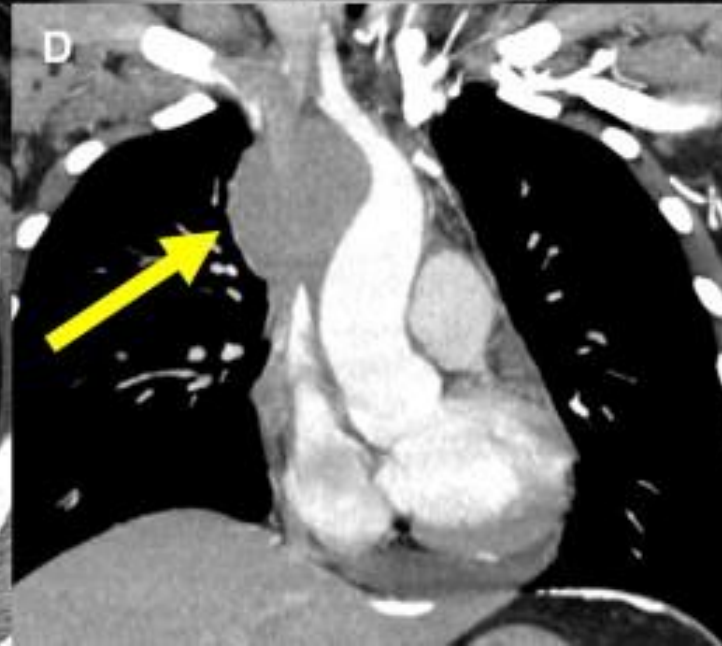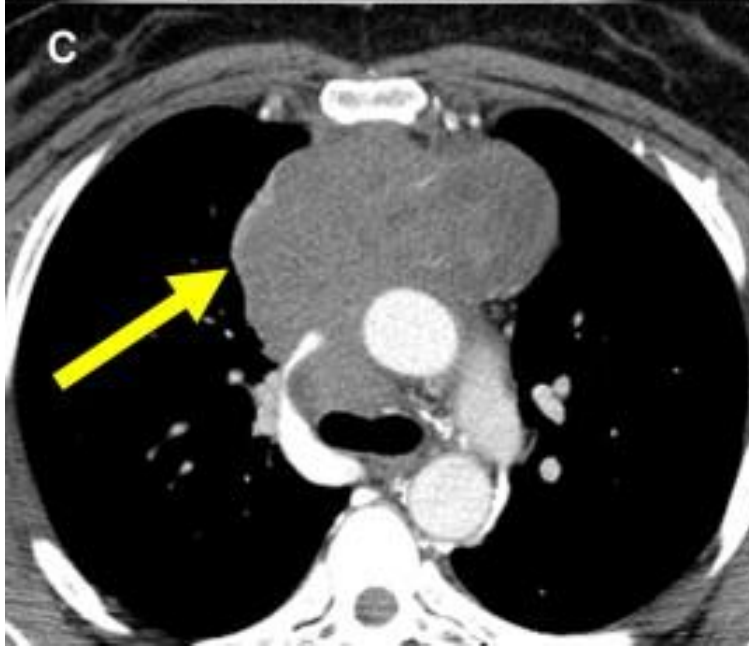
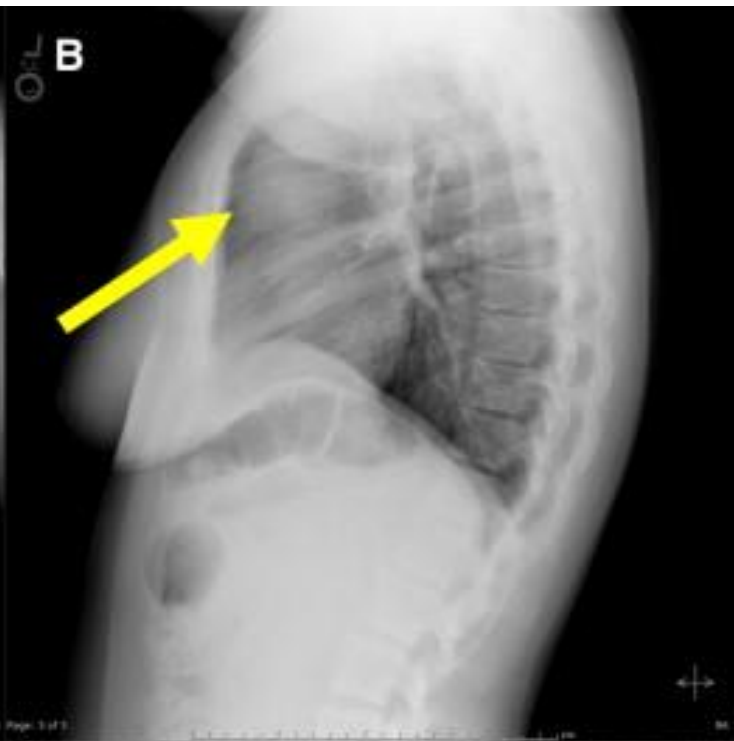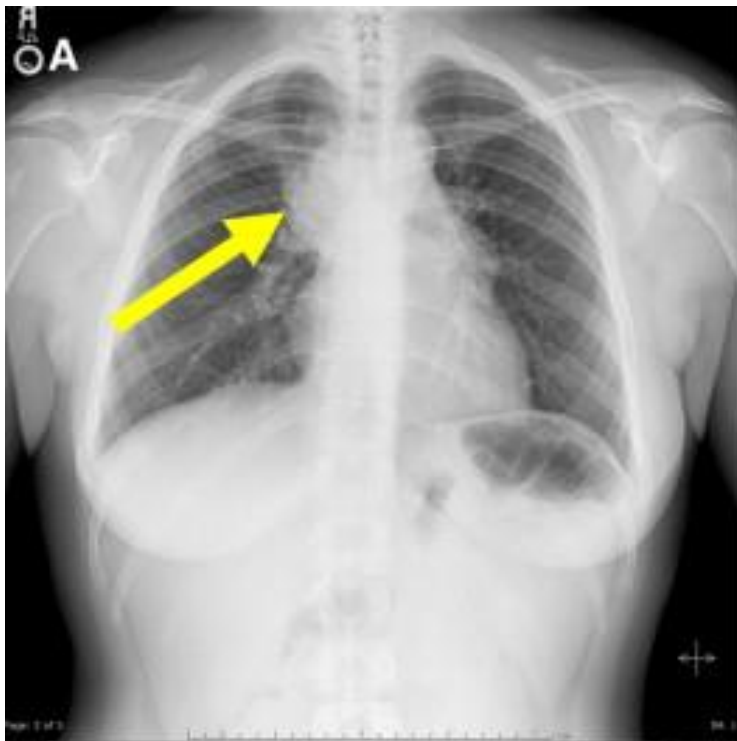


Splenomegaly

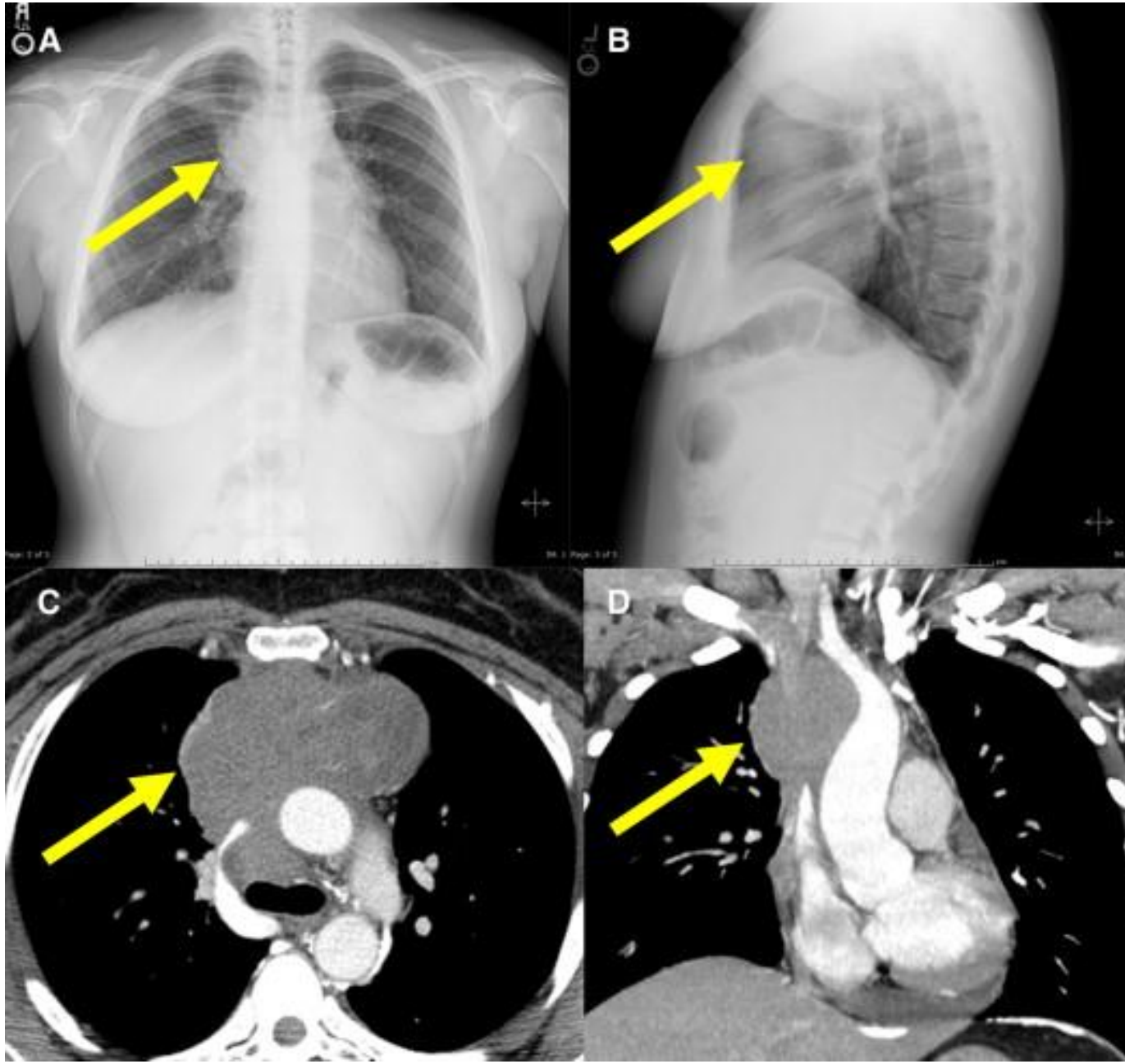
10 cm

R

A

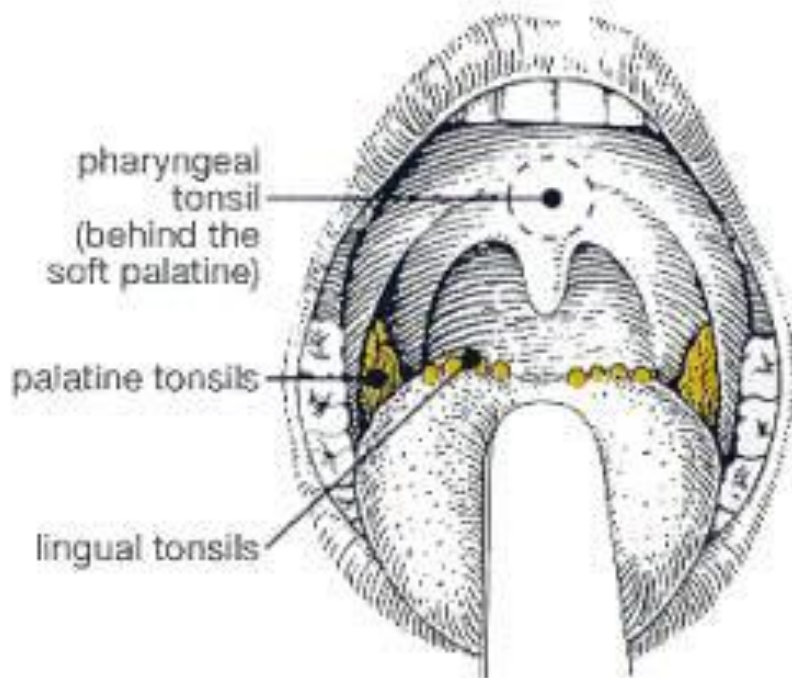


Thymus Tumor

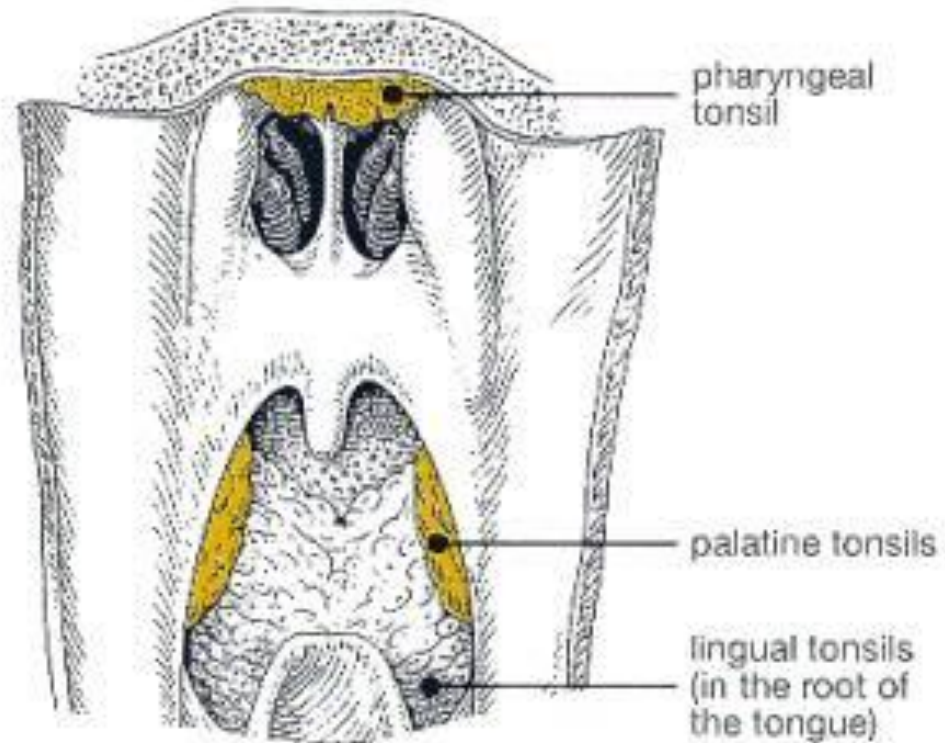


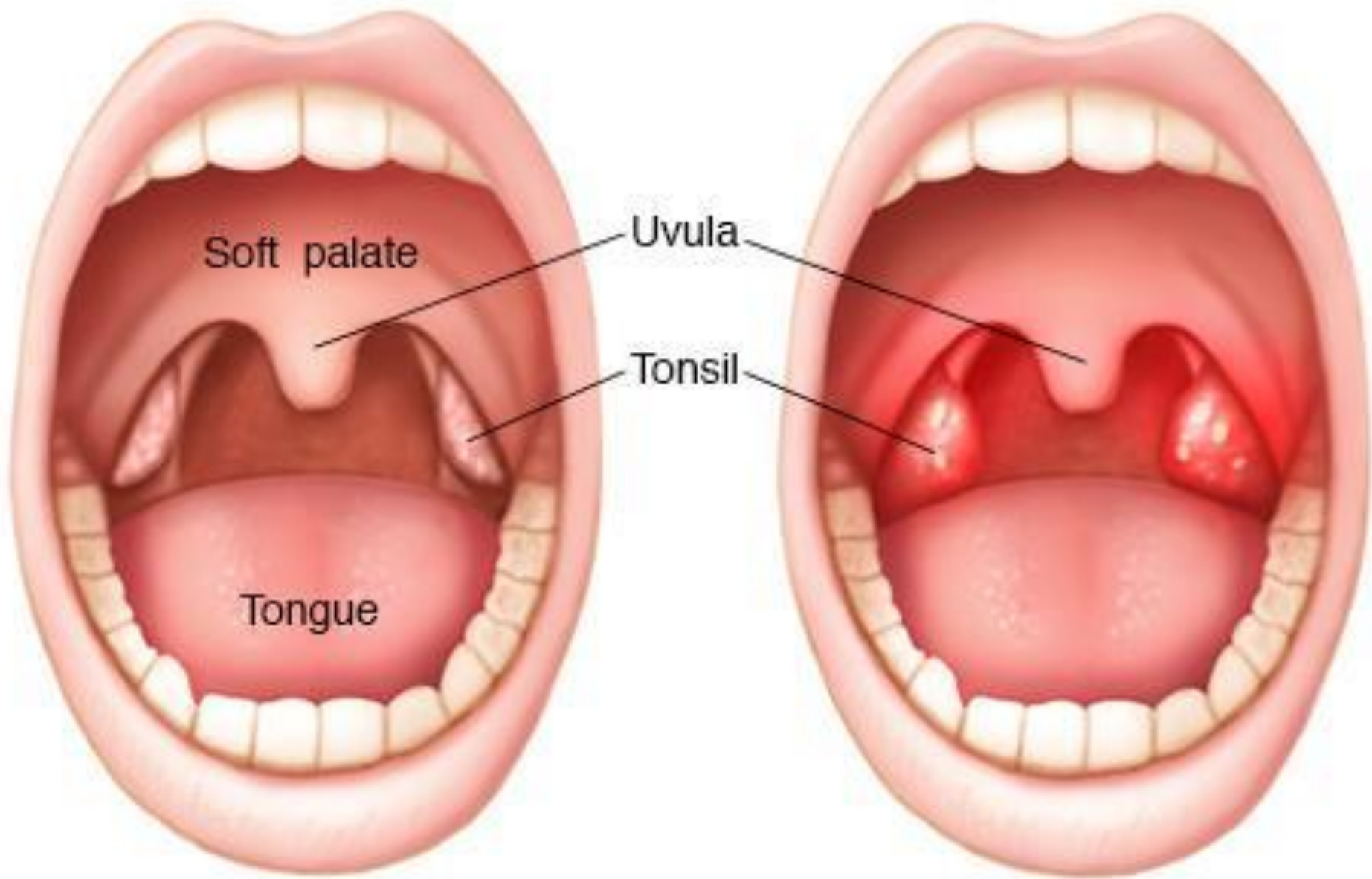
Waldeyer's Ring

FROM THE FRONT
-anterior view



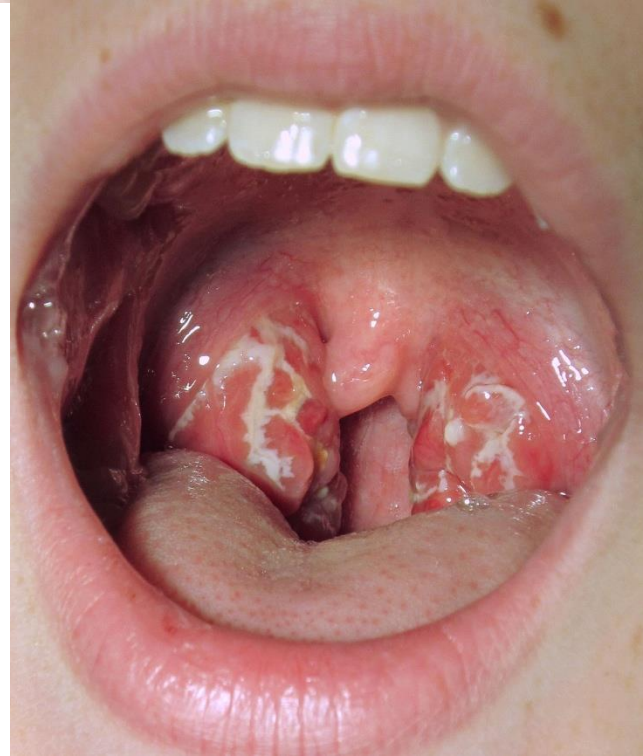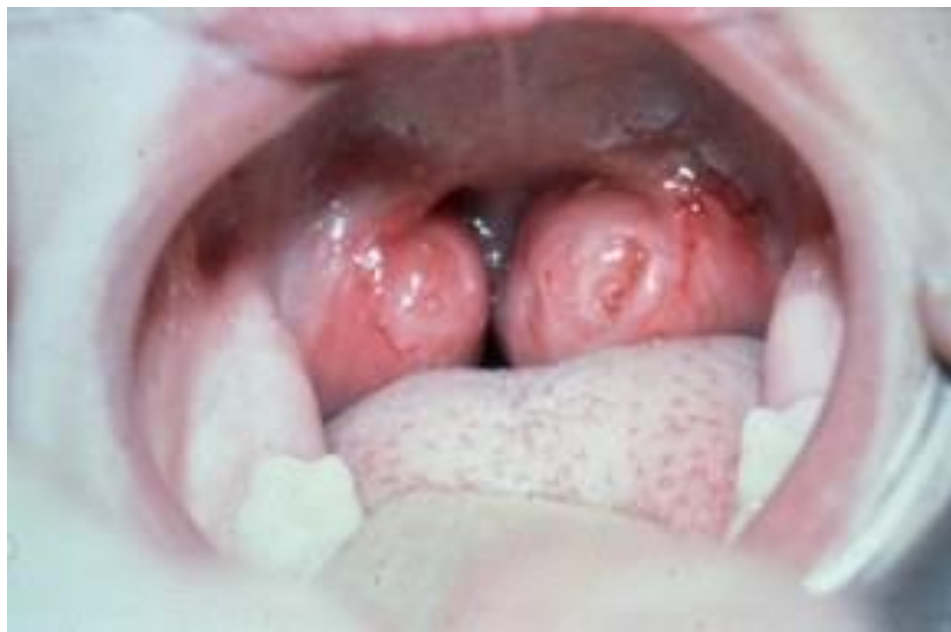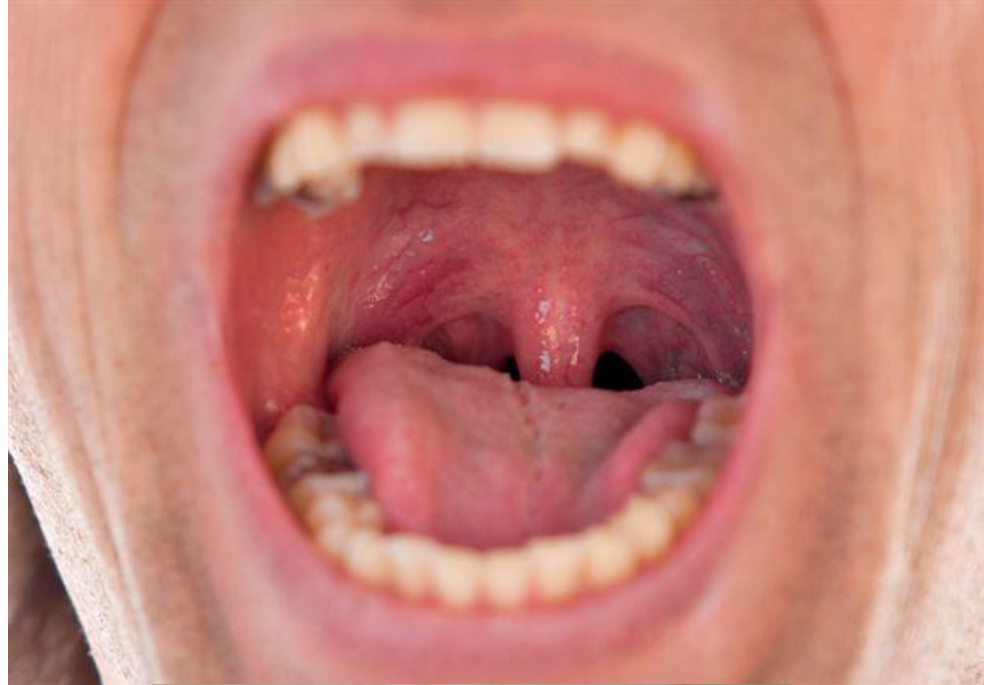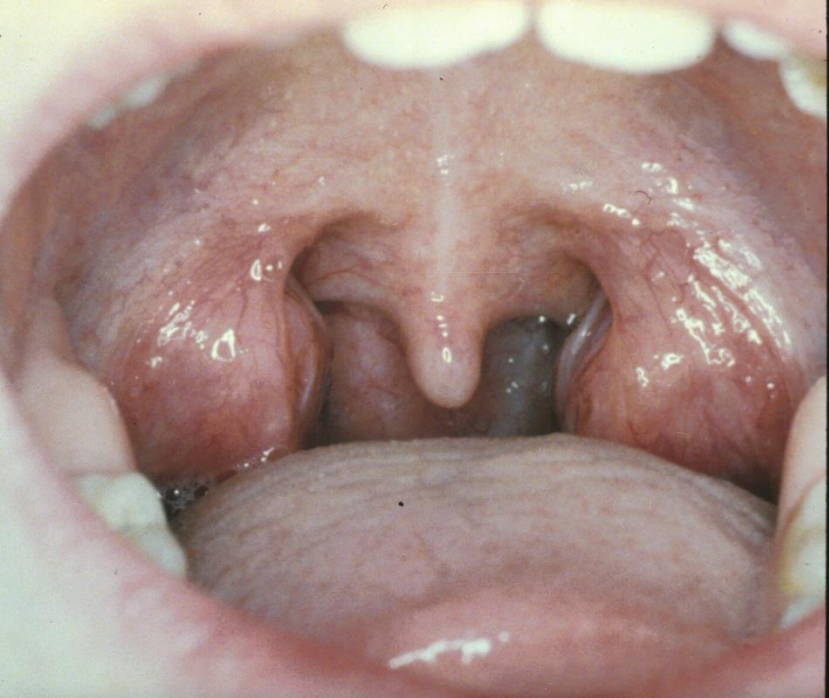FROM THE BACK
-posterior view



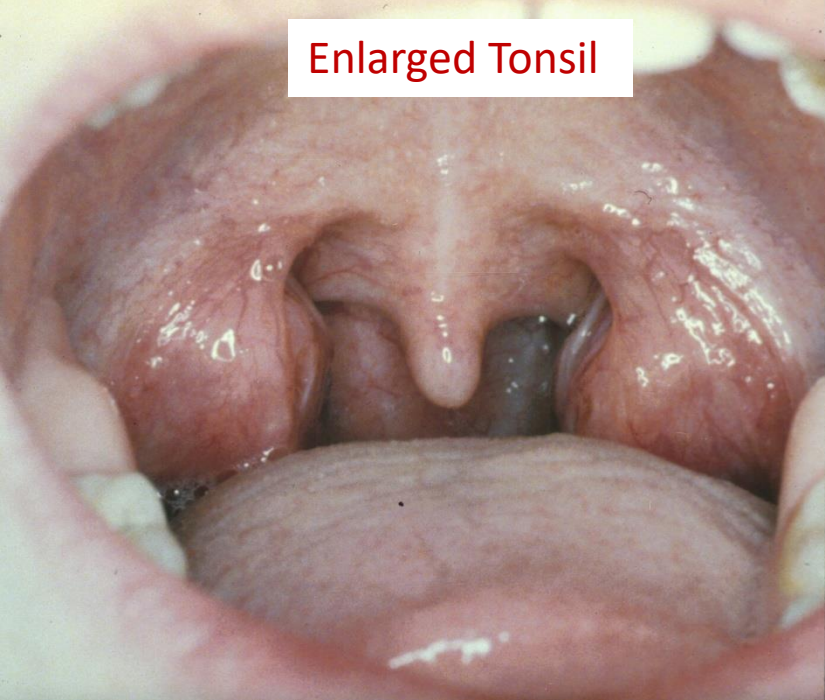


Normal tonsils

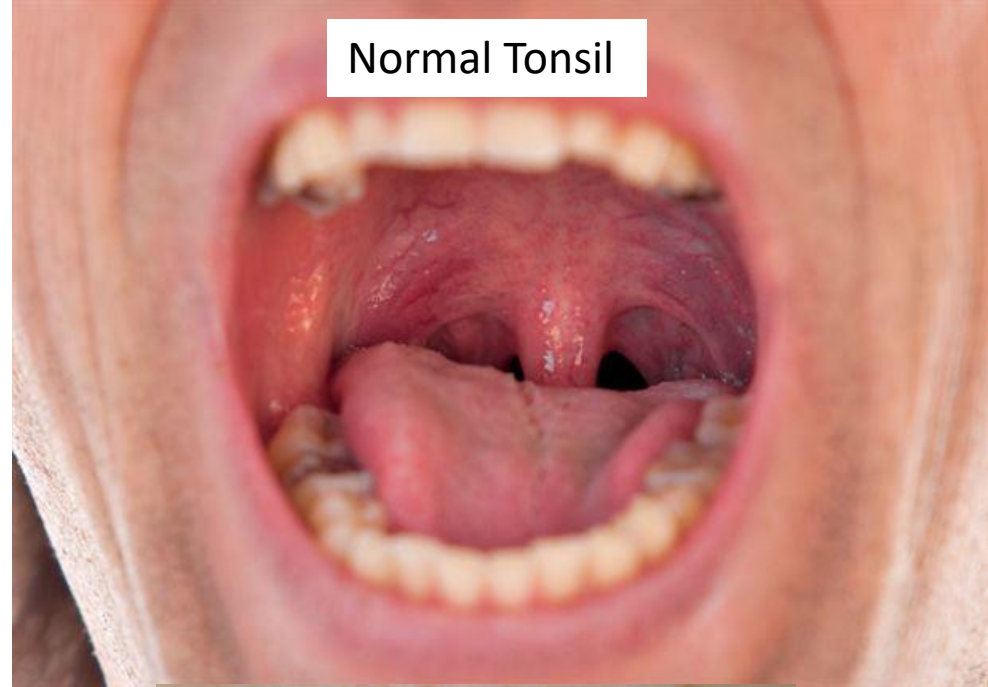Inflamed tonsils



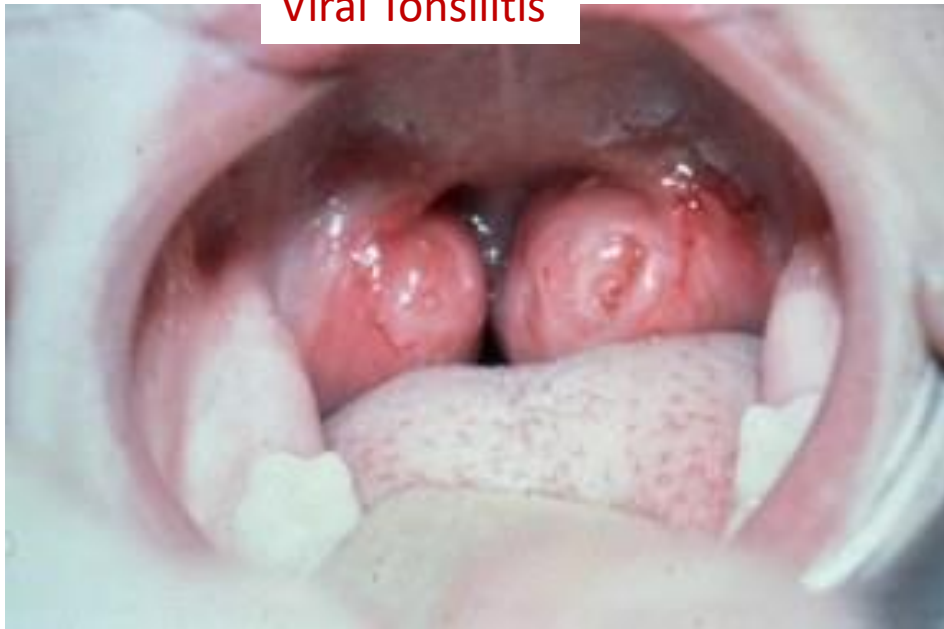Enlarged Tonsil



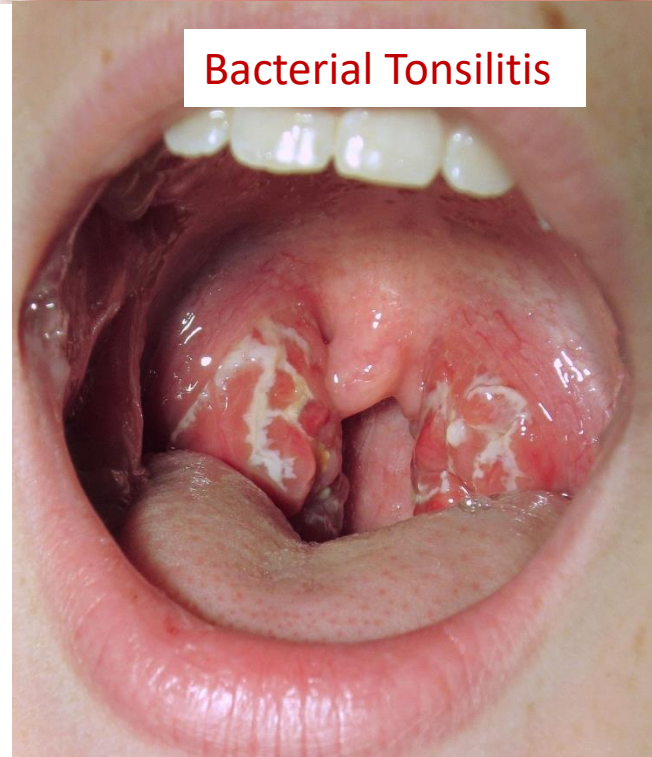Normal Tonsil

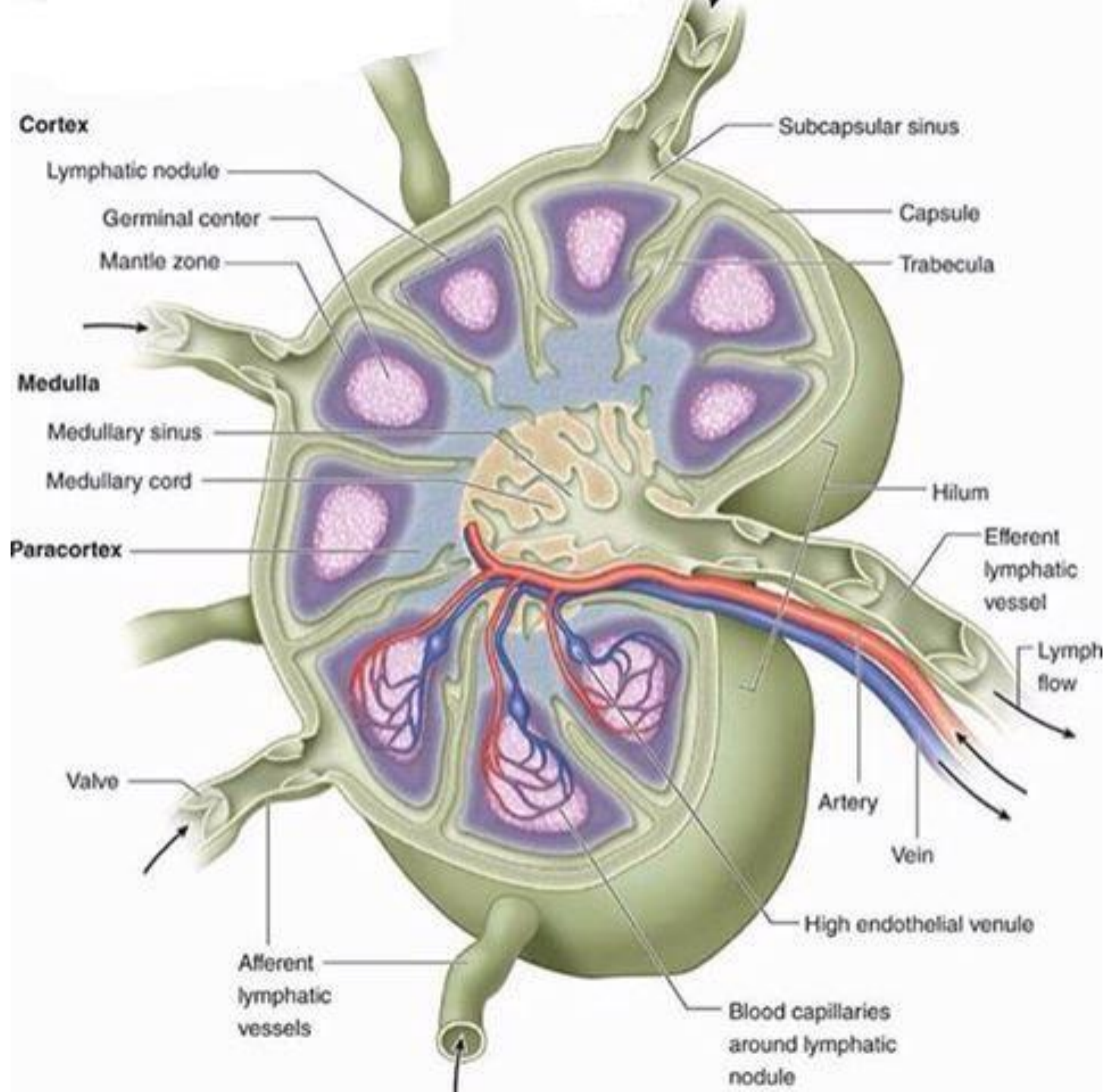


Viral Tonsillitis



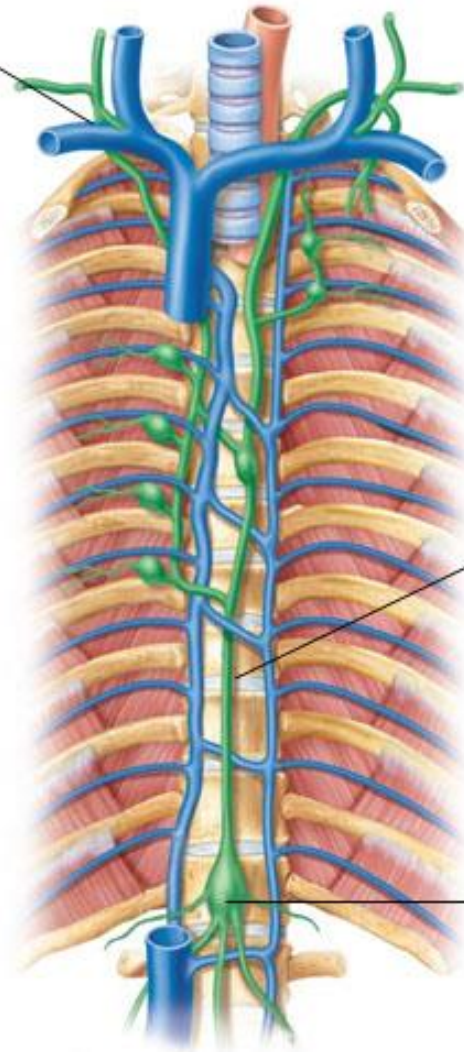
Bacterial Tonsillitis





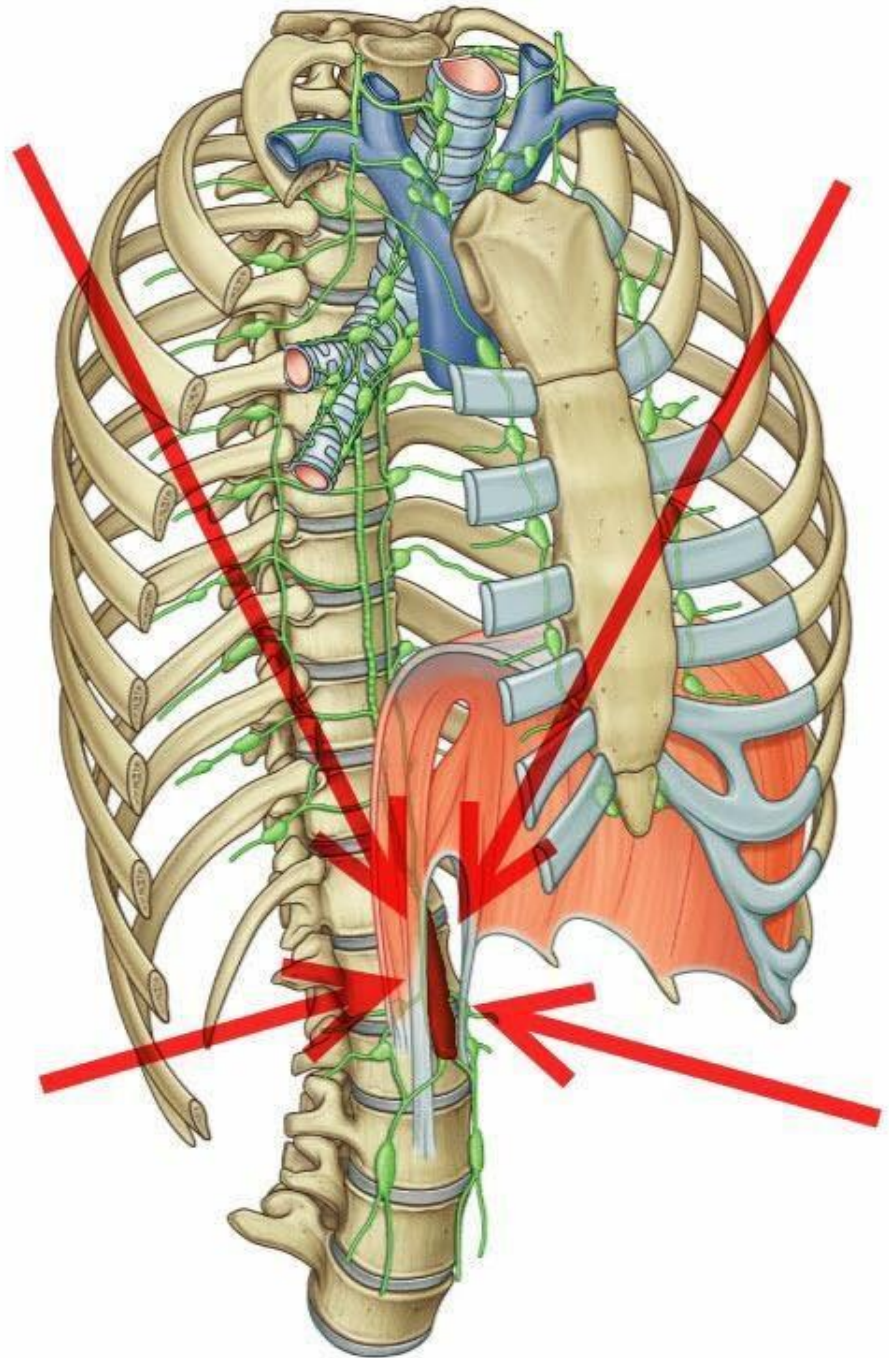
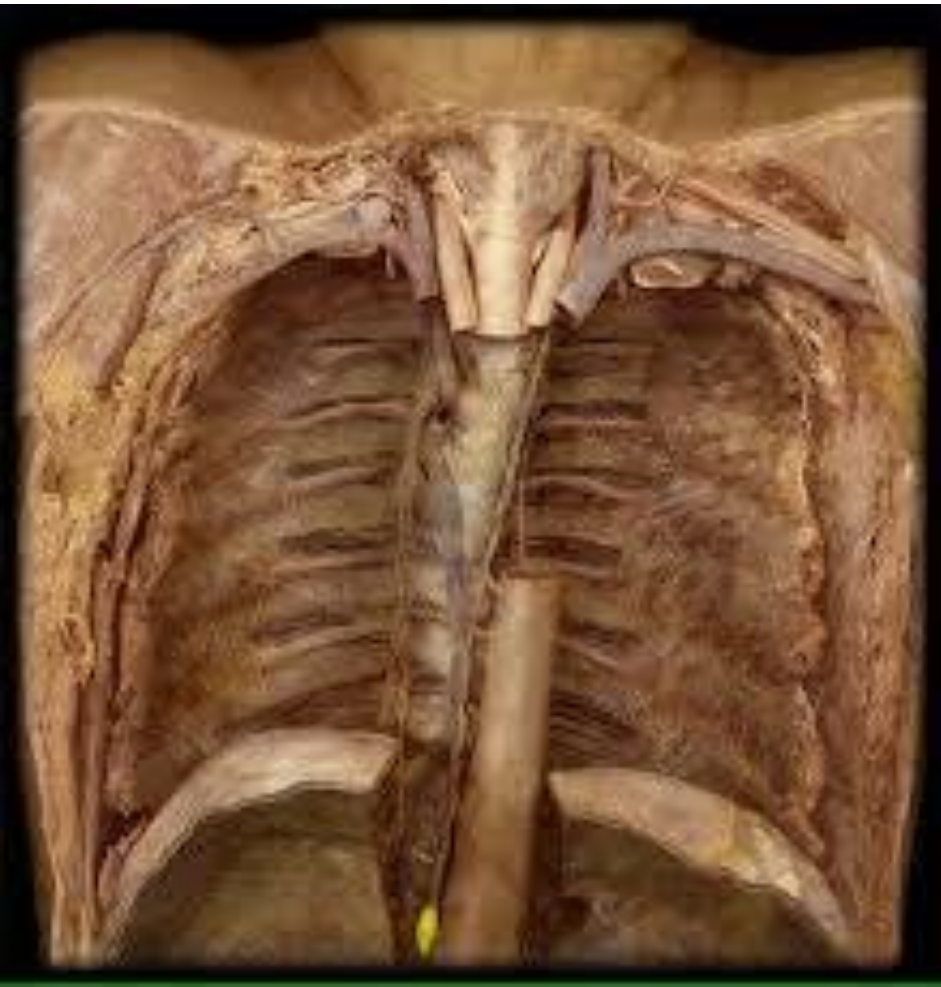Lymphatic Ducts

Right Lymphatic Duct empties at junction of right internal jugular and right subclavian veins

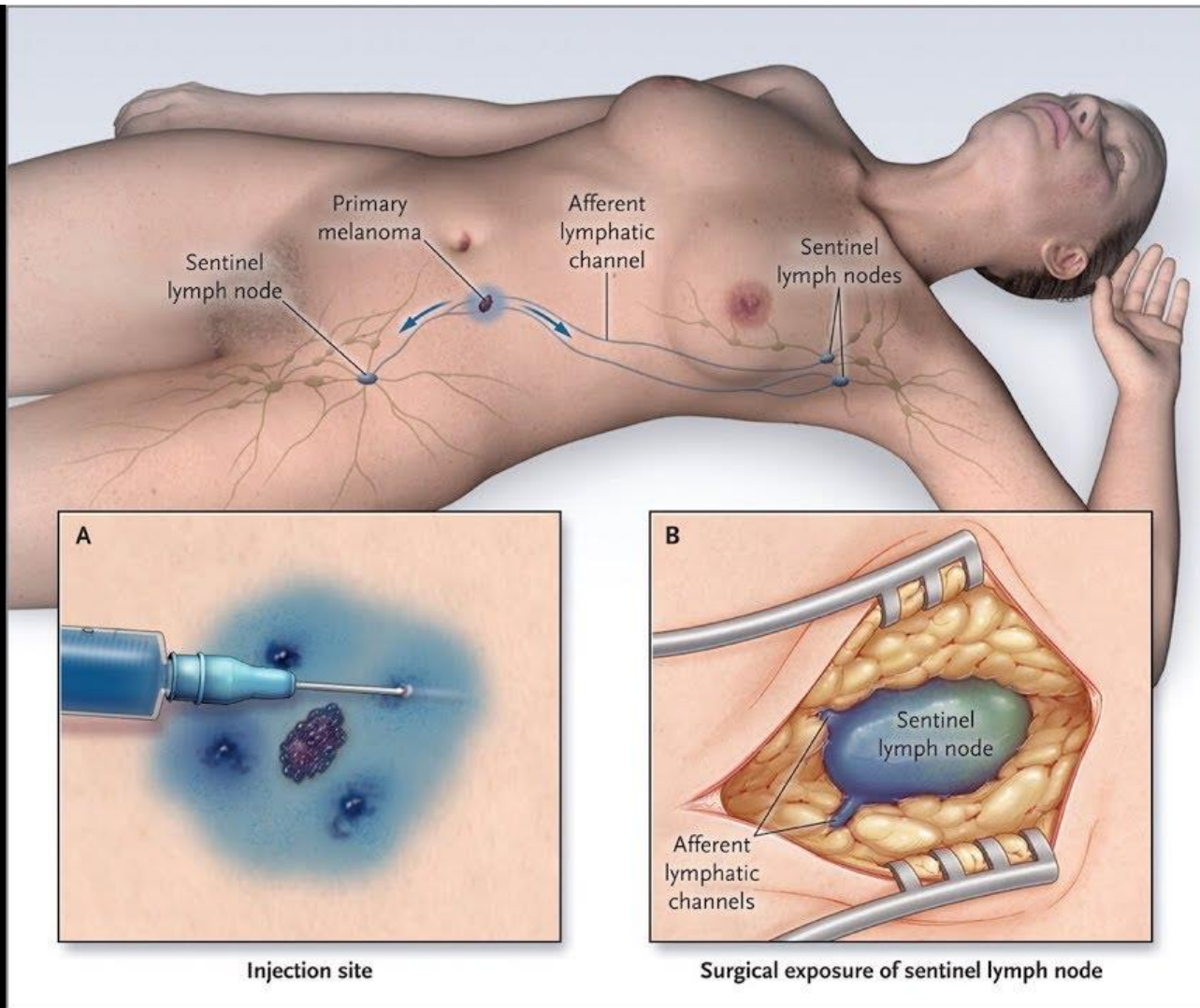


Thoracic Duct - empties into junction of left internal jugular and left subclavian veins

Cisterna Chyli – most inferior part of thoracic duct



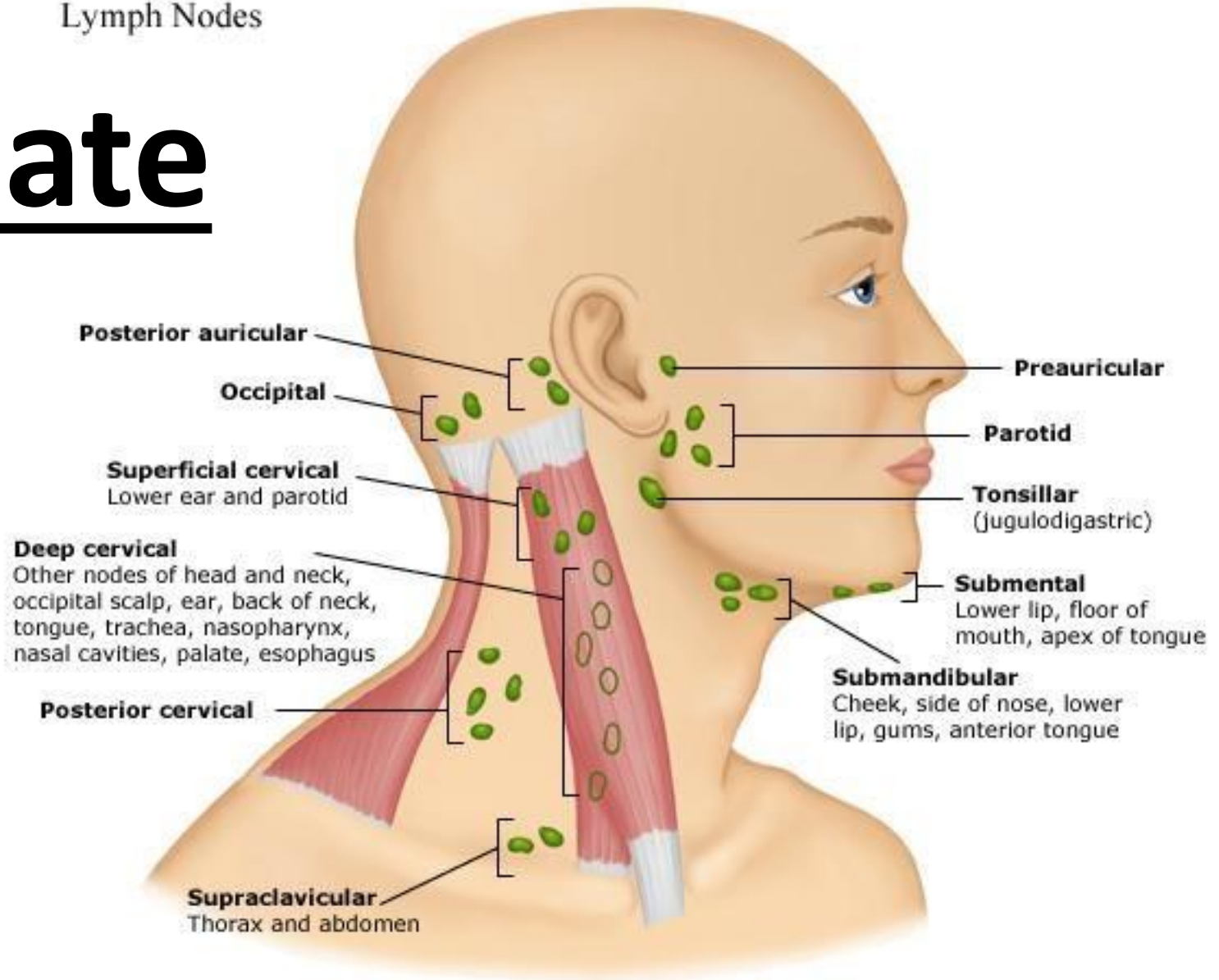
Practical concept of “sentinel Lymph node

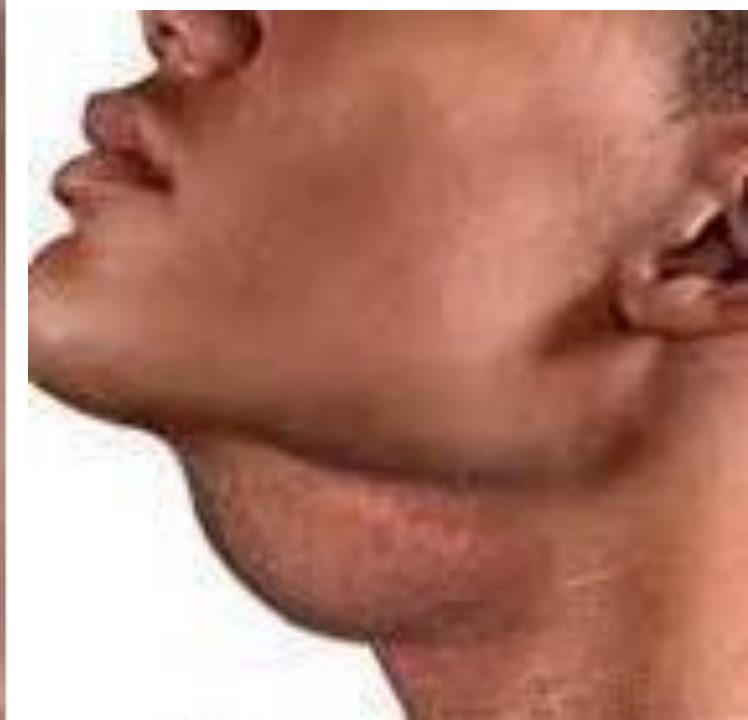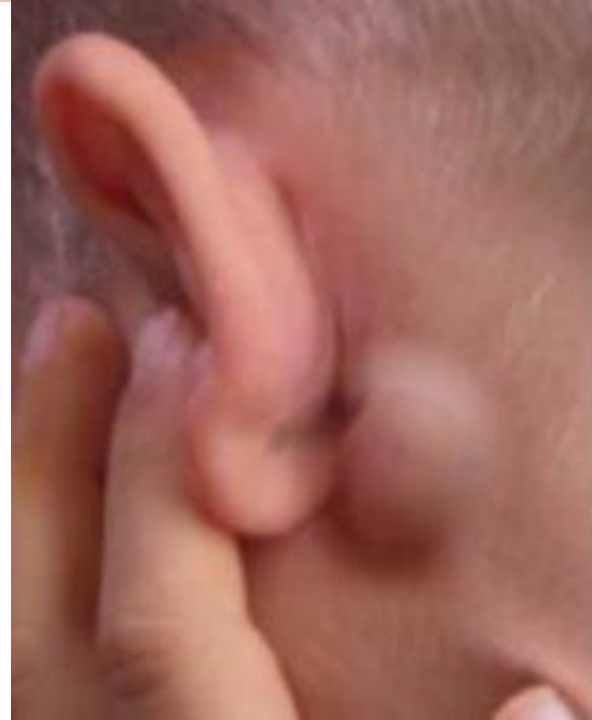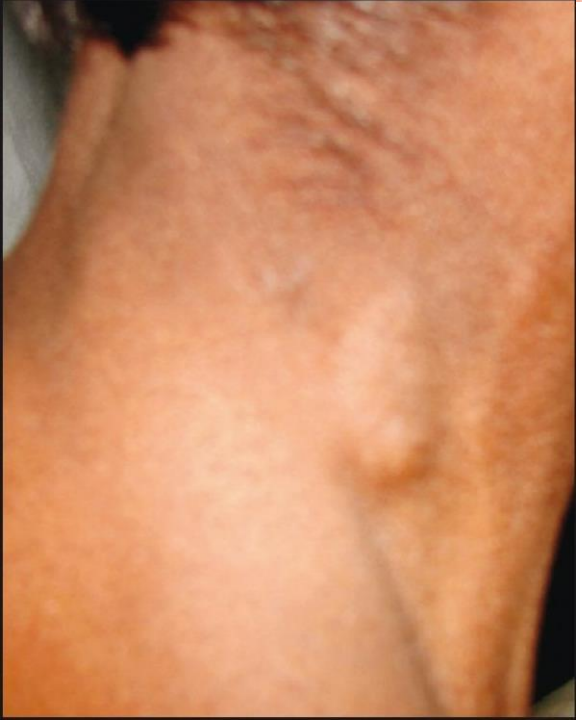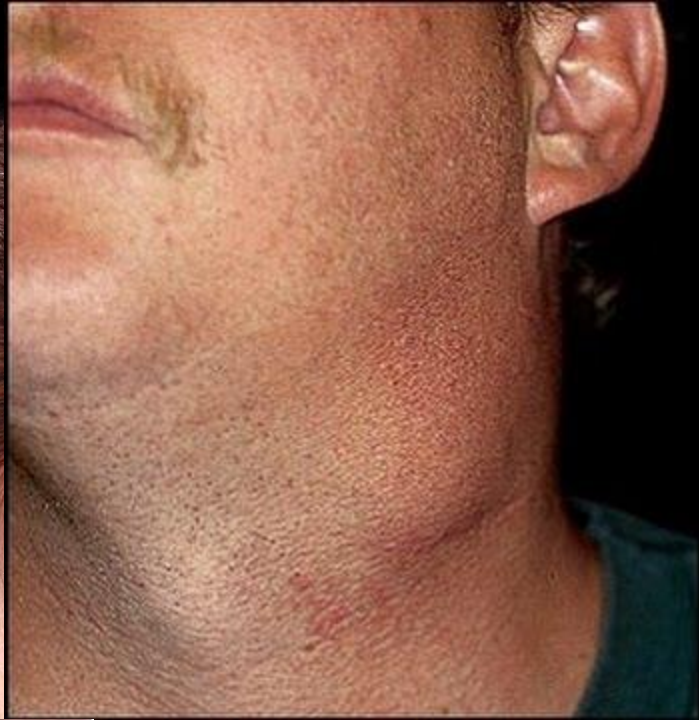


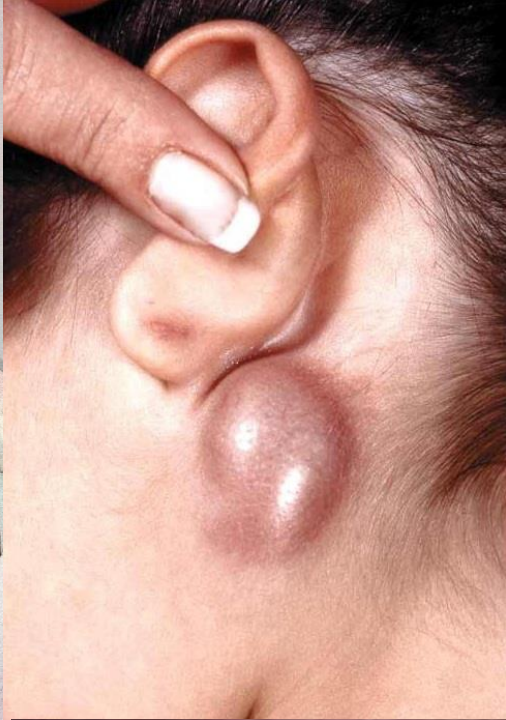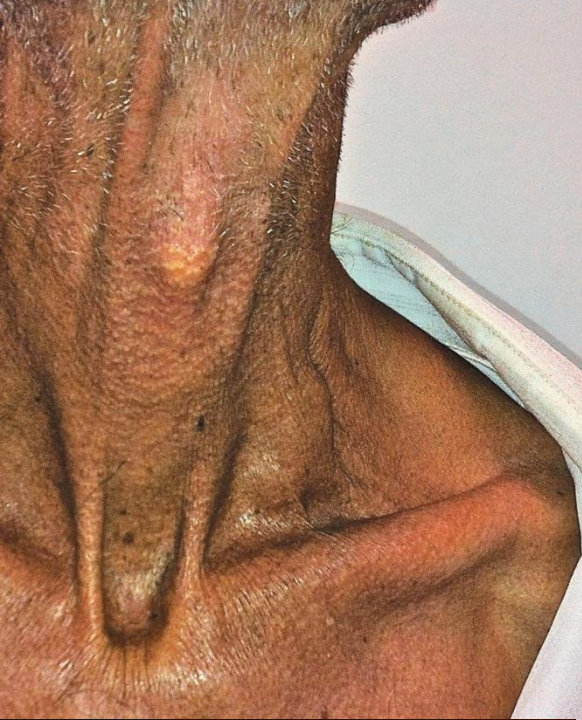Palpable Lymph Nodes

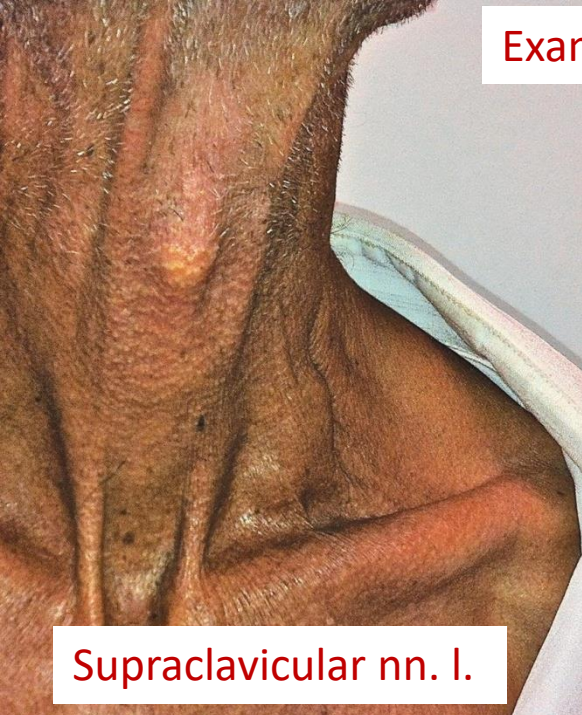
Lymph Nodes

Palpate

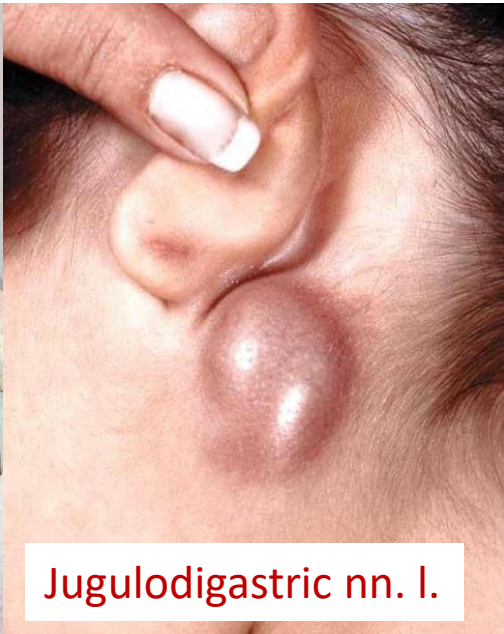




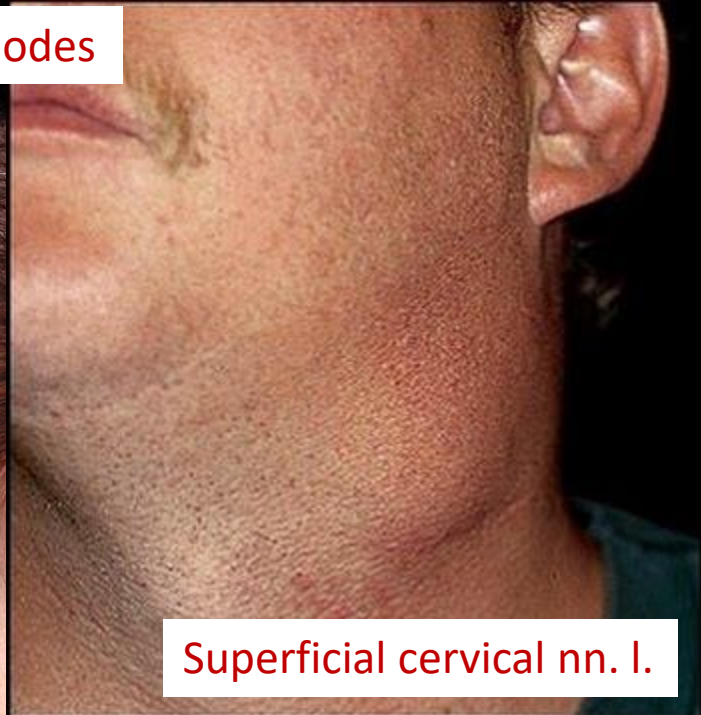
Examples of enlarged lymph nodes



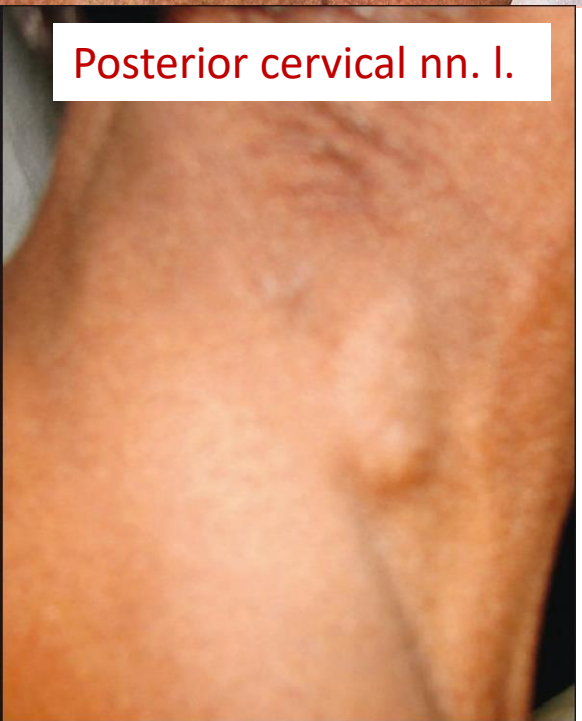Supraclavicular nn. I.



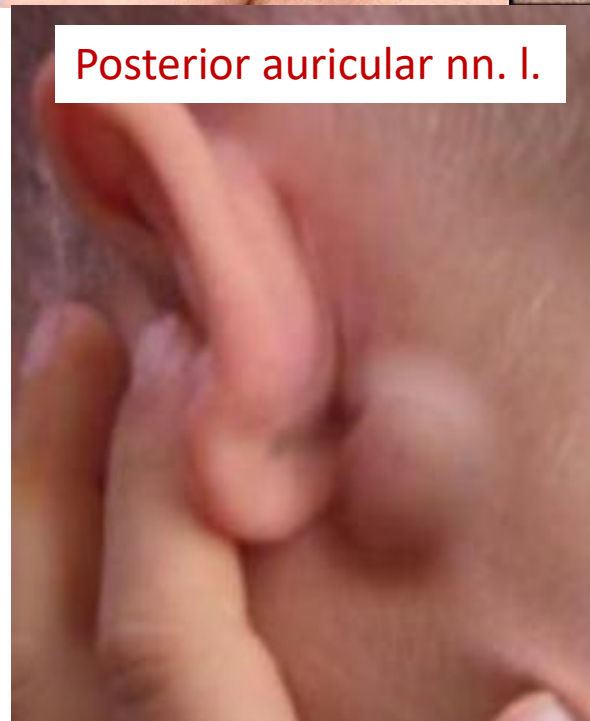Jugulodigastric nn. I.



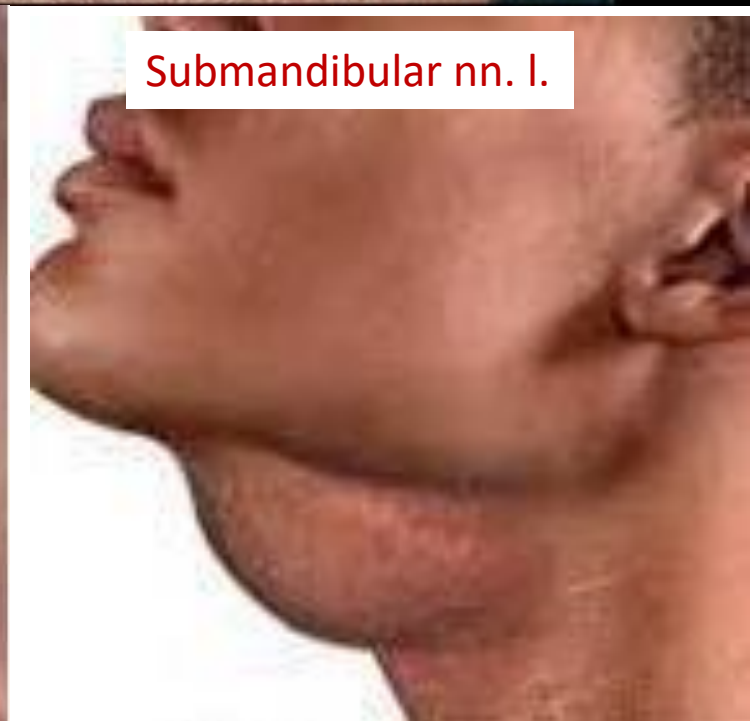
Superficial cervical nn. I.



Posterior cervical nn. I.

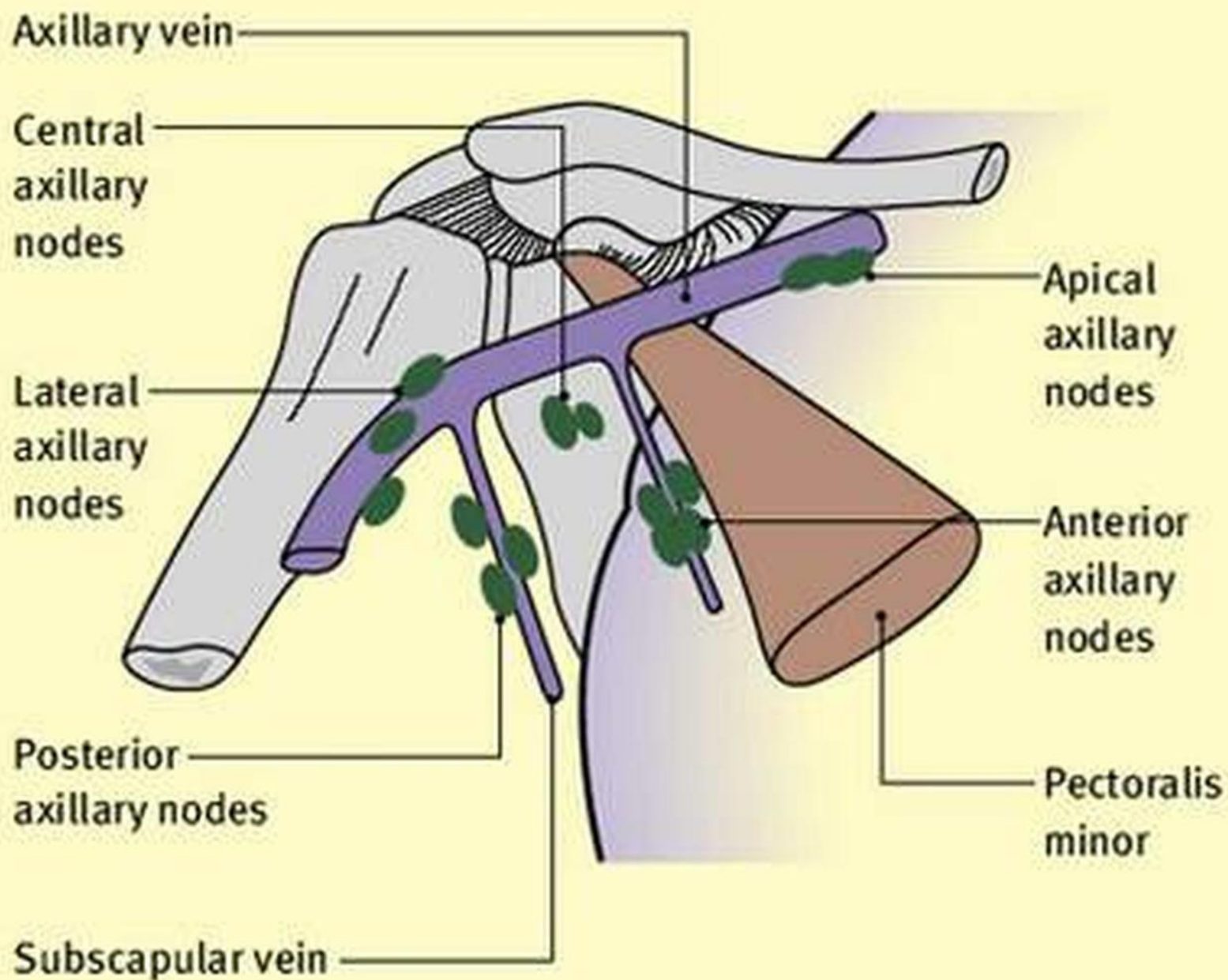


Posterior auricular nn. I.



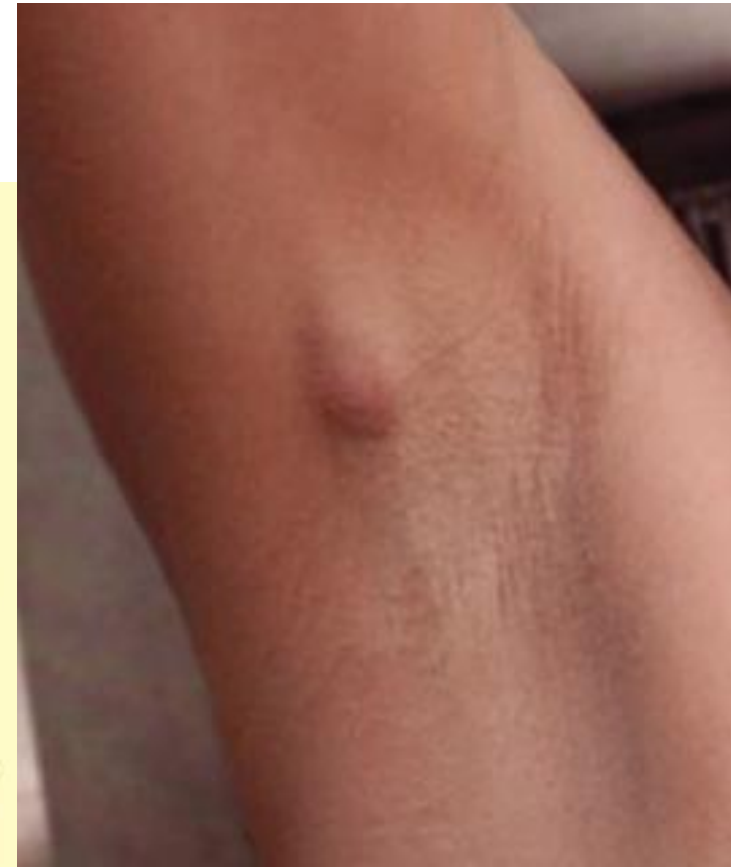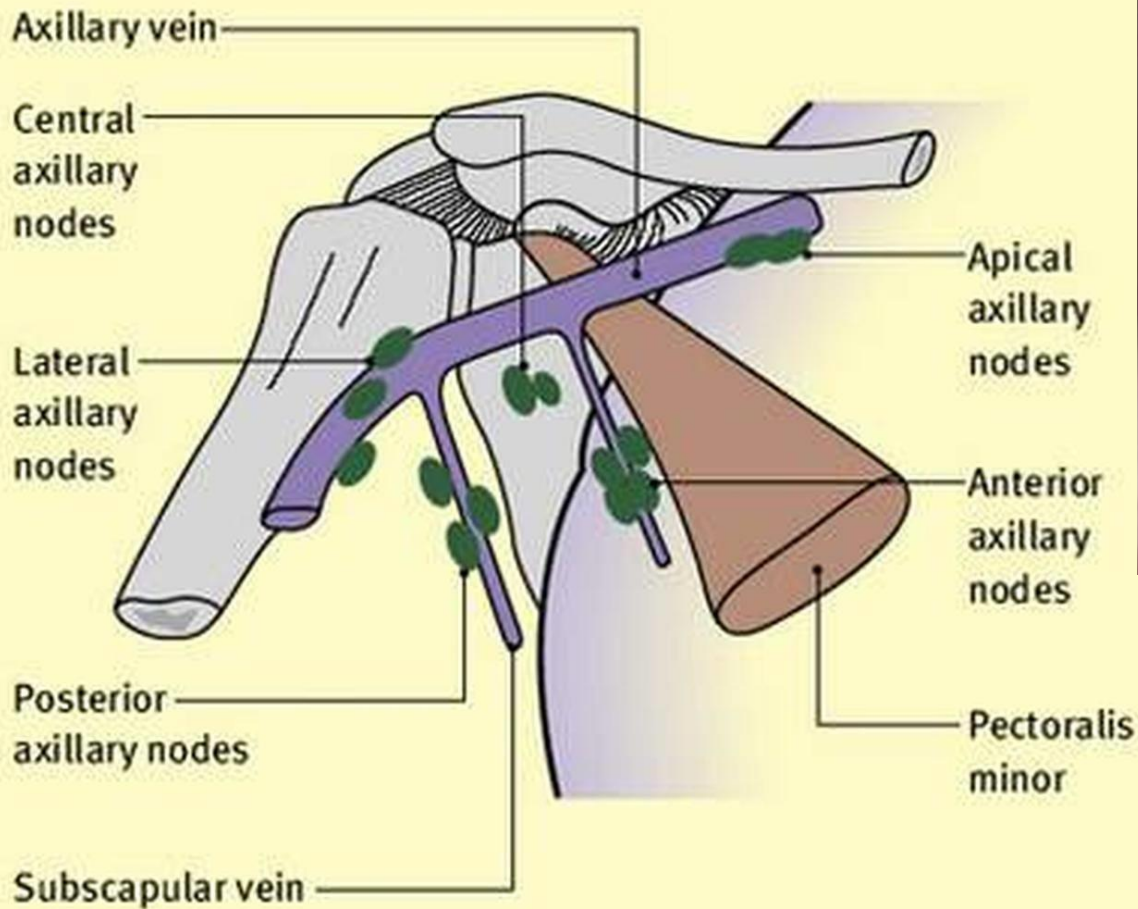
Submandibular nn. I.

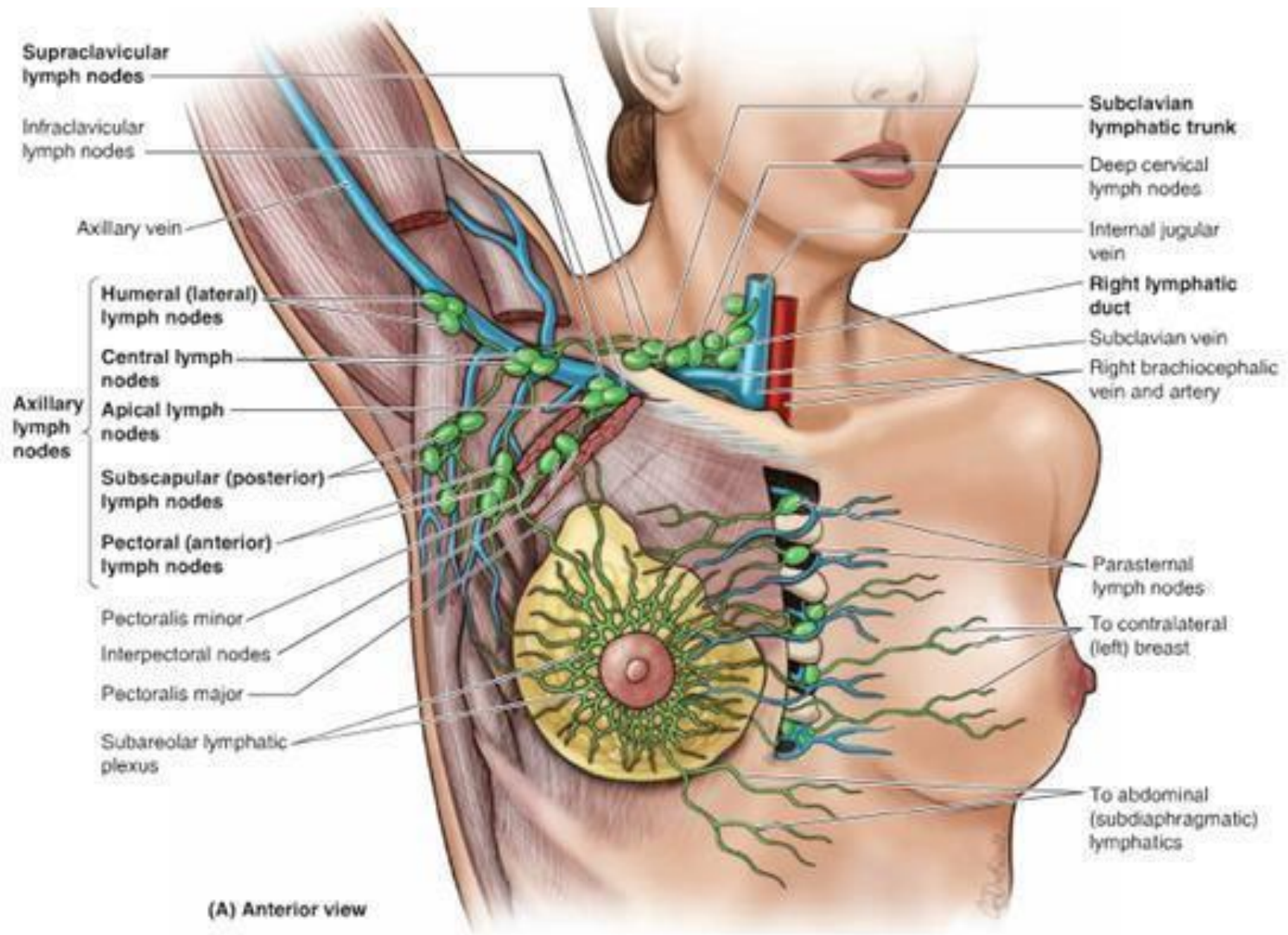
Lymph nodes of the axilla



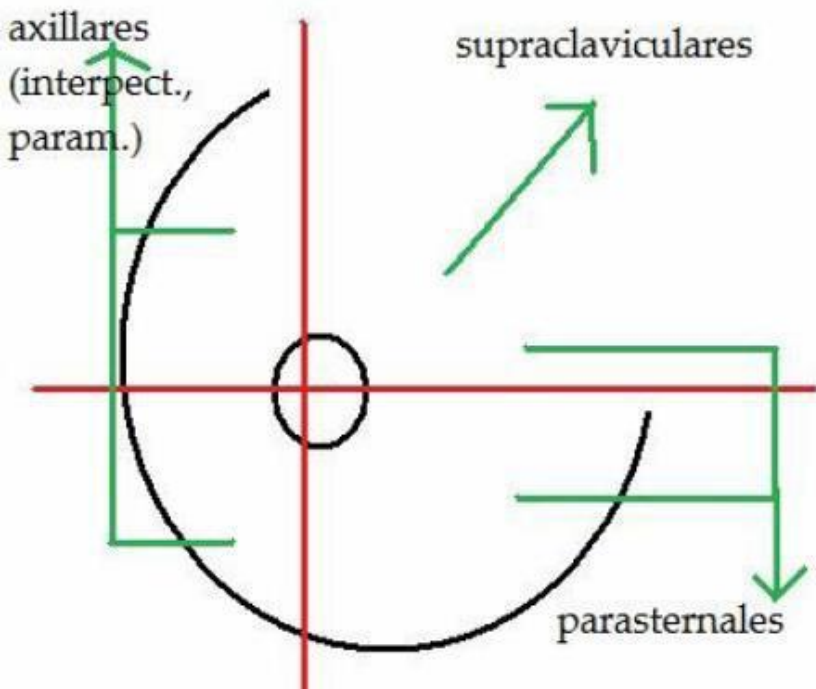
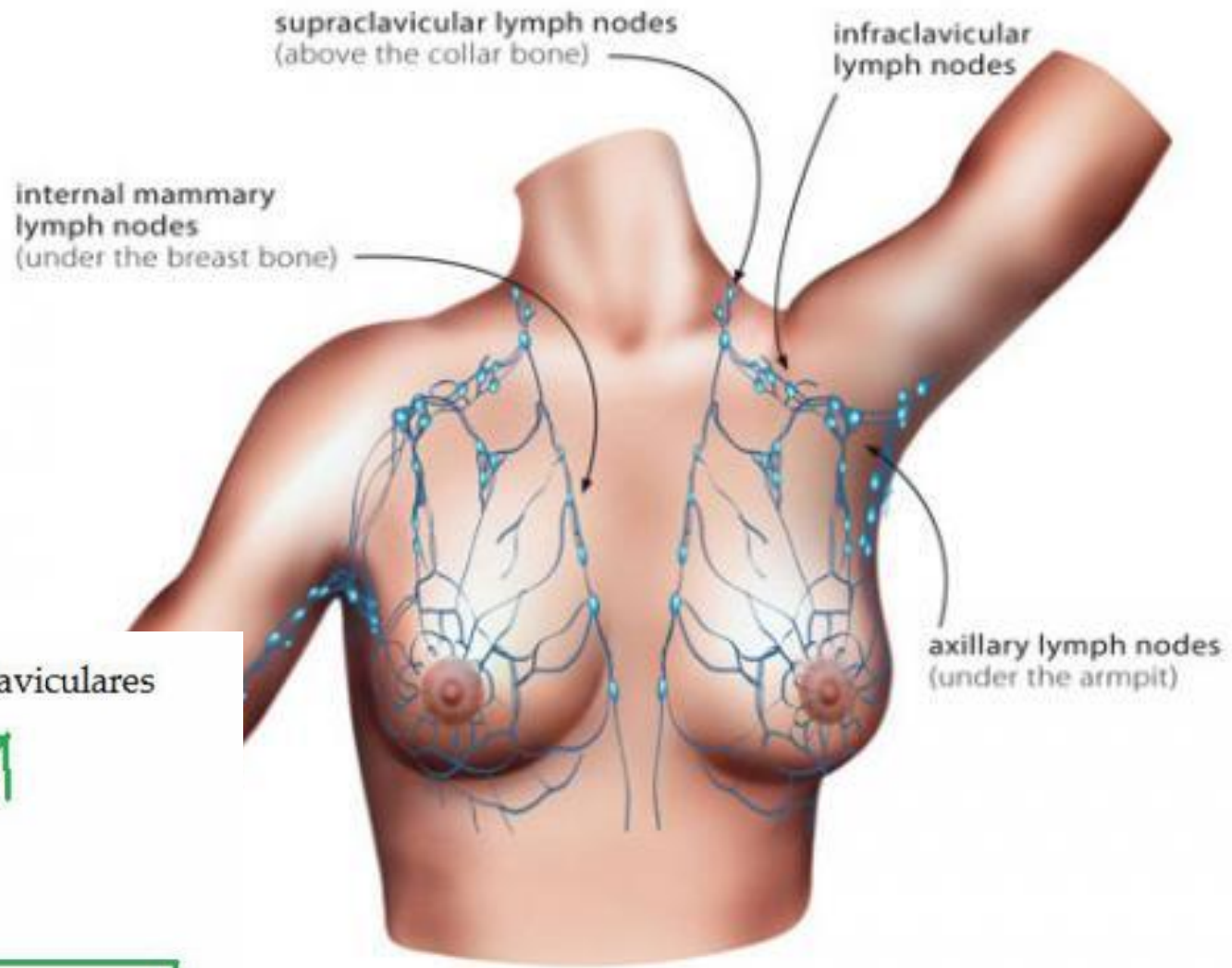
Example of an enlarged lymph node- lateral axillary nn. I.

Lymph nodes of the axilla



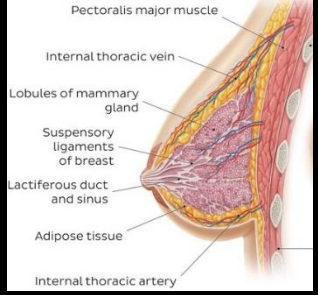


(A) Anterior view



Breast mammography

Pectoralis m.



R MLO Axillary LN

Primary Tumor

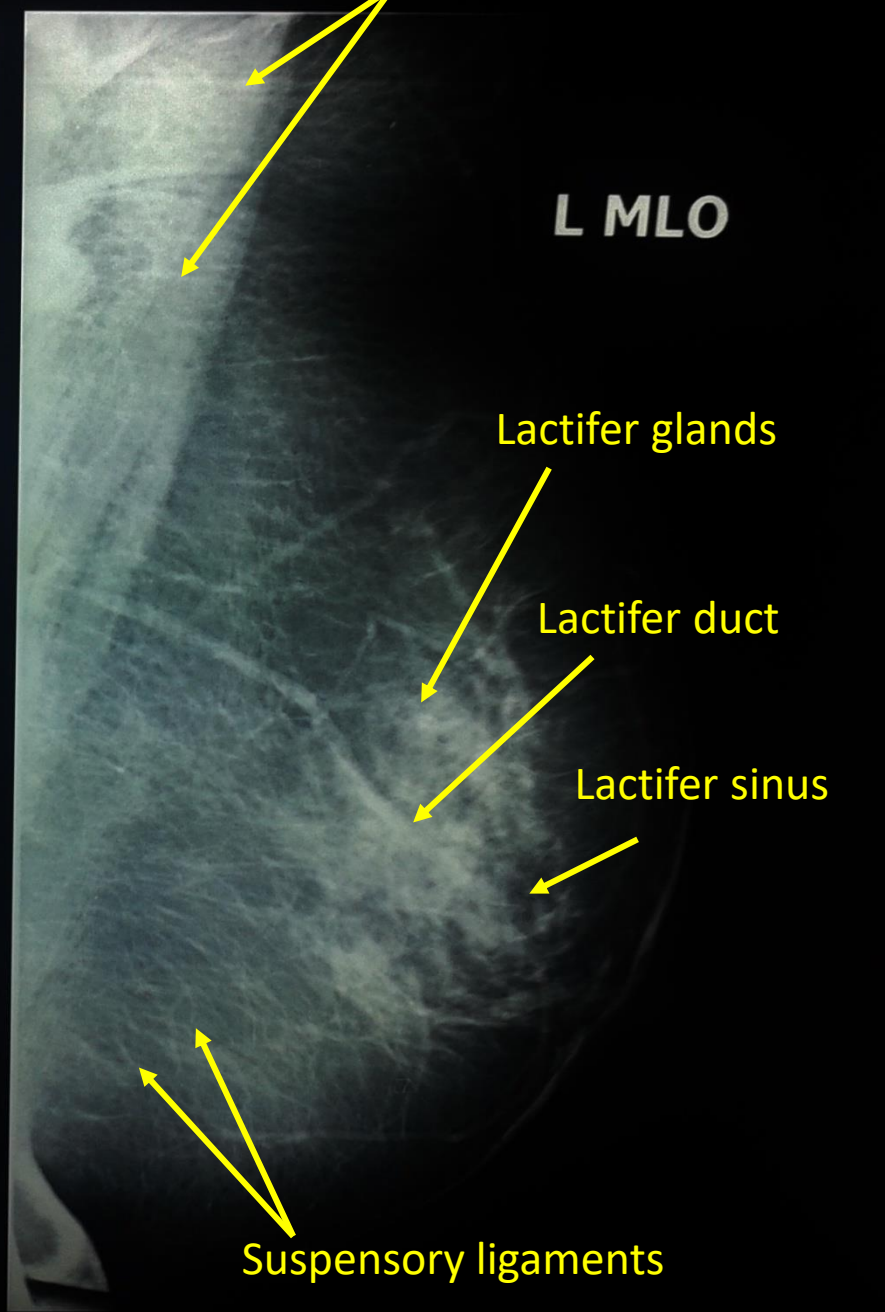
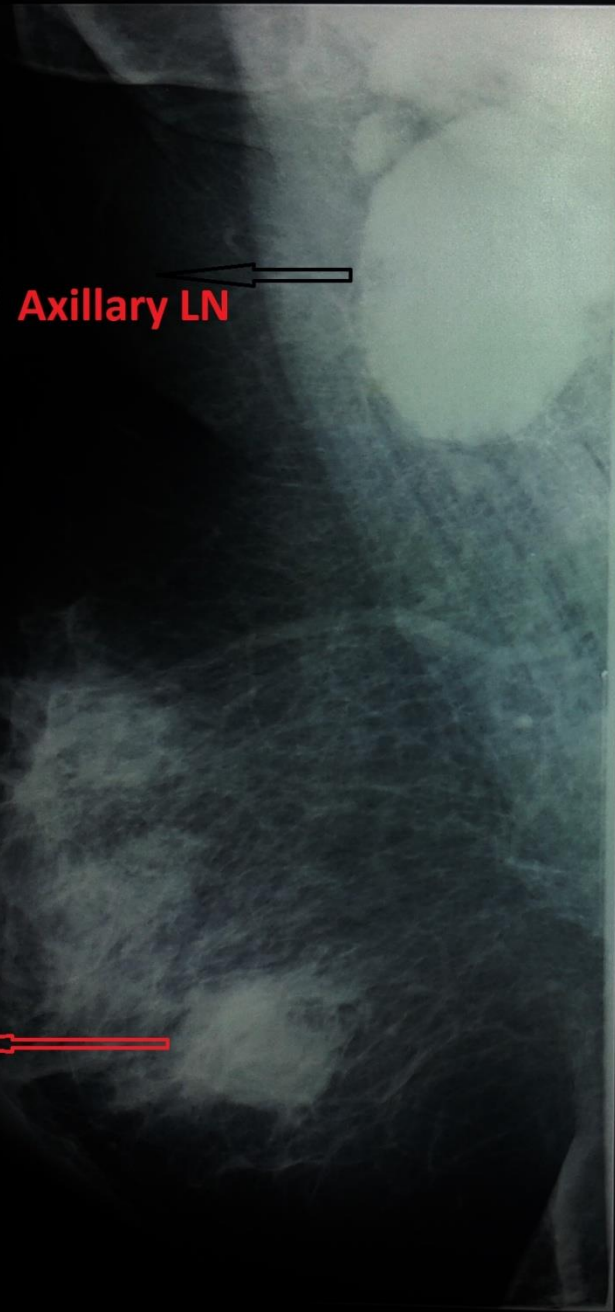
L MLO

Lactifer glands

Lactifer duct

Lactifer sinus

Suspensory ligaments



Breast mammography

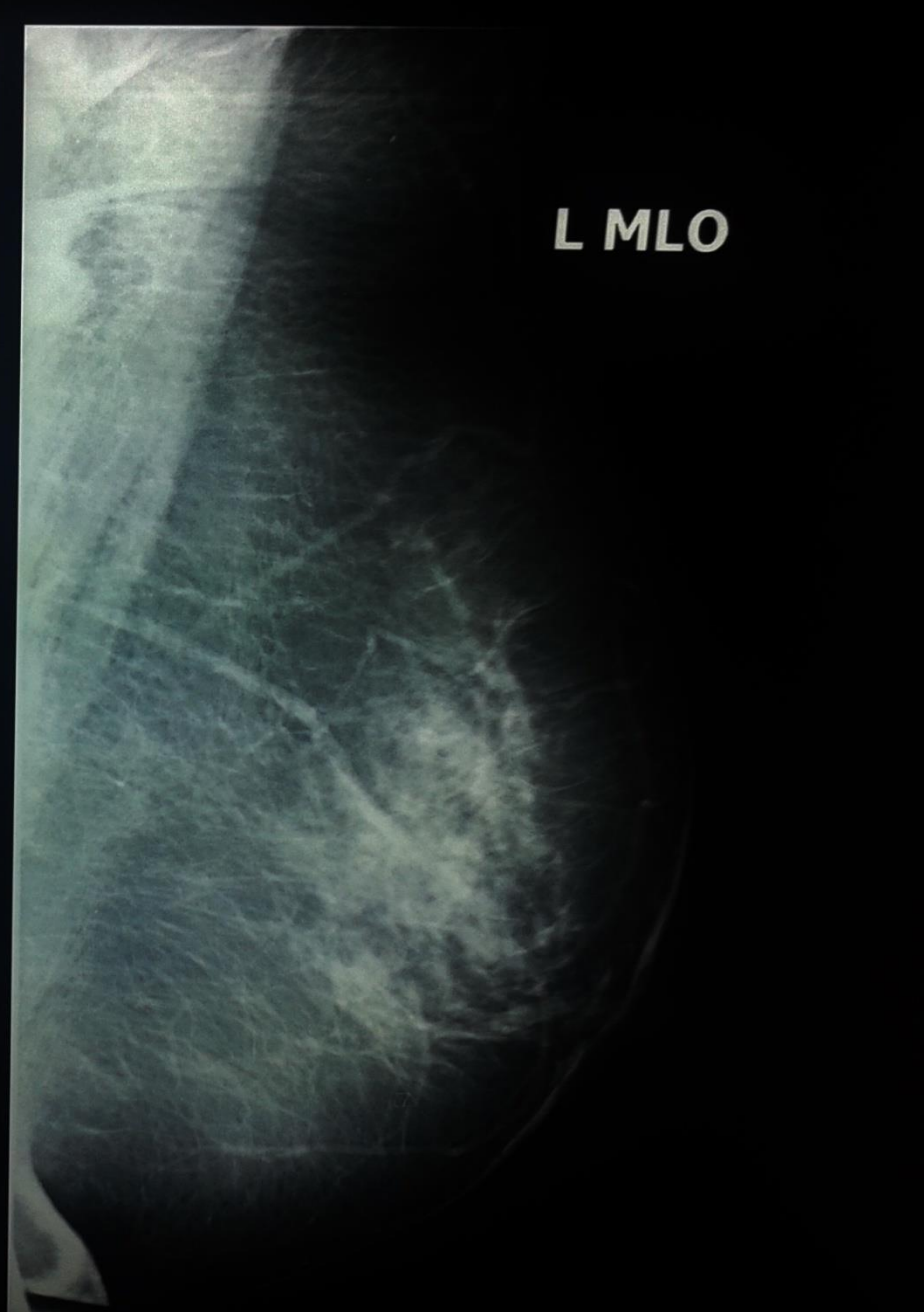
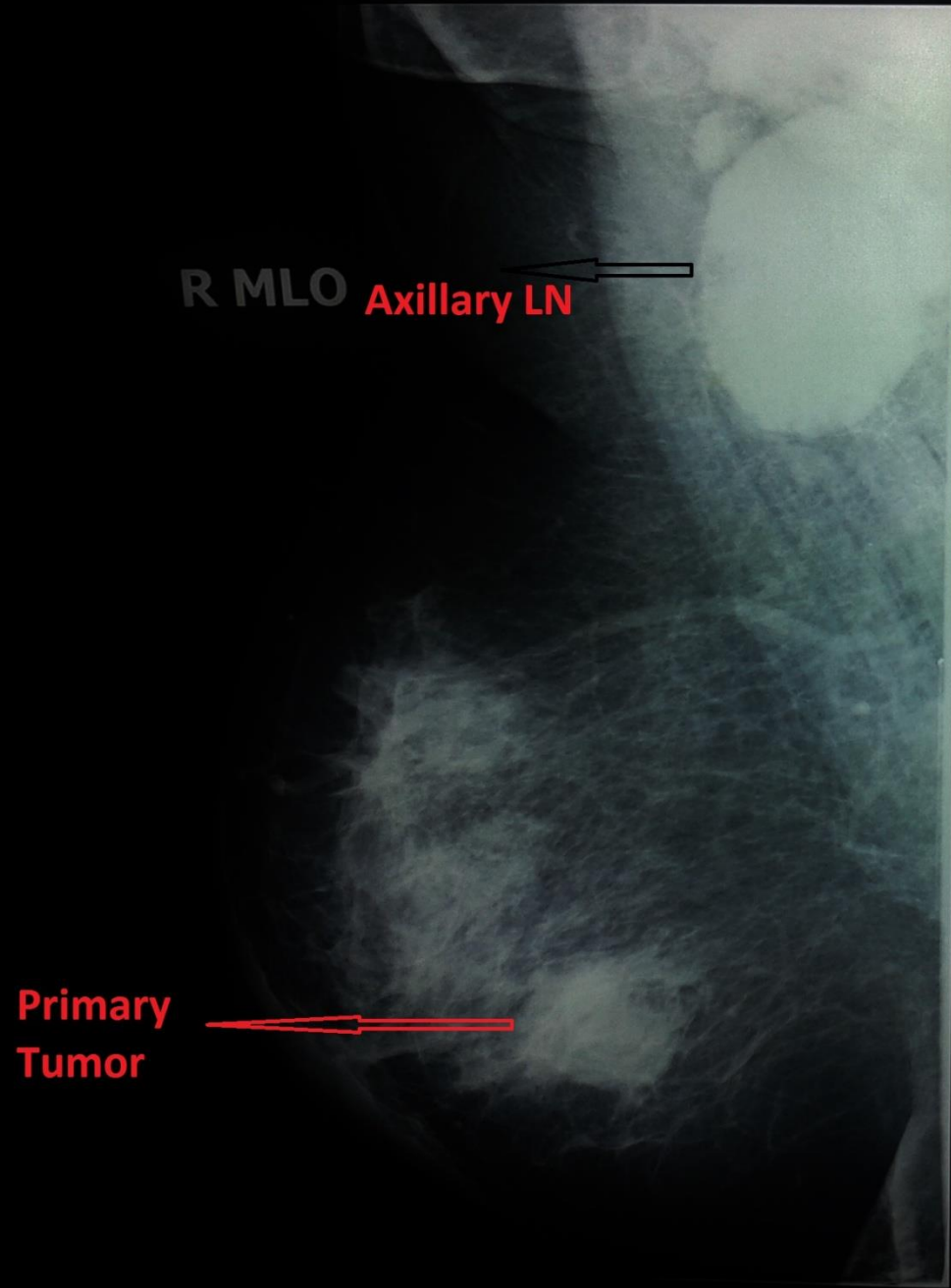
R MLO

Axillary LN



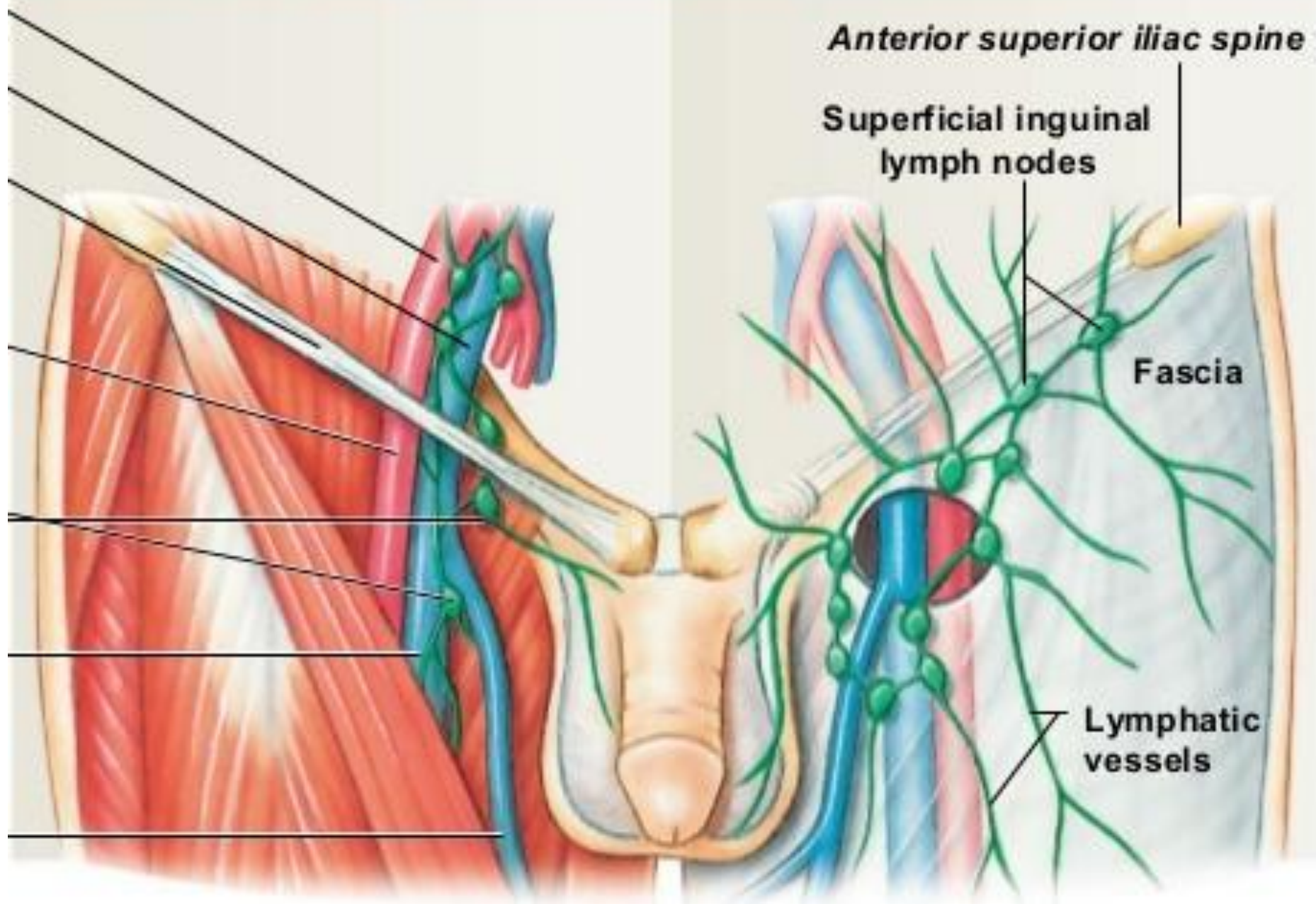
Primary Tumor

L MLO

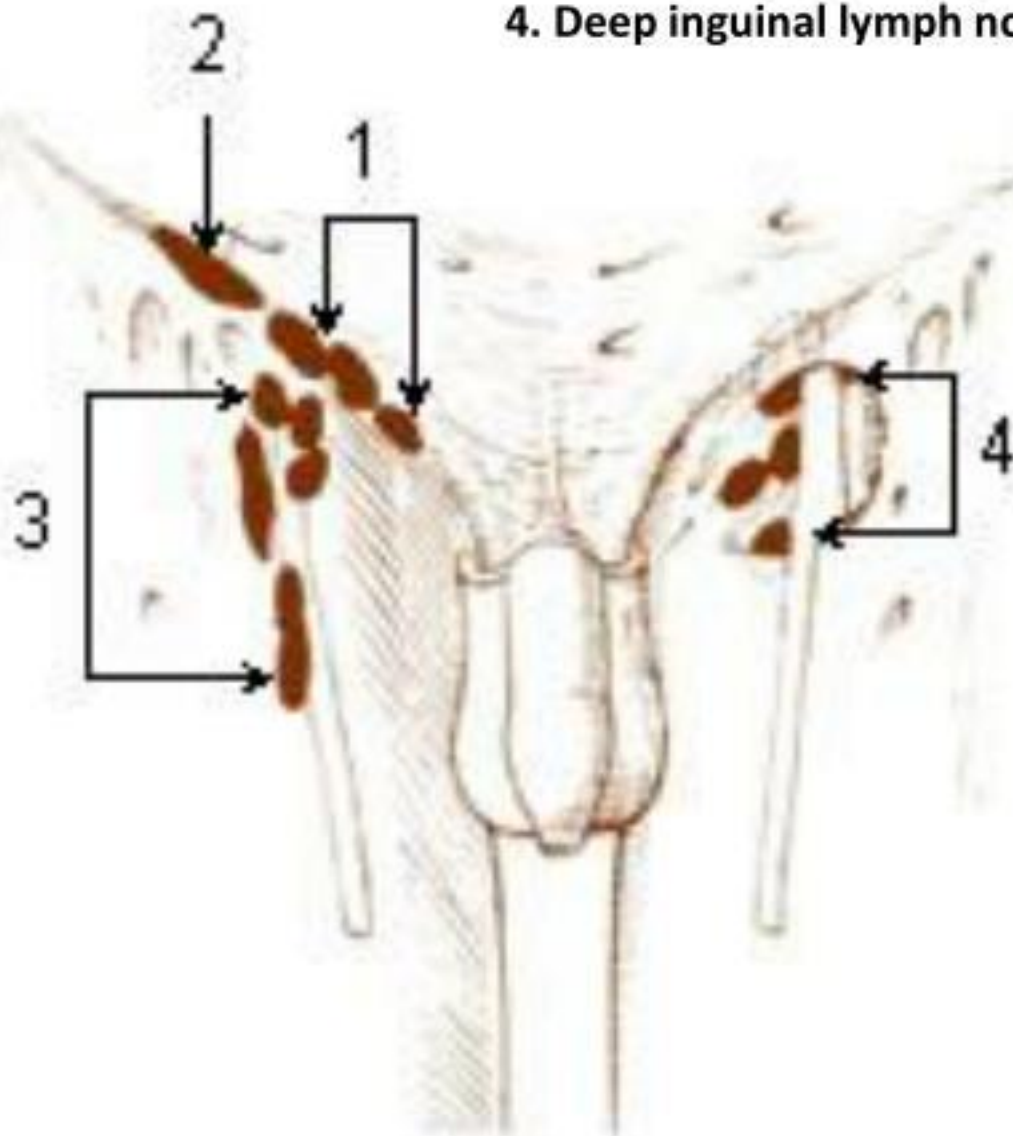


Deep Inguinal and Iliac Lymph Nodes

Superficial Inguinal Lymph Nodes



1. Superomedial superficial inguinal
2. Superolateral superficial inguinal
3. Inferior superficial inguinal
4. Deep inguinal lymph nodes



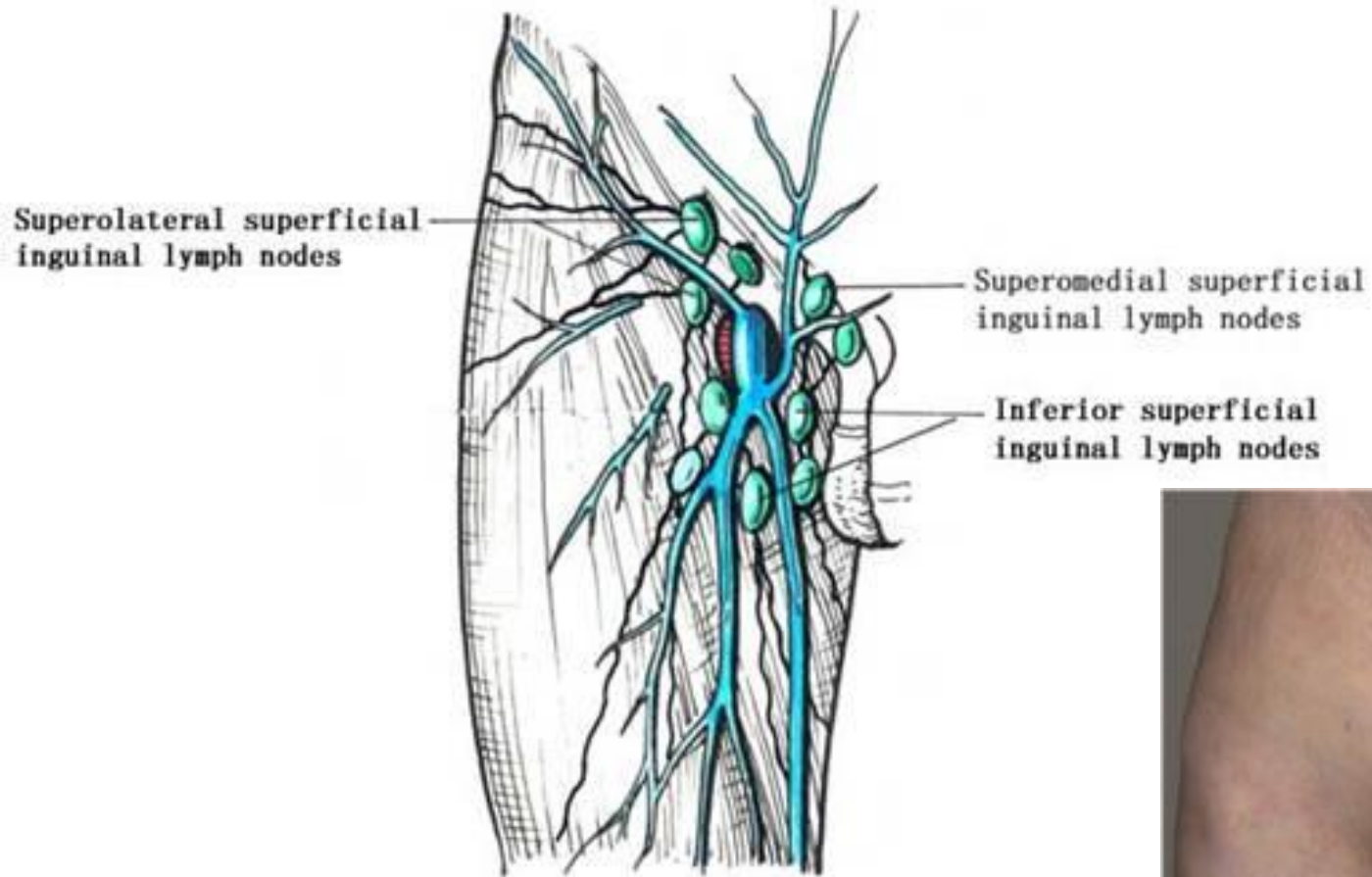
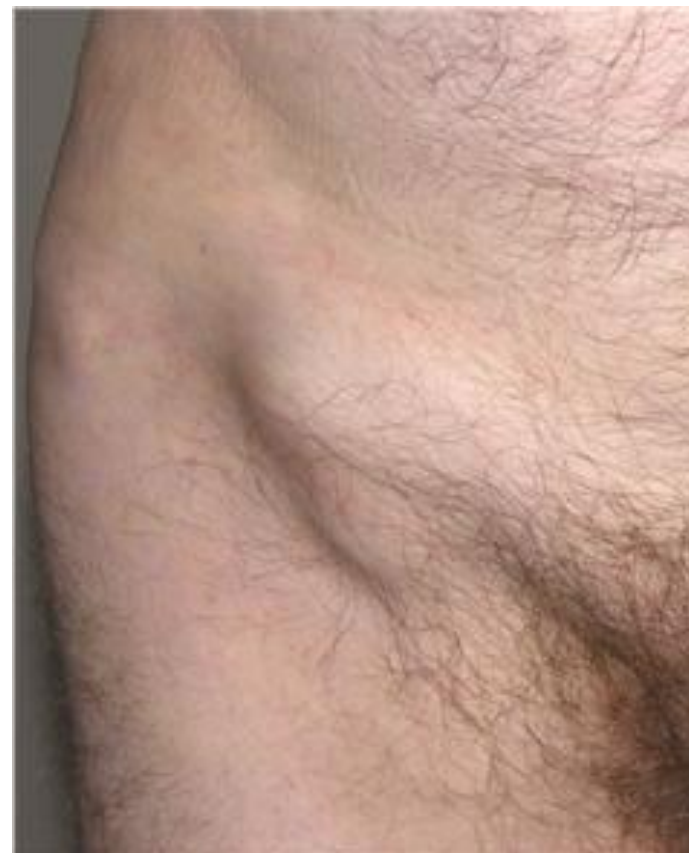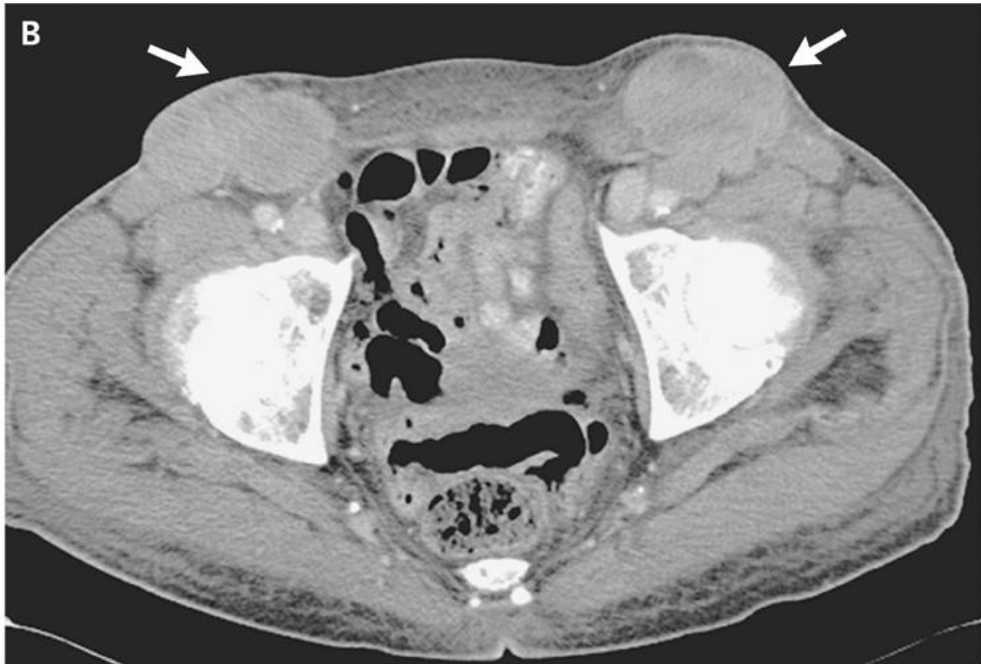
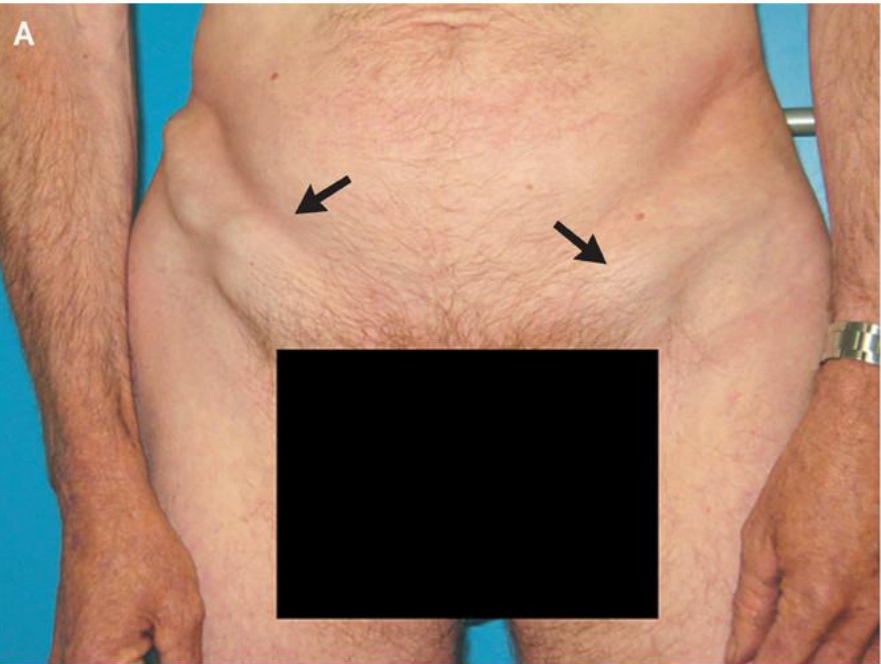


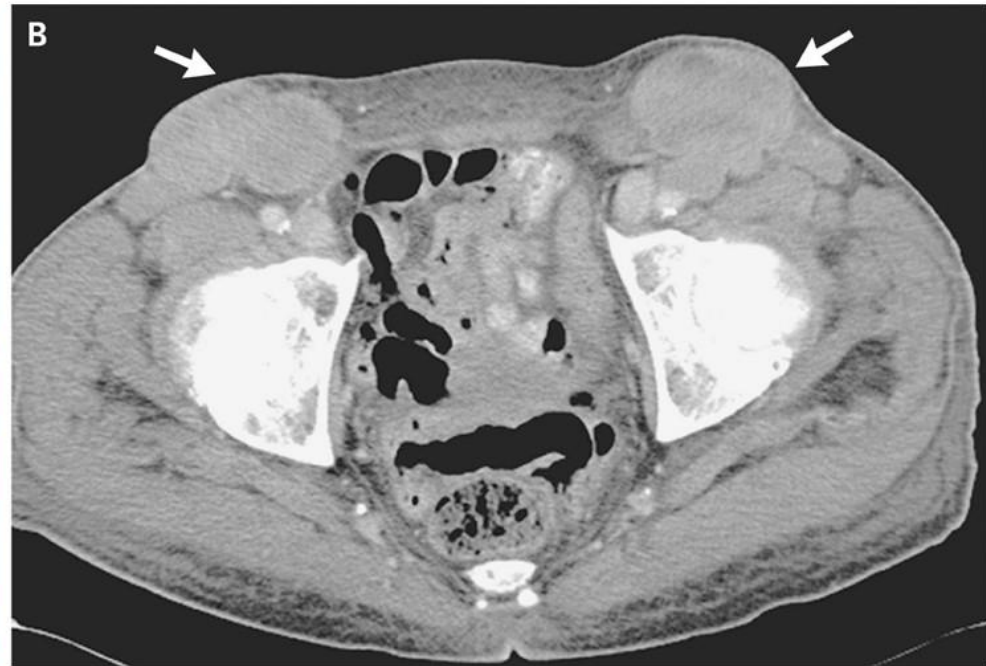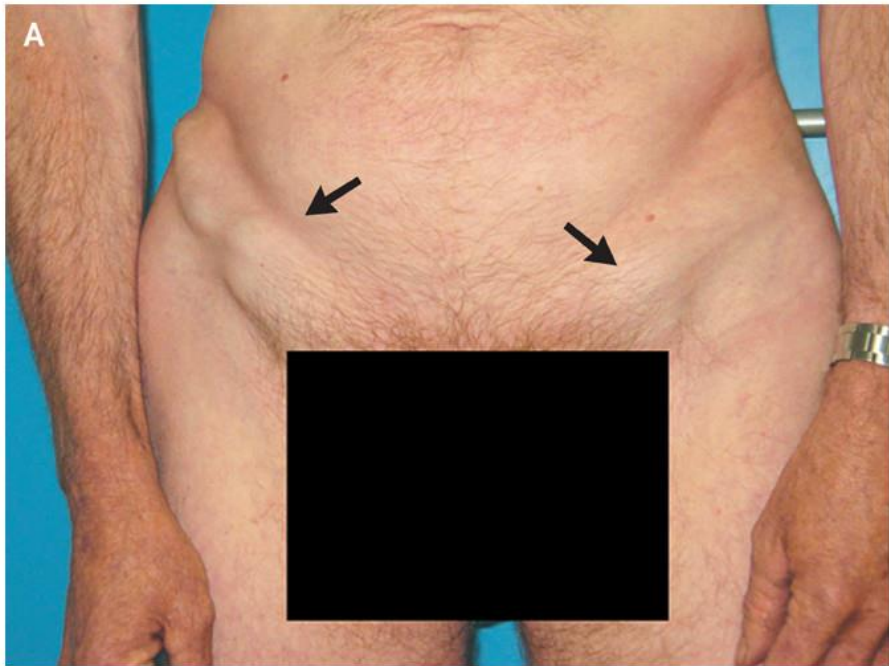Fig. 3-2-14 The superficial inguinal lymph nodes

Lymphadenopathy- enlarged superficial inguinal nn. I.



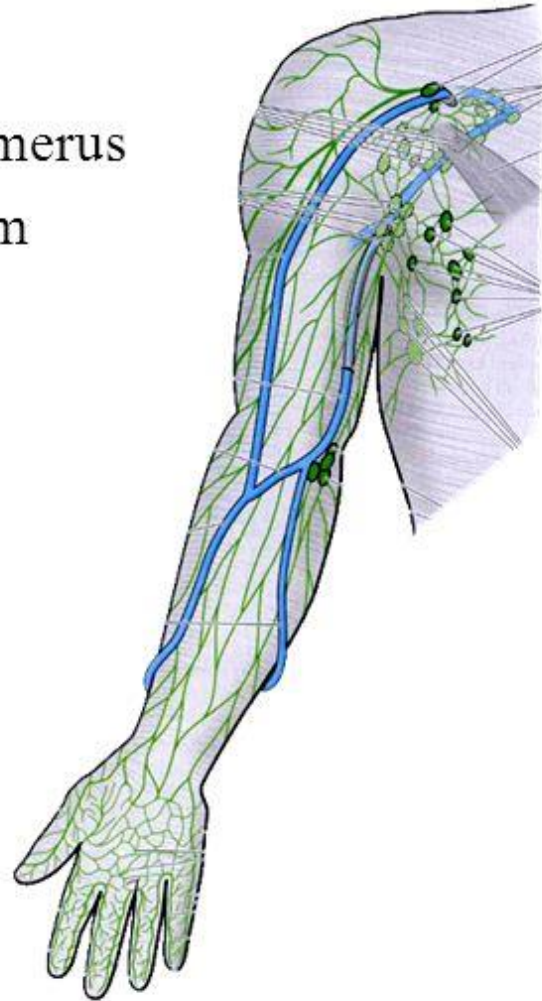


Lymphadenopathy- enlarged inguinal nn. I.

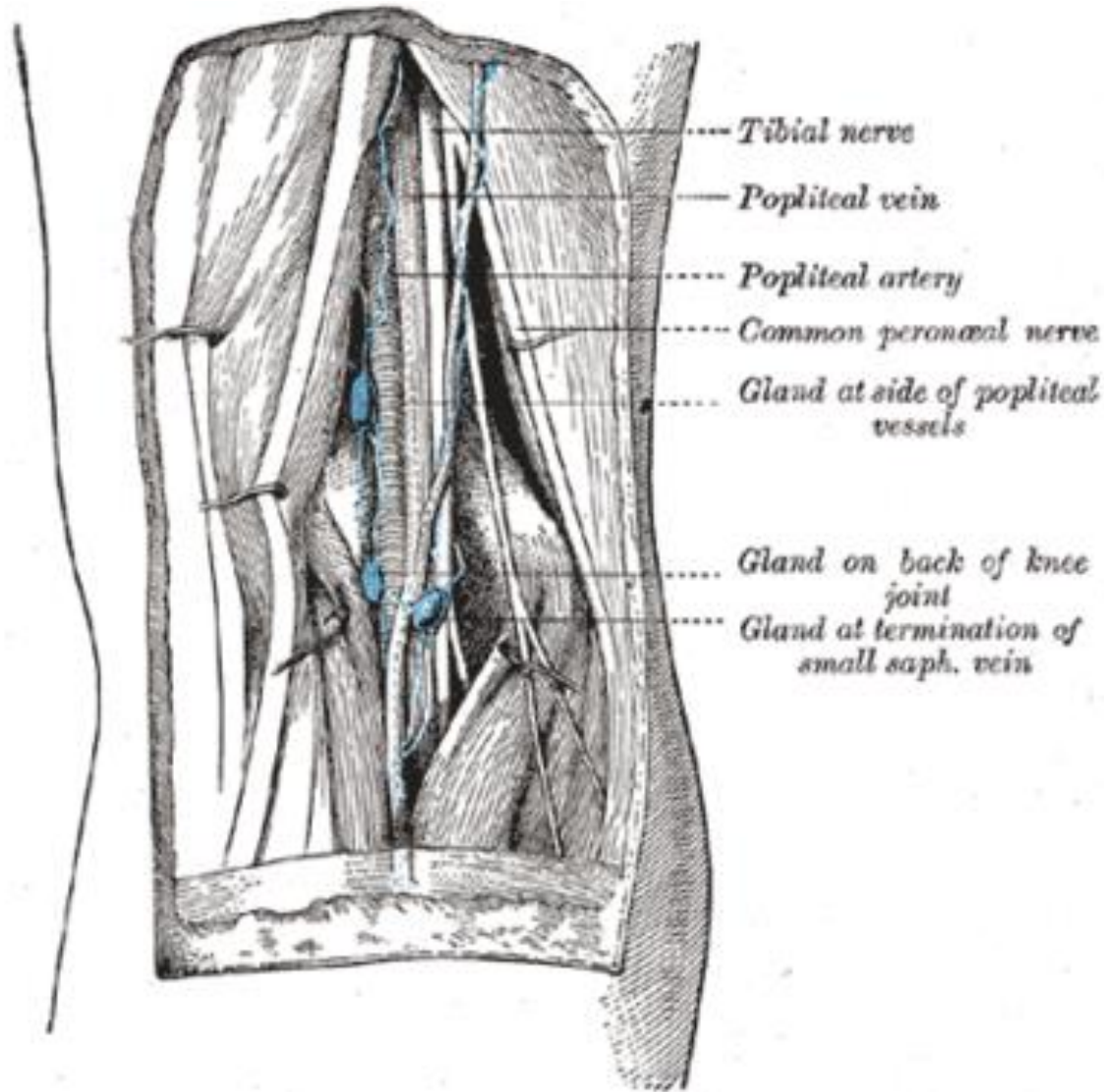


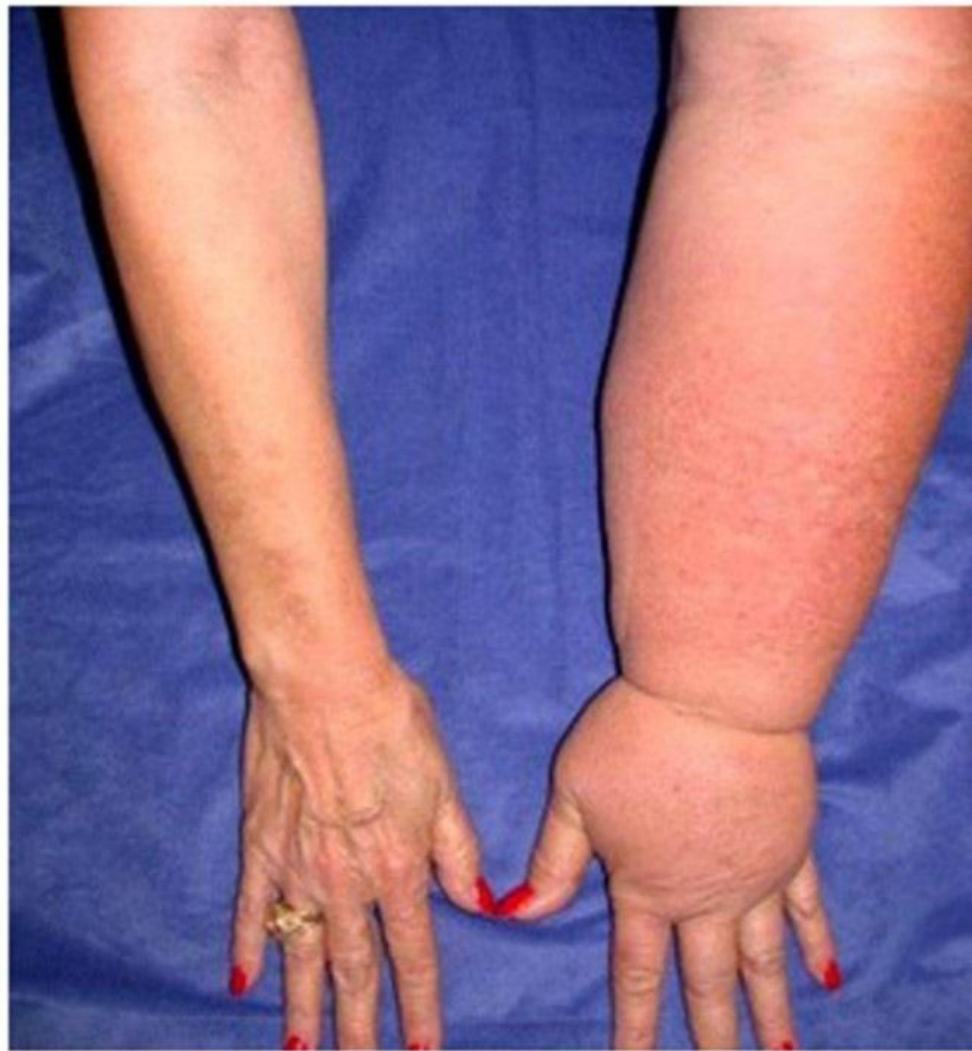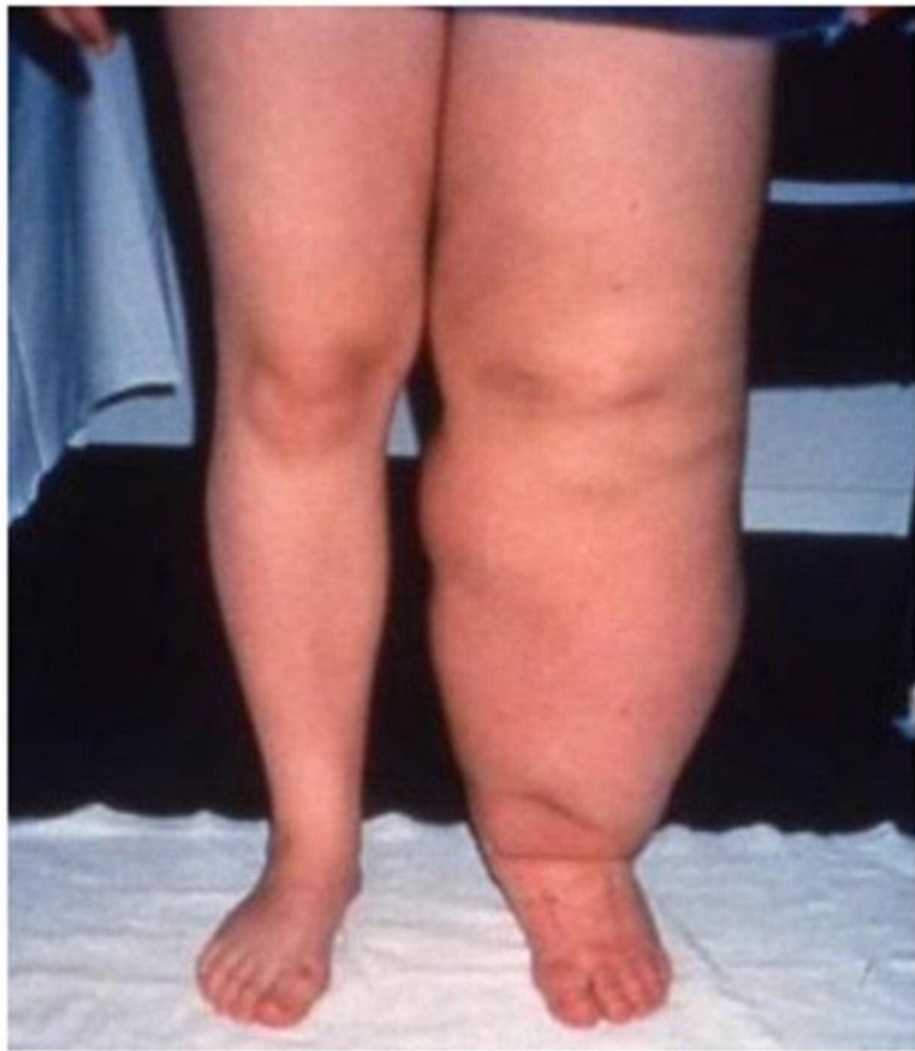Lymph nodes of upper limb

- **Cubital lymph node**
- lies above medial epicondyle of humerus
- Receive lymph vessels from forearm
- **Axillary lymph node**
- arranged in five groups

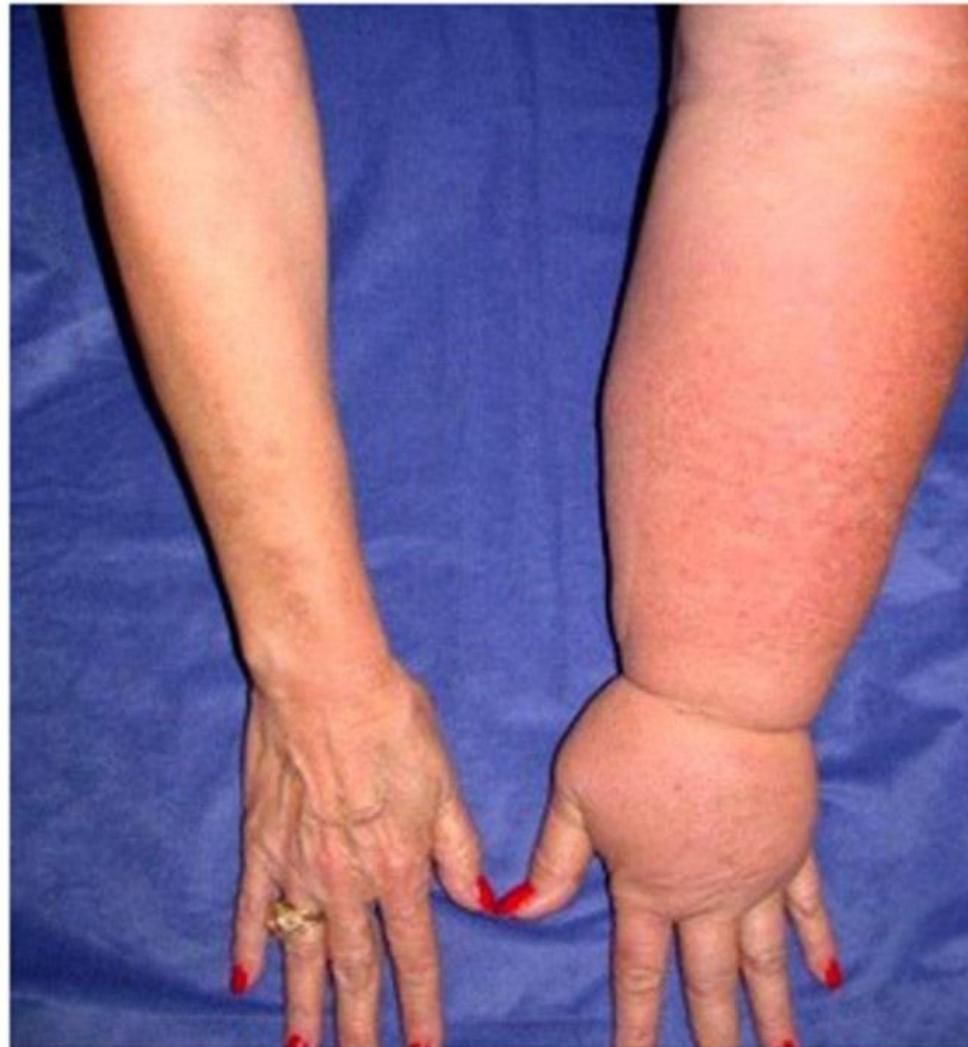
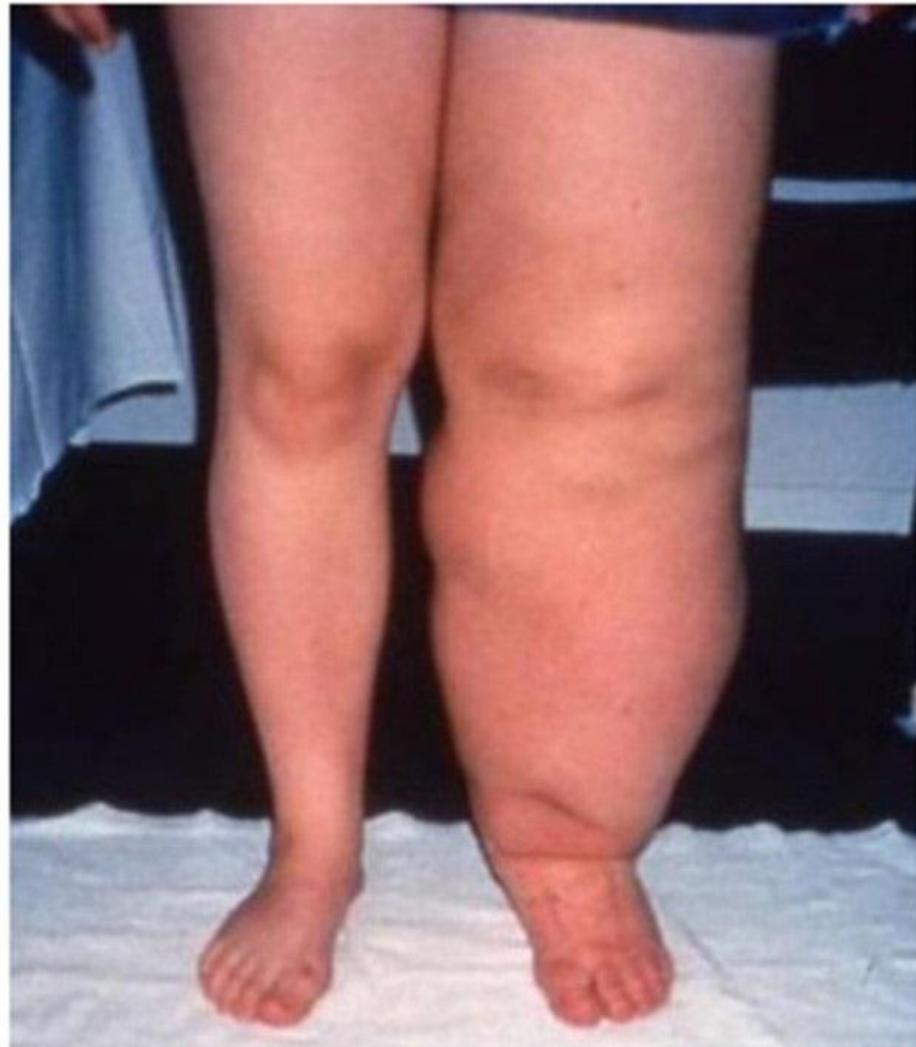
Lymph nodes of the lower limb

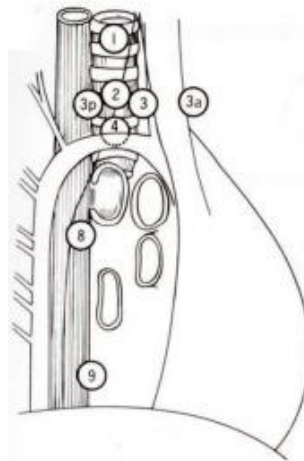
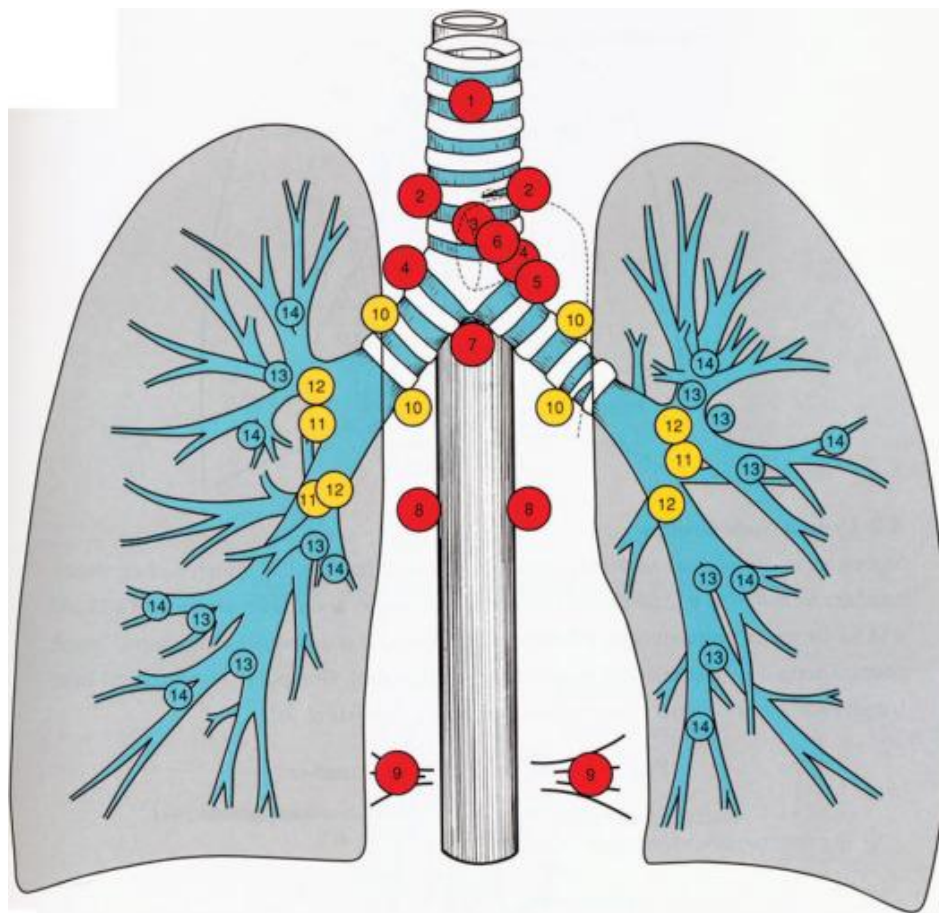




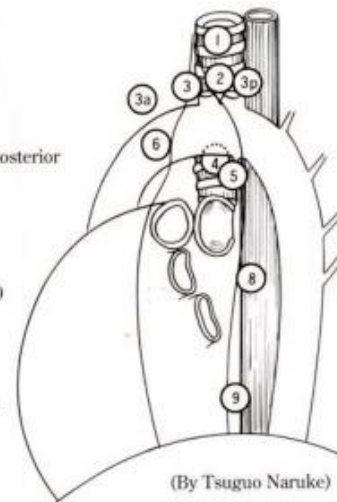
Lymphadenopathy- (filariasis) Elephantiasis



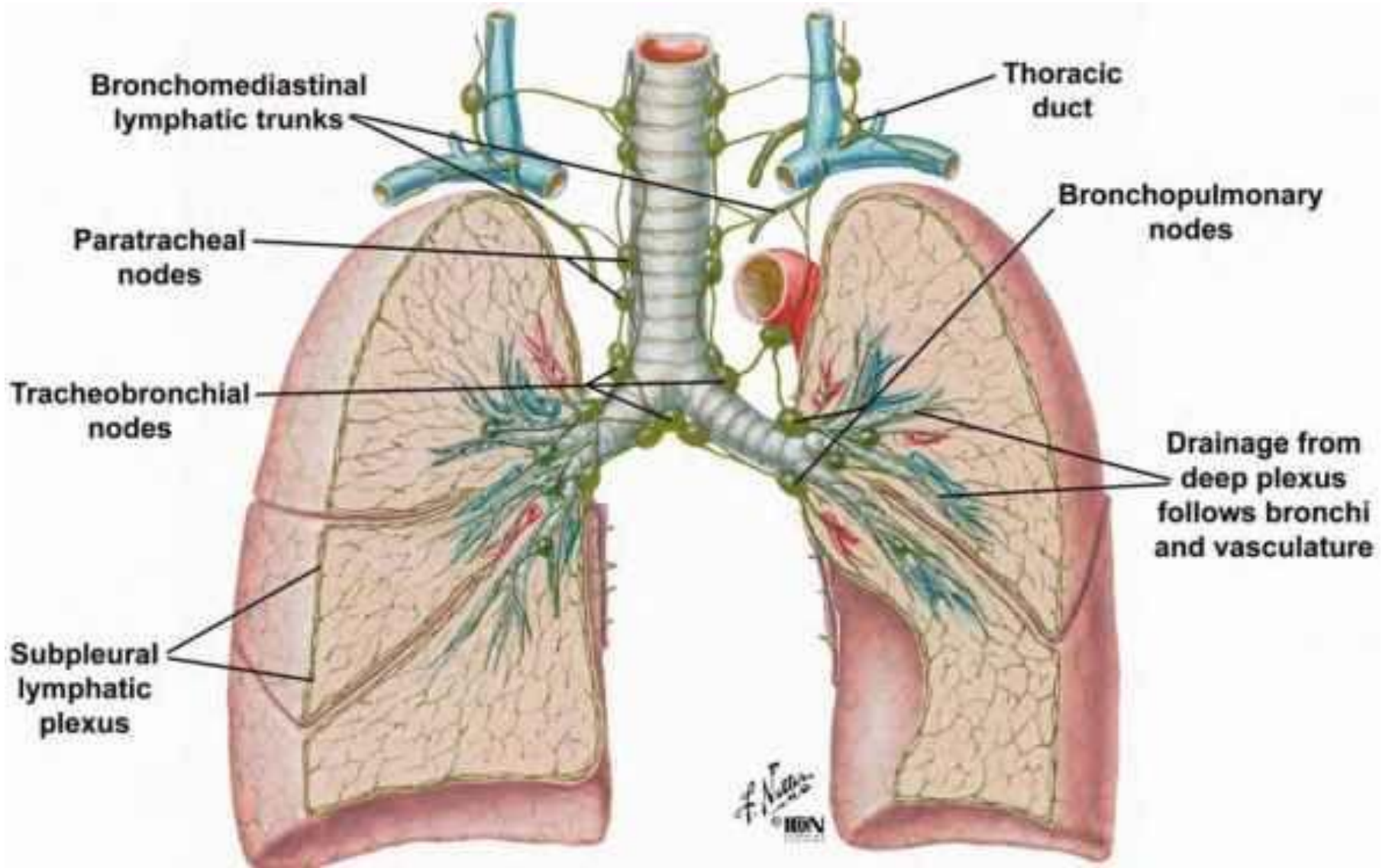
Unpalpable Lymph nodes

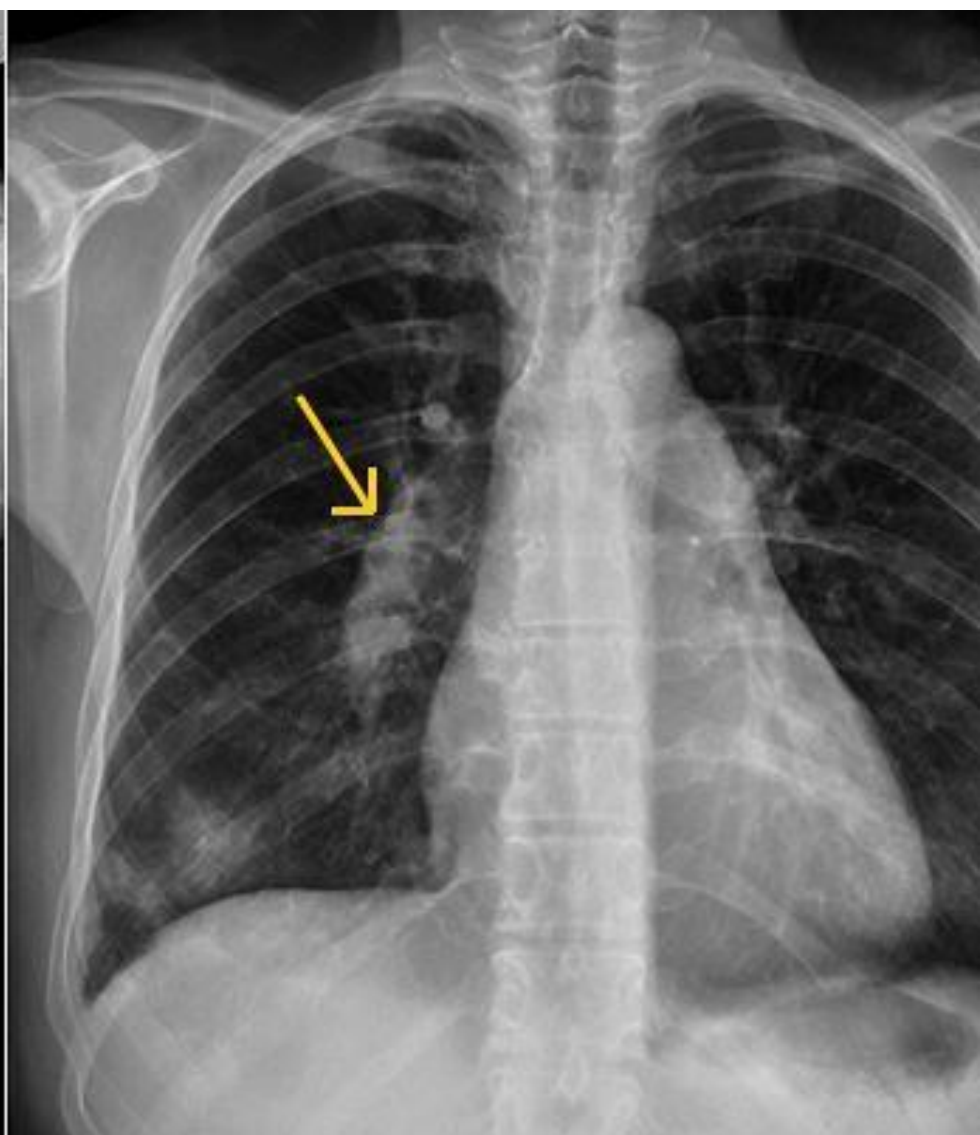
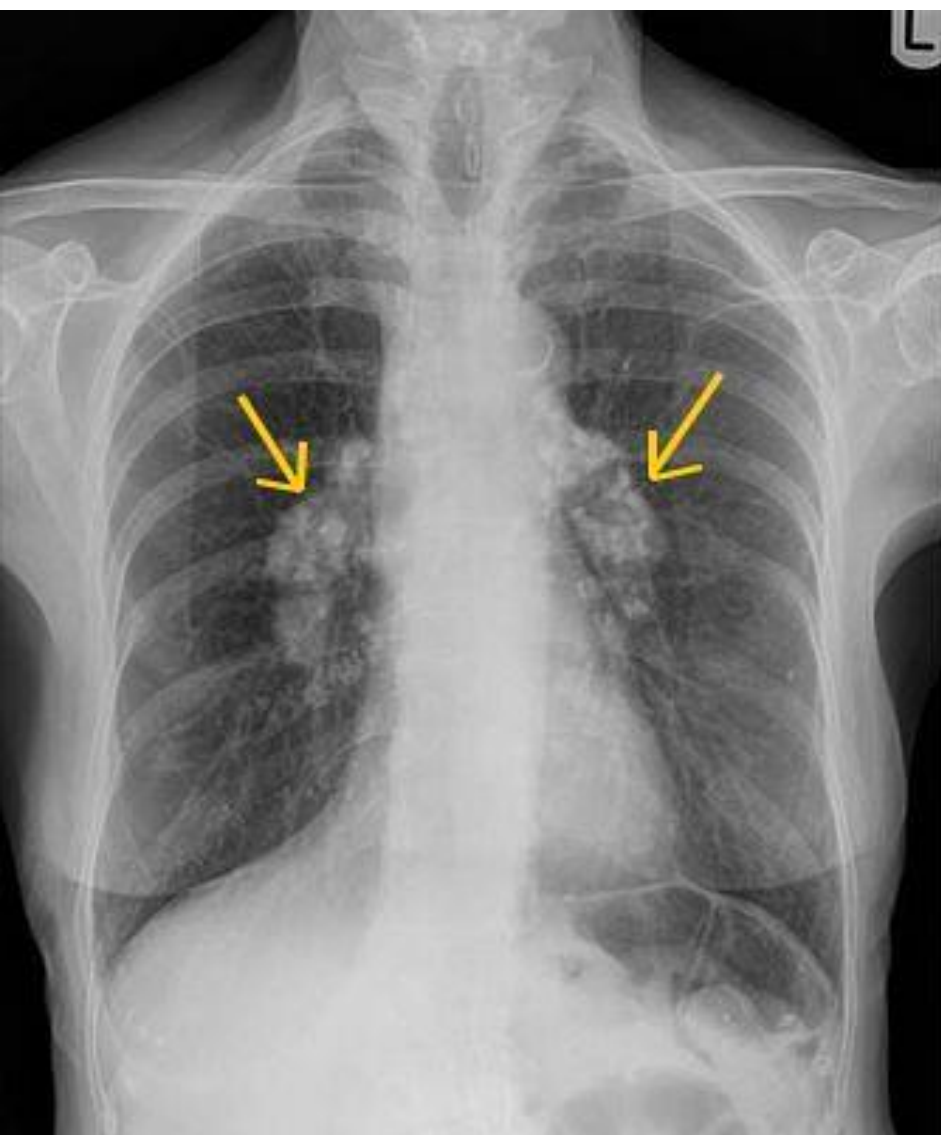


- #1 Superior mediastinal or highest mediastinal
- #2 Paratracheal
- #3 Pretracheal
- #3a Anterior mediastinal
- #3p Retrotracheal mediastinal or posterior mediastinal
- #4 Tracheobronchial
- #5 Subaortic or Botallo's
- #6 Paraaortic (ascending aorta)
- #7 Subcarinal
- #8 Paraesophageal (below carina)
- #9 Pulmonary ligament
- #10 Hilar (main bronchus)
- #11 Interlobar
- #12 Lobar - upper lobar, middle lobar, and lower lobar
- #13 Segmental
- #14 Subsegmental

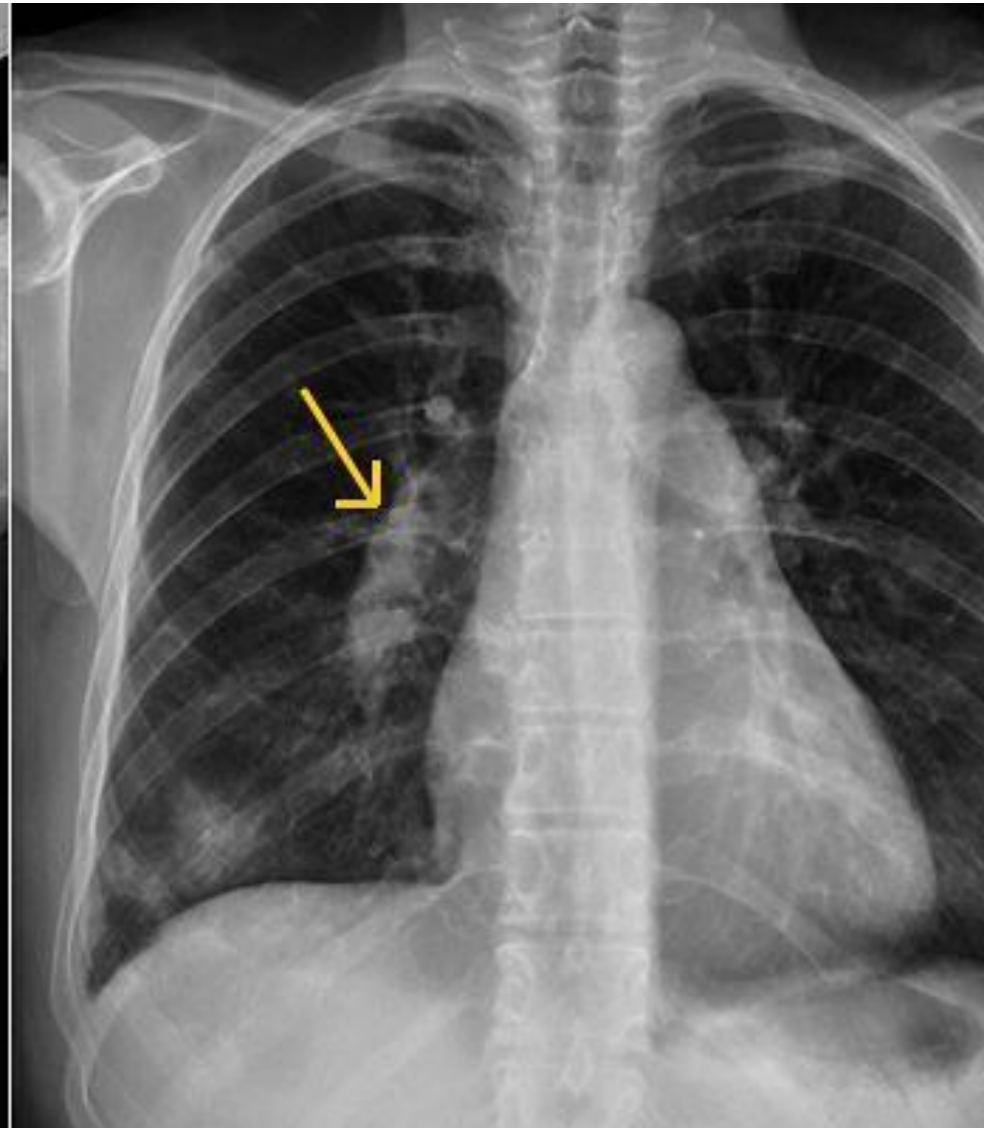
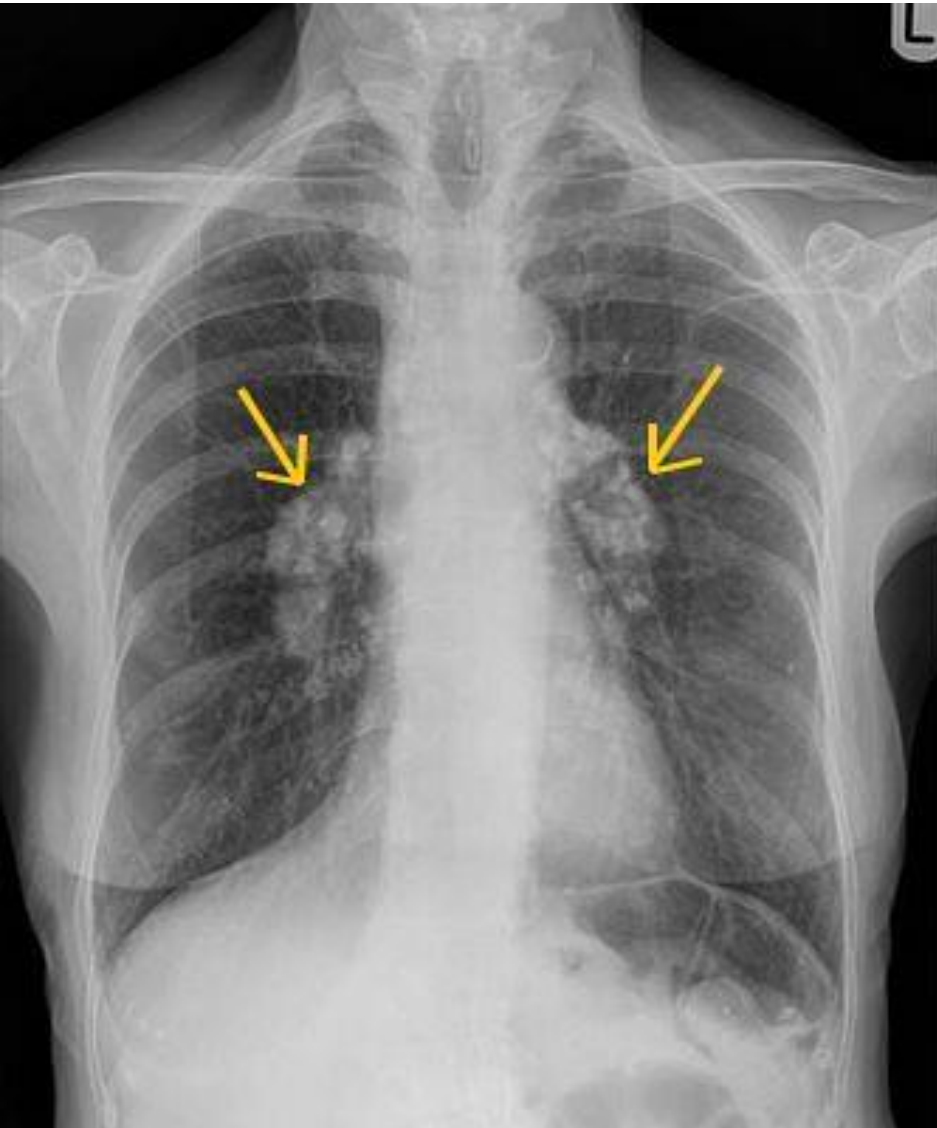


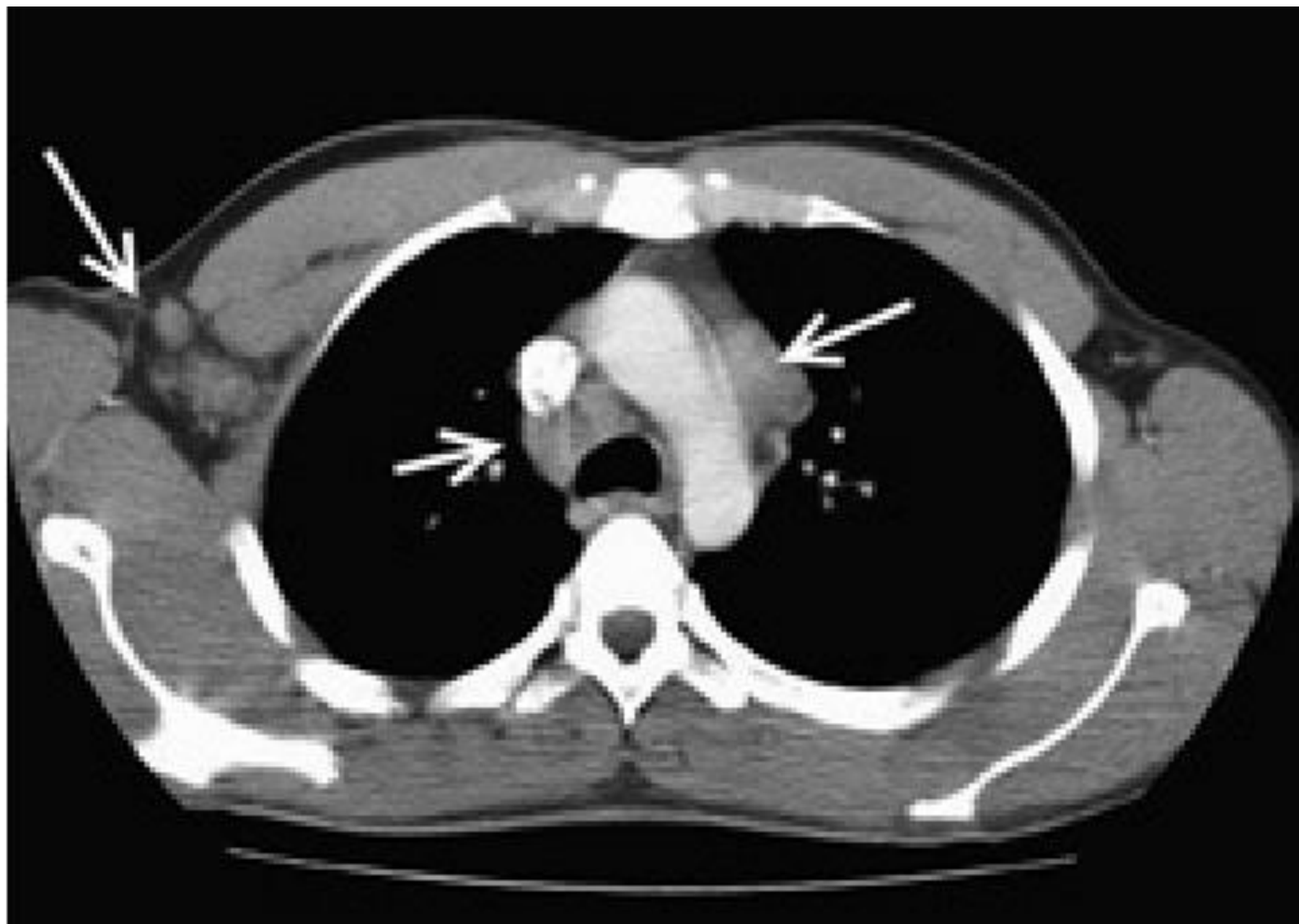
(By Tsuguo Naruke)





Metastatic Hilary lymph nodes





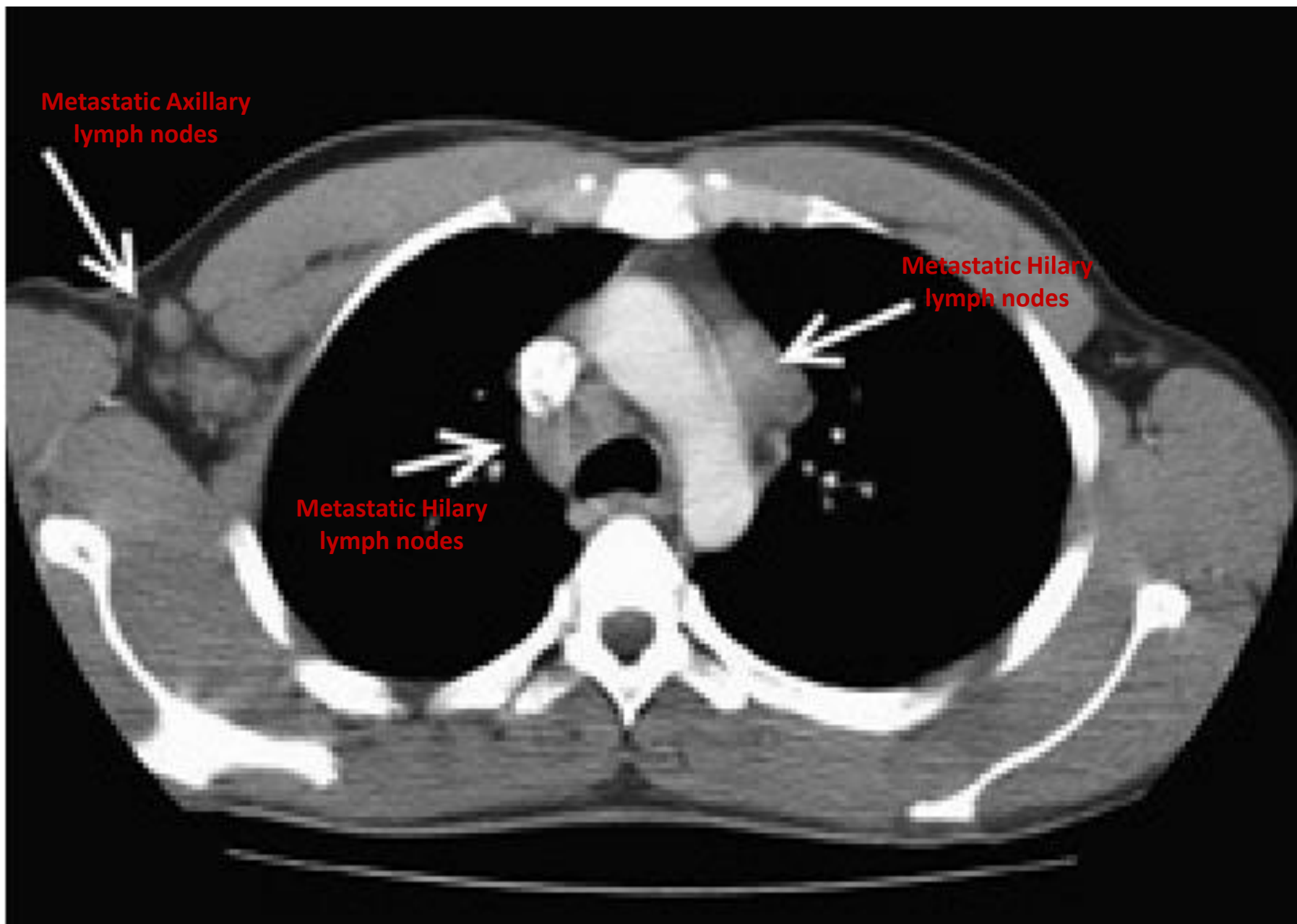
Metastatic Axillary lymph nodes

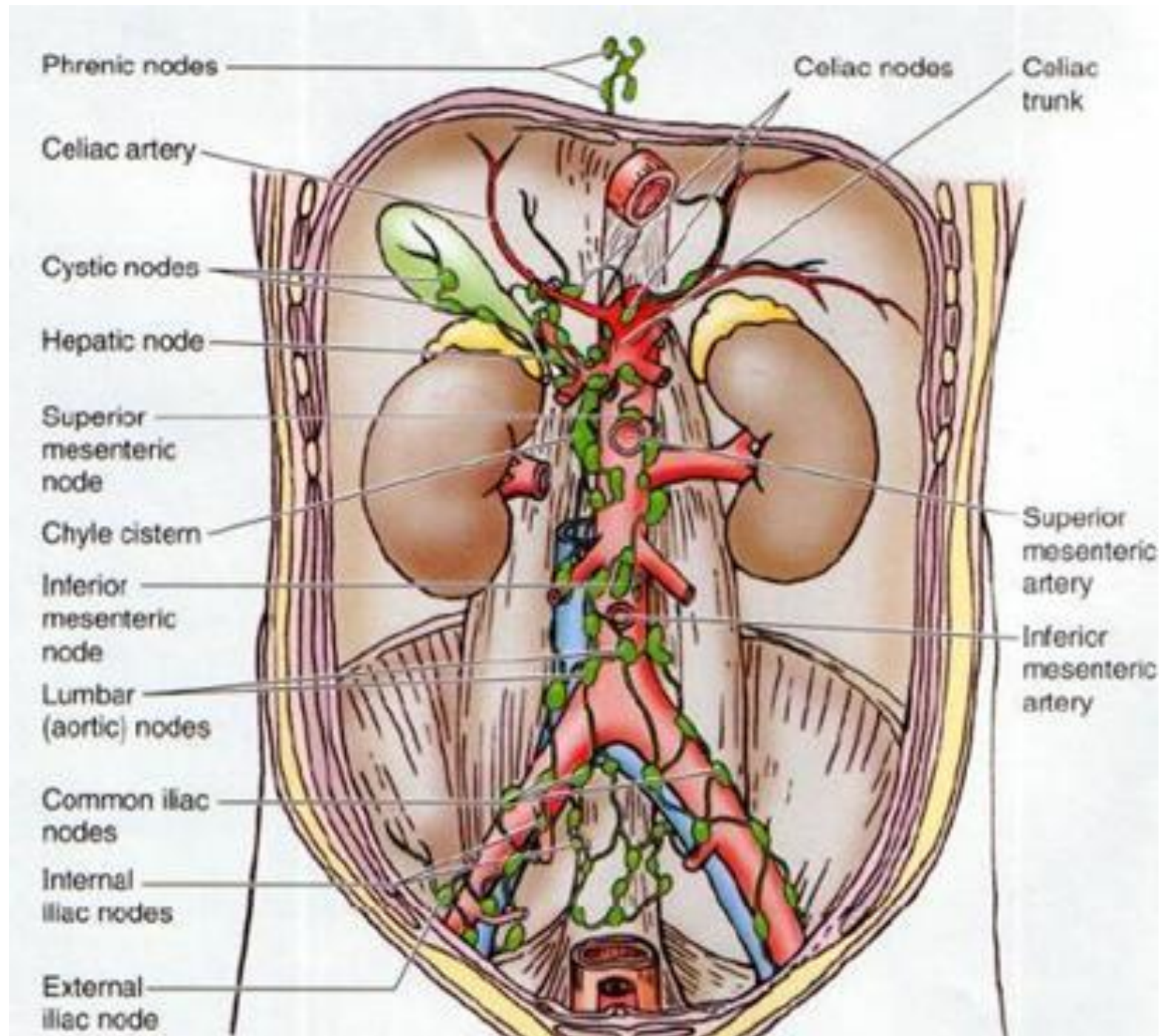


Metastatic Hilary lymph nodes



Metastatic Hilary lymph nodes





Visceral Nodes of the Abdominal Cavity

1. Celiac
2. Gastric (right and left)
3. Lymphatic anulus of heart (cardioesophageal)
4. Gastrointestinal (right and left) (gastroepiploic)

Hepatic Lymph Nodes

13. Cystic
14. Foraminal (foramen of Winslow)

Pyloric Lymph Nodes

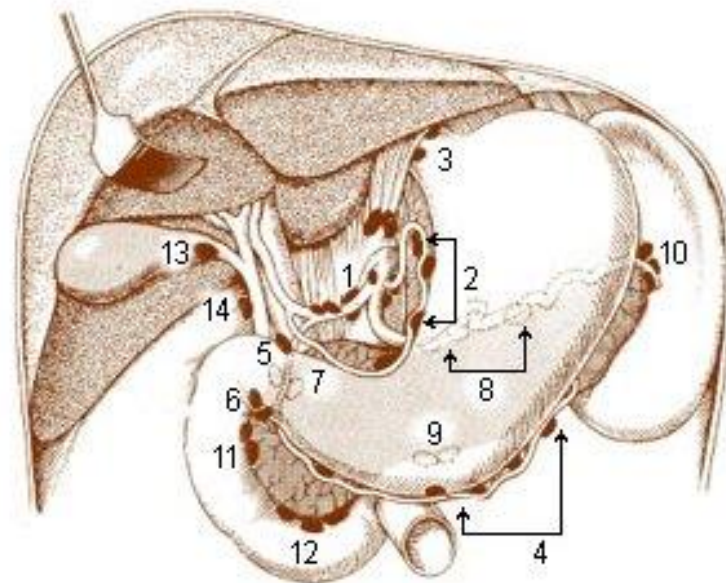
5. Suprapyloric
6. Subpyloric
7. Retropyloric

Pancreatic Lymph Nodes

8. Superior pancreatic
9. Inferior pancreatic
10. Splenic (Lienal)

Pancreaticoduodenal Lymph Nodes

11. Superior pancreaticoduodenal
12. Inferior pancreaticoduodenal

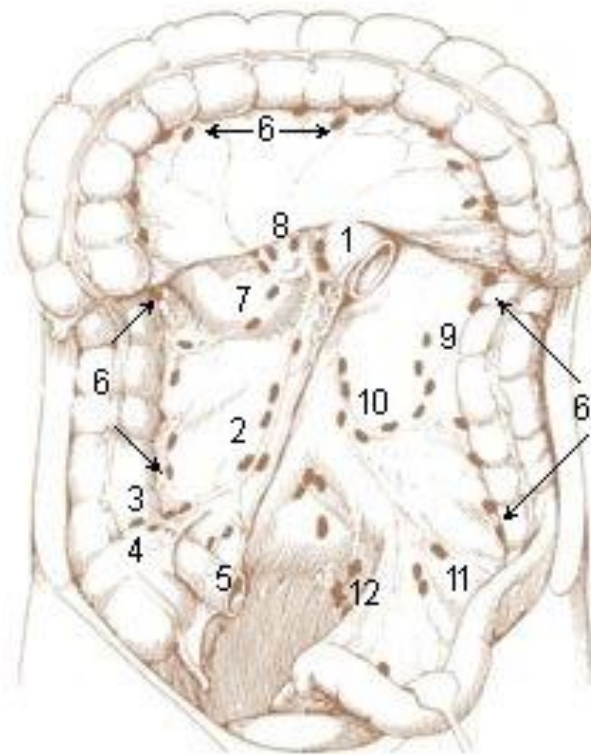


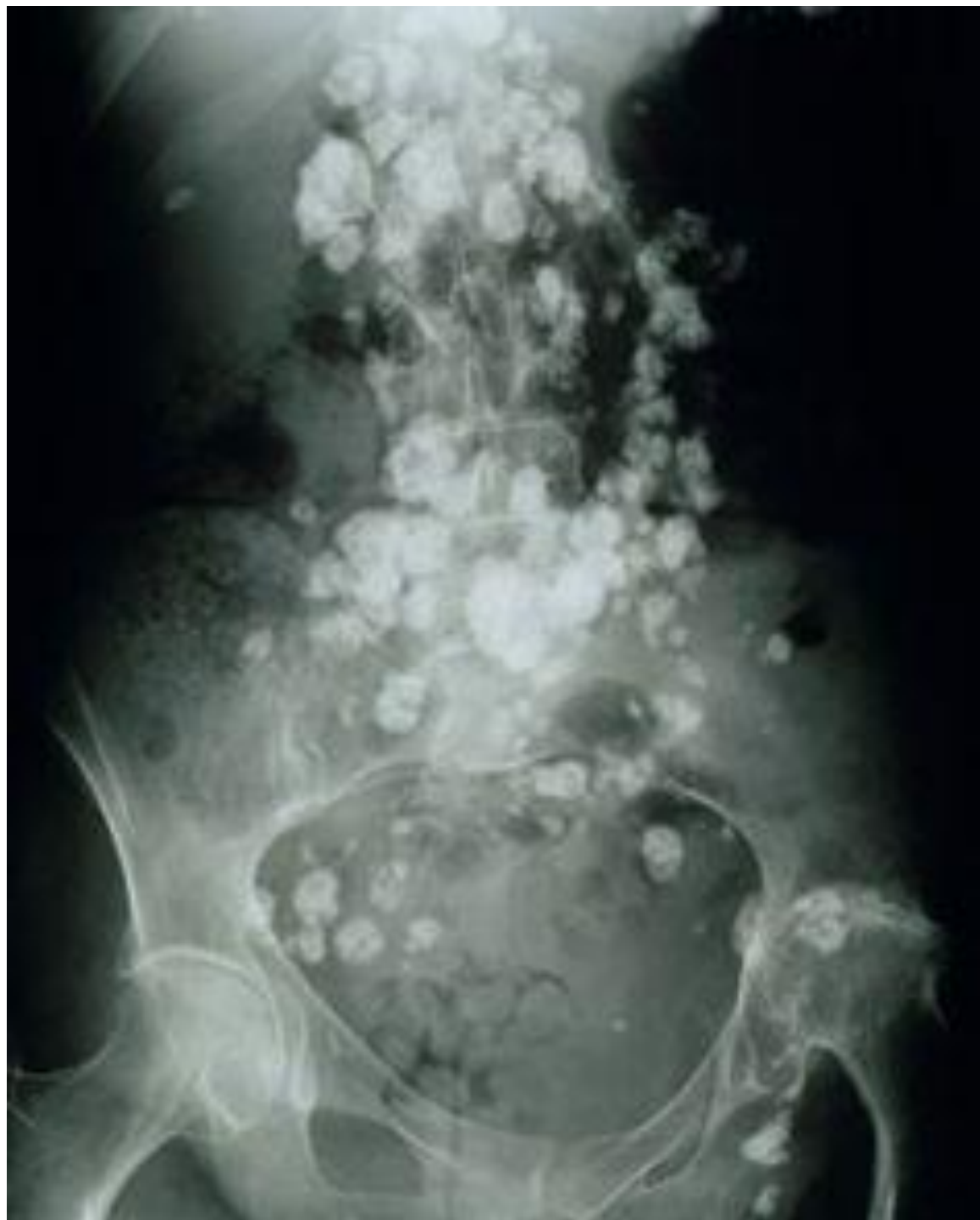
Lymph Nodes of the Large Intestine and Lower Abdomen

1. Superior Mesenteric Lymph Nodes
2. Ileocolic Lymph Nodes
3. Prececal Lymph Nodes
4. Retrocecal Lymph Nodes
5. Appendicular Lymph Nodes

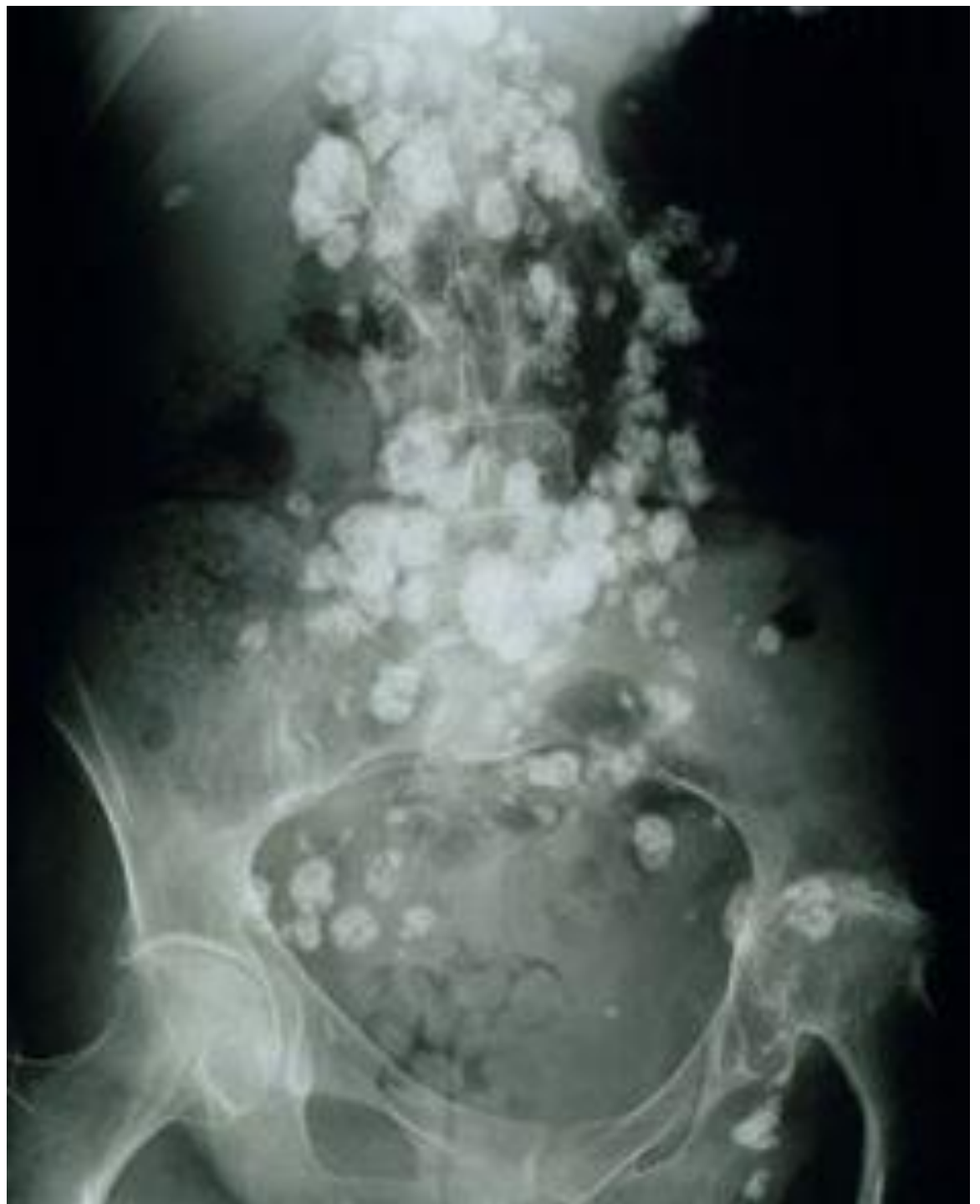
Mesocolic Lymph Nodes

6. Paracolic
7. Right colic
8. Middle colic
9. Left colic
10. Inferior Mesenteric Lymph Nodes
11. Sigmoid
12. Superior rectal





**Metastatic Abdominal
lymph nodes**



Lymph Nodes of the Female Pelvis

Internal Iliac Nodes

1. Superior gluteal
2. Inferior gluteal
3. Sacral

Perivesical Lymph Nodes

4. Prevesicular
5. Postvesicular
6. Lateral vesicular
7. Parauterine
8. Paravaginal
9. Anorectal (pararectal)

