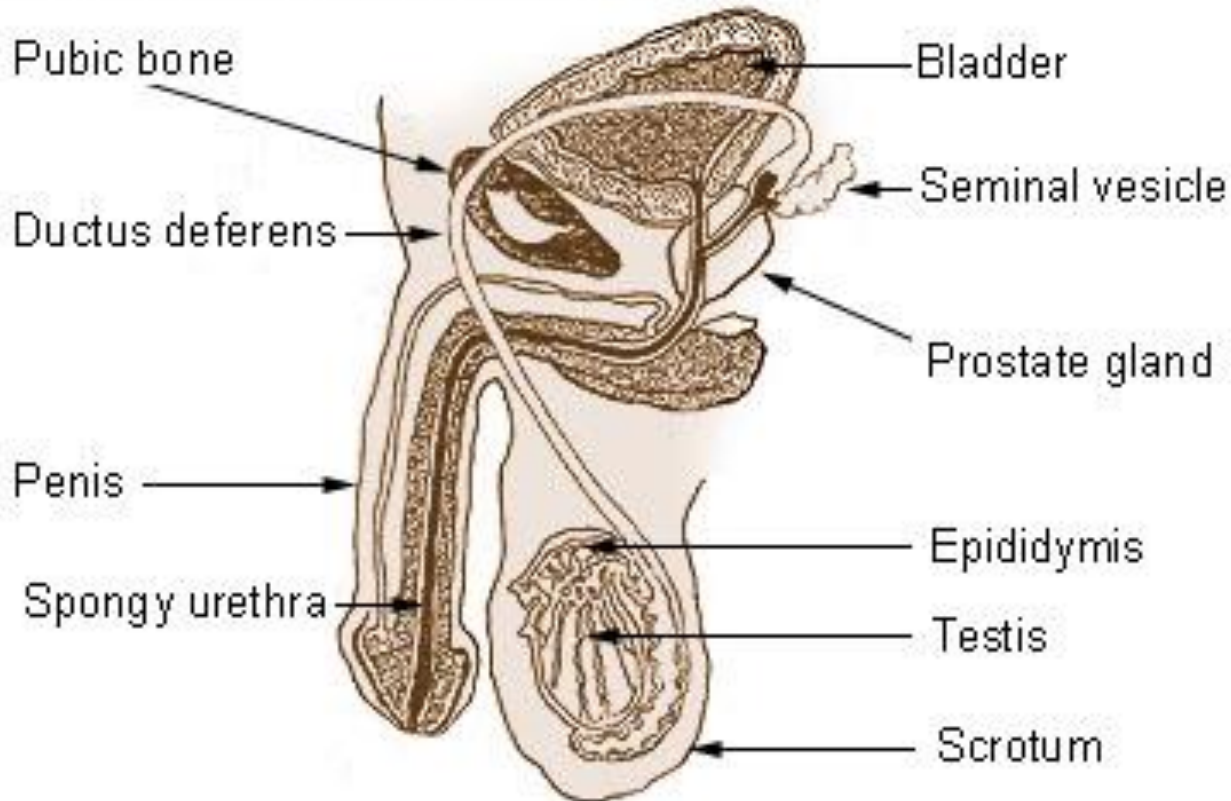


Male Genital System



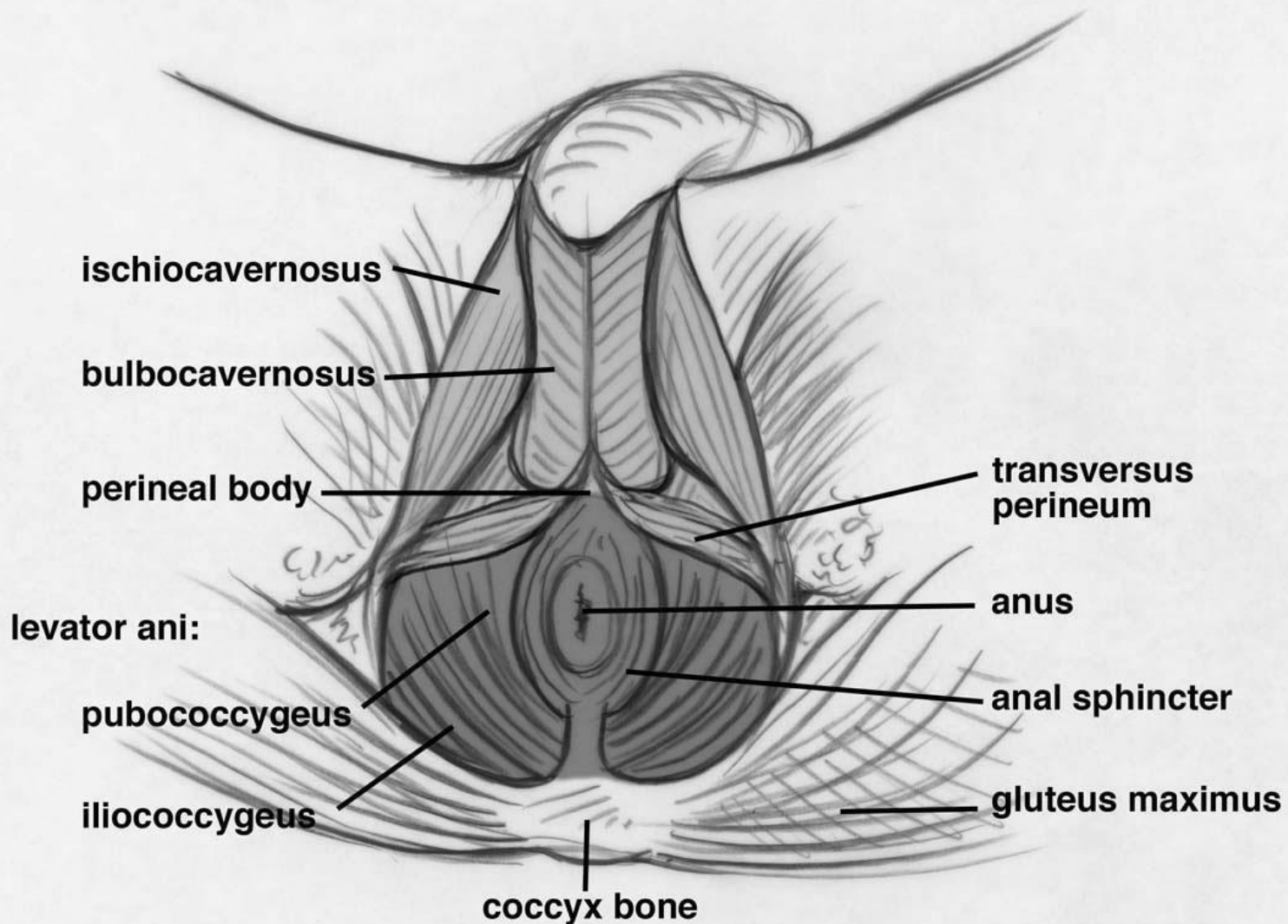
Department of Anatomy
Second Faculty of Medicine
Charles University

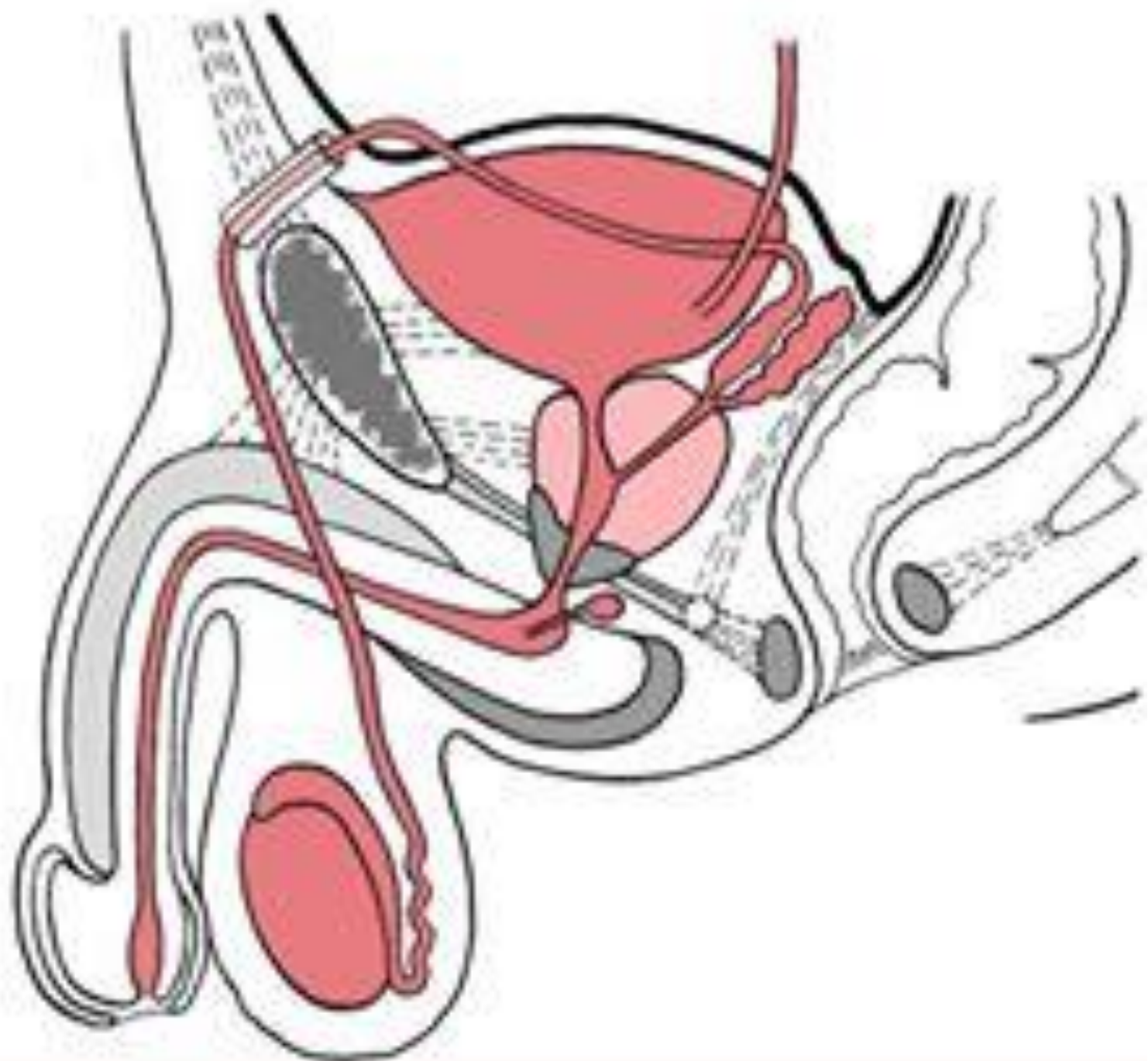
Male Reproductive System

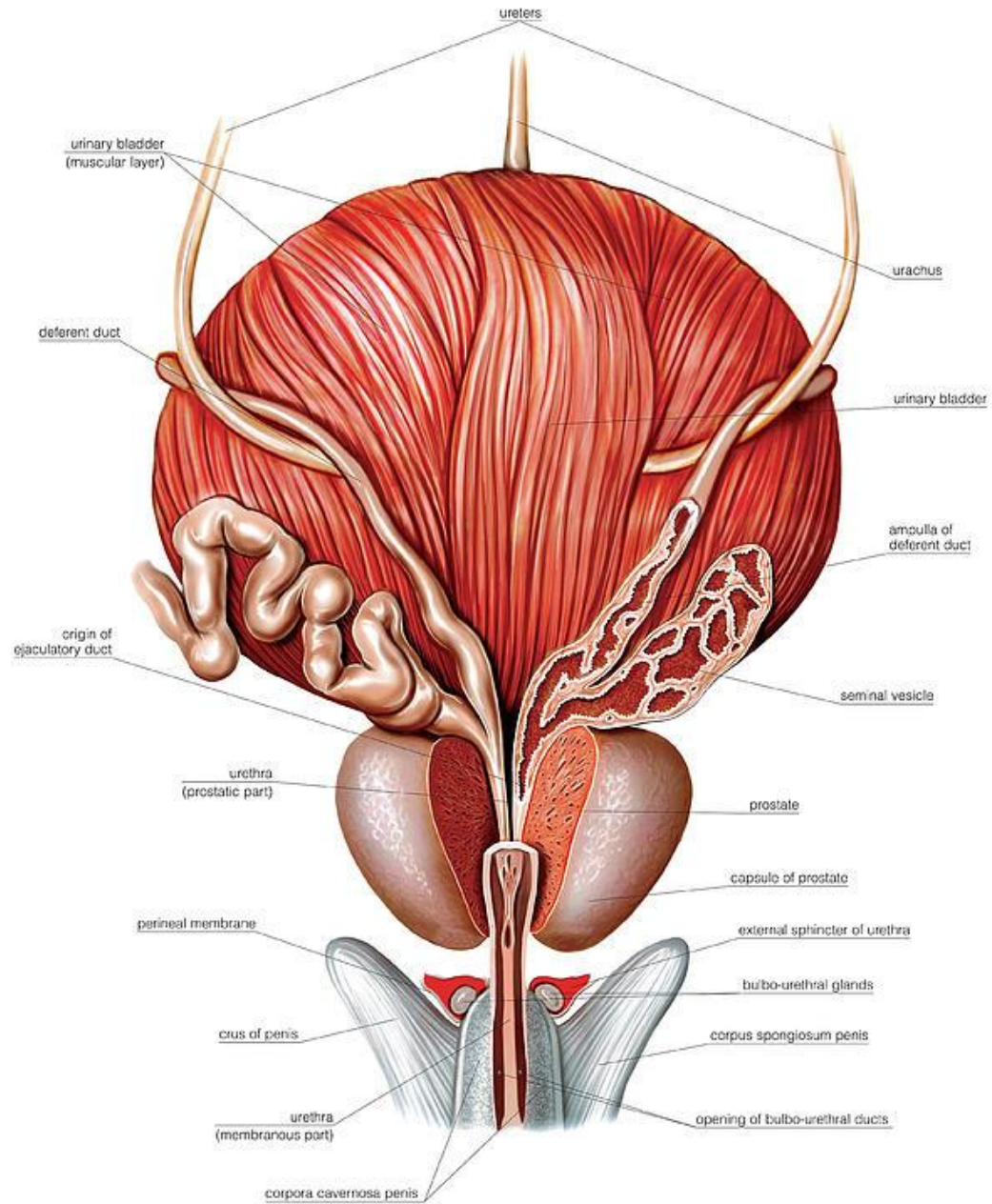


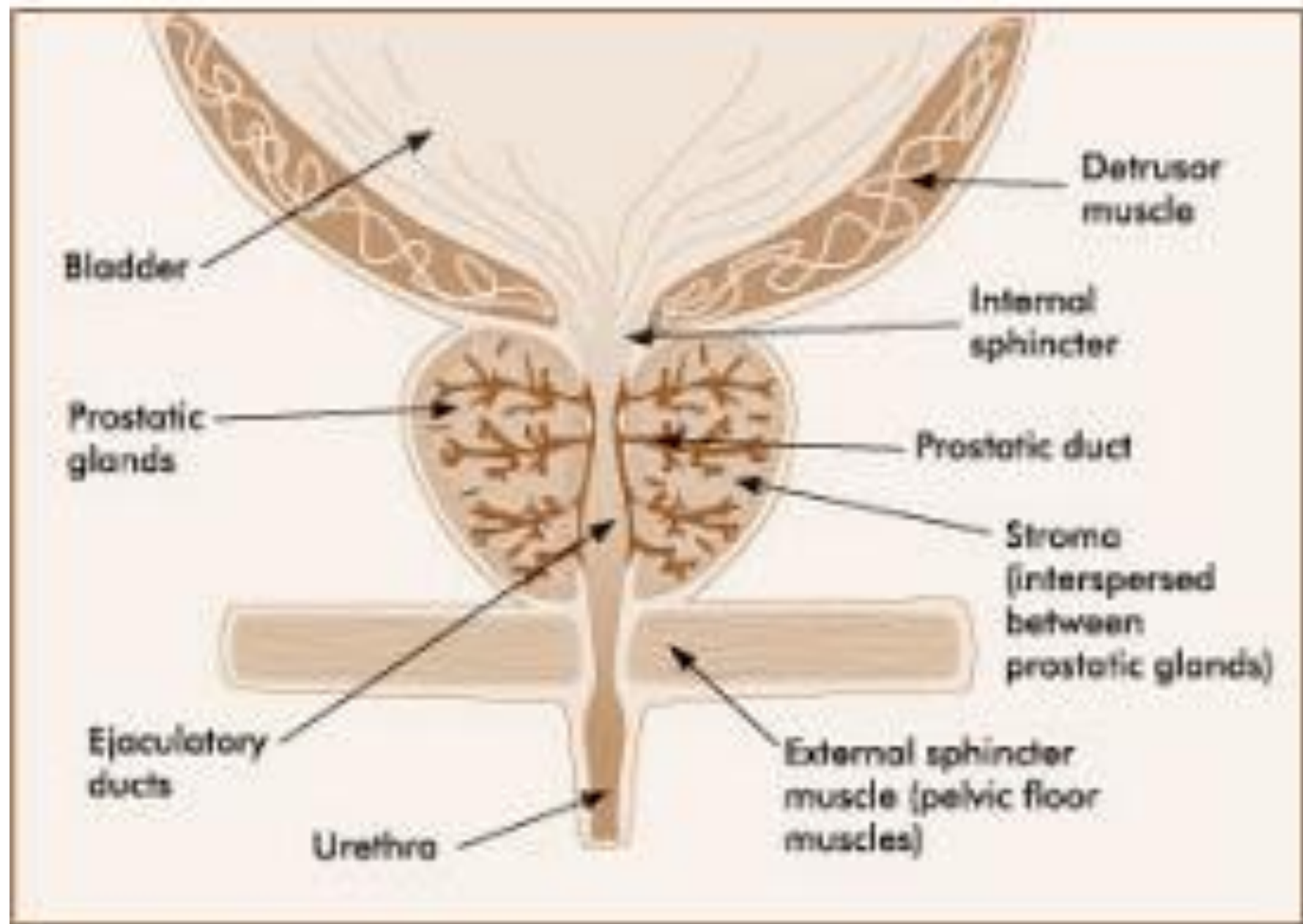
MUDr. Azzat Al-Redouan

Illustration #4 Male Pelvic Floor Anatomy

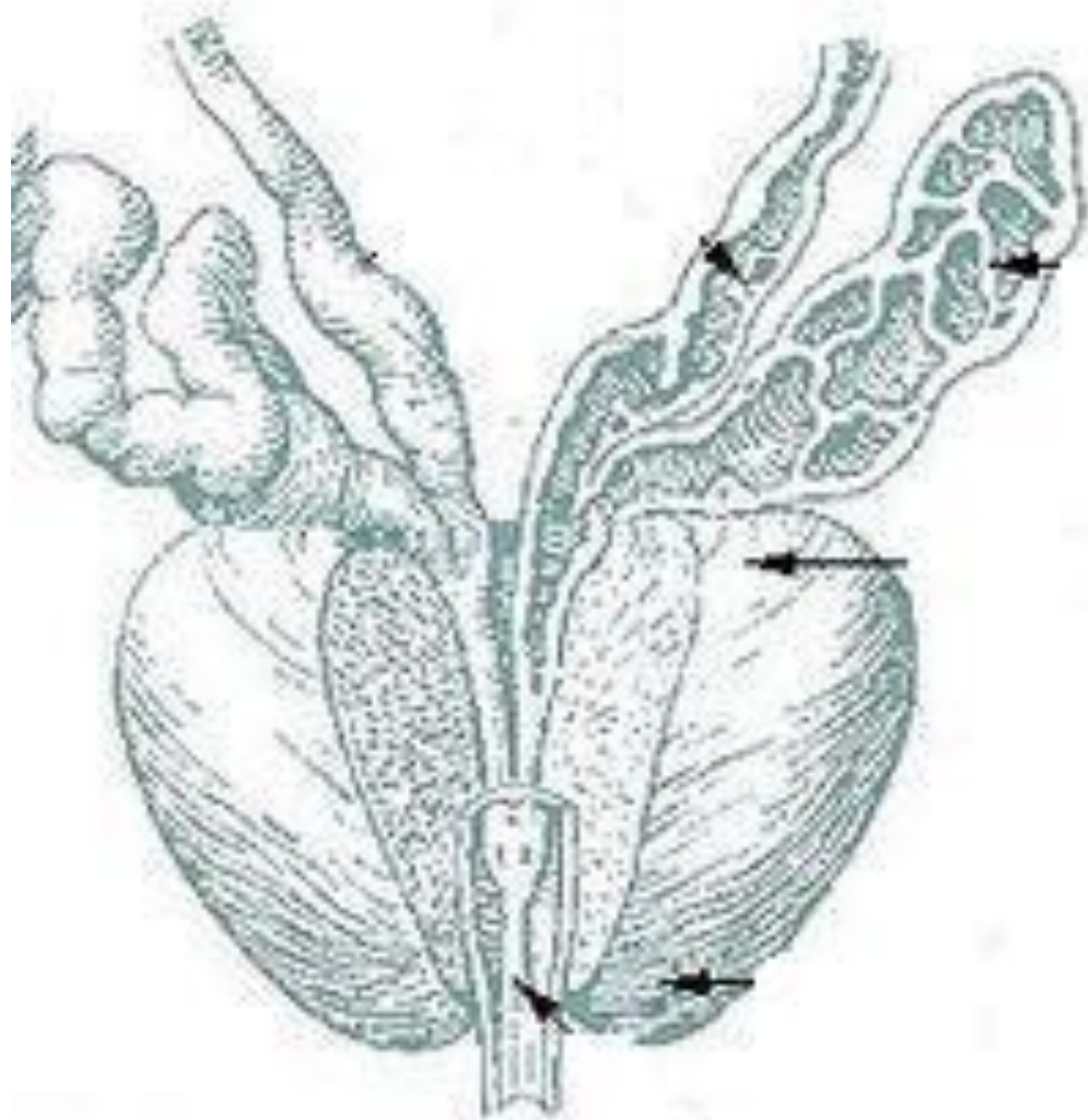


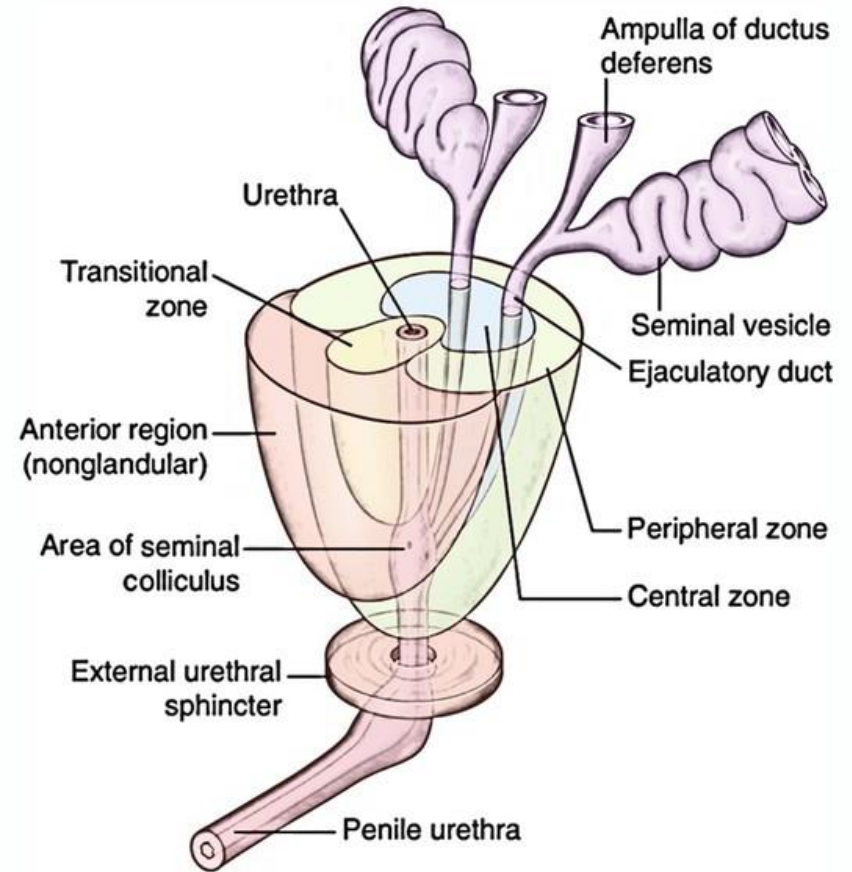
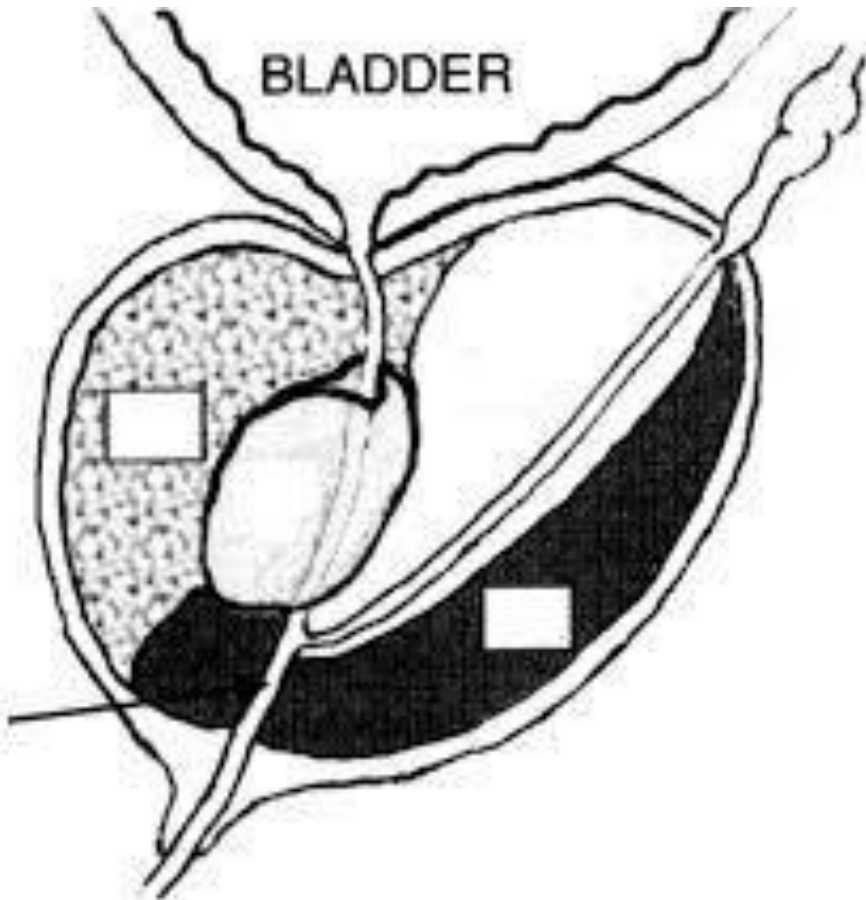


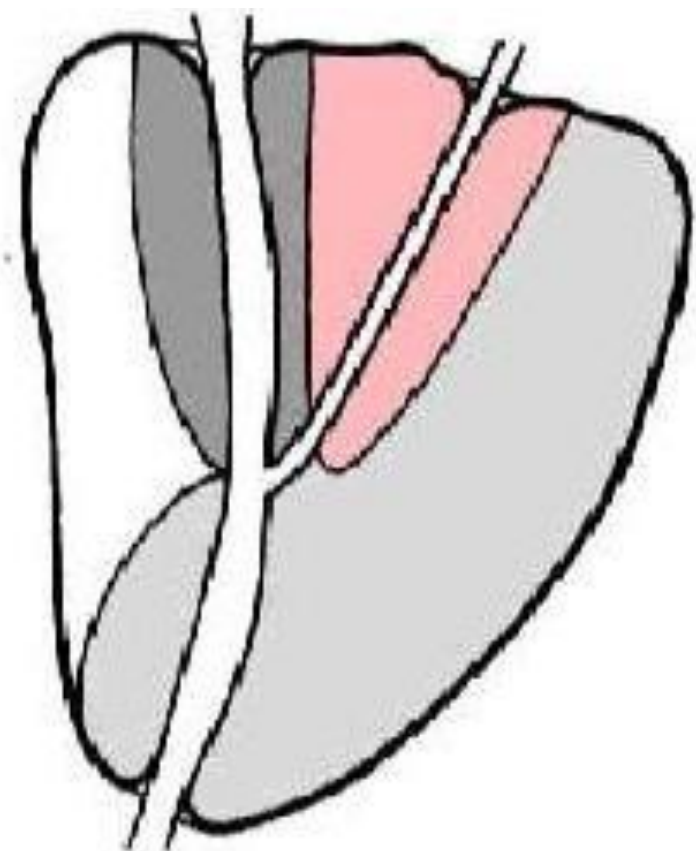
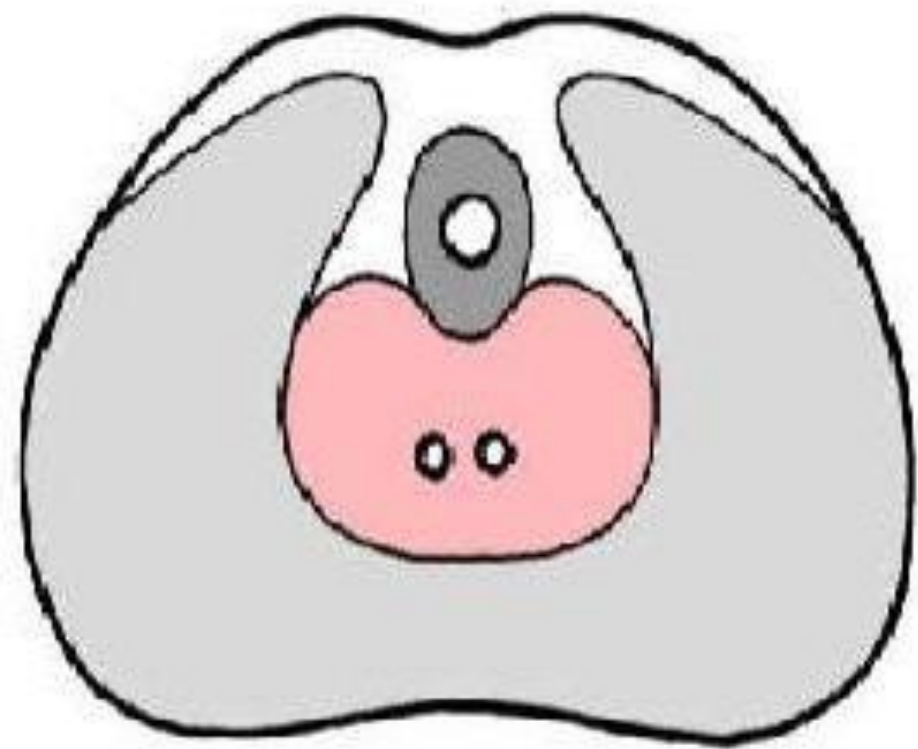



Cross-section of the prostate gland









HRAST DR POPOVIC

ADM

MI 1.0

TIs 0.9

C1-5

intestine

FR 30

AO% 100

CHI

0-Frq 4.0

Gn 70

S/A 3/3

-Map F/0

D 14.0

DR 60

LS7
Exp

LS7
Exp

0

-10

10

1 L	3.13 cm
2 H	3.77 cm
3 W	3.01 cm
Volume	18.62 ml

PROSTATA

