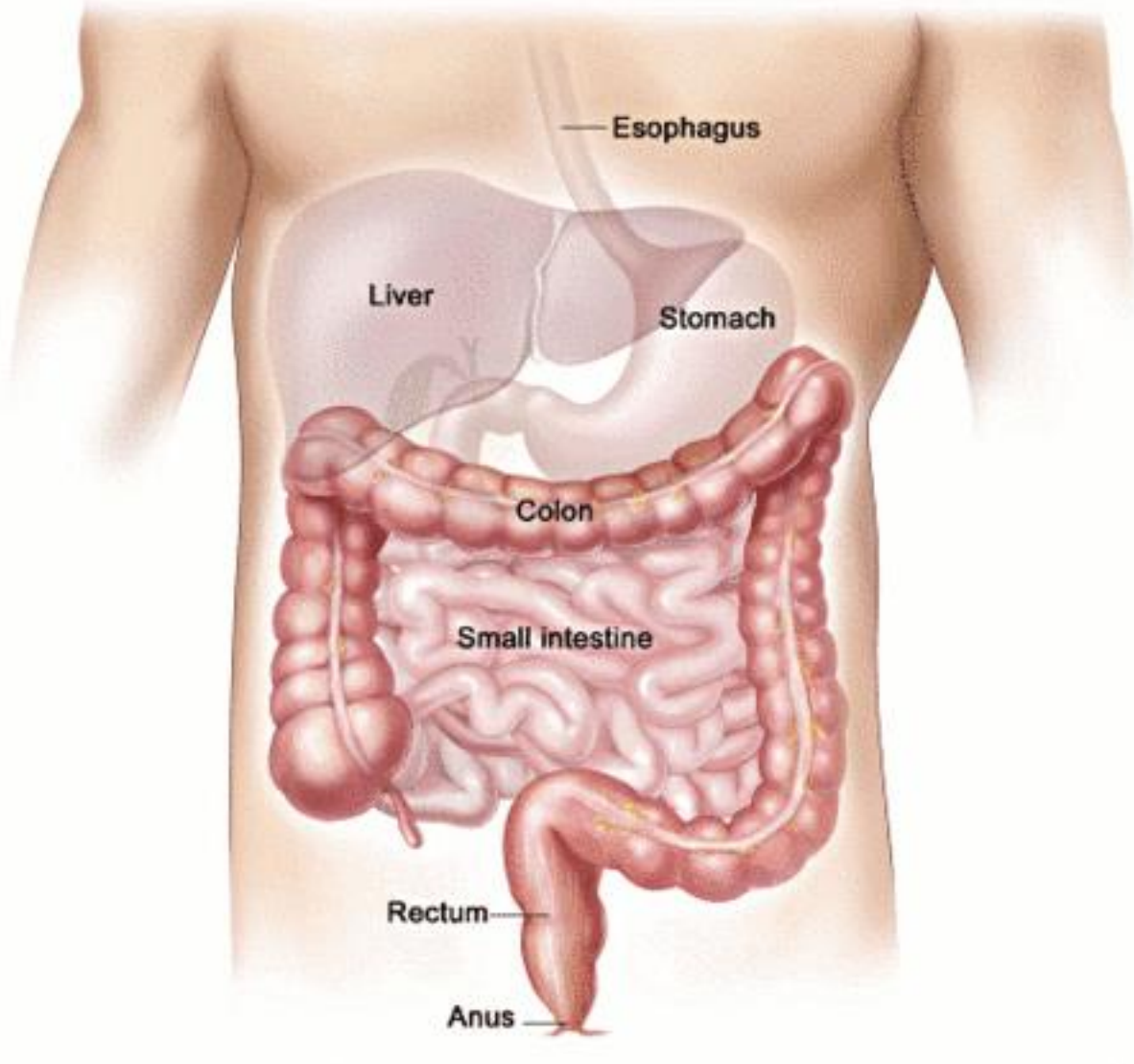


DIGESTIVE SYSTEM – LOWER GIT

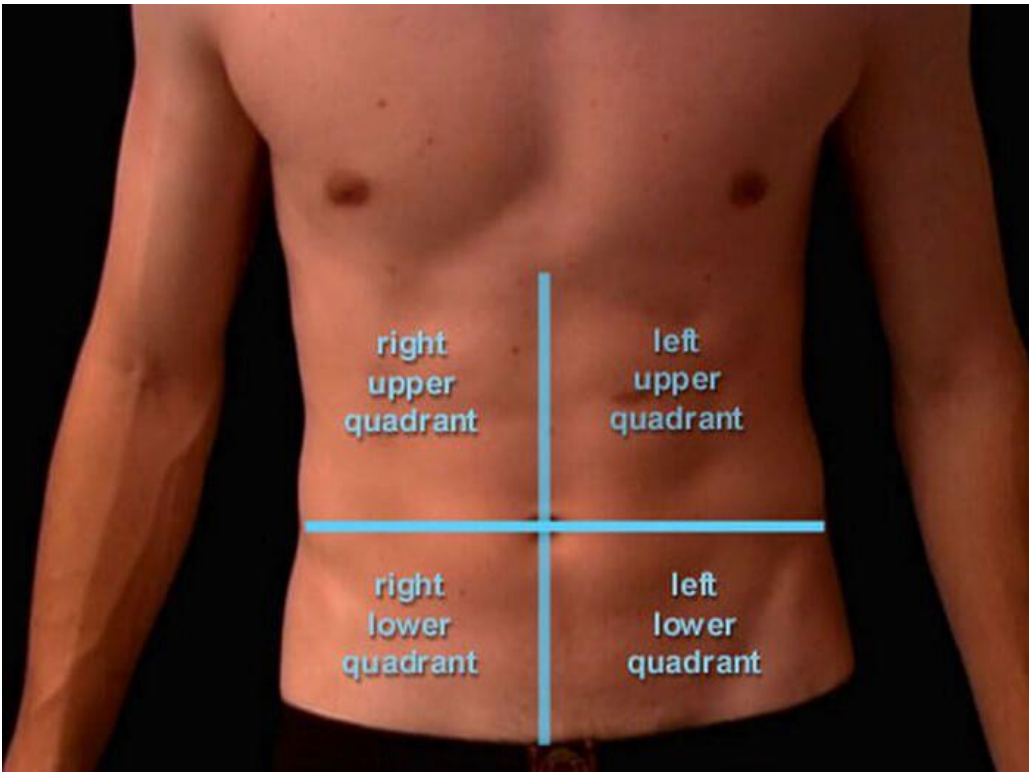
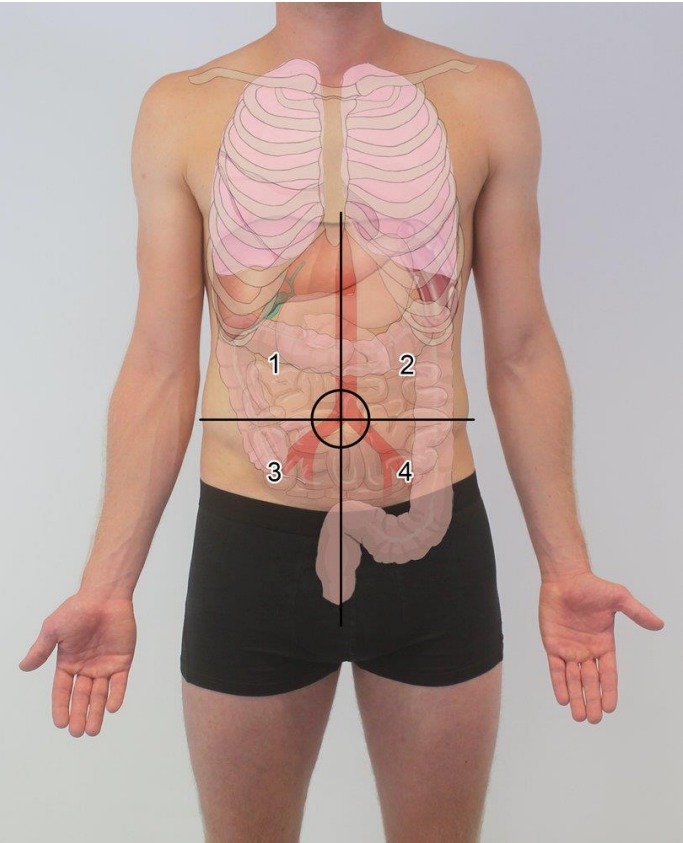


Department of Anatomy
Second Faculty of Medicine
Charles University

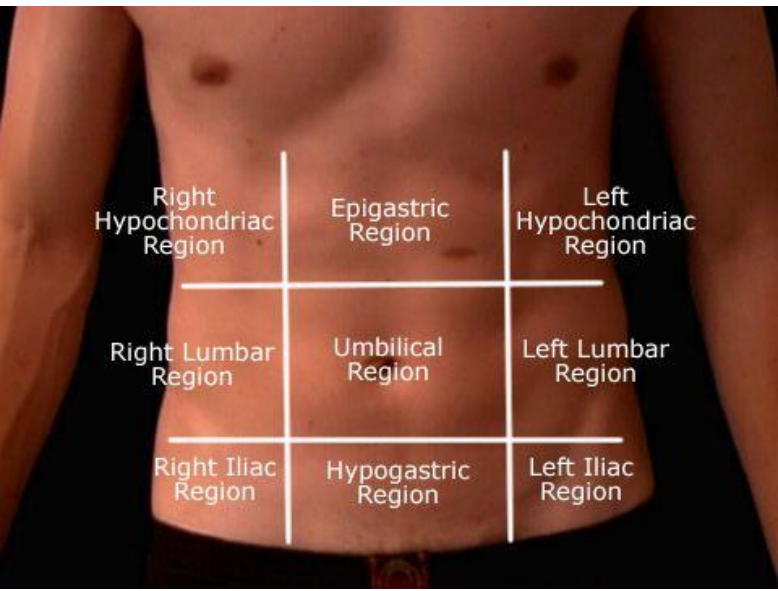
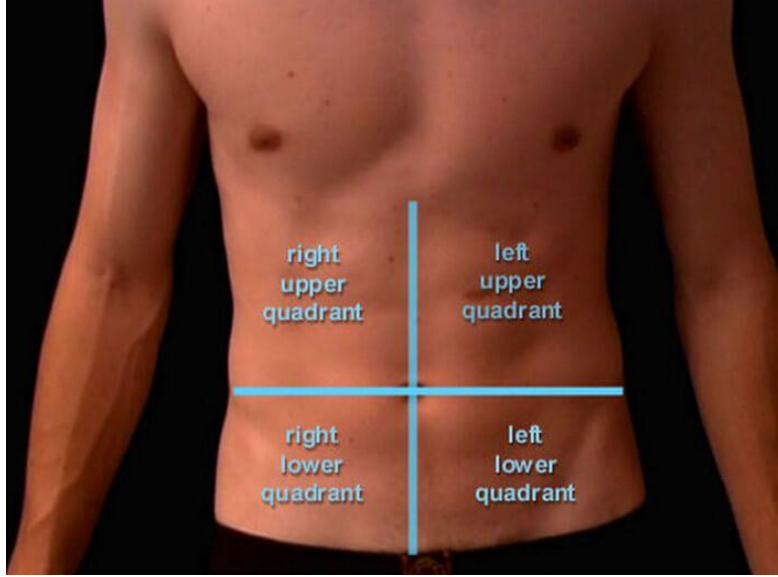
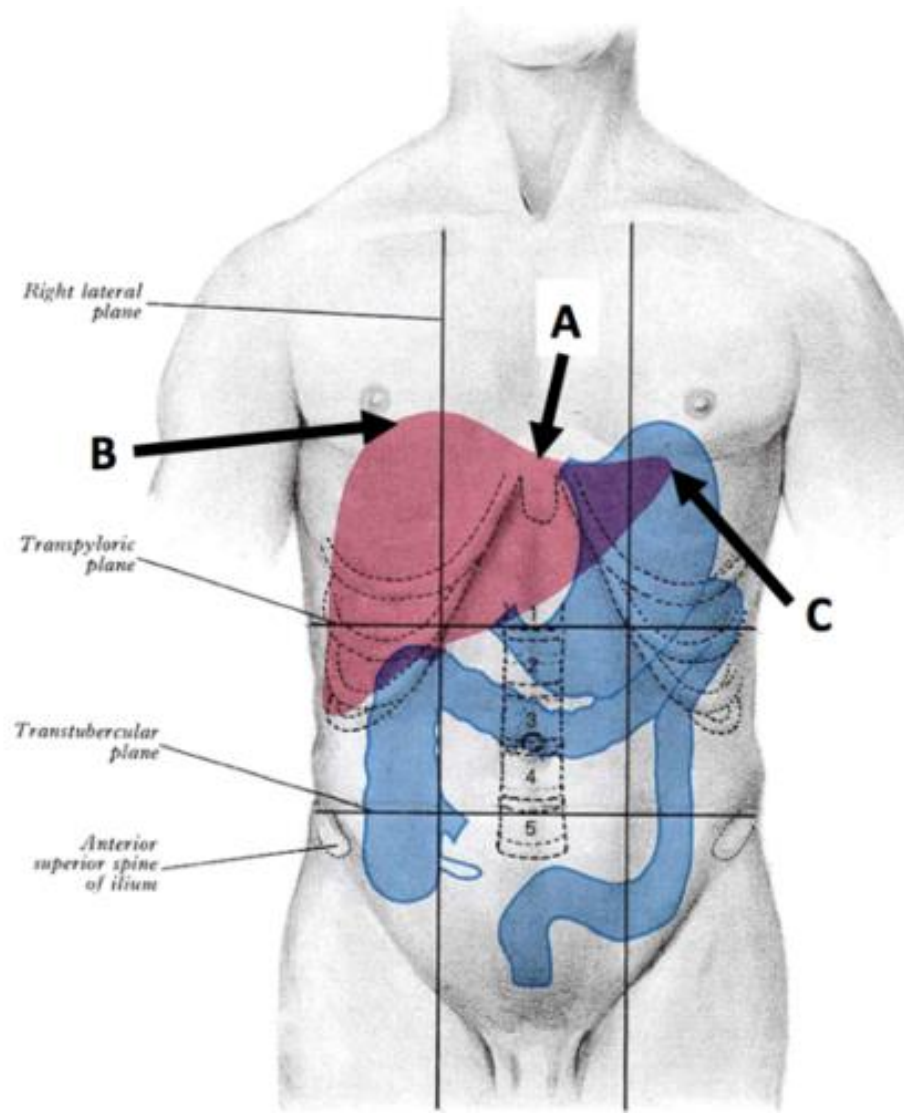
MUDr. Azzat Al-Redouan

SURFACE ANATOMY- ABDOMINAL ORGAN PROJECTION

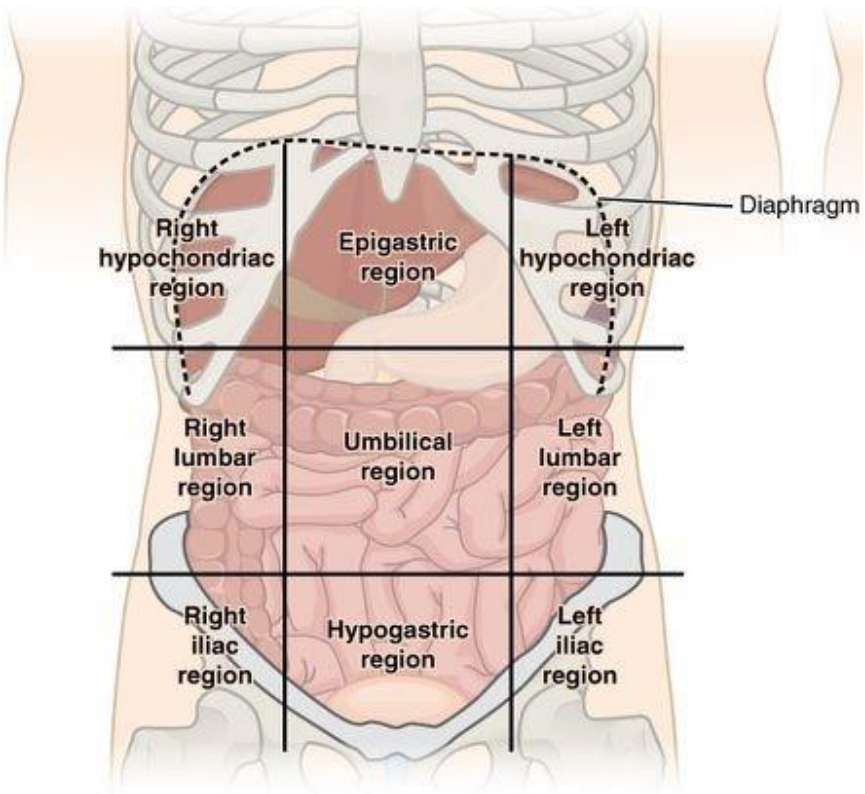
Surface Anatomy- Abdominal Organ Projection



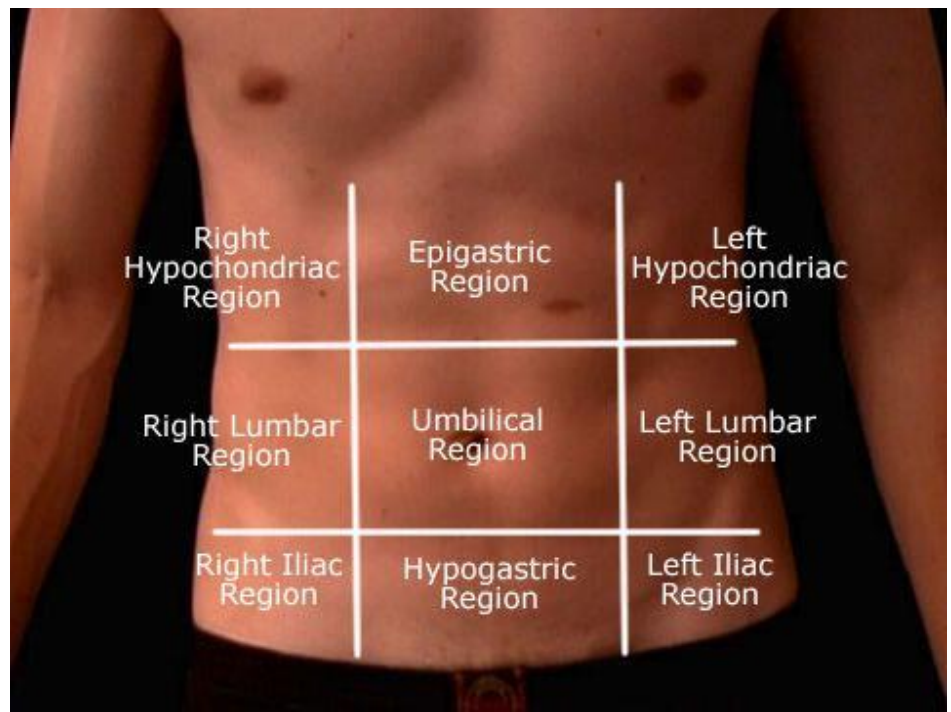
Surface Anatomy- Abdominal Organ Projection



Surface Anatomy- Abdominal Organ Projection



(a) Abdominopelvic regions



Surface Anatomy- Abdominal Organ Projection

Projections of organs

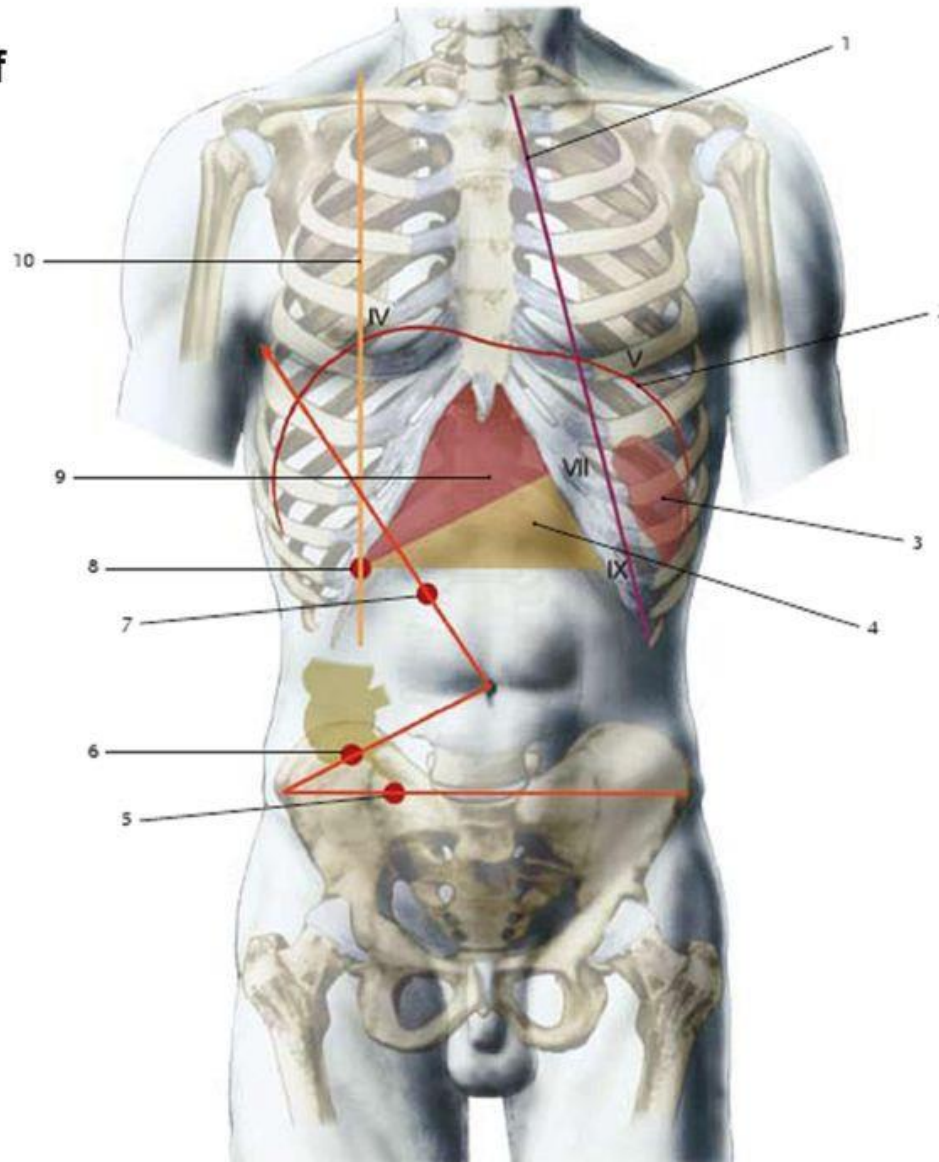
Points :

Murphy

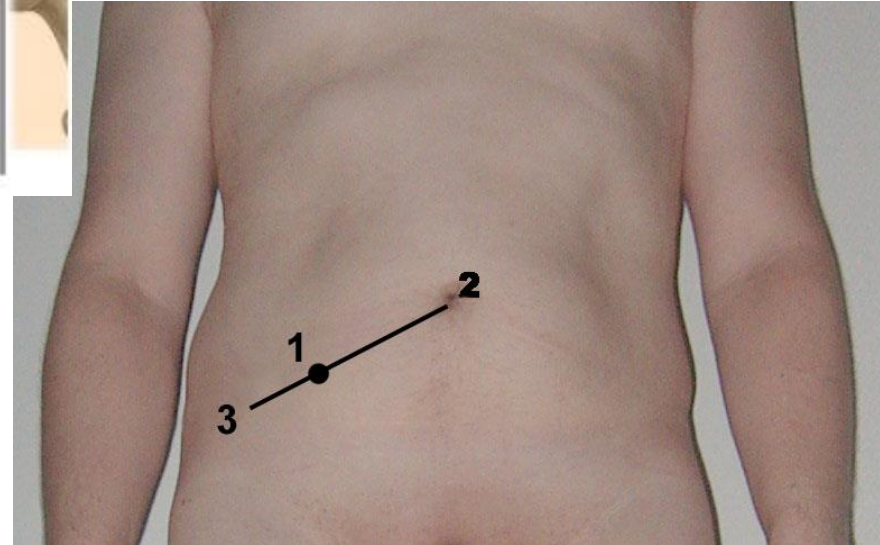
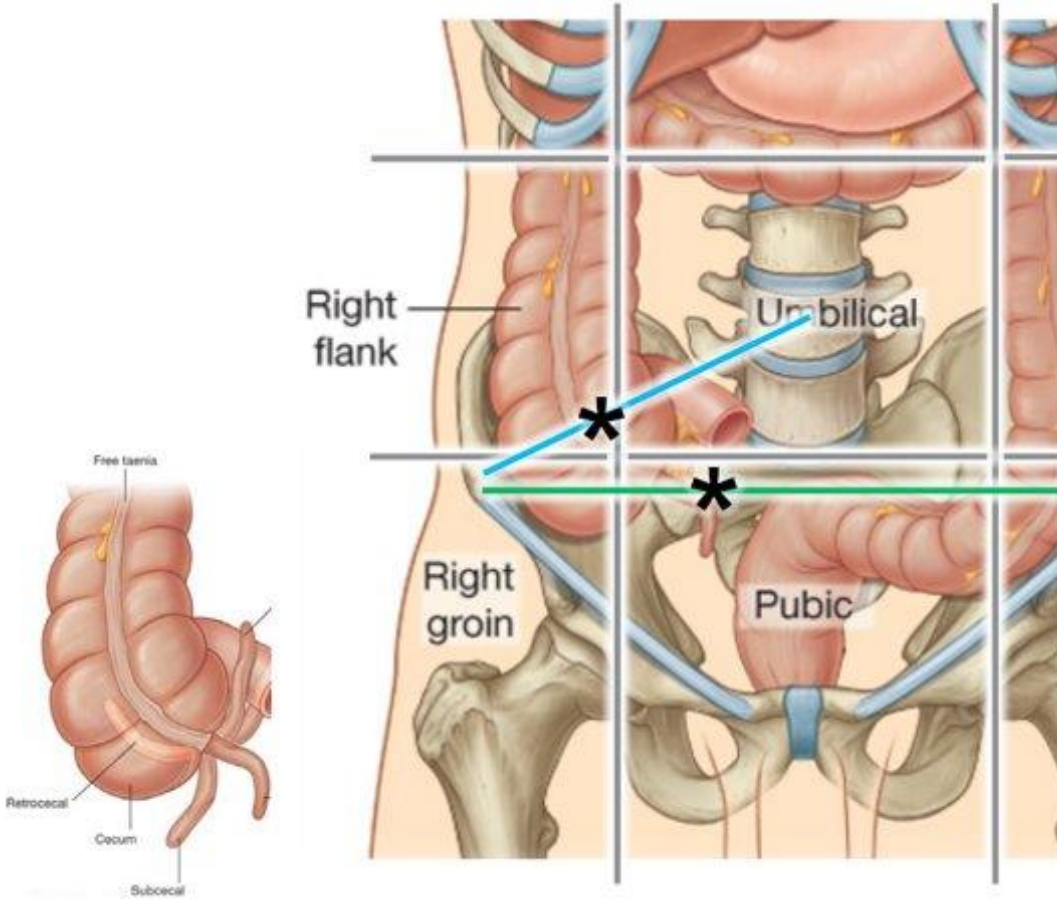
Desjardins

McBurney

Lanz

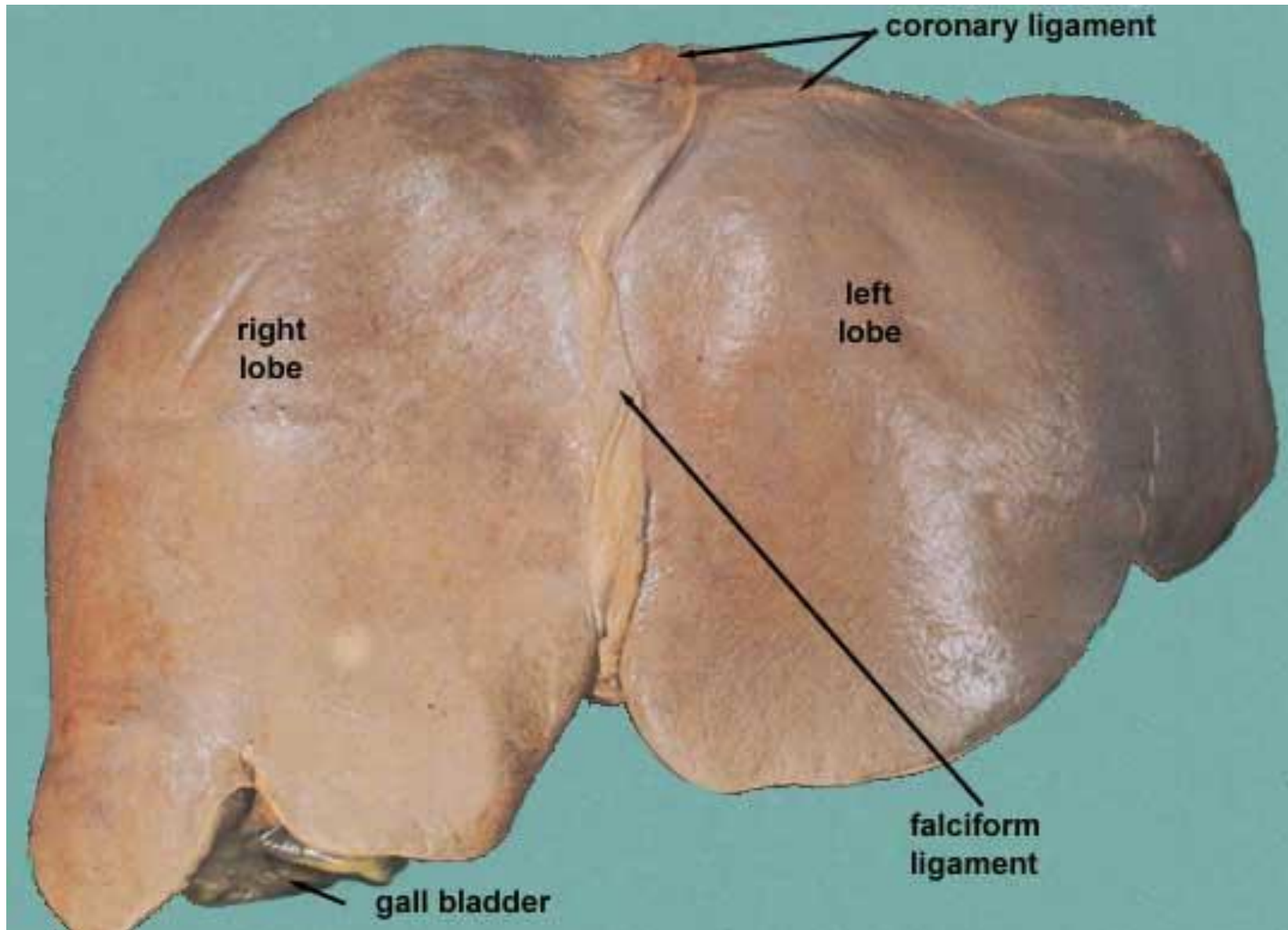


Surface Anatomy- Abdominal Organ Projection

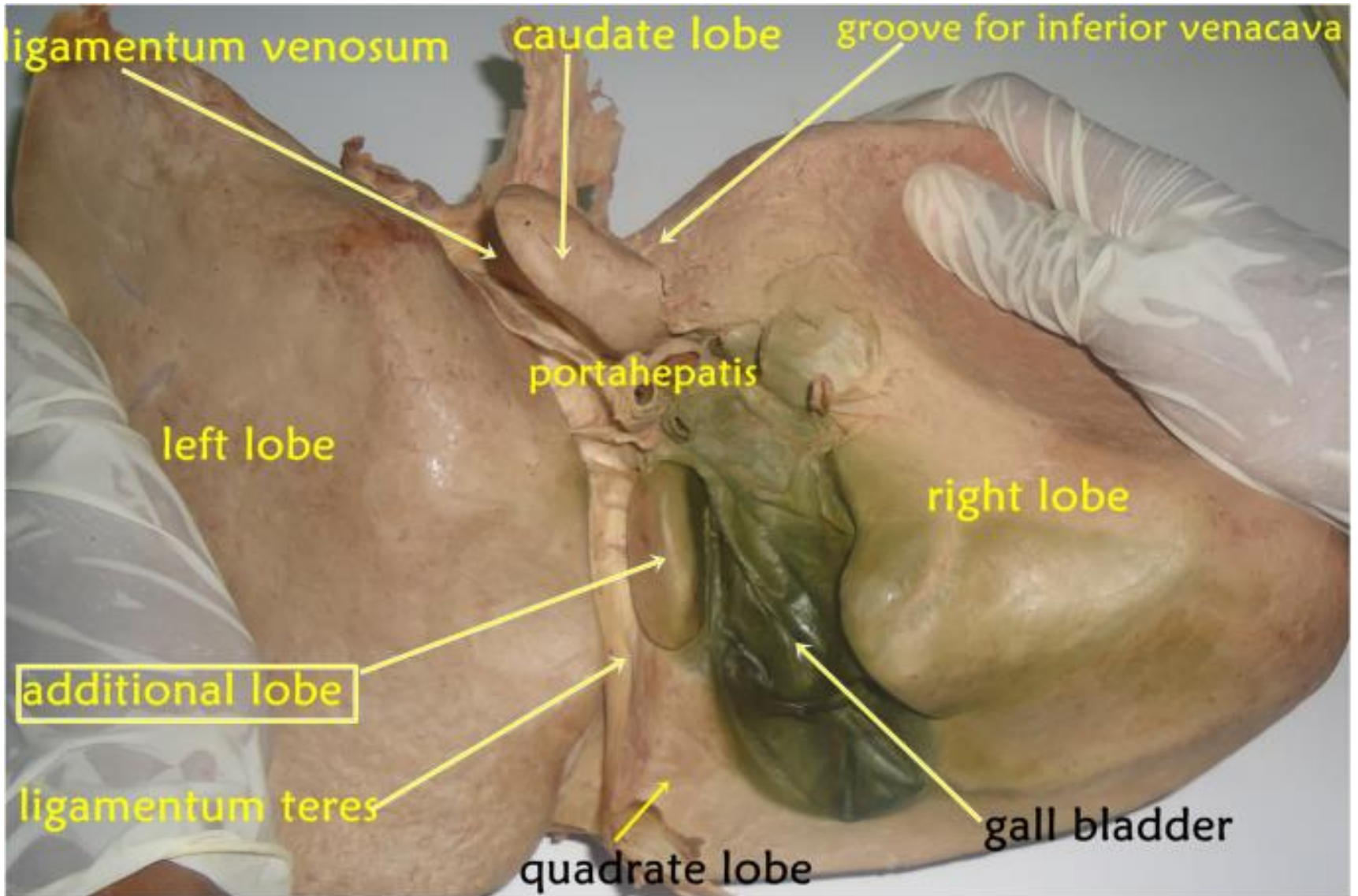


CADAVERIC SPECIMENS

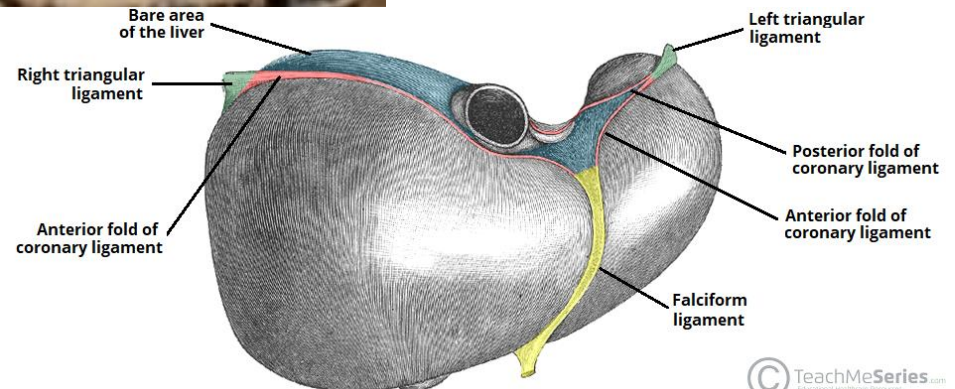
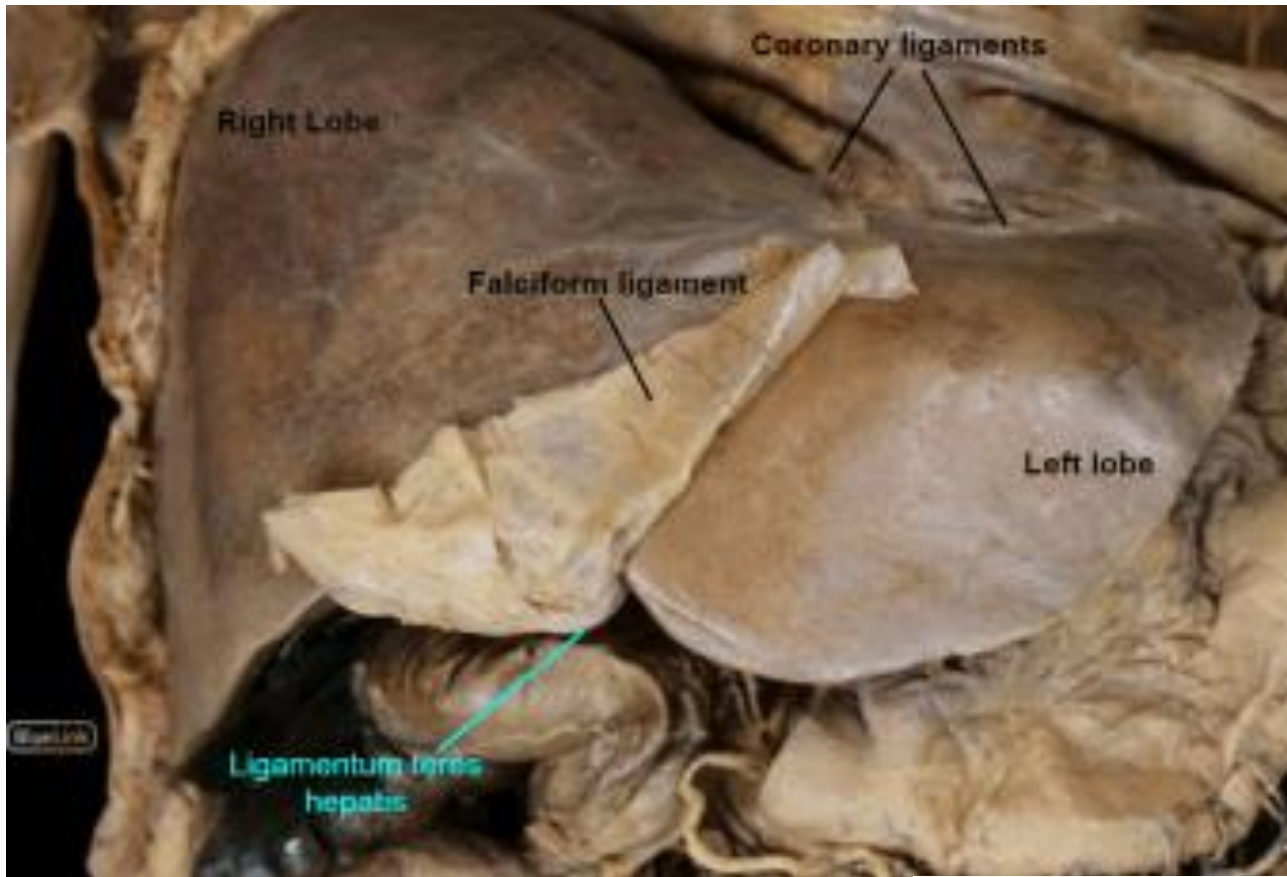
Liver- Anterior View



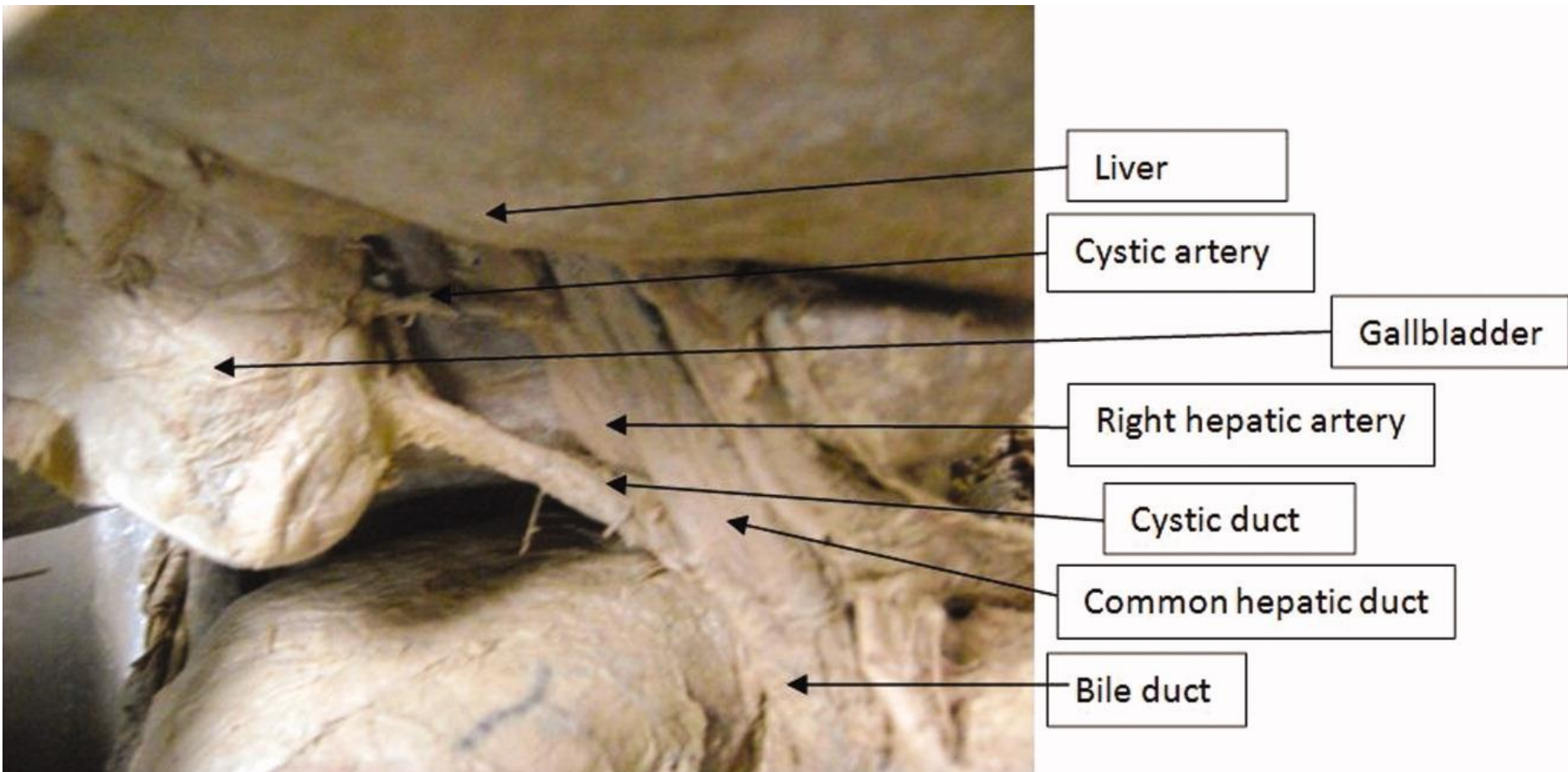
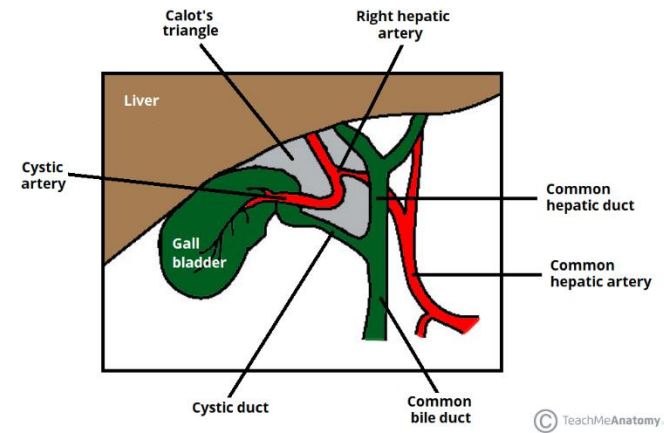
Liver- Posterior View



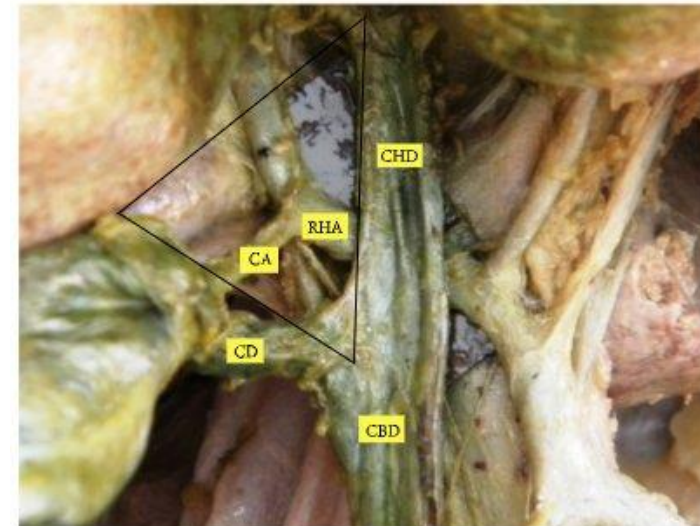
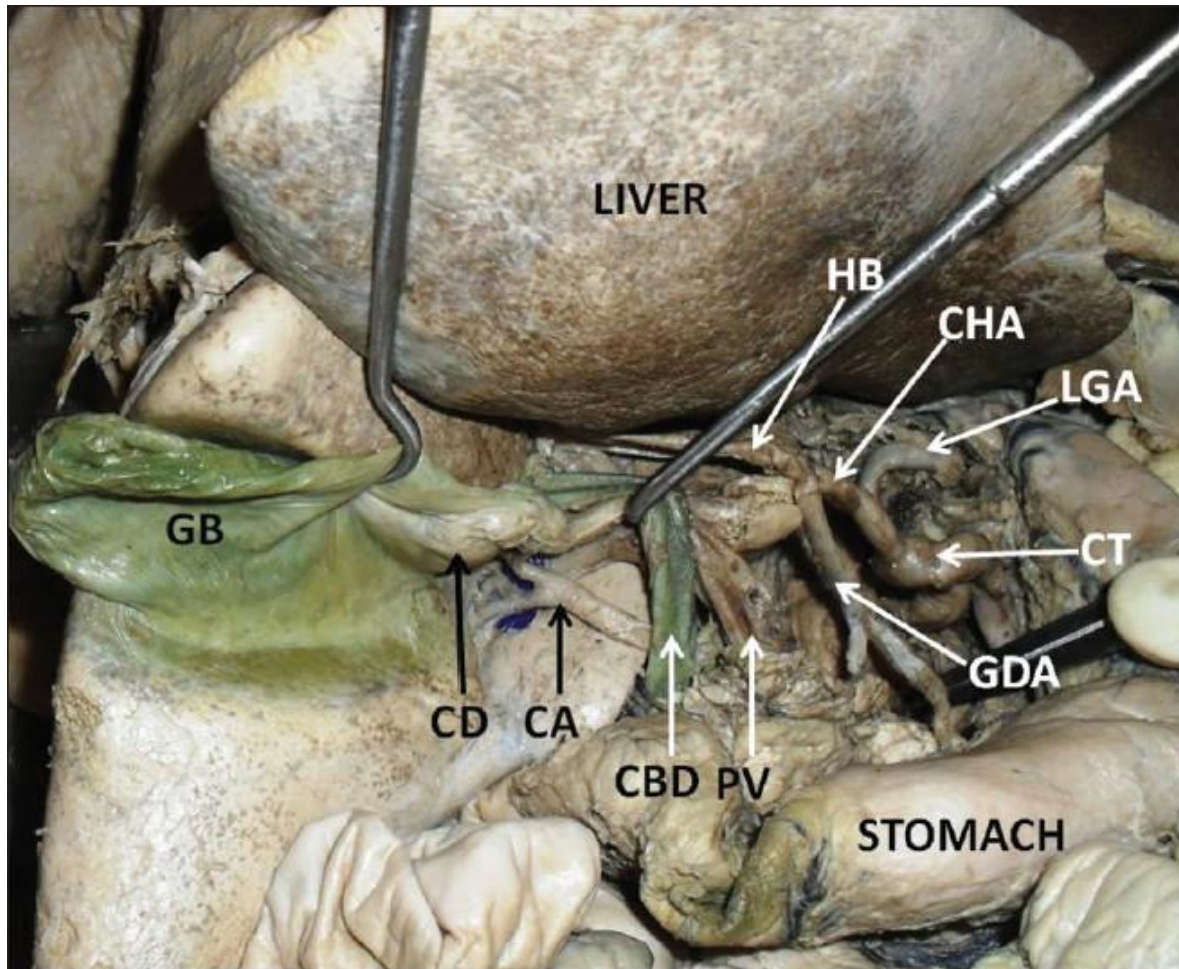
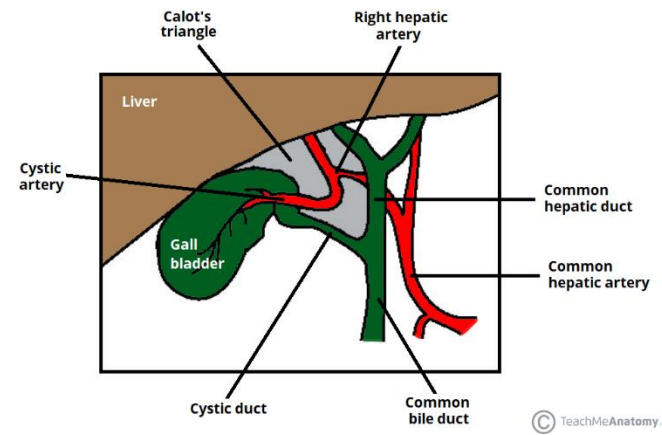
Liver Ligamentum Fixation



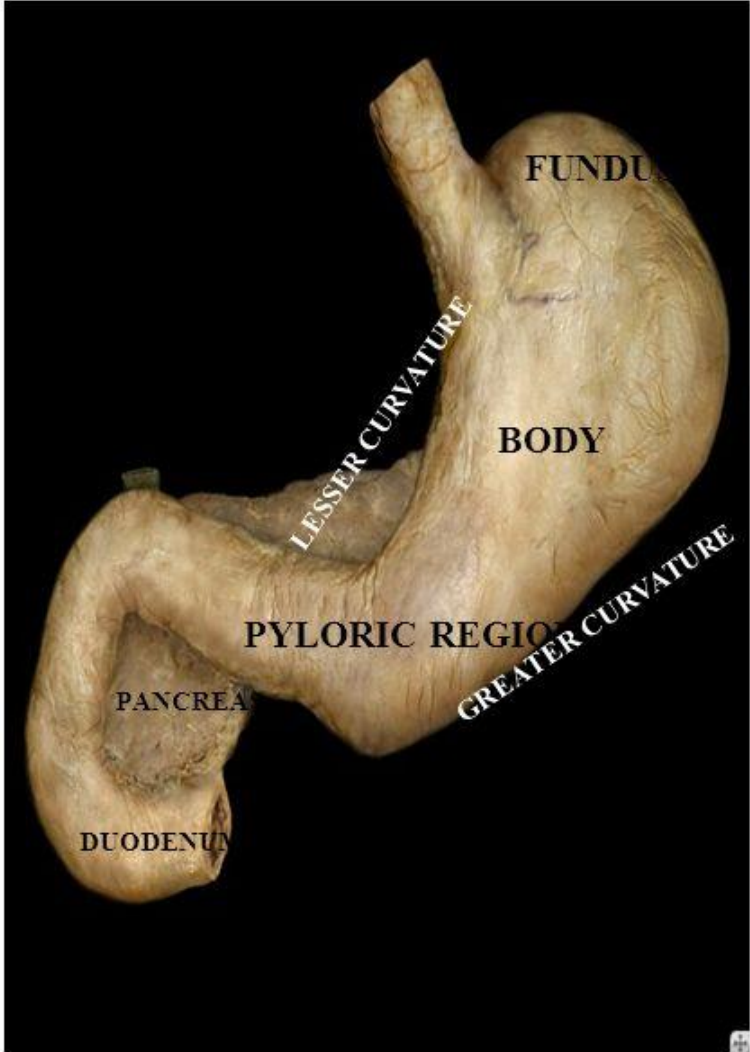
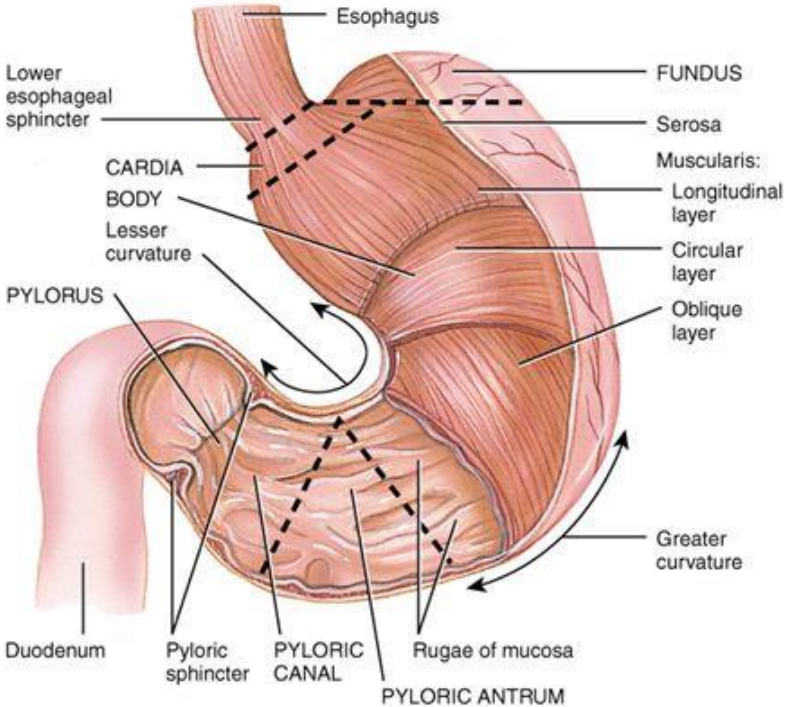
Calot Triangle



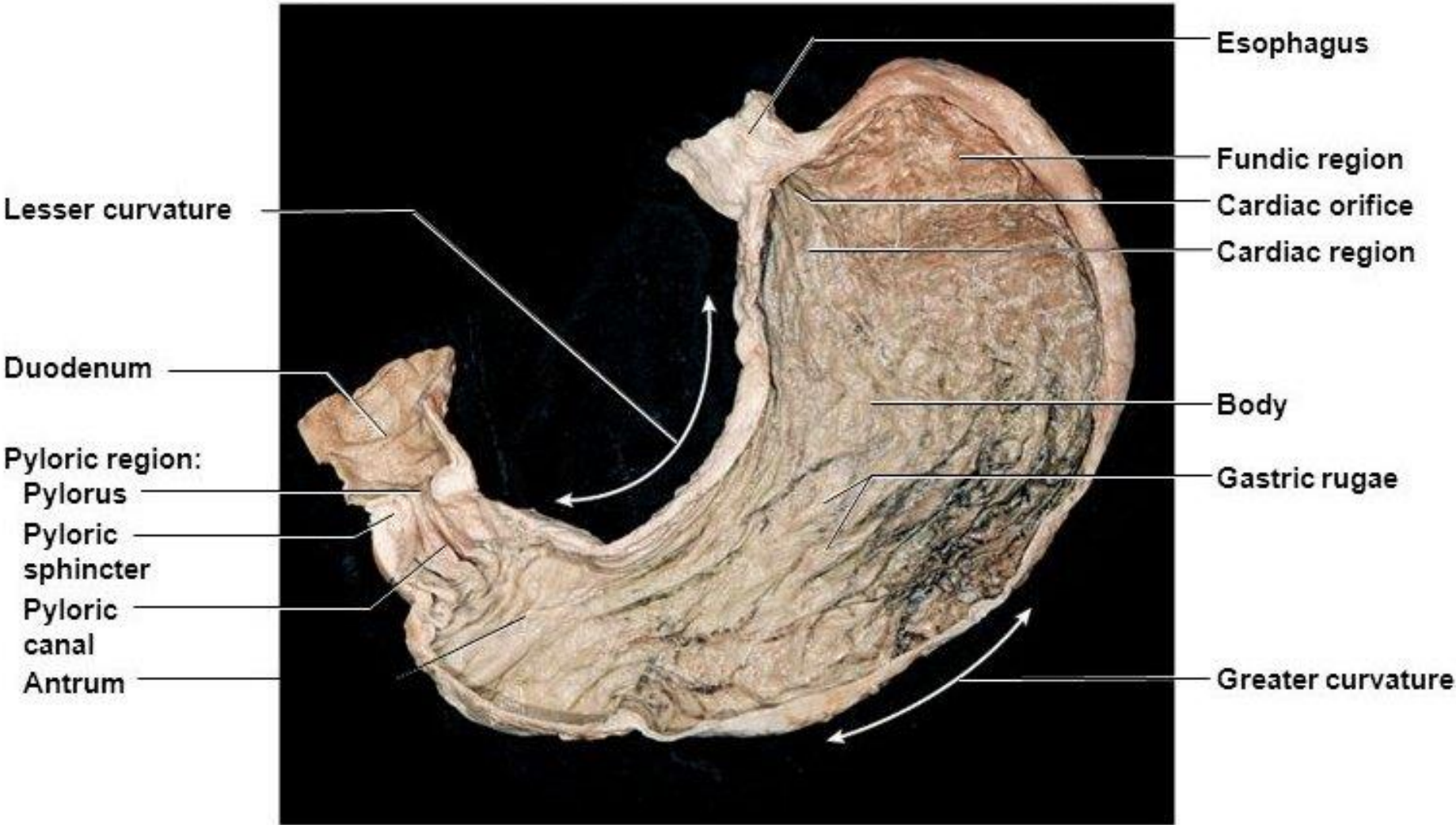
Calot Triangle



Stomach



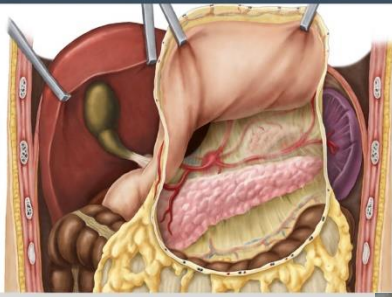Stomach



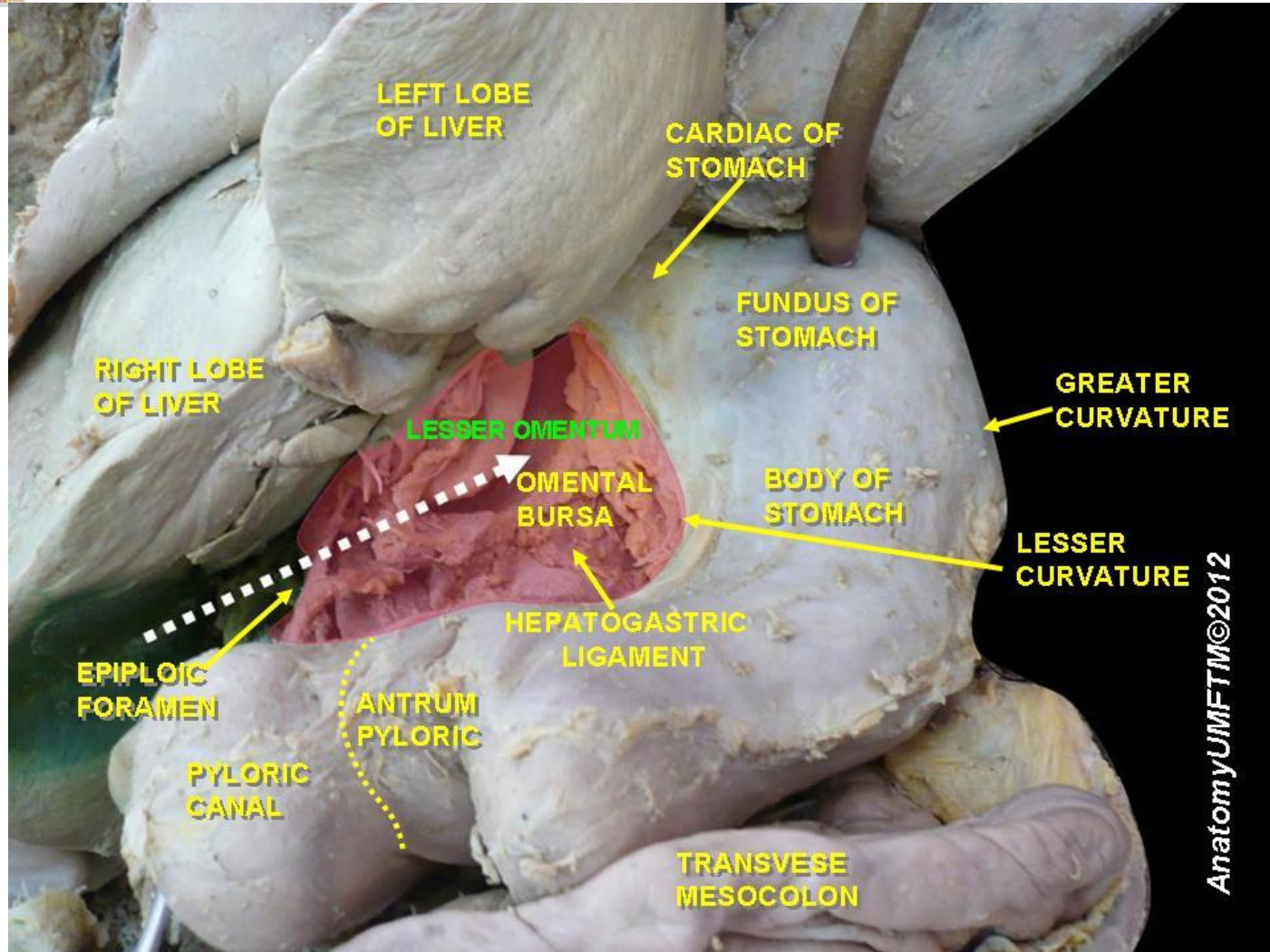
(b)

© The McGraw-Hill Companies, Inc./Rebecca Gray, photographer/Don Kincaid, dissections

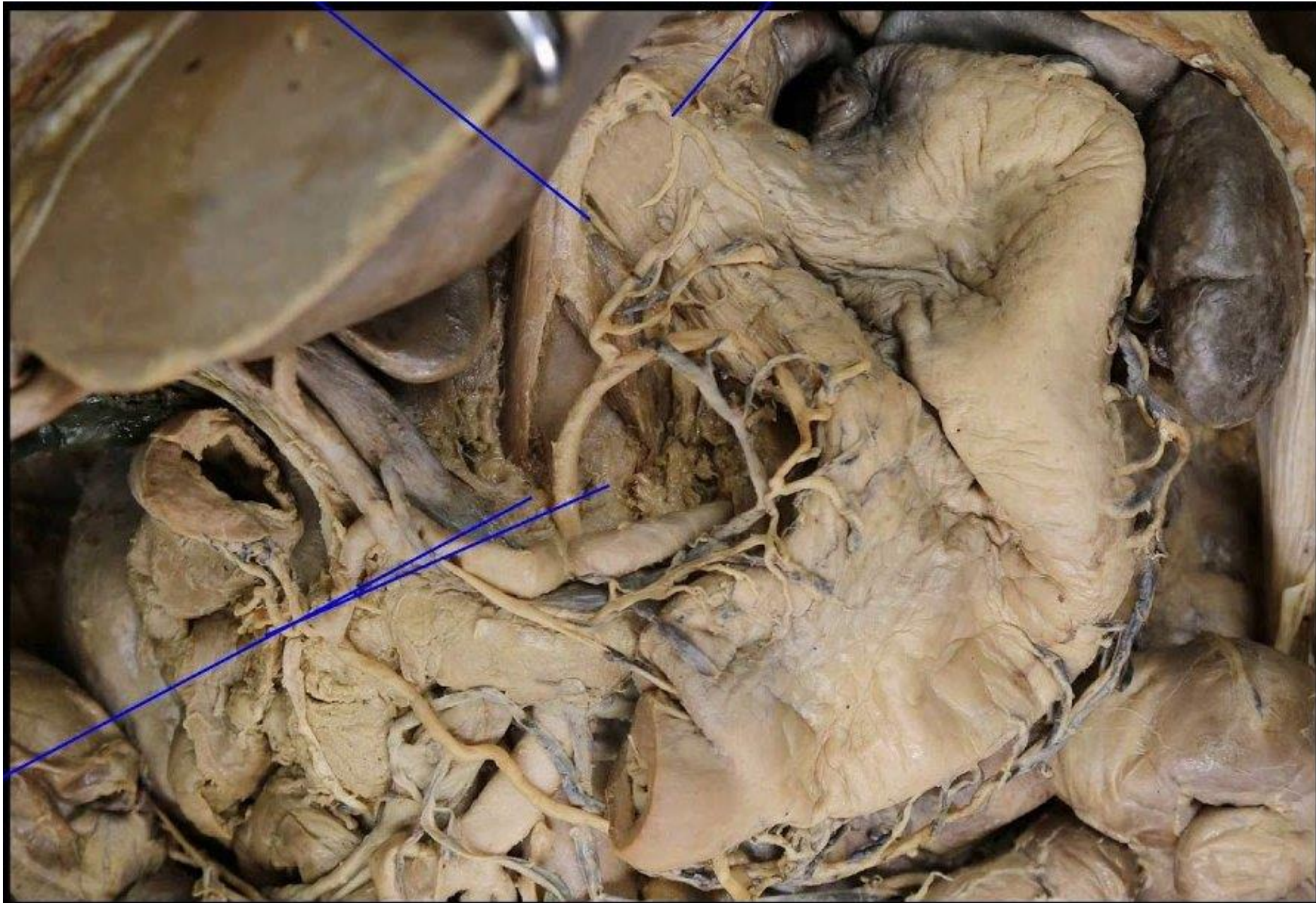
Omental bursa



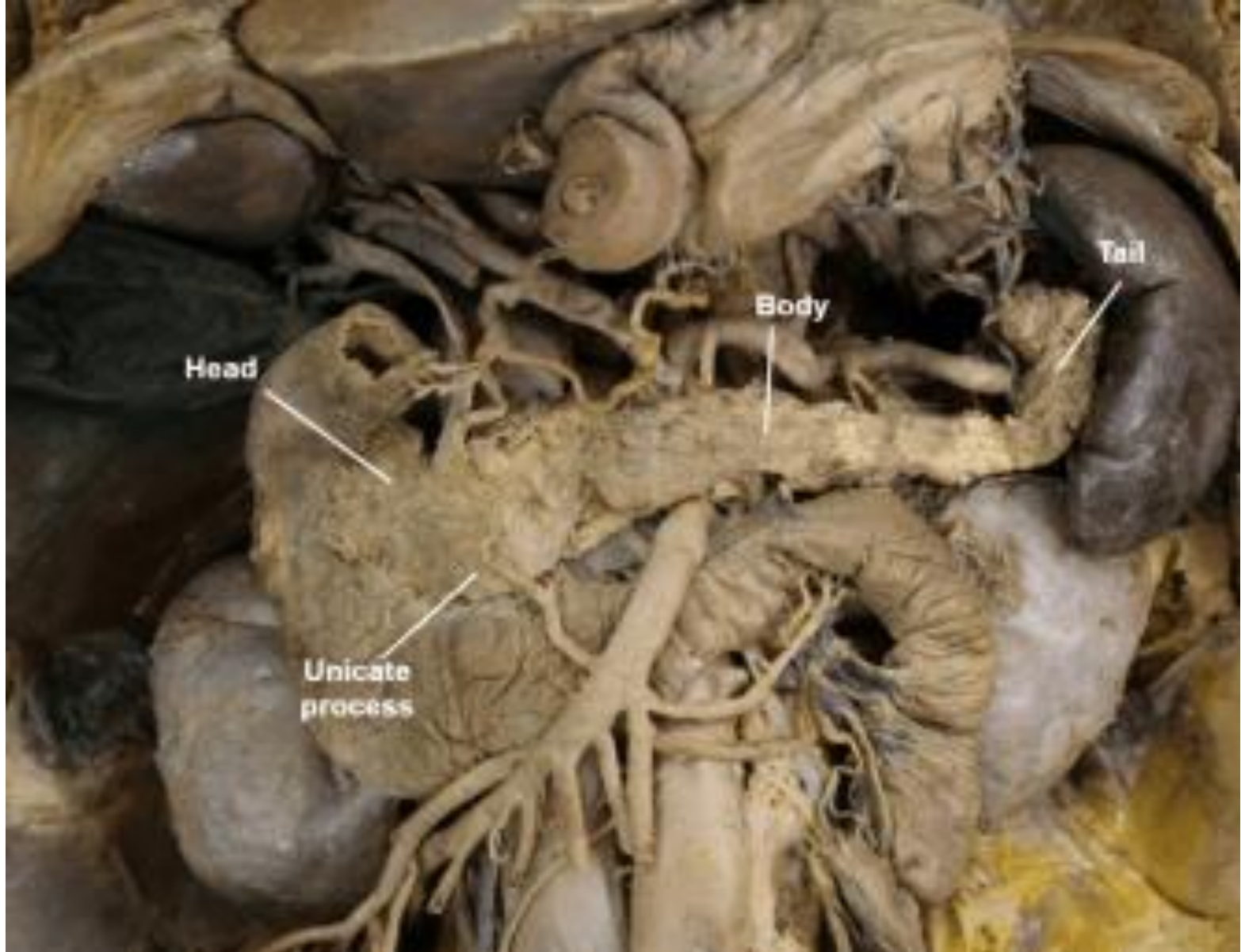
K



Celiac Trunk

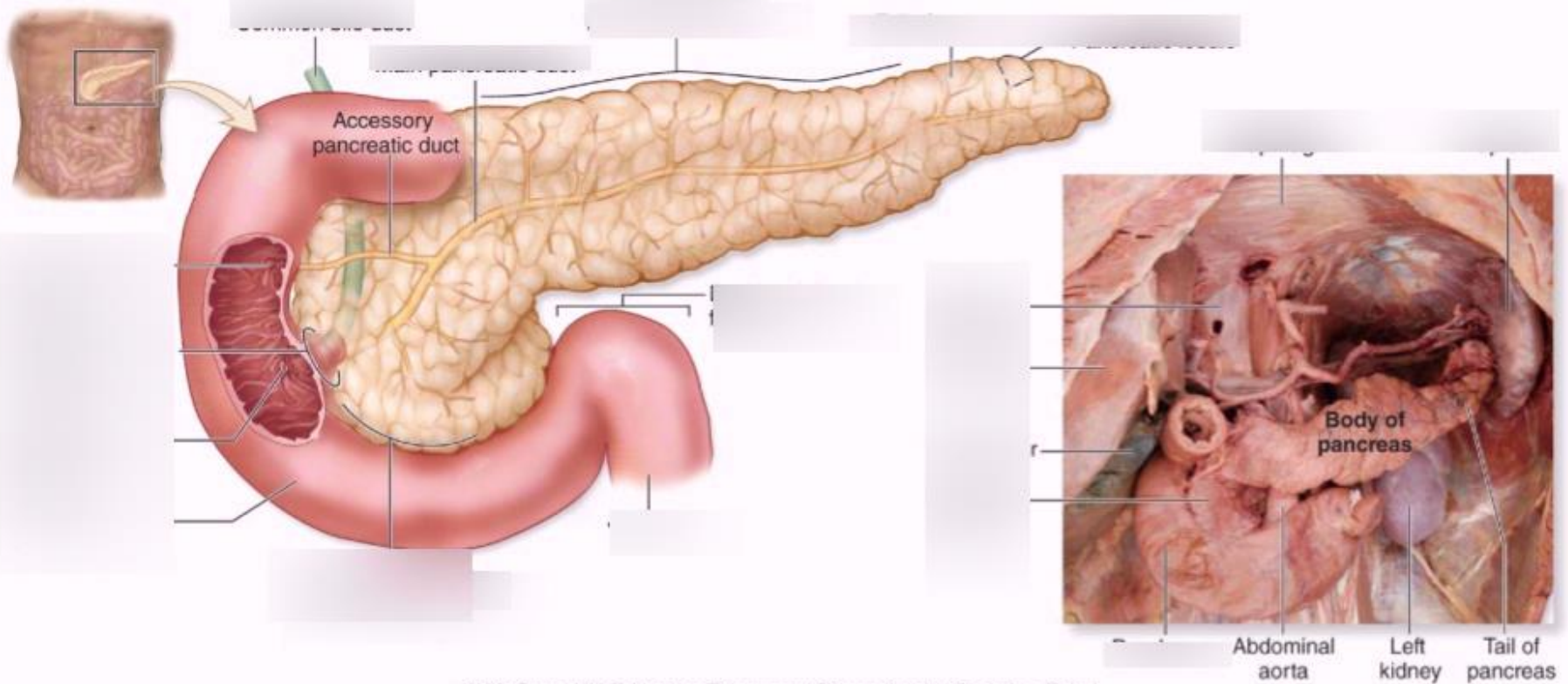


Pancreas



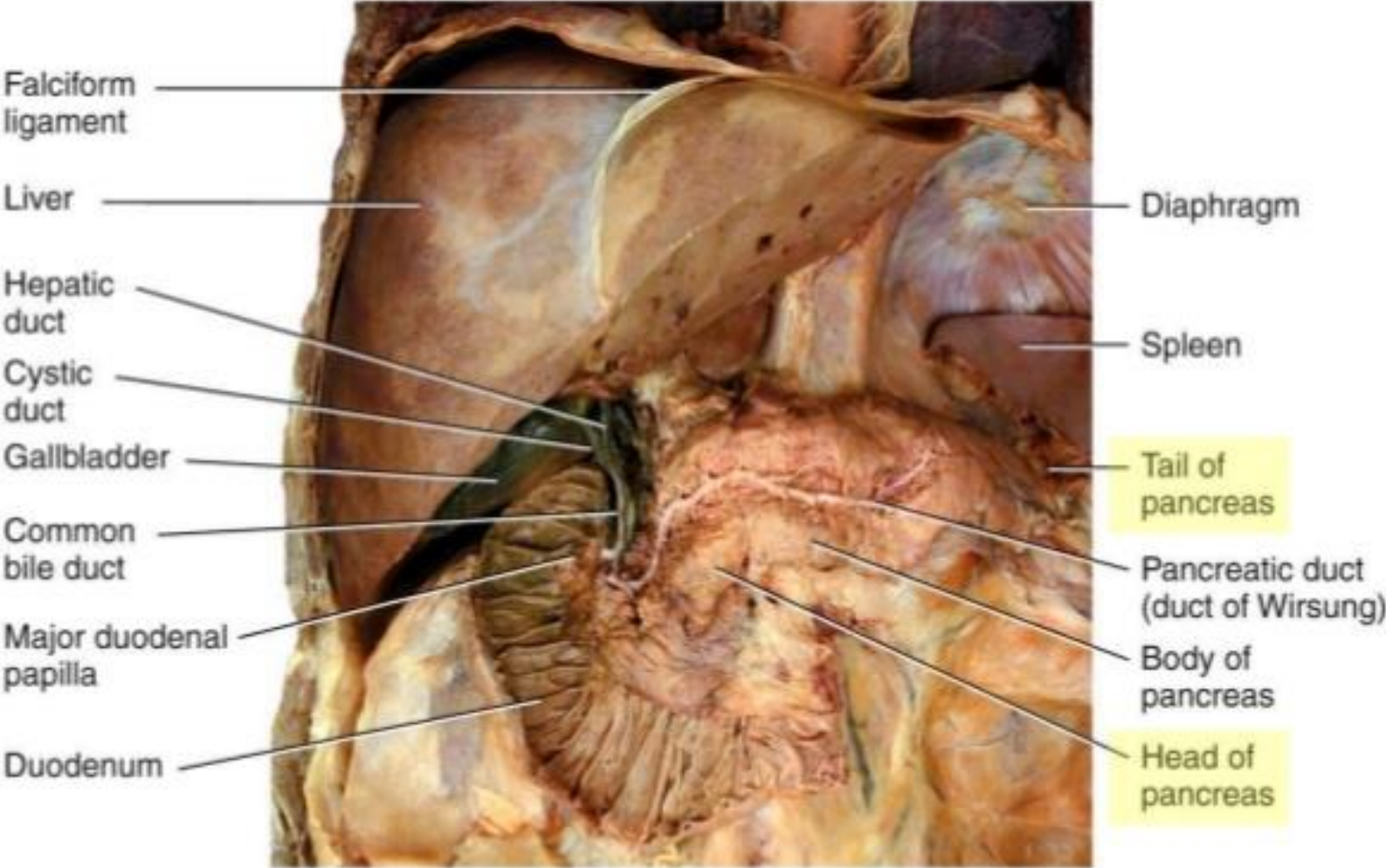
Pancreas

Copyright © McGraw-Hill Education. Permission required for reproduction or display.

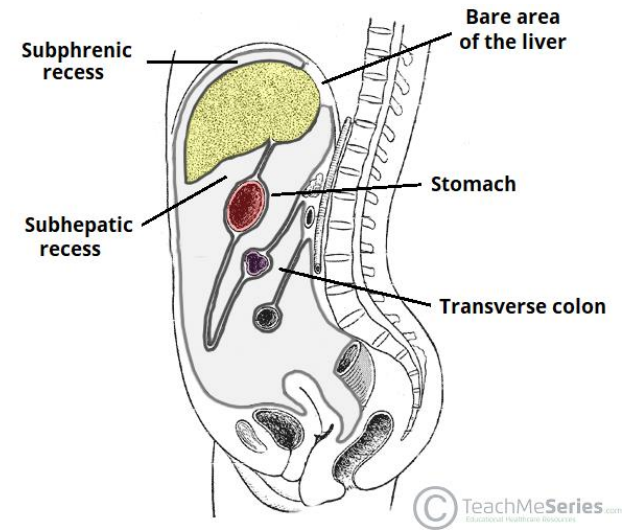
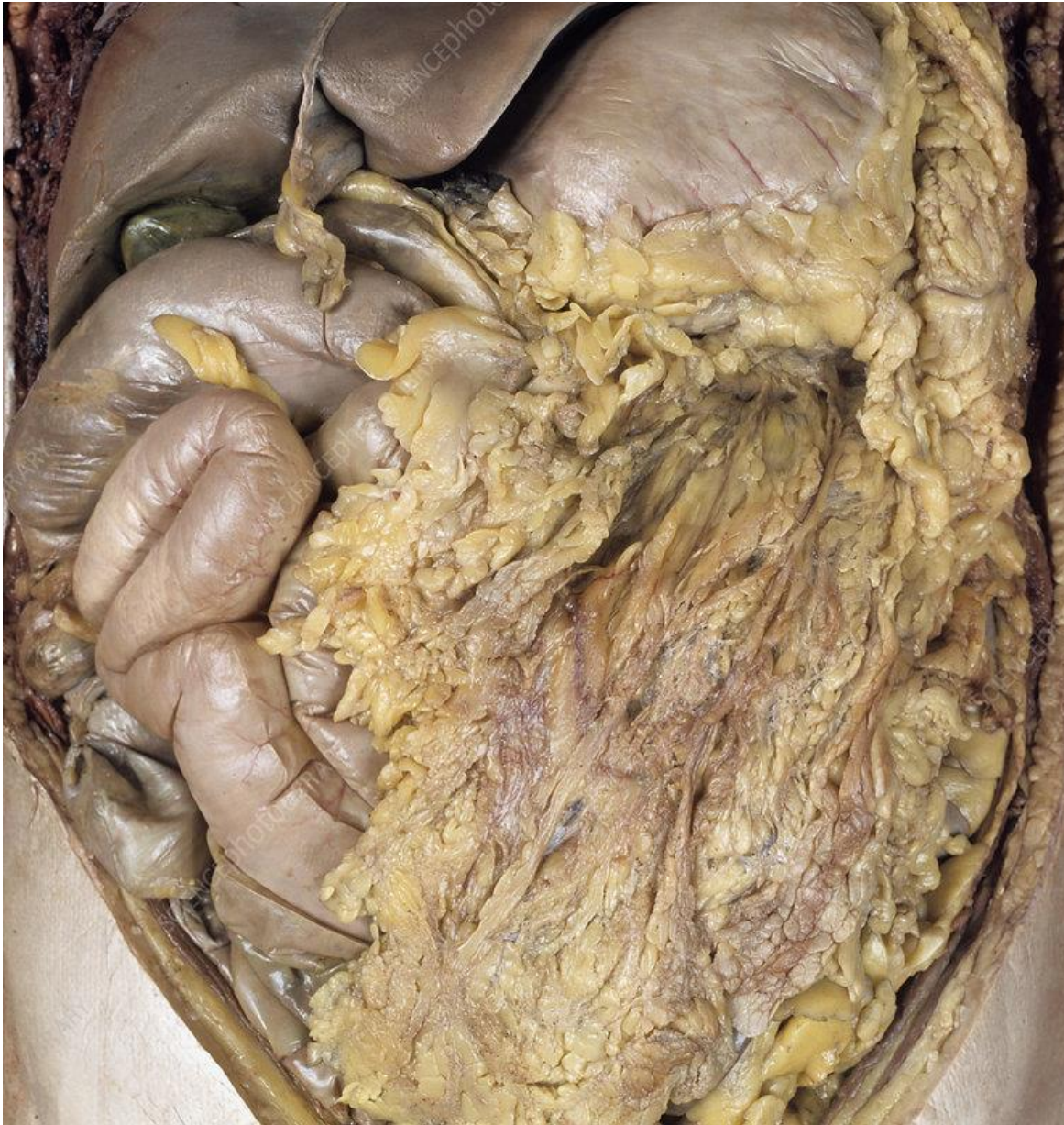


© McGraw-Hill Education/Photo and Dissection by Christine Eckel

The Pancreas



Greater Omentum



After Reflecting away Greater omentum

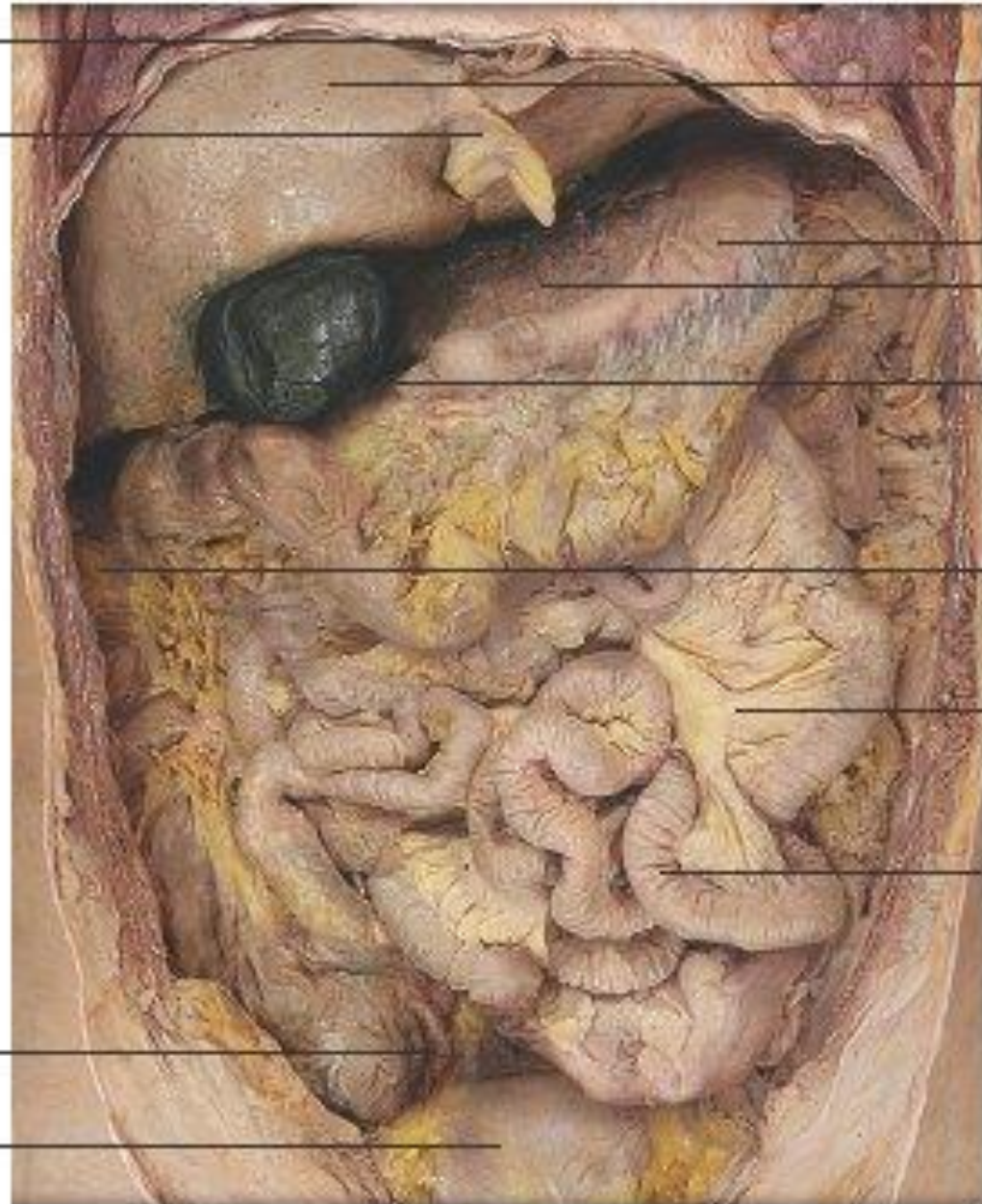
Diaphragm

Falciform ligament

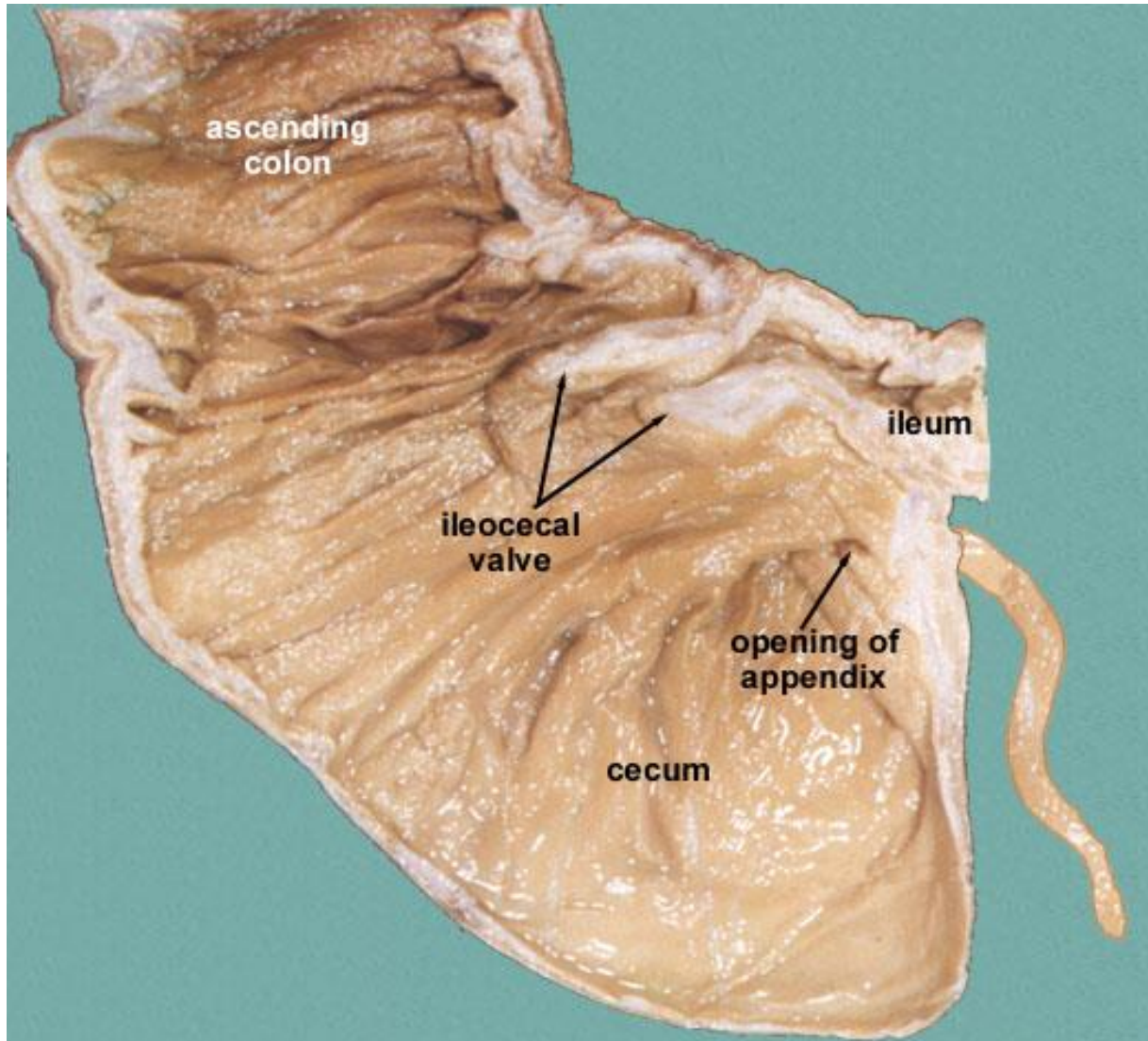
Terms:
Gallbladder
Large intestine
Lesser omentum
Liver
Mesentery
Small intestine
Stomach

Appendix

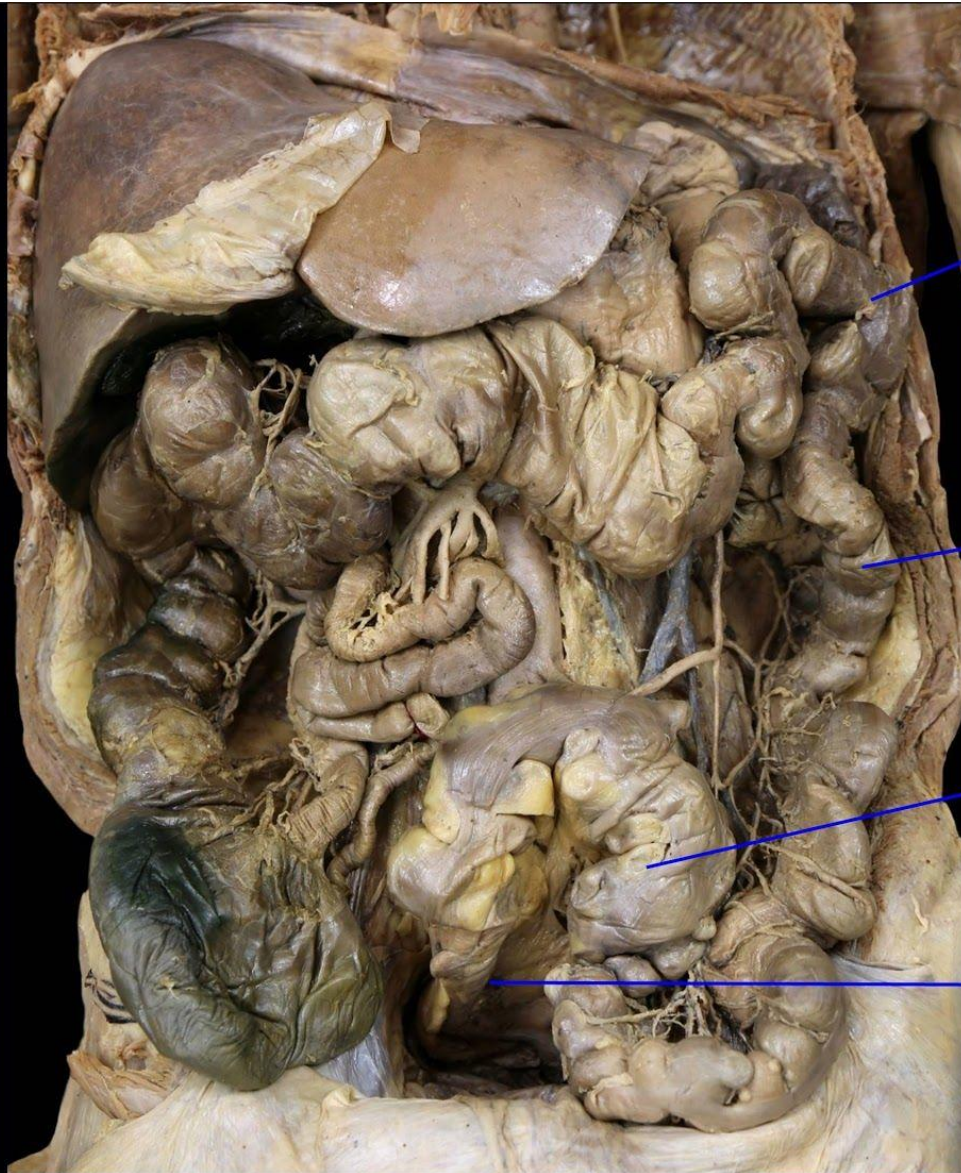Urinary bladder



Ileocecal Junction



Large Intestine



Left colic
(splenic)
flexure

Descending
colon

Sigmoid
colon

Rectum

Abdominal cavity, anterior

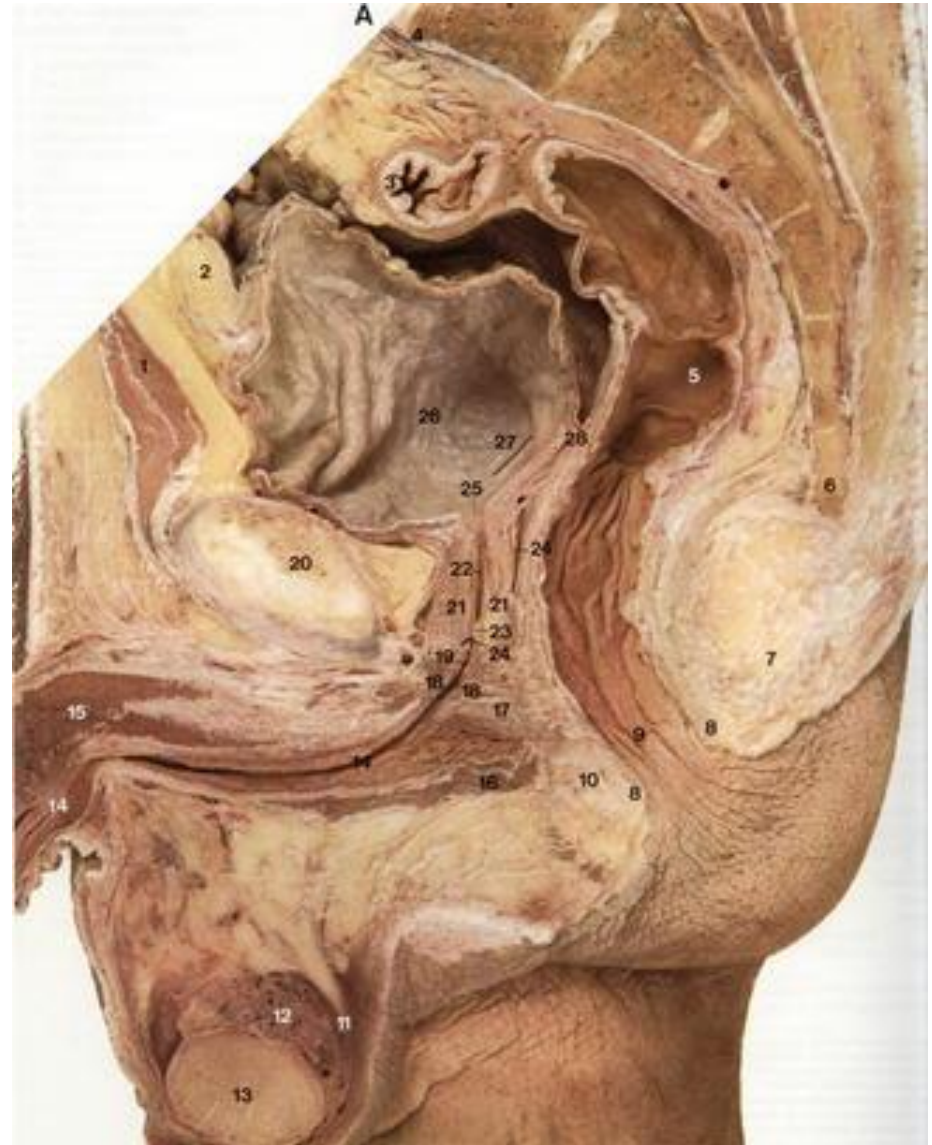
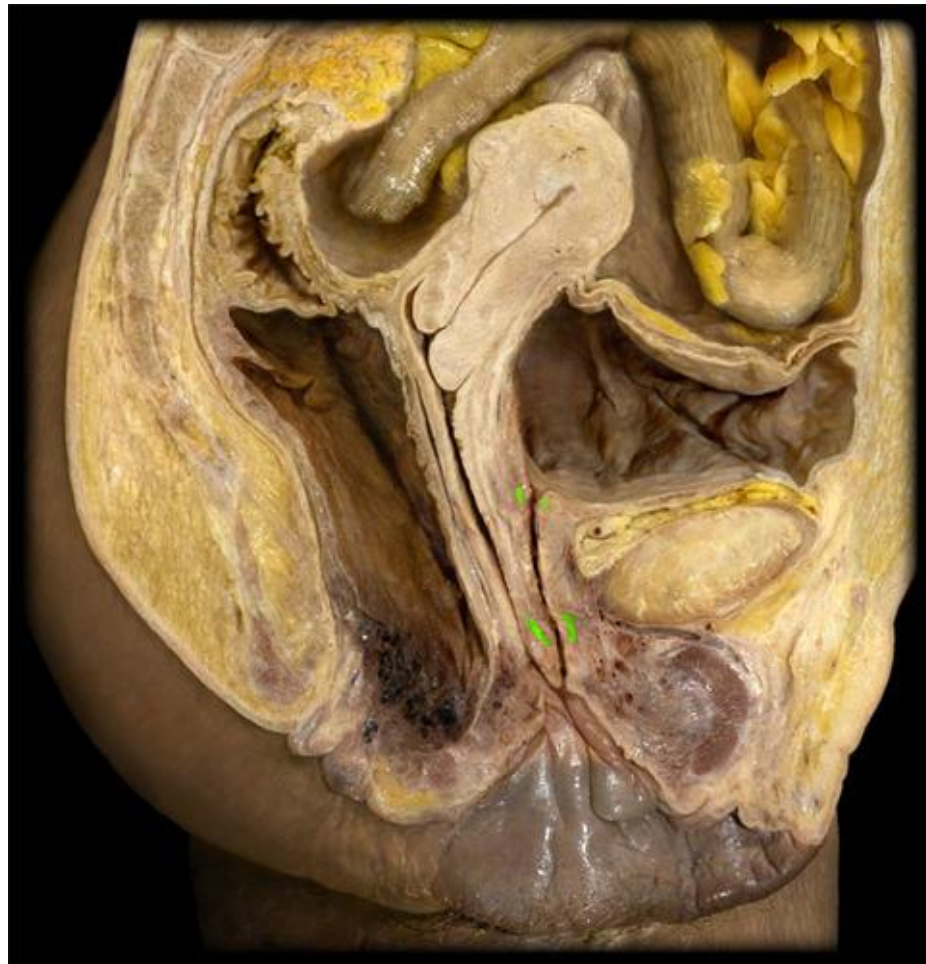BlueLink

© B. Kathleen Alsup & Glenn M. Fox

Rectum & Anal Canal

Female

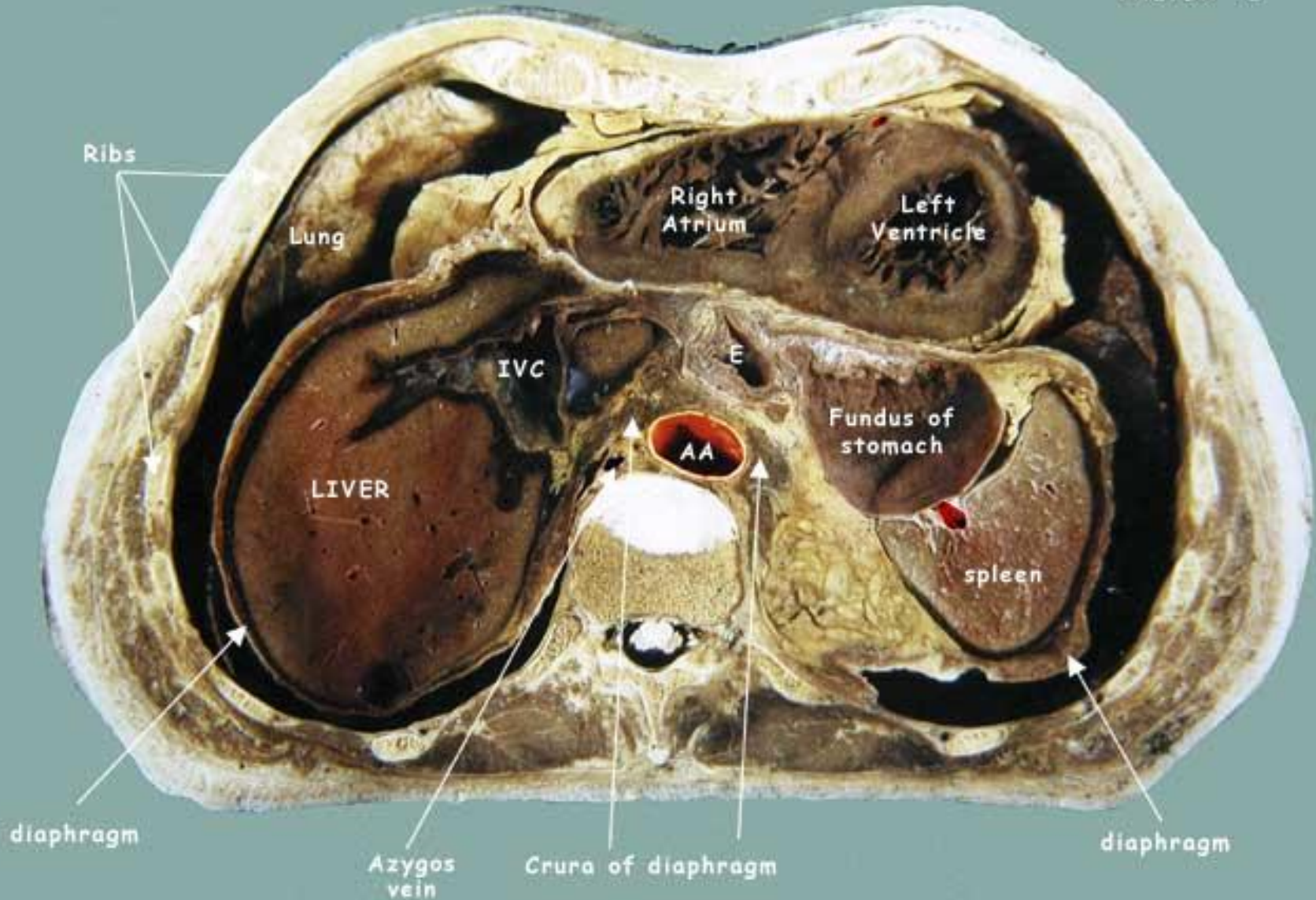
Male



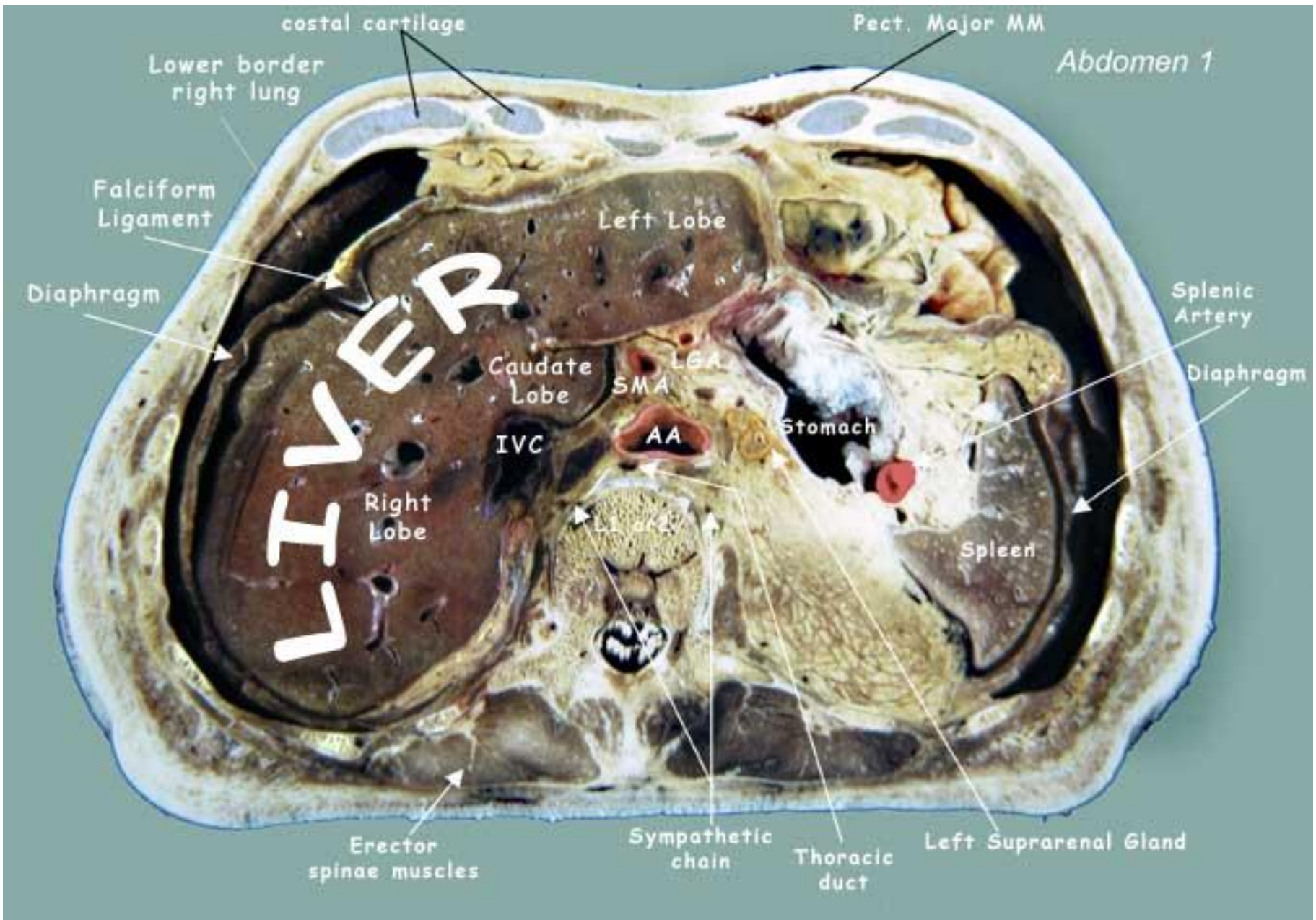
CROSS SECTIONAL ANATOMY

Cross Sectional Anatomy- Th10

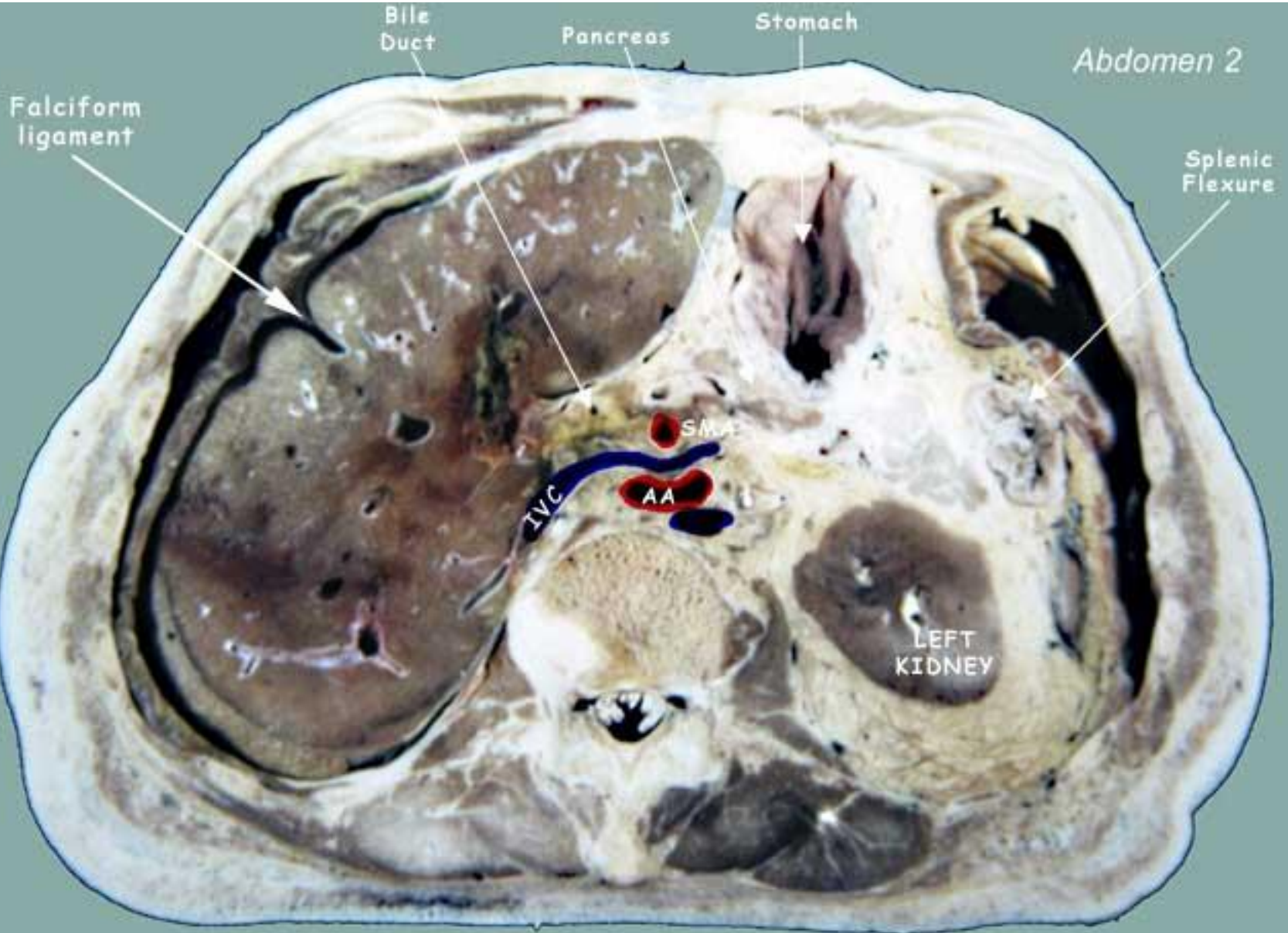
Thorax 13



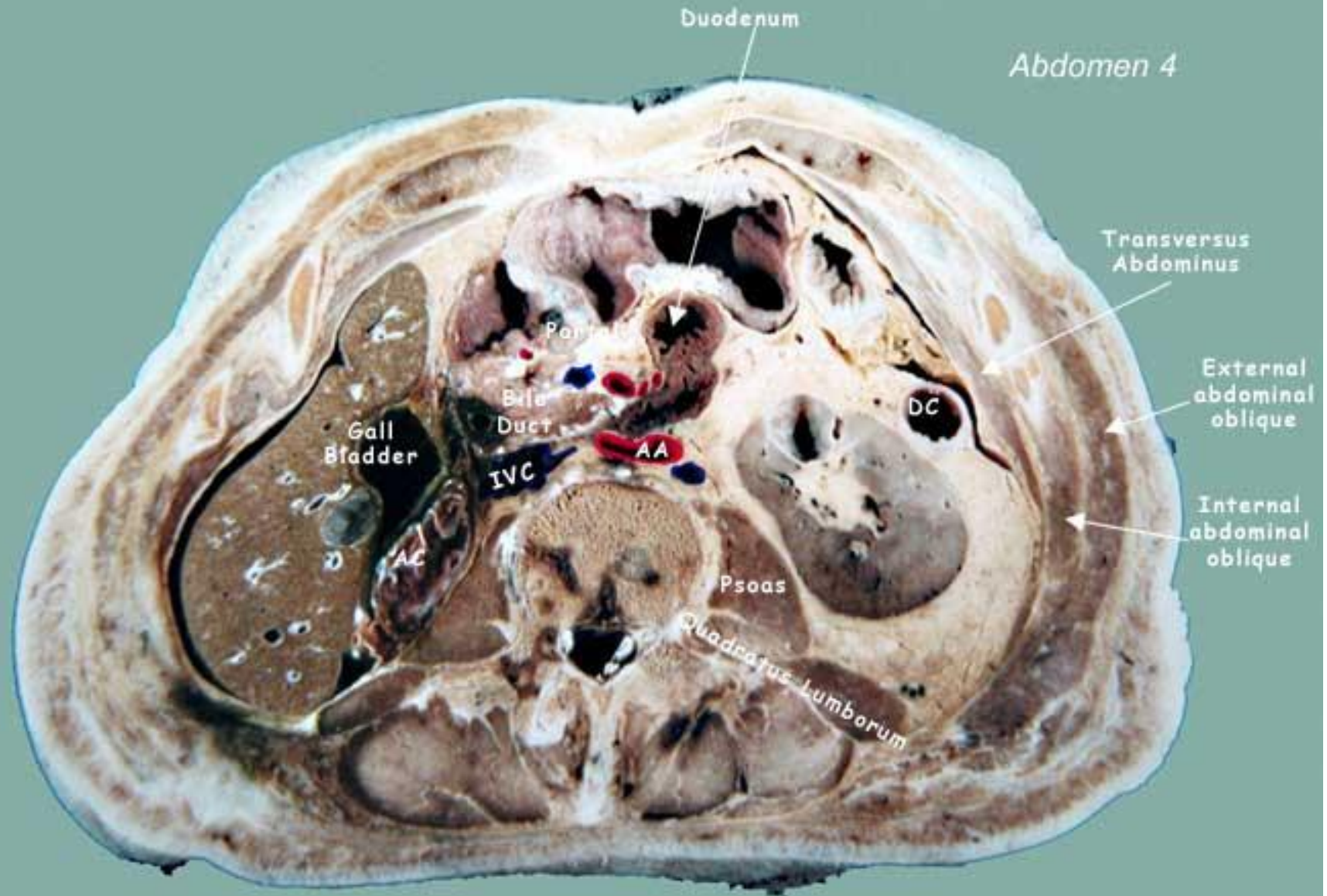
Cross Sectional Anatomy- L1/L2



Cross Sectional Anatomy- L2

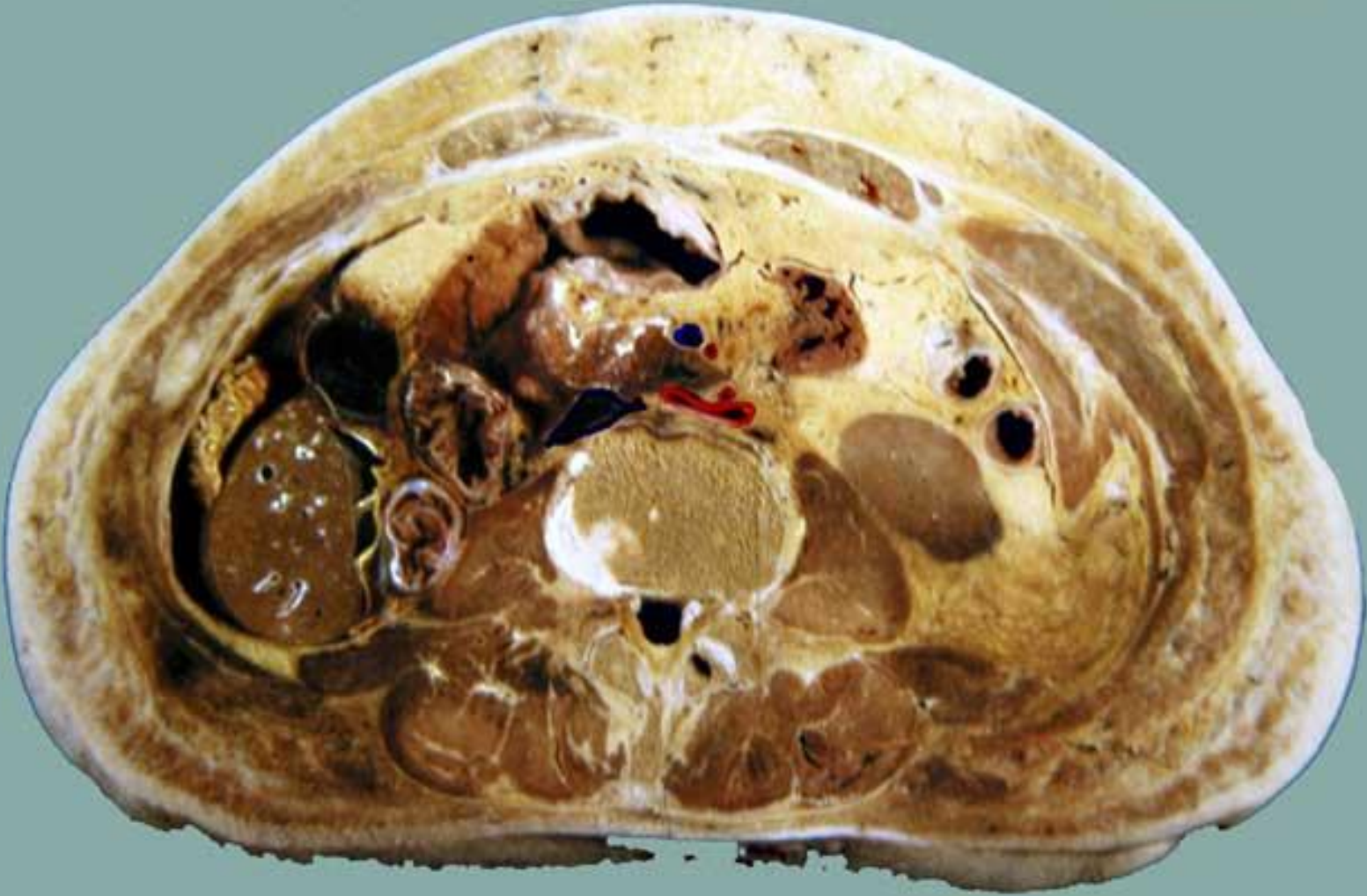


Cross Sectional Anatomy- L2/L3

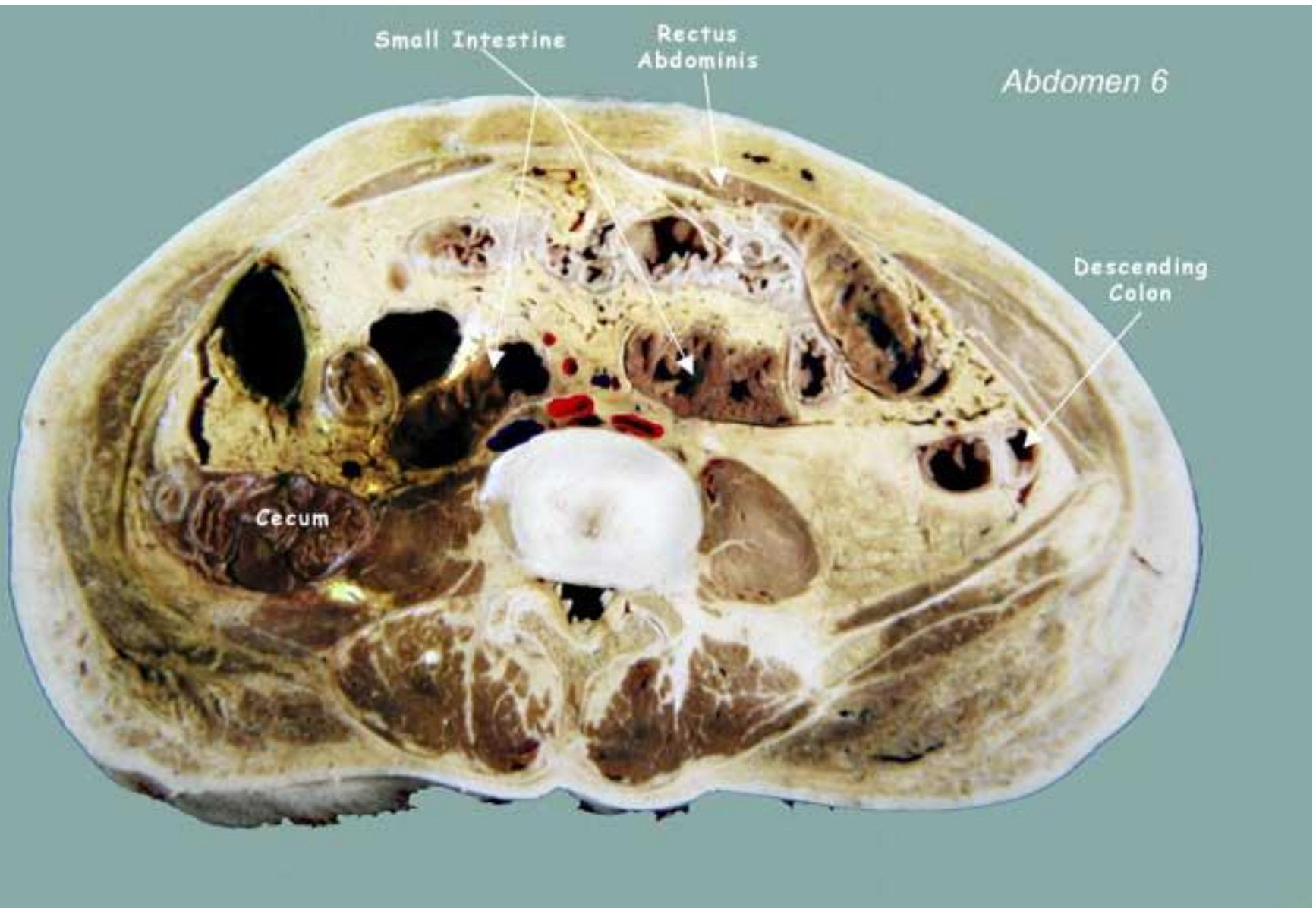


Cross Sectional Anatomy- L3

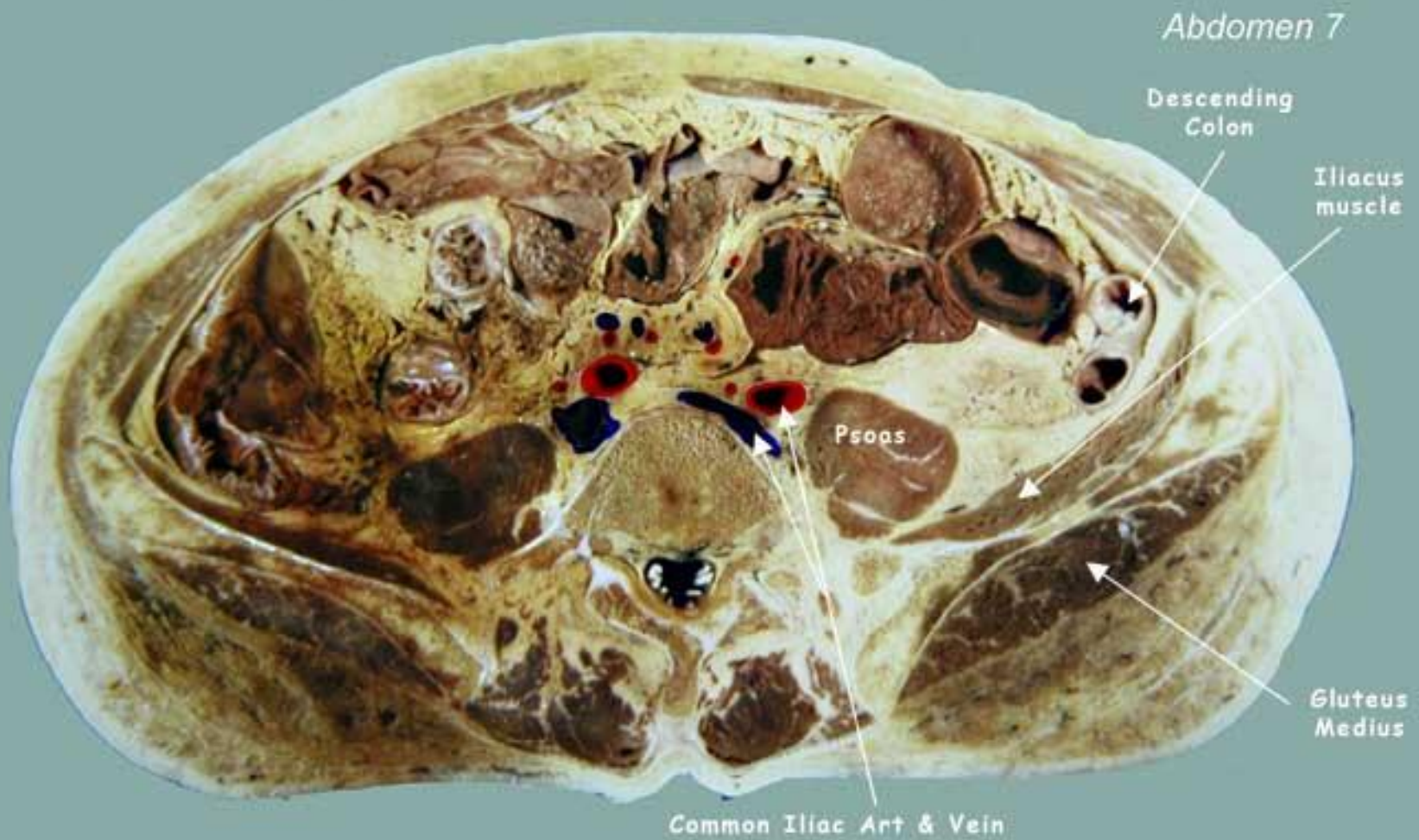Abdomen 5



Cross Sectional Anatomy- L4

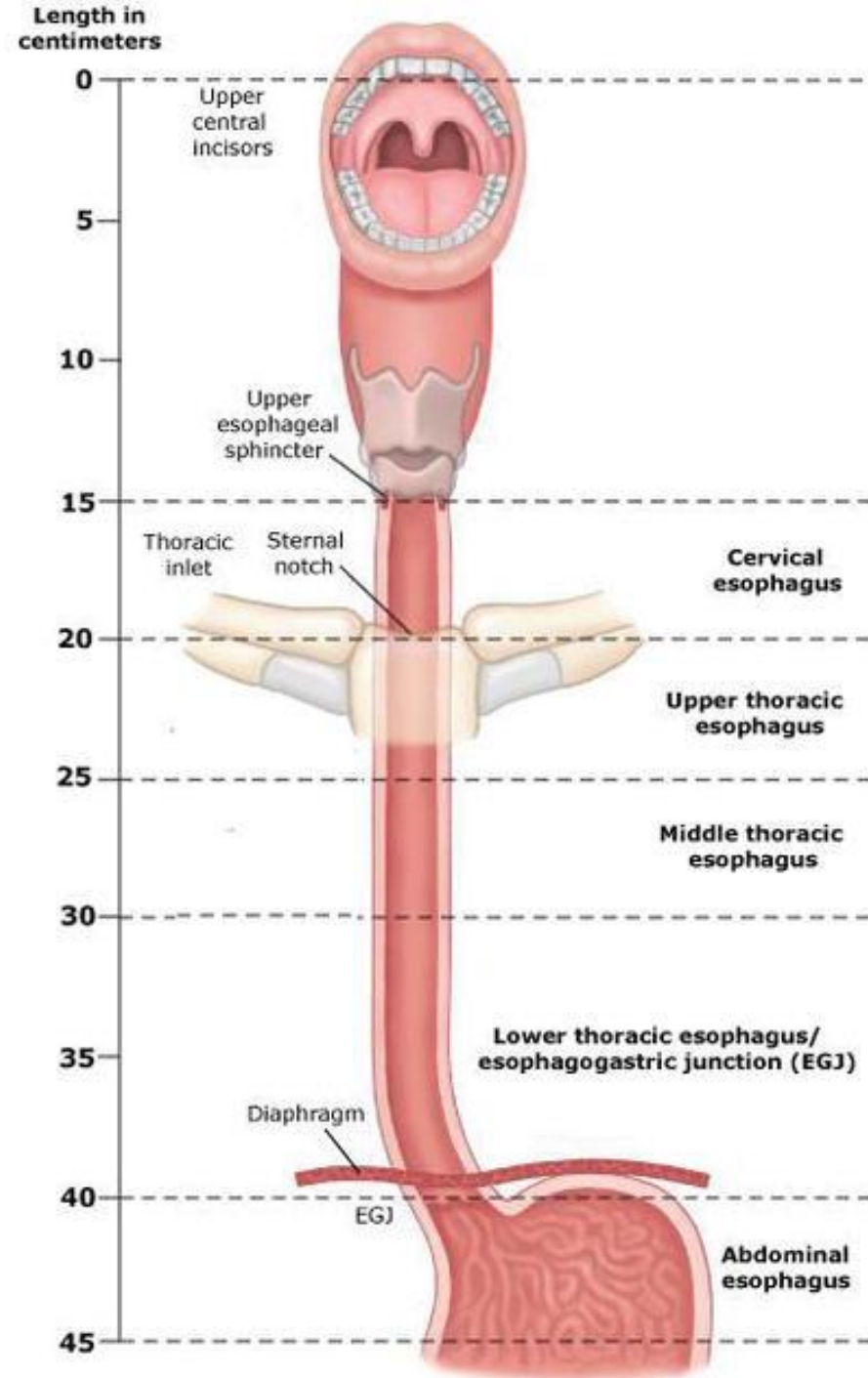


Cross Sectional Anatomy- L5



ENDOSCOPIC ANATOMY

Upper GIT Rout



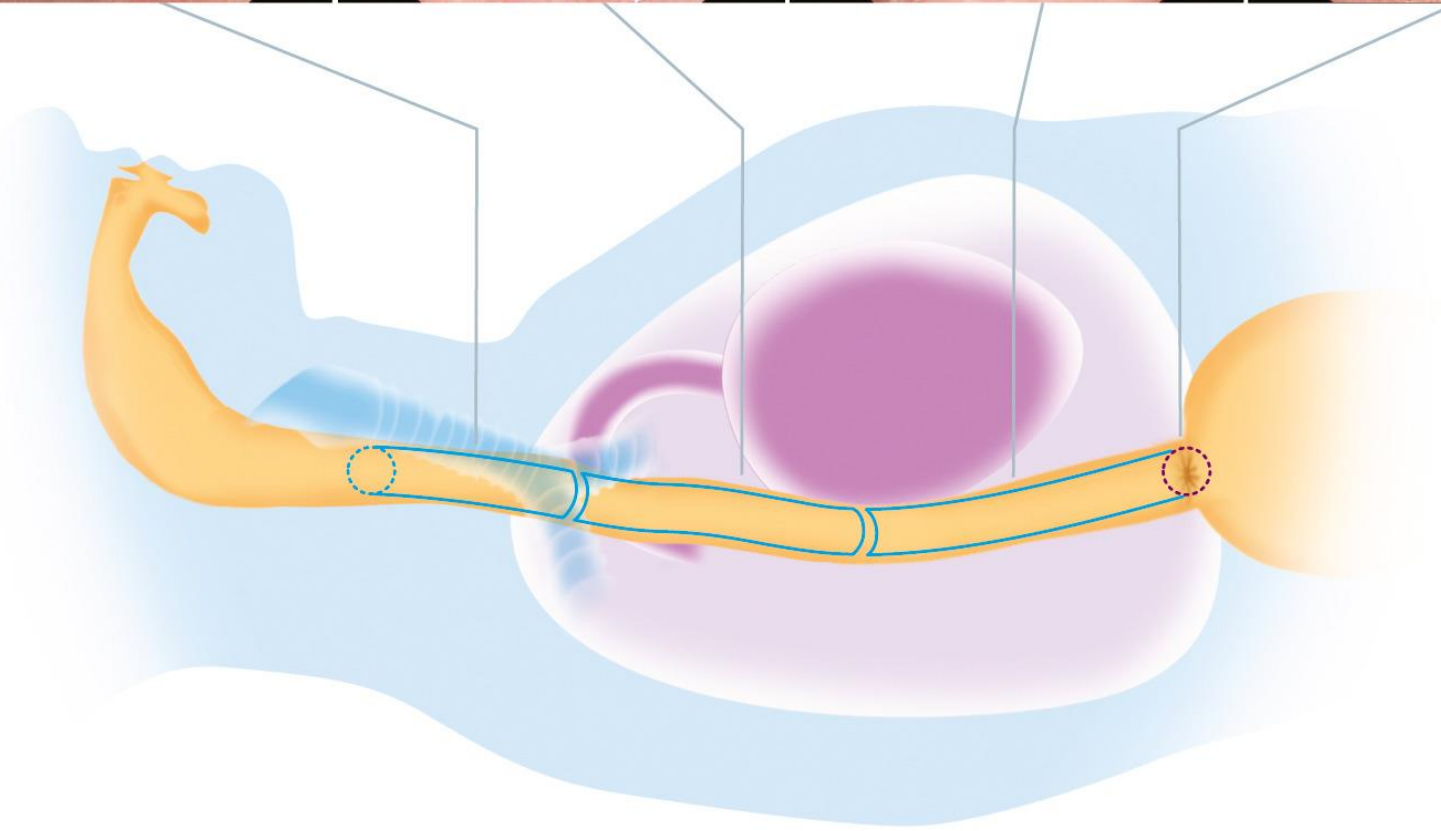
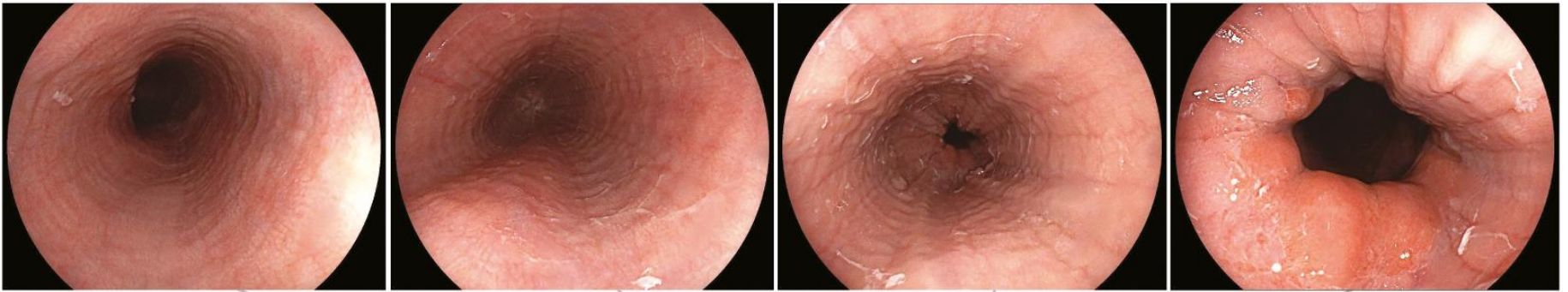
Esophagus

1. Upper third

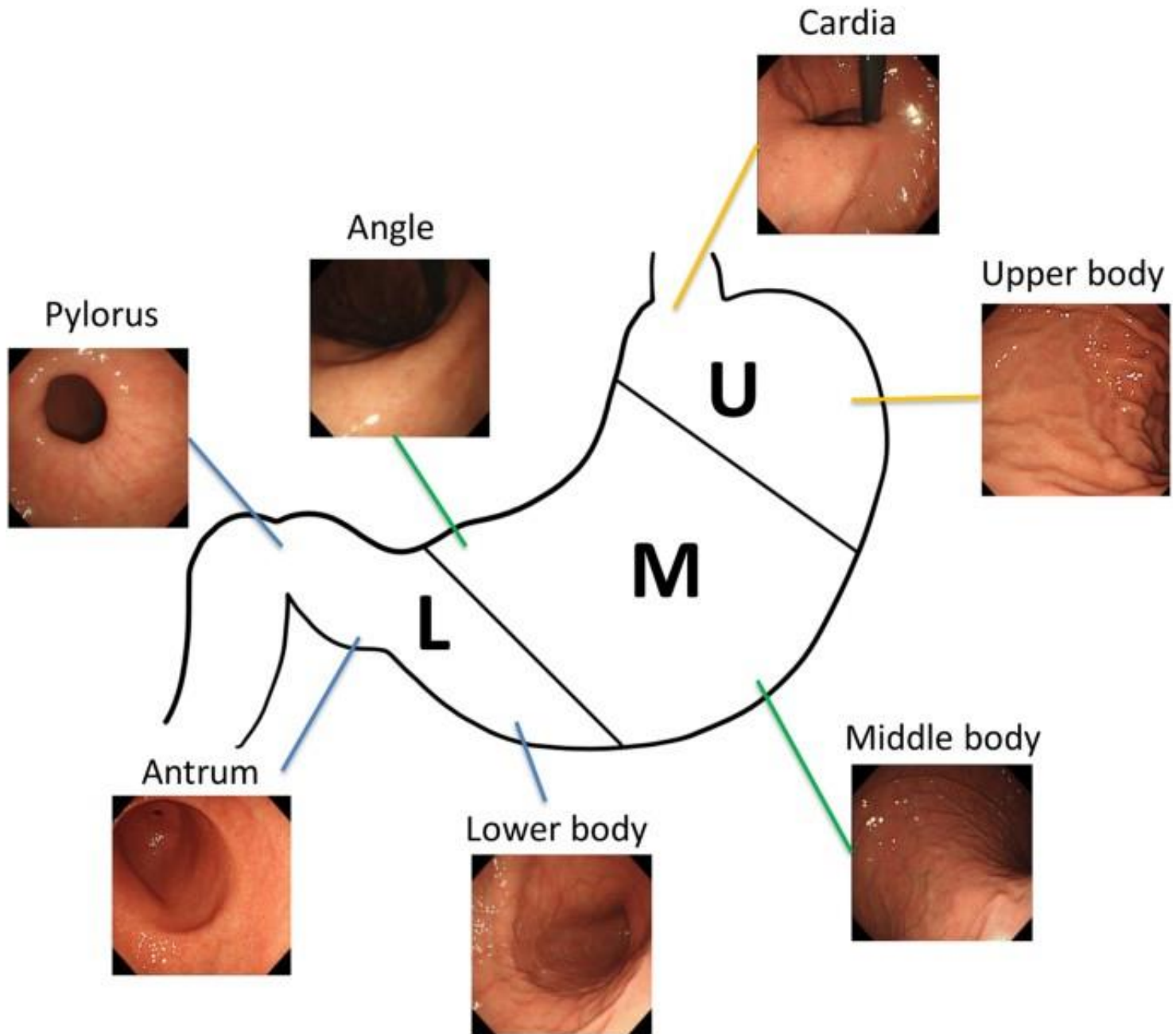
2. Middle third

3. Lower third

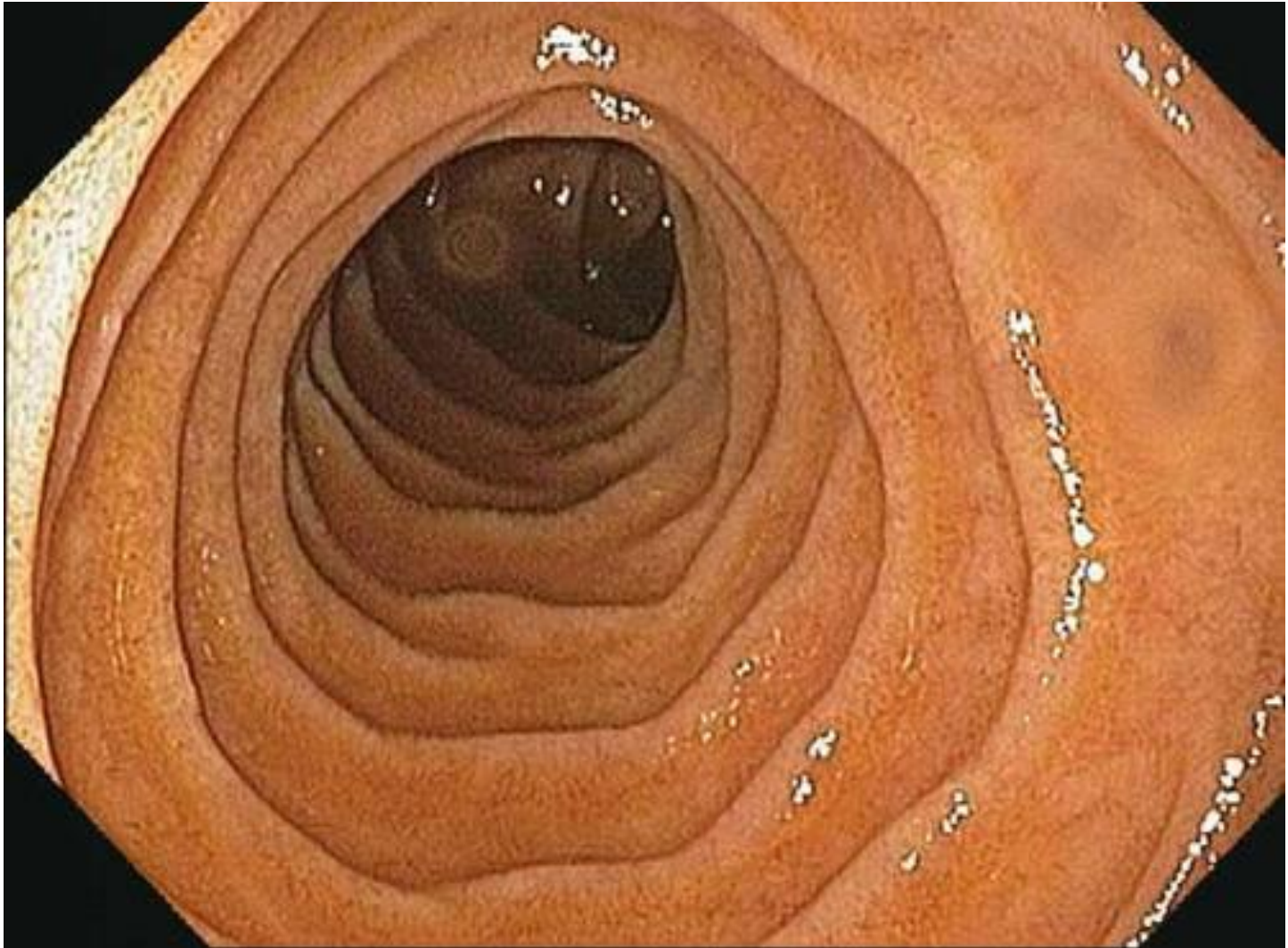
4. Esophagogastric junction



Stomach



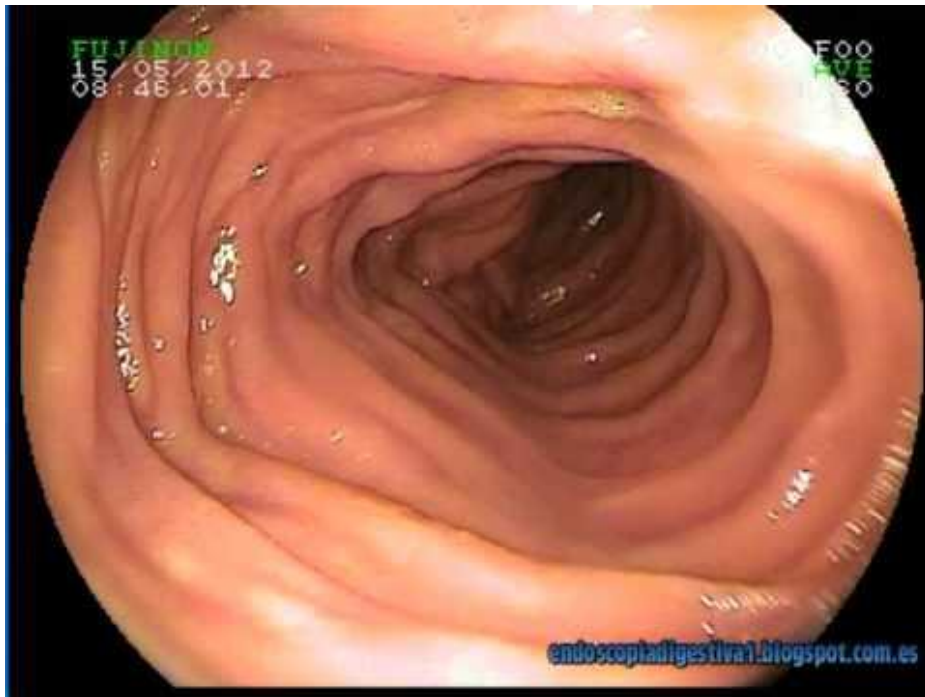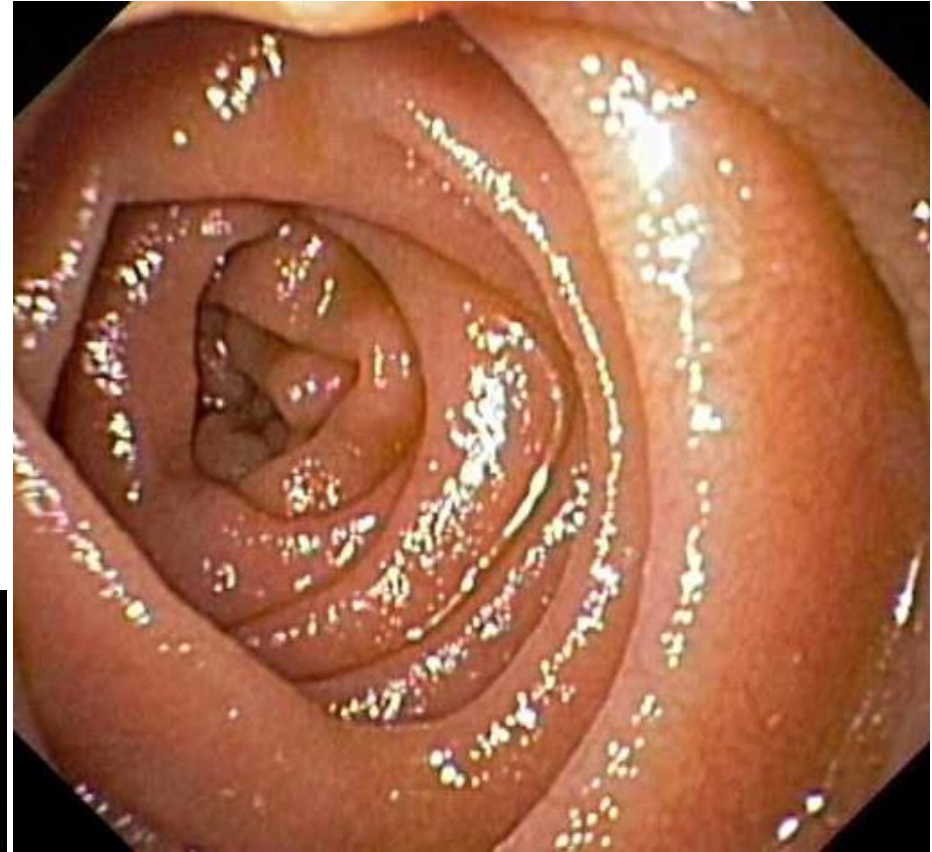
Duodenum



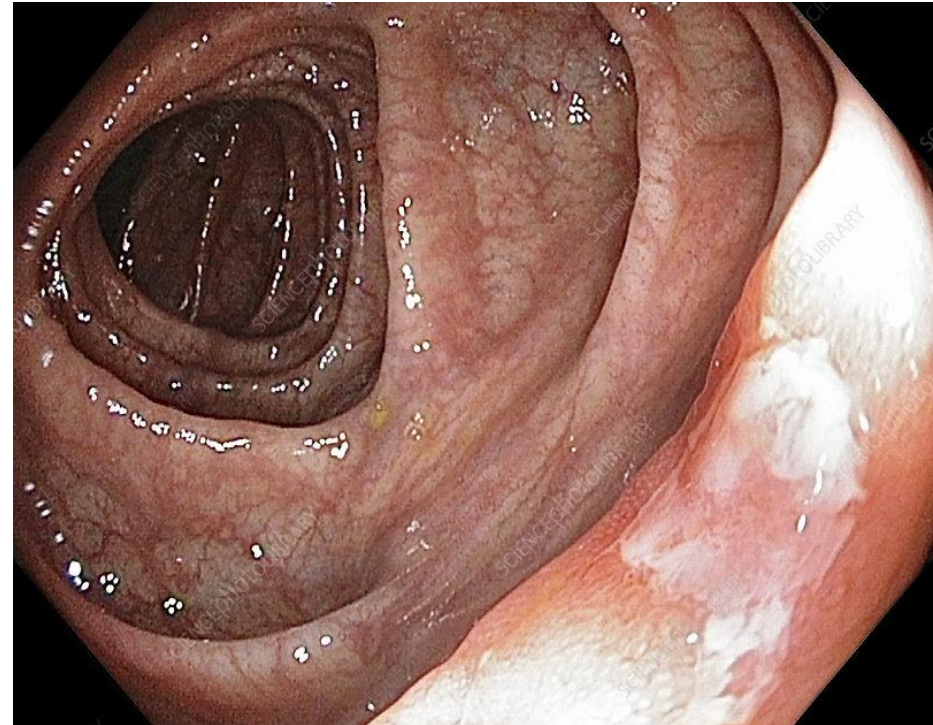
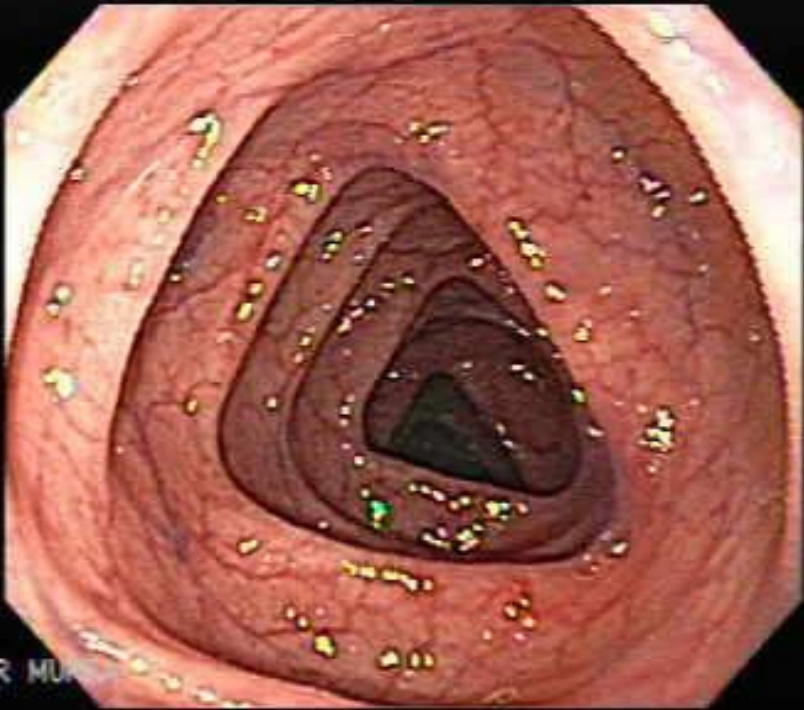
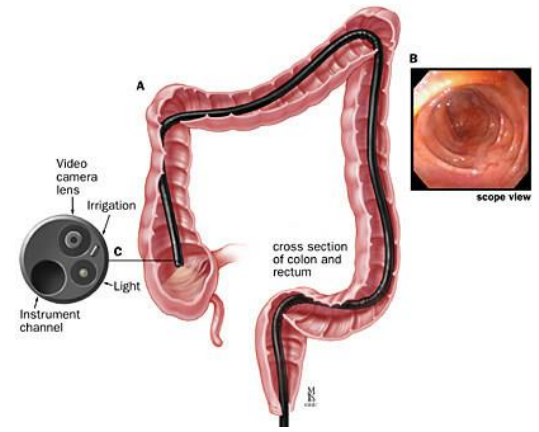
Small Intestine

Distal

Proximal



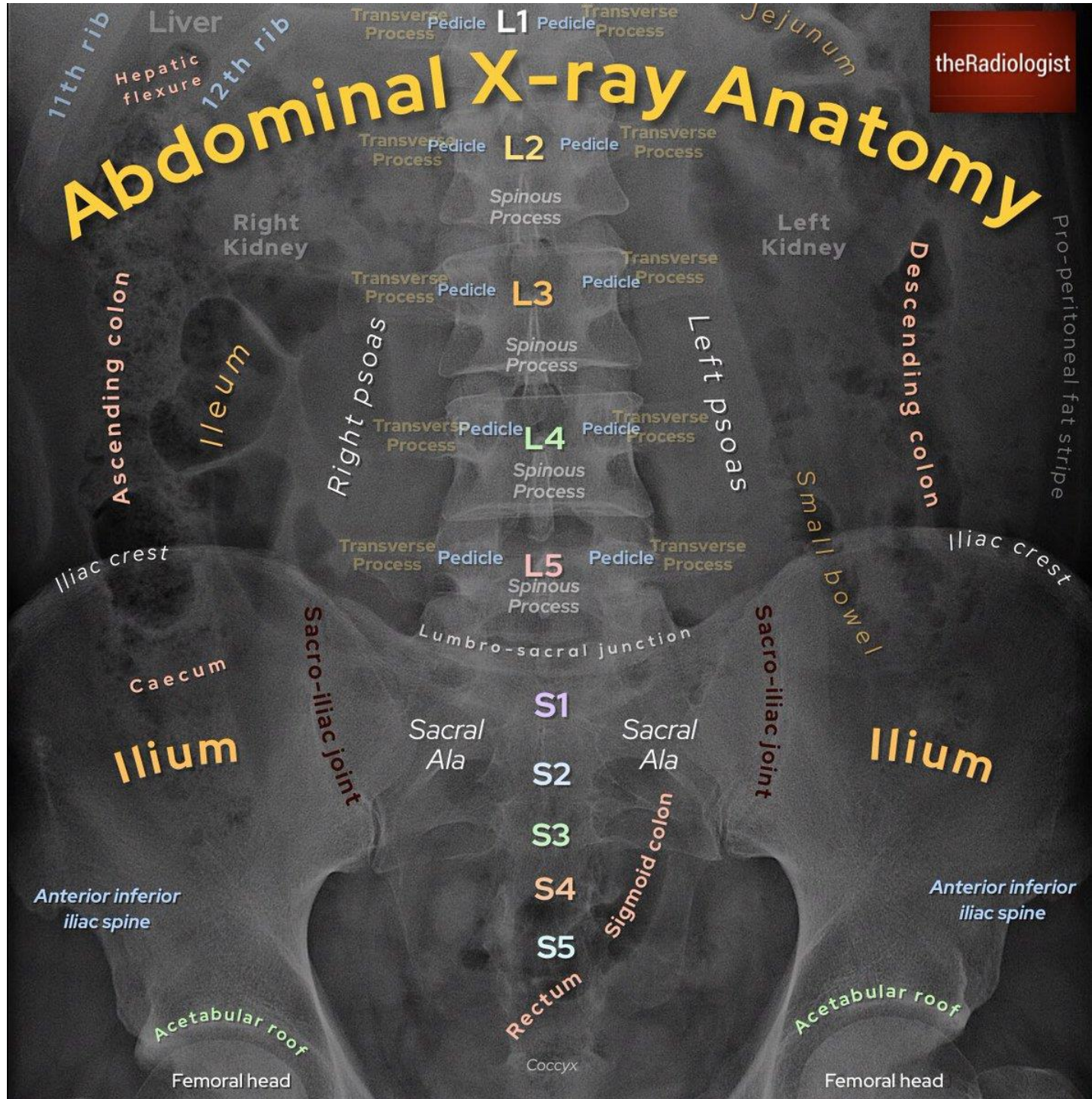
Colonoscopy



DR. MUHAMMAD

BASIC RADIOLOGY ANATOMY

Abdominal X-ray Anatomy



11th rib
Liver
Hepatic flexure
12th rib

Transverse Process
Pedicle L1
Pedicle
Transverse Process

Jejunum

Transverse Process
Pedicle L2
Pedicle
Transverse Process

Right Kidney

Spinous Process

Left Kidney

Ascending colon

Ileum

Right psoas

Transverse Process
Pedicle L3
Pedicle
Transverse Process

Spinous Process

Left psoas

Descending colon

Pro-peritoneal fat stripe

Iliac crest

Transverse Process
Pedicle L4
Pedicle
Transverse Process

Spinous Process

Small bowel

Iliac crest

Caecum

Sacro-iliac joint

Lumbro-sacral junction

Transverse Process
Pedicle L5
Pedicle
Transverse Process

Spinous Process

Sacro-iliac joint

Ilium

Sacral Ala

S1

Sacral Ala

Ilium

Anterior inferior iliac spine

S2

S3

S4

S5

Sigmoid colon

Anterior inferior iliac spine

Acetabular roof

Femoral head

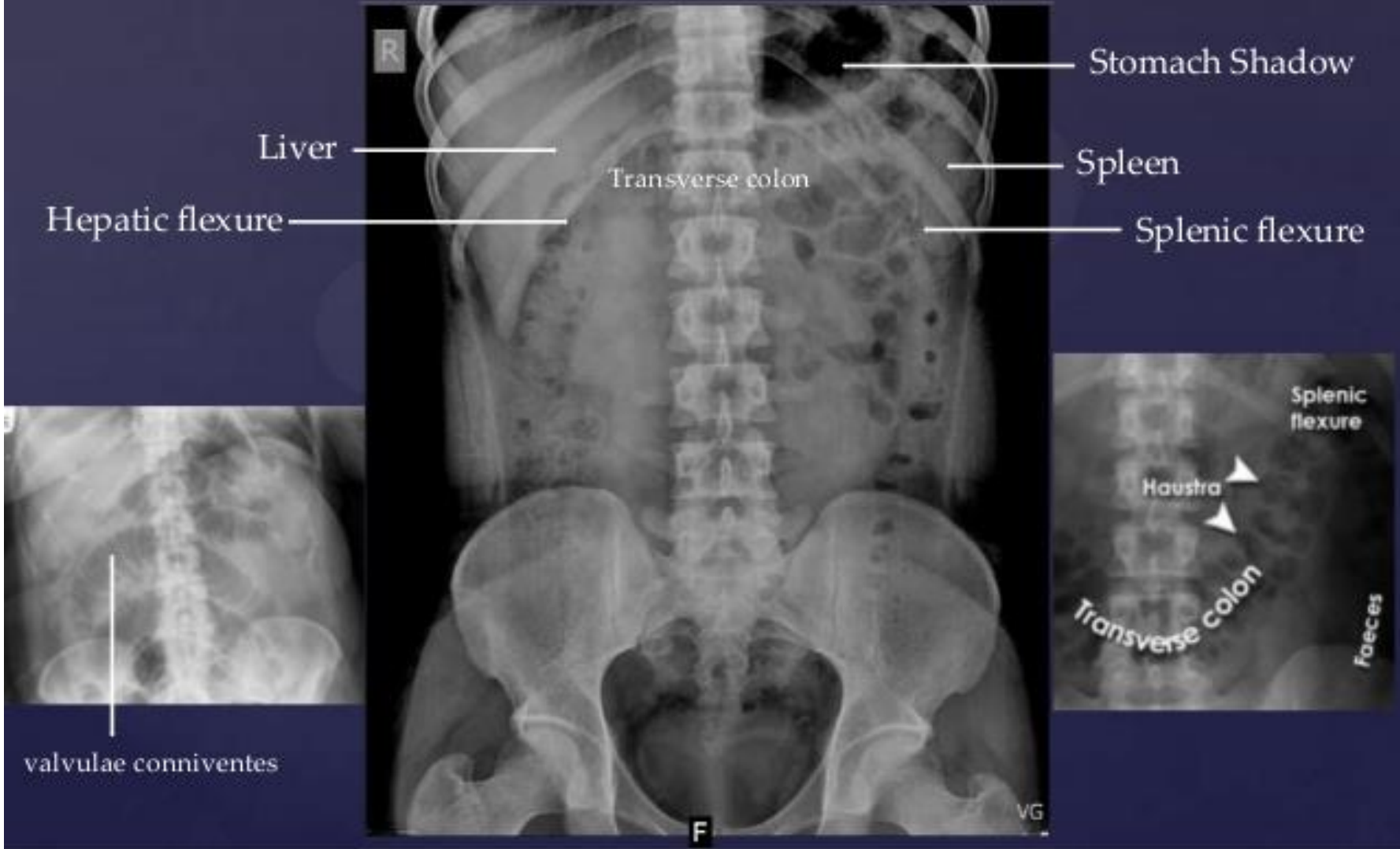
Coccyx

Acetabular roof

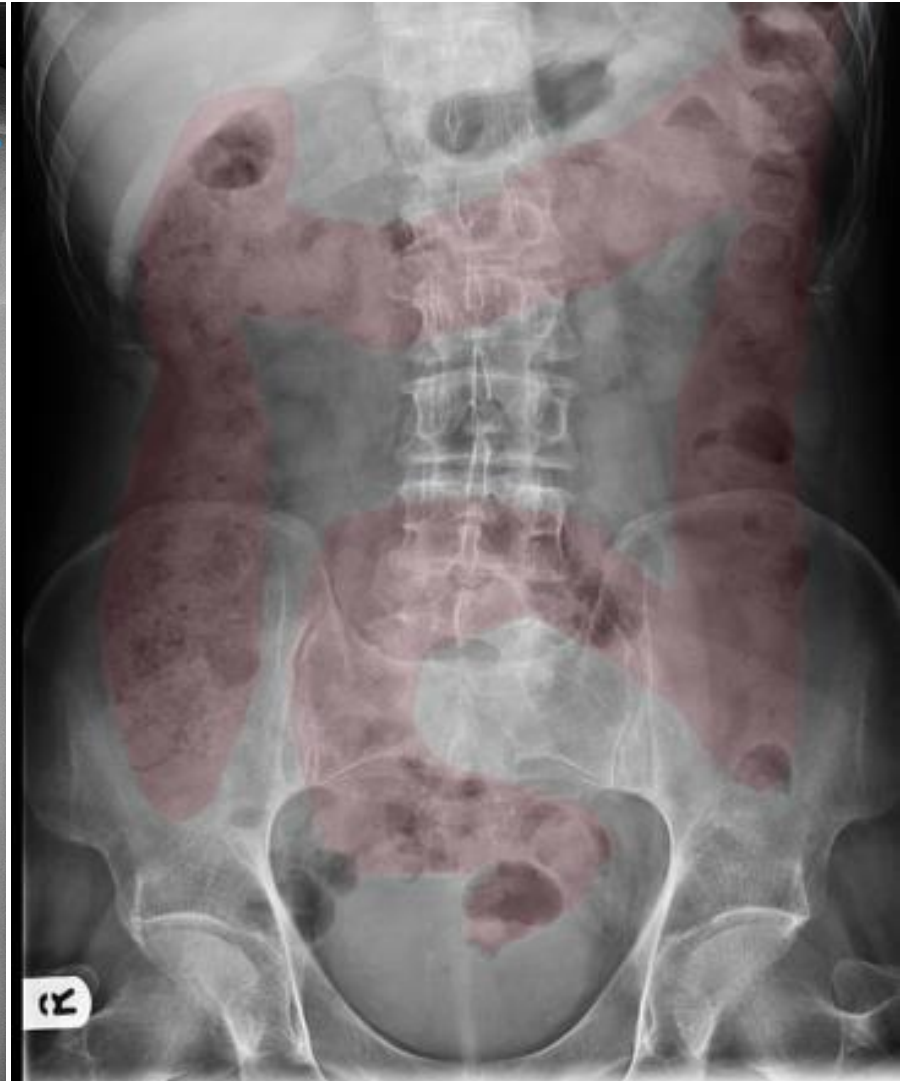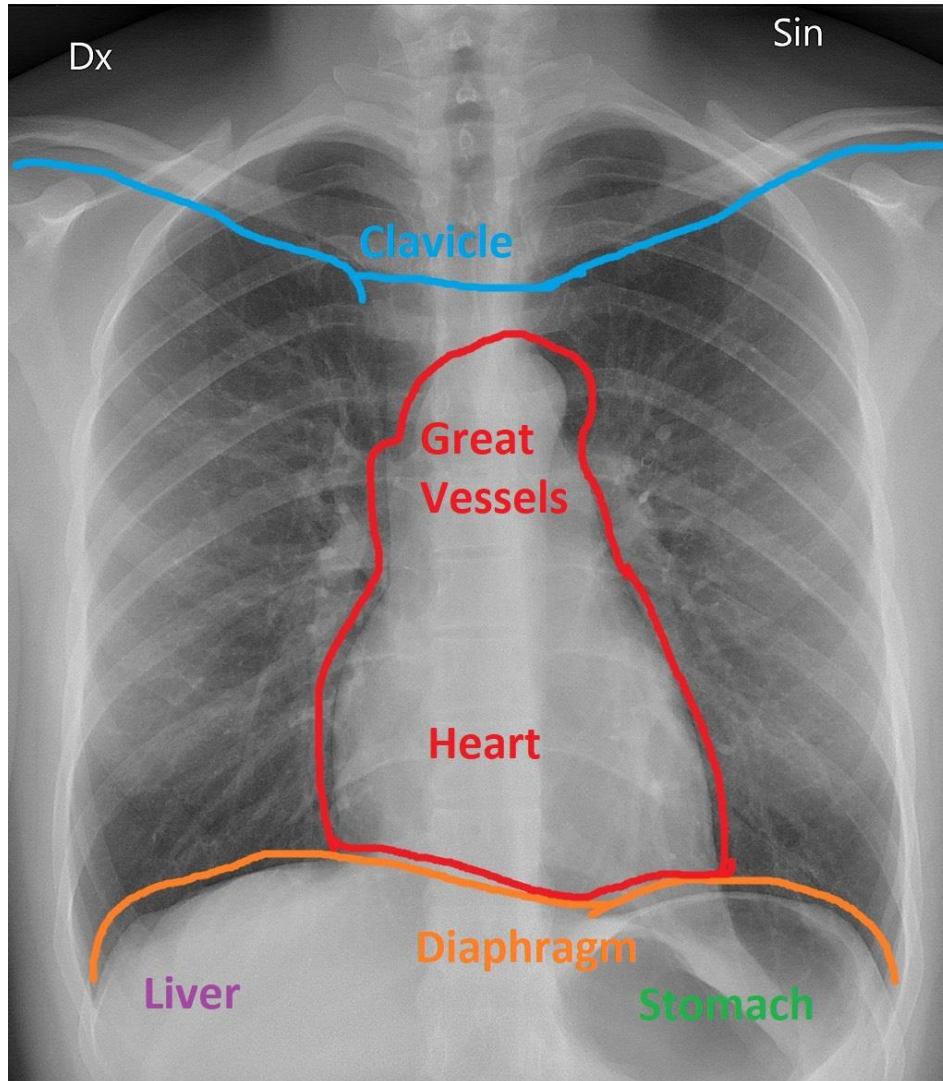
Femoral head

Rectum

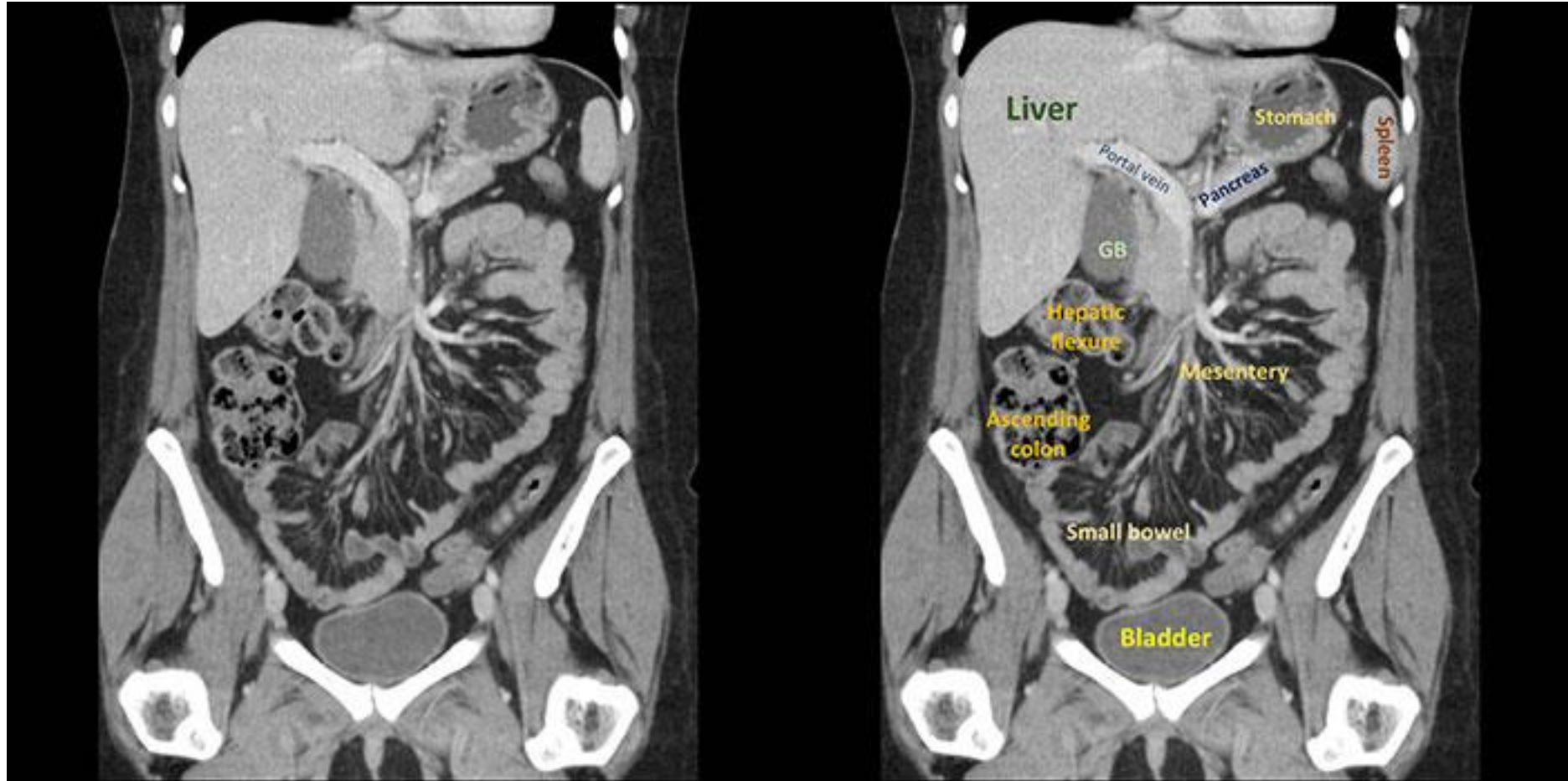
Anatomy on Abdominal X-Ray



Basic Radiology Anatomy



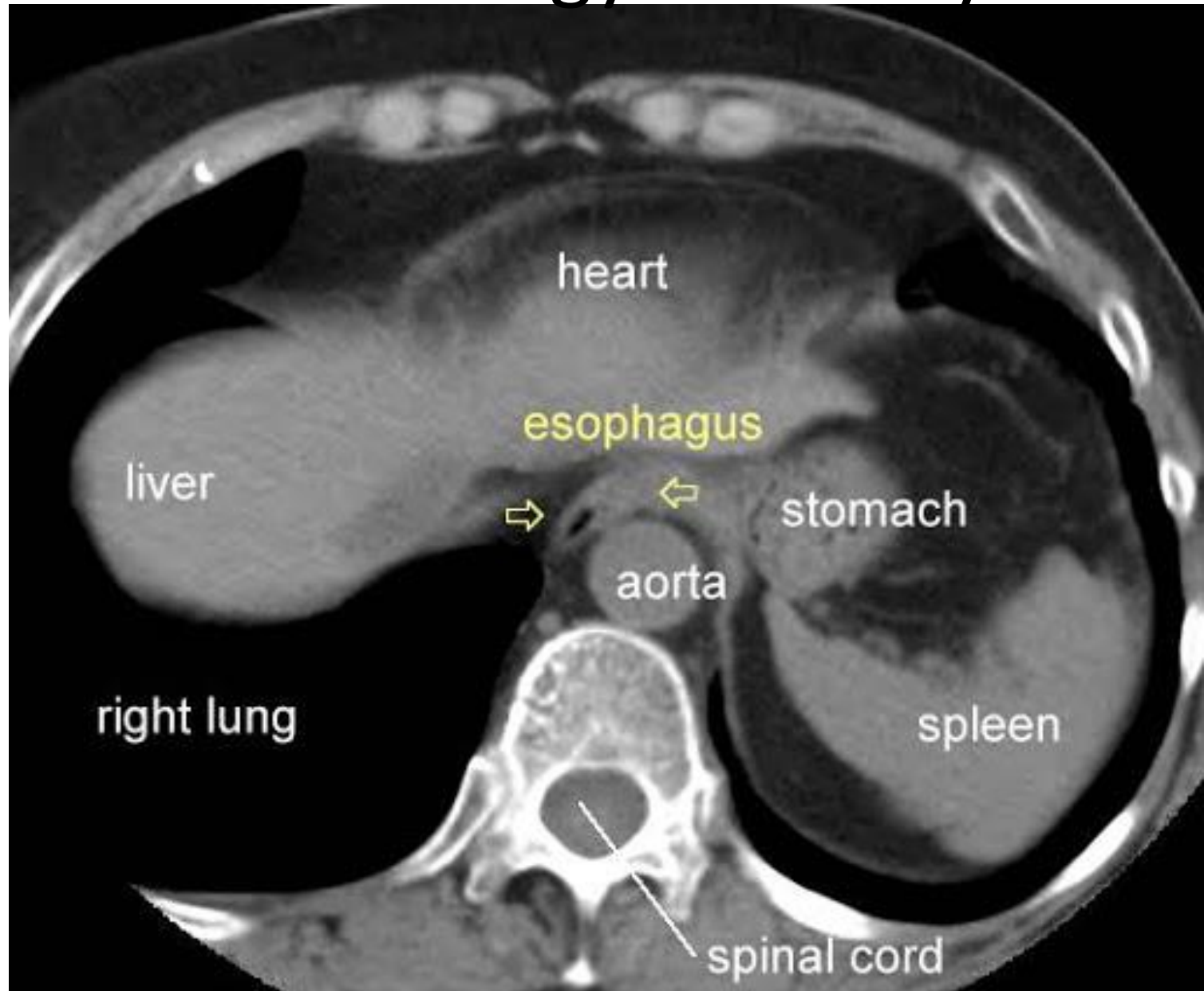
Basic Radiology Anatomy- Coronal CT



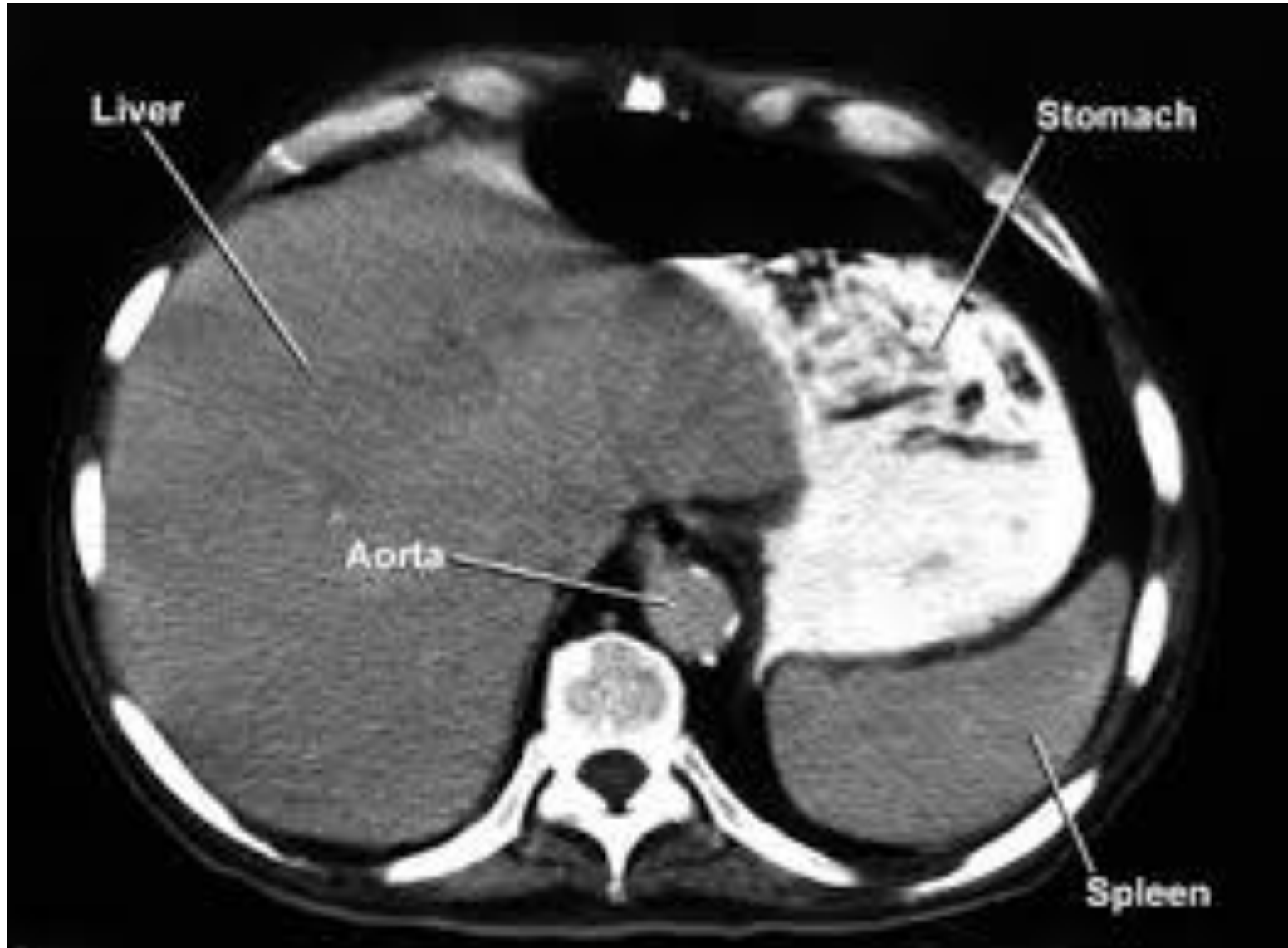
Basic Radiology Anatomy

- <https://www.radiologycafe.com/medical-students/radiology-basics/abdomen-anatomy>
- <https://www.startradiology.com/internships/internal-medicine/abdomen/ct-abdomen-general/index.html>

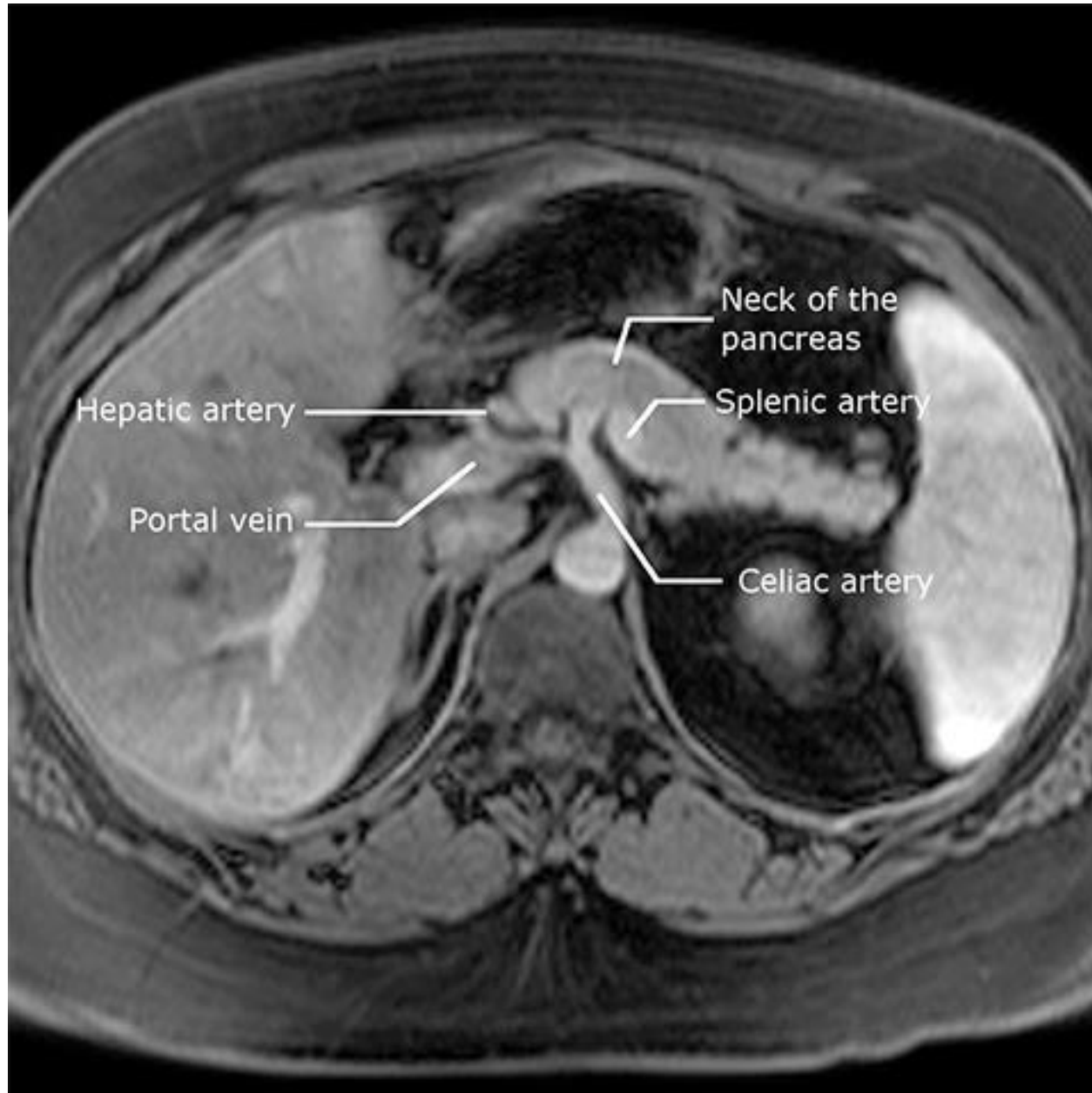
Basic Radiology Anatomy- CT



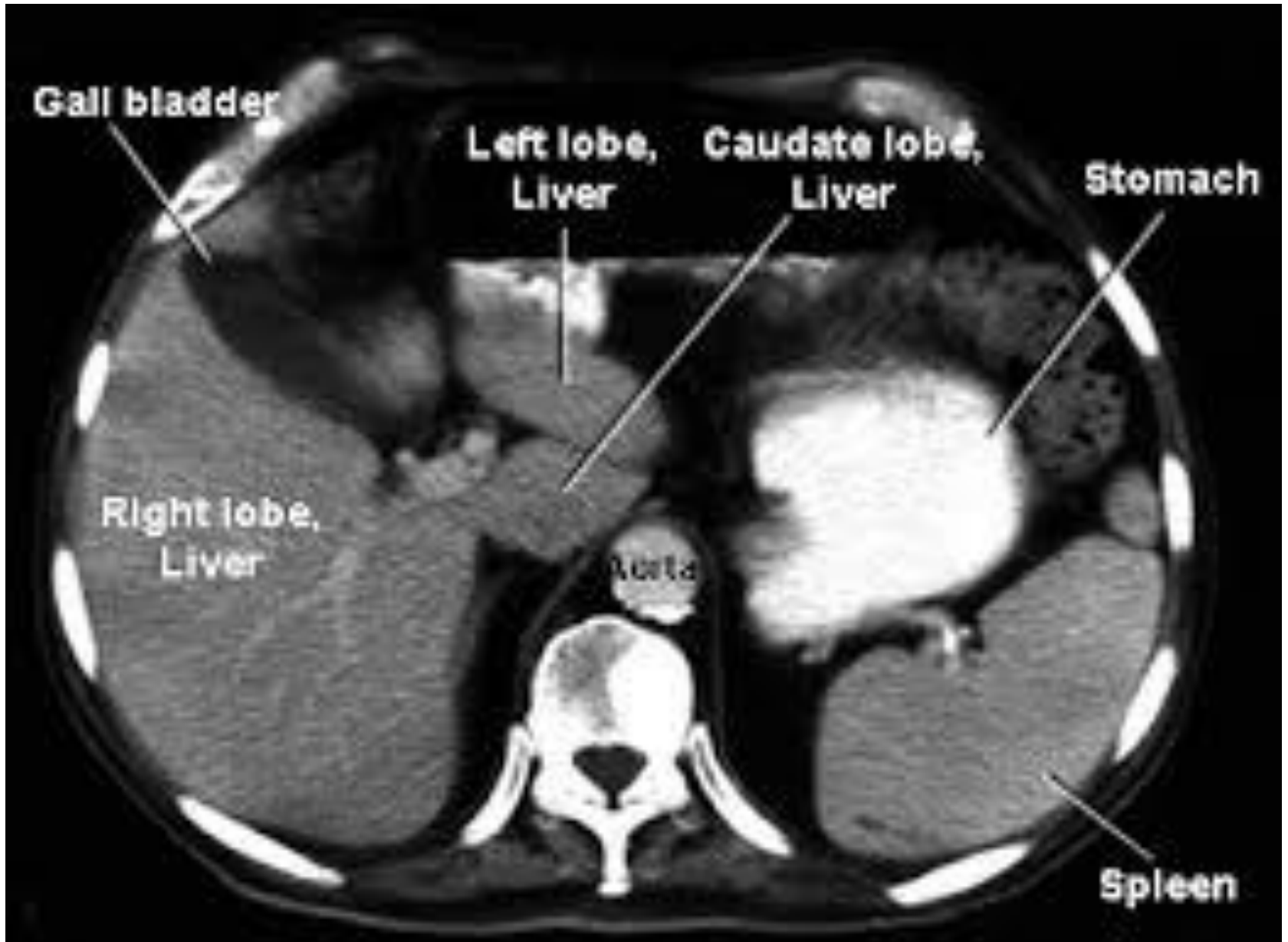
Basic Radiology Anatomy- CT



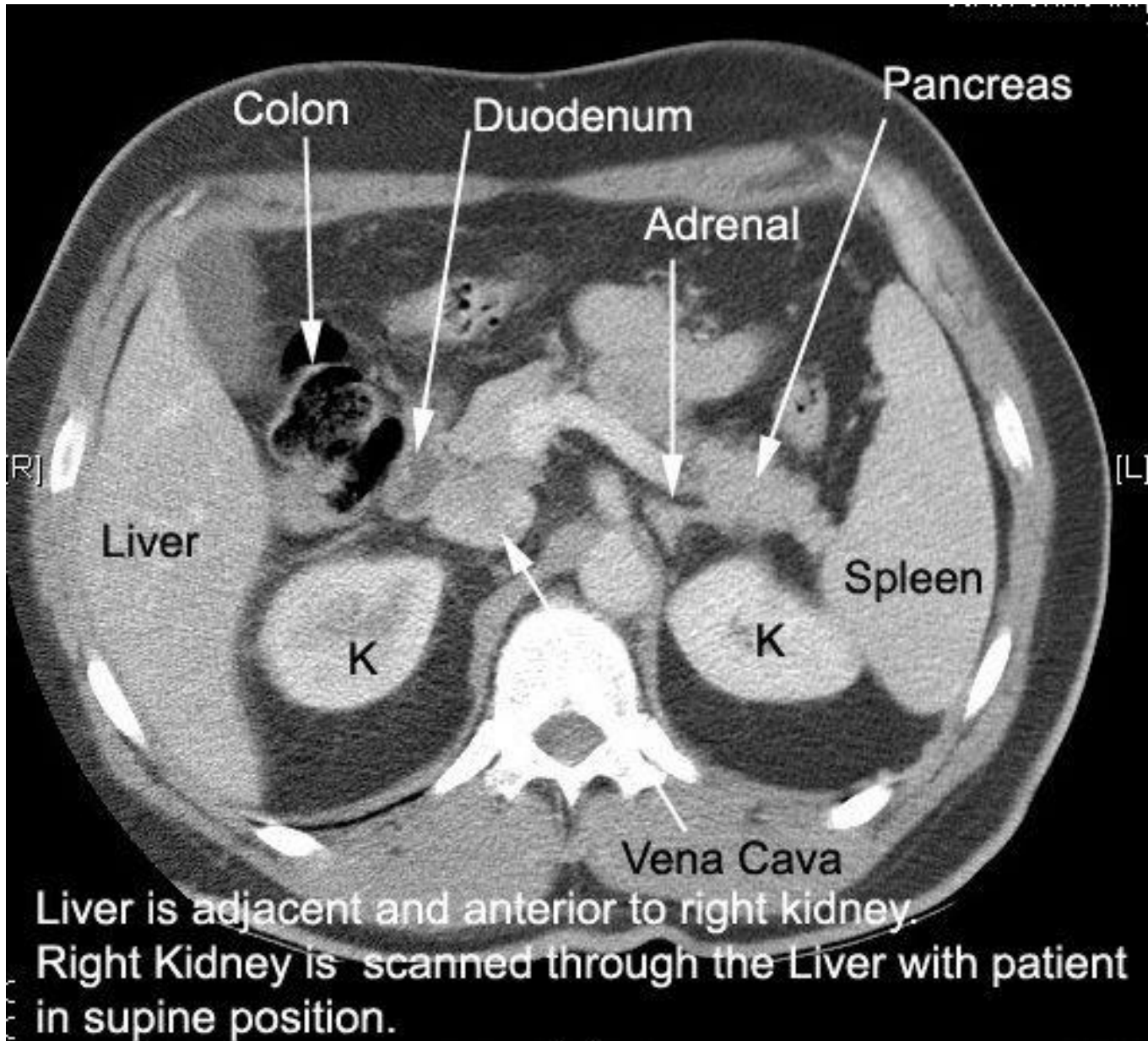
Basic Radiology Anatomy- CT



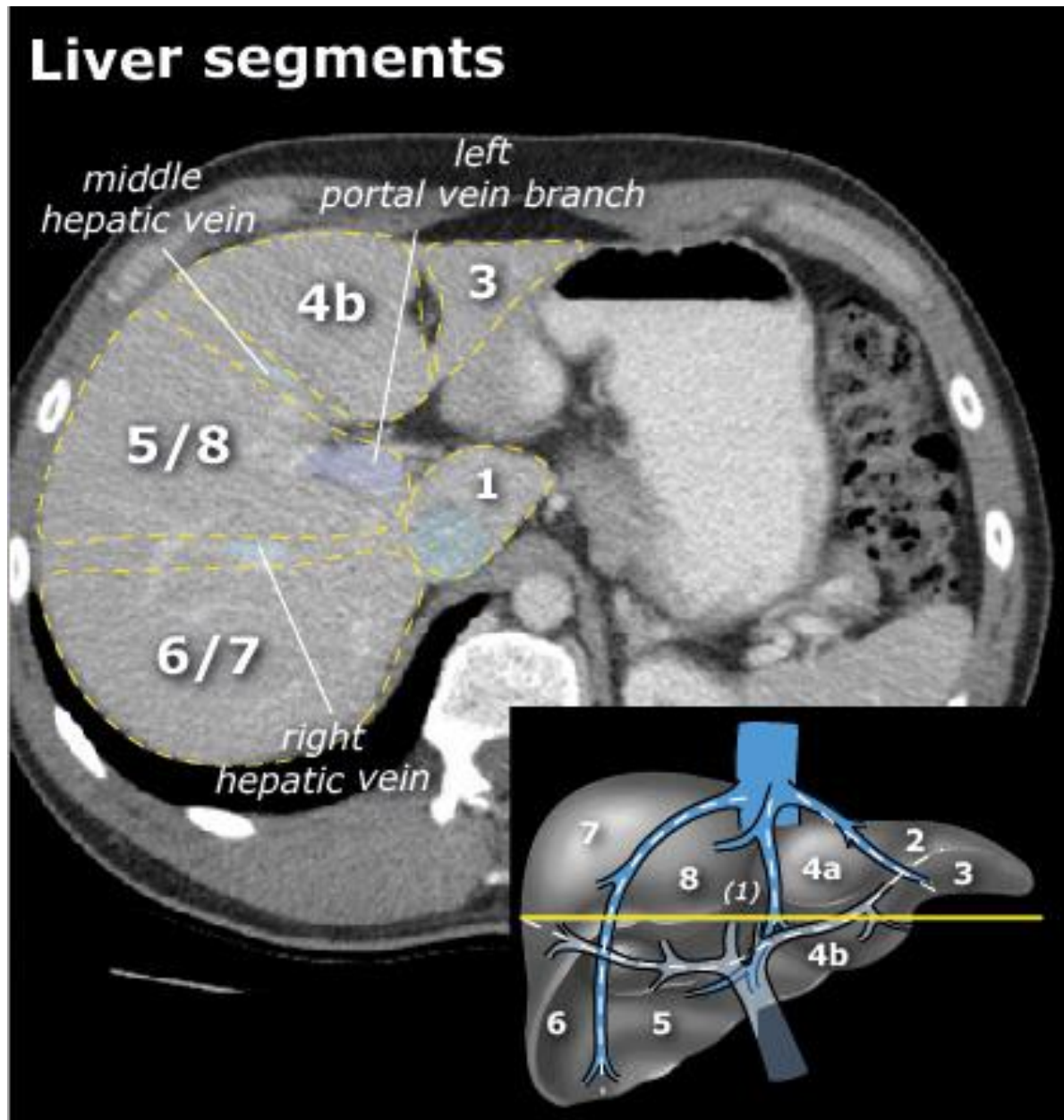
Basic Radiology Anatomy- CT



Basic Radiology Anatomy- CT

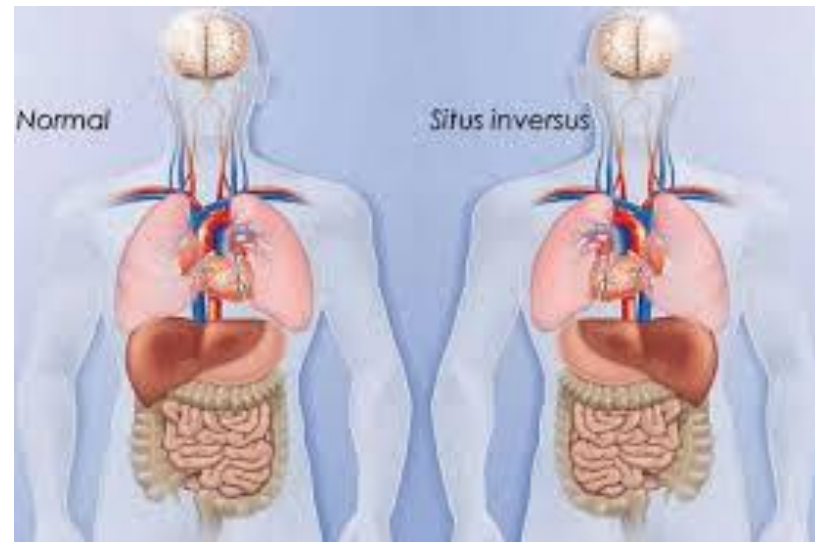


Basic Radiology Anatomy- CT

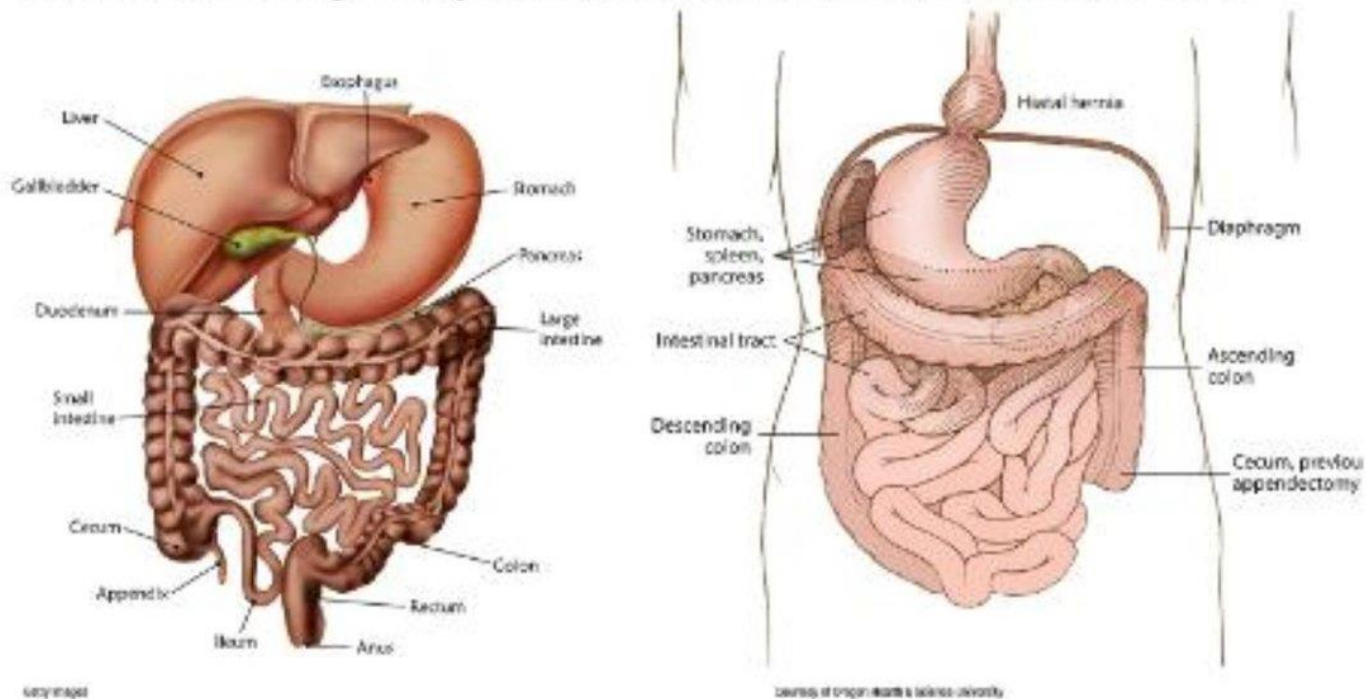


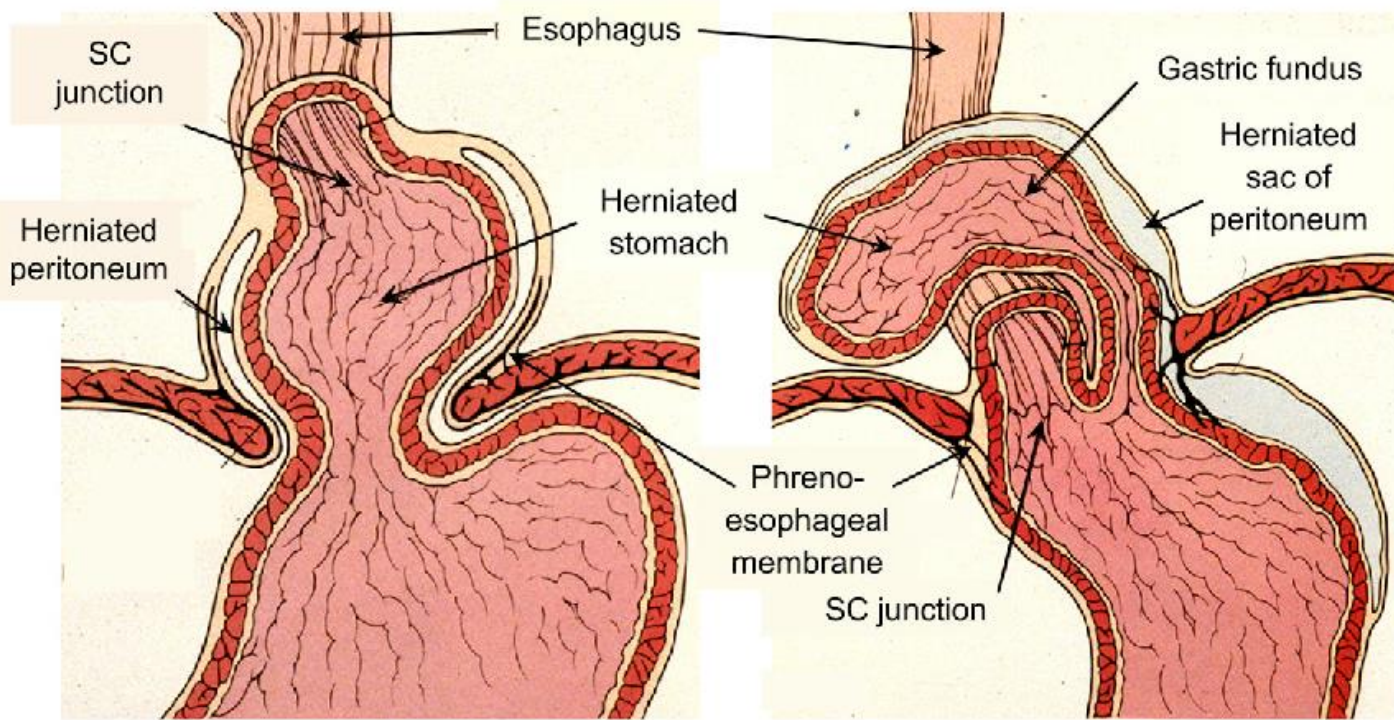
Basic Clinical Anatomy Conditions

Situs Inversus

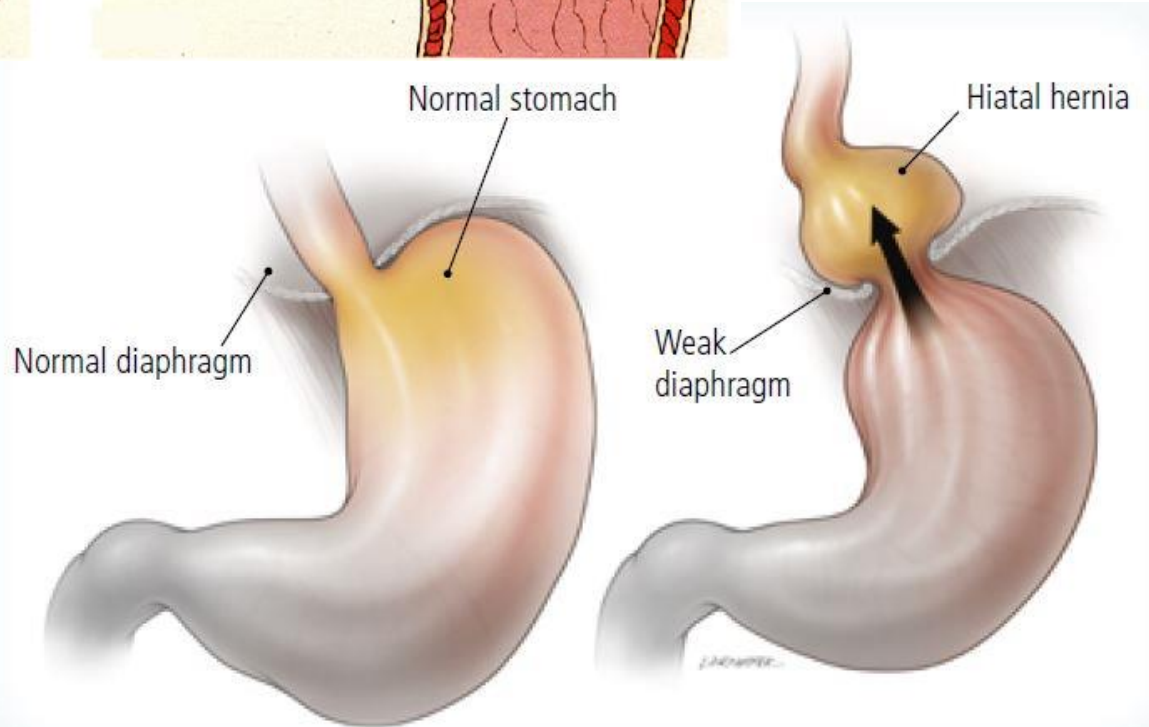


Normal anatomy compared to situs inversus with levocardia

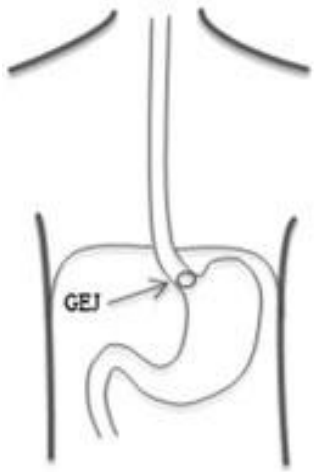




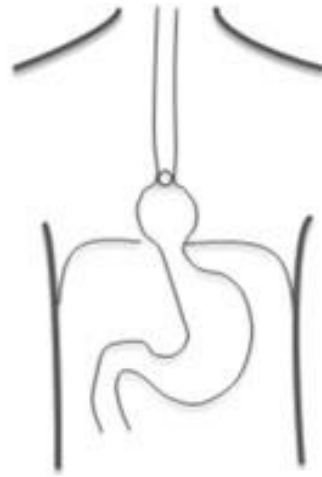Esophageal Herniae



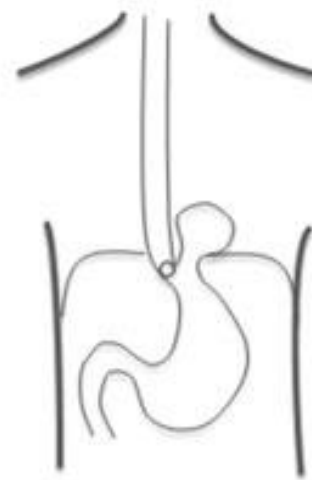Basic Types of Esophageal Herniae



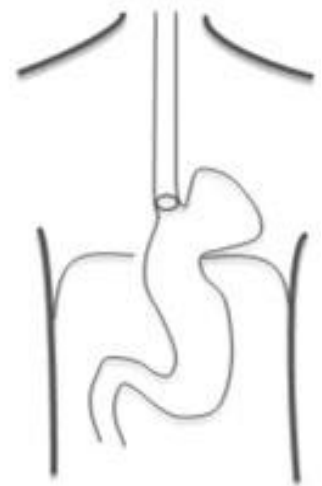Normal
esophagus
and stomach



Hiatal Hernia
Type I
(*“sliding”*)

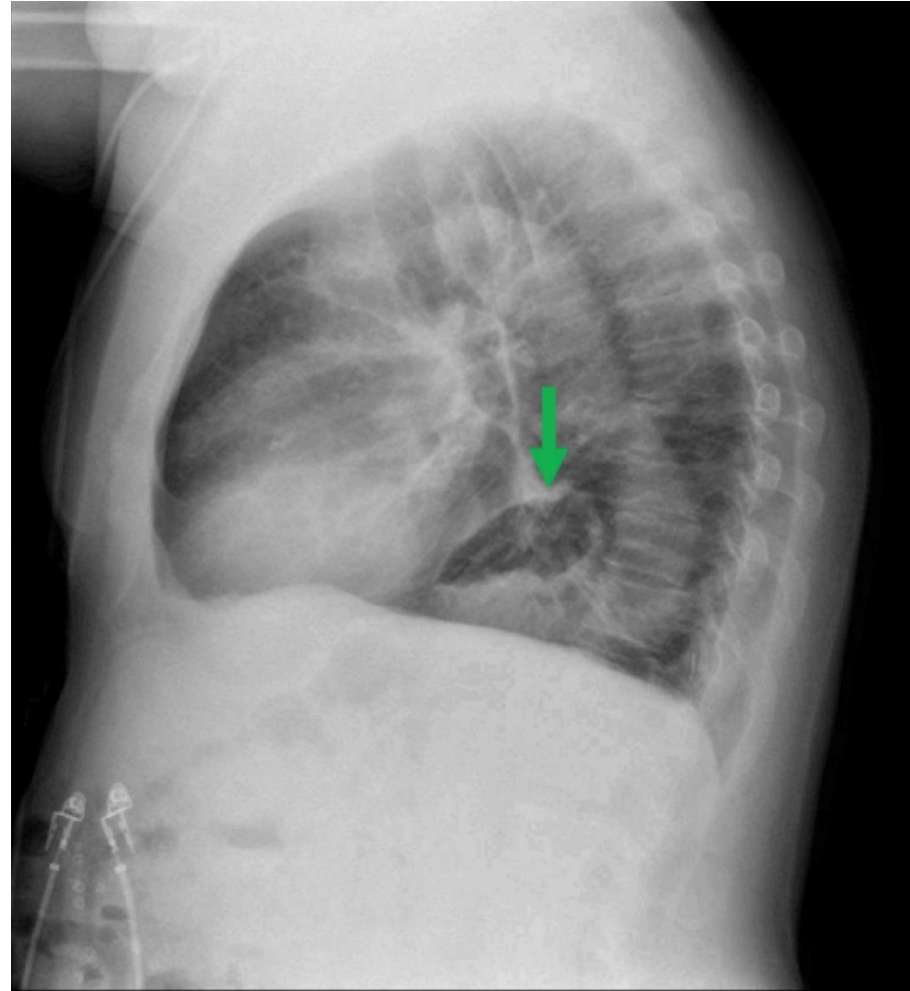
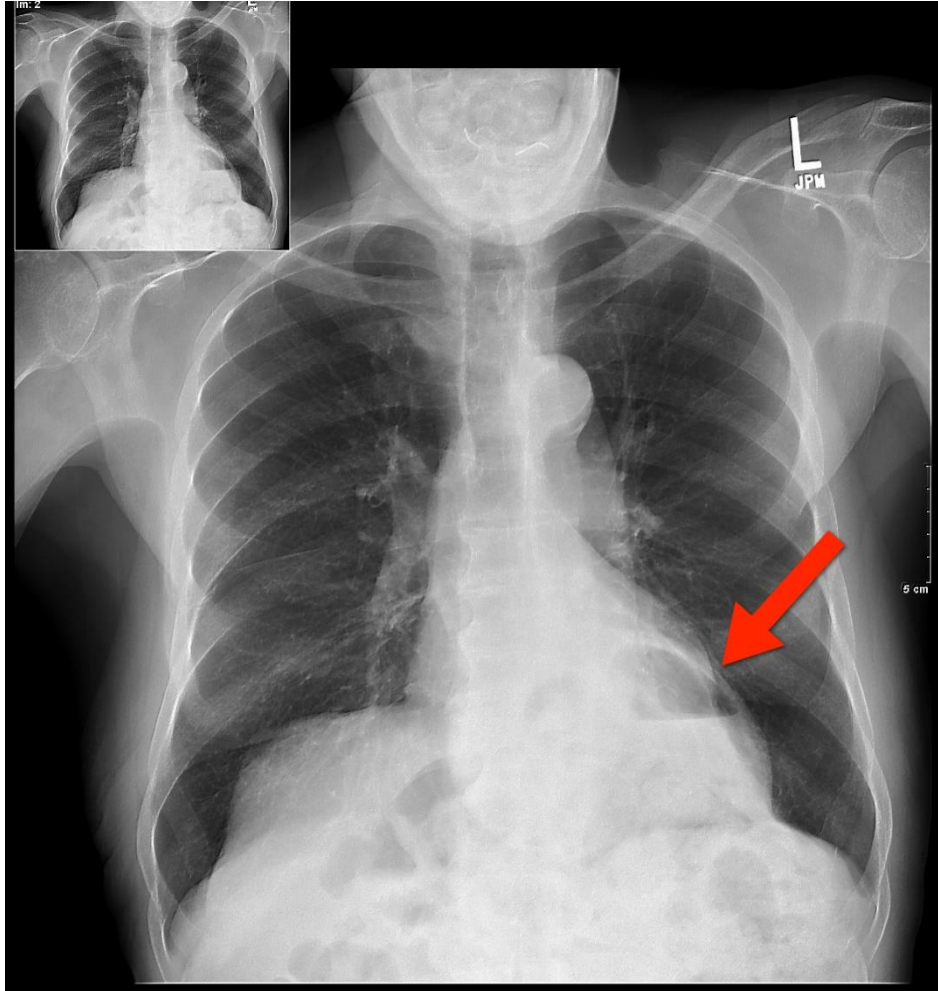


Hiatal Hernia
Type 2
(*“rolling”*)

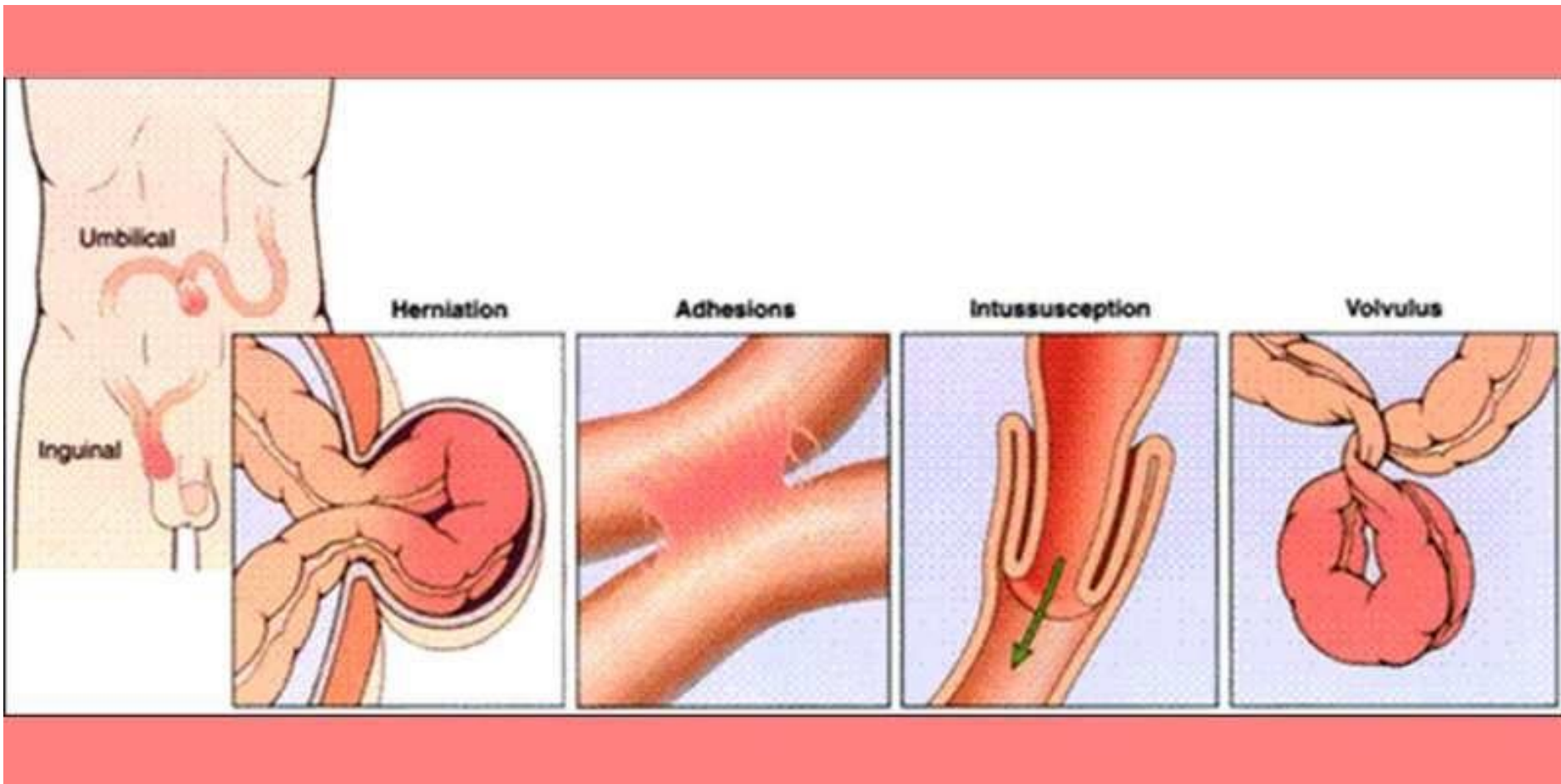


Hiatal Hernia
Type 3
(*“mixed”*)

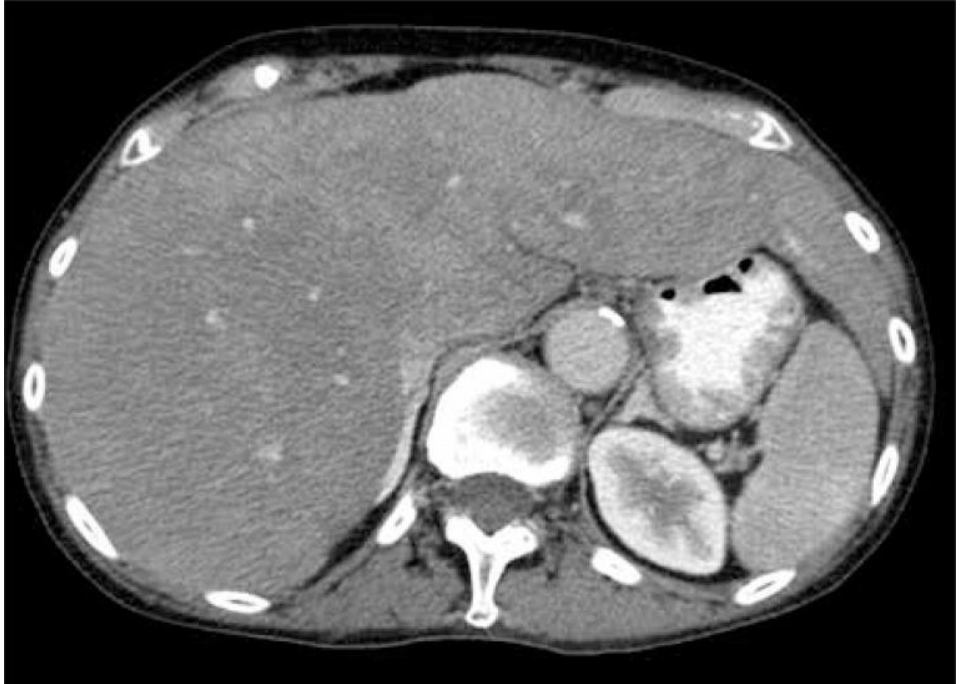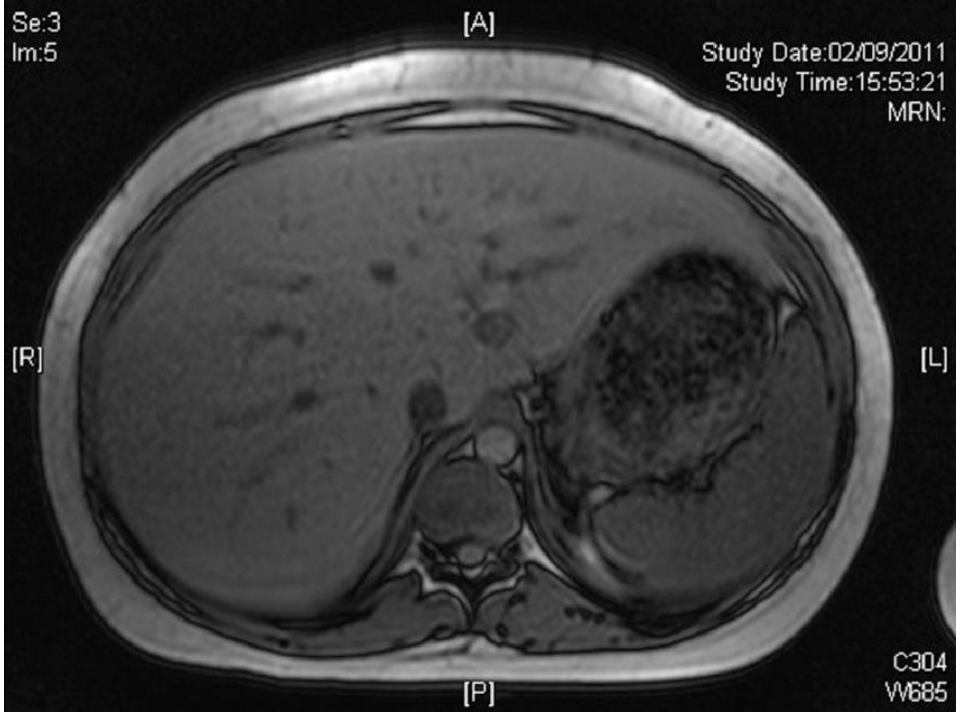
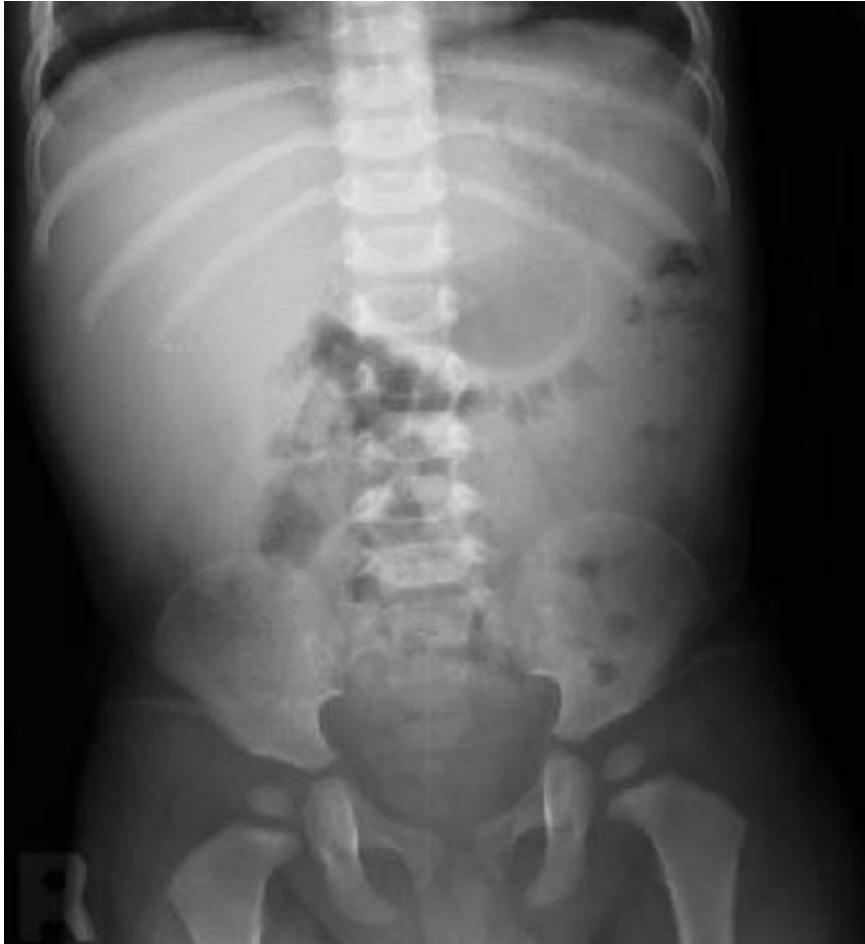Esophageal Herniae – X-Ray



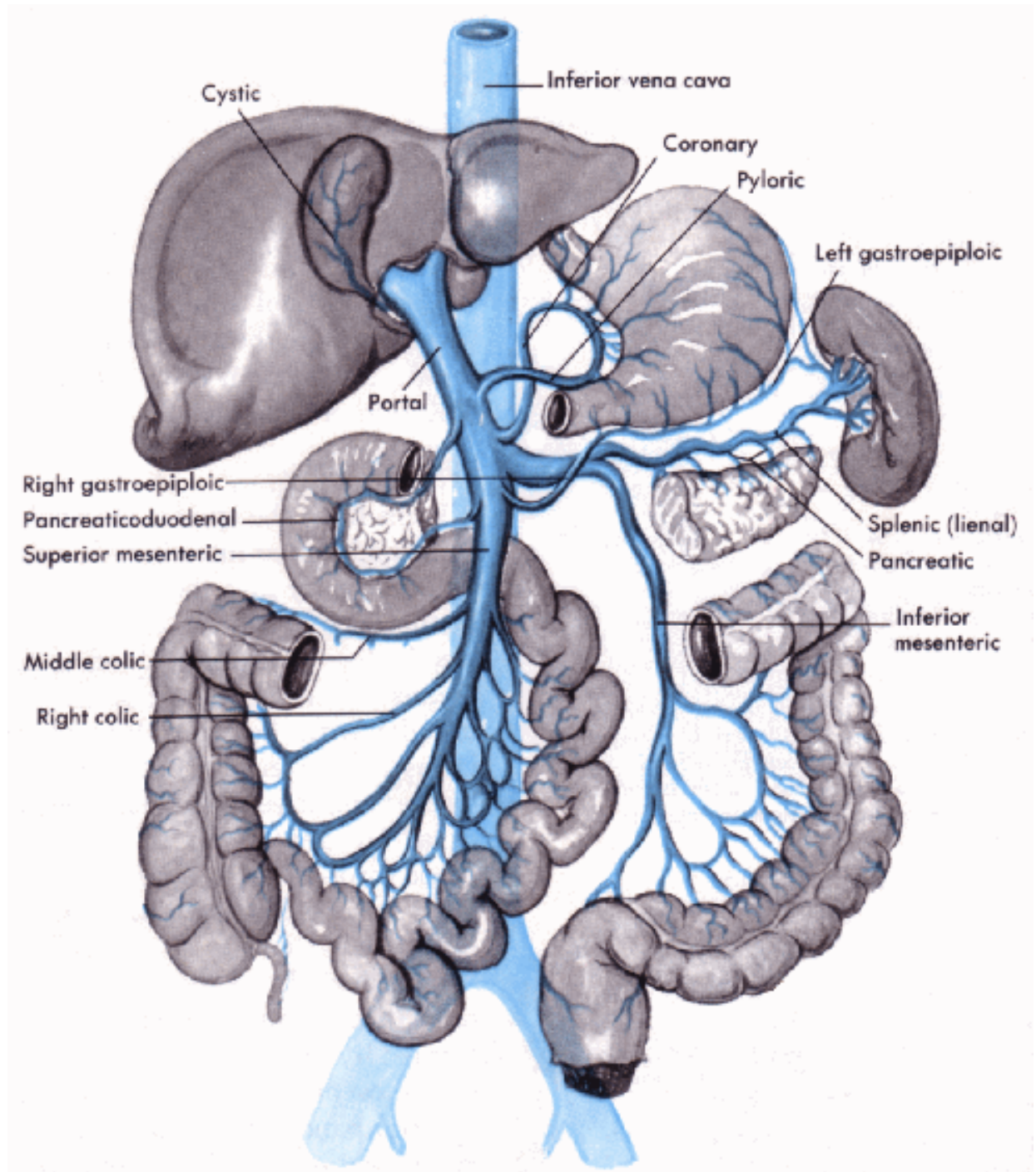
Intestinal Obstruction



Hepatomegaly



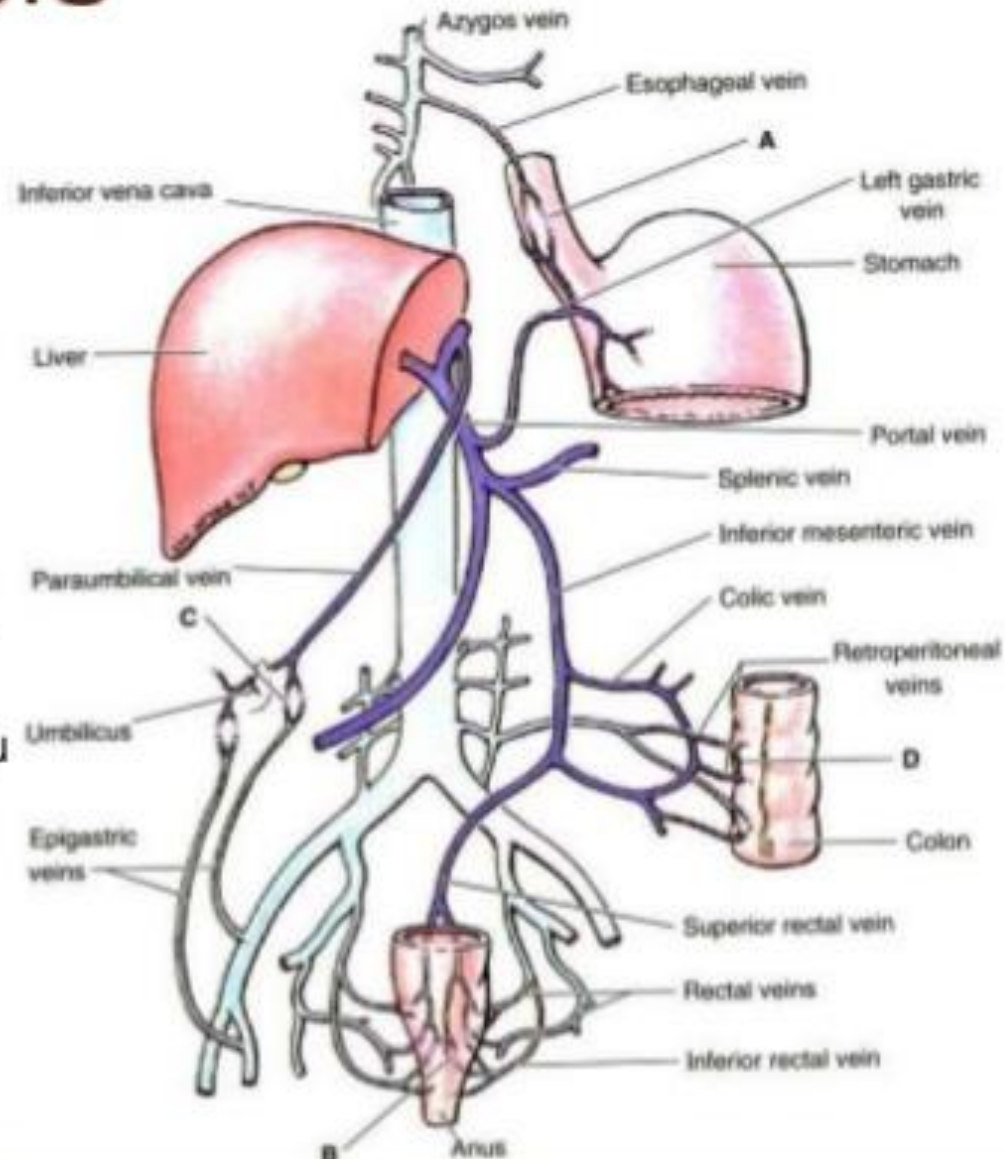
Portal Vein Tributaries



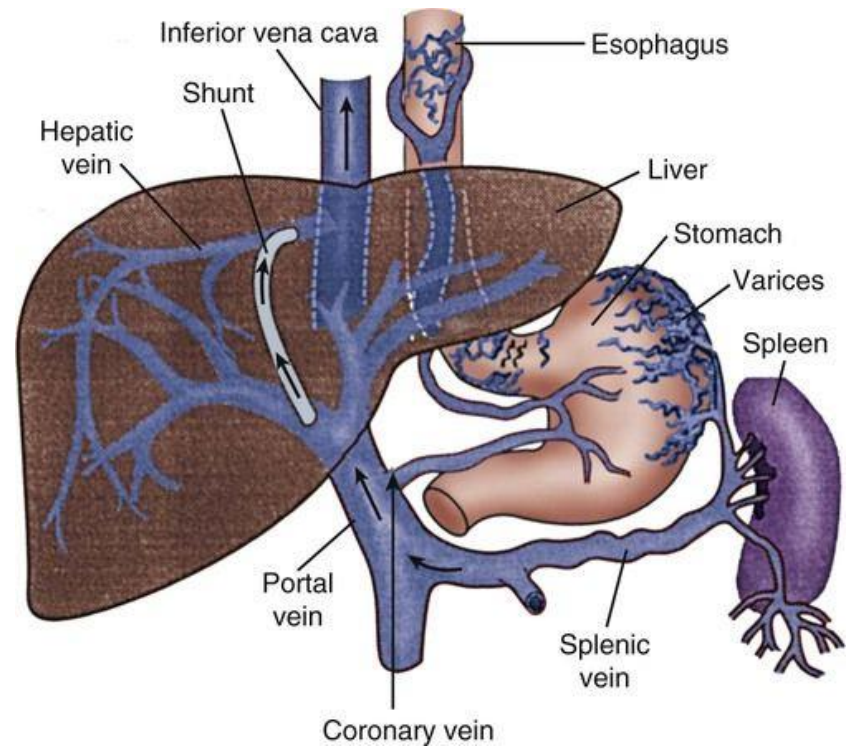
SITES OF PORTACAVAL ANASTOMOSIS

Five sites of portal/systemic circulation :

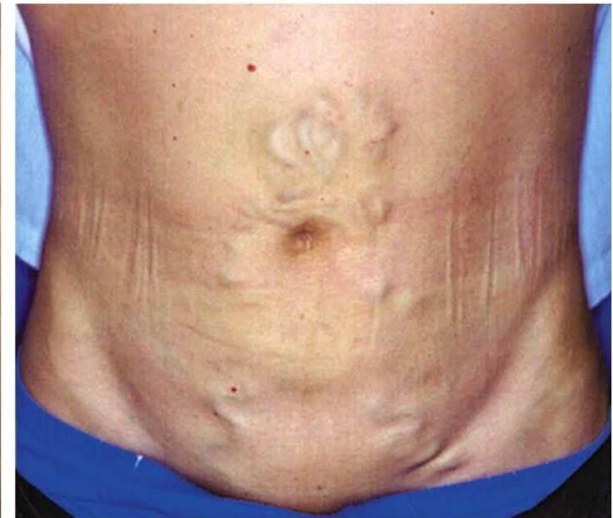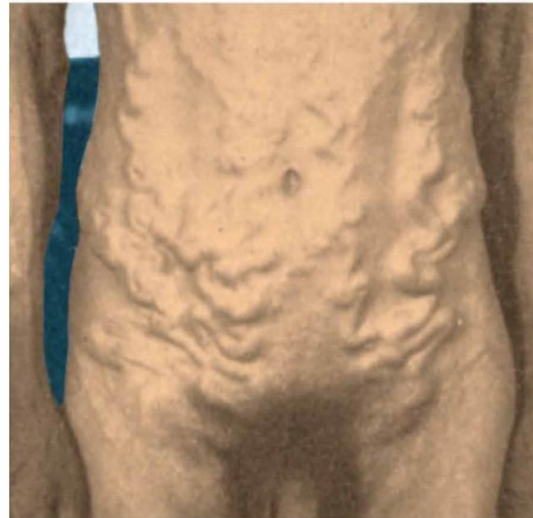
1. Lower third of the Esophagu
2. Paraumbilical Area
3. Upper end of Anal canal
4. Retroperitoneal
5. Bare area of liver



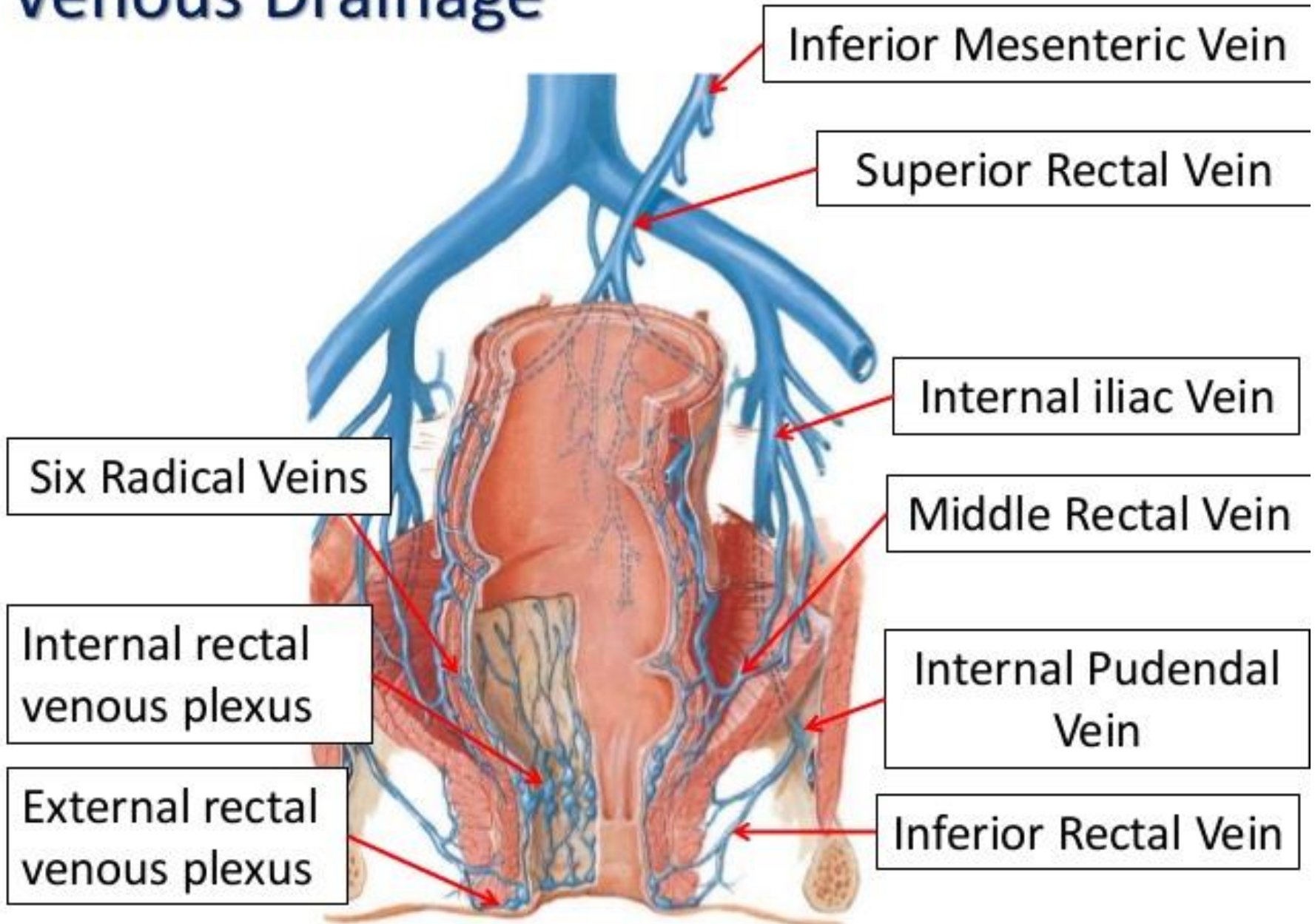
Portal Vein Hypertension



Caput medusae



Venous Drainage



Hemorrhoids

