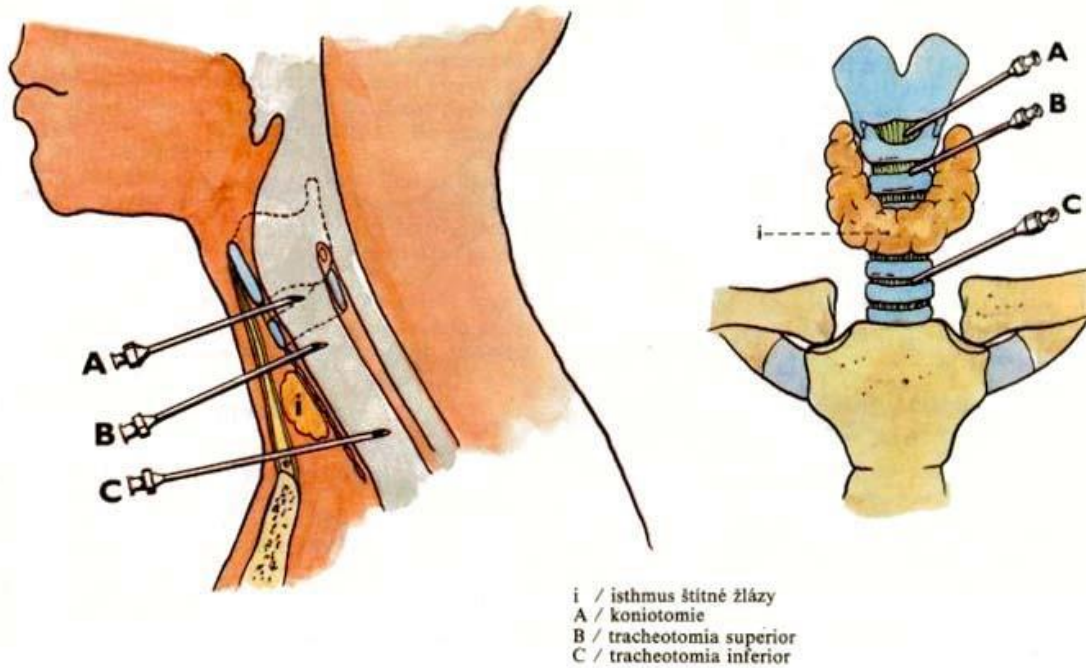


CONIOTOMY and TRACHEOTOMY



Layers of incision

Coniotomy	Tracheotomy
Emergency quick intervention by transverse section between cartilago thyroidea et cricoidea through lig. cricothyroideum medianum which is 14 x 12 mm	Superior tracheostomy: sagittal incision for cannulation through several cartilages of the trachea.
<ul style="list-style-type: none"> • skin + subcutaneous tissue (longitudinal section) • lamina superficialis fasciae cervicalis • lamina pretrachealis fasciae cervicalis • lig. cricothyroideum medianum + mucosa (transverse section) • Precaution (SAVE)- rr. cricothyroidei a. laryngeae superioris just below the cartilago thyroidea. • Precaution- Lobus pyramidalis glandulae thyroideae (40%) 	<ul style="list-style-type: none"> • skin + subcutaneous tissue • lamina superficialis fasciae cervicalis • venous arcus venosus jugularis (lower part only) • lamina pretrachealis fasciae cervicalis + intersection of the raphe of mm. sternohyoids (in lower coniotomy) • venous plexus thyroideus impar (only in the lower tracheotomy) • tracheal cartilage + ligg. anularia + mucosa (only in the lower tracheotomy)

