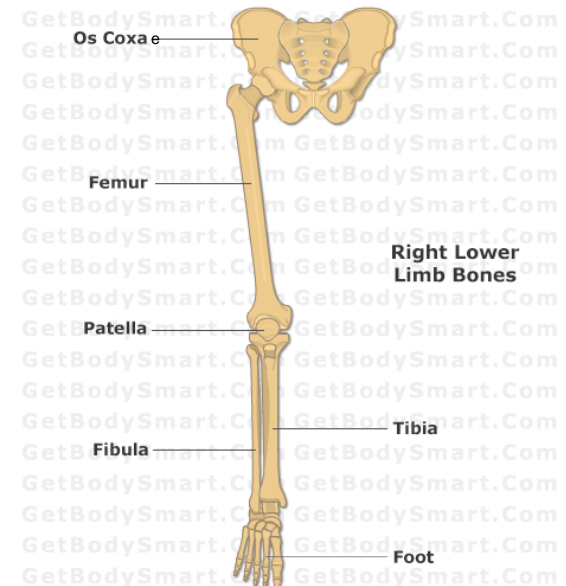
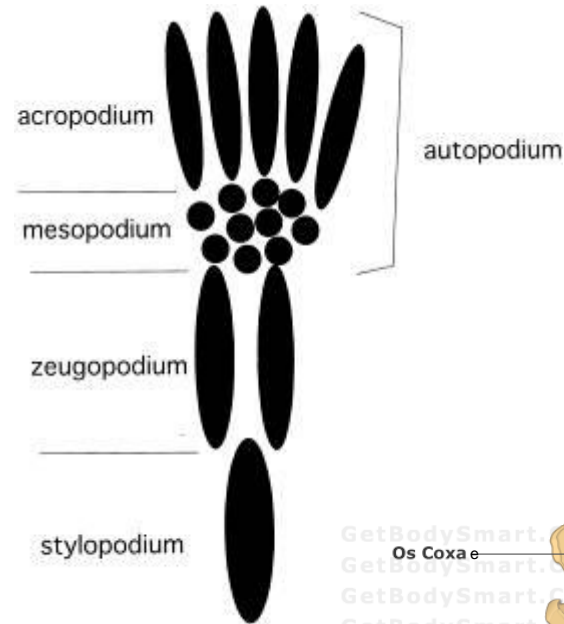


Bones of the Lower Extremities

David Kachlík

Dolní končetina

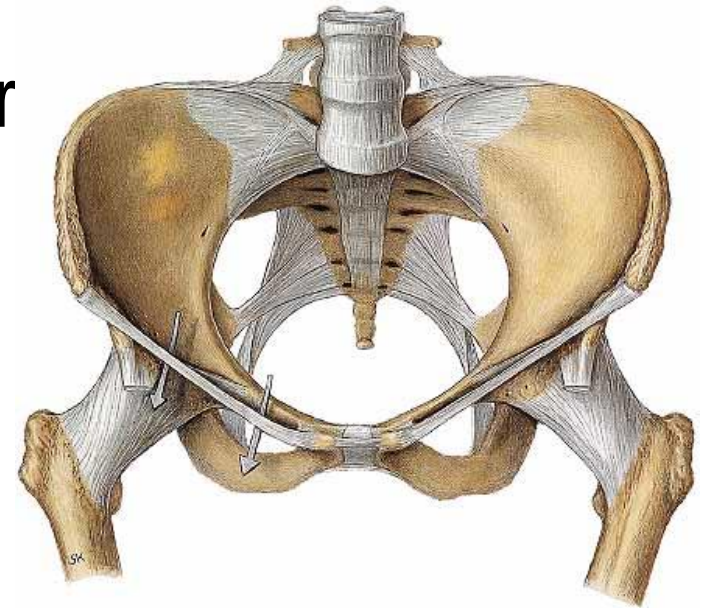
- girdle = *cingulum*
 - pelvis = *pelvis*
 - **Hib bone**= *os coxae*
 - Sacrum = *os sacrum*
- Free parts= *pars libera*
 - stylopodium
 - **Femur** = *femur*
 - **Patella** = *patella*
 - zeugopodium
 - **Tibia**= *tibia*
 - **Fibula** = *fibula*
 - autopodium
 - **Tarsal bones** = *ossa tarsi* (8)
 - **Metatarsal bones**= *ossa metatarsi* (5)
 - **Phalnges** = *phalanges pedis* (14)
 - **Sesamoid bones** = *ossa sesamoidea*



Pelvis (*Pelvis*)

- Hip bone = *os coxae*
- Sacrum = *os sacrum*

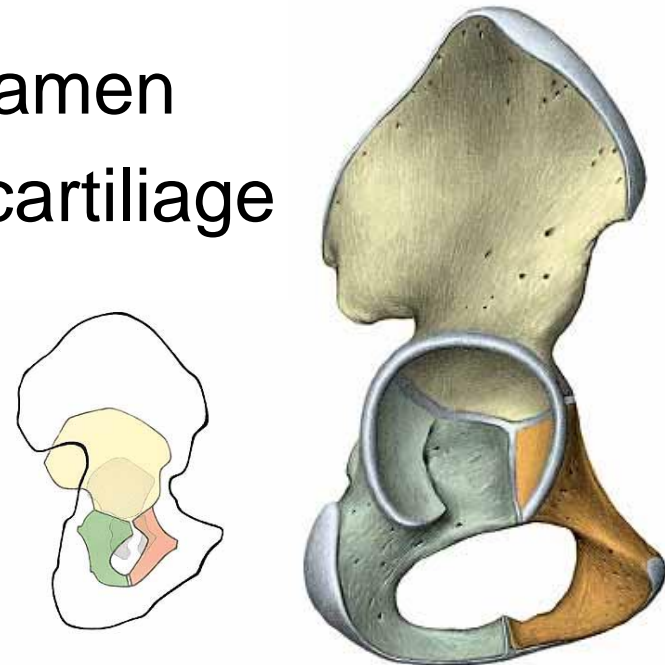
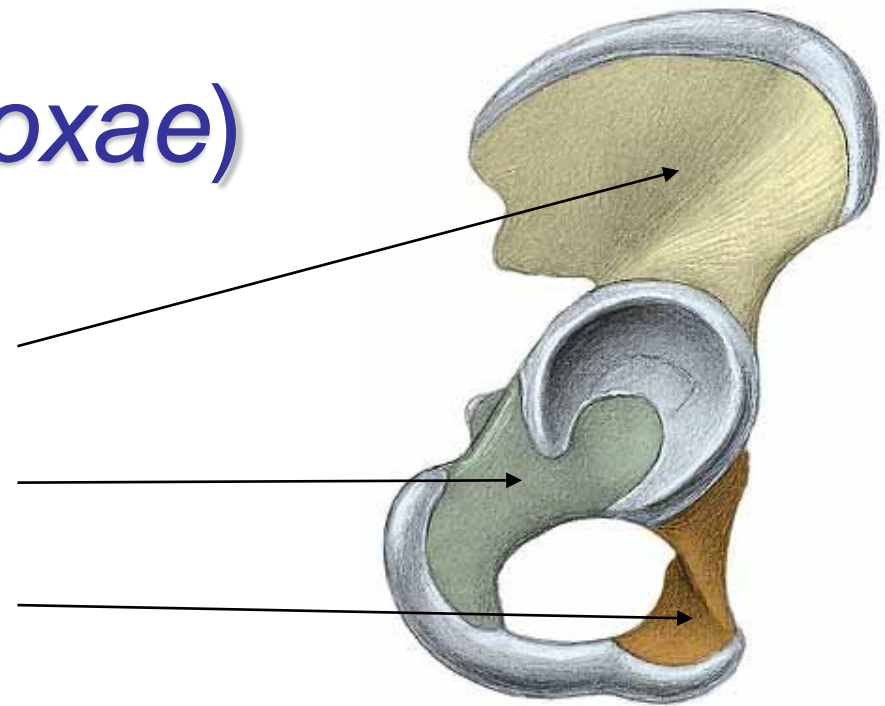
- Greater pelvis = *pelvis major*
- *linea terminalis*
- Lesser pelvis = *pelvis minor*



Hip bone (*Os coxae*)

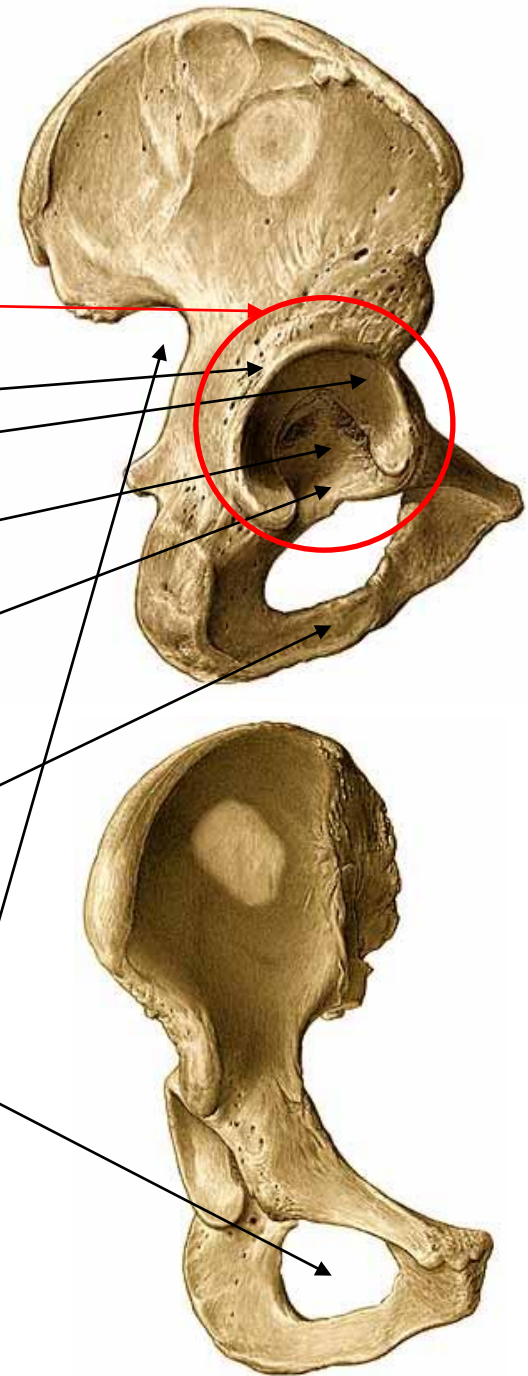
- Ilium (*Os ilium*)
- Ischium (*Os ischii*)
- Pubis (*Os pubis*)

- Acetabulum / Acetabulum
- Foramen obturatum / obturator foramen
- Cartilago ypsiloformis / Y shaped cartilage
 - Ossification around age 14 -16 y



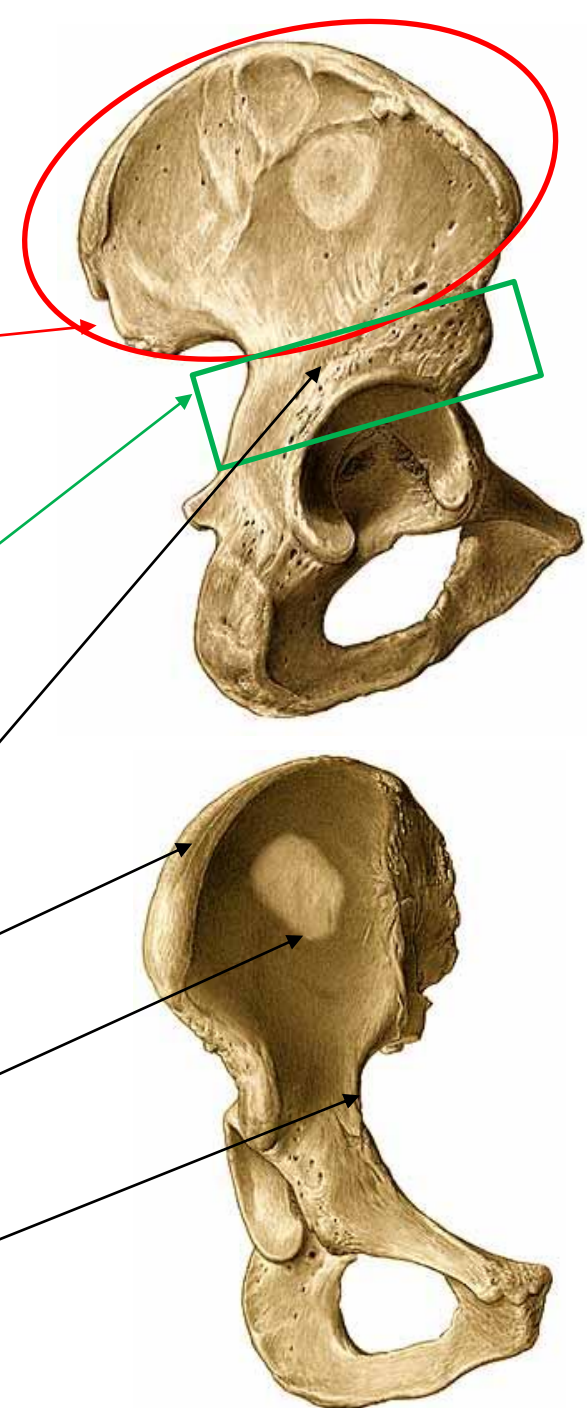
Hib bone (*Os coxae*)

- Acetabulum / Acetabulum
- Limbus acetabuli / Acetabular margin
- Facies lunata / lunar surface
- Fossa acetabuli / Acetabular fossa
- Incisura acetabuli / Acetabular notch
- Ramus ischiopubicus / Ischiopubic ramus
- Foramen obturatum / obturator foramen
- Incisura ischiadica major / Greater sciatic notch



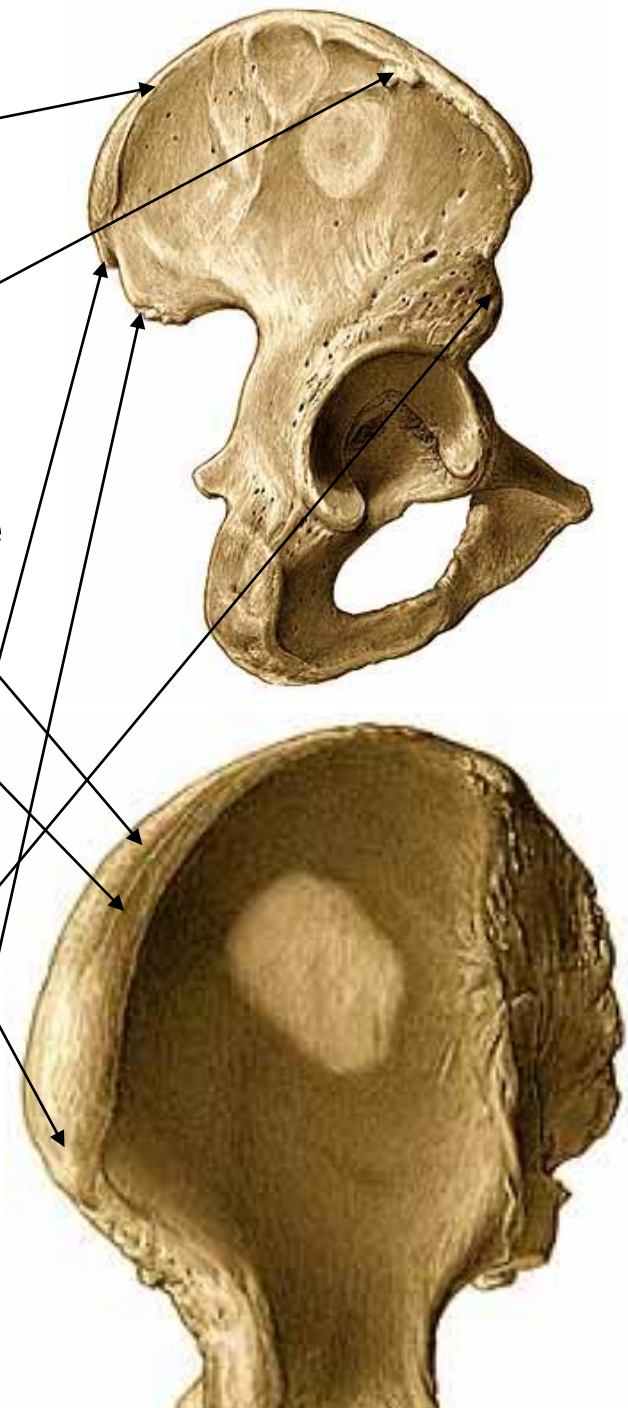
Ilium (*Os ilium*)

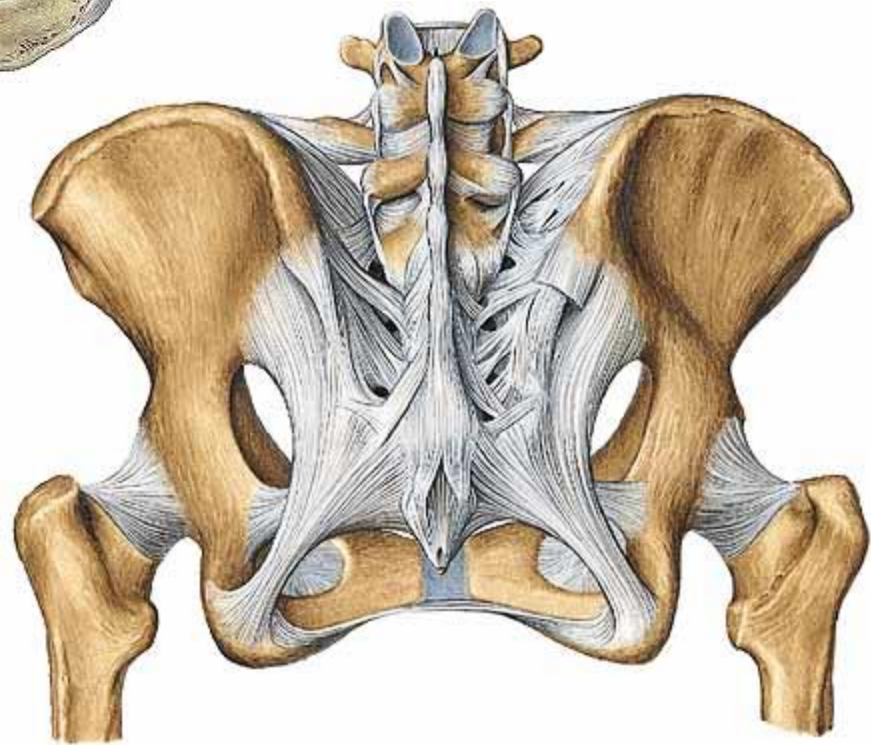
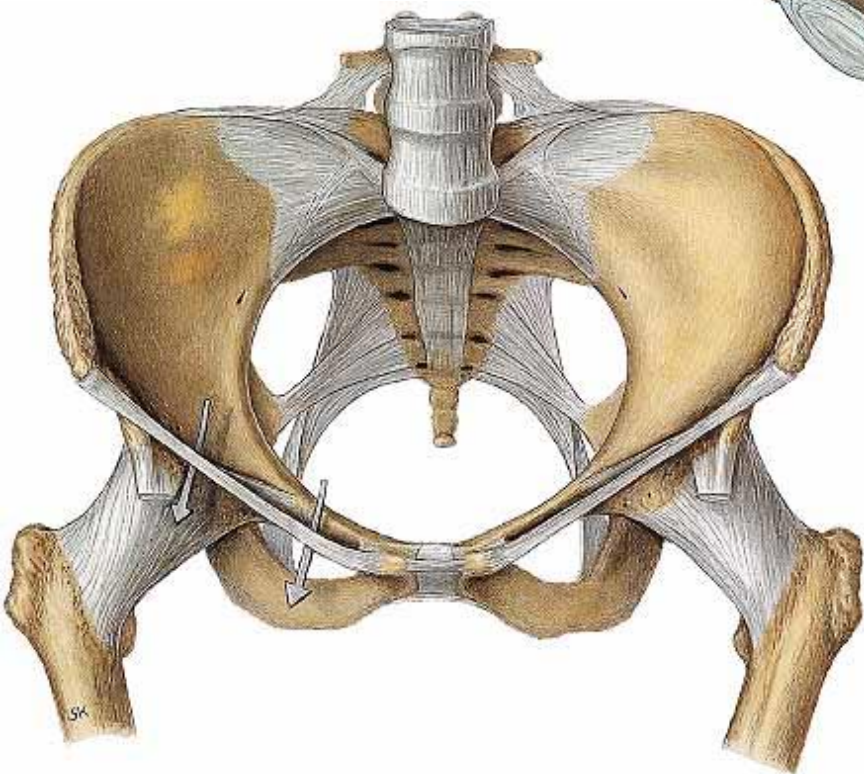
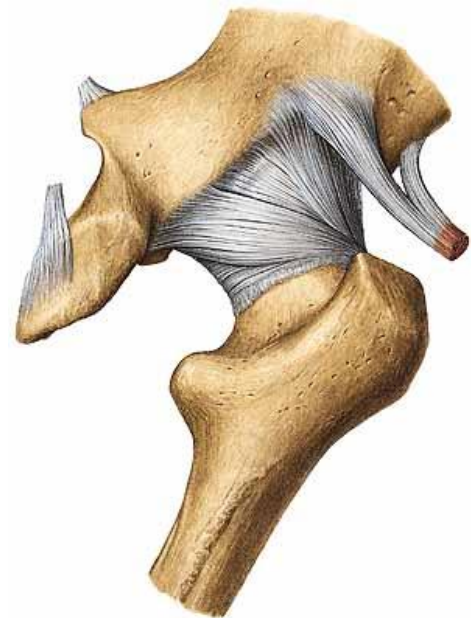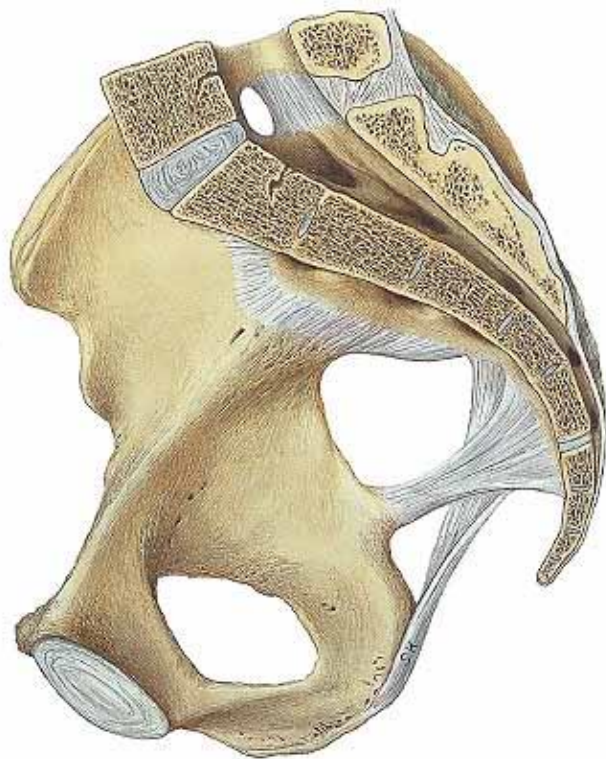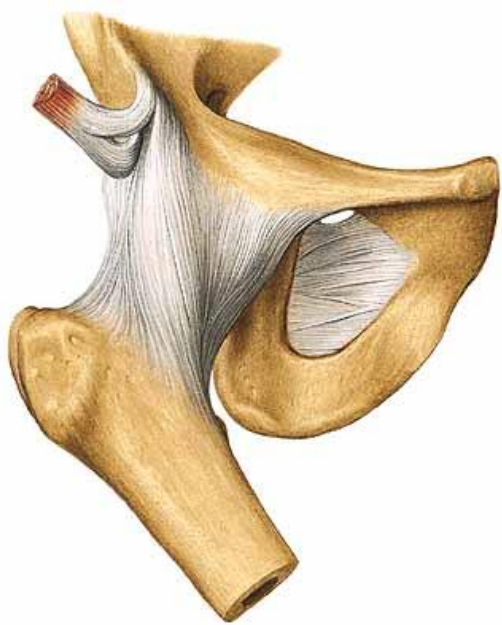
- Ala ossis ilii / Ala (wing) of ilium
- Corpus ossis ilii / body of the ilium
- Sulcus supraacetabularis / Supra-acetabular groove
- Crista iliaca / iliac crest
- Fossa iliaca / iliac fossa
- Linea arcuata / arcuate line



Ilium (*Os ilium*)

- **Crista iliaca / iliac crest**
- Labium externum cristae iliacaе / Outer lip of iliac crest
- Tuberculum iliacum / iliac tubercle
- Linea intermedia cristae iliacaе / intermediate line of iliac crest
- Labium internum cristae iliacaе / inner lip of iliac crest
- Spina iliaca anterior superior / anterior superior iliac spine
- Spina iliaca anterior inferior / anterior inferior iliac spine
- Spina iliaca posterior superior / posterior superior iliac spine
- Spina iliaca posterior inferior / posterior inferior iliac spine

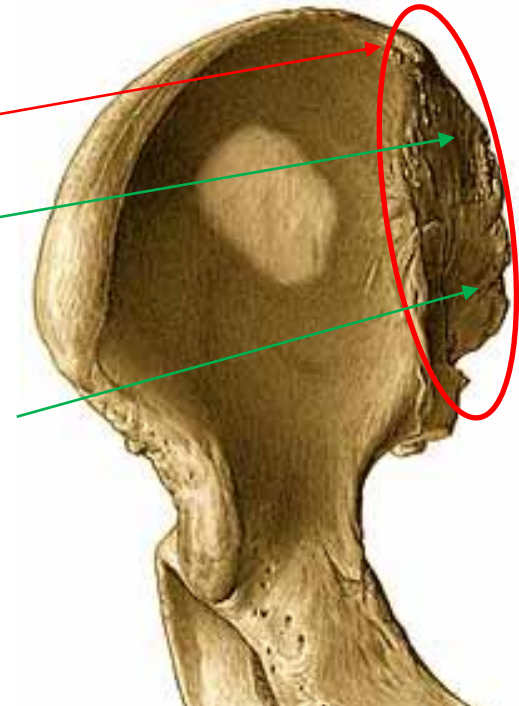
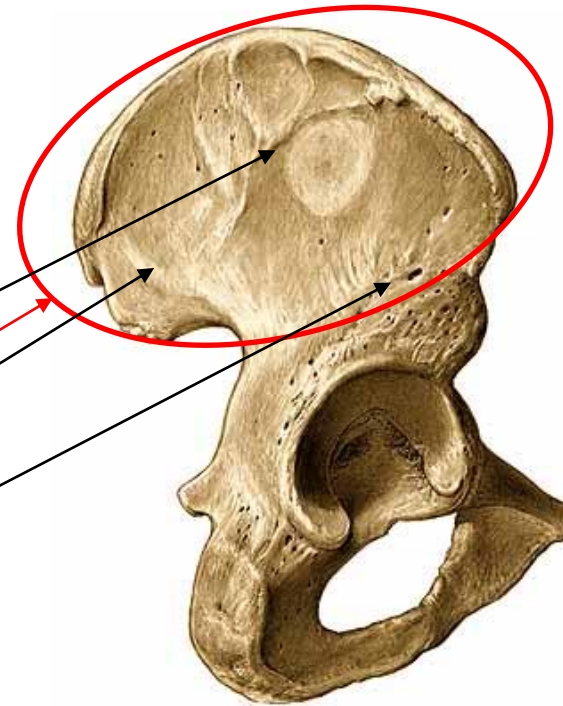




Ilium (*Os ilium*)

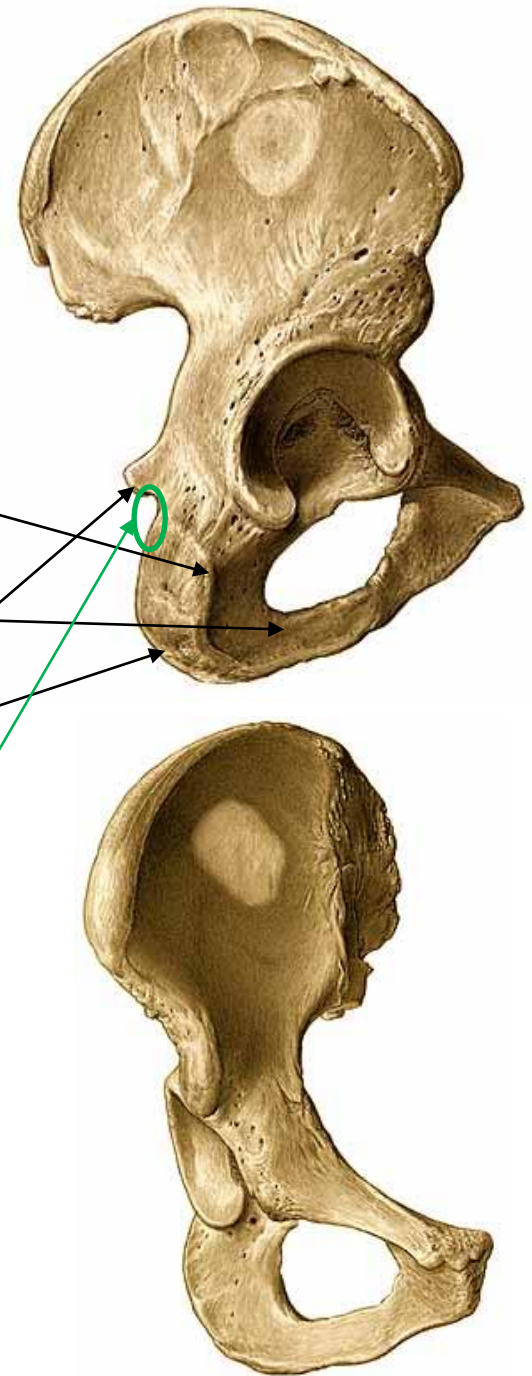
- Facies glutea / gluteal surface
- Linea glutea anterior
- Linea glutea posterior
- Linea glutea inferior

- Facies sacropelvica
- Tuberositas iliaca
- Facies auricularis



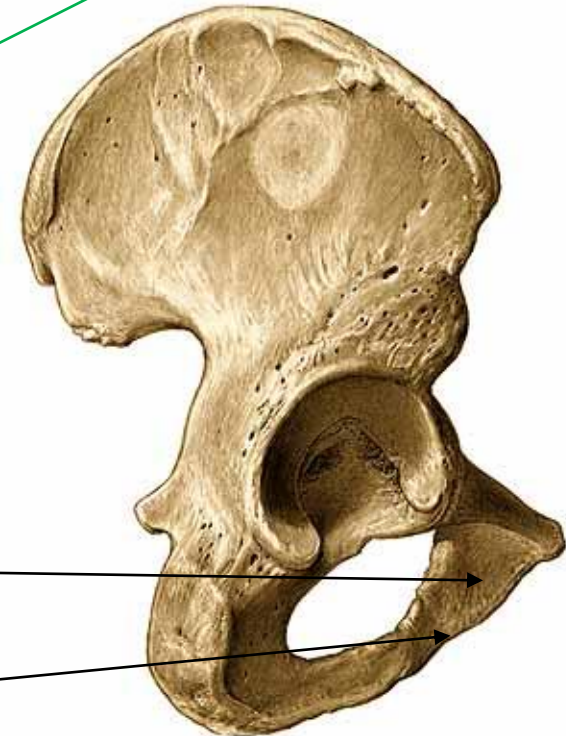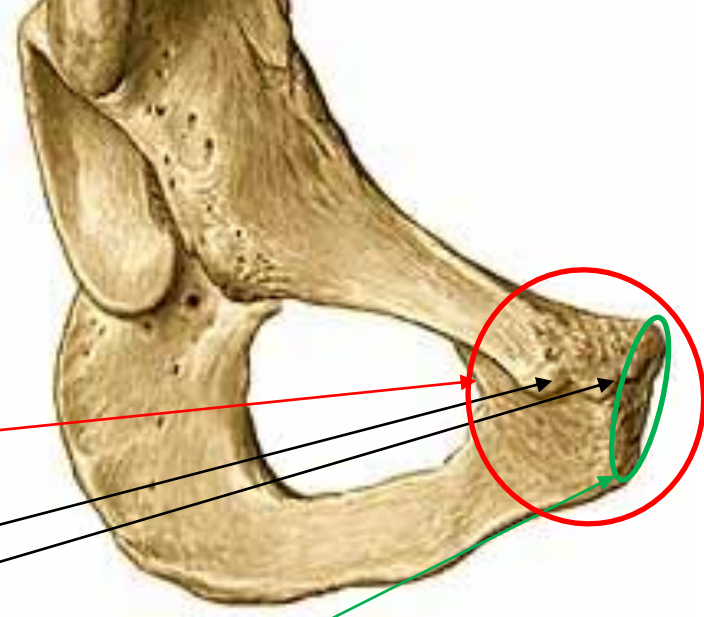
Iscium (*Os ischii*)

- Corpus ossis ischii
- Ramus ossis ischii
- Tuber ischiadicum
- Spina ischiadica
- Incisura ischiadica minor



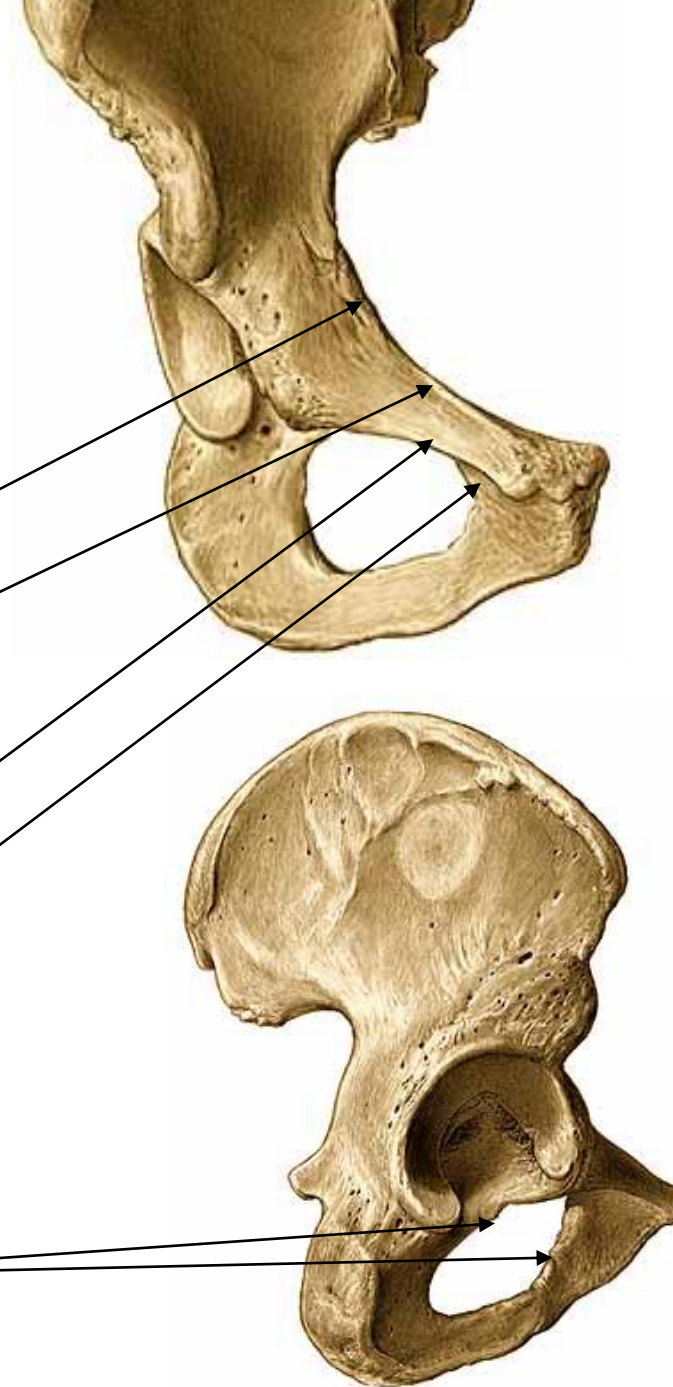
Pubis (*Os pubis*)

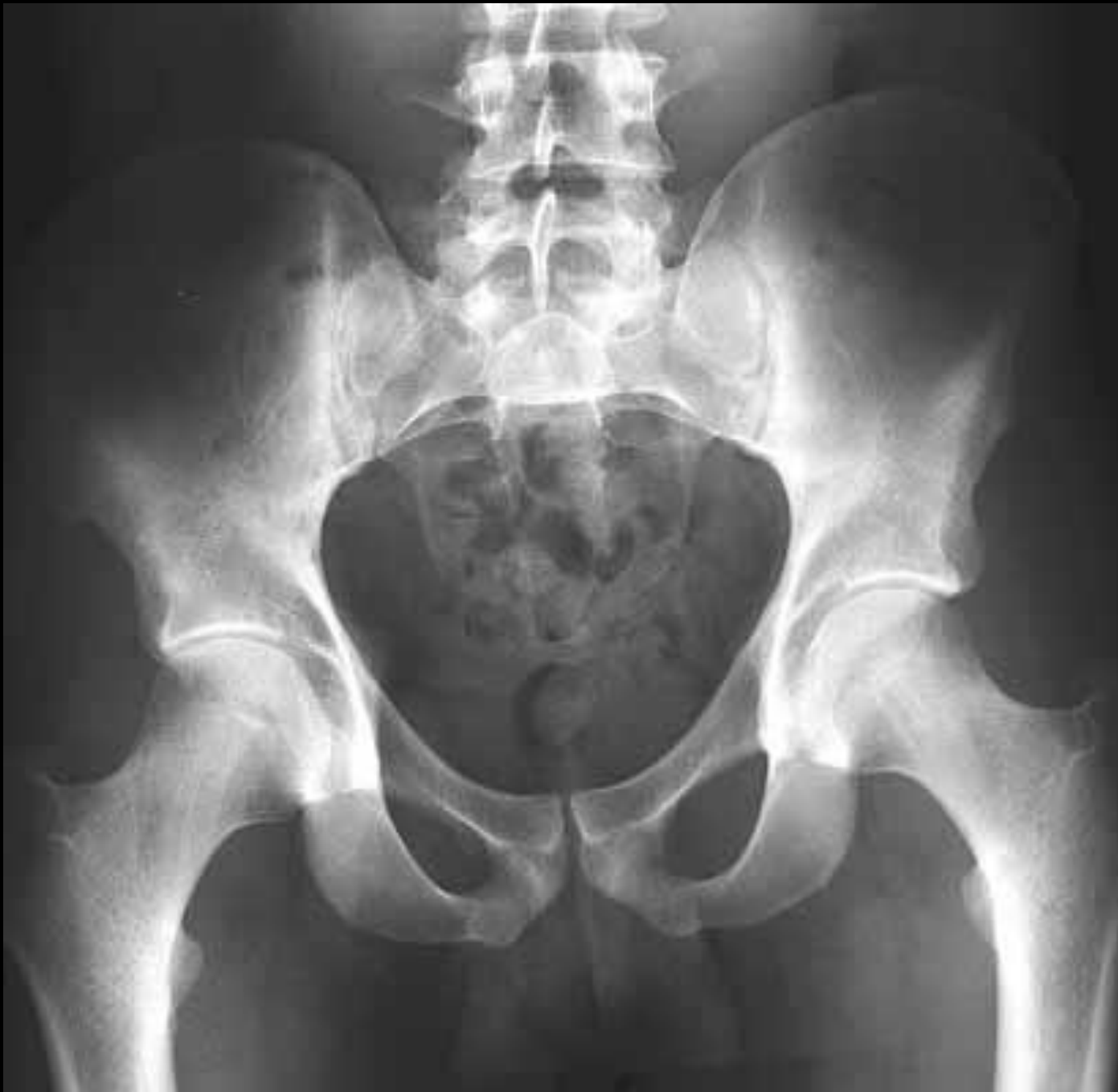- **Corpus ossis pubis**
- Tuberculum pubicum
- Crista pubica
- Facies symphysialis / pubic symphysis facet
- **Ramus inferior ossis pubis**
- Crista phallica

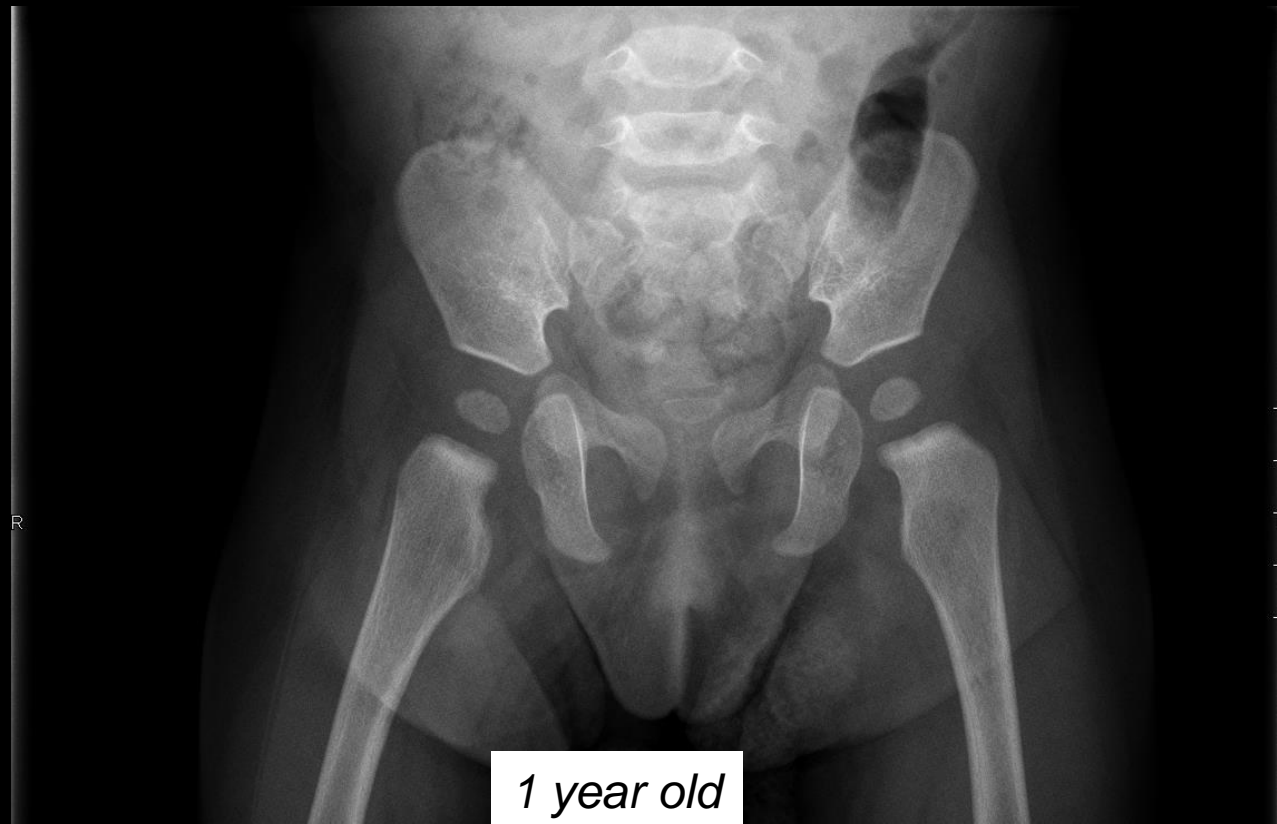
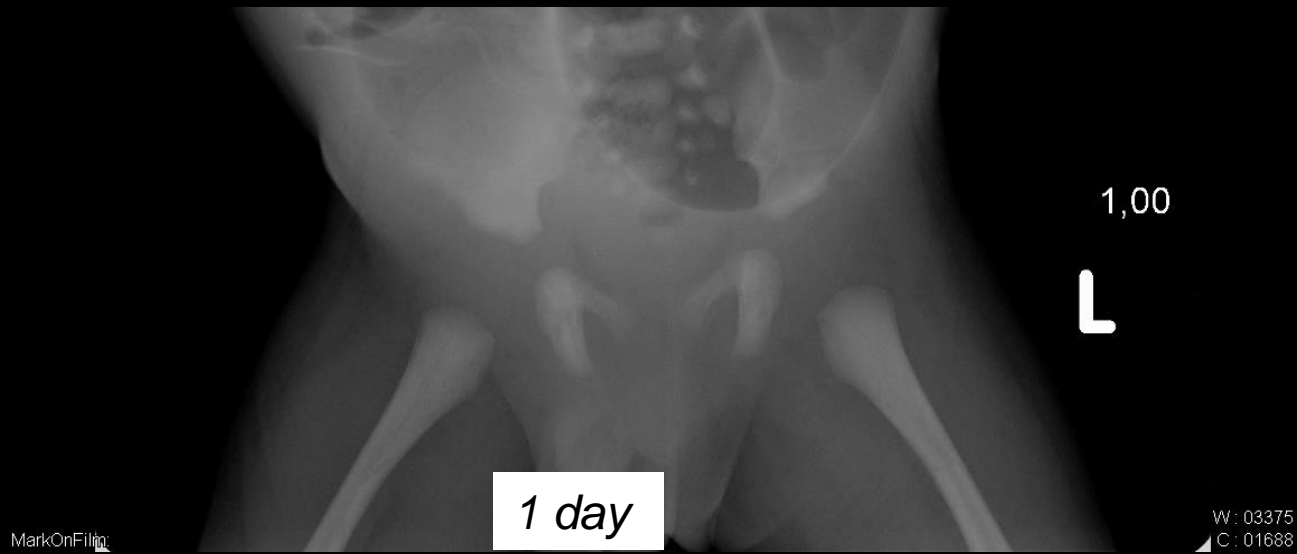
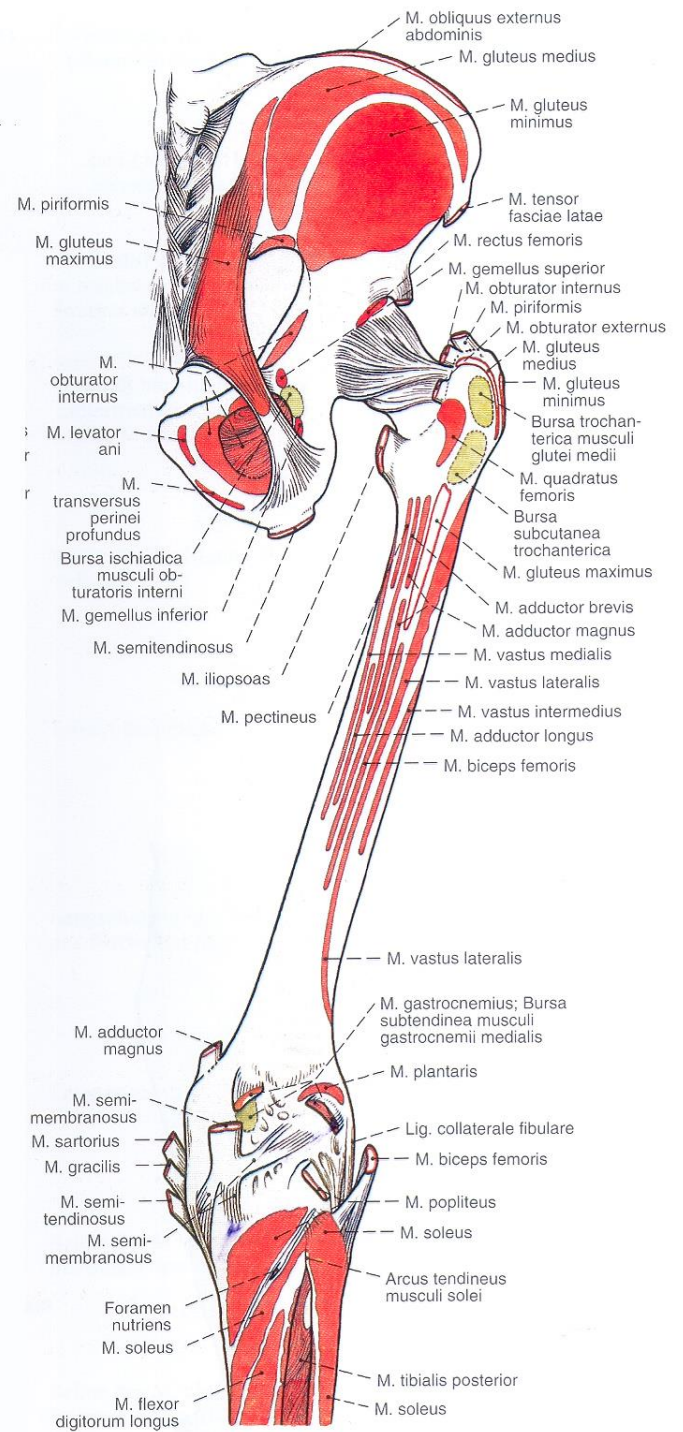
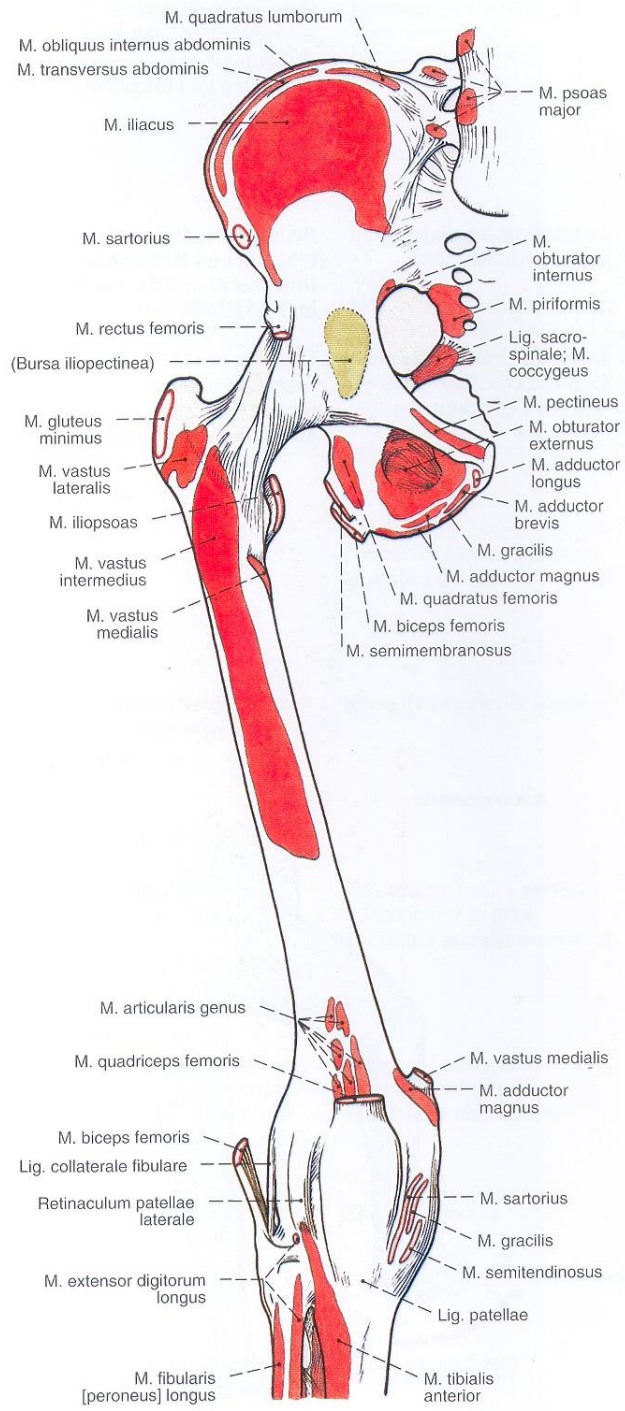
Pubis (*Os pubis*)

- **Ramus superior ossis pubis**
- Eminentia iliopubica
- Pecten ossis pubis
- Crista obturatoria
- Sulcus obturatorius
- (Tuberculum obturatorium
anteriorius et posteriorius)







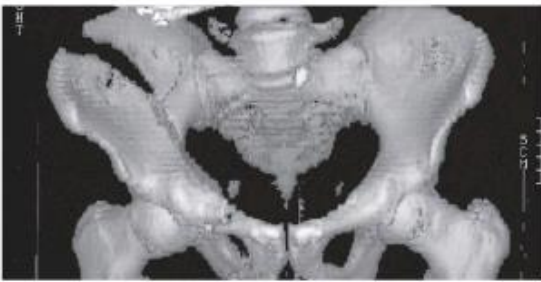


Clinical notes

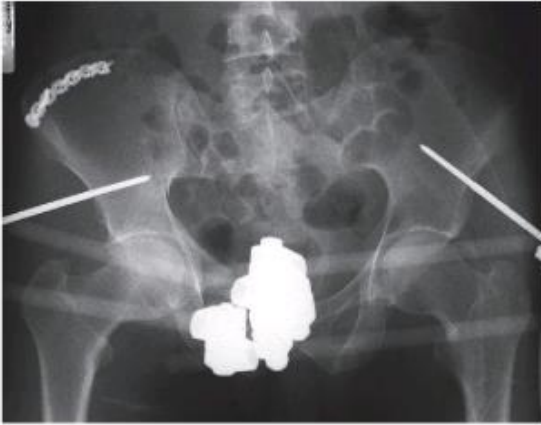
- the pelvis contains many important easily vulnerable structures (arteries, veins, nerves, ureters, bladder, urethra, rectum)
- fractures are usually caused by high-energy mechanisms
- Severe pelvic injuries (complex injuries) must be considered a life-threatening condition - there is a risk of bleeding if the organs stored in the pelvis are injured! (blood loss up to 5l)
- Type of fracture - „open book“
- avulsion fractures - detachment of muscle attachment (*spina iliaca anterior superior*)
- Birth canal pass through the pelvis

Pelvic fractures

a

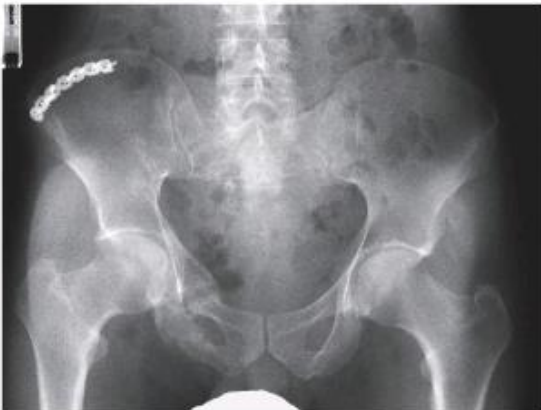

b

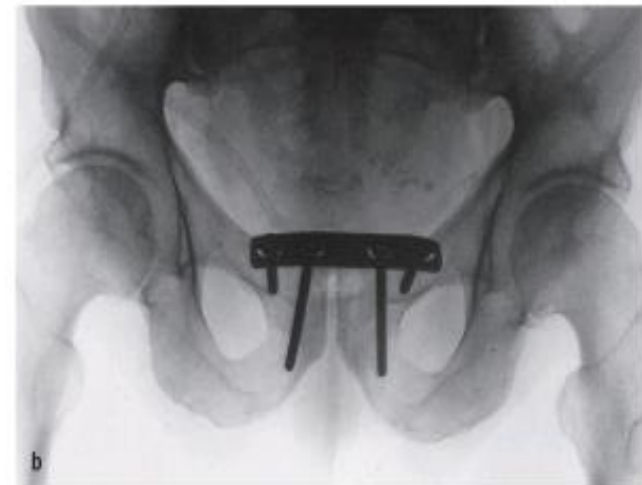
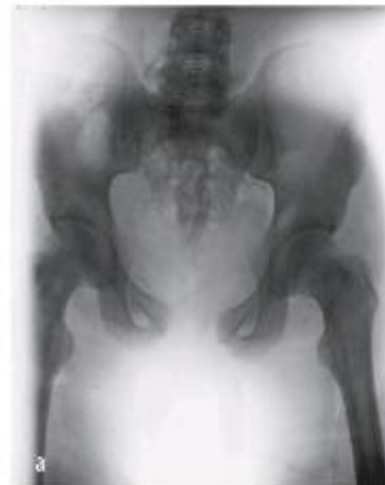

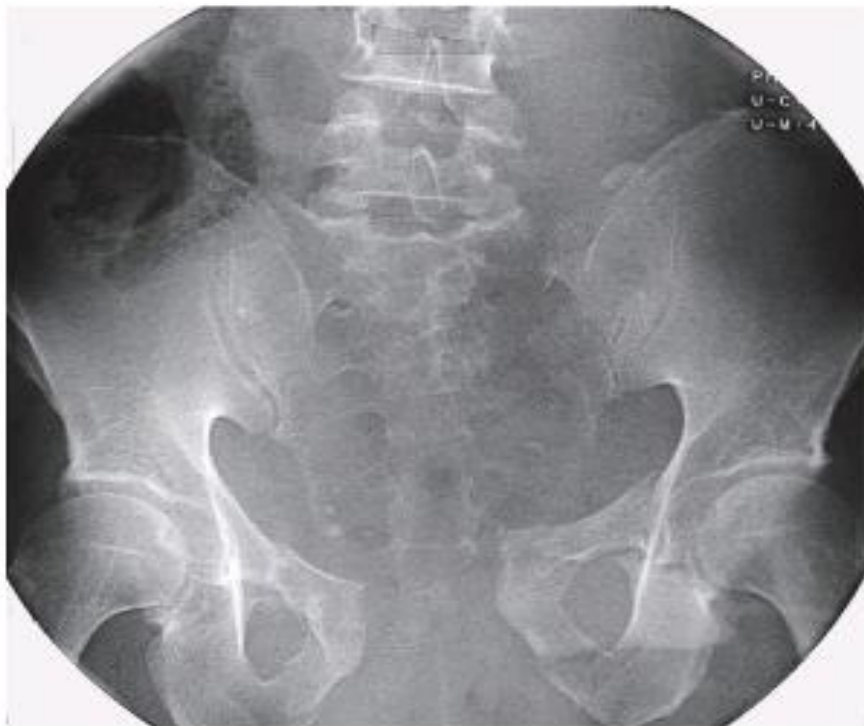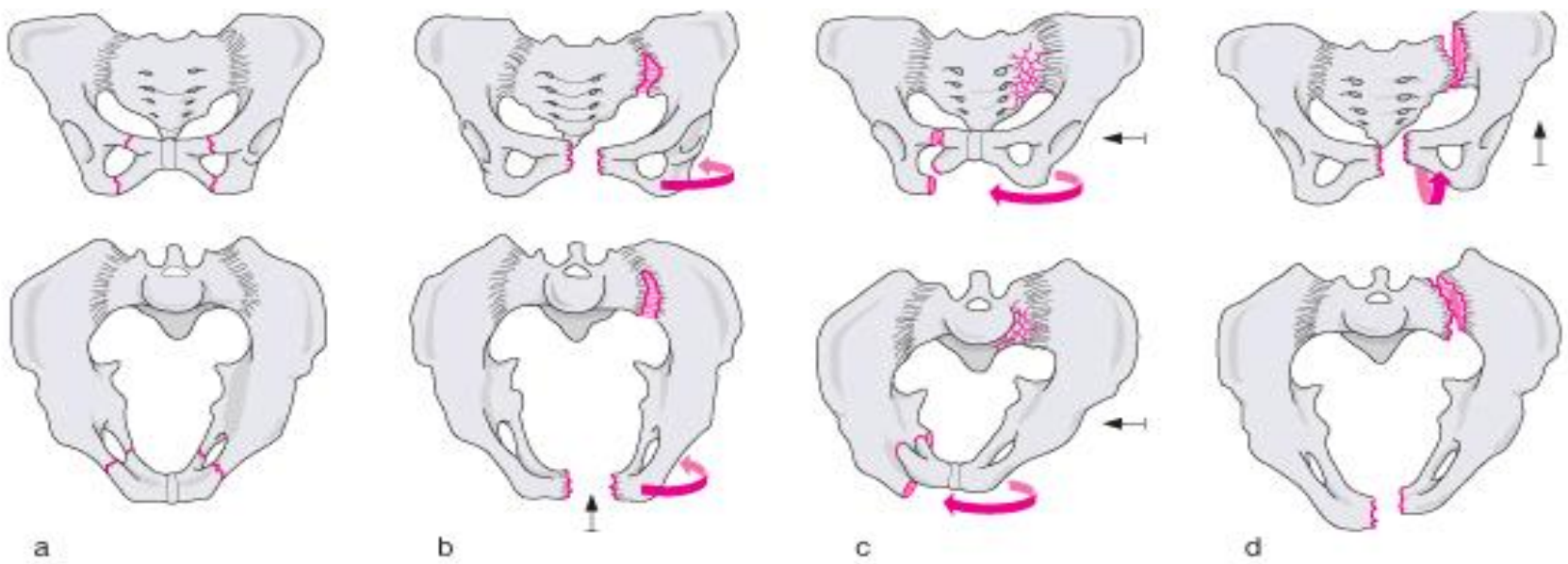
← hip bone fracture

c

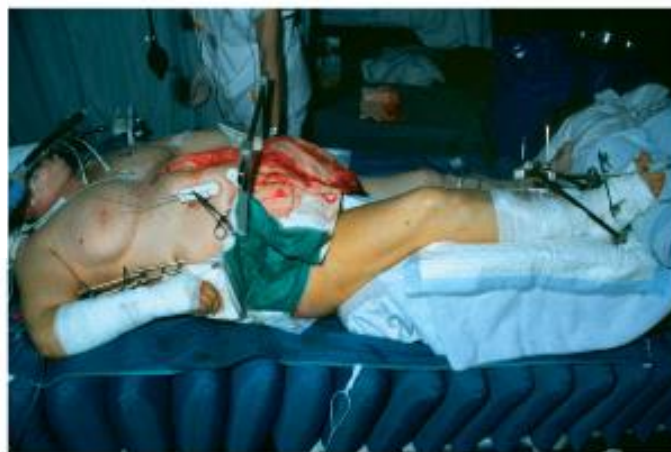
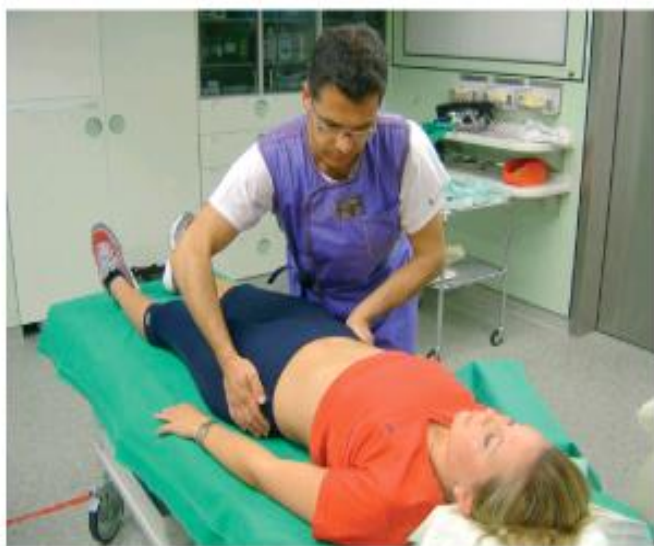
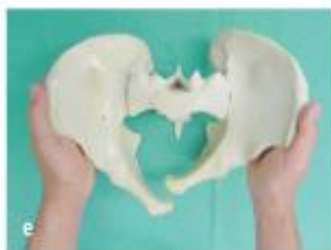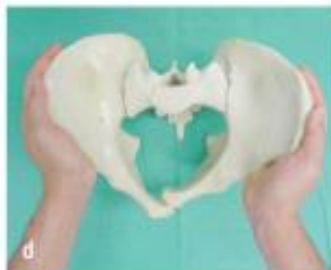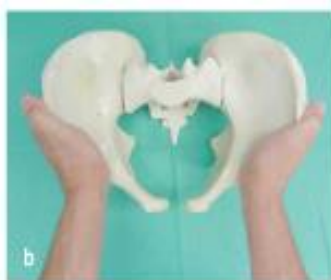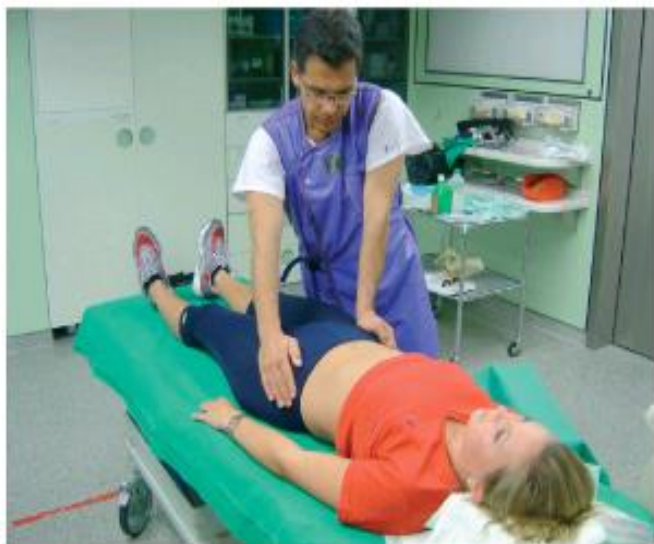„open book“ fracture ↓





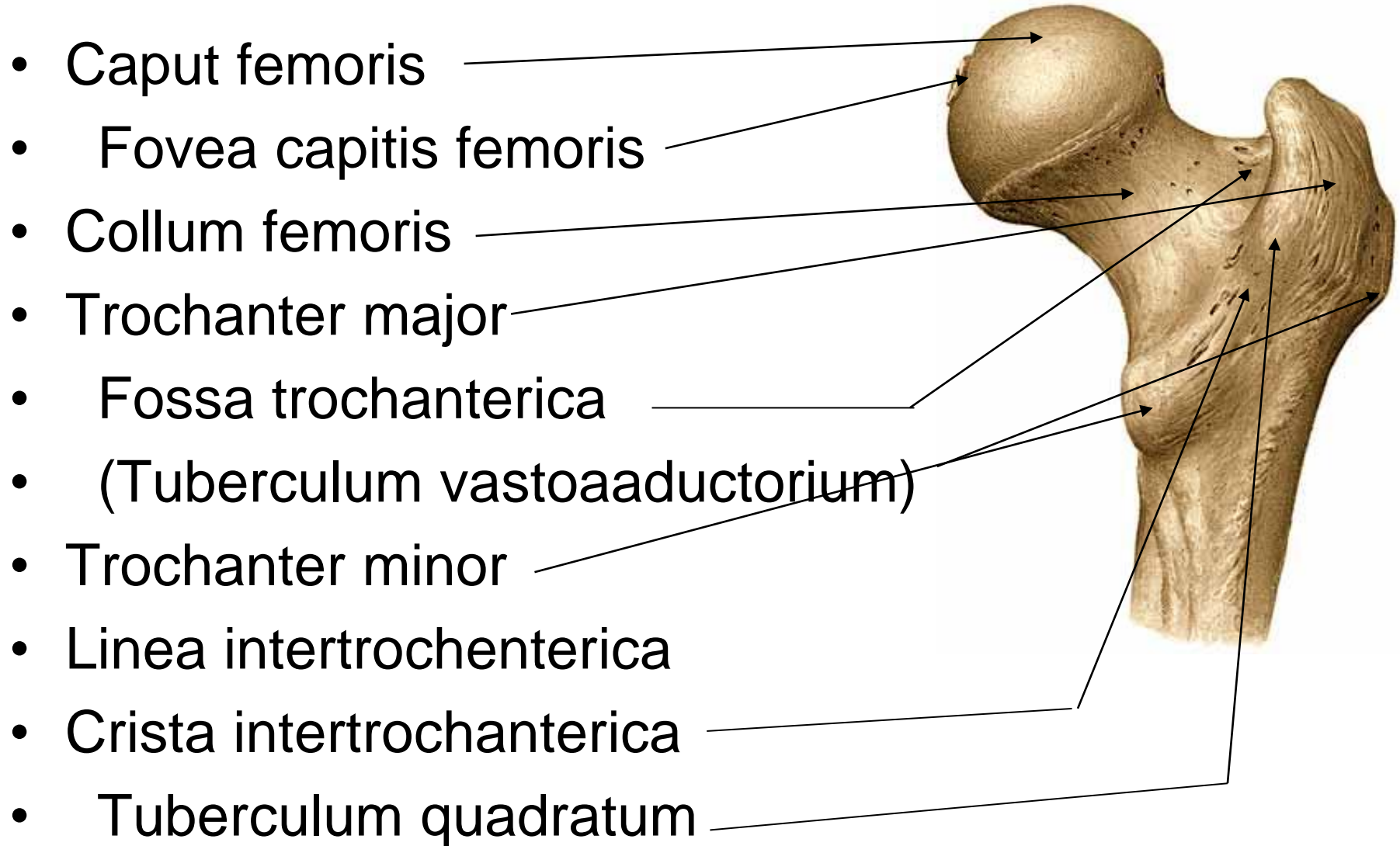
„open book“
fracture type



Berchtold/Bruch/Trentz: Chirurgie, 5.A. © Elsevier GmbH. www.studentconsult.de

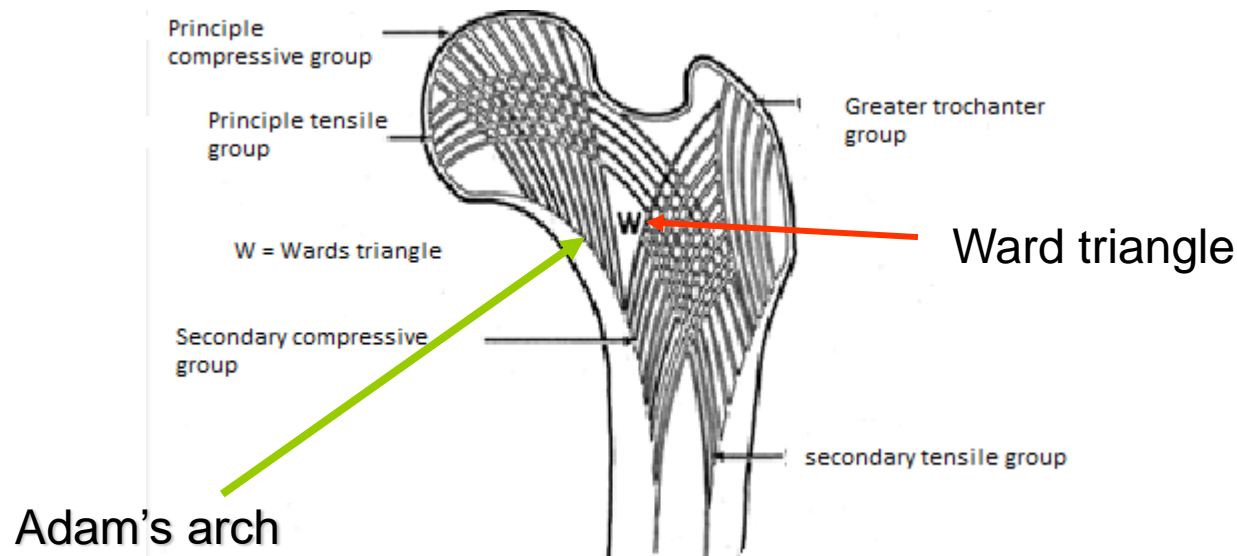
Berchtold/Bruch/Trentz: Chirurgie, 5.A. © Elsevier GmbH. www.studentconsult.de

Femur (*Femur / Os femoris*)

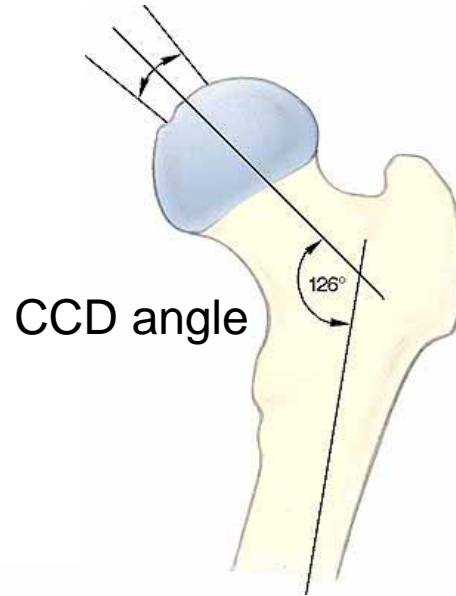
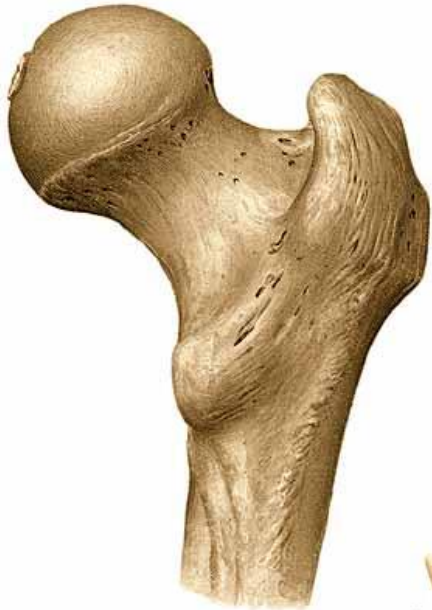

Inner structure of the femur

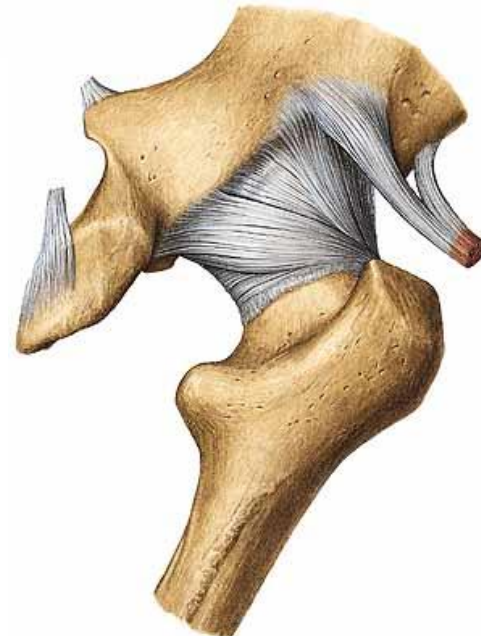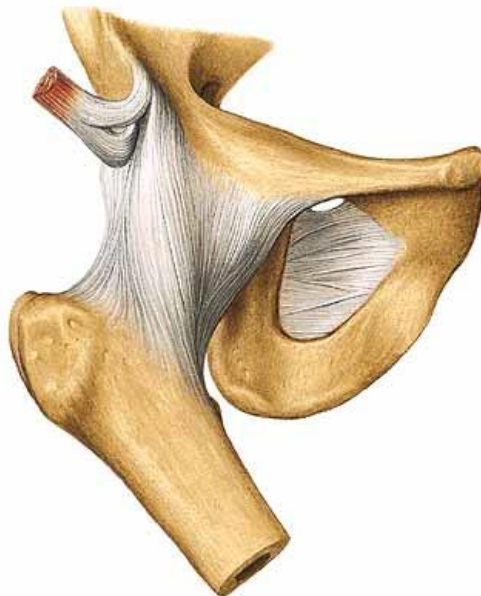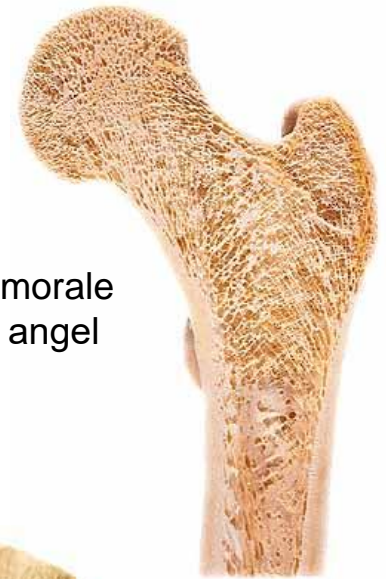- Adam's arch
 - Neck of the femur continues to the shaft on the medial side with a thick compact bone
- Ward triangle
 - Space inside the neck of the femur between the crossing osseous trabeculae



Femur (*Femur / Os femoris*)



calcar femorale
Adam's angel



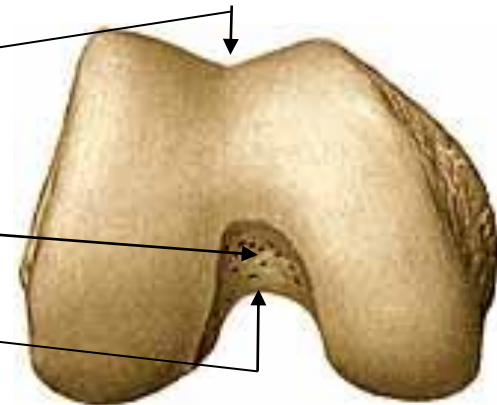
Femur (*Femur / Os femoris*)

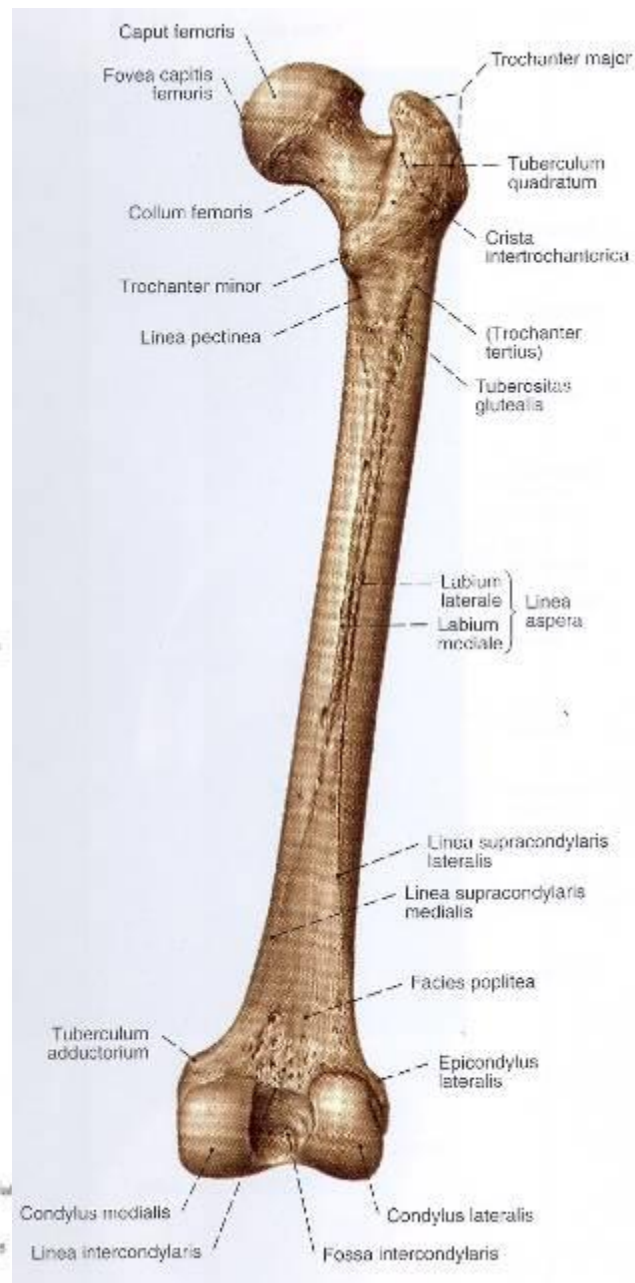
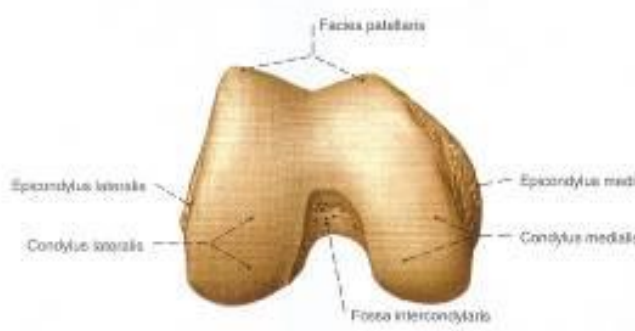
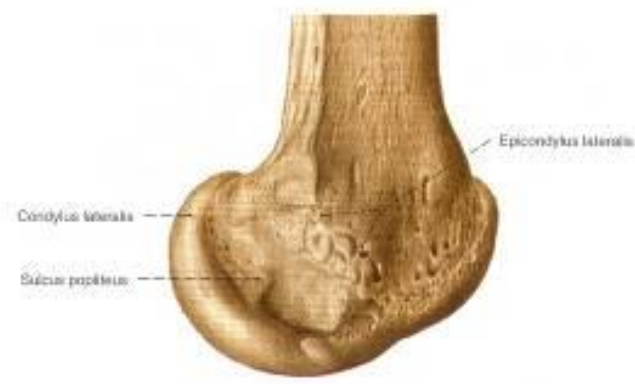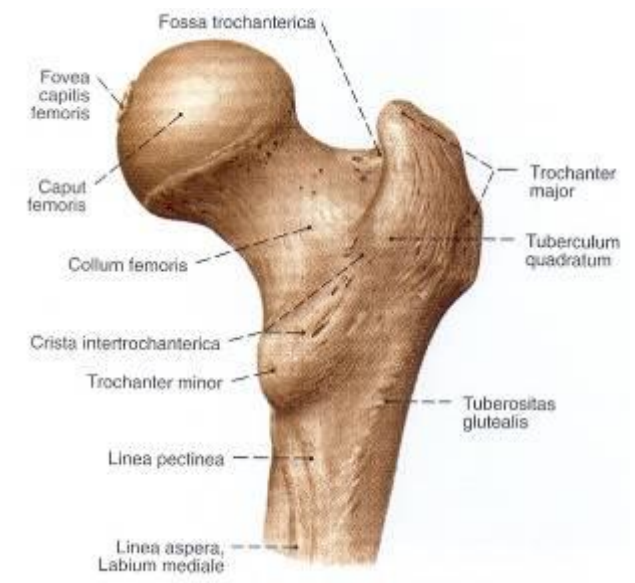

- Corpus femoris
- Linea aspera / (Rough line)
- Labium laterale lineae asperae
- Labium mediale lineae asperae
- (Linea spiralis)
- Linea pectinea / (Comb line)
- Tuberositas glutea / (Buttock roughness)
- (*Trochanter tertius / The third crest*) – *variable*
-
- Facies poplitea
- Linea supracondylaris medialis
- Linea supracondylaris lateralis



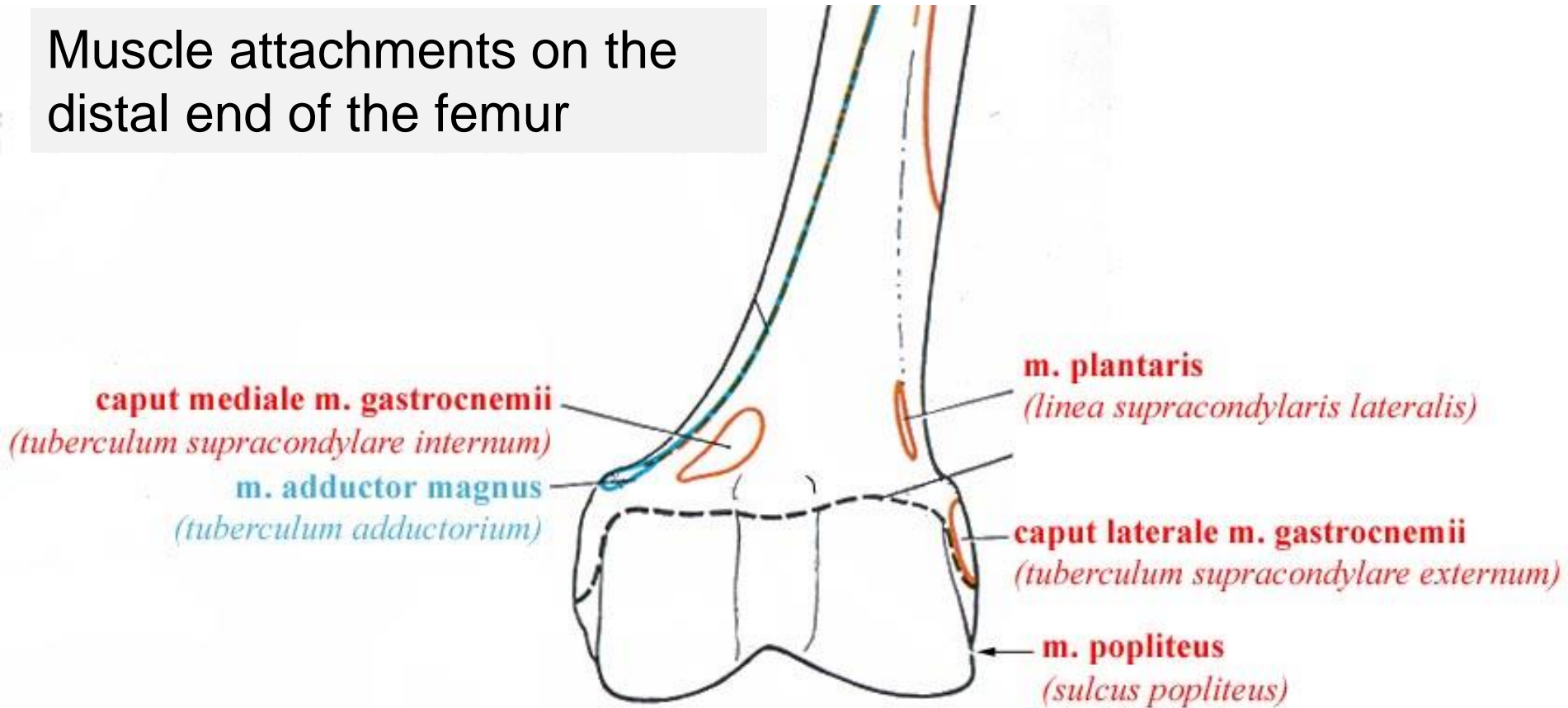
Femur (*Femur / Os femoris*)

- Condylus medialis
- Epicondylus medialis
- Tuberculum adductorium
- (*Tuberculum supracondylare internum*) - variable
- Condylus lateralis
- Epicondylus lateralis
- Sulcus popliteus / (Groove for popliteus)
- (*Tuberculum supracondylare externum*) - variable
- Facies patellaris / (cup area)
- Fossa intercondylaris
- Linea intercondylaris





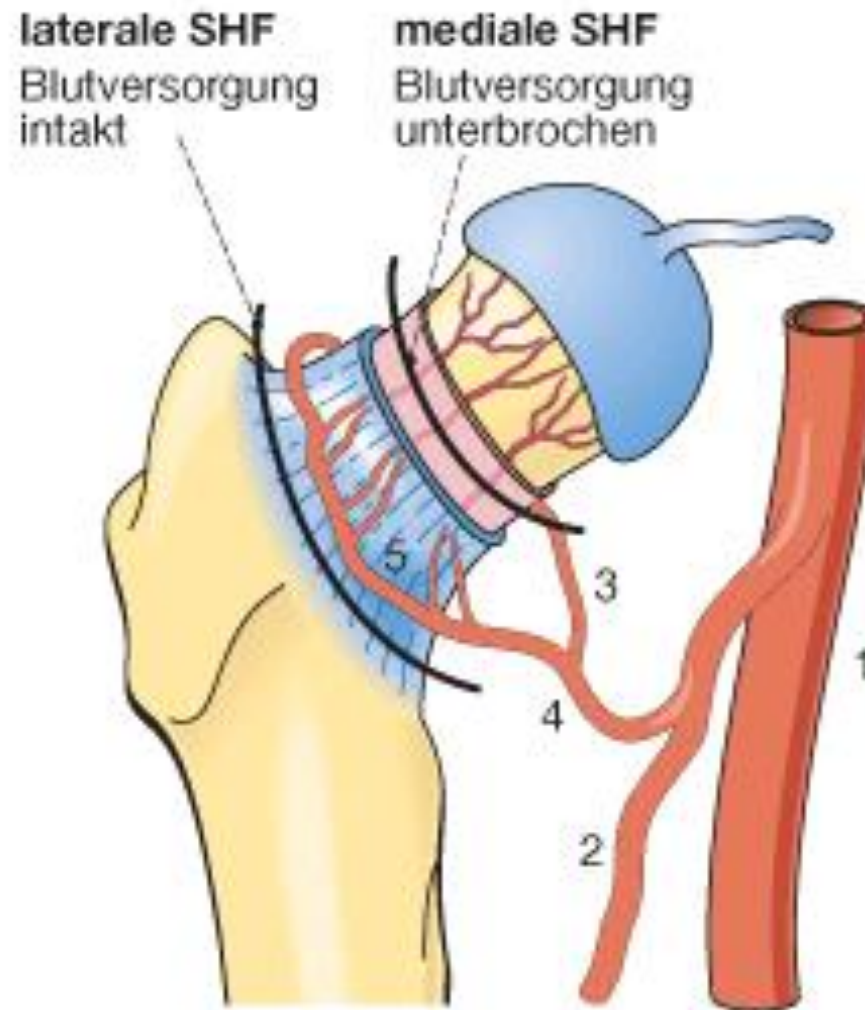
Muscle attachments on the distal end of the femur



Clinical notes

- *Adam's angle* – reinforces medially the cortical substance in the lesser trochanter area - transfer of forces from the neck to the femur body
- Vascular supply of the head of femur are mainly from the *arteria circumflexa femoris medialis* – in case of a broken neck, avascular necrosis may occur
- Neck of femur fracture is one of the most common injuries in the elderly! (clinical complication)
- Pertrochanteric fractures - in the area of trochanters
- Subtrochanteric - transition through the diaphysis (they have similar clinical picture as the neck of femur fracture)
- Fractures of the shaft occur under greater forces
- Fractures of the distal femur are common in car accidents

Arteria circumflexa femoris medialis



Hib X-Ray

← Anterioposterior projection

Lateral projection

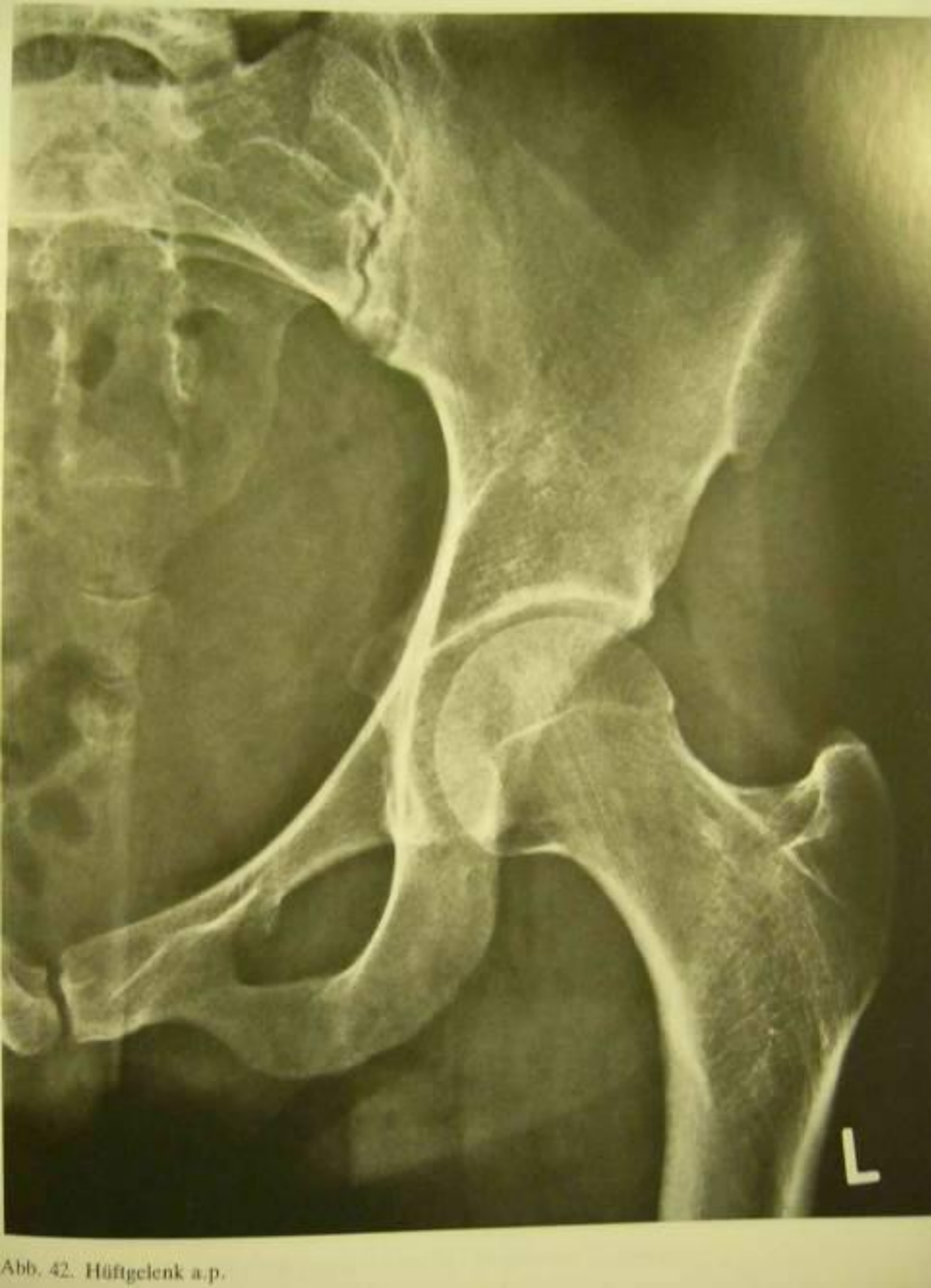
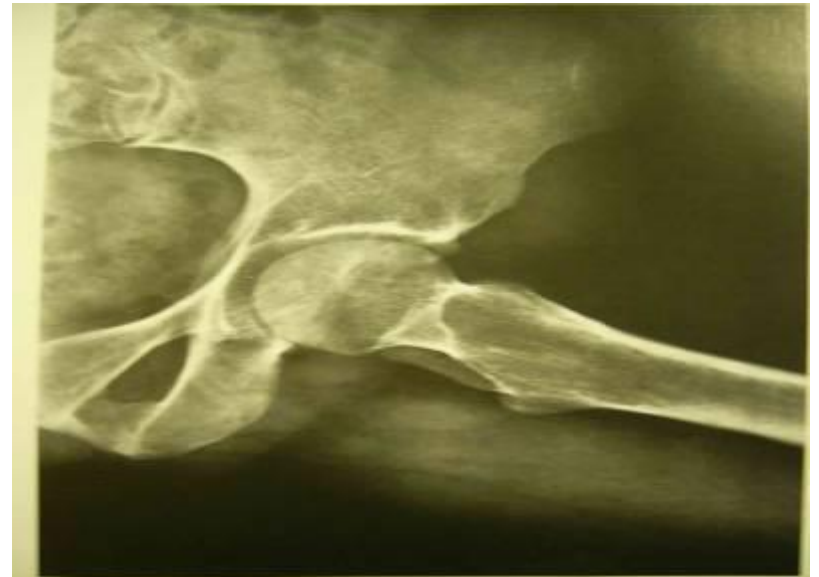
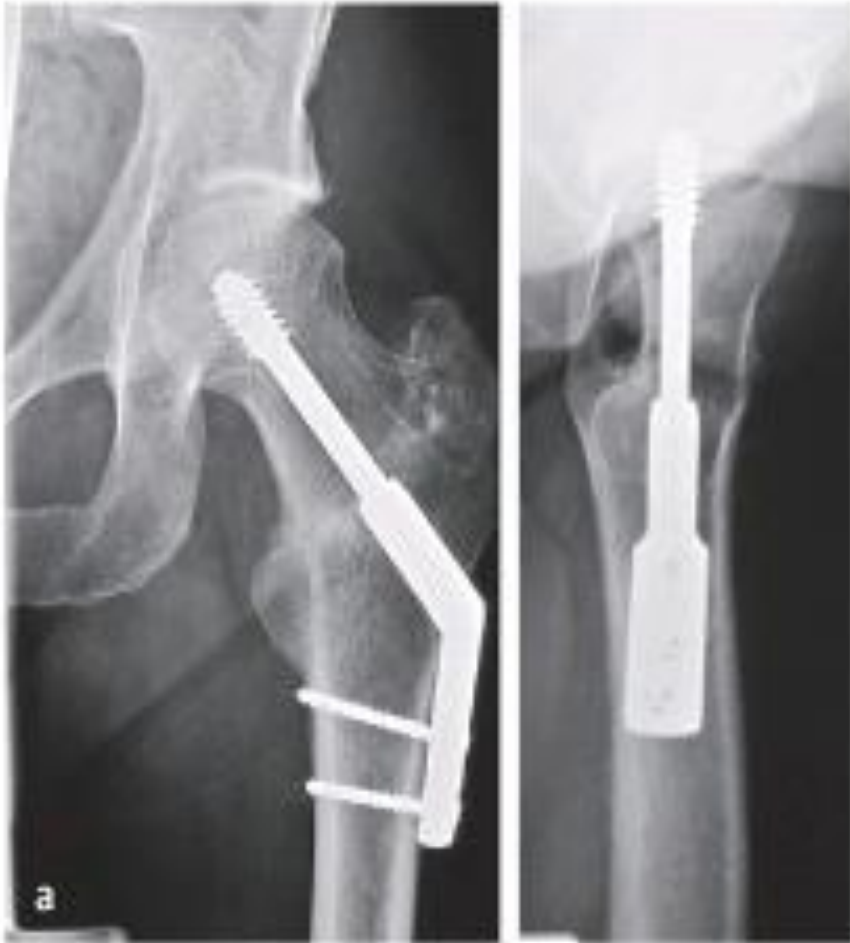Abb. 42. Hüftgelenk a.p.

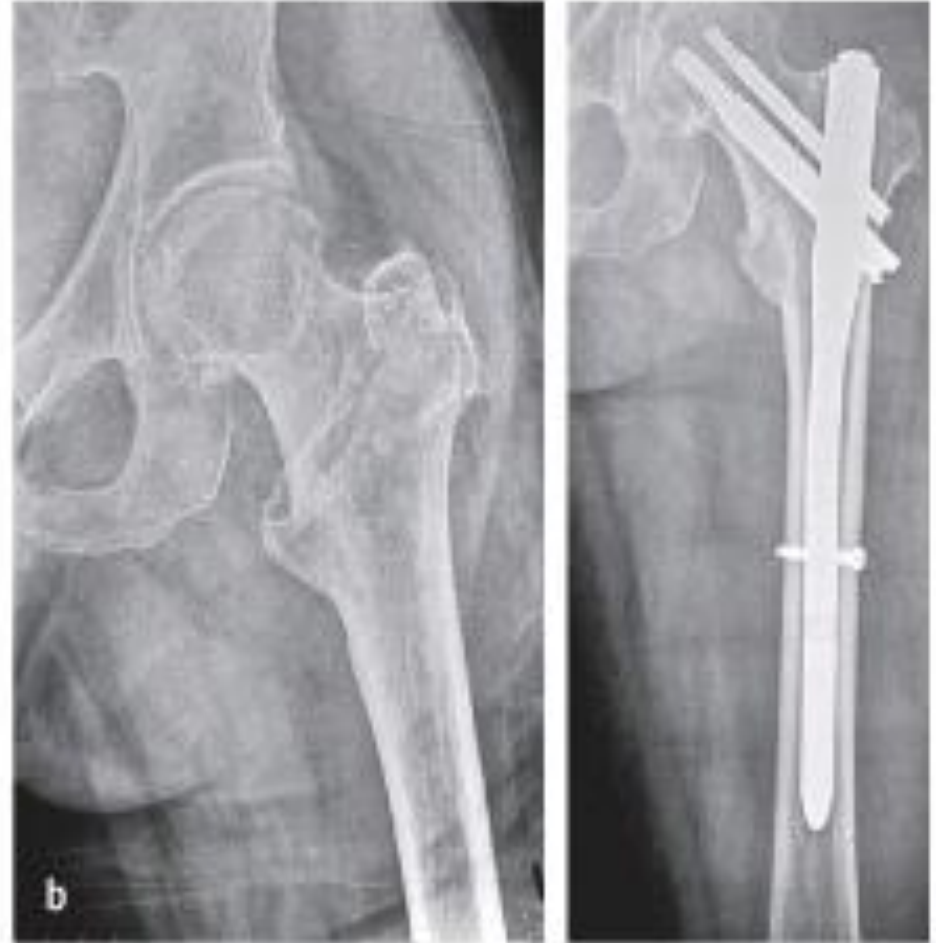DHS ↓

Dynamic Hip Screw



PFN ↓

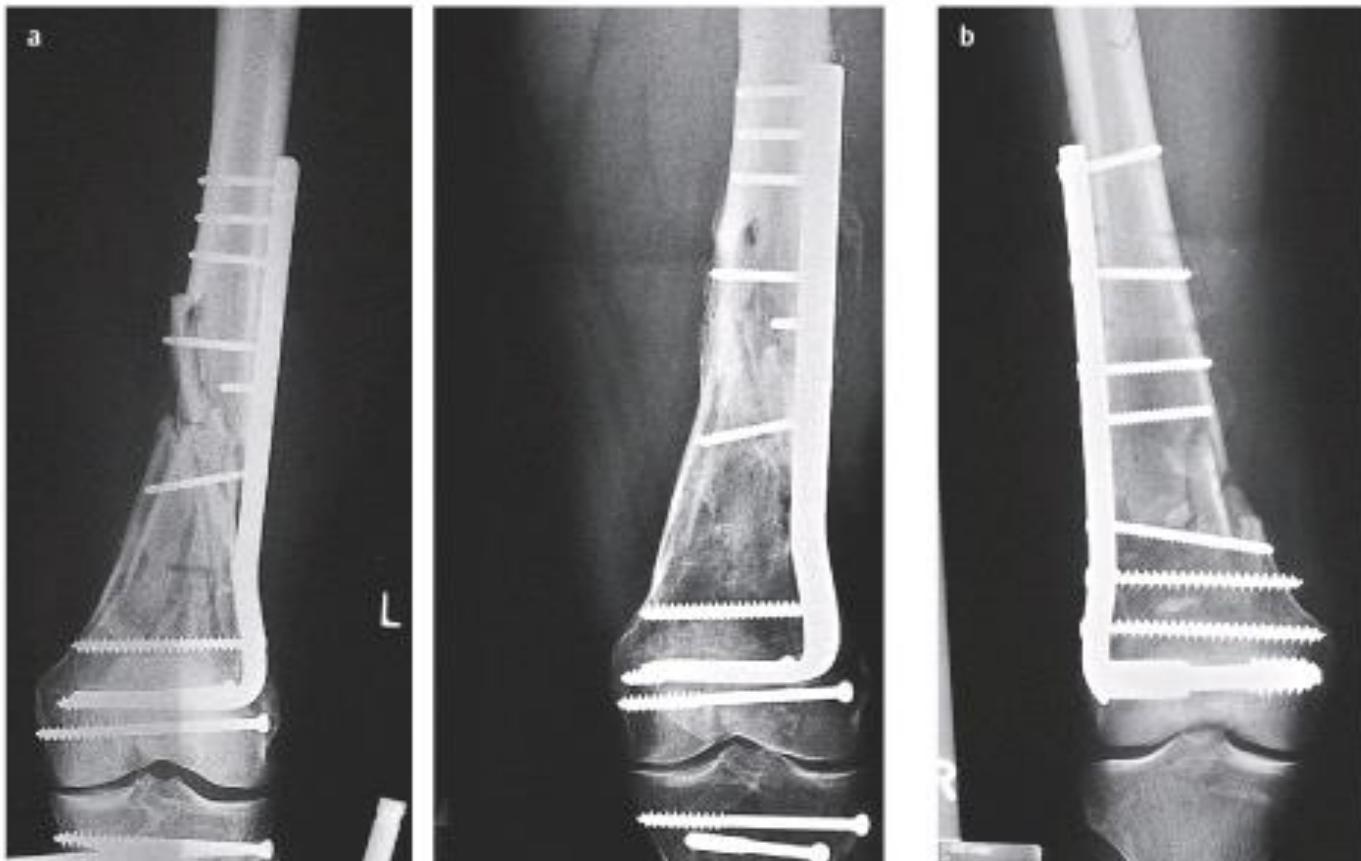
Proximal femoral nail



Fracture of the distal end of the femur

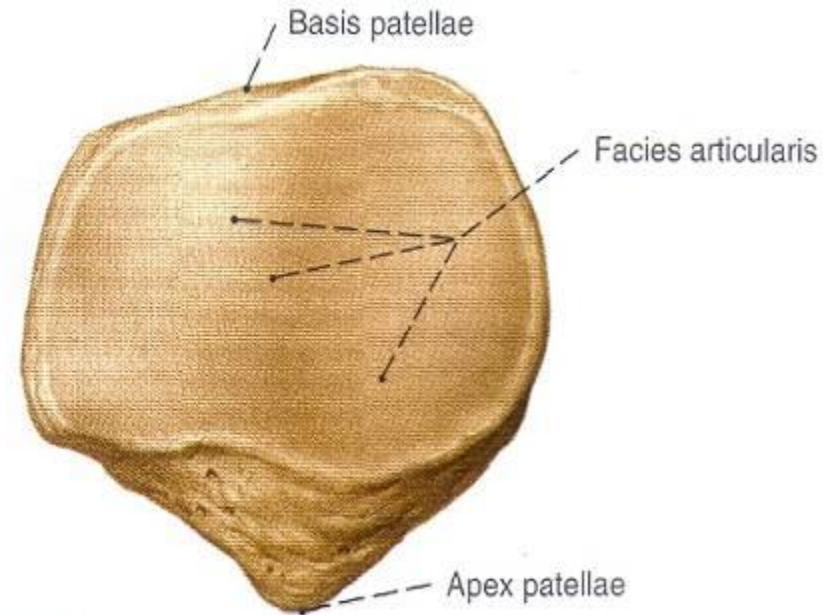
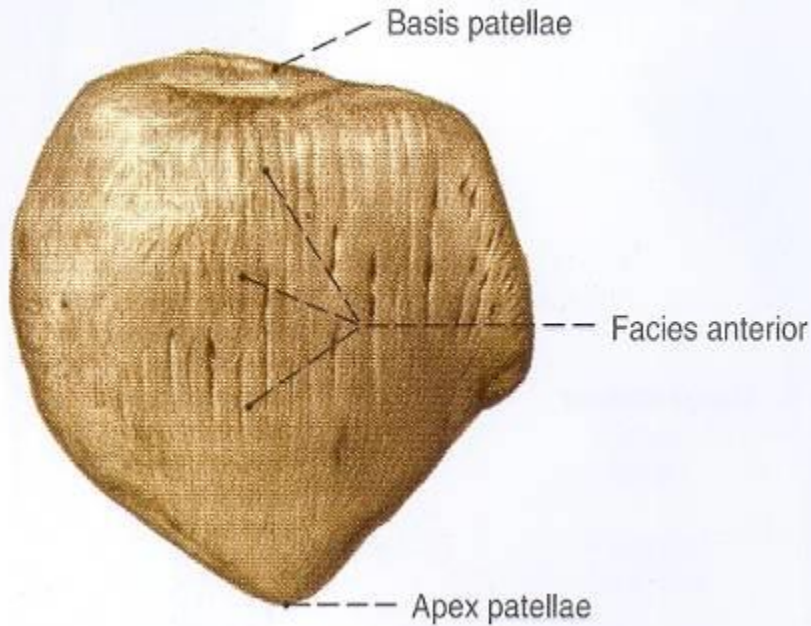
(a) osteosynthesis fixation plate

(b) dynamic condylar screw



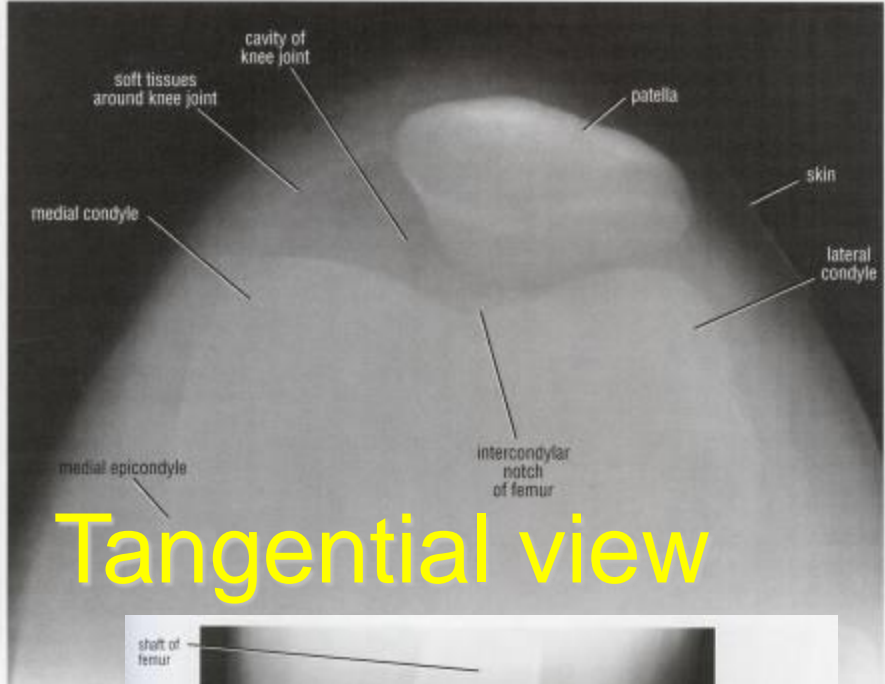
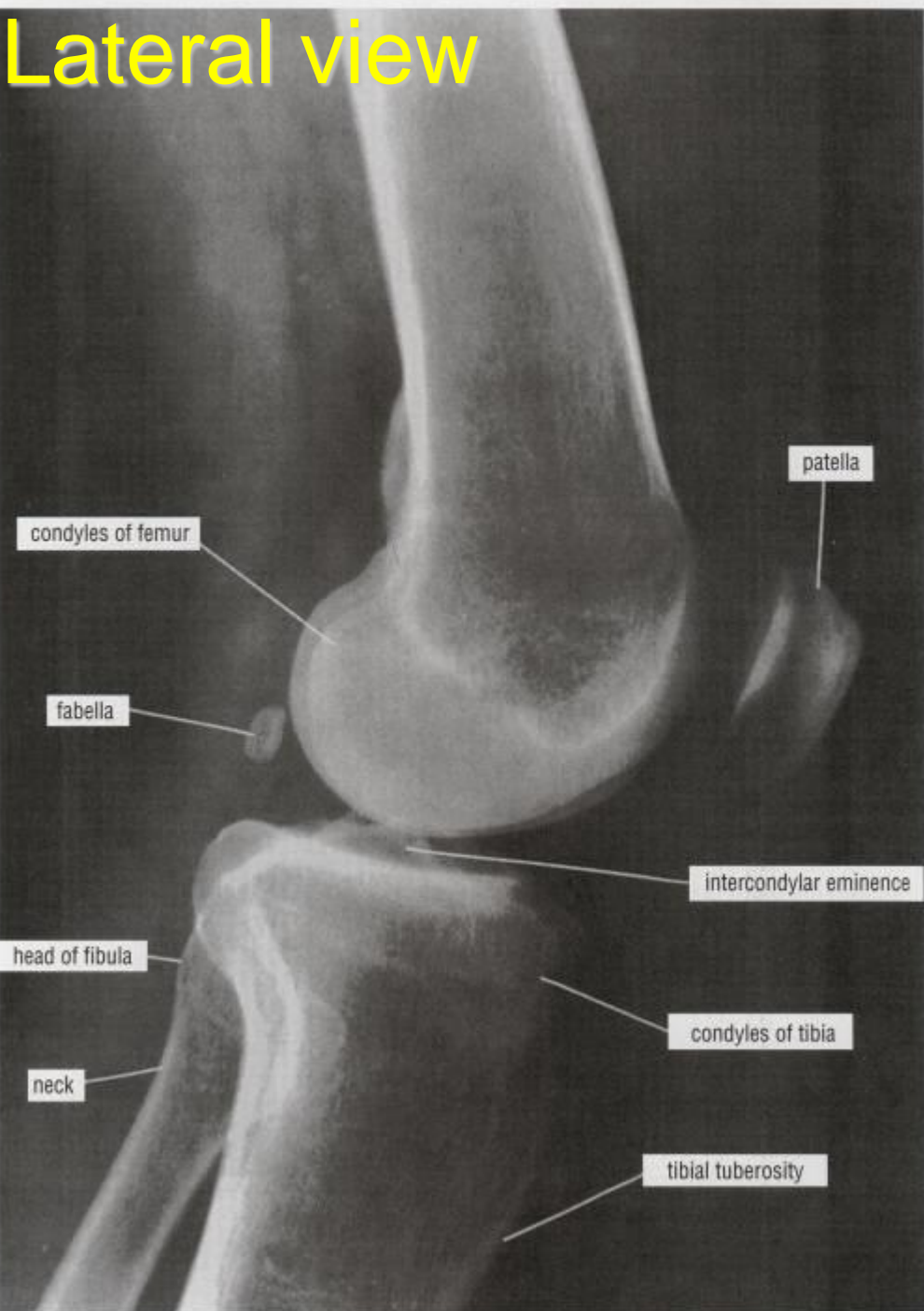Patella (kneecap)

Basis patellae
Apex patellae
Facies articularis
Facies anterior
(*Patellula*)

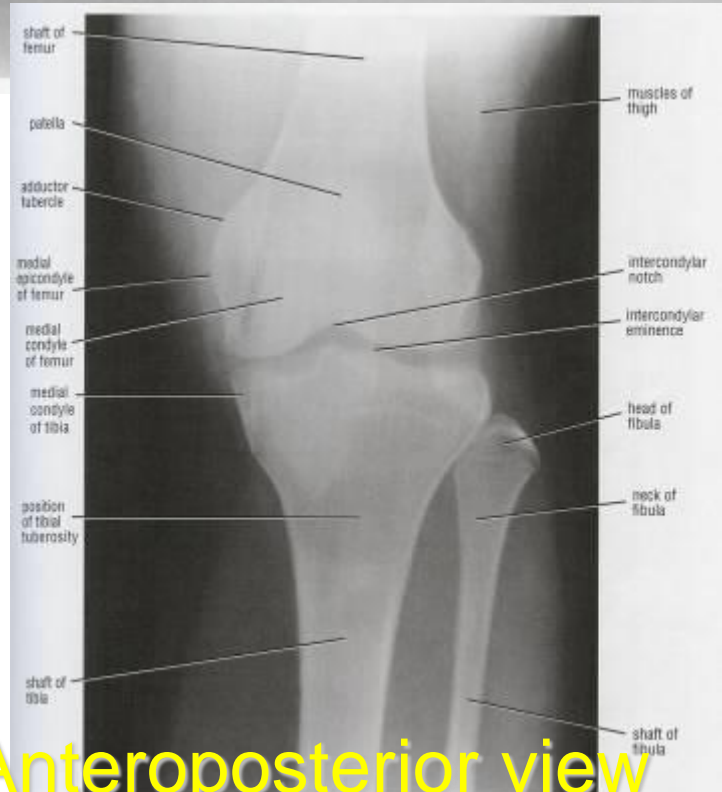

dislocation of the patella occur most often in lateral fractures - transverse, longitudinal, fragmentary (car accidents)

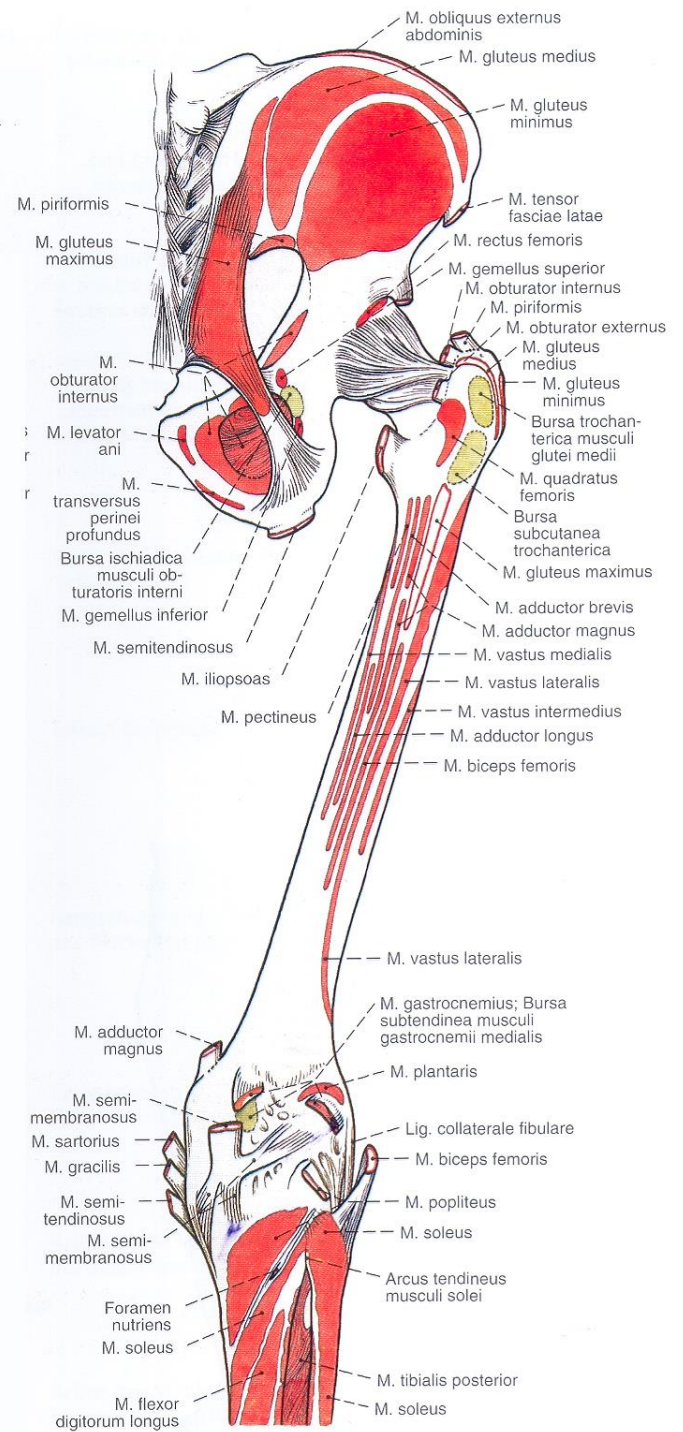
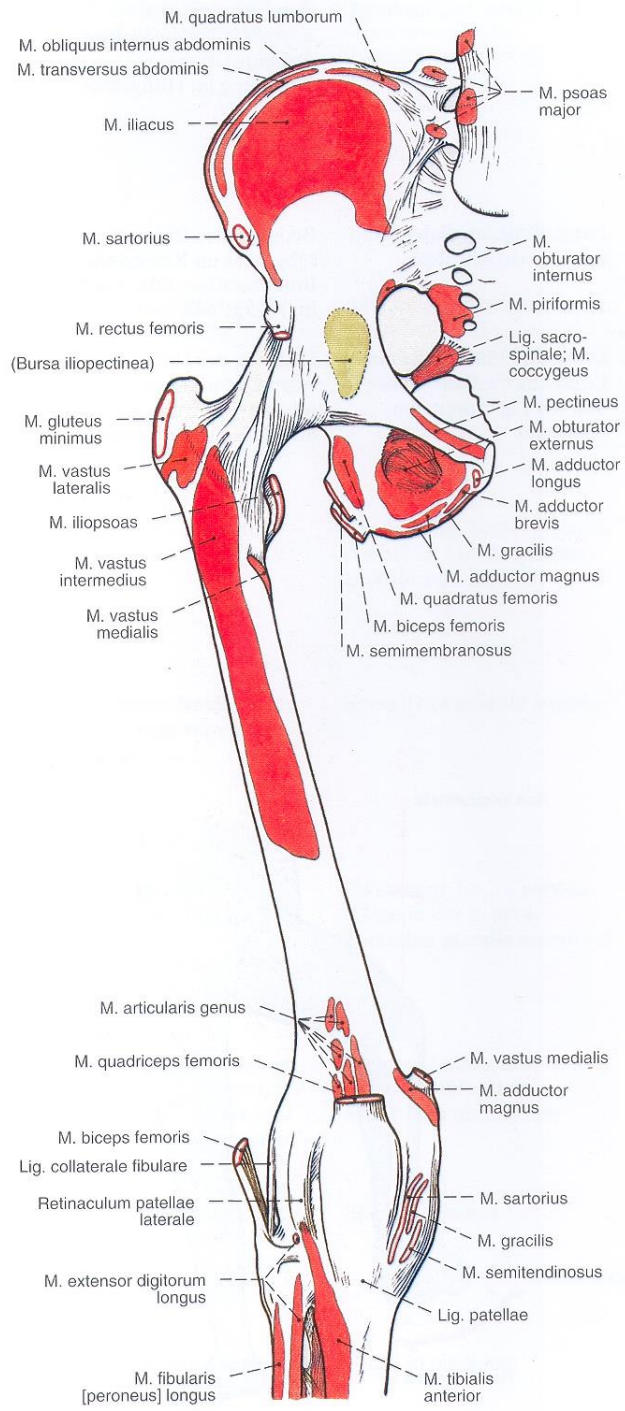
Lateral view



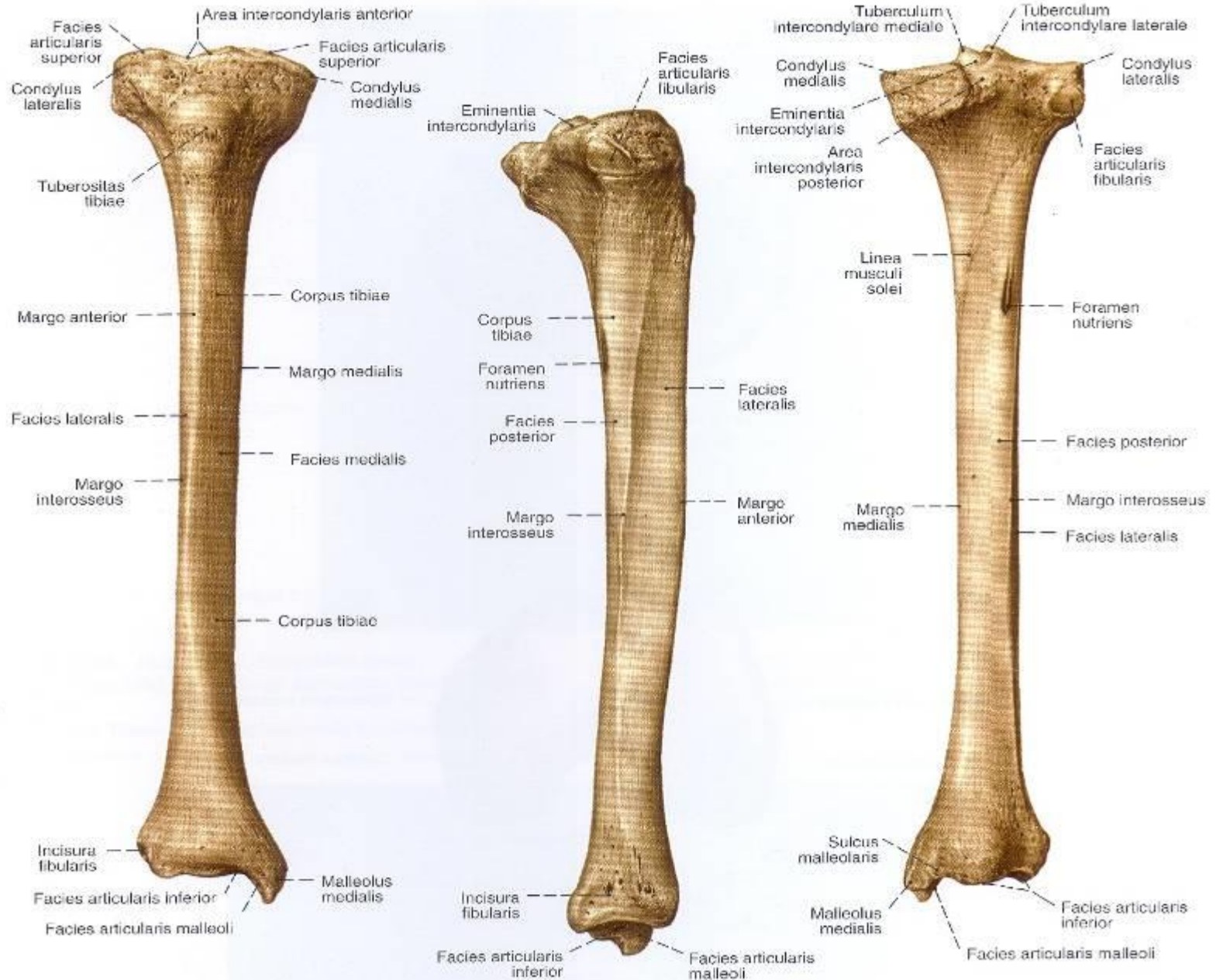
Tangential view



Anteroposterior view

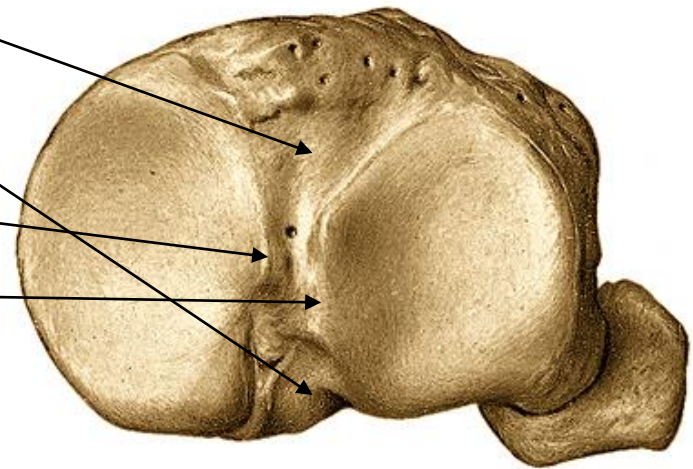


Tibia (Shin bone)

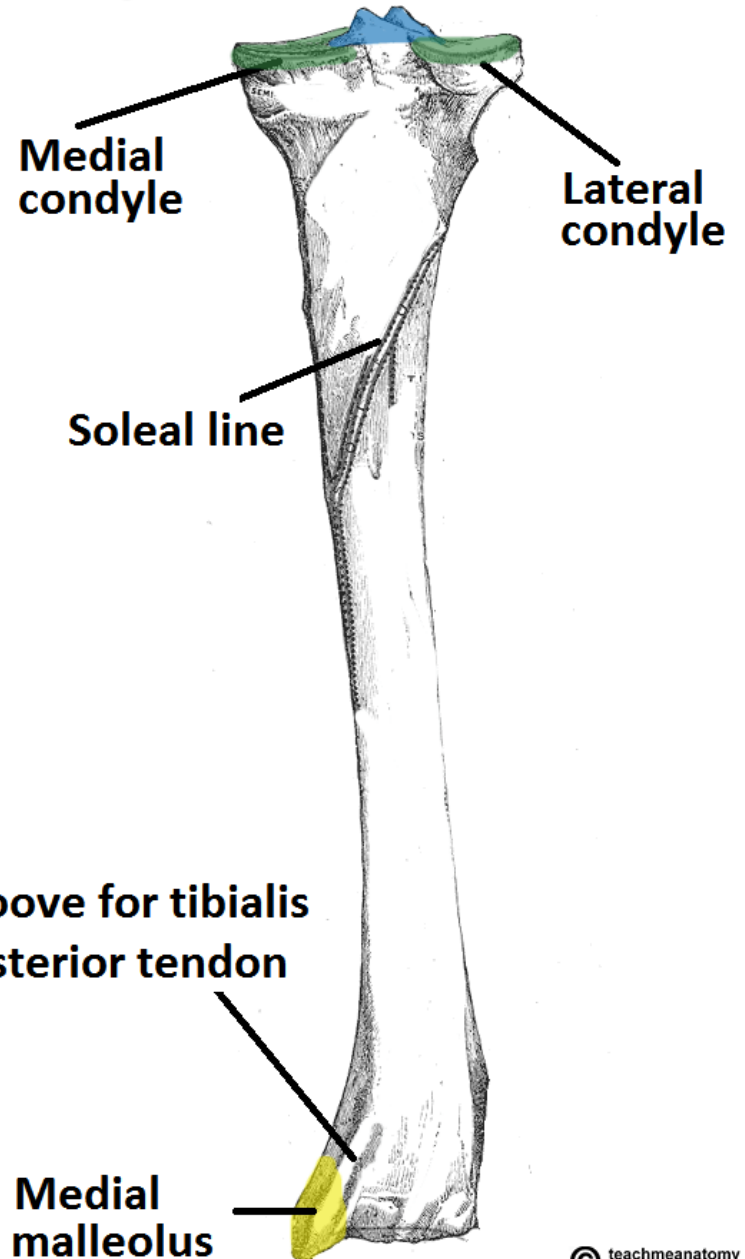
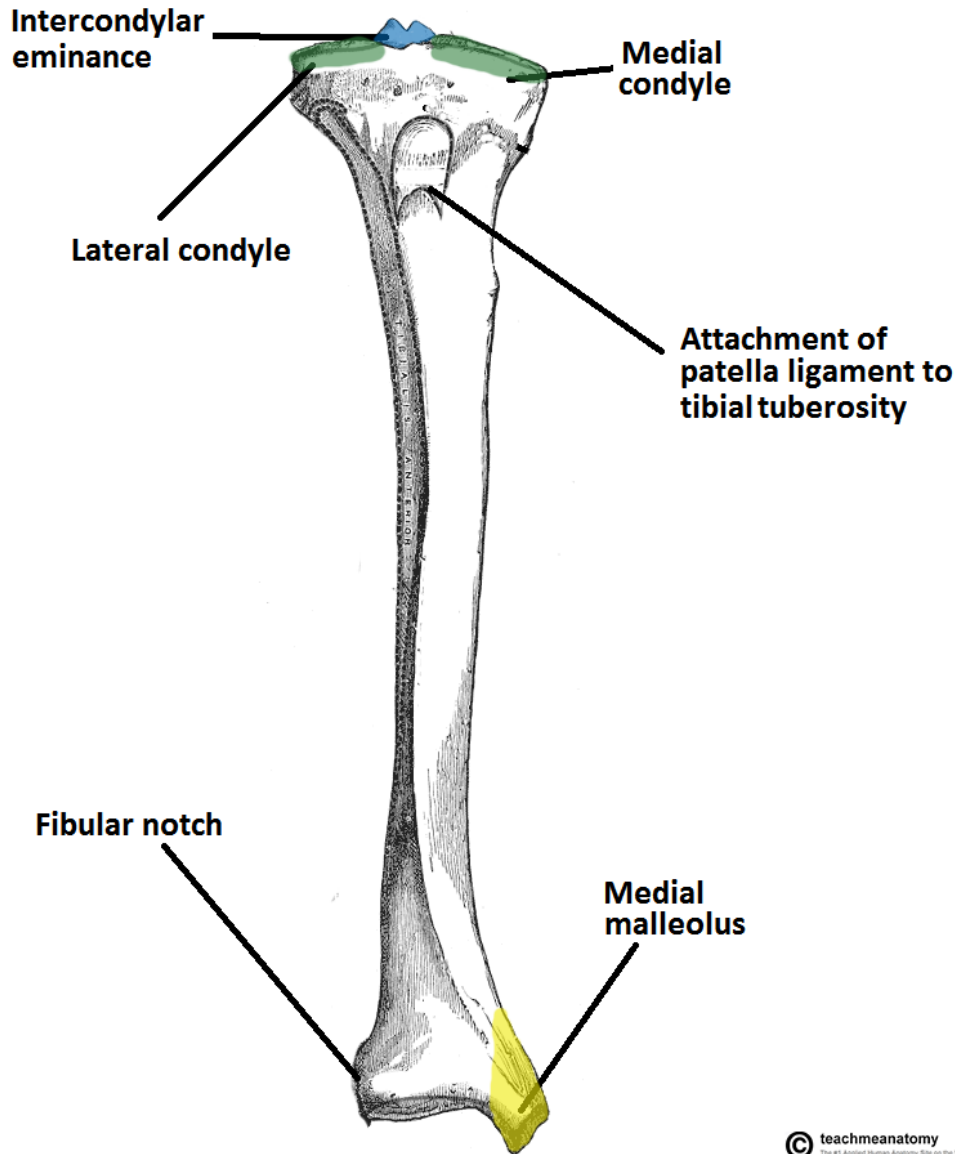


Tibia (Tibia)

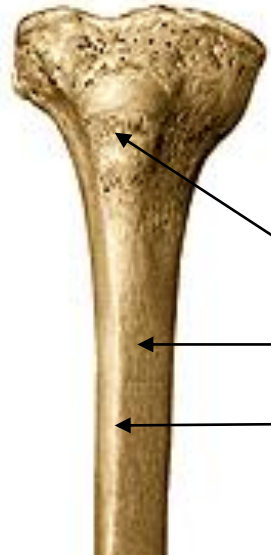- Facies articularis superior
- Condylus medialis
- Condylus lateralis
- Facies articularis fibularis
- Tuberositas tractus iliotibialis *Gerdyi*
- Area intercondylaris anterior
- Area intercondylaris posterior
- Eminentia intercondylaris
- Tuberculum intercondylare mediale
- Tuberculum intercondylare laterale



Tibia (Tibia)




Tibia (Tibia)



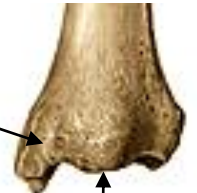- Corpus tibiae
- Tuberositas tibiae
- Facies medialis, posterior, lateralis
- Margo anterior, medialis, intersosseus
- Linea musculi solei / (Flounder muscle line)



- Malleolus medialis / (Inner ankle)
- Facies articularis malleoli medialis
- Sulcus malleolaris tibiae / (Ankle groove)



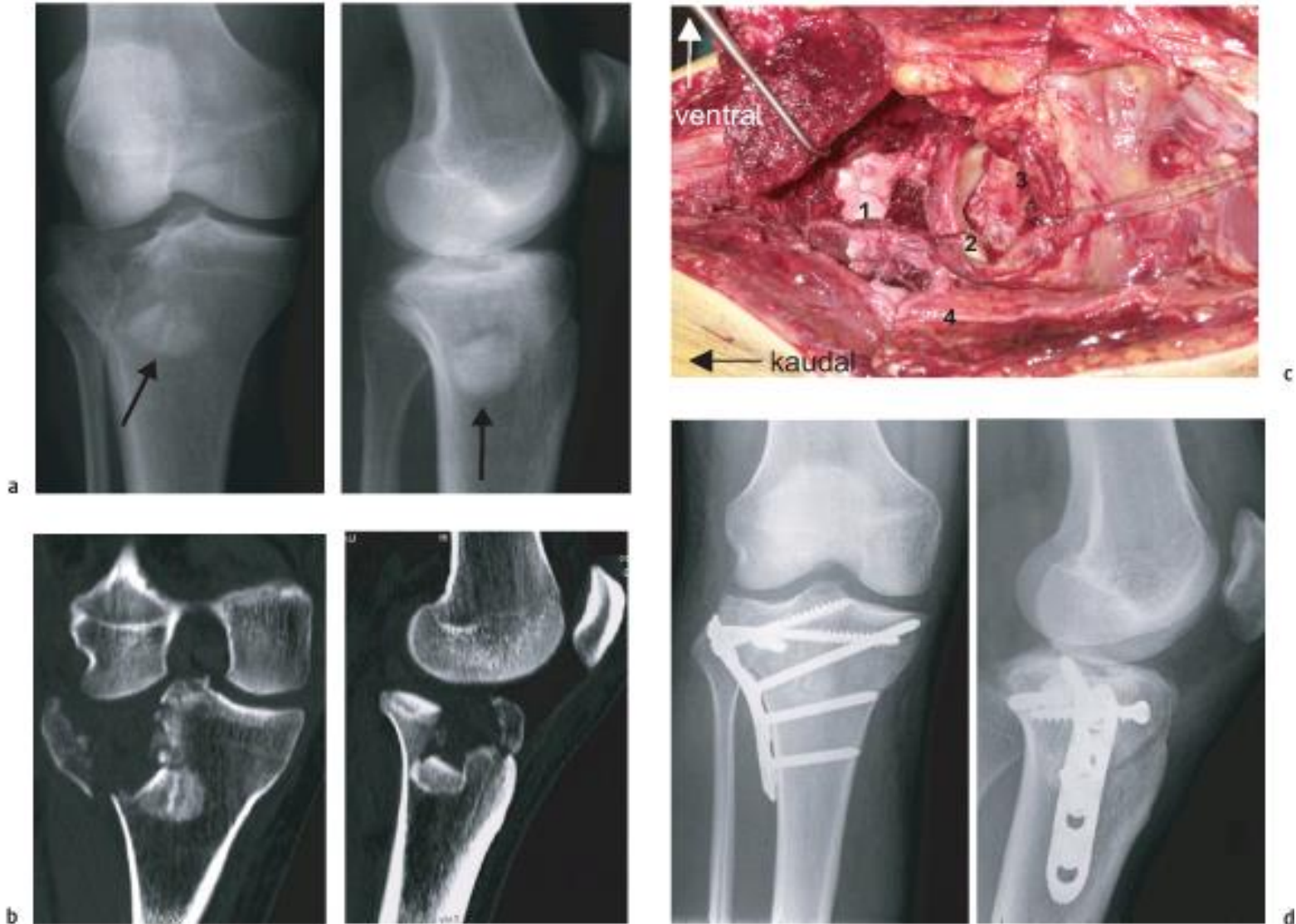- Incisura fibularis
- Facies articularis inferior



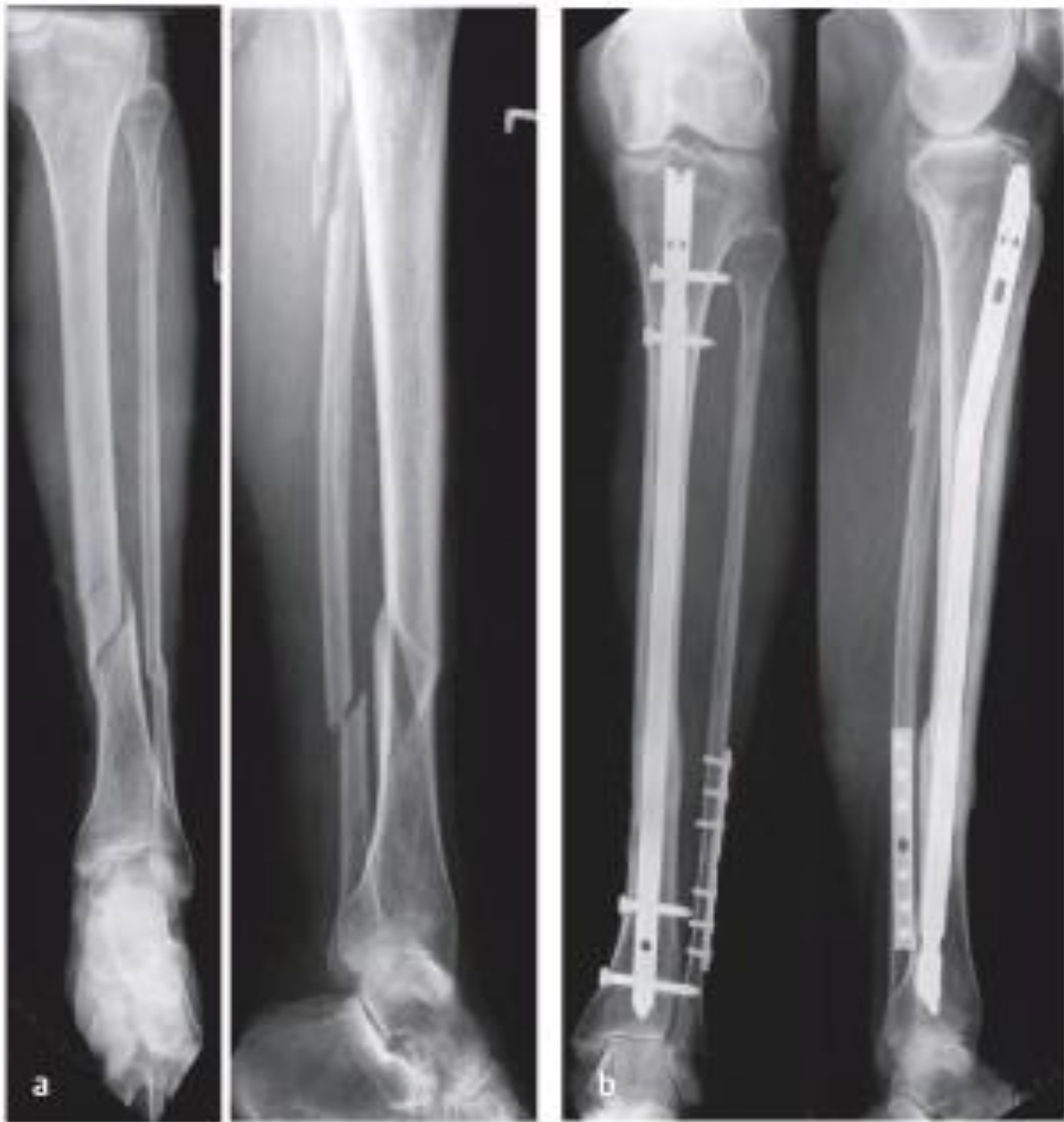Clinical notes

- proximal part (*facies art. superior*) = tibial **plateau**
- distal part= tibial **pilon** (*pylon*)
- in intensive care medicine in cases of inaccessible venous access it is possible to administer an infusion solution 1 cm below the tuberositas tibiae - richly perfused spongiosis (in pediatrics)
- in jumpers, *m. quadriceps femoris* detachment injury
- the surface of the medial tibia is poorly covered by soft tissue- *often consequence in open fracture trauma*
- When both tibia are fractures, its usually in car accidents.
- Pilon fracture occur in fall accidents

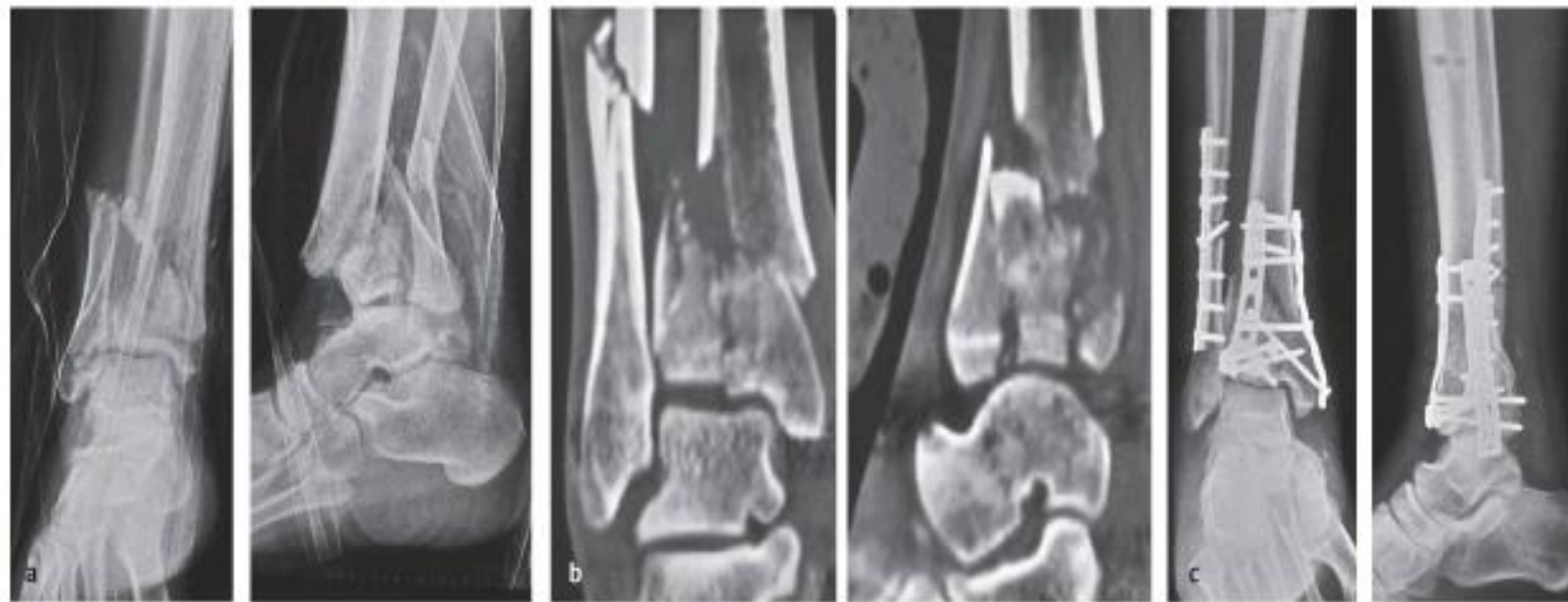
Impressive fracture of the proximal end of the tibia



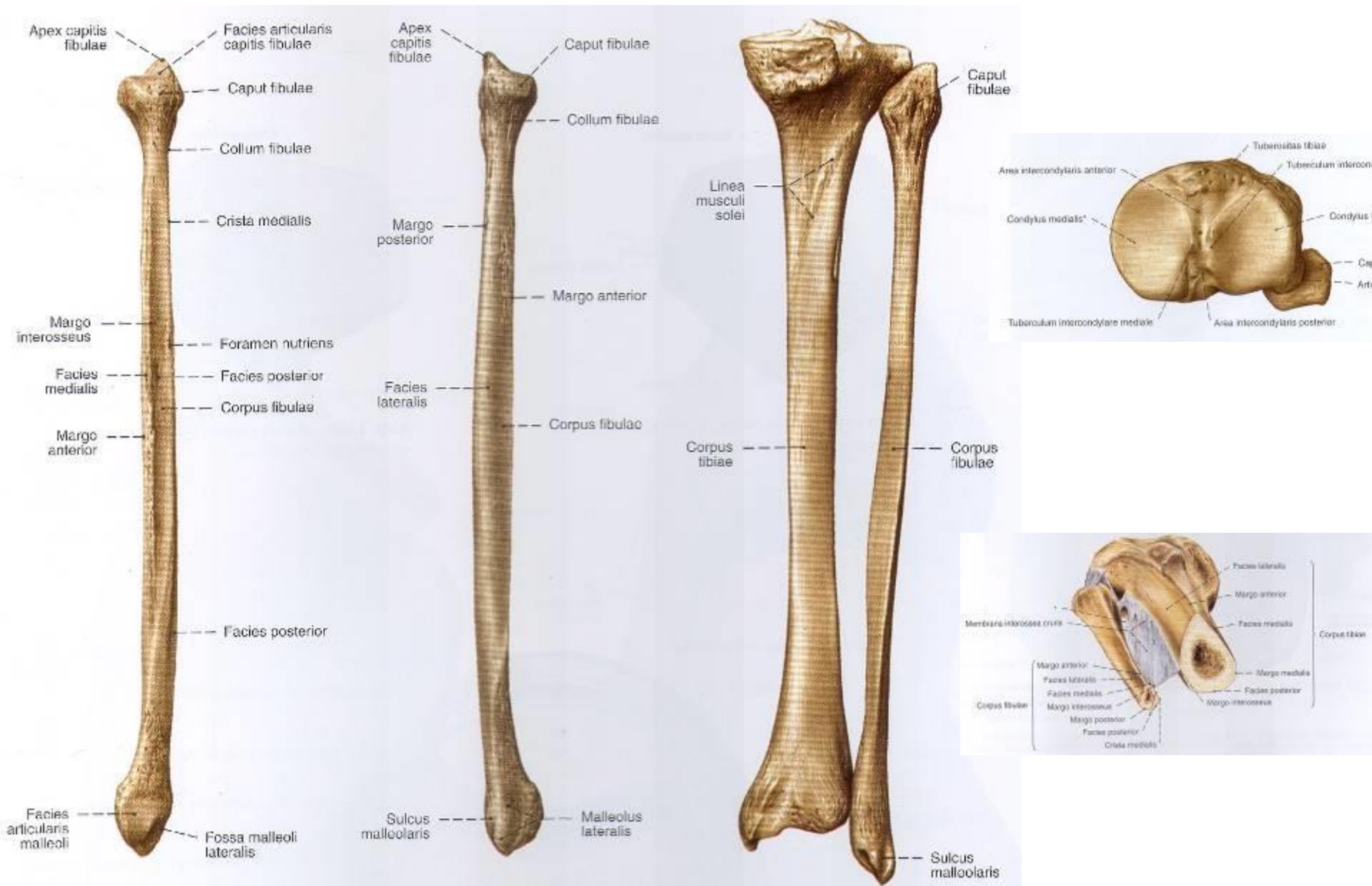
Spiral fracture of the lower leg, intramedullary nail



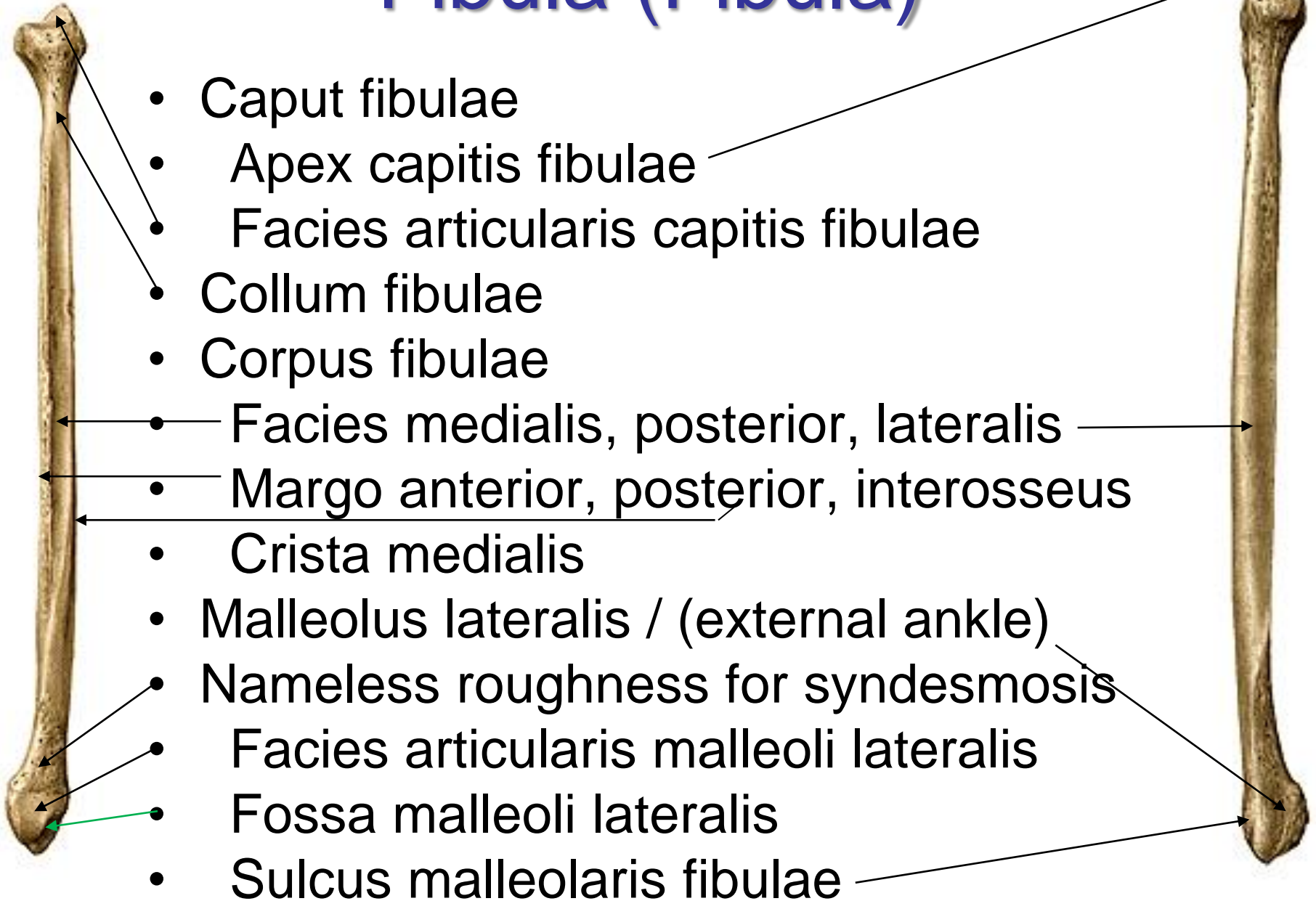
pilon shattered fracture



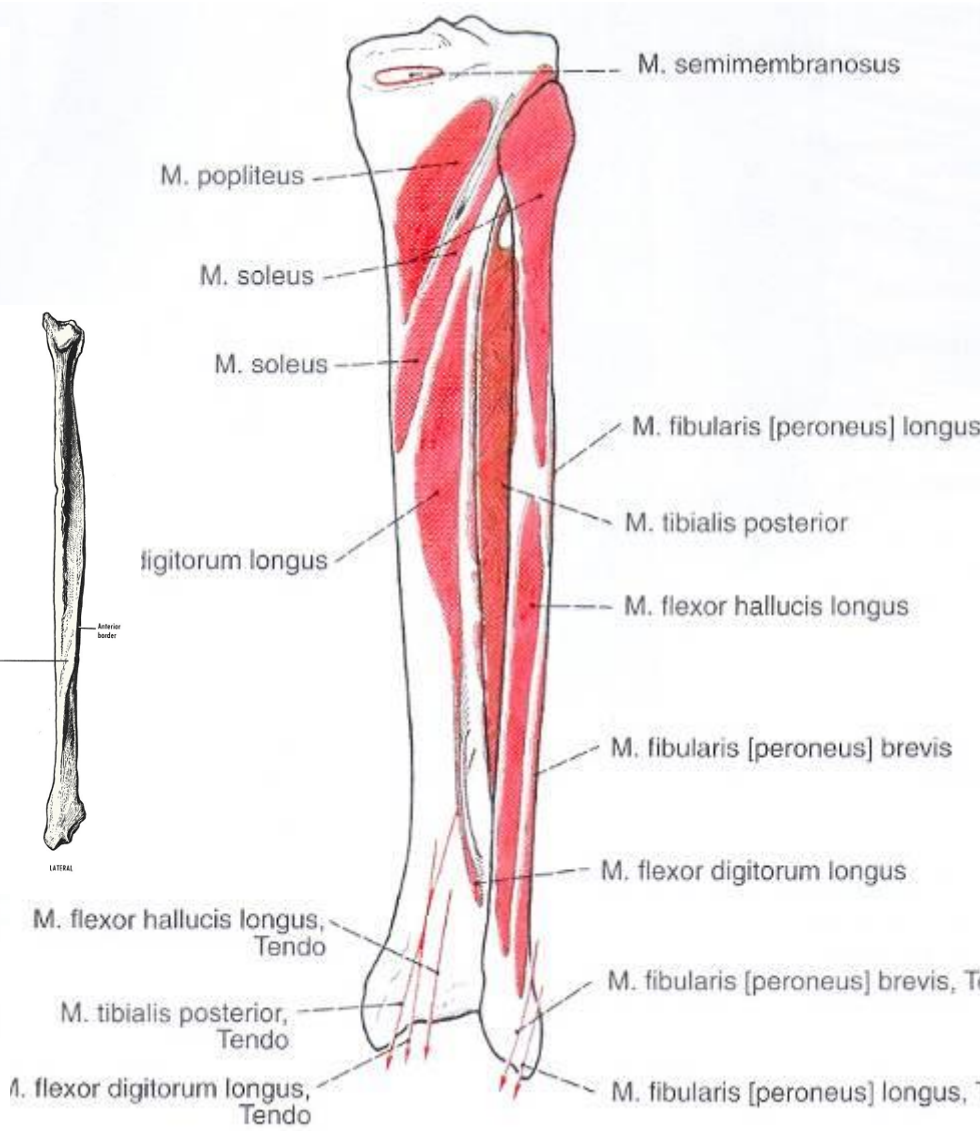
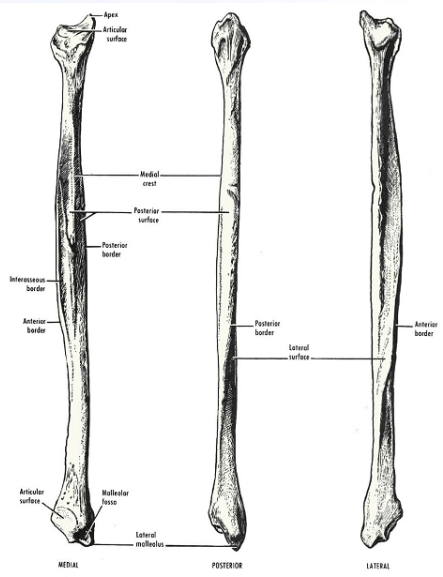
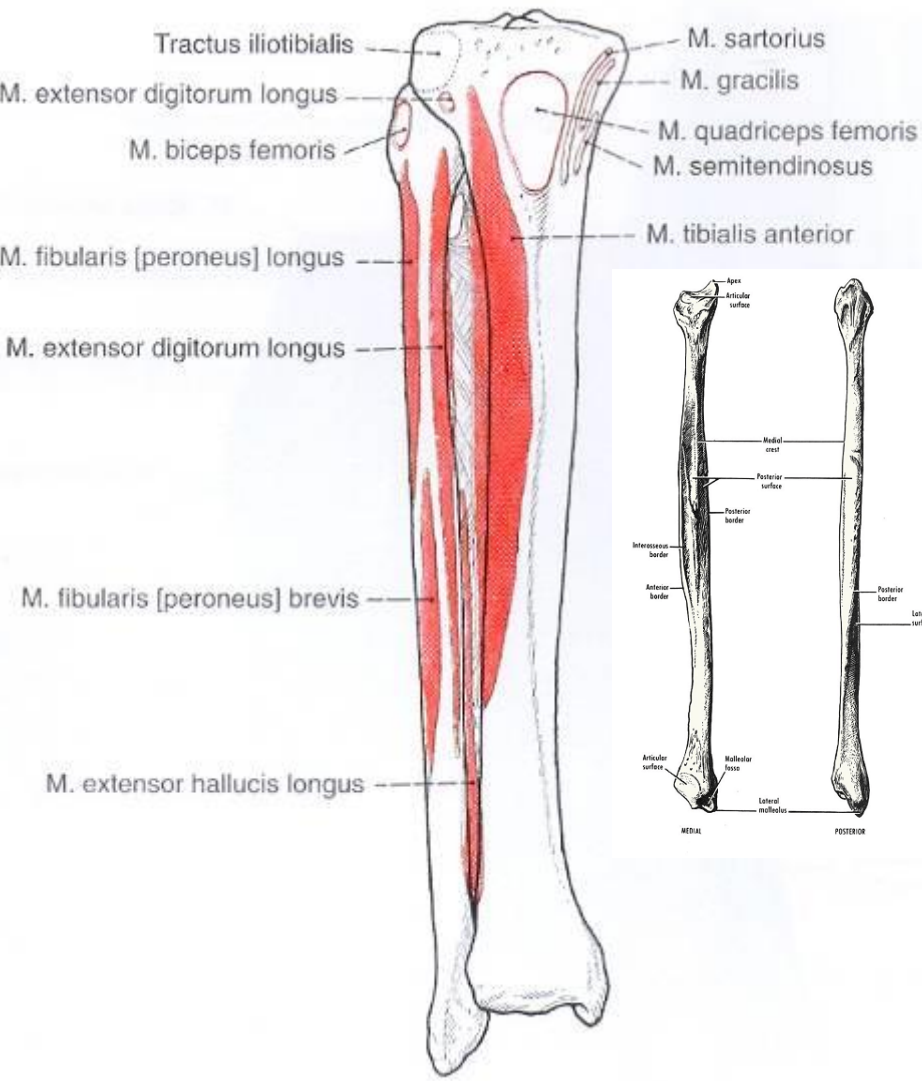
Fibula (calf bone)



Fibula (Fibula)



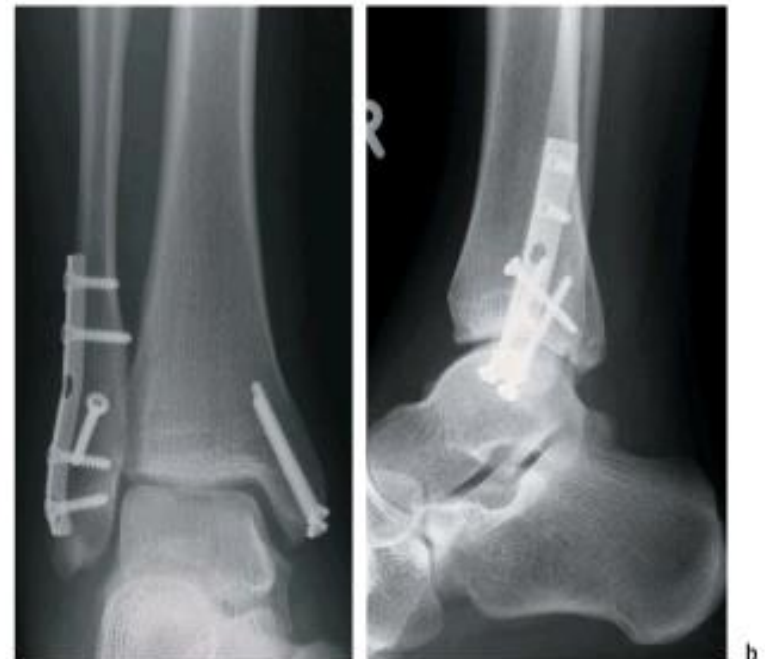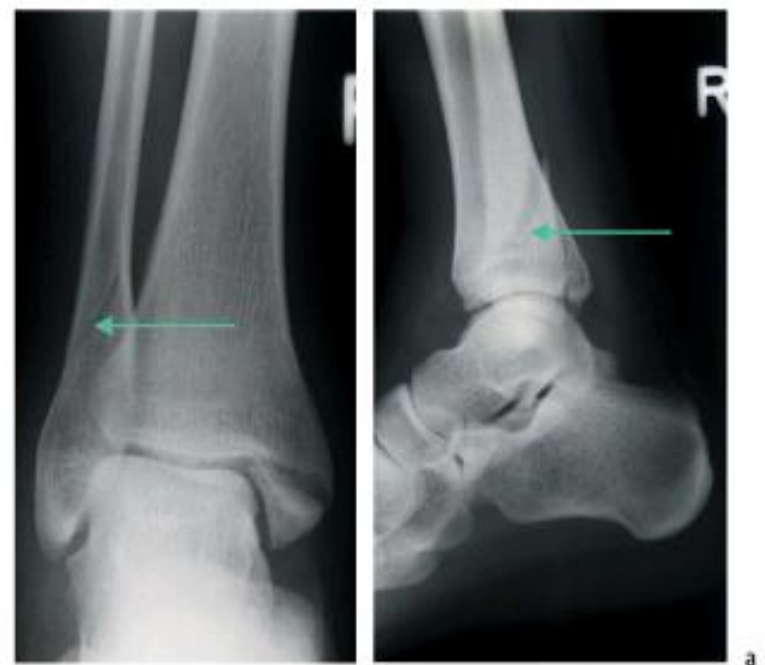- Caput fibulae
- Apex capitis fibulae
- Facies articularis capitis fibulae
- Collum fibulae
- Corpus fibulae
- Facies medialis, posterior, lateralis
- Margo anterior, posterior, interosseus
- Crista medialis
- Malleolus lateralis / (external ankle)
- Nameless roughness for syndesmosis
- Facies articularis malleoli lateralis
- Fossa malleoli lateralis
- Sulcus malleolaris fibulae



Clinical notes

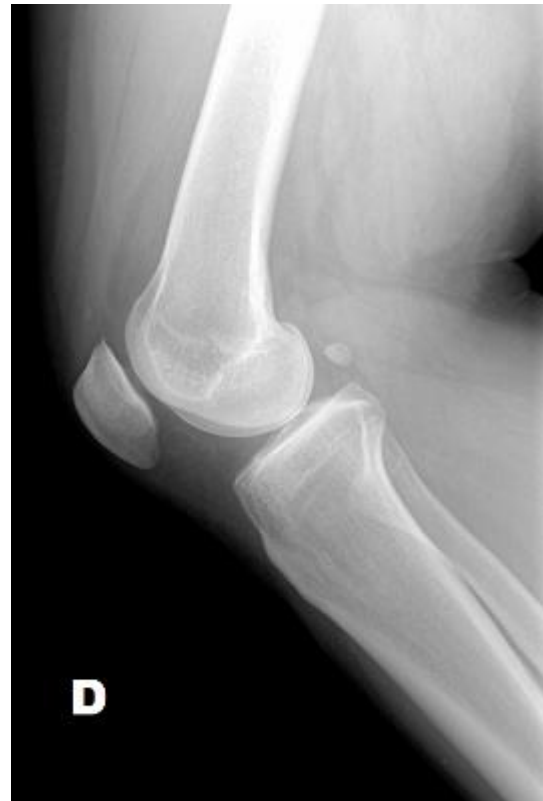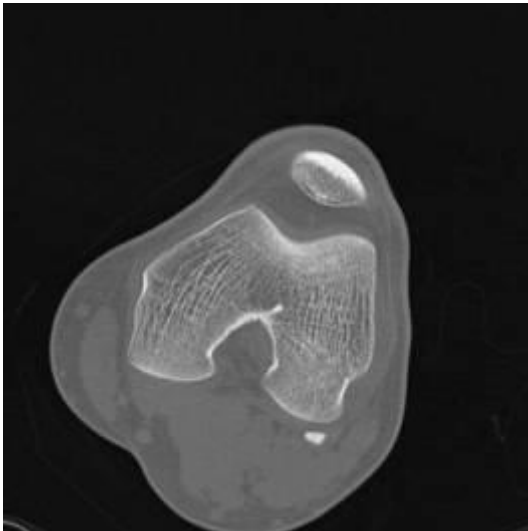
- ***nervus fibularis communis*** runs around the head of fibula → compression injury in tightly applied cast
- in case of a tibial fracture, it is always necessary to screen any fibula fracture on the X-ray!
- the whole fibula - proximal to distal - must be visible on the x-ray
- *Fibula has no load-bearing function*
- *the middle third of the fibula can be used in bone tissue craft*

Fracture of both sides of the ankle (bimalleolar fracture)

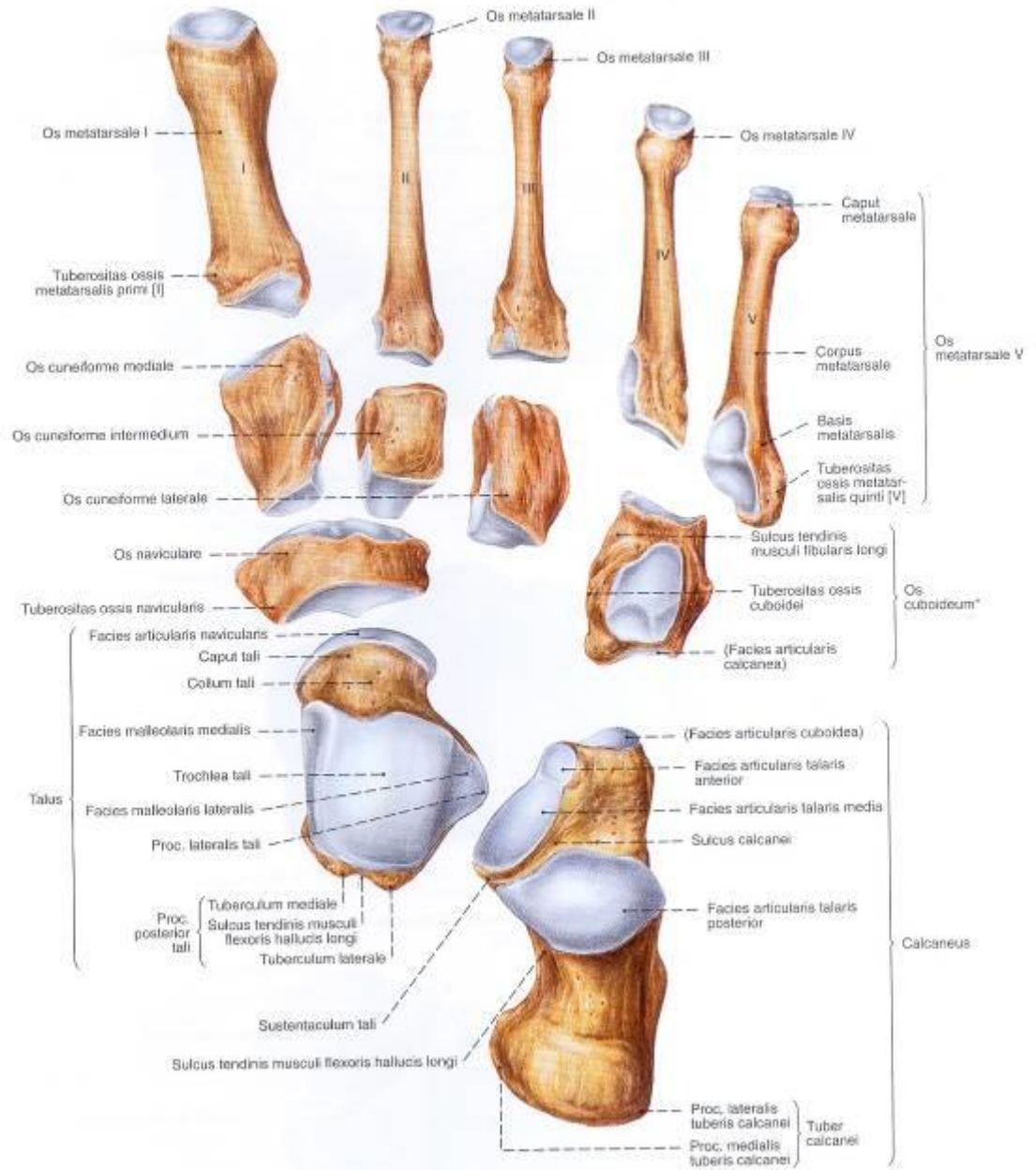
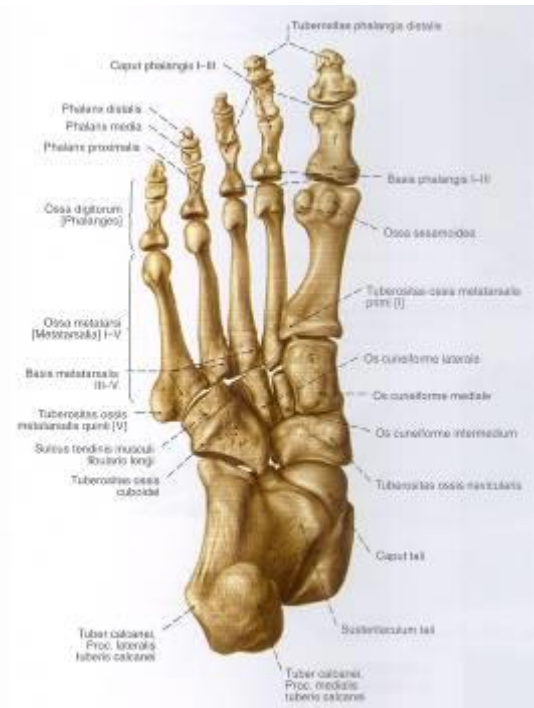
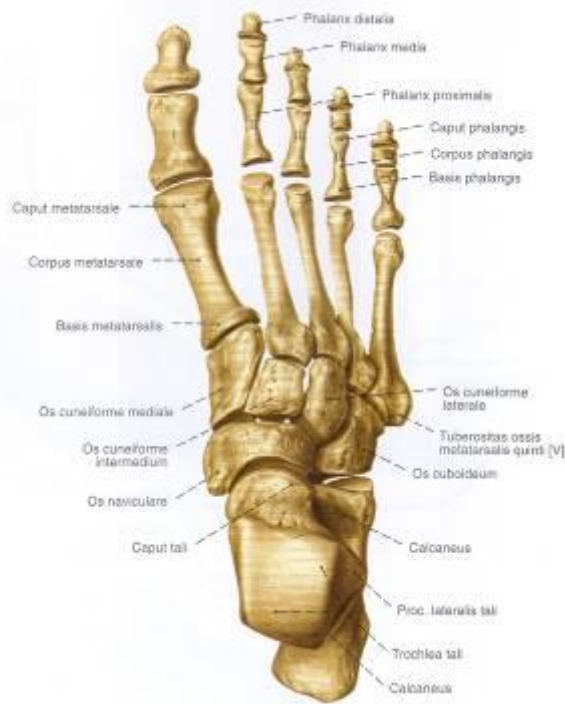
Fabella

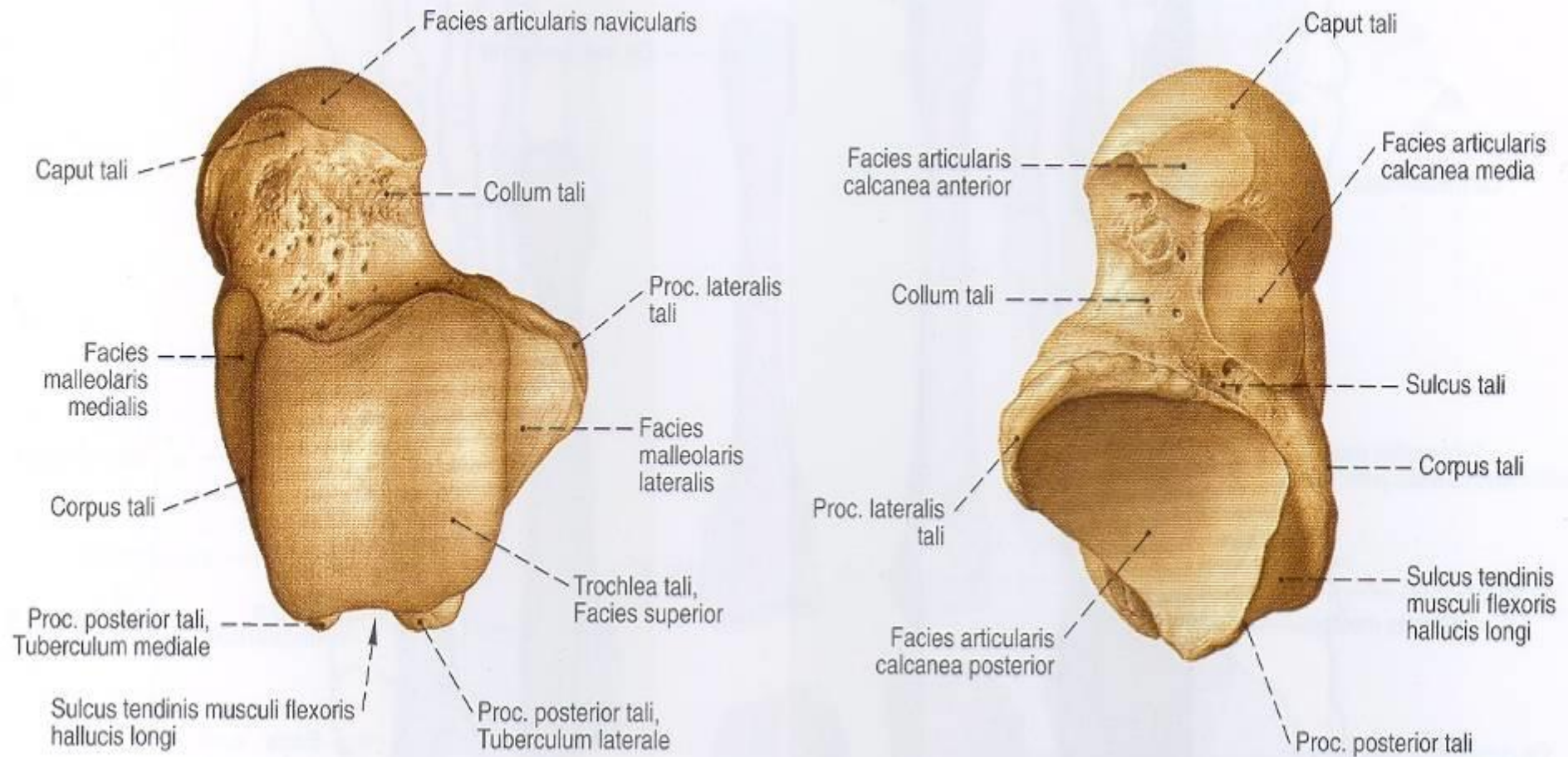
- *os sesamoideum musculi gastrocnemii*
- incidence 10-20 %



Ossa pedis (tarsal bones)

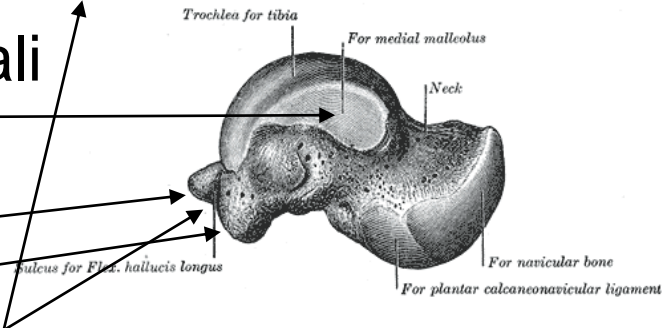
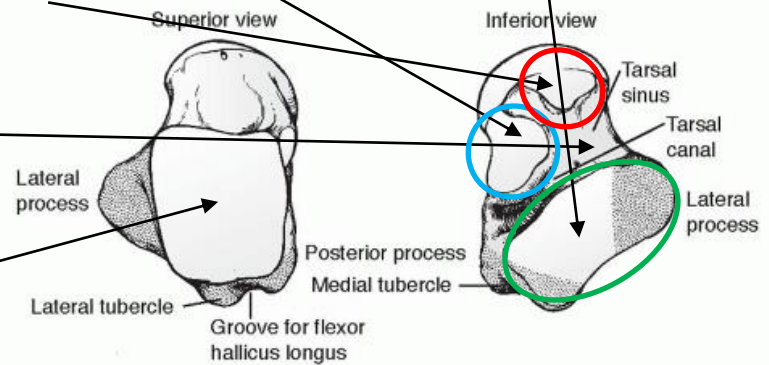
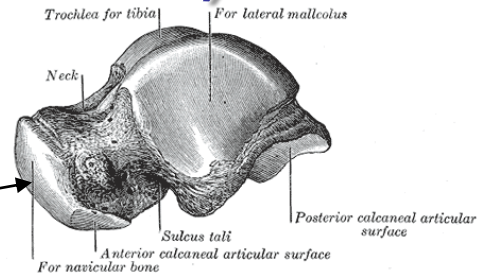


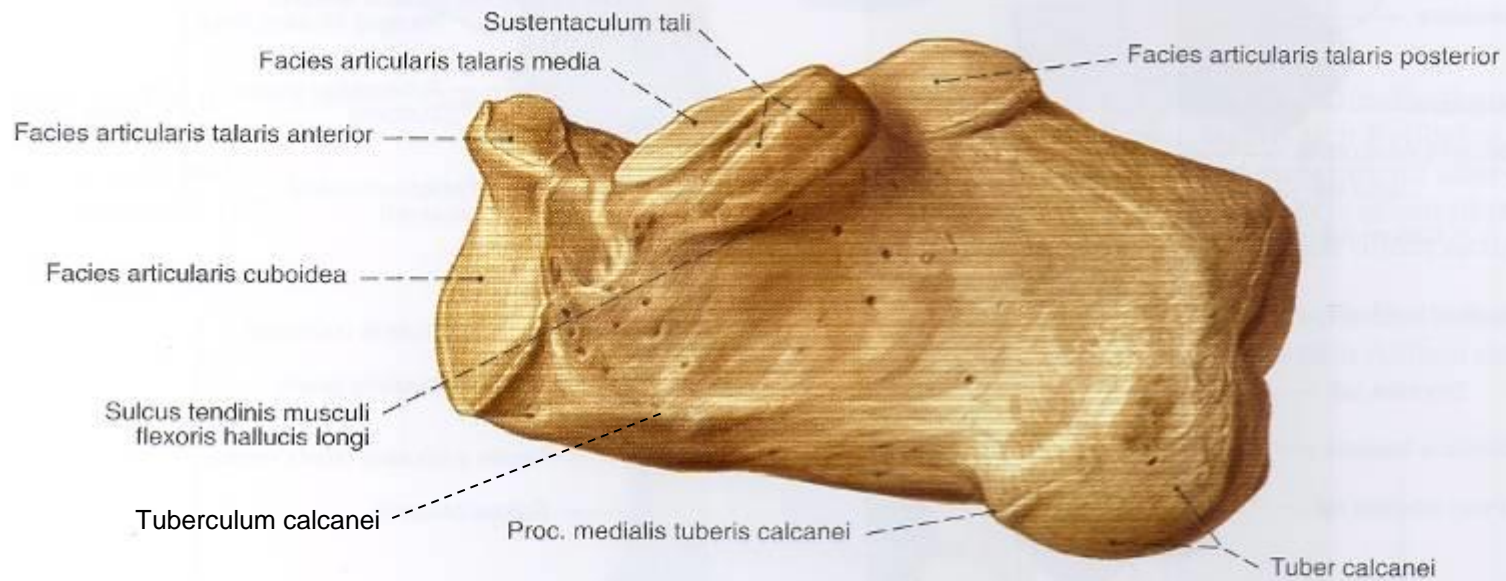
Talus (ankle bone)



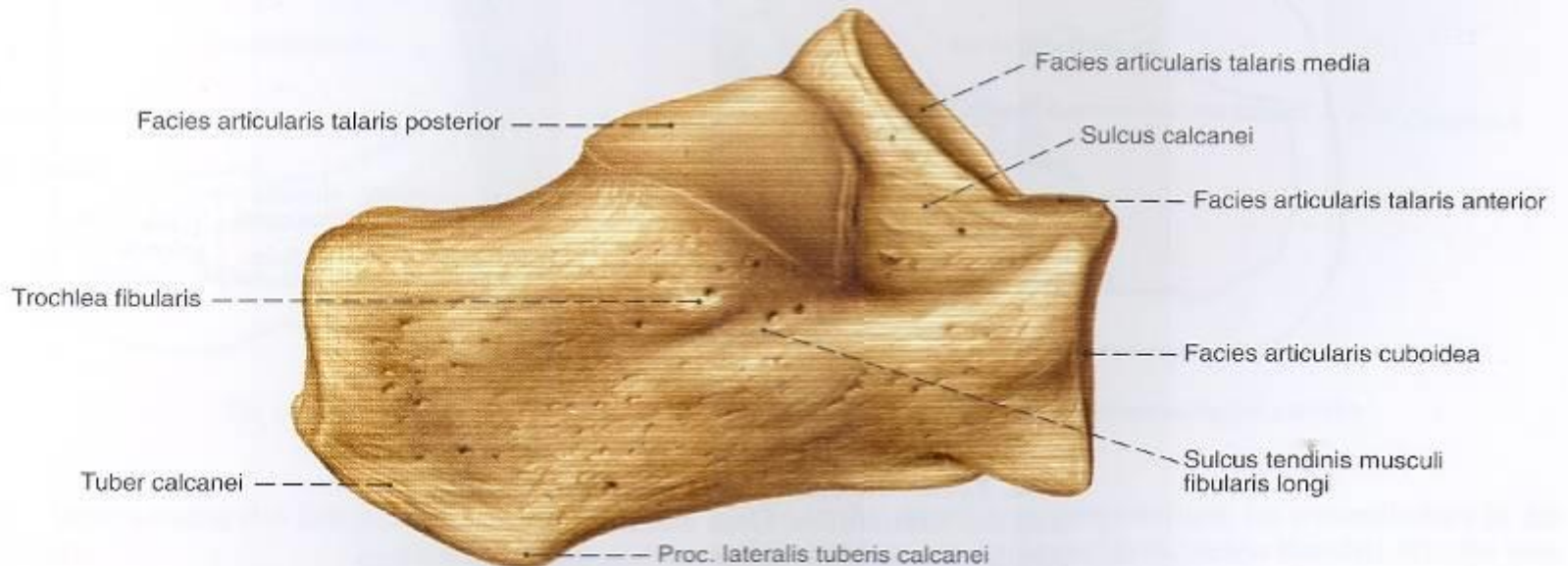
Talus (Talus; Astragalus)

- Caput tali
- Facies articularis navicularis
- Facies articularis calcanea **anterior**, **media**, **posterior**
- Collum tali
- Sulcus tali
- Corpus tali
- Trochlea tali
- Facies superior tali
- Facies malleolaris lateralis, medialis tali
- Processus lateralis tali
- Processus posterior tali
- Tuberculum laterale, mediale
- Sulcus tendinis musculi flexoris hallucis longi tali



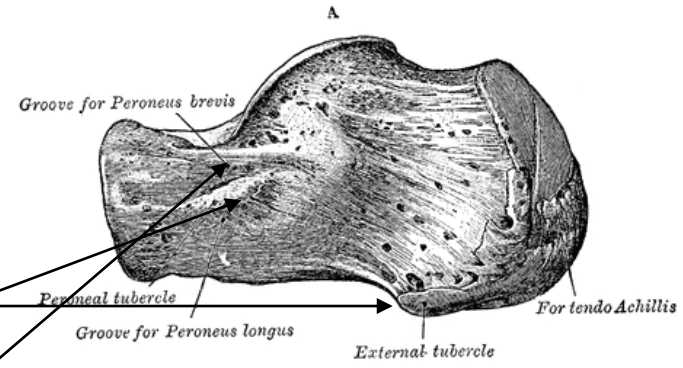


Calcaneus (heel bone)

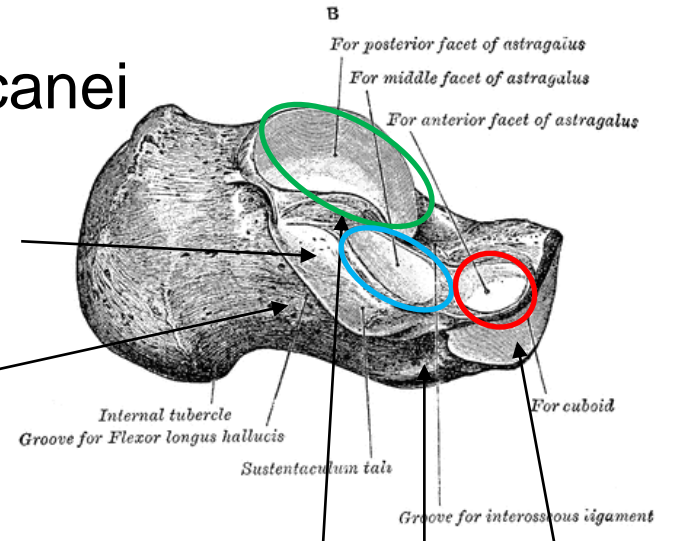


Calcaneus (Calcaneus)

- Tuber calcanei
- Processus medialis, lateralis tuberis calcanei
- Trochlea fibularis
- Sulcus tendinis m. fibularis longi calcanei



- Sustentaculum tali / (ankle support)
- Sulcus tendinis musculi flexoris hallucis longi calcanei



- Sulcus calcanei
- Sinus tarsi
- Tuberculum calcanei
- Facies articularis talaris anterior, media, posterior
- (Tuberculum ligamenti calcaneofibularis) - variable
- Facies articularis cuboidea

Clinical notes

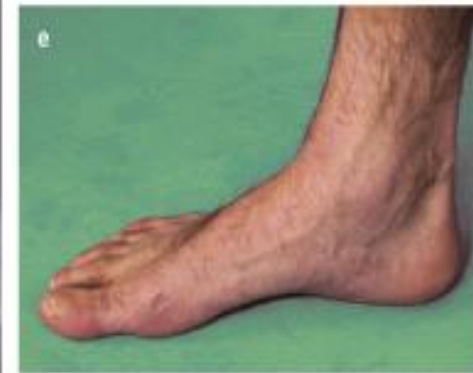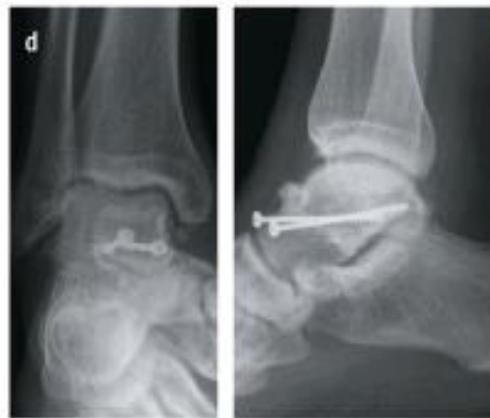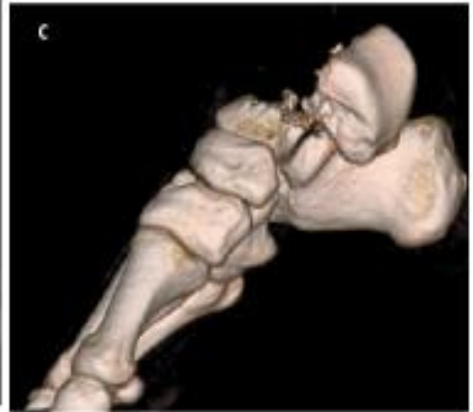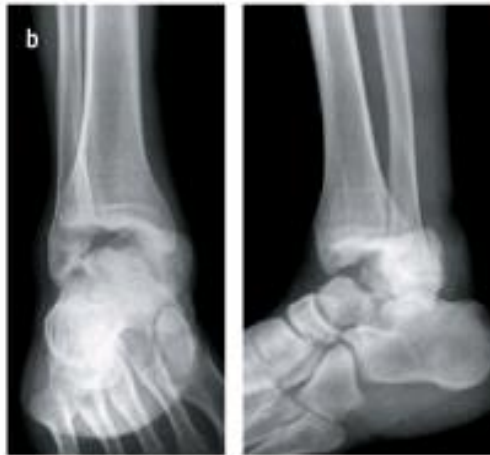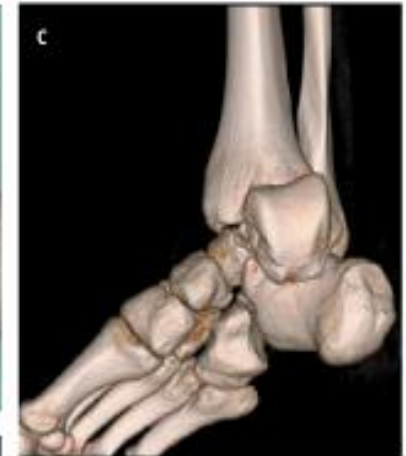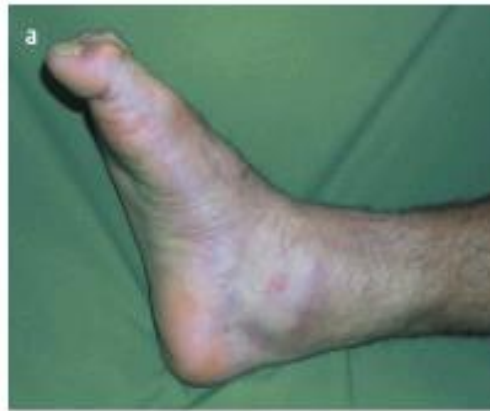TALUS

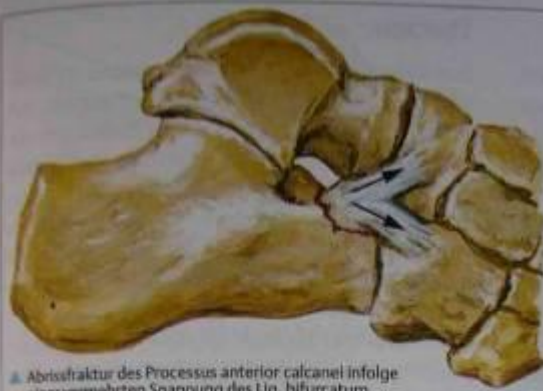- Structural adaptation to bear the weight of the whole body
- 3/5th covered by cartilage - blood vessels enter outside the cartilage – very vulnerable supply
- isolated fractures of the talus are not common

CALCANEUS

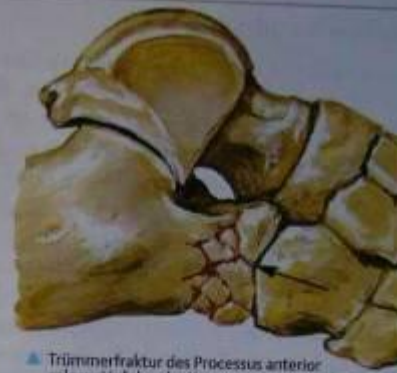- Common pathological fractures
- the most common injuries are in the event of an impact from a height or car accidents, (underneath explosion)

Ankle fracture dislocation

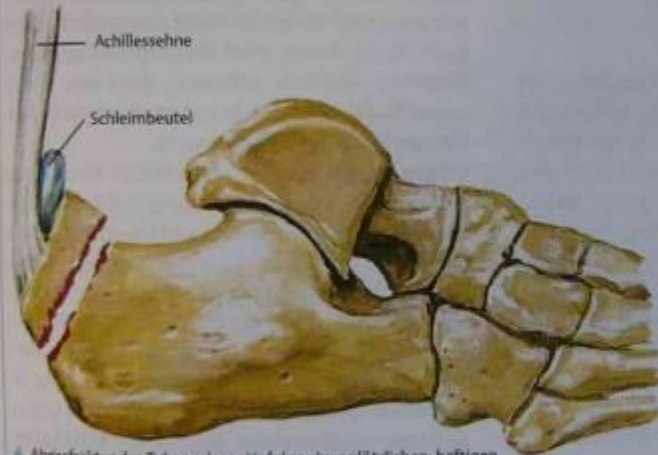



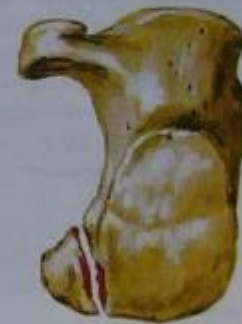▲ Avulsionsfraktur des Processus anterior calcanei infolge einer vermehrten Spannung des Lig. bifurcatum



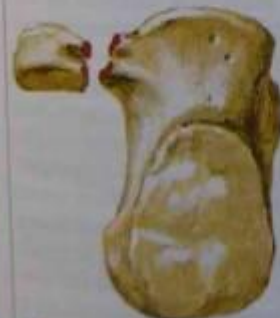▲ Trümmerfraktur des Processus anterior calcanei infolge der Kompression durch das Küboid bei gewaltsamer Abduktion des Vorfußes



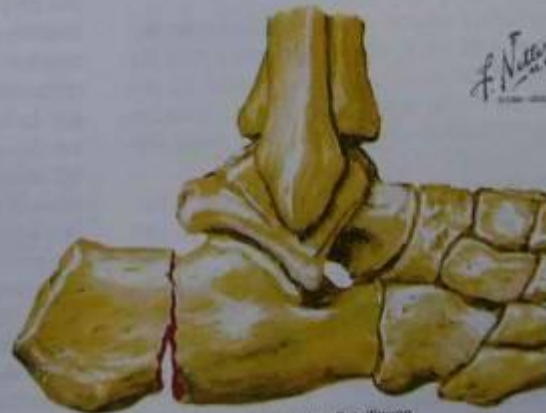▲ Avulsionsfraktur des Tuber calcanei infolge einer plötzlichen, heftigen Kontraktion der Achillessehne („Entenschnabelfraktur“)



▲ Fraktur des Processus medialis des Tuber calcanei



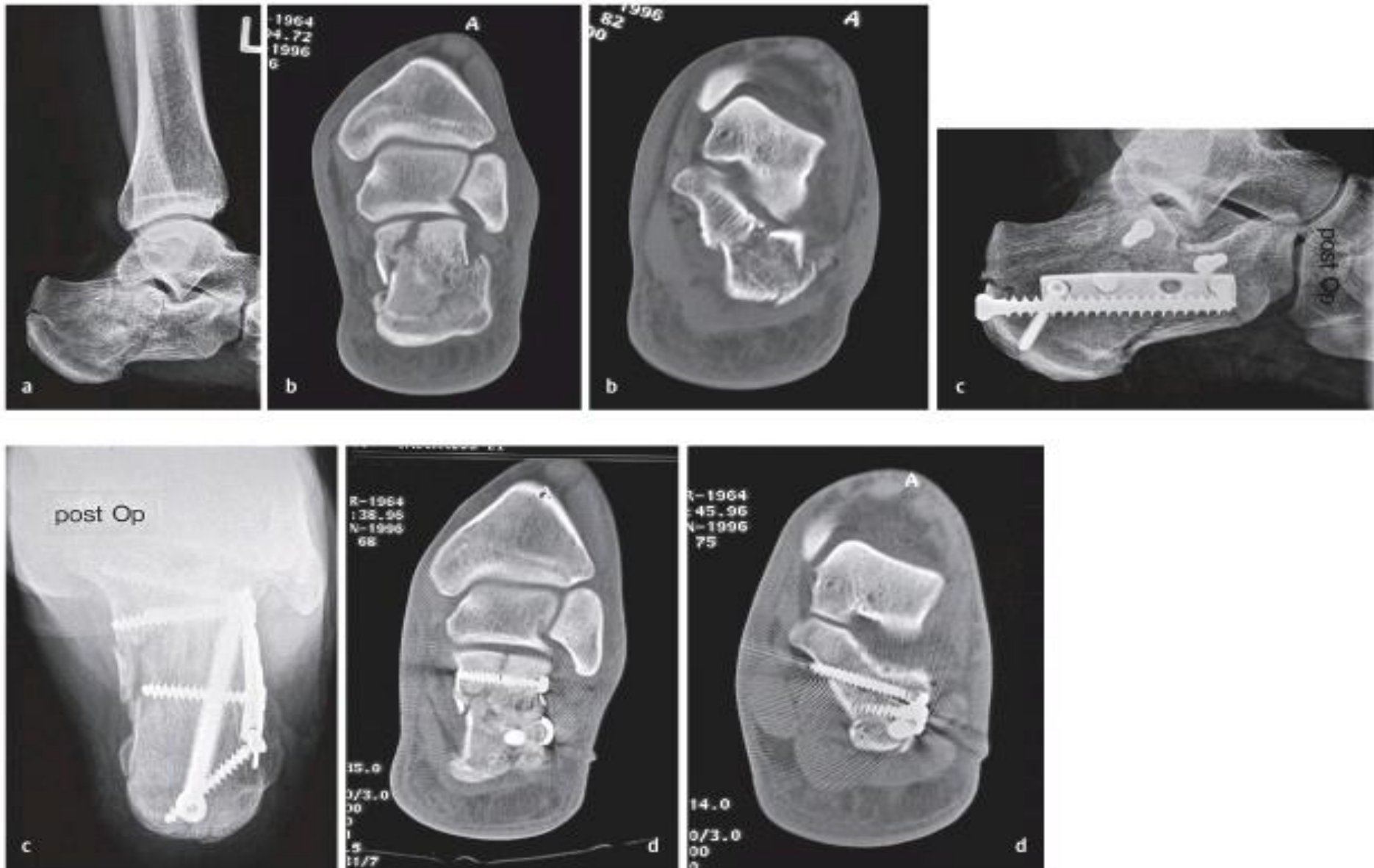
▲ Fraktur des Sustentaculum tali



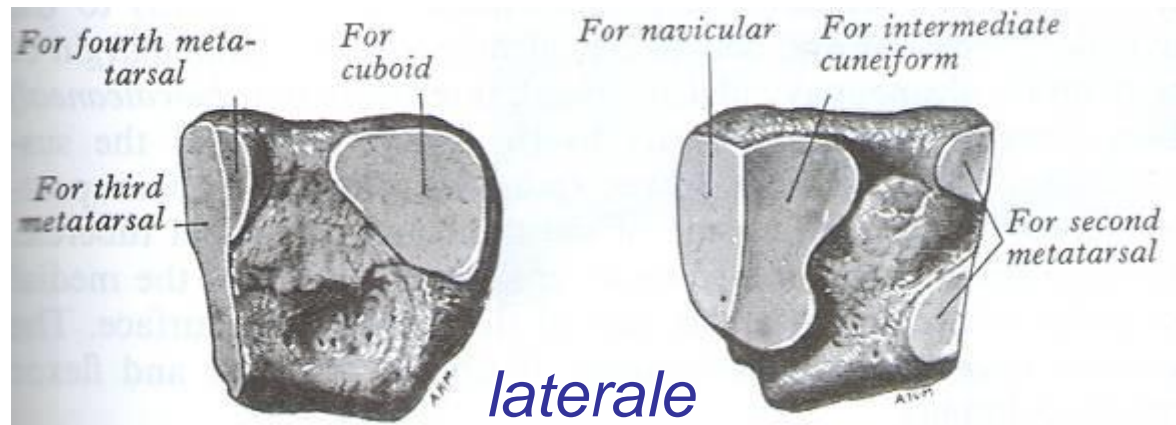
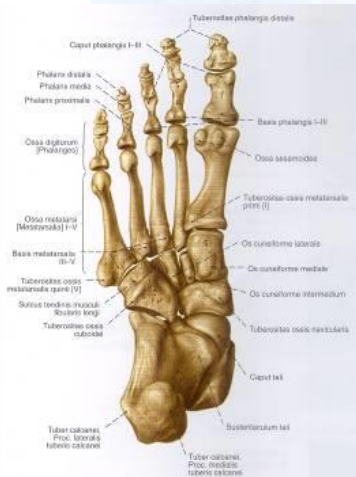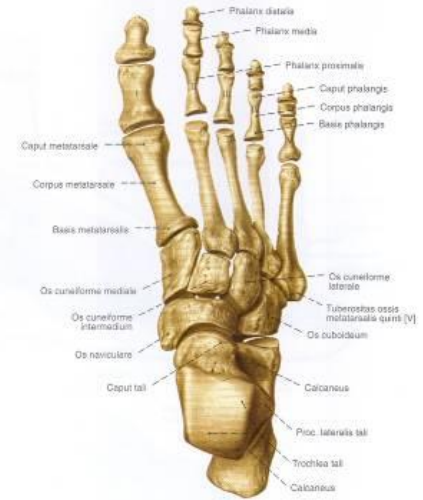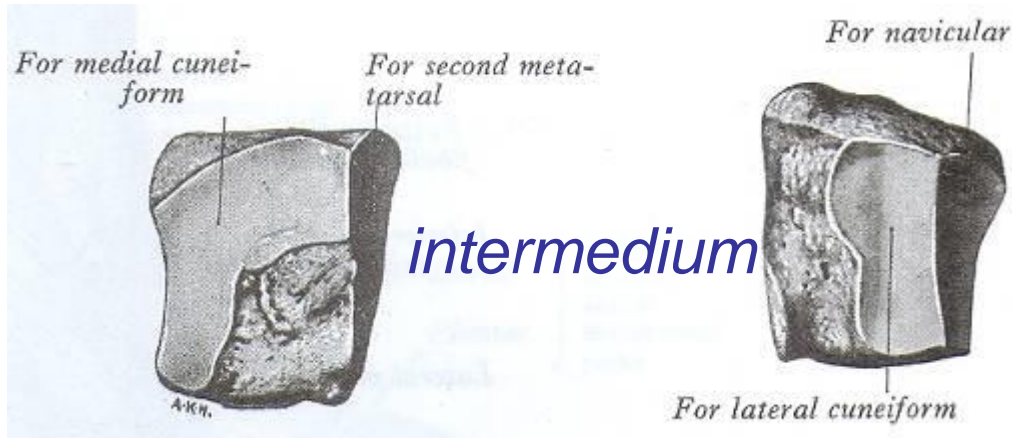
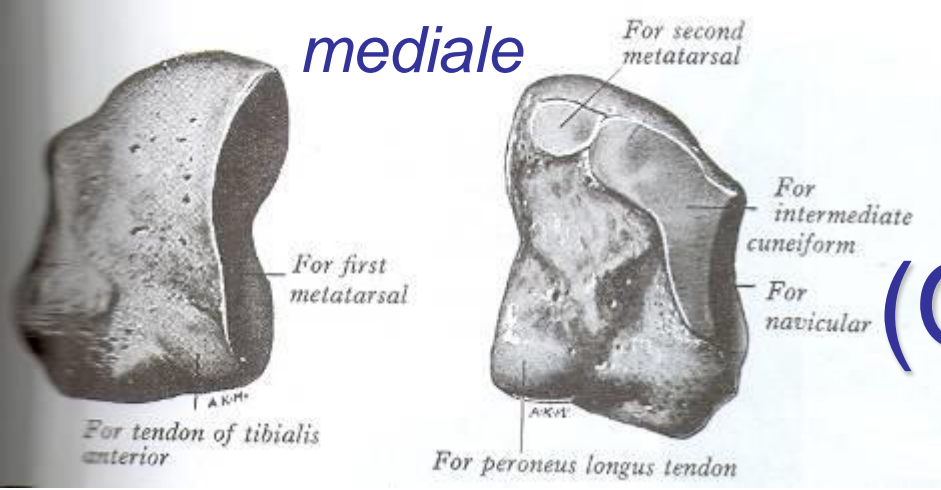
▲ Fraktur des Corpus calcanei ohne Beteiligung des Subtalargelenks

F. Netter
M.D.

Calcaneus fractures

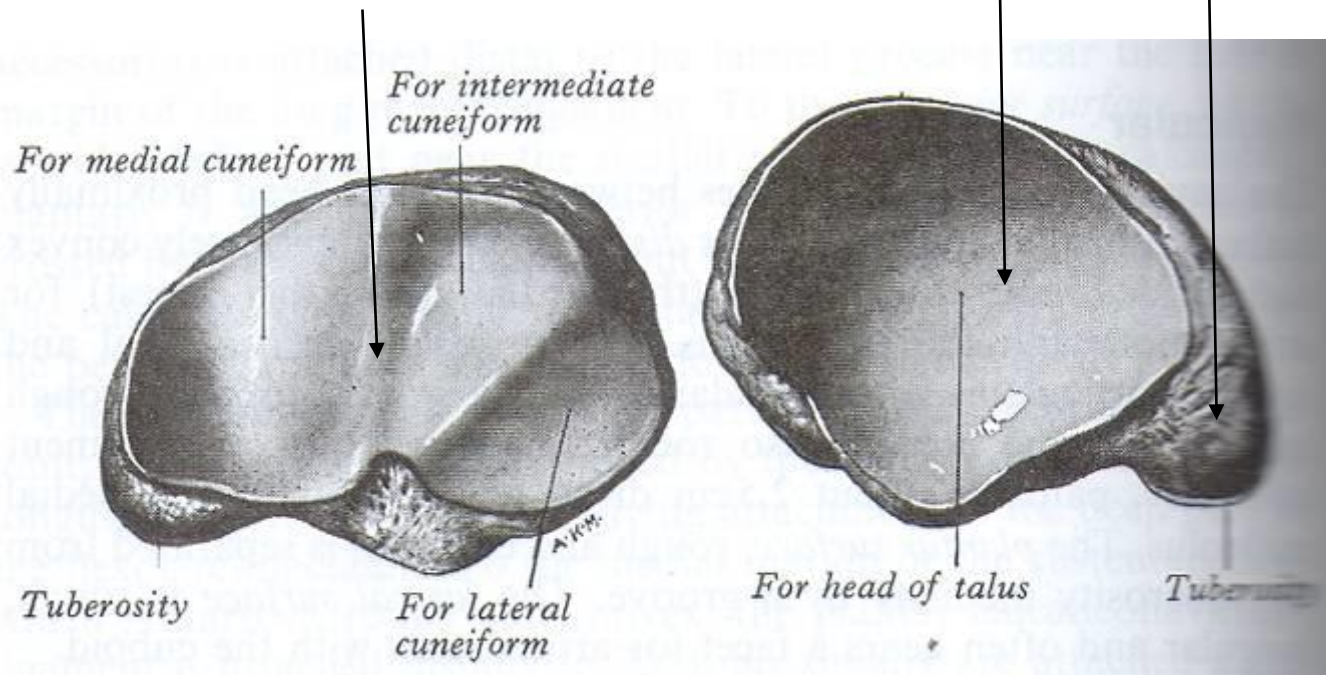


cuneiform bones (Ossa cuneiformia)



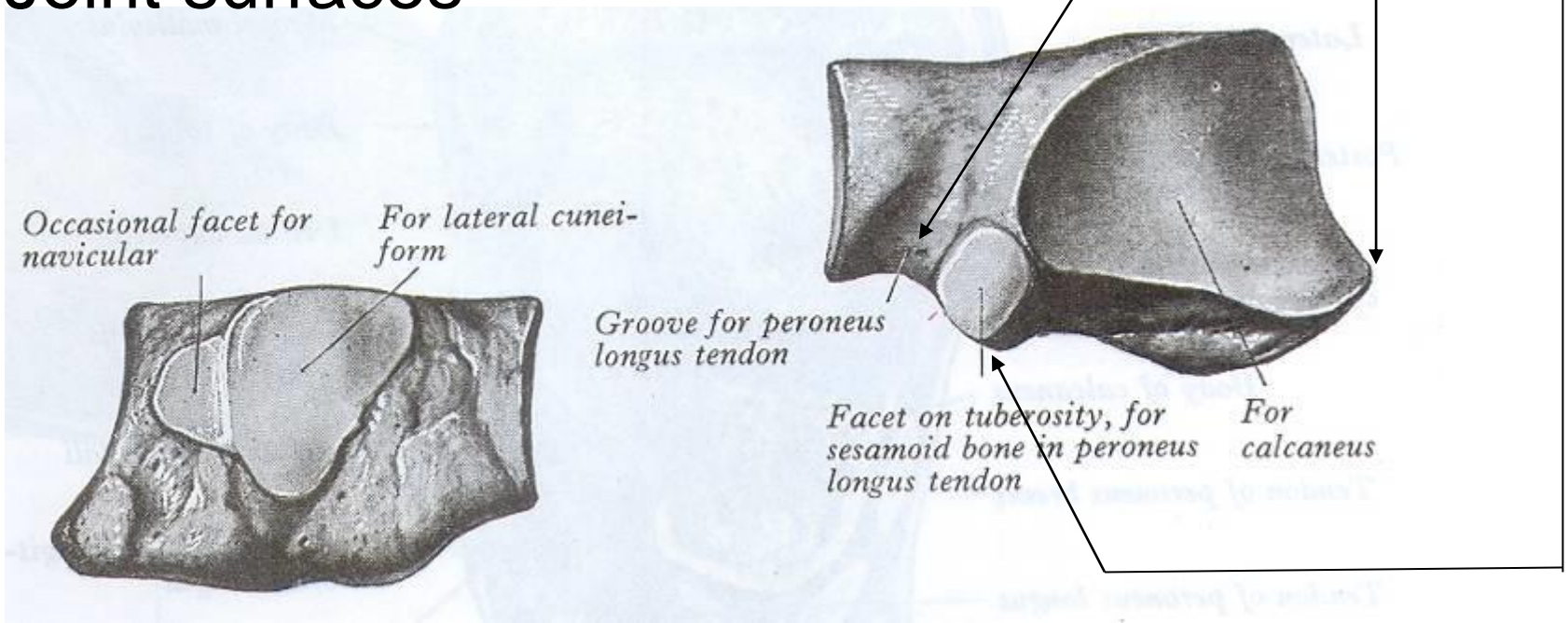
Navicular bone (os naviculare)

- Tuberositas ossis navicularis
- Facies articularis talaris
- Facies articularis cuneiformis

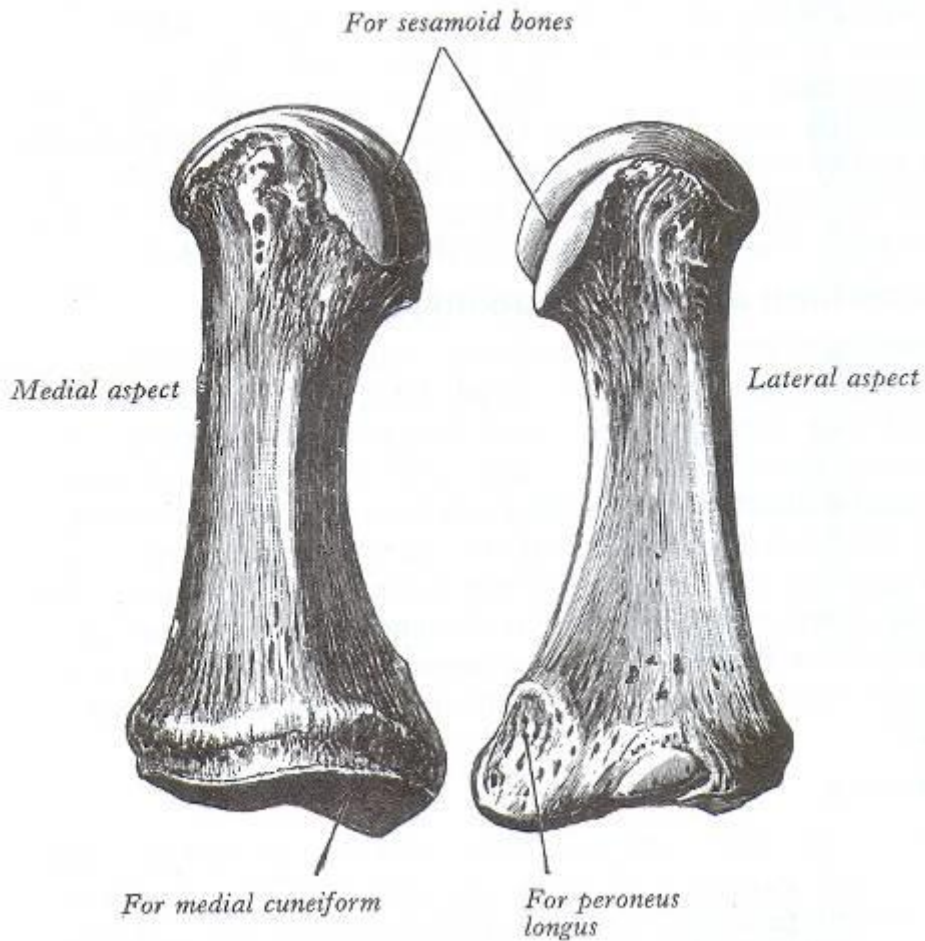


Cuboid bone (os cuboideum)

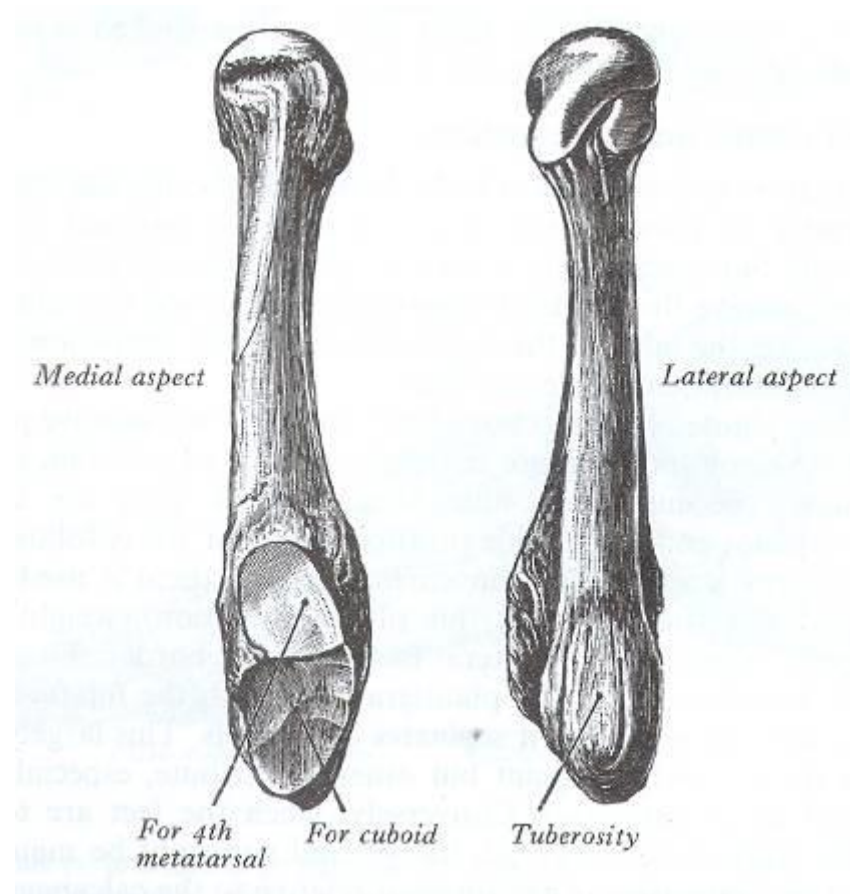
- Sulcus tendinis musculi fibularis longi ossis cuboidei
- Tuberositas ossis cuboidei
- Processus calcaneus
- Joint surfaces



Metatarsal bones (ossa metatarsi) I.

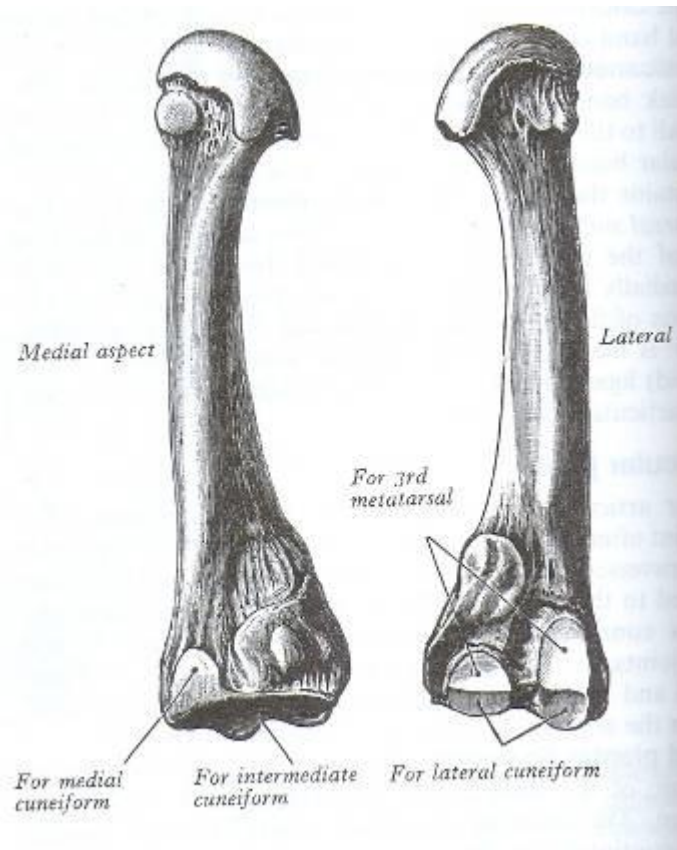


O.m. primum

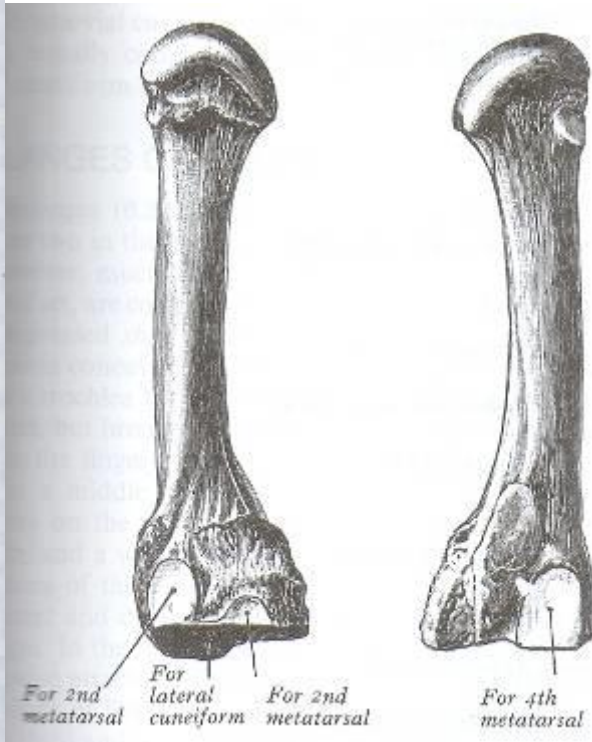


O.m. quintum

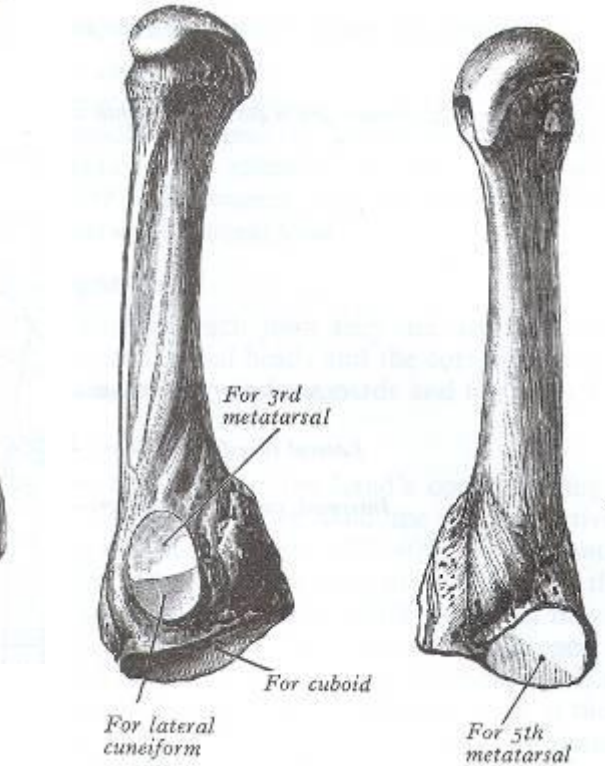
Metatarsal bones (Ossa metatarsi) II.



O.m. secundum



O.m. tertium

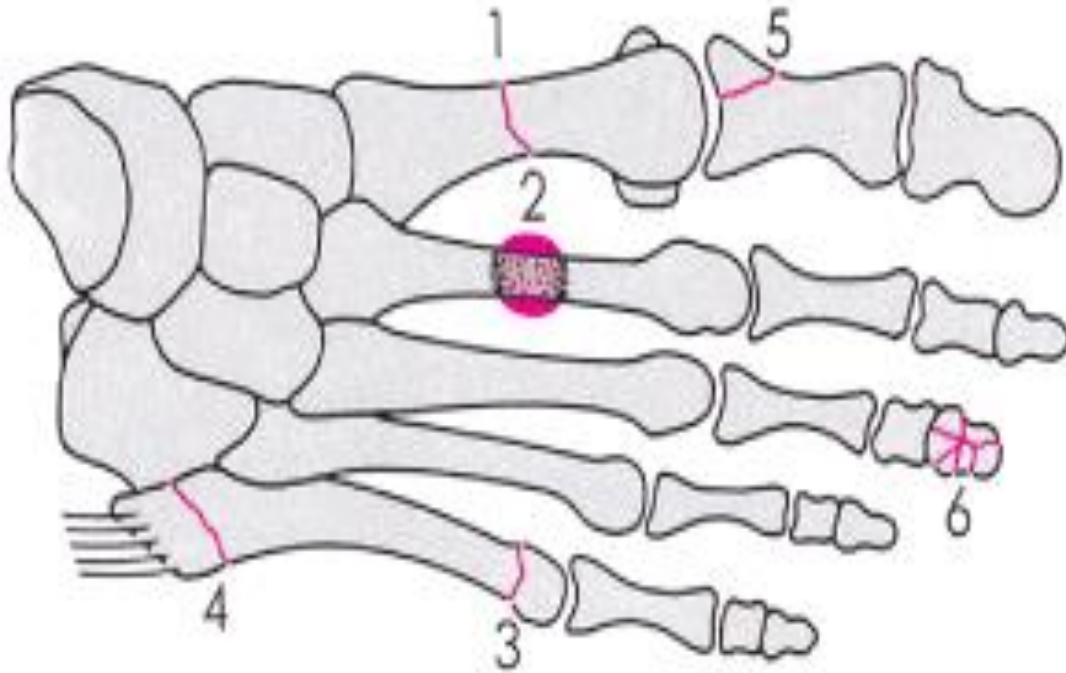


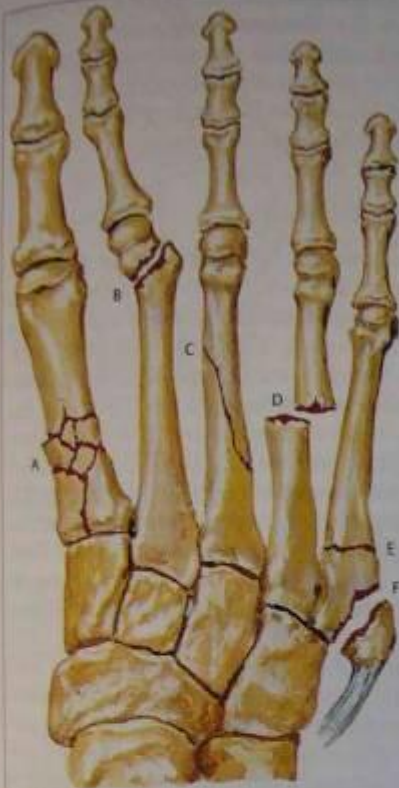O.m. quartum

Clinical notes

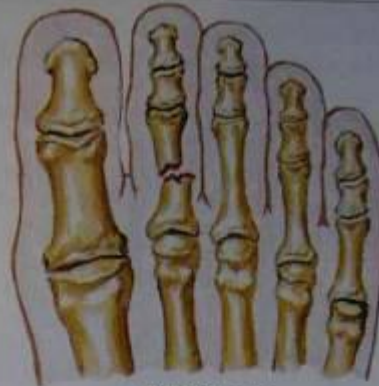- monoepiphyseal bones - see metacarpus
- „March fracture“ – stress fracture most often in II. and III. metatarsus
- Metatarsal avulsion fracture – detachment of the *musculus fibularis brevis* attachment
- frequent fractures due to direct violence – instep falls

March Fracture

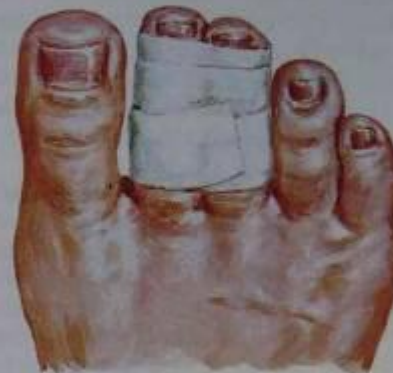



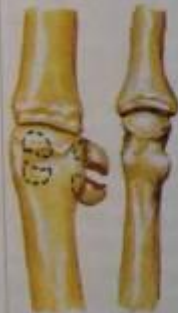▲ Metatarsalfrakturen: Typ A – Trümmerfraktur, Typ B – diszierte Halbfraktur, Typ C – Schrägfraktur, Typ D – diszierte Querfraktur, Typ E – Fraktur an der Basis des Metatarsale V, Typ F – Abriss an der Tuberositas des Metatarsale V



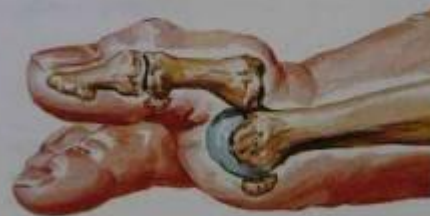▲ Grundgliedfraktur



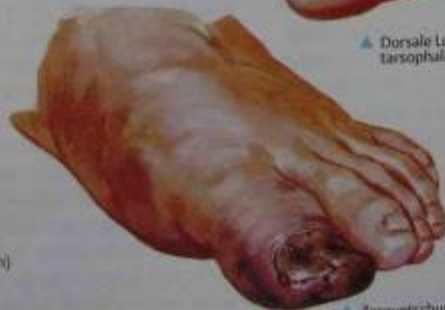▲ Schienung einer Phalangenfraktur durch Heftpflasterfixierung an der Nachbarzehe („buddy taping“)



▲ Fraktur der Sesambeine (gegenüber einem angeborenen Os sesamoideum separatum zu differenzieren)

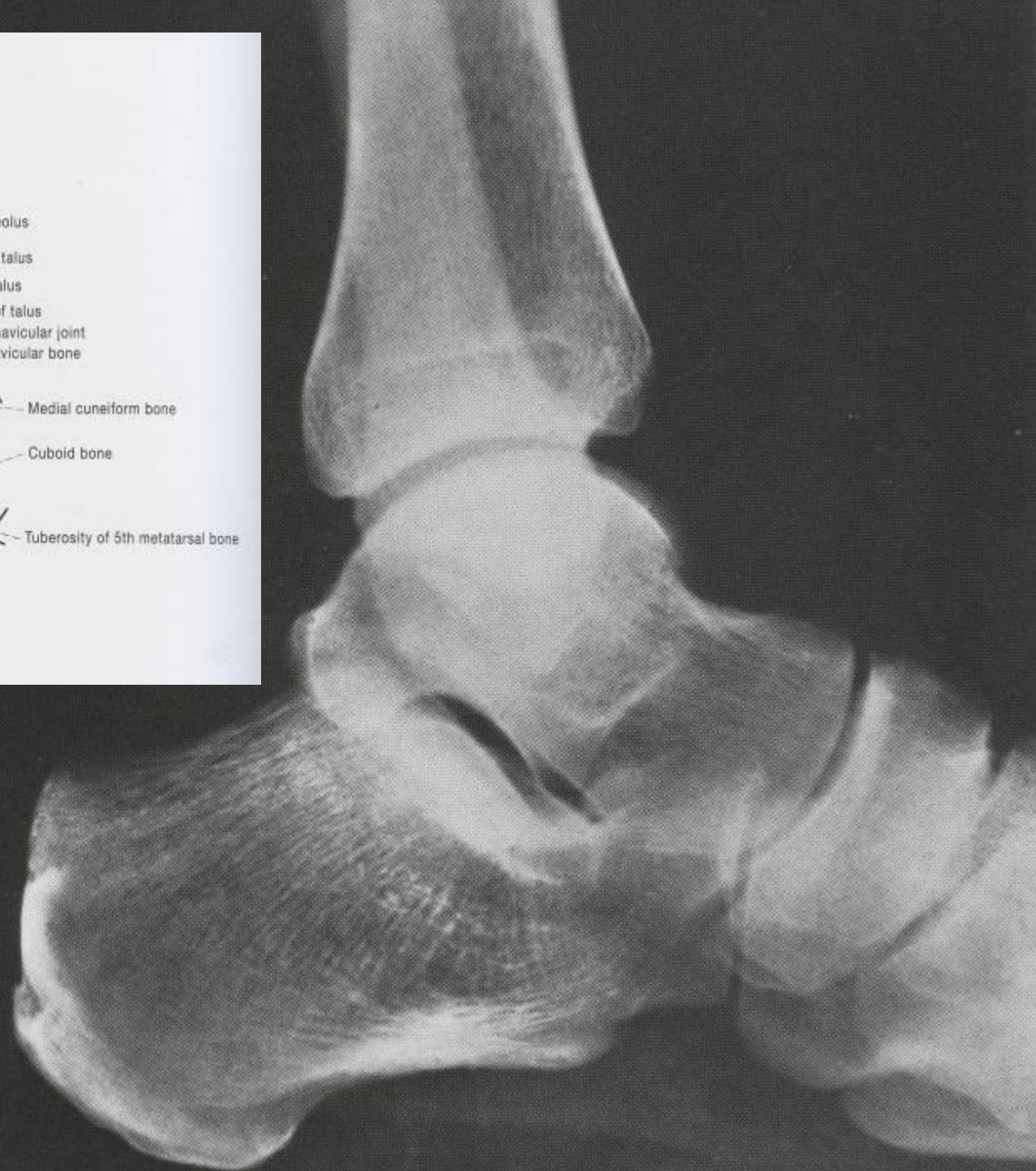
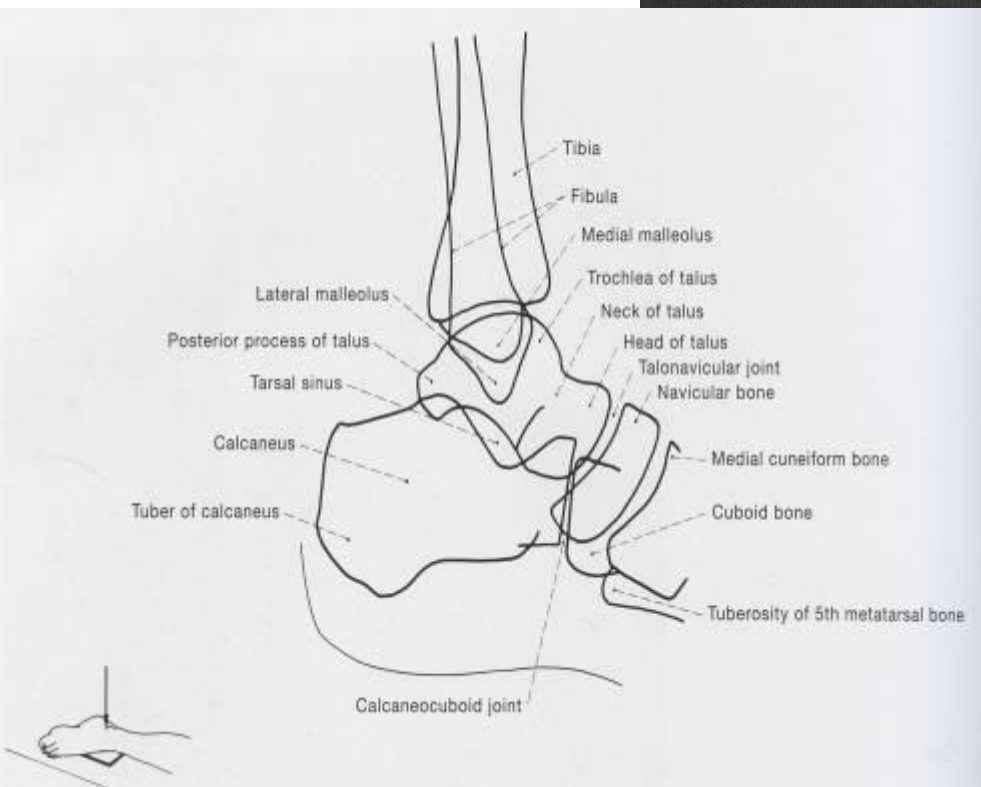


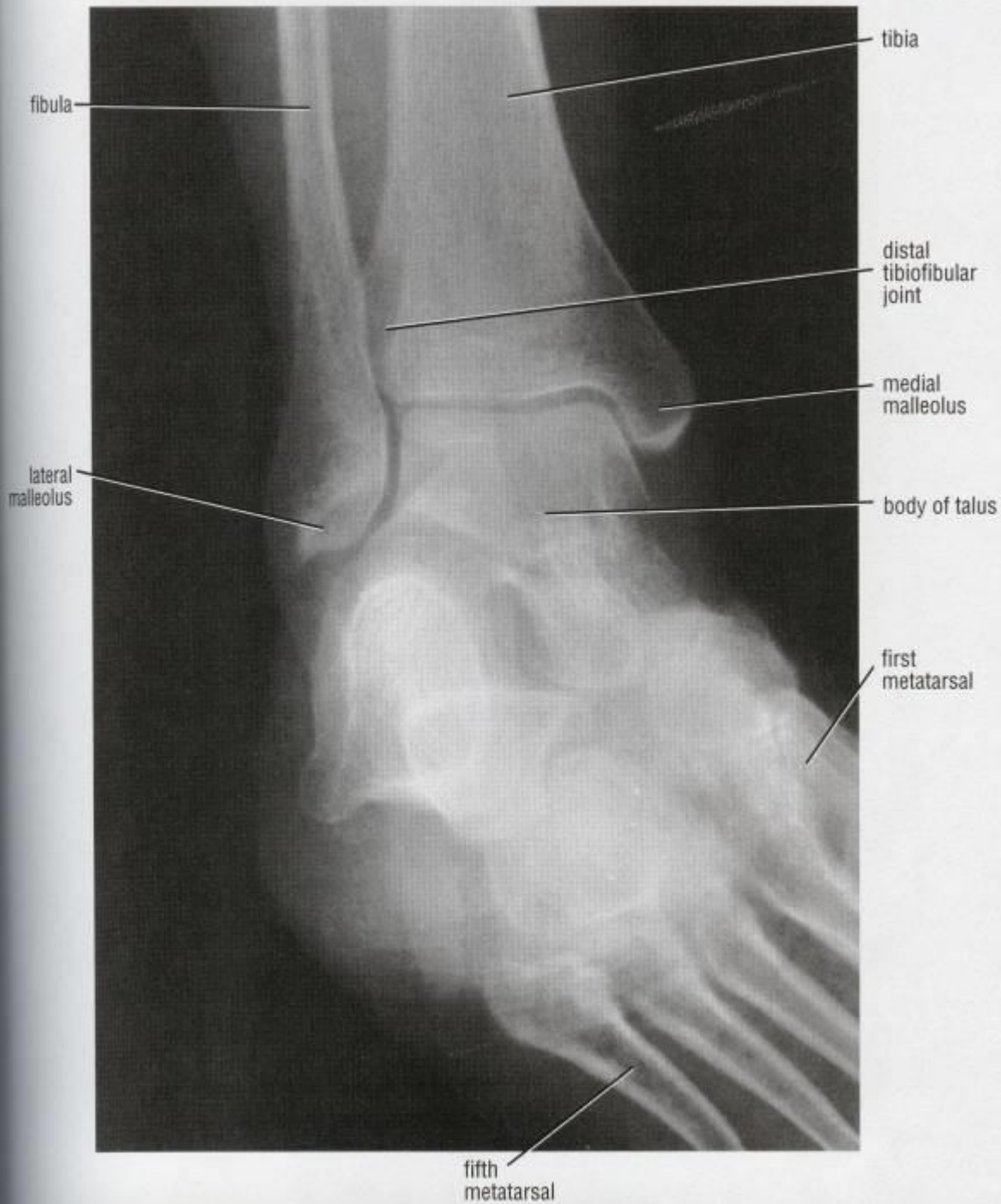
▲ Dorsale Luxation des Metatarsophalangealgelenks I

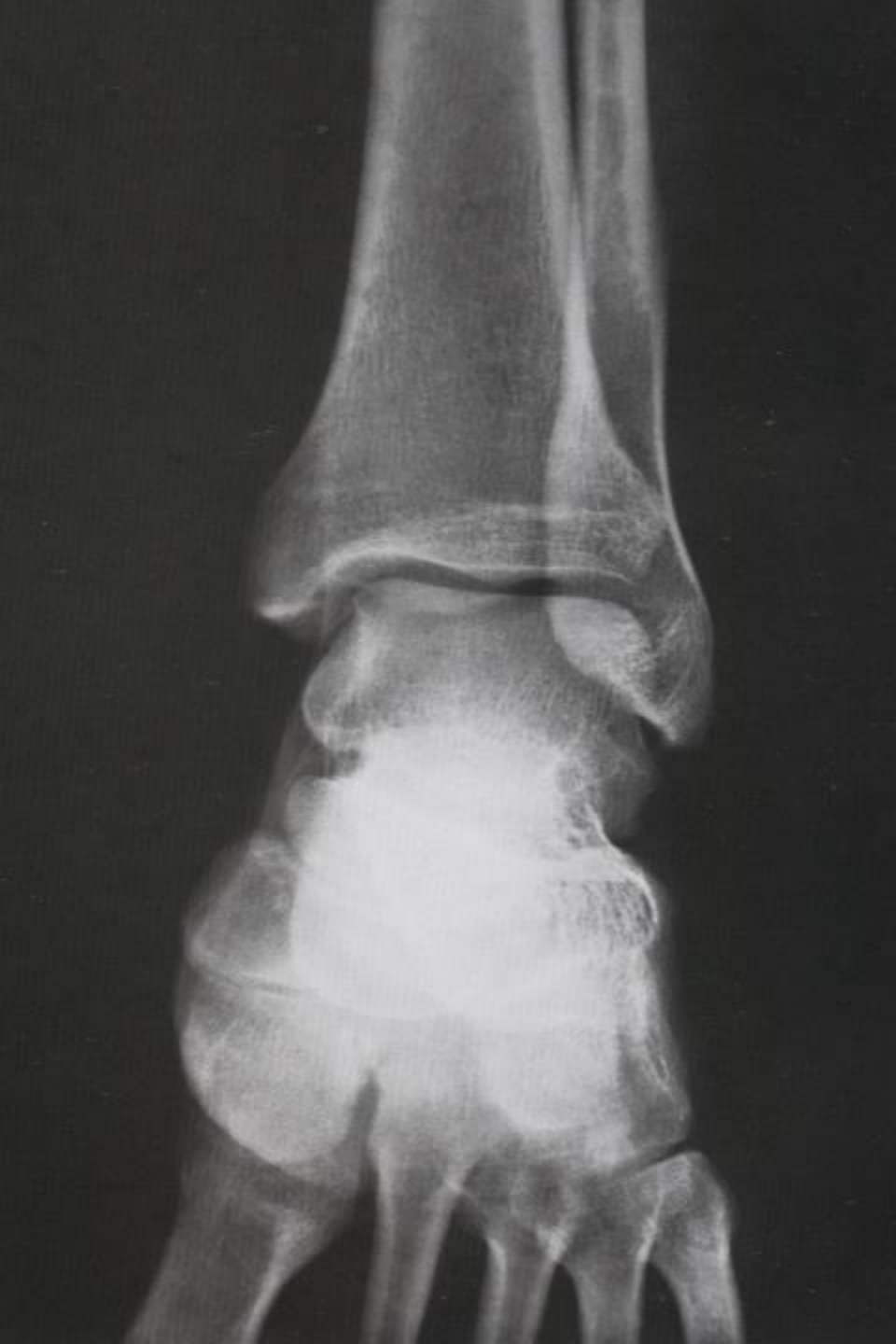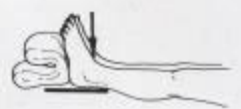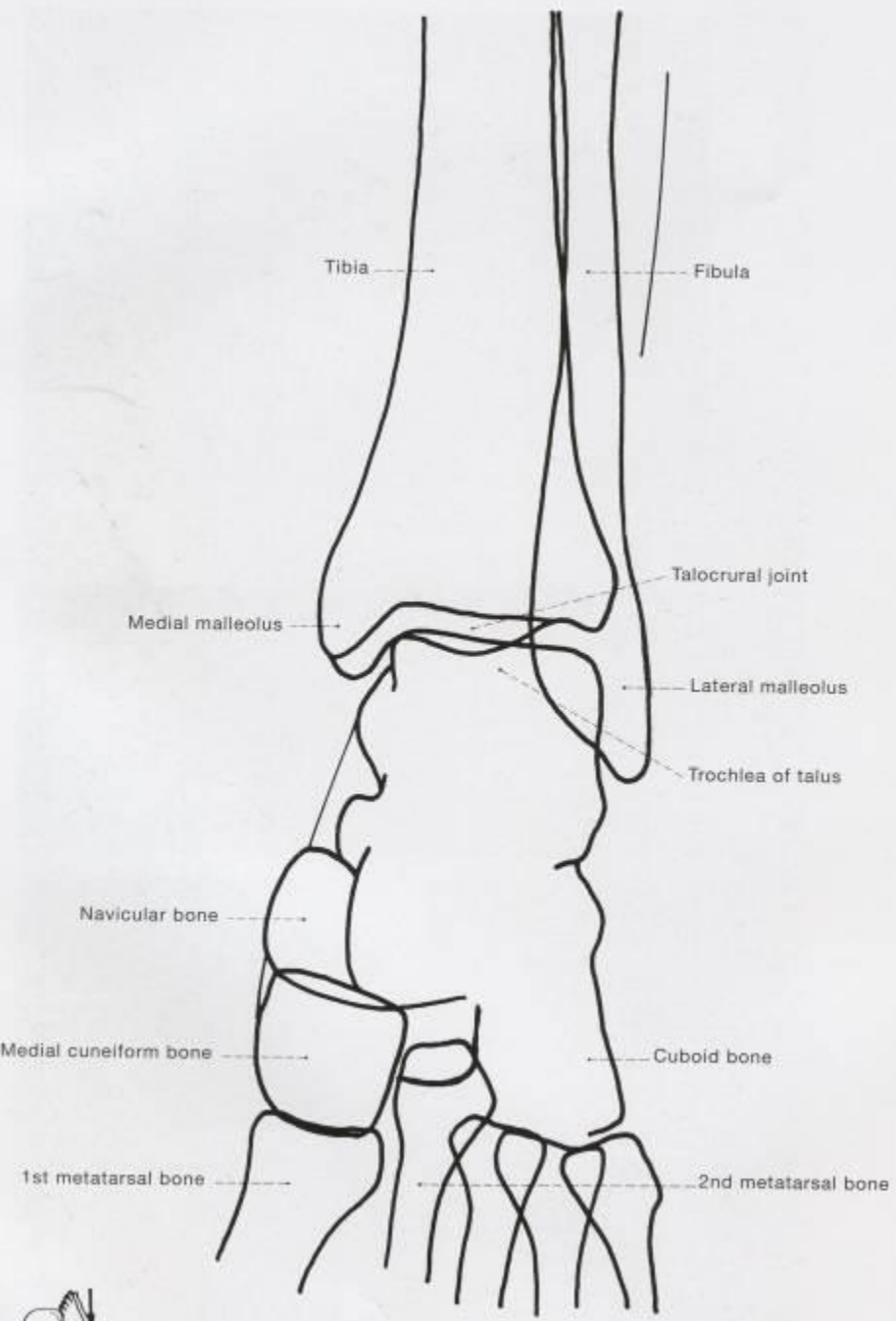


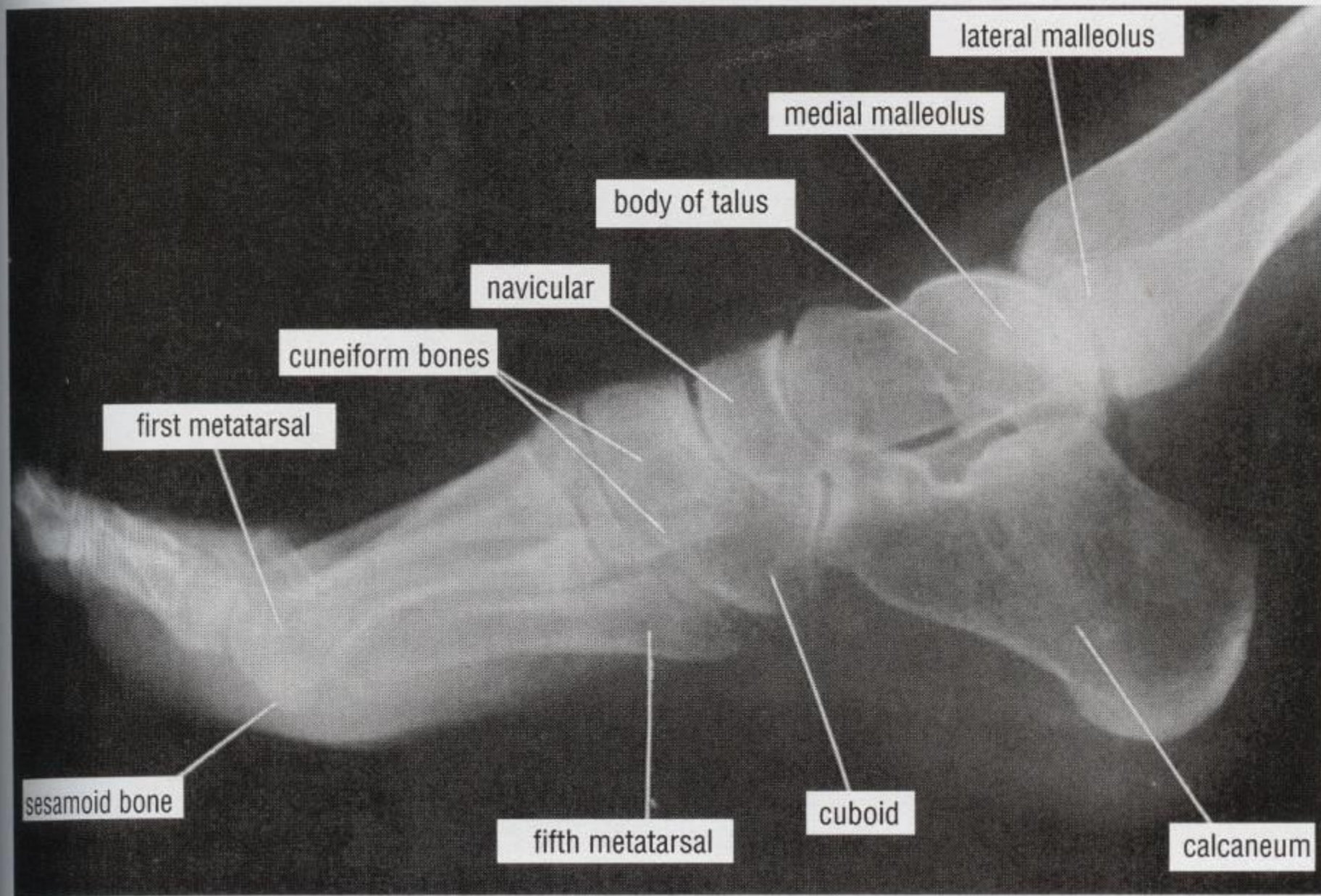
▲ Zerquetschung der Großzehe

F. Netter
© 2005

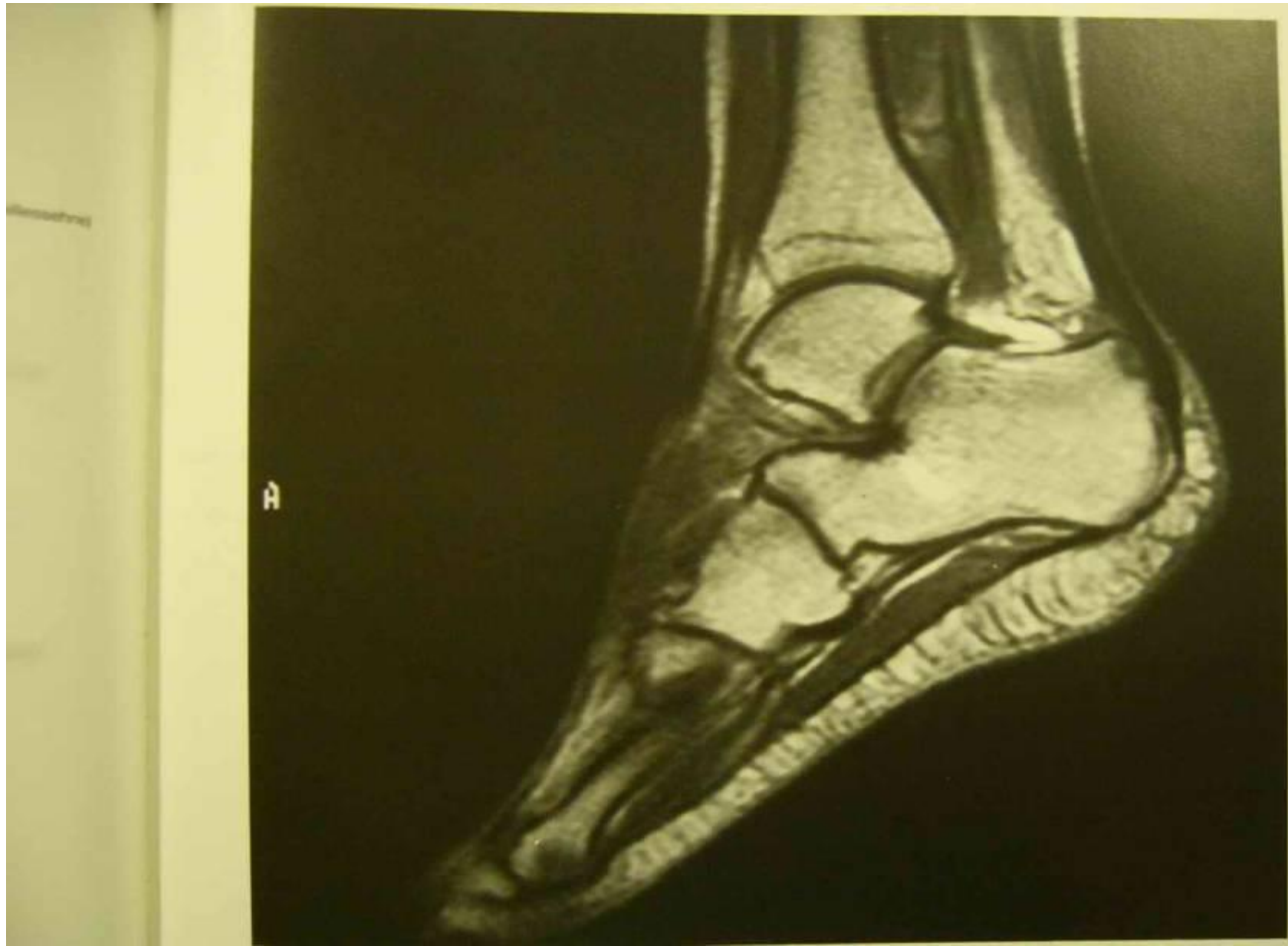






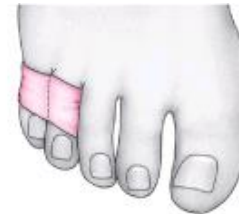
MRI Foot



Clinical notes

- phalanges pedis – monoepiphyseal bones
- the big toe plays very important supporting role in walking and maintaining balance while standing
- direct impact injuries (kicking) - 3 weekspatch fixation



Berchtold/Bruch/Trentz: Chirurgie, 5.A. © Elsevier GmbH. www.studentconsult.de

- hallux valgus (bunion) – orthopedic deformity, the thumb is turned to the other fingers

Hallux valgus

