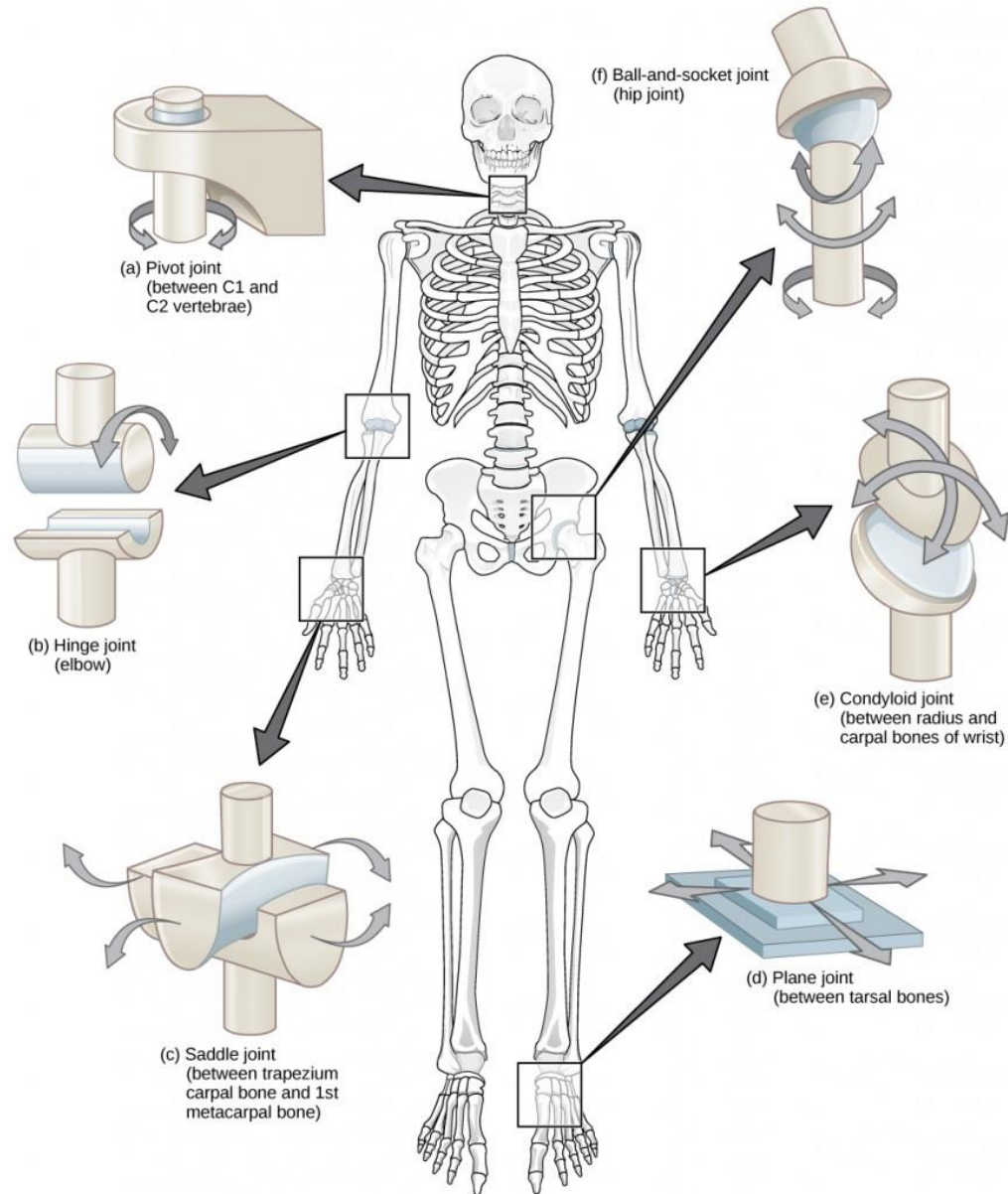


Joints of the Upper & Lower Limbs

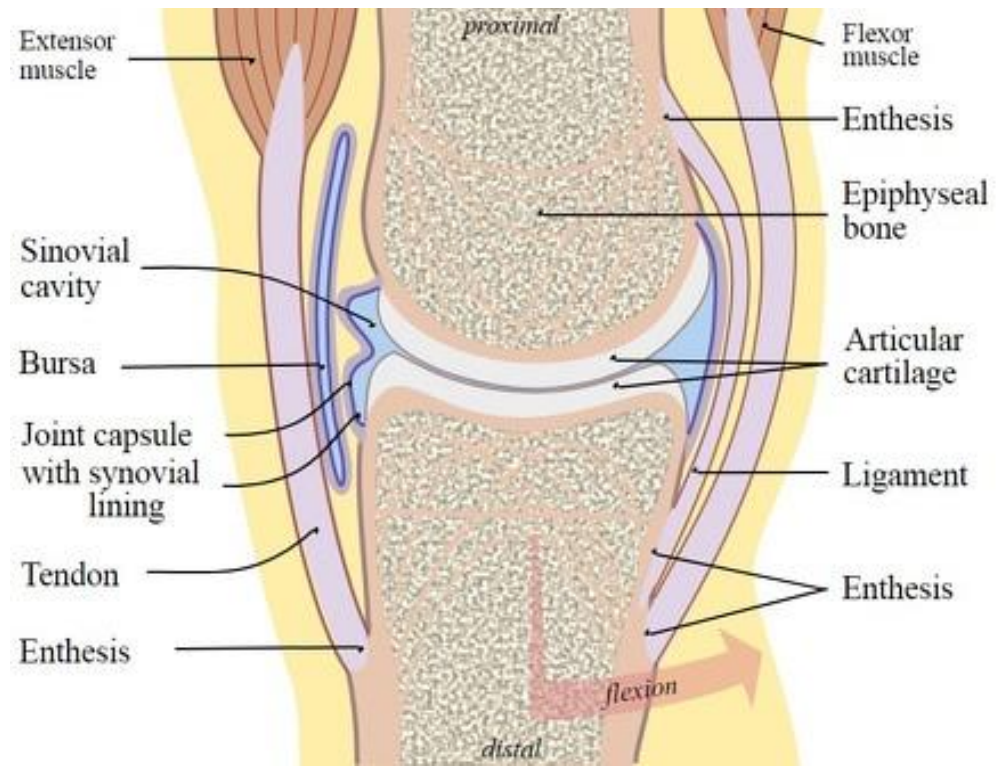
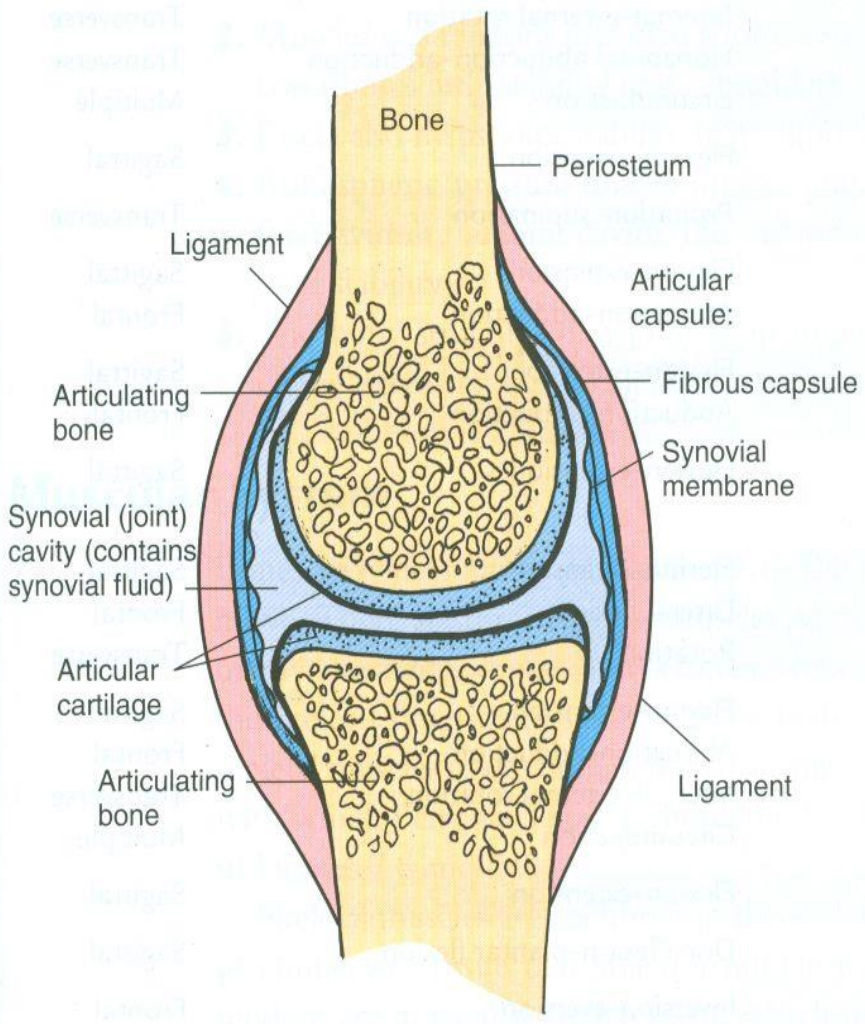


Department of Anatomy
Second Faculty of Medicine
Charles University

MUDr. Azzat Al-Redouan

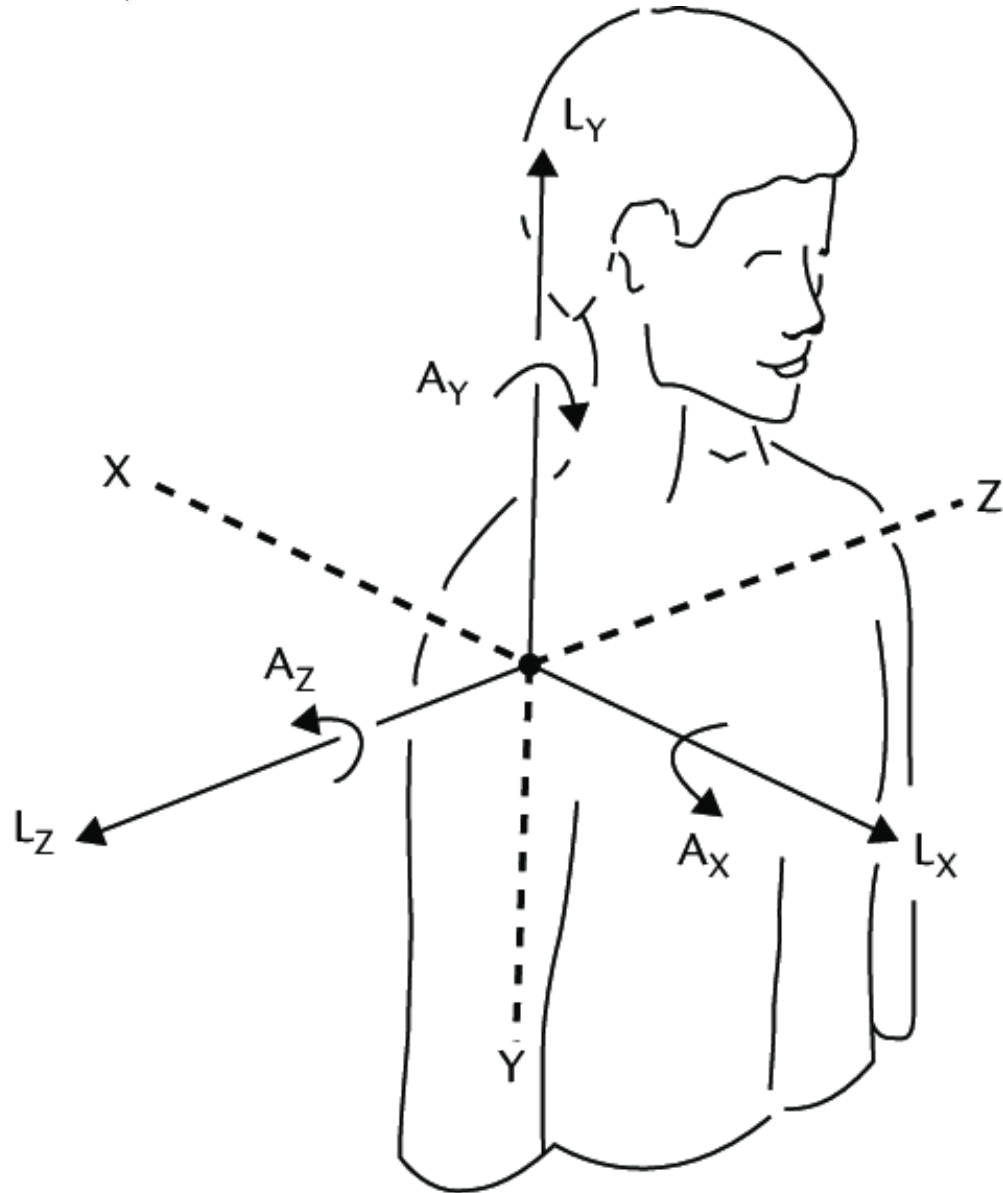


Synovial Joint

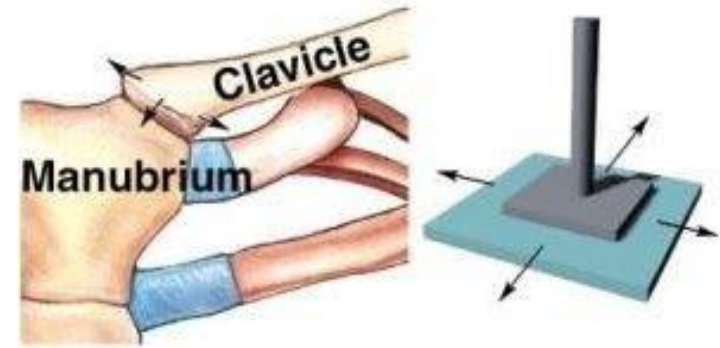
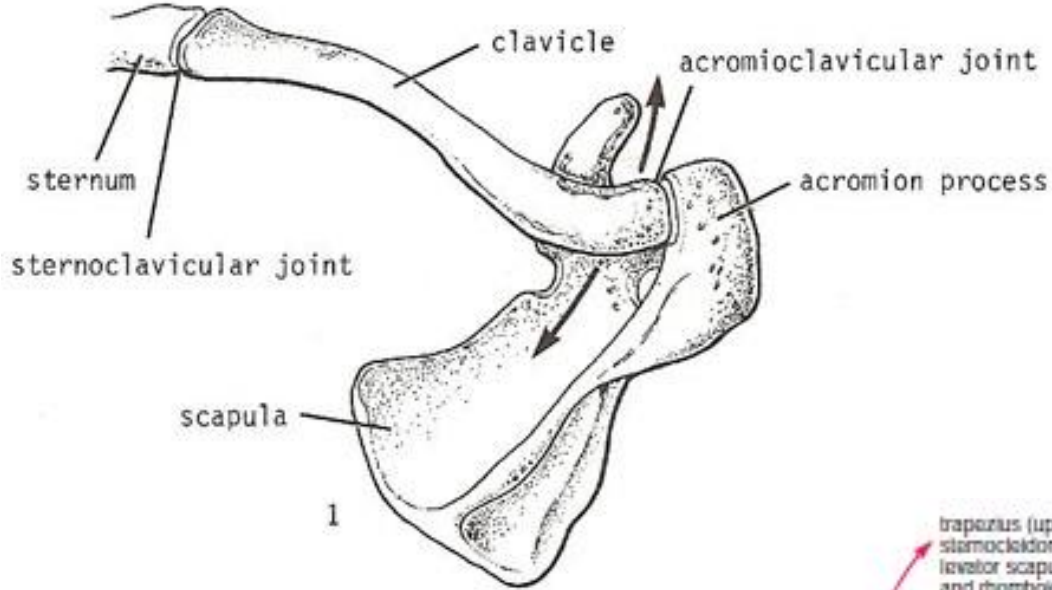


Degrees of Freedom

- Degree of freedom
 - Number of planes in which a joint has the ability to move
- 1 degree of freedom
 - Uniaxial
 - Example: Elbow
- 2 degrees of freedom
 - Biaxial
 - Example: Wrist
- 3 degrees of freedom
 - Triaxial
 - Example: Shoulder



Sternoclavicular joint (*Articulatio sternoclavicularis*)



Gliding joint

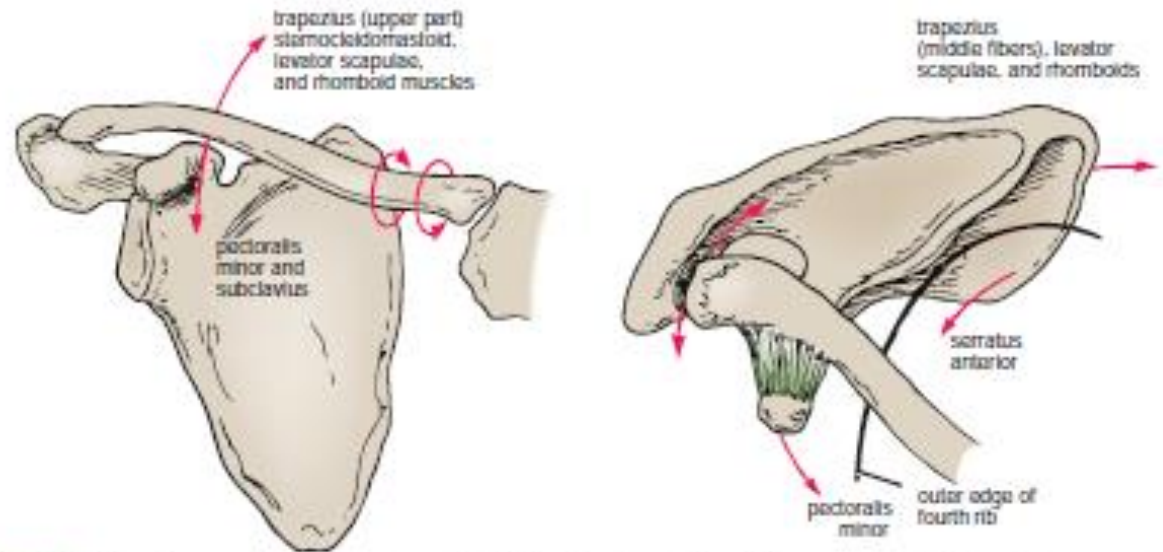
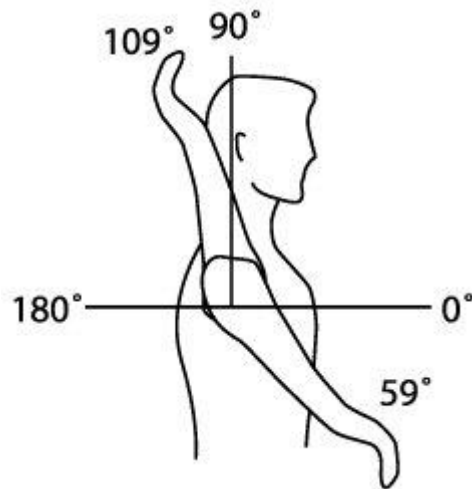
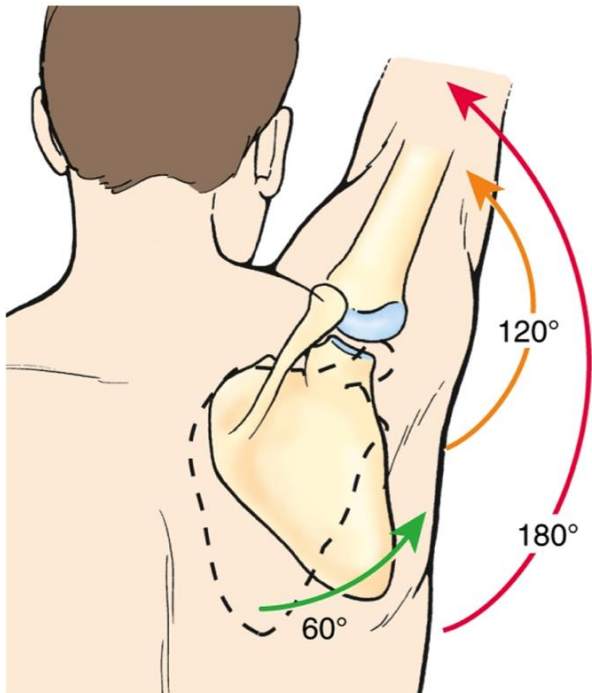
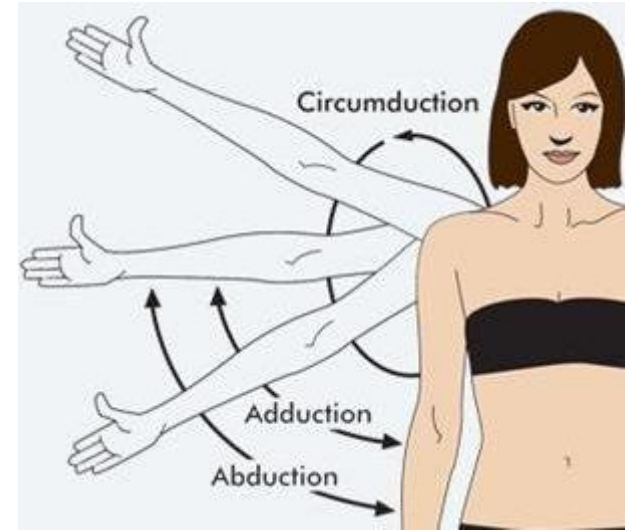
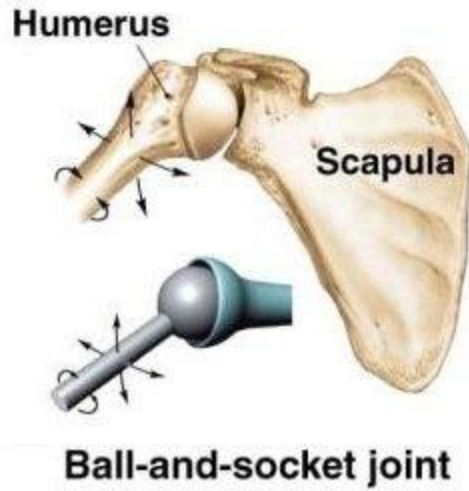
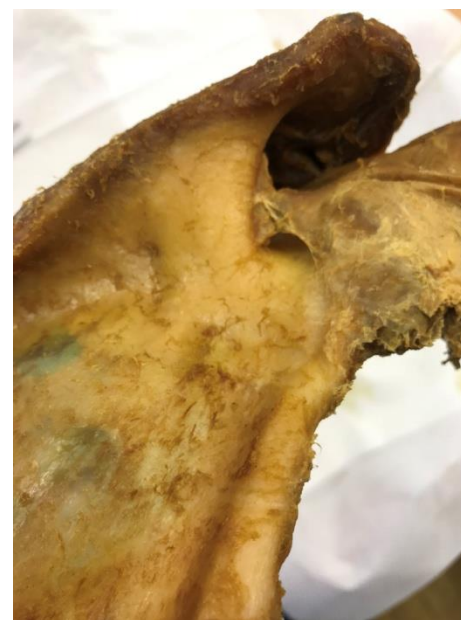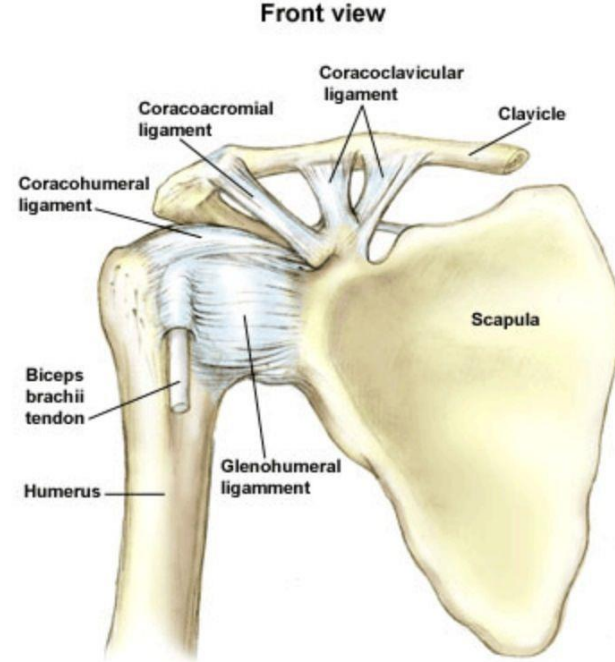
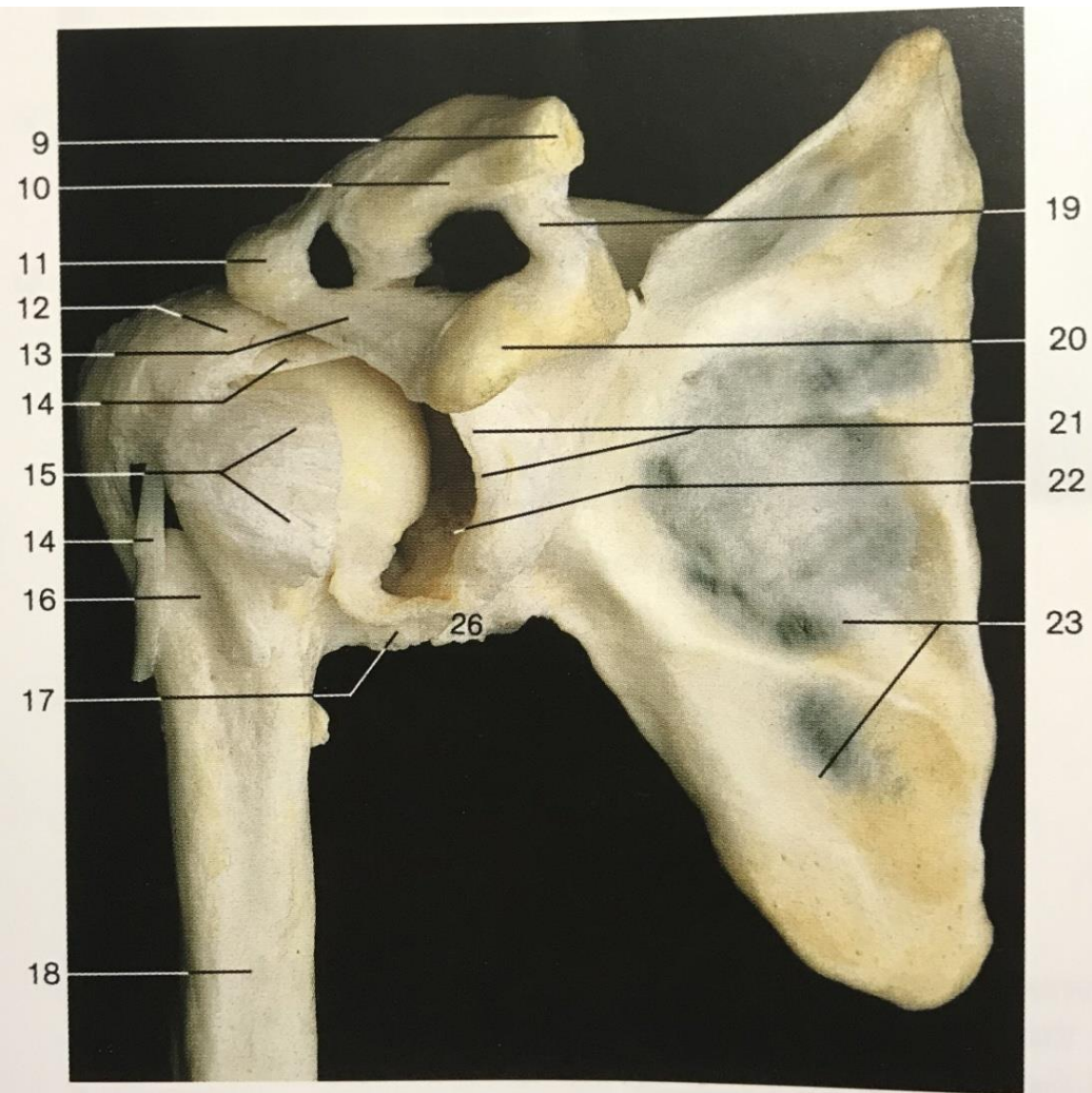
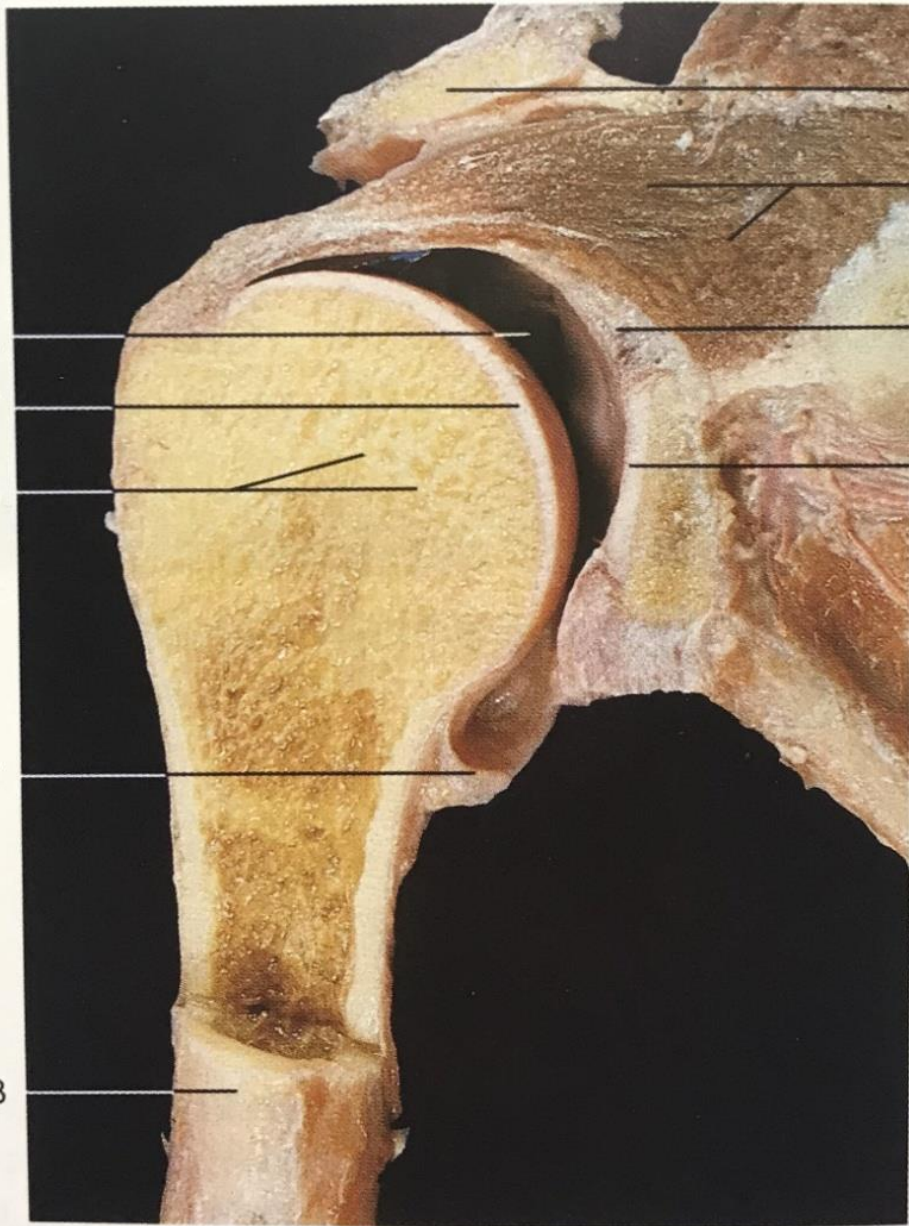


FIGURE 9.33 The wide range of movements possible at the sternoclavicular and the acromioclavicular joints gives great mobility to the clavicle and the upper limb.

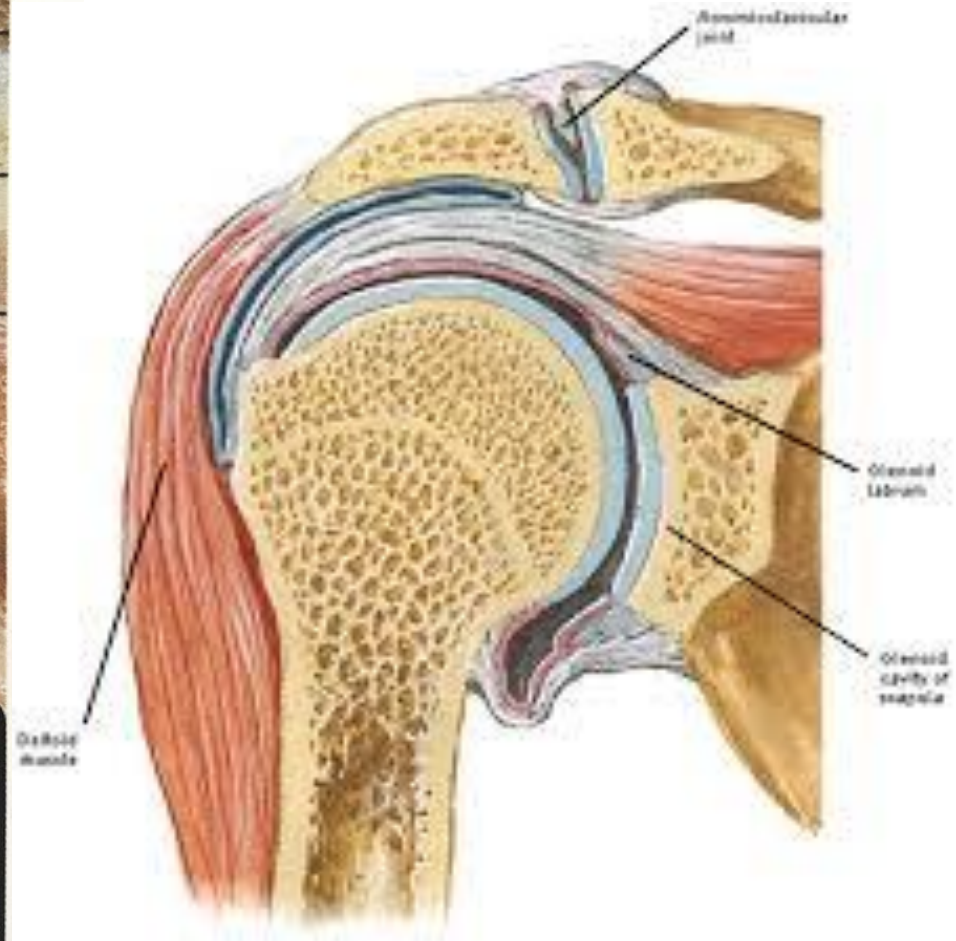
Shoulder joint (*Articulatio glenohumeralis*)

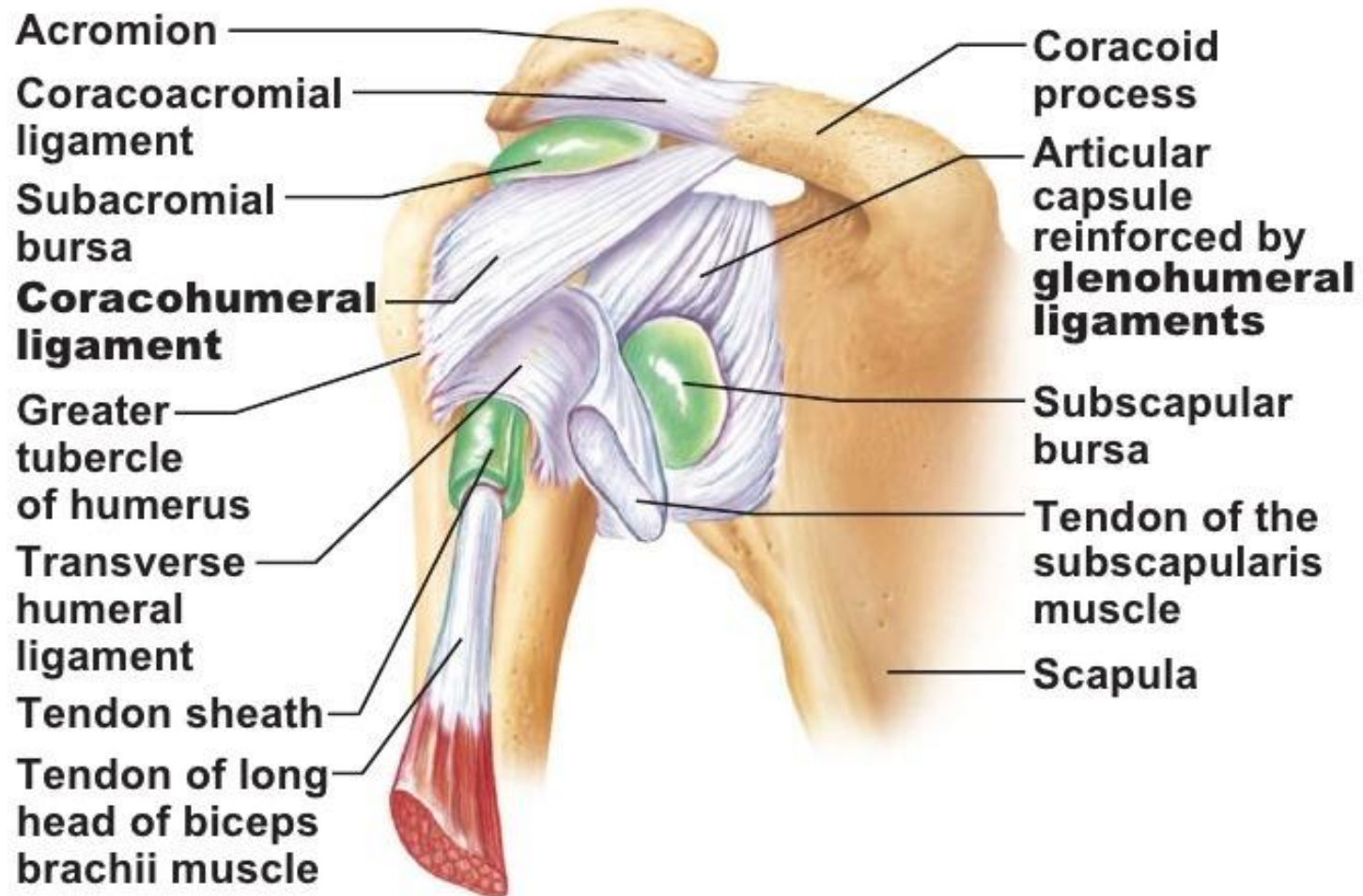




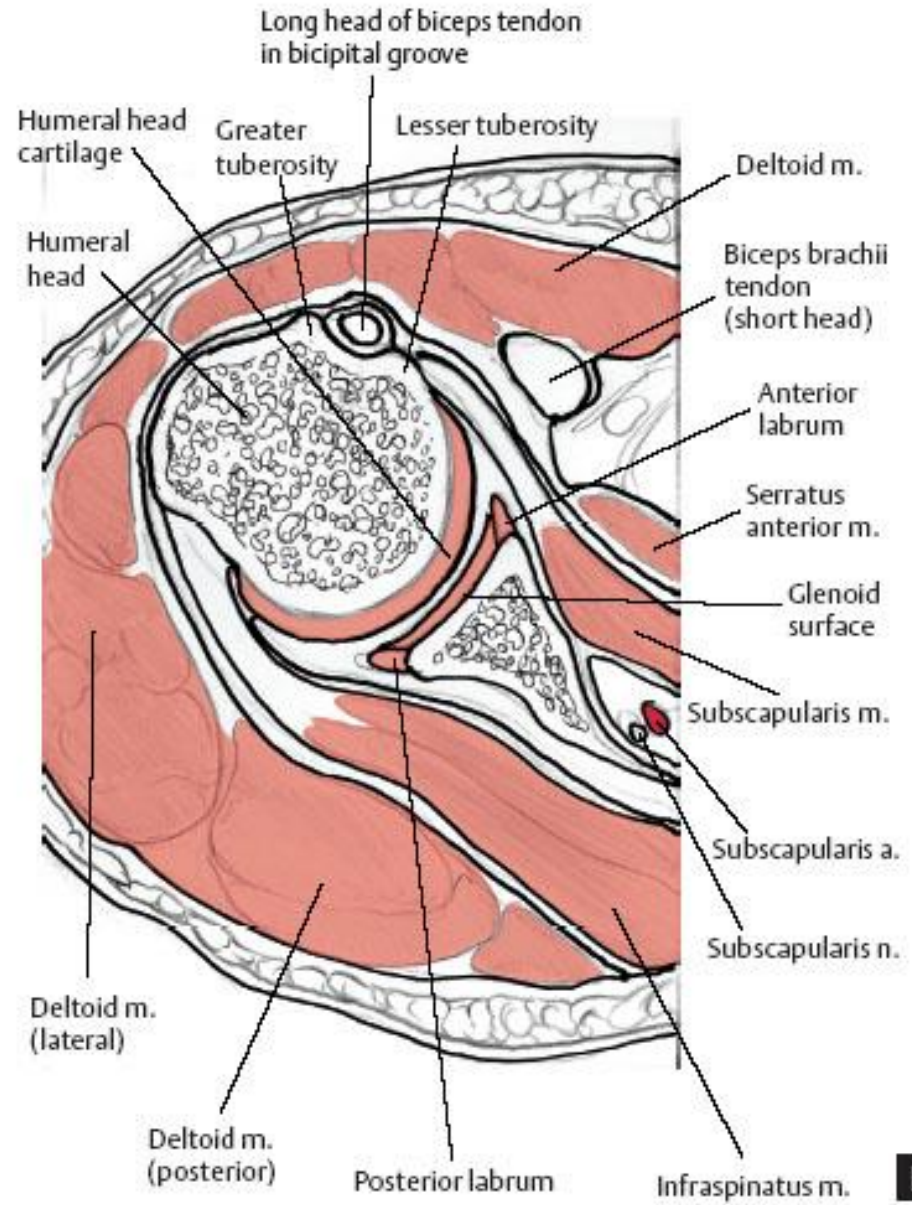
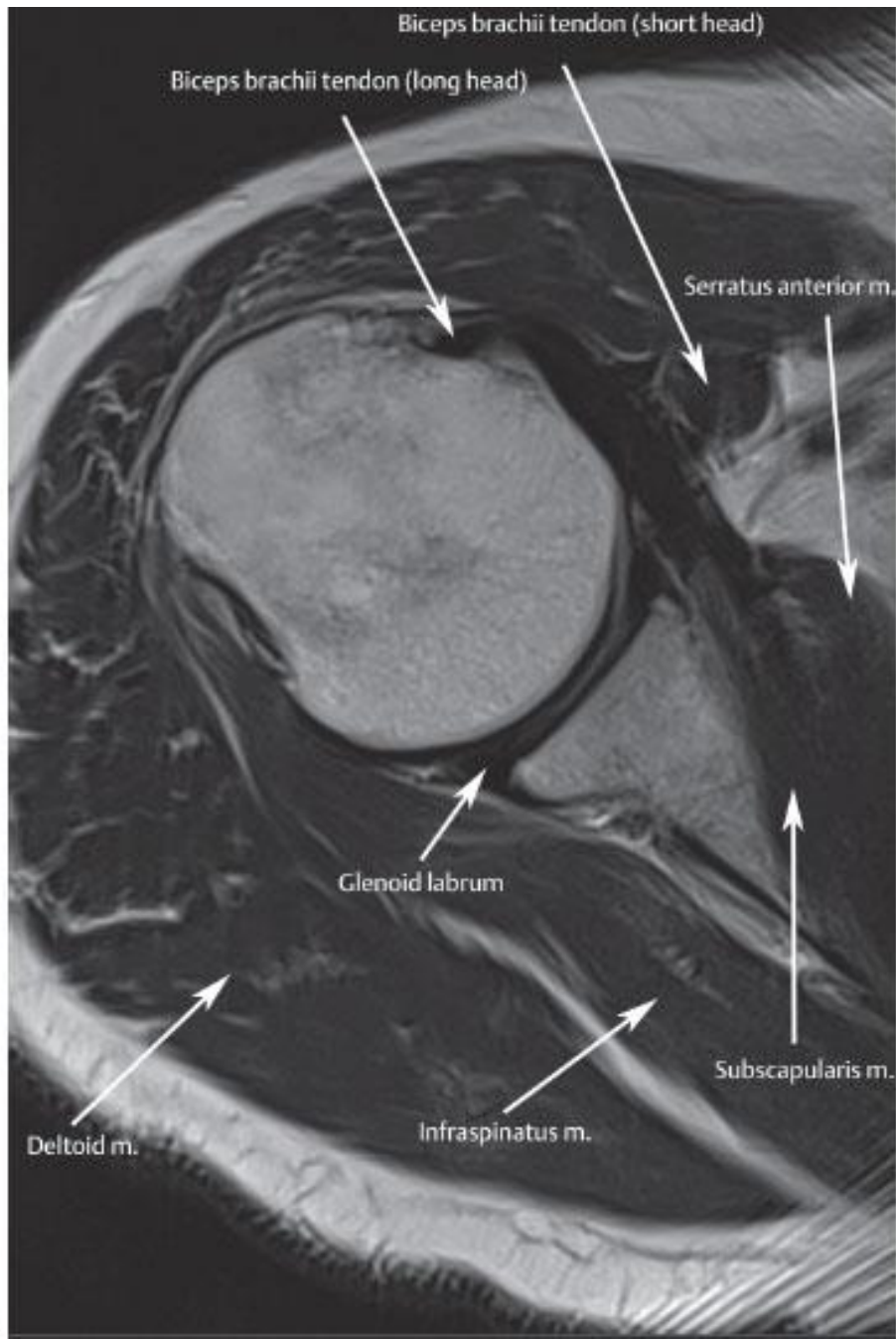


11

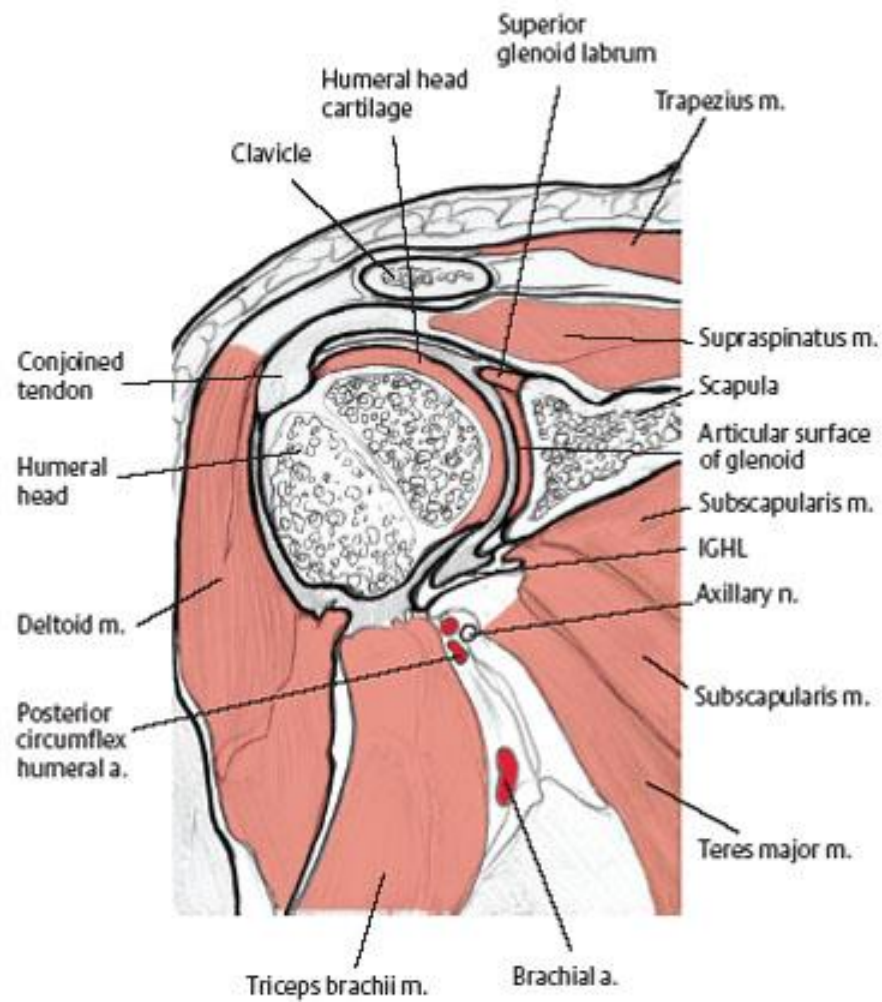
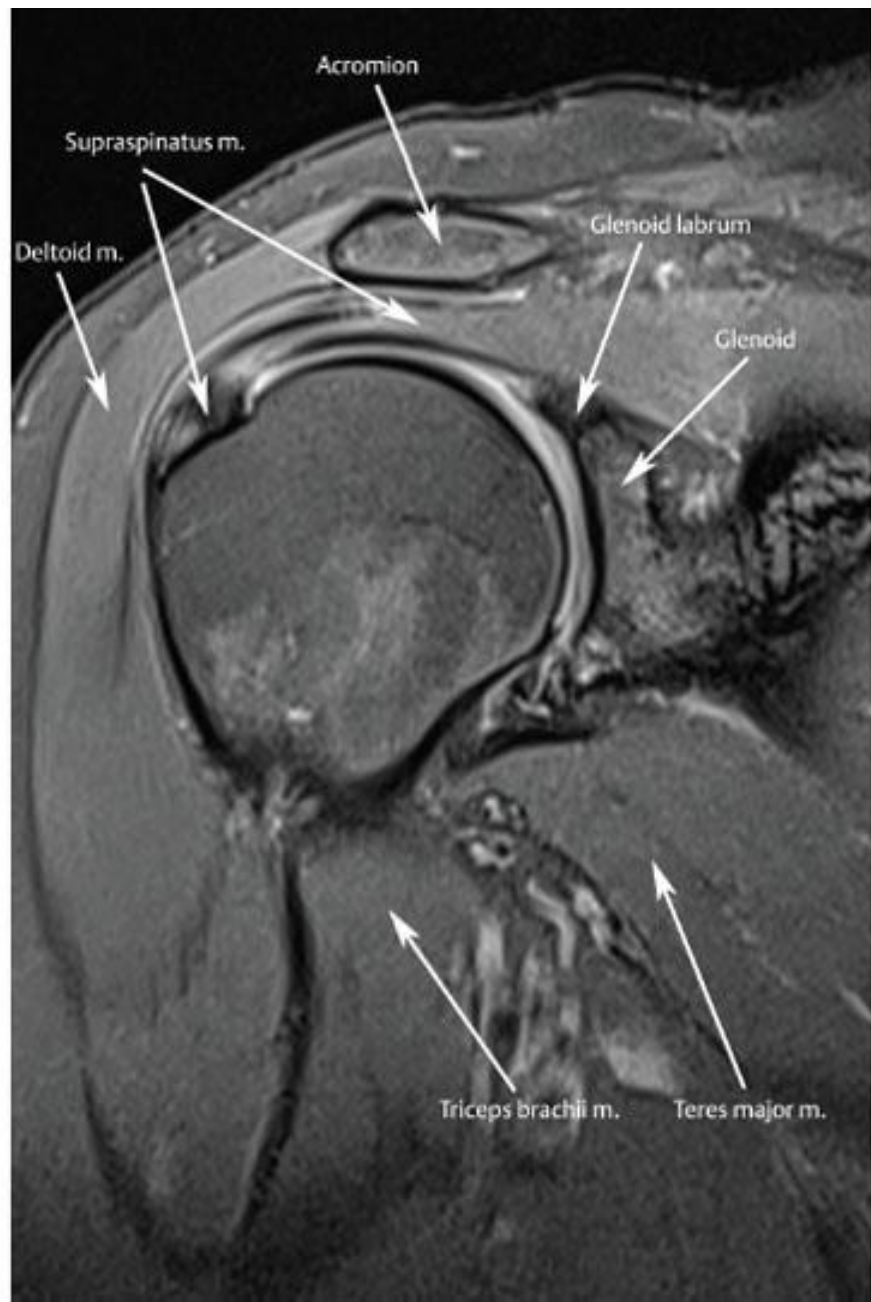




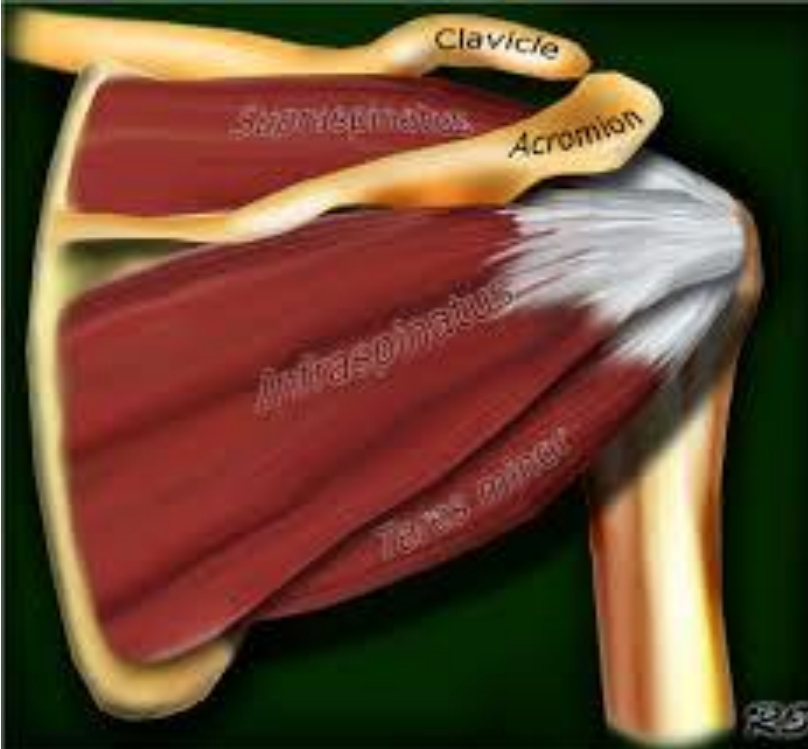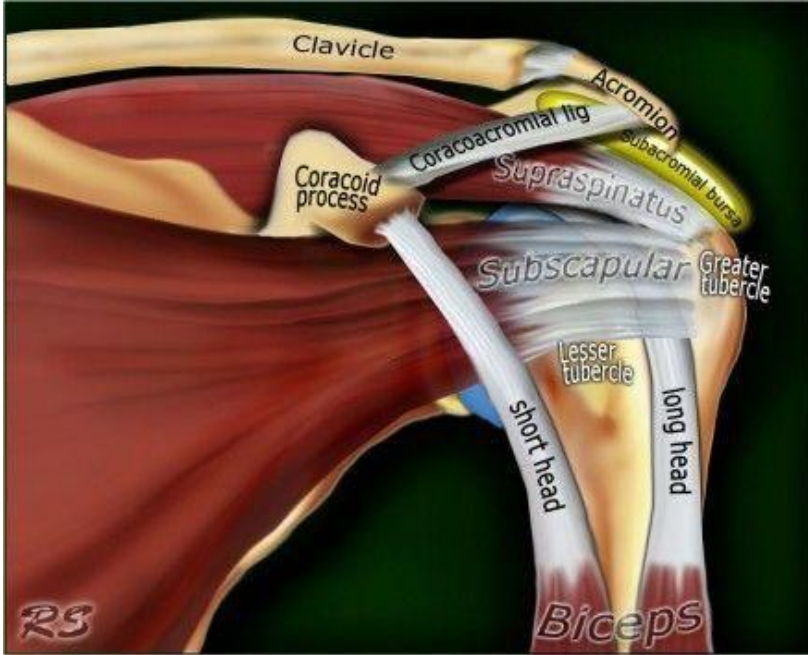
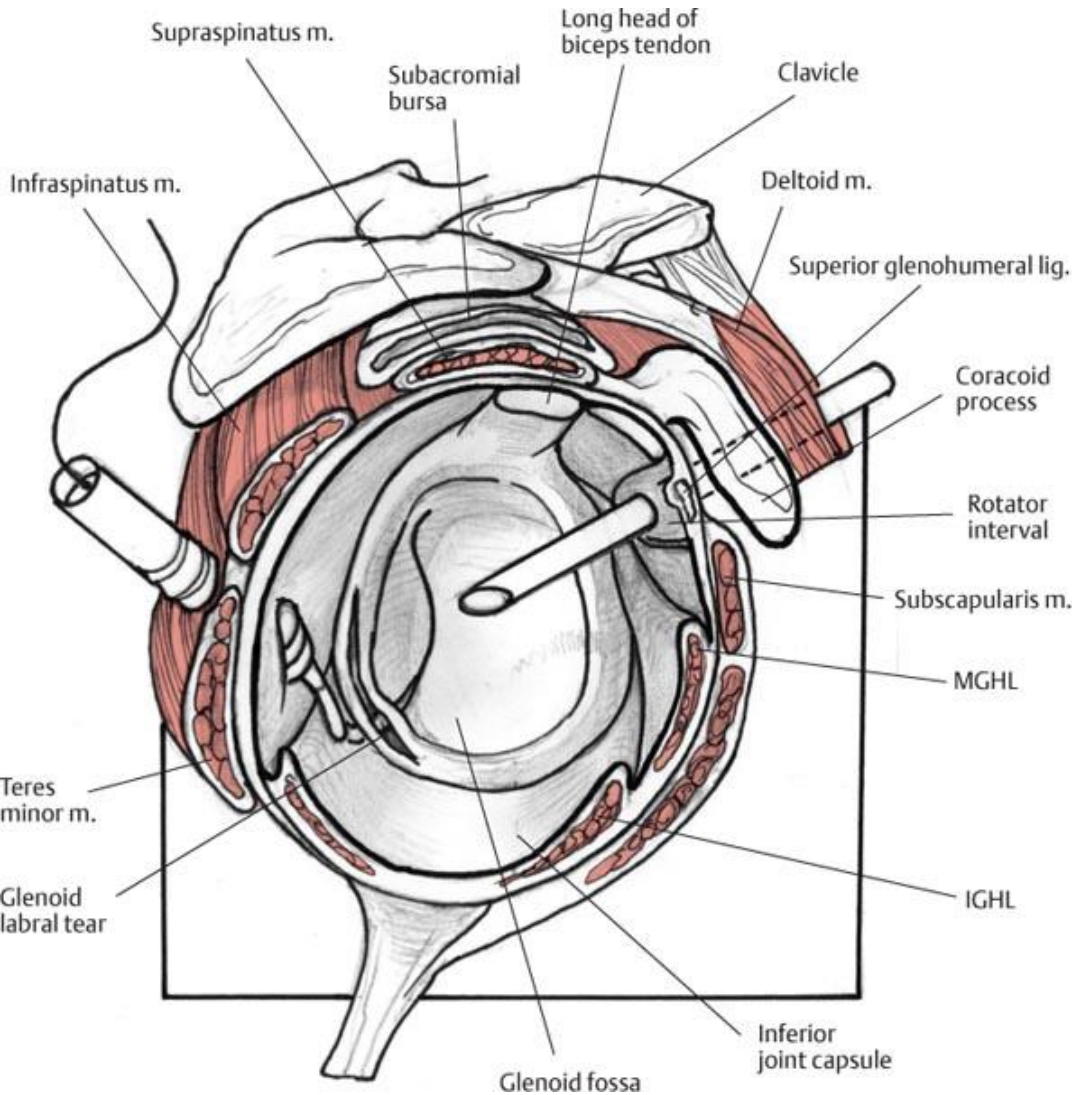
(c) Anterior view of right shoulder joint capsule



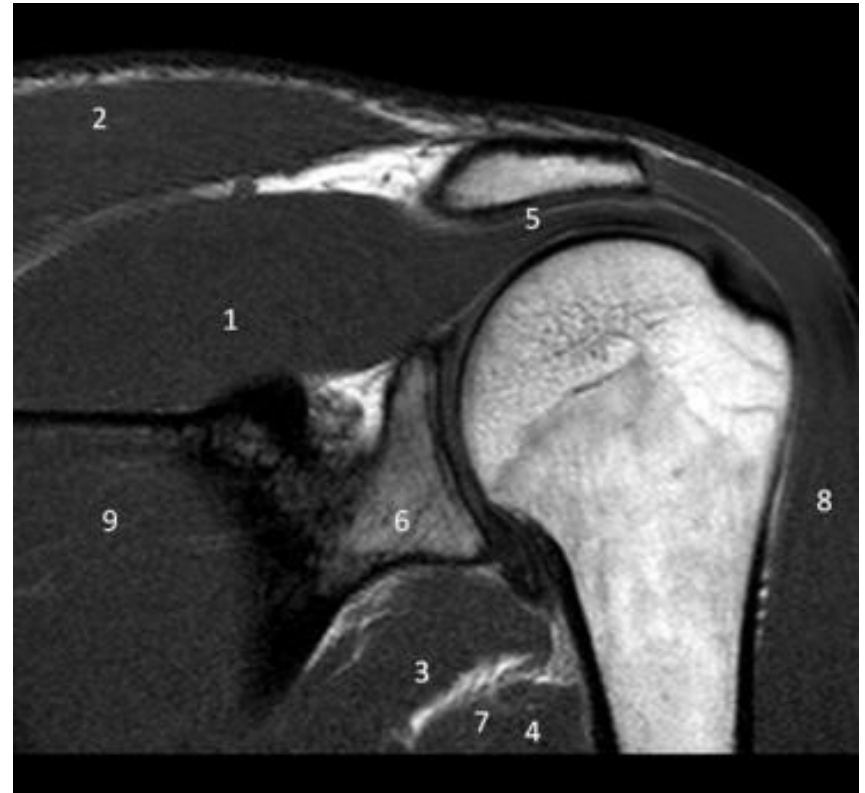B



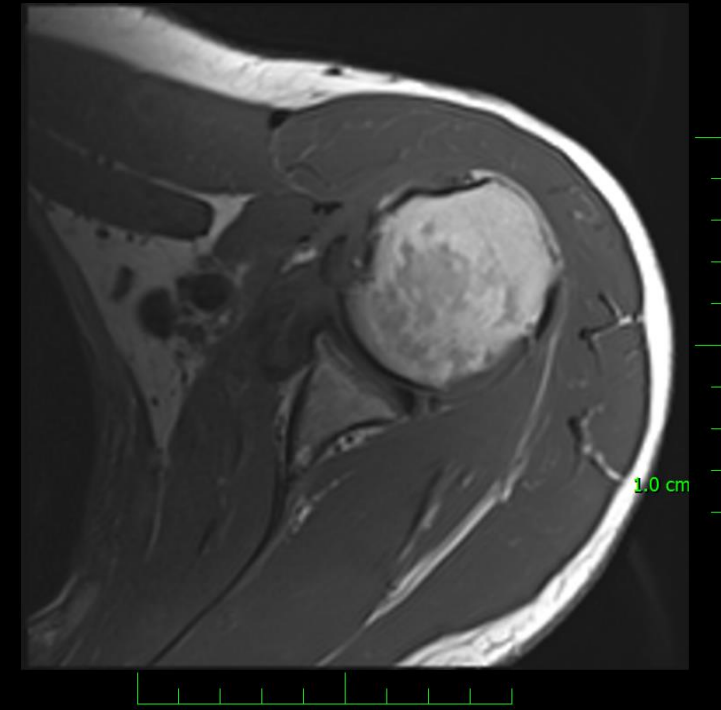
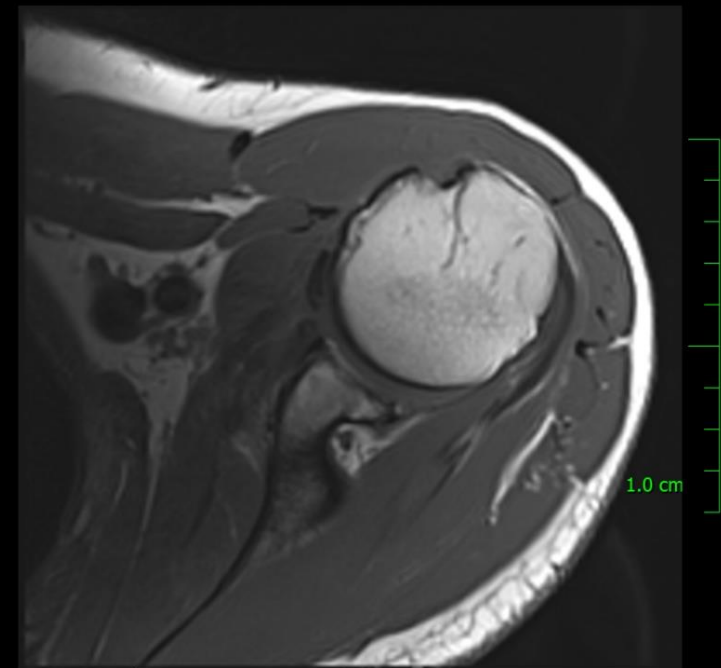
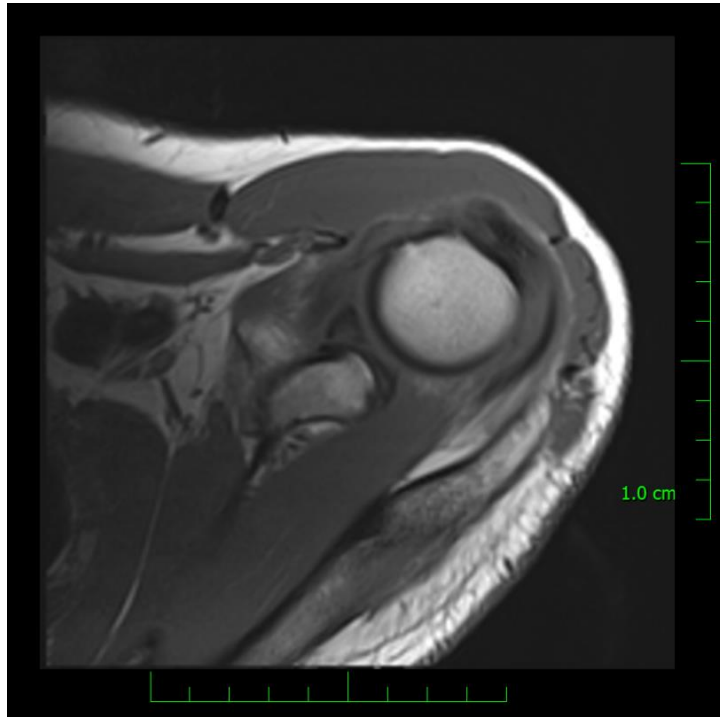
Rotator Cuff Muscles



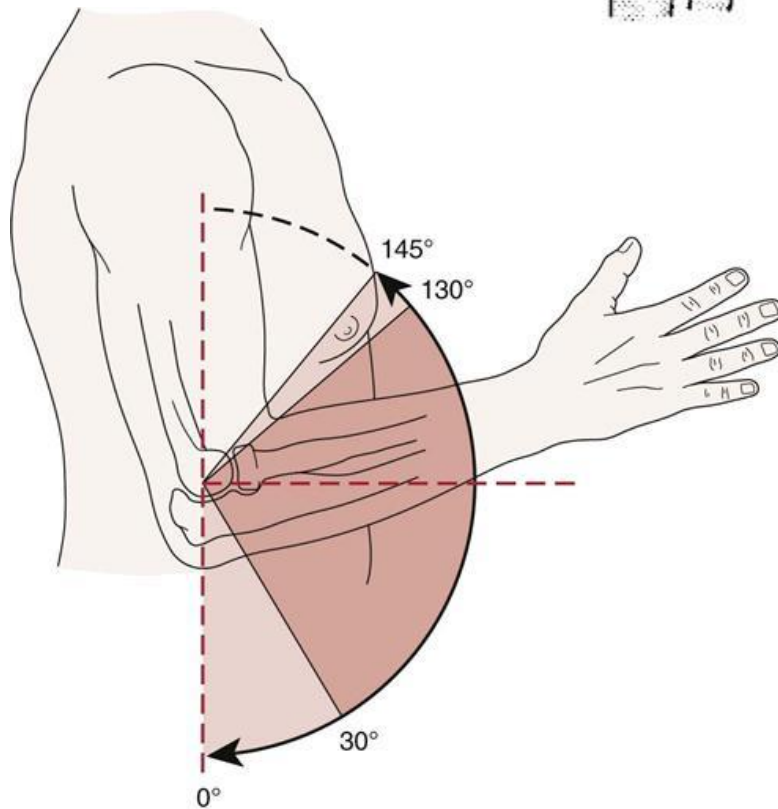
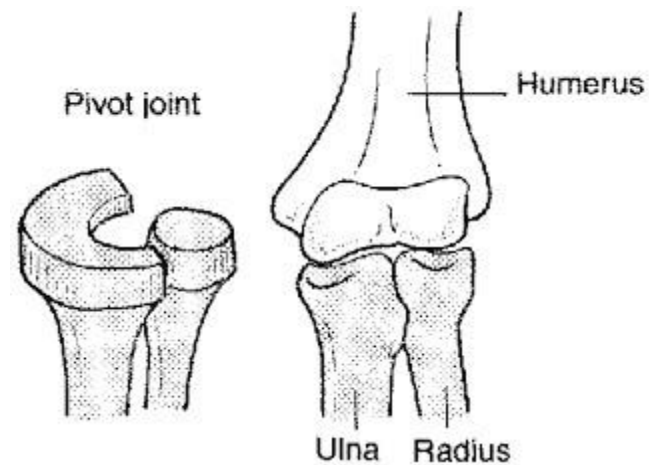
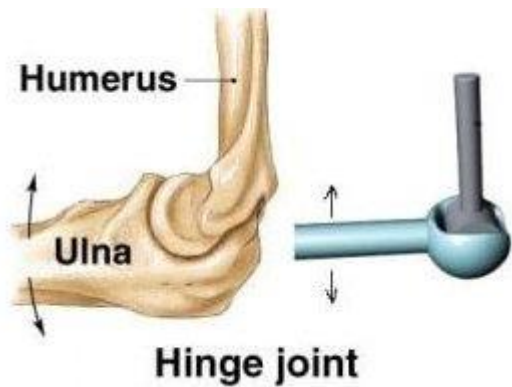
supra spinatus&infraspinatus tendon
 acromion
 acromioclavicular joint
 clavicle
 trapezius muscle
 sup glenoid labrum
 humerus, head
 suprascapular art.&nerve
 deltoid muscle
 glenoid
 inf glenoid labrum
 subscapular muscle
 articular capsule
 subscapular artery
 postcircumflex humeral artery
 teres major & latissimus dorsi muscle

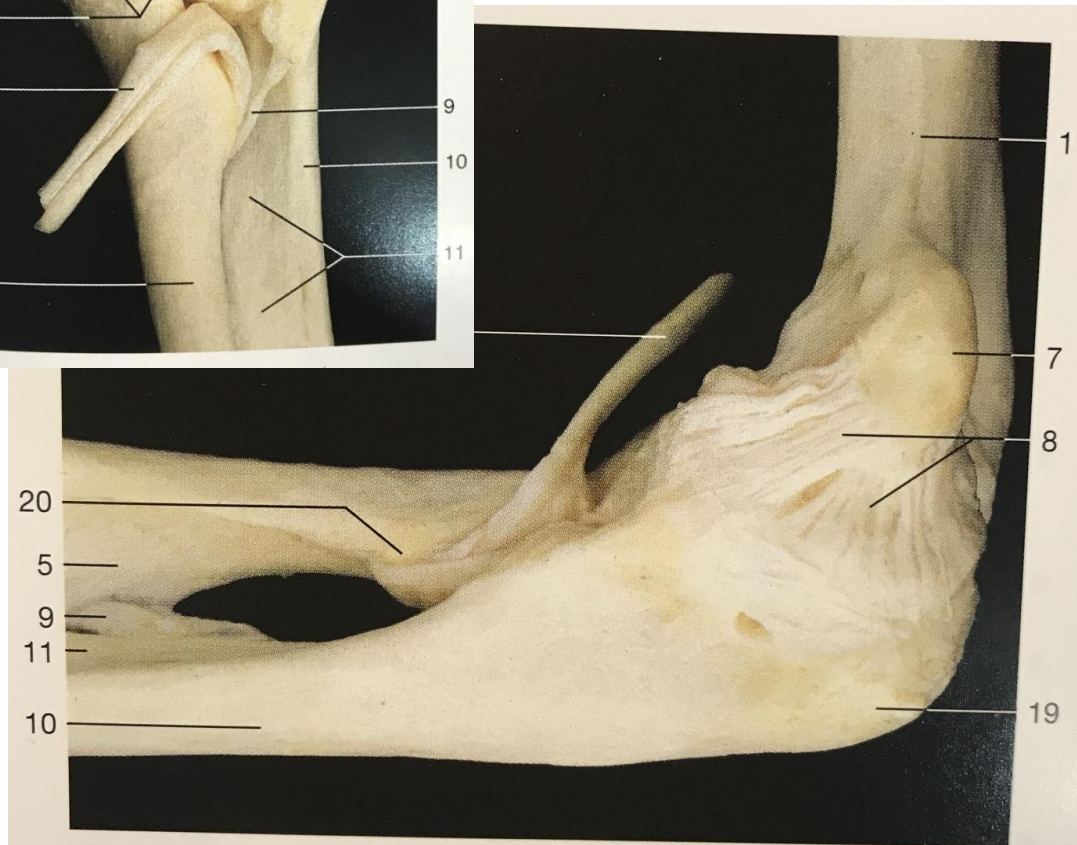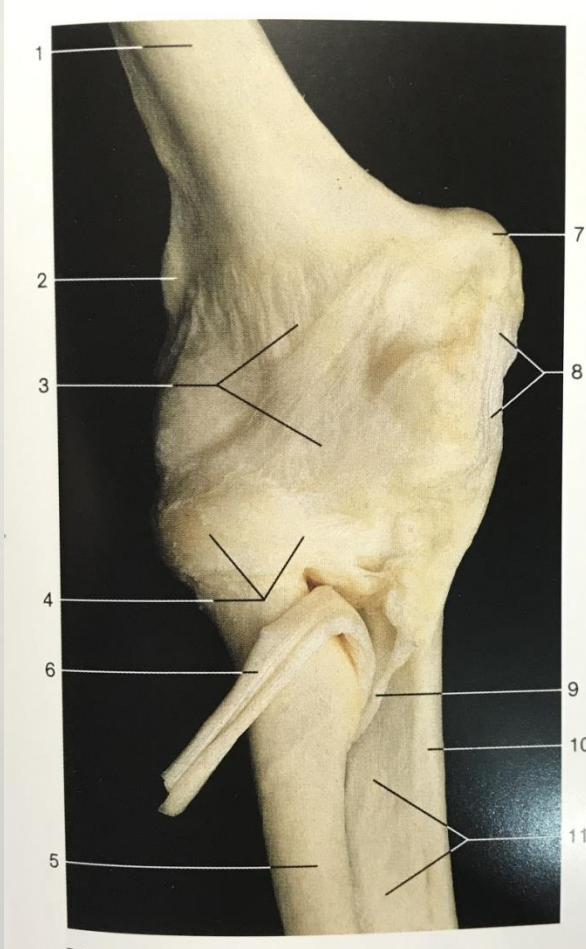
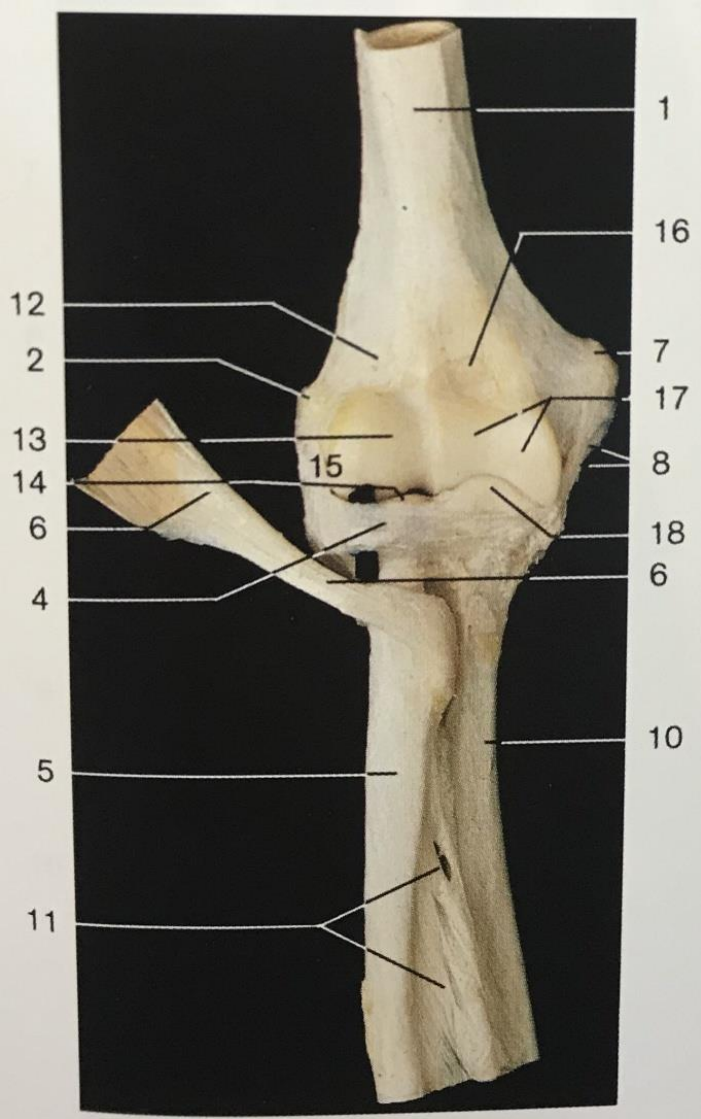


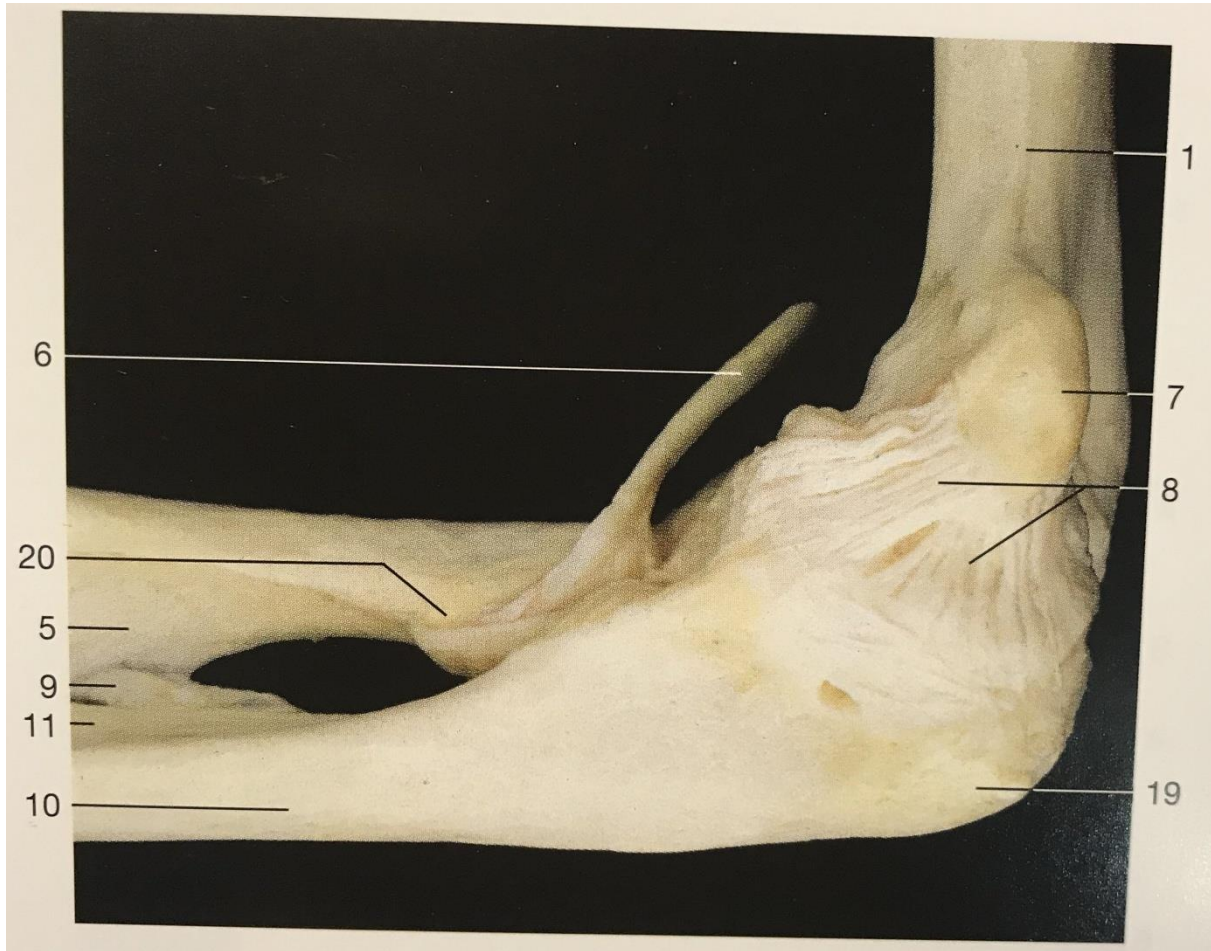Rotator Cuff Muscles - MRI

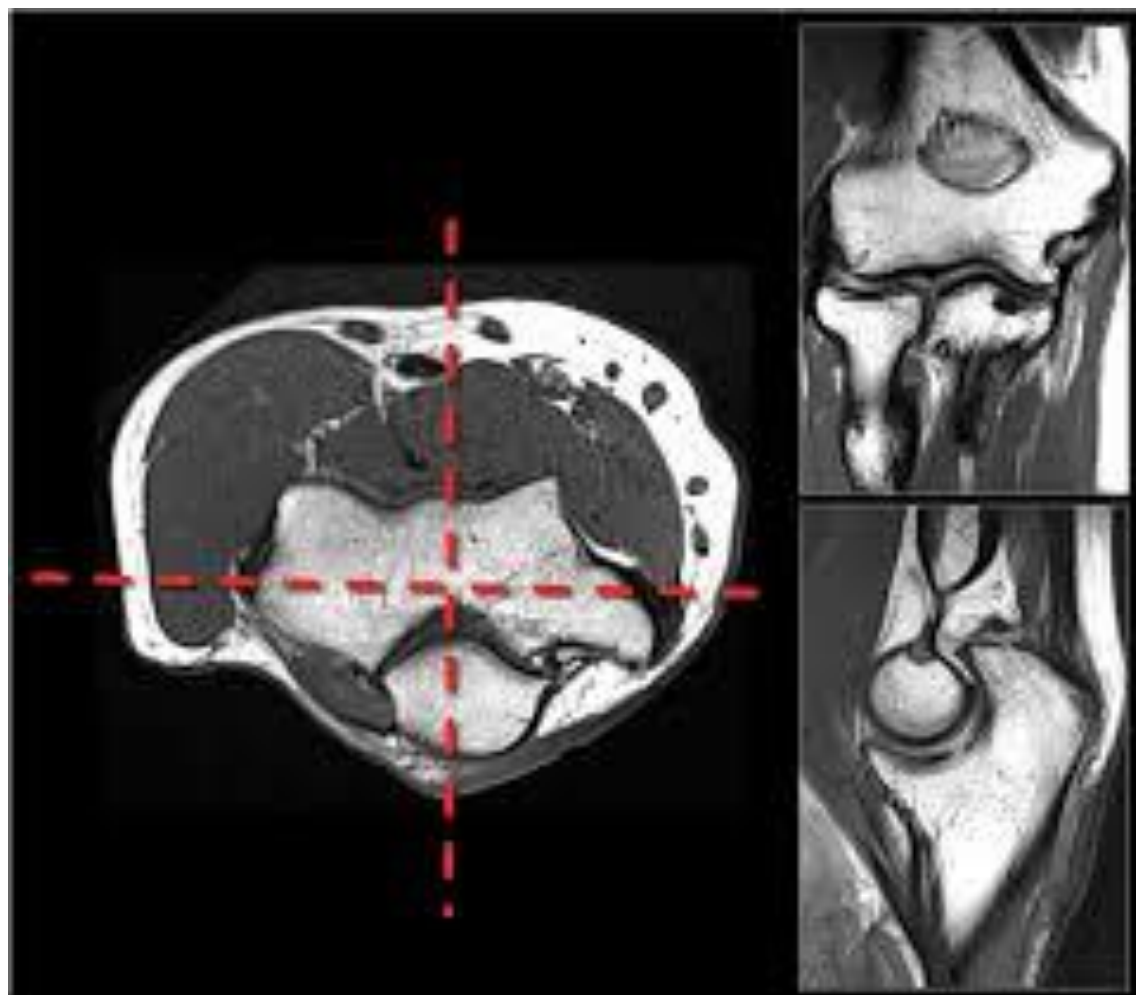


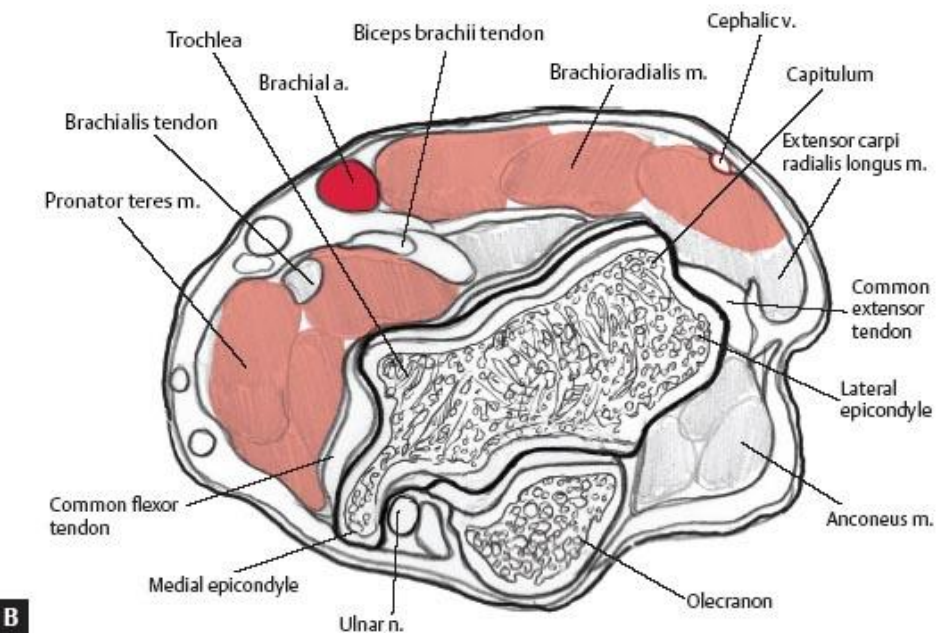
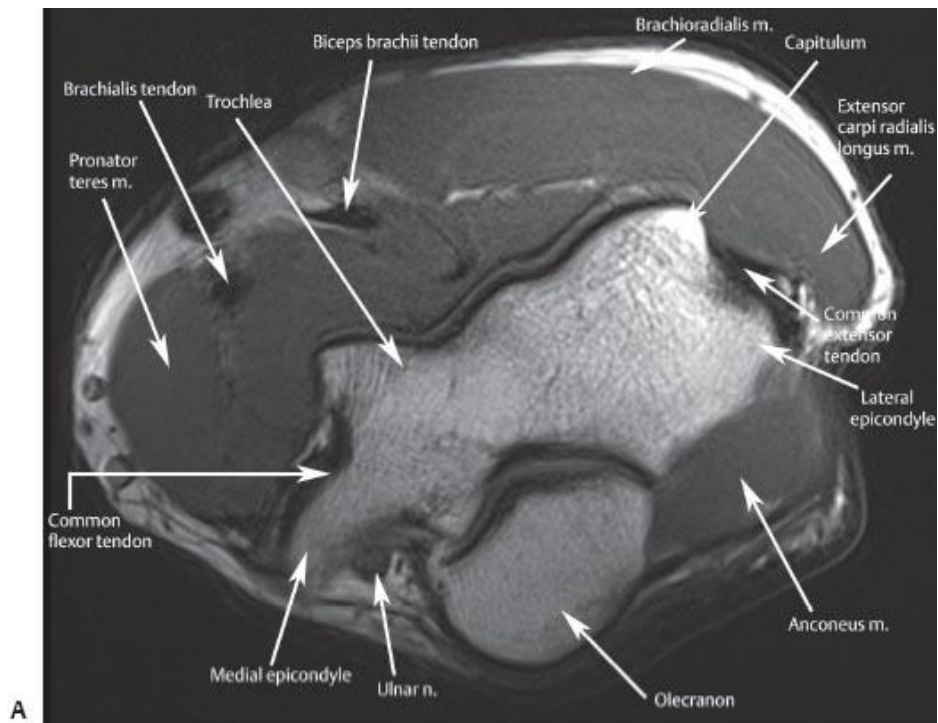
Elbow joint (*Articulatio cubiti*)

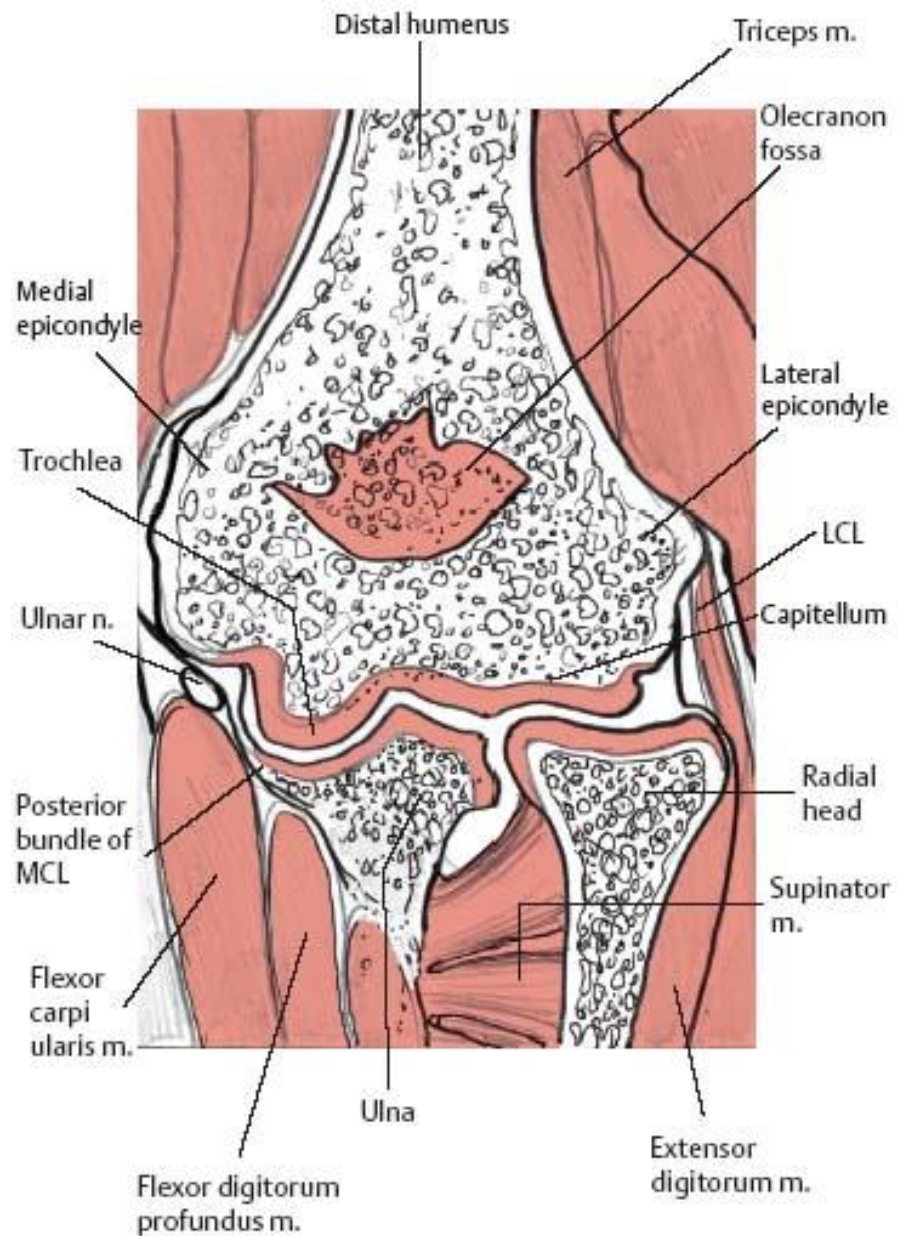
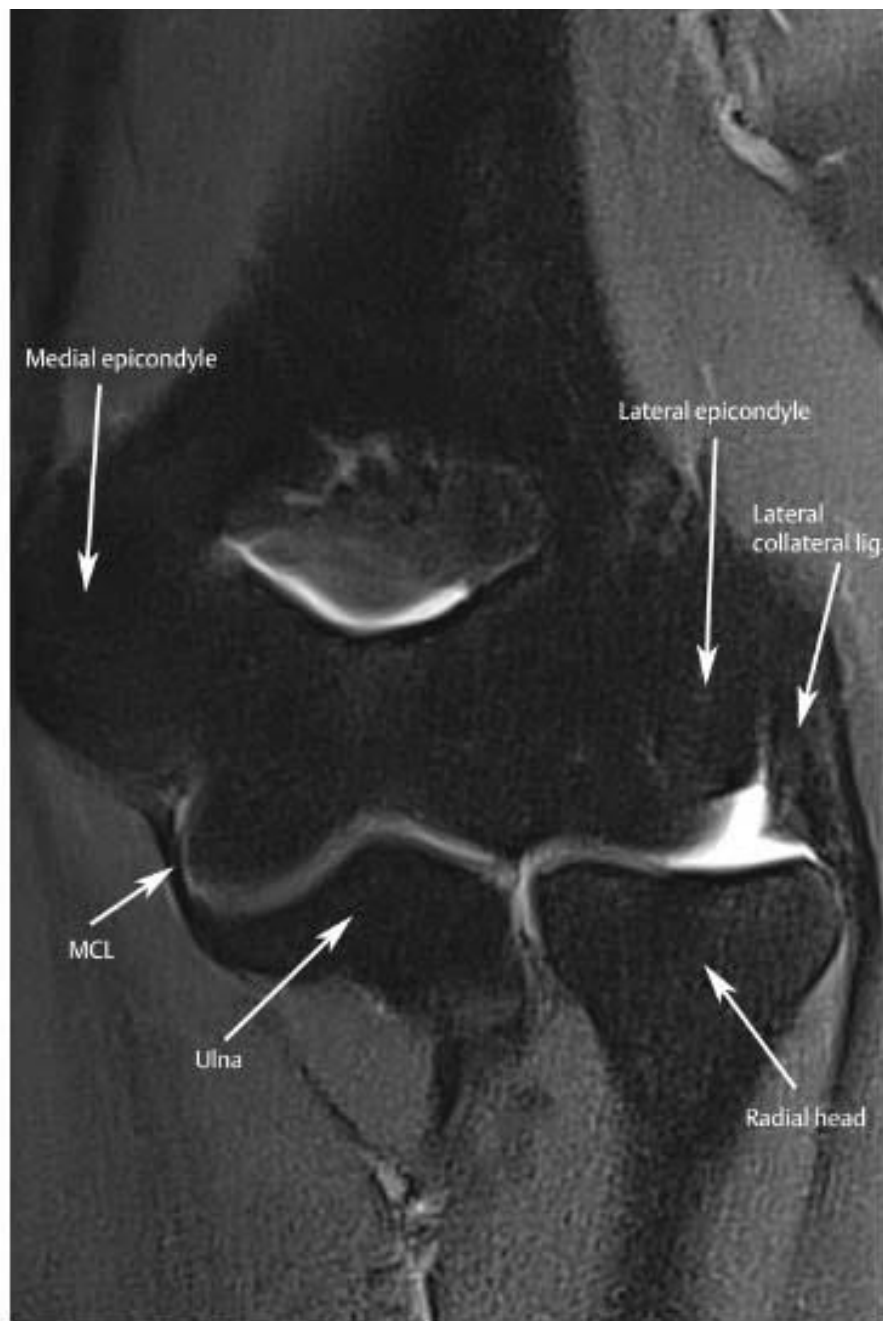


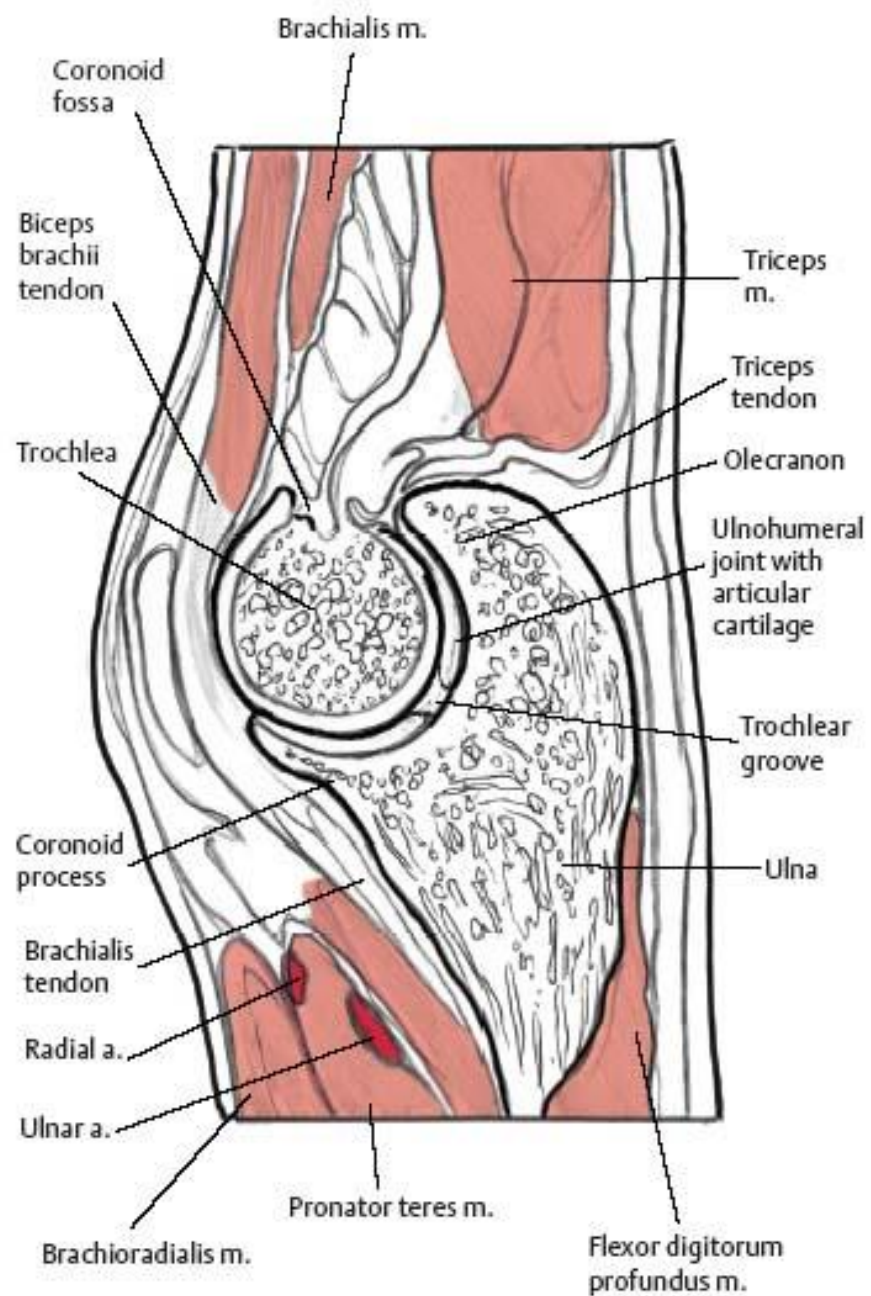
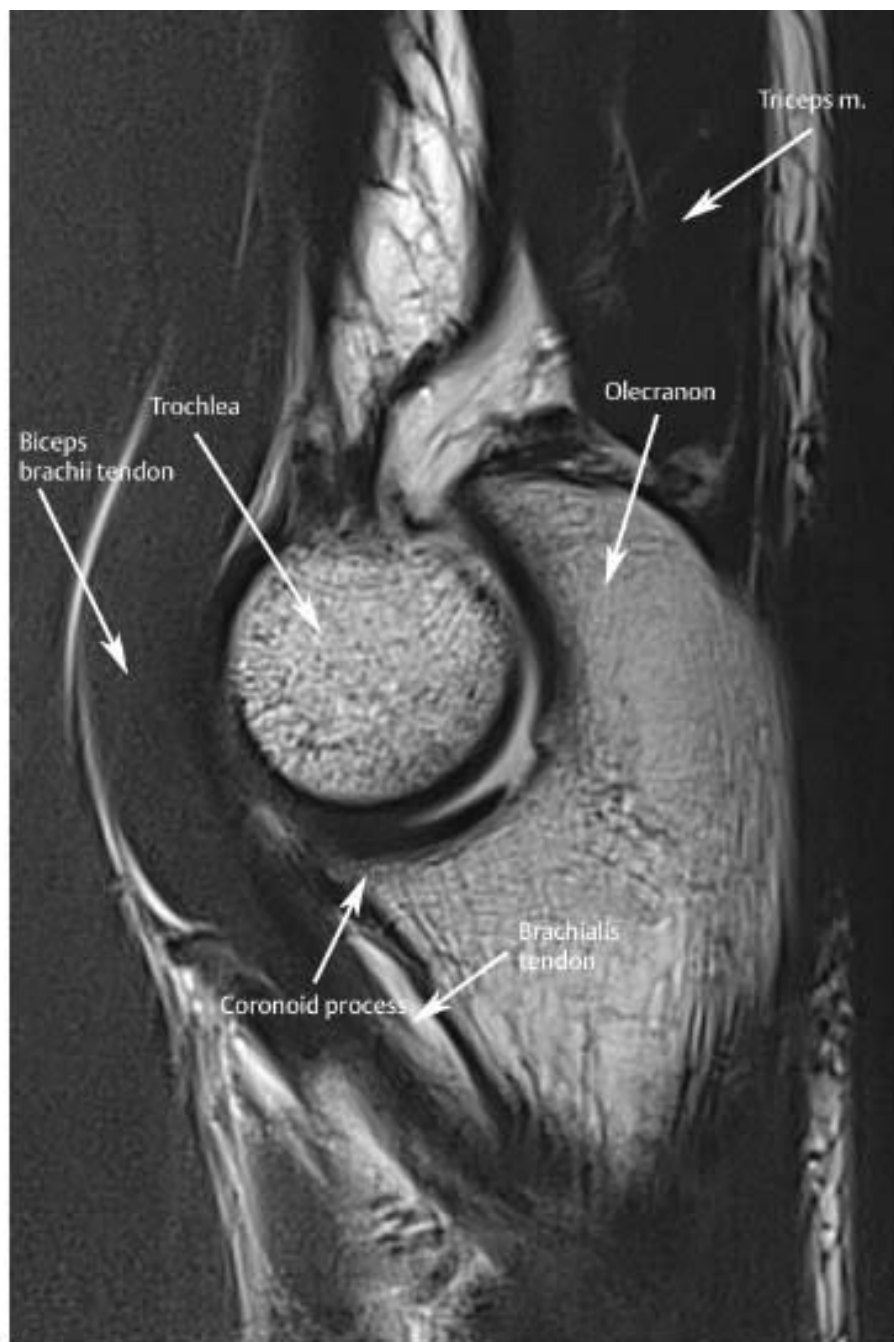




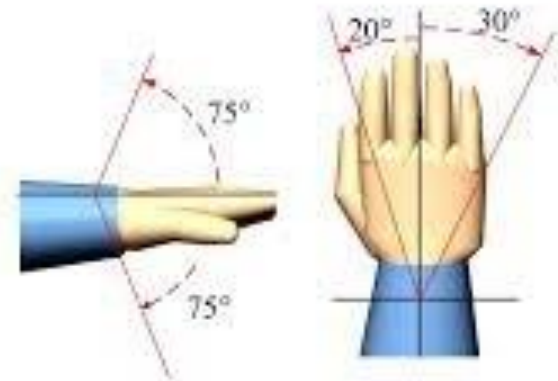
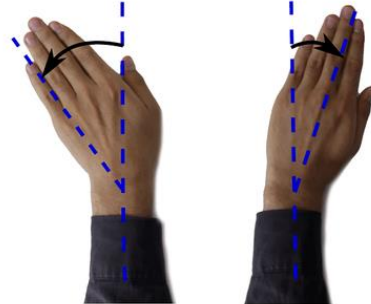

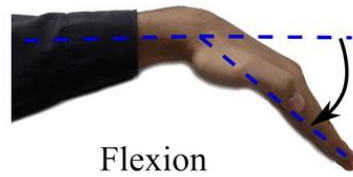
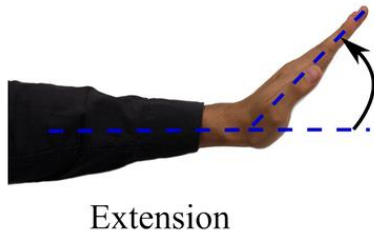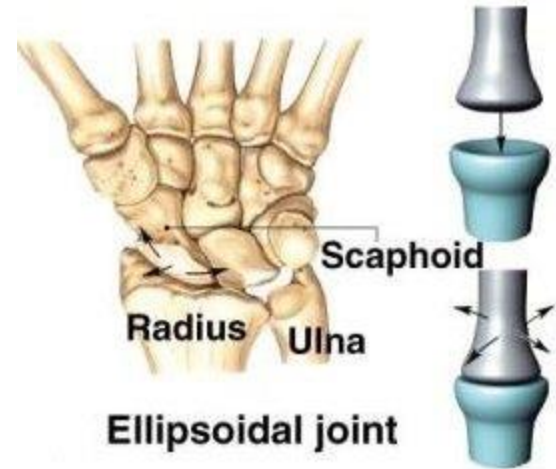
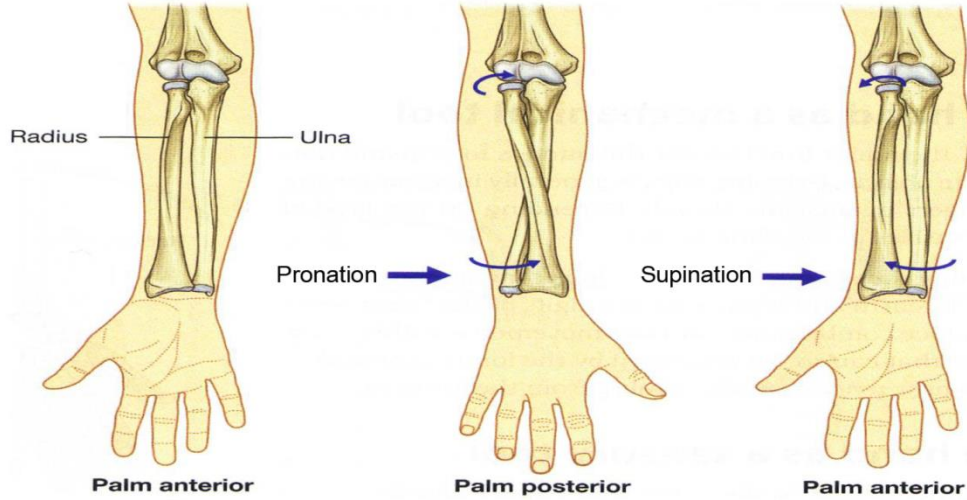




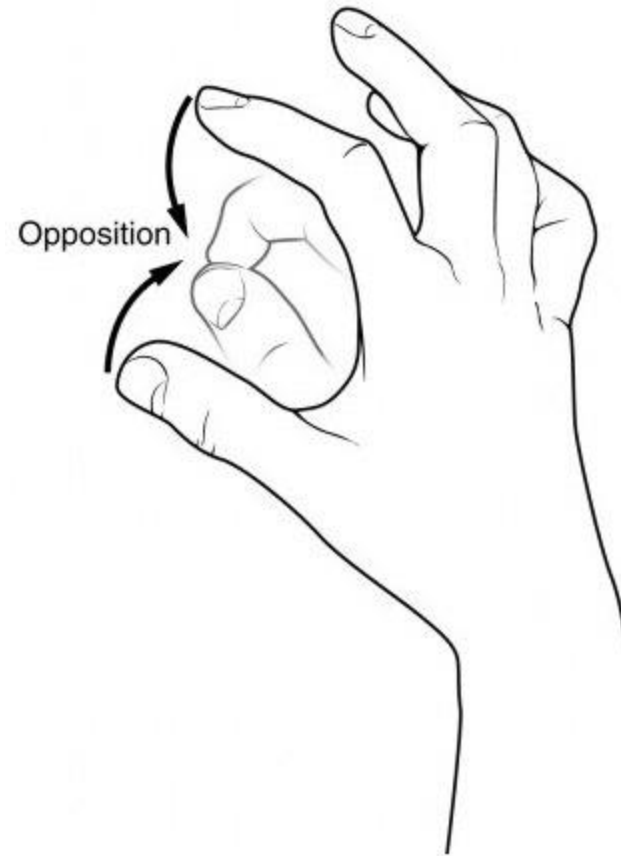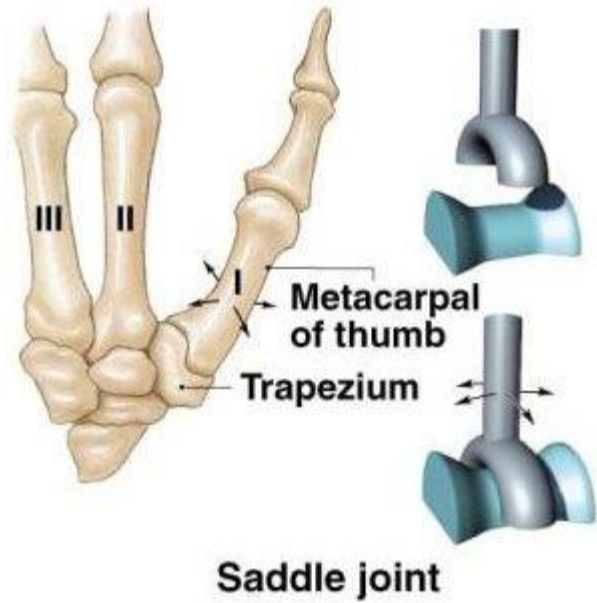


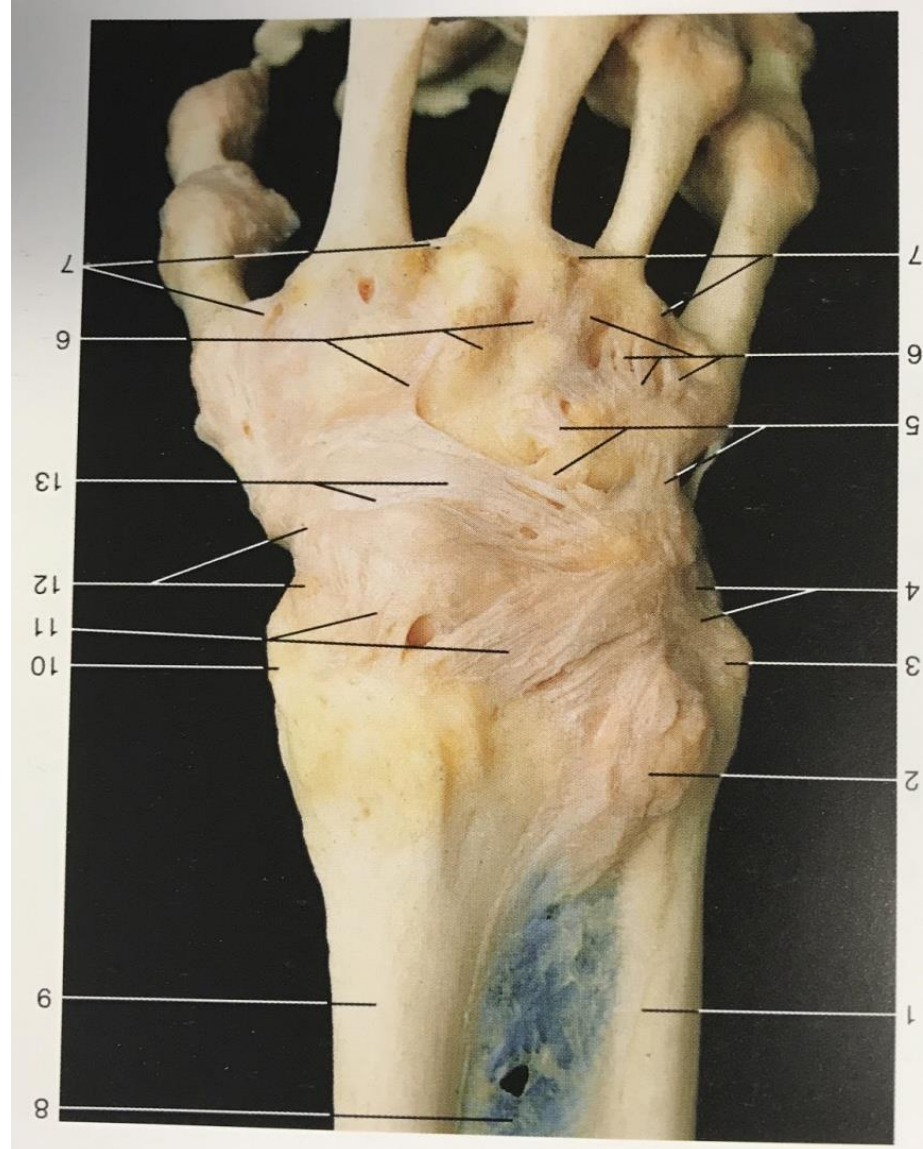
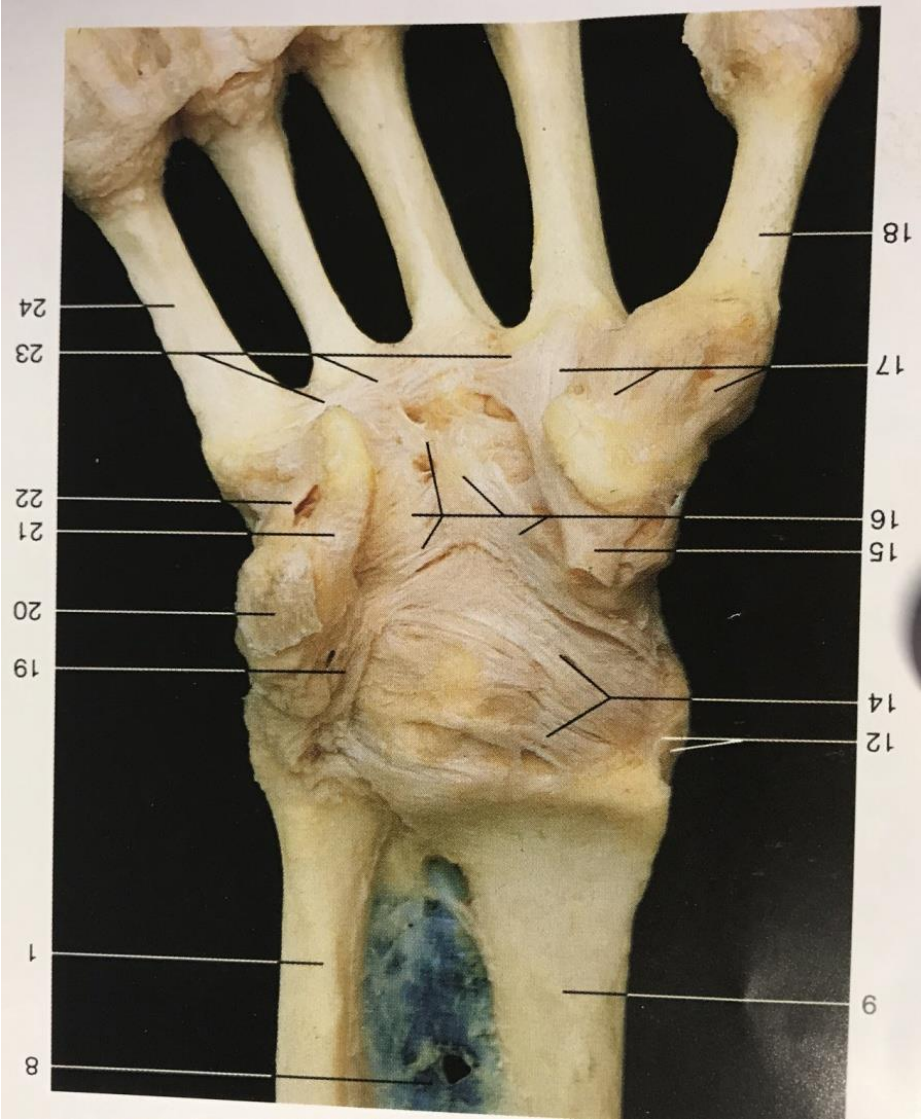


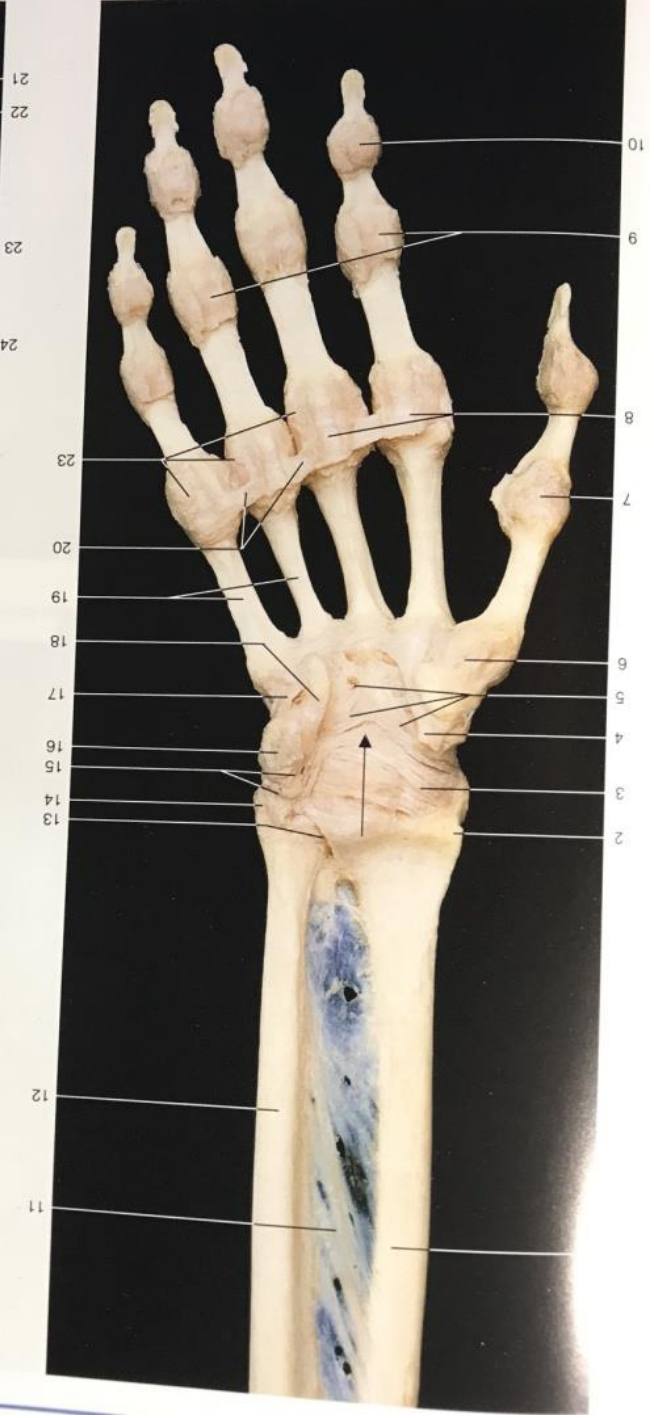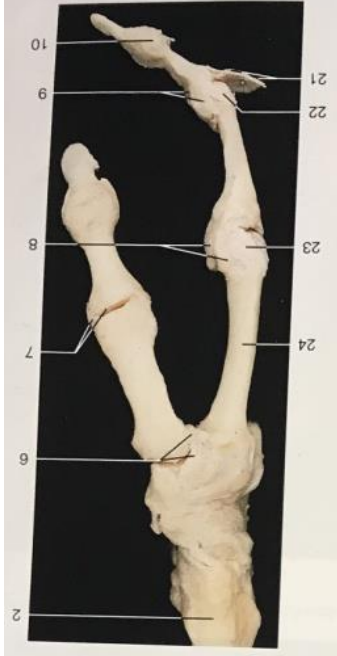Wrist joint (*Articulatio radiocarpalis*)

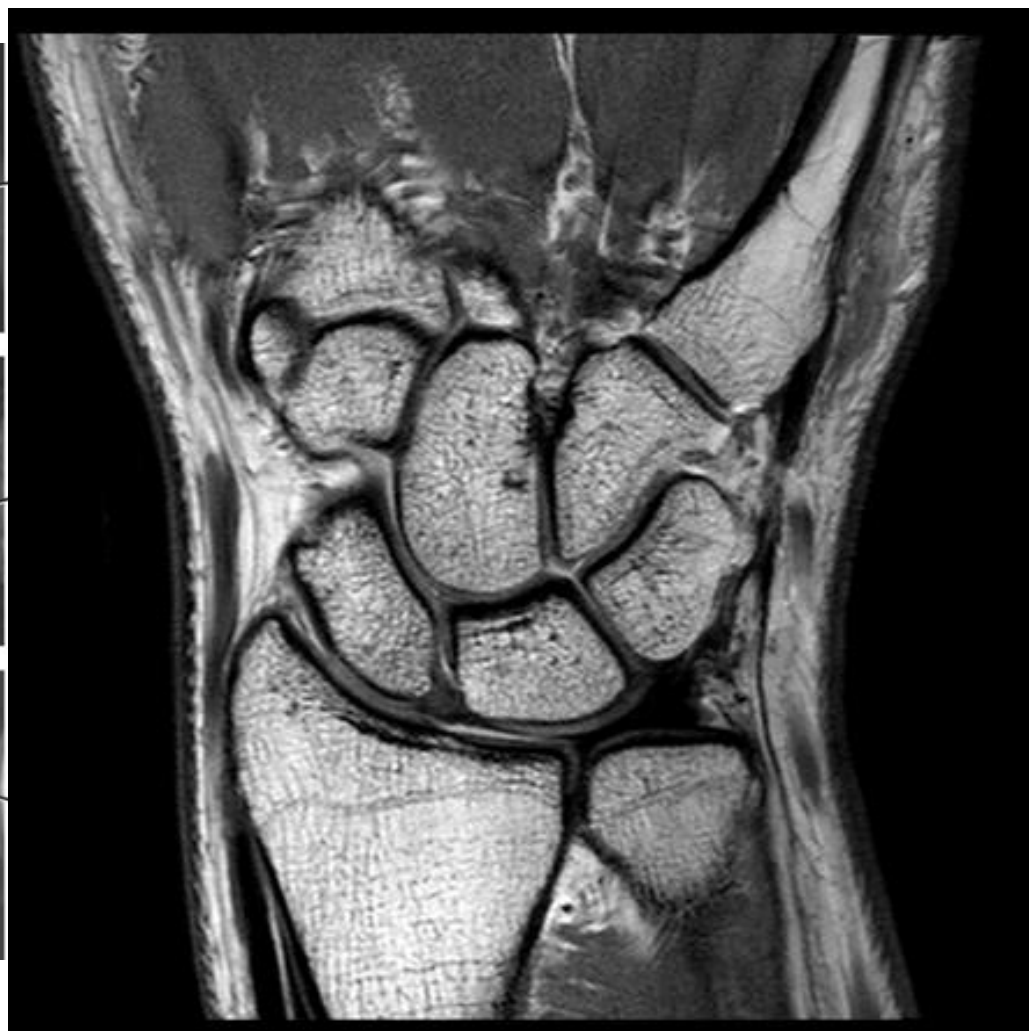
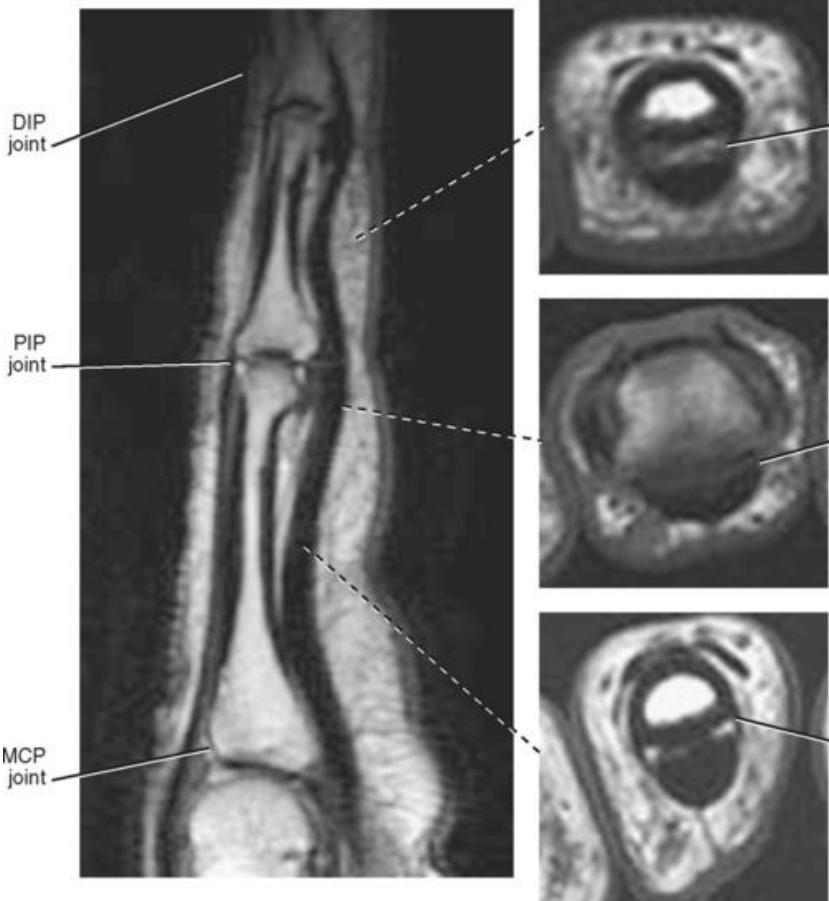
Joints of the hand (*Articulationes manus*)

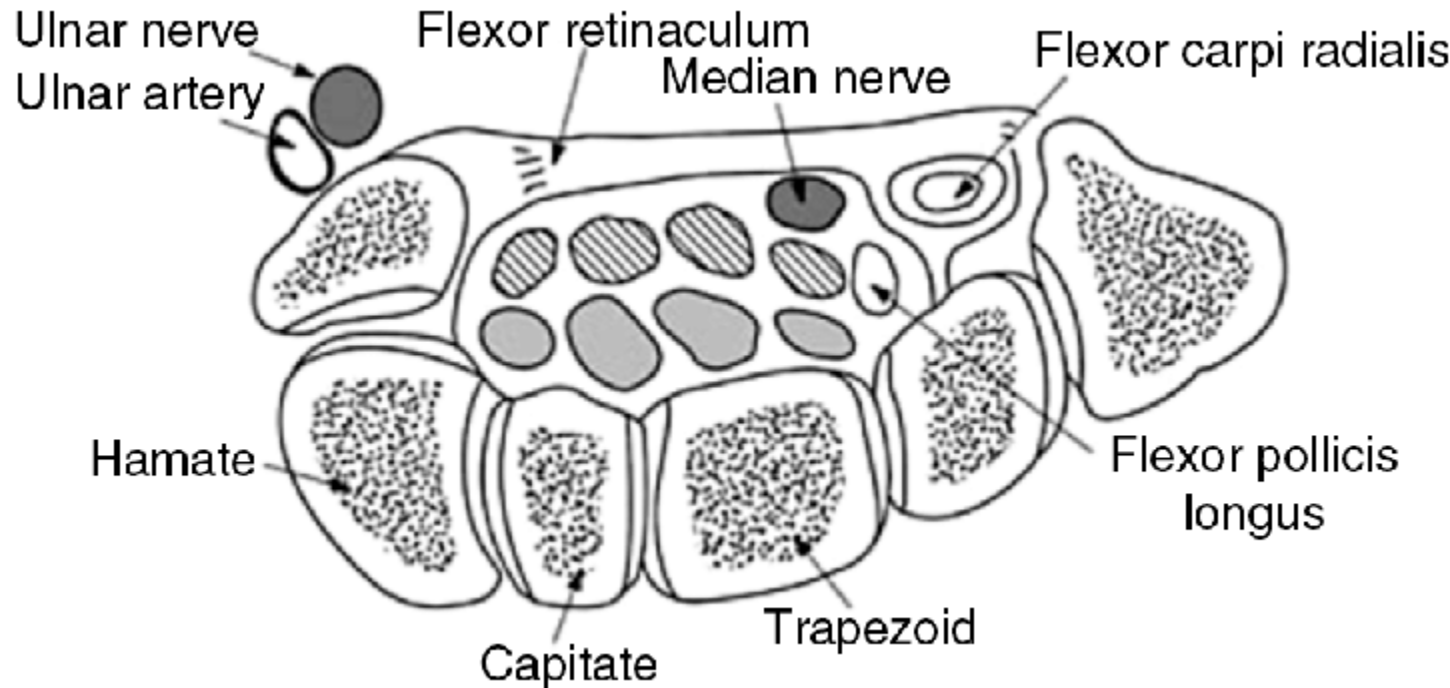
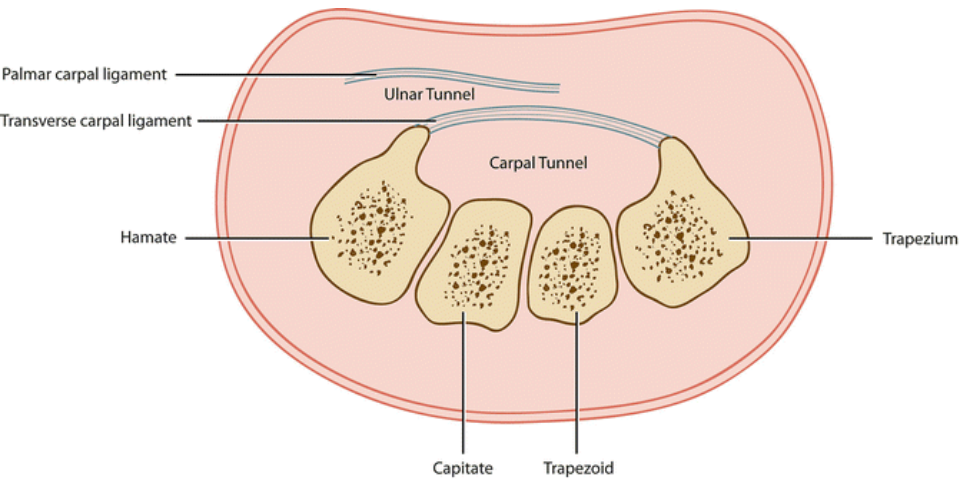


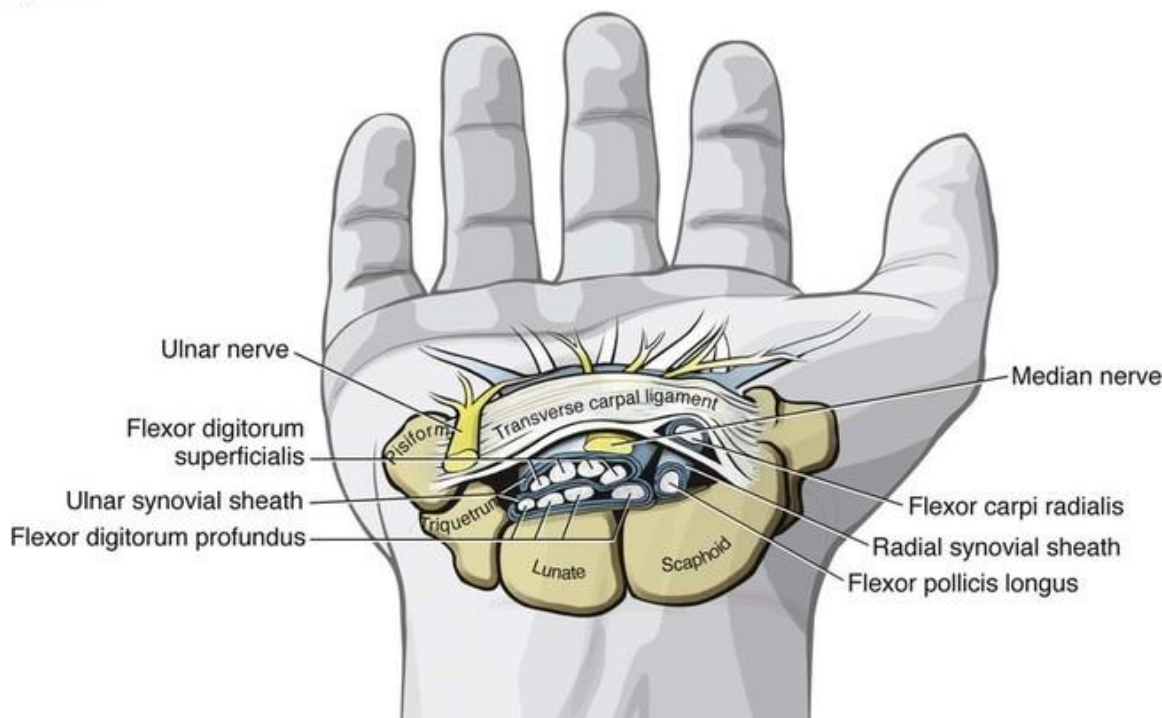
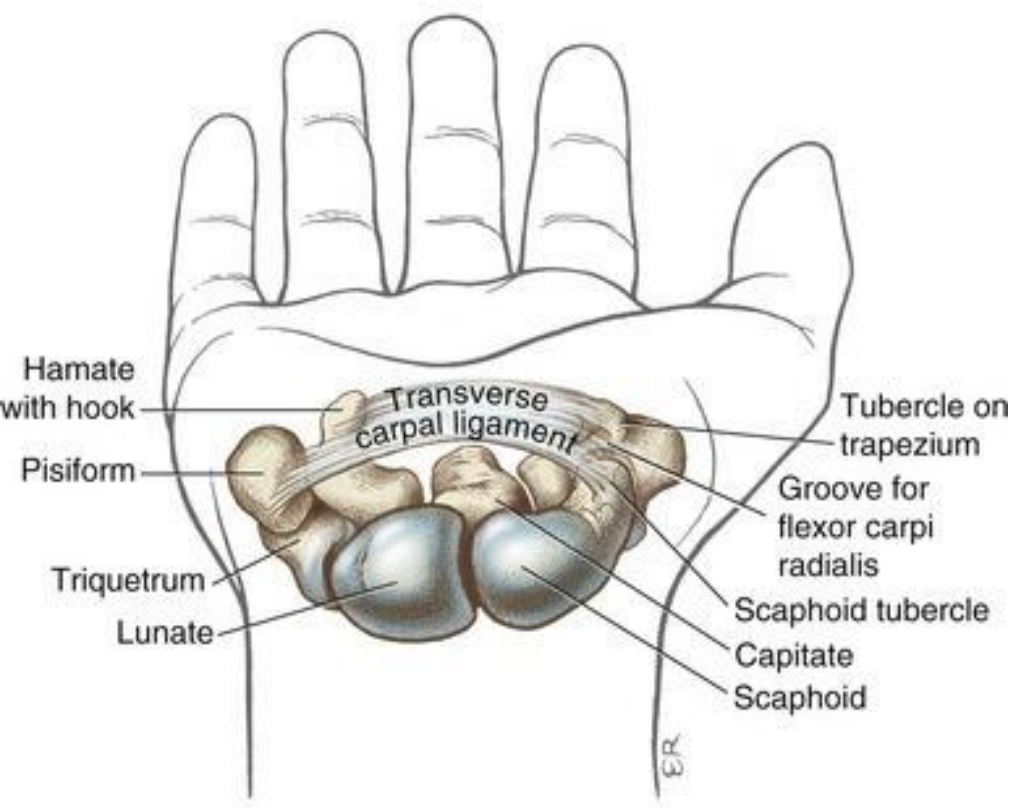


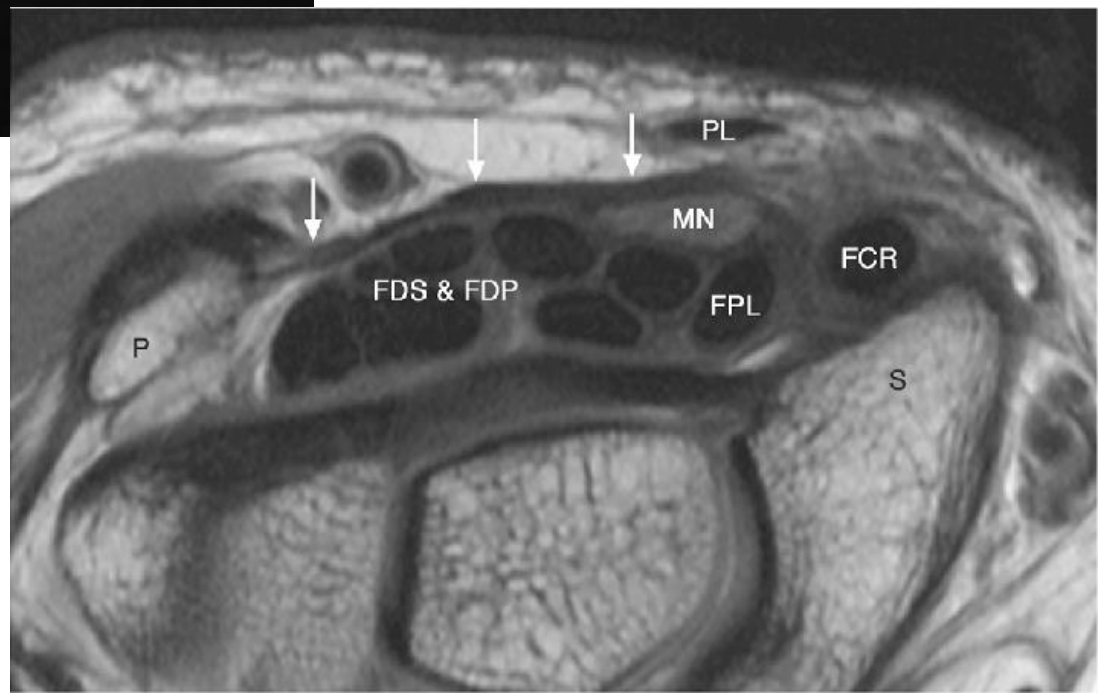
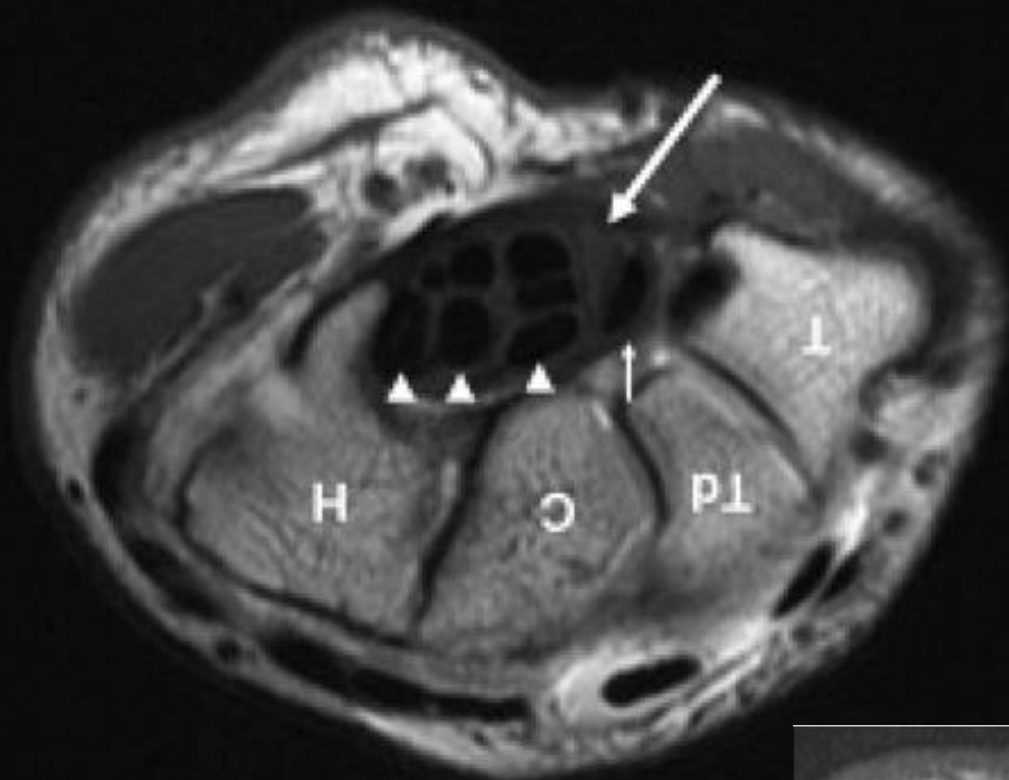




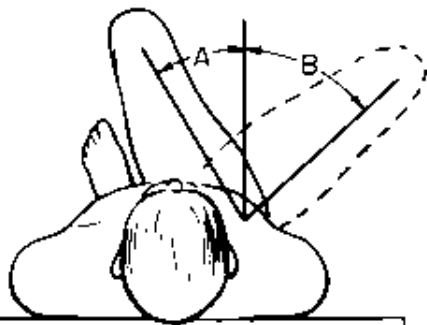
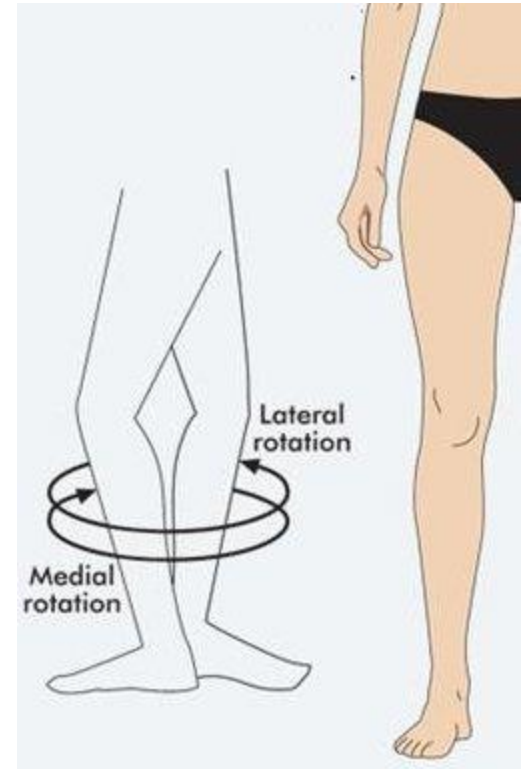
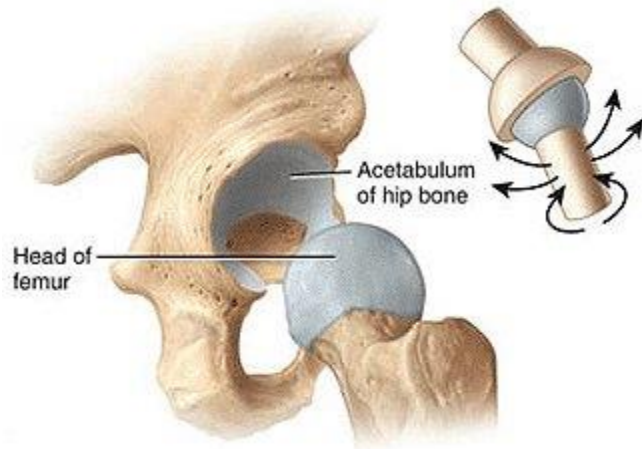
Carpal Canal (*Canalis carpi*)



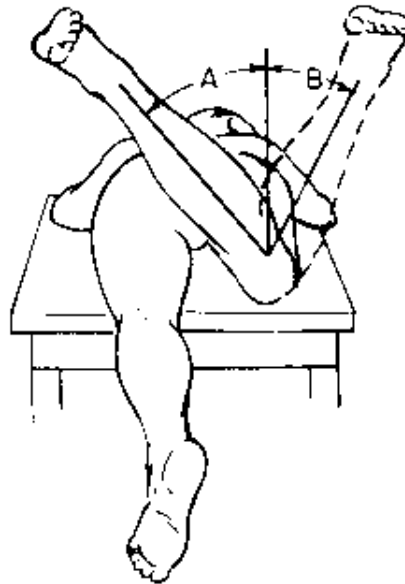




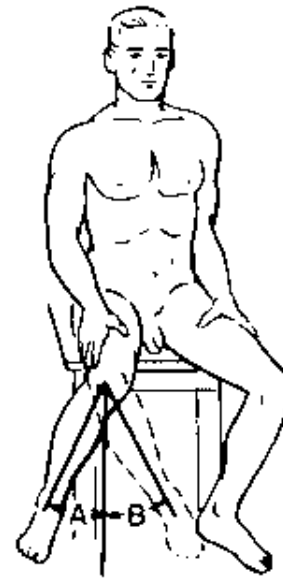The Hip Joint (*Articulatio coxofemoralis*)



HIP ADDUCTION (A),
ABDUCTION (B)

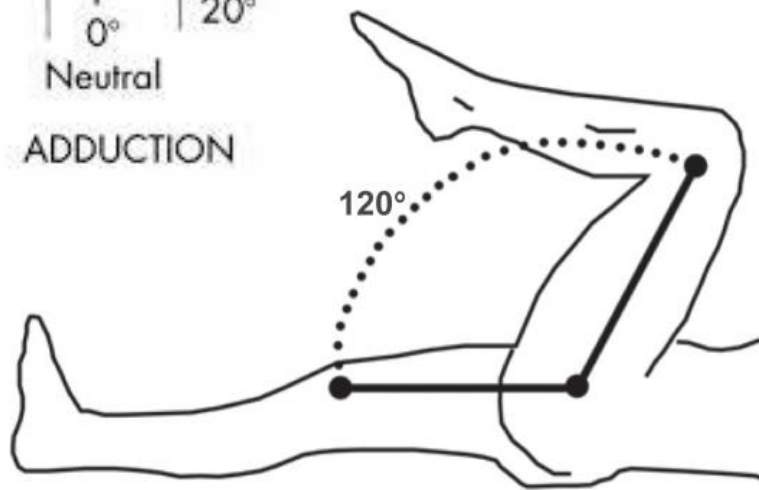
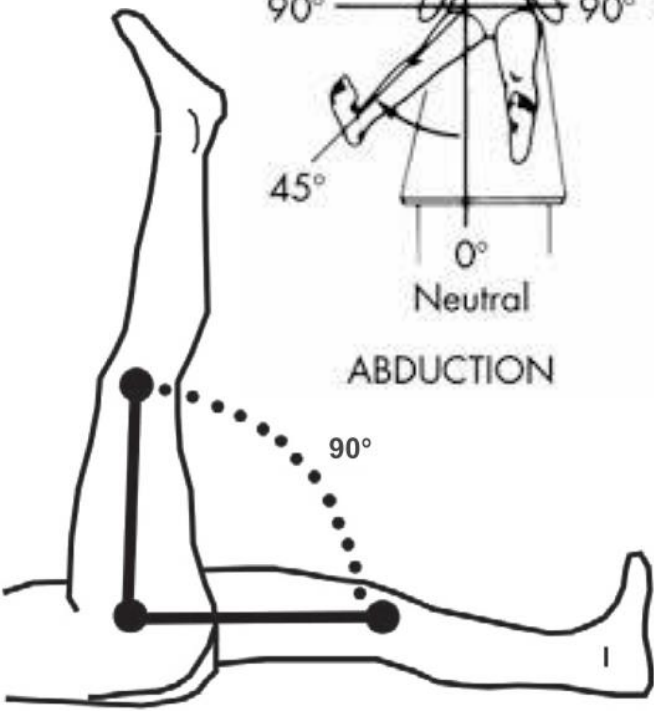
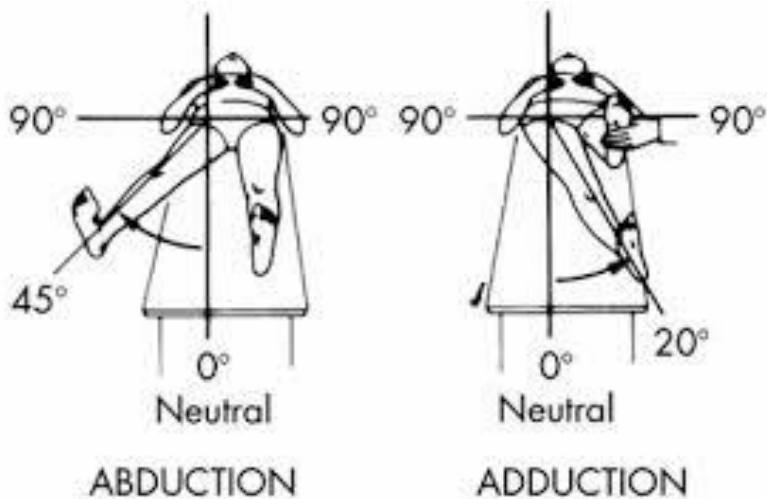
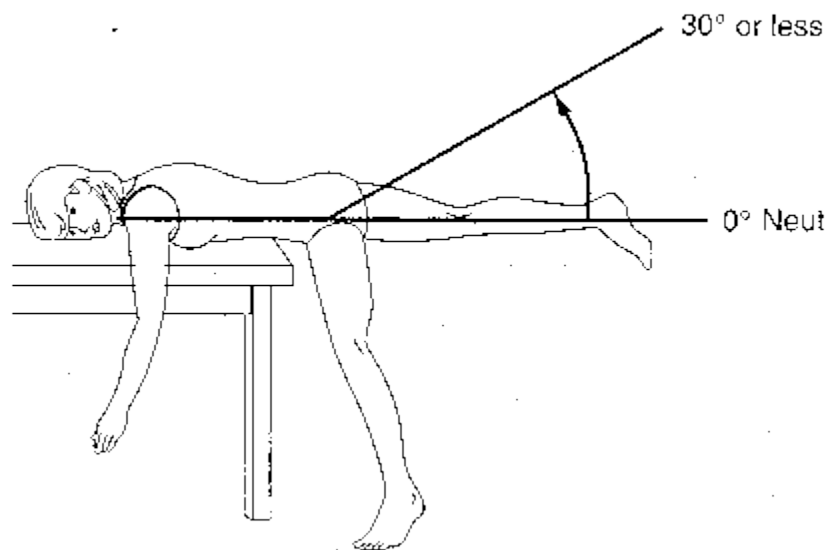
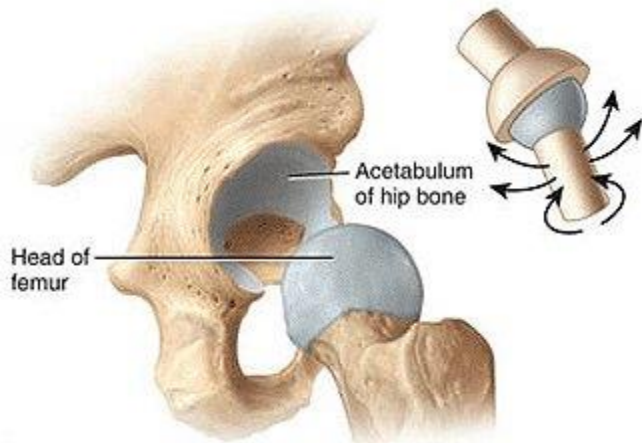


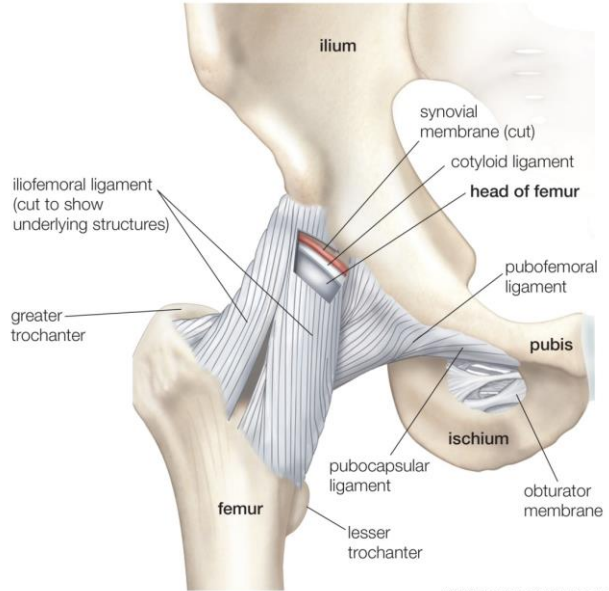
HIP ROTATION, PRONE,
MEDIAL (A),
LATERAL (B)



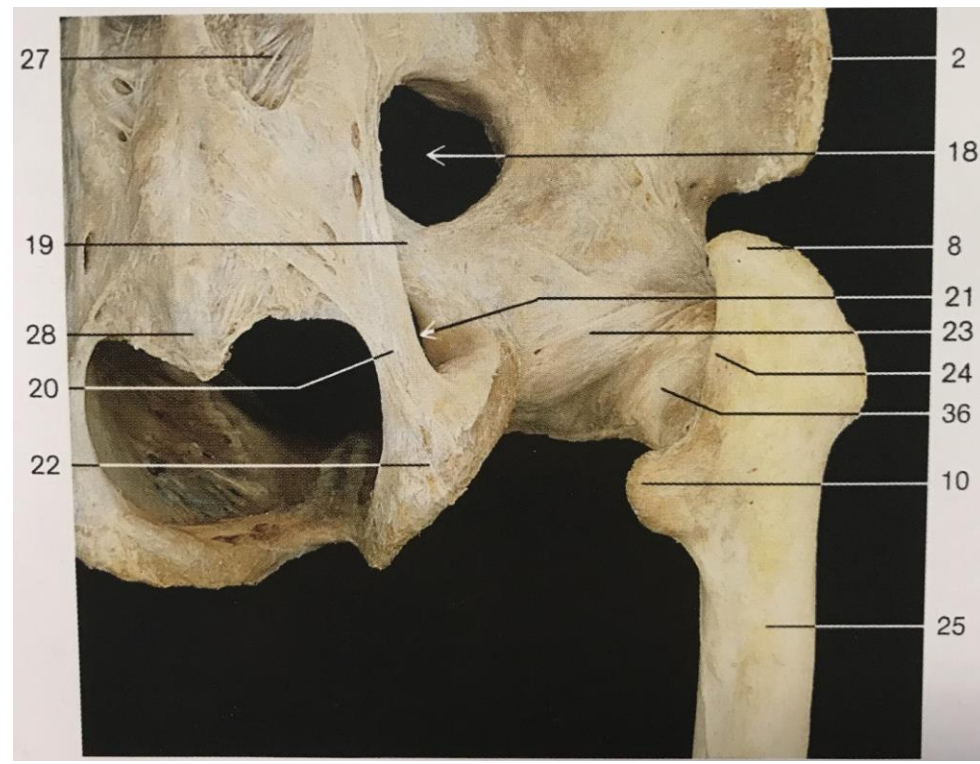
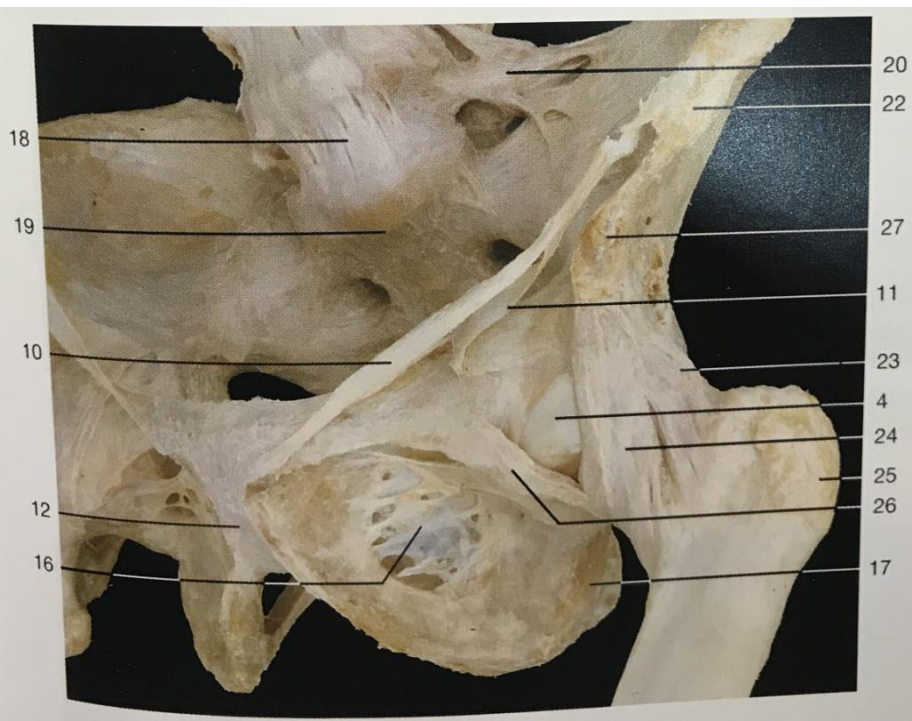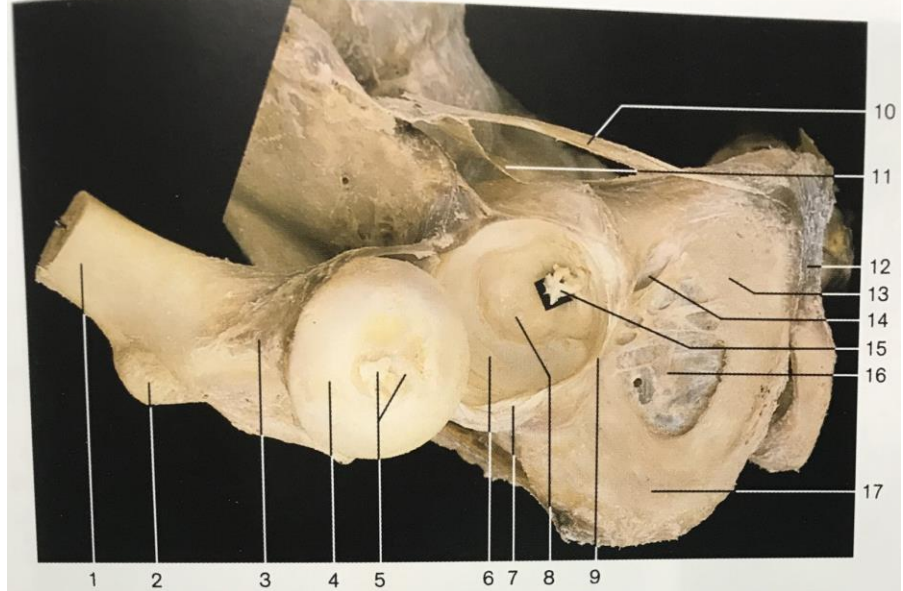
HIP ROTATION,
SITTING,
LATERAL (A),
MEDIAL (B)

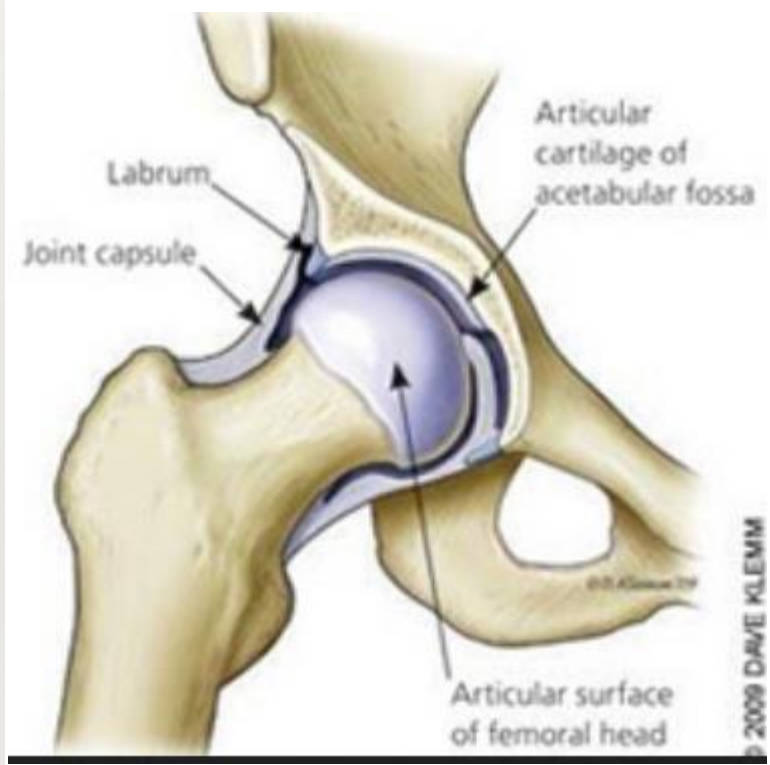
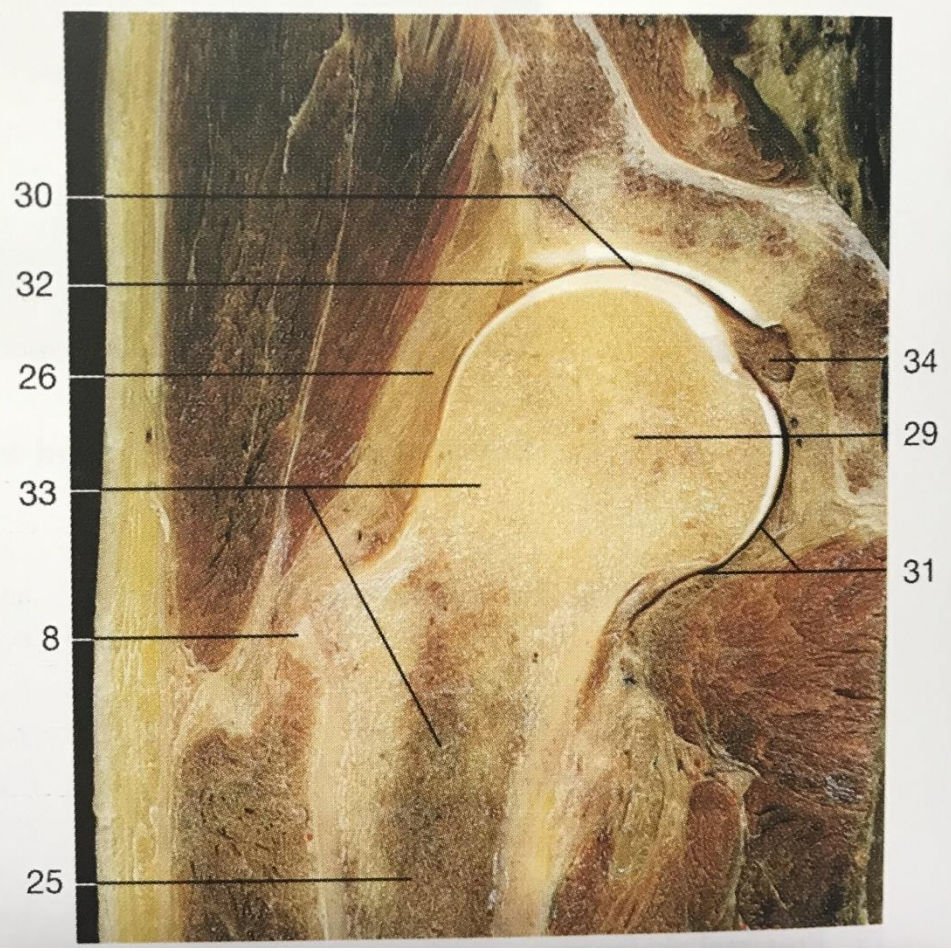
The Hip Joint (*Articulatio coxofemoralis*)



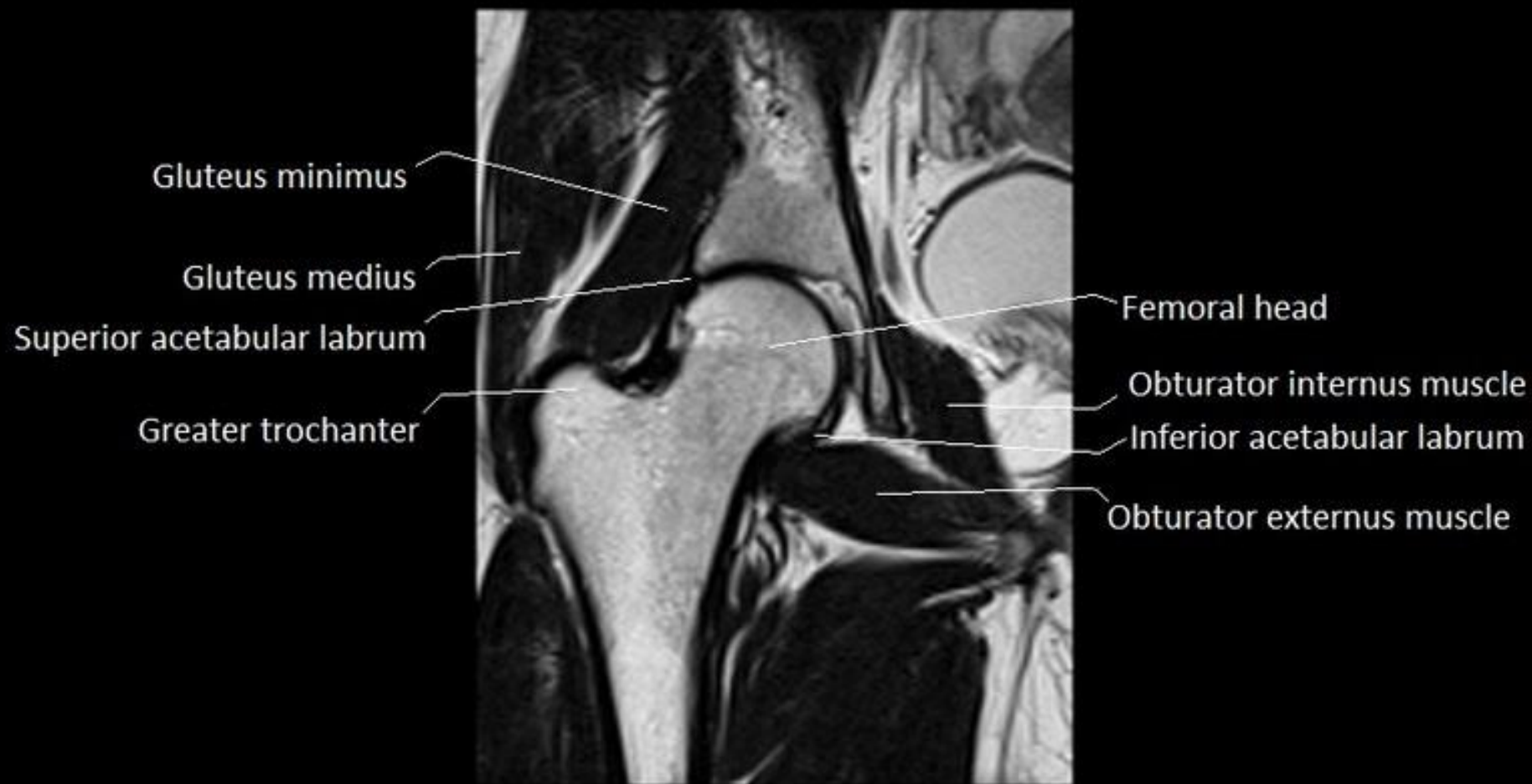


© 2011 Encyclopaedia Britannica, Inc.

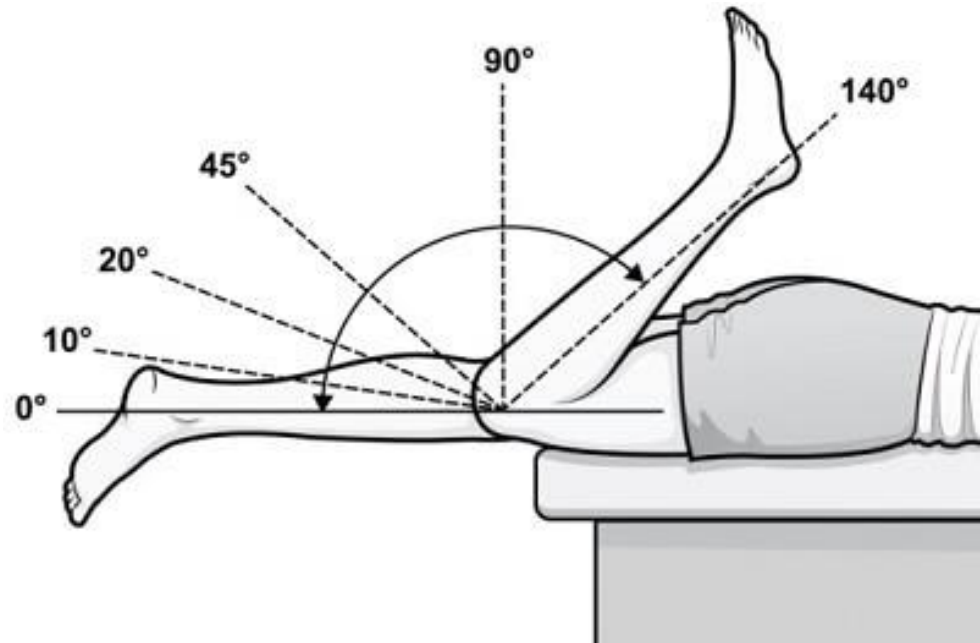
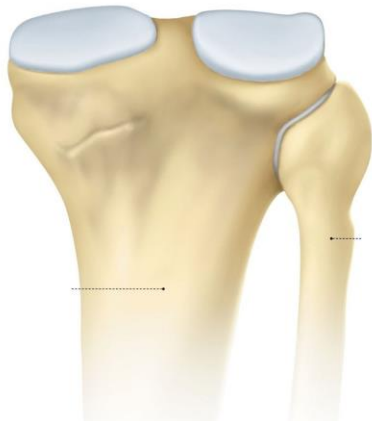
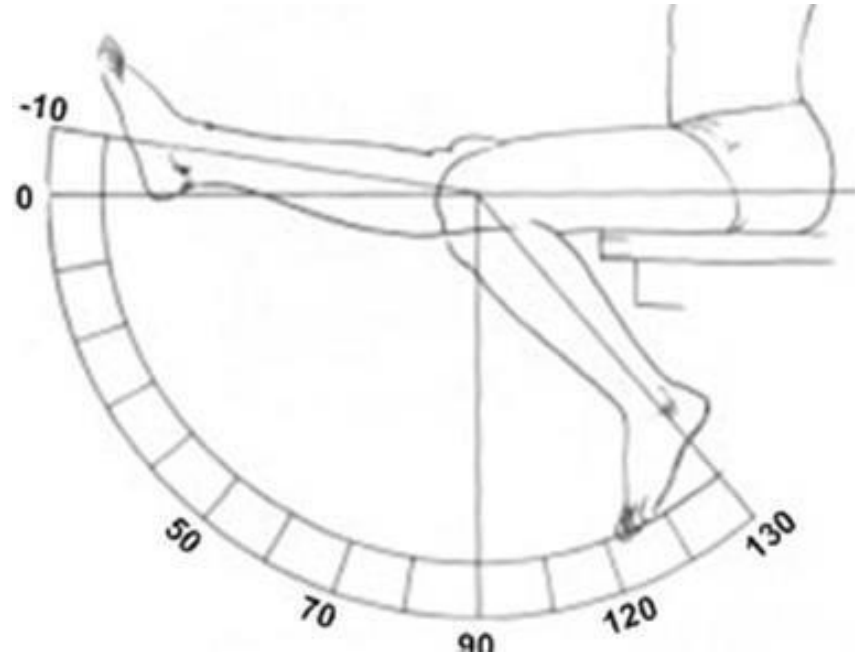
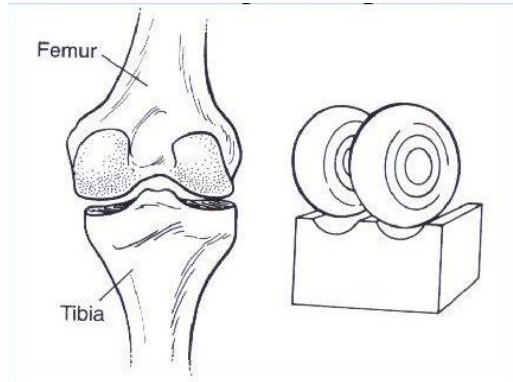




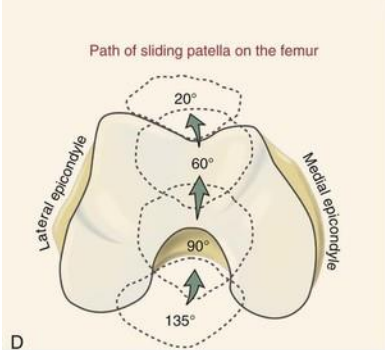
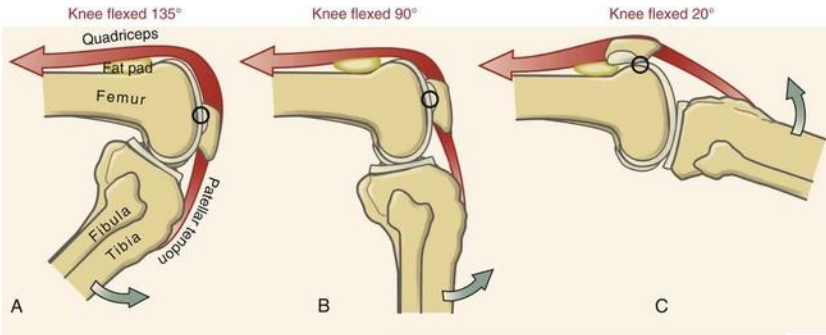
© 2009 DAVE KLEMM



The Knee Joint (*Articulatio genus*)

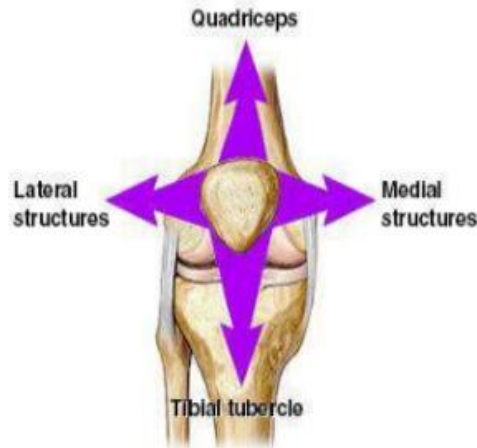


The role of the Patella



STABILITY

- Transvers group of stabilizer
- Longitudinal group of stabilizer

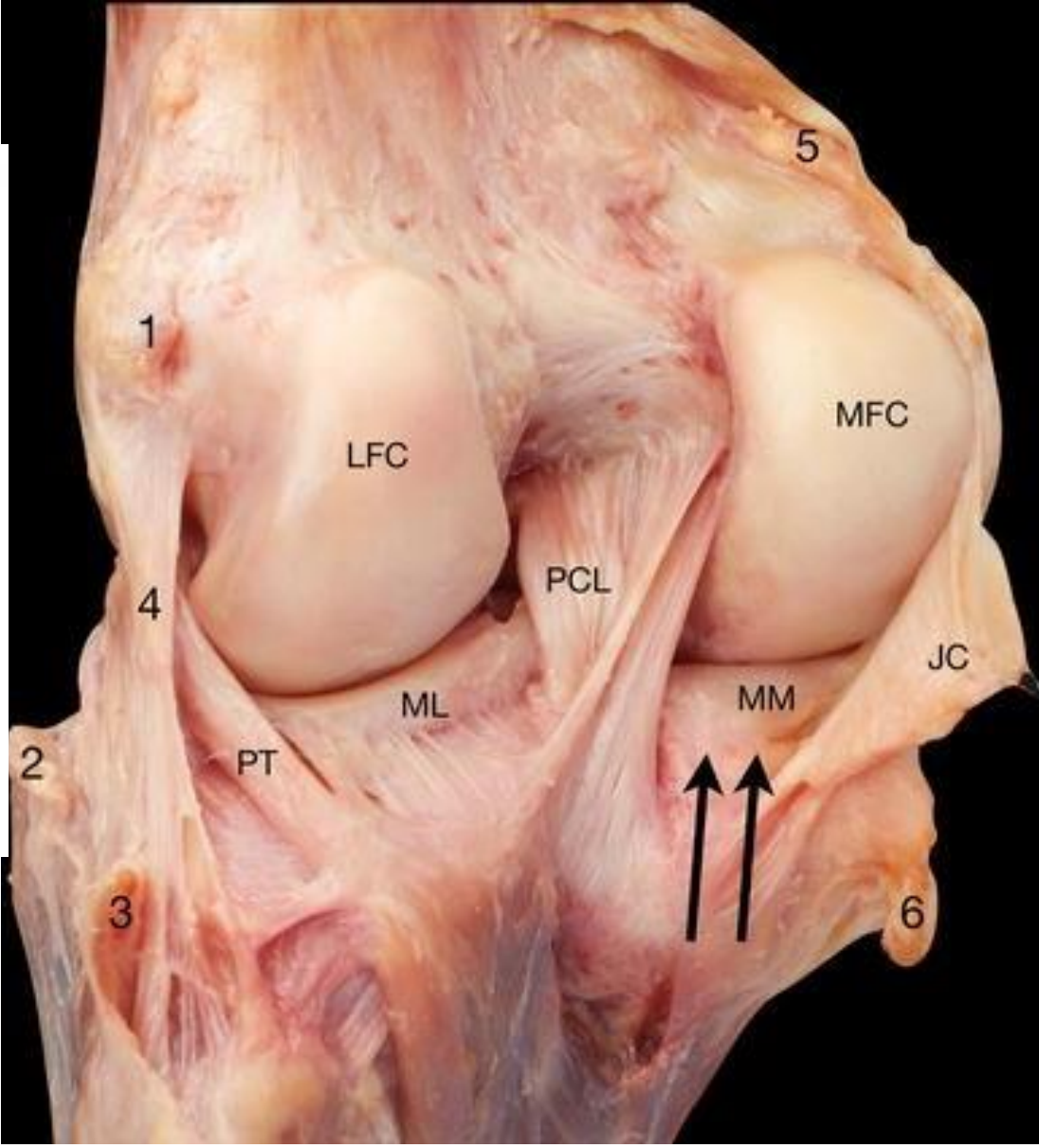
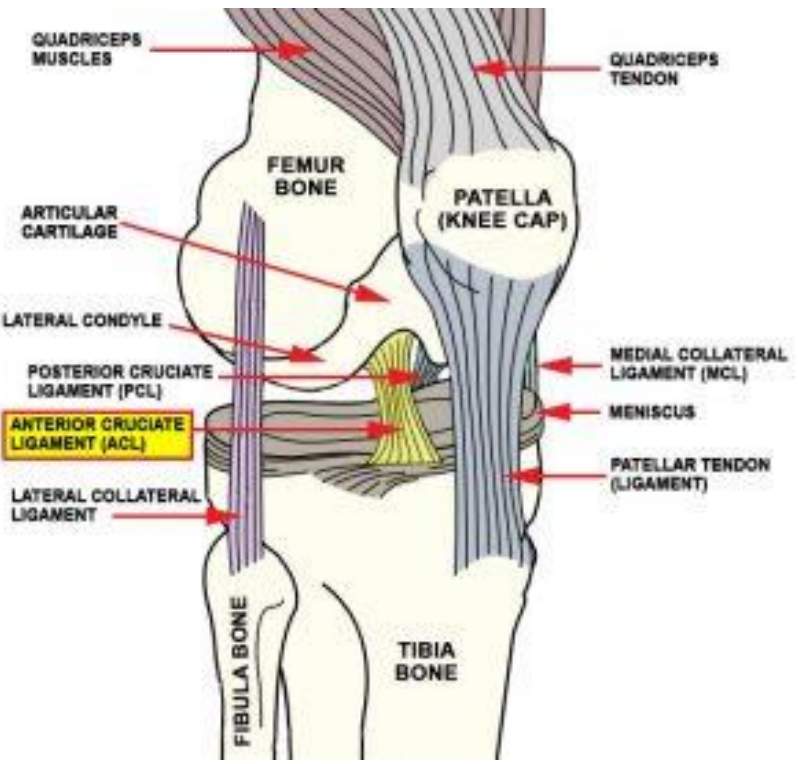


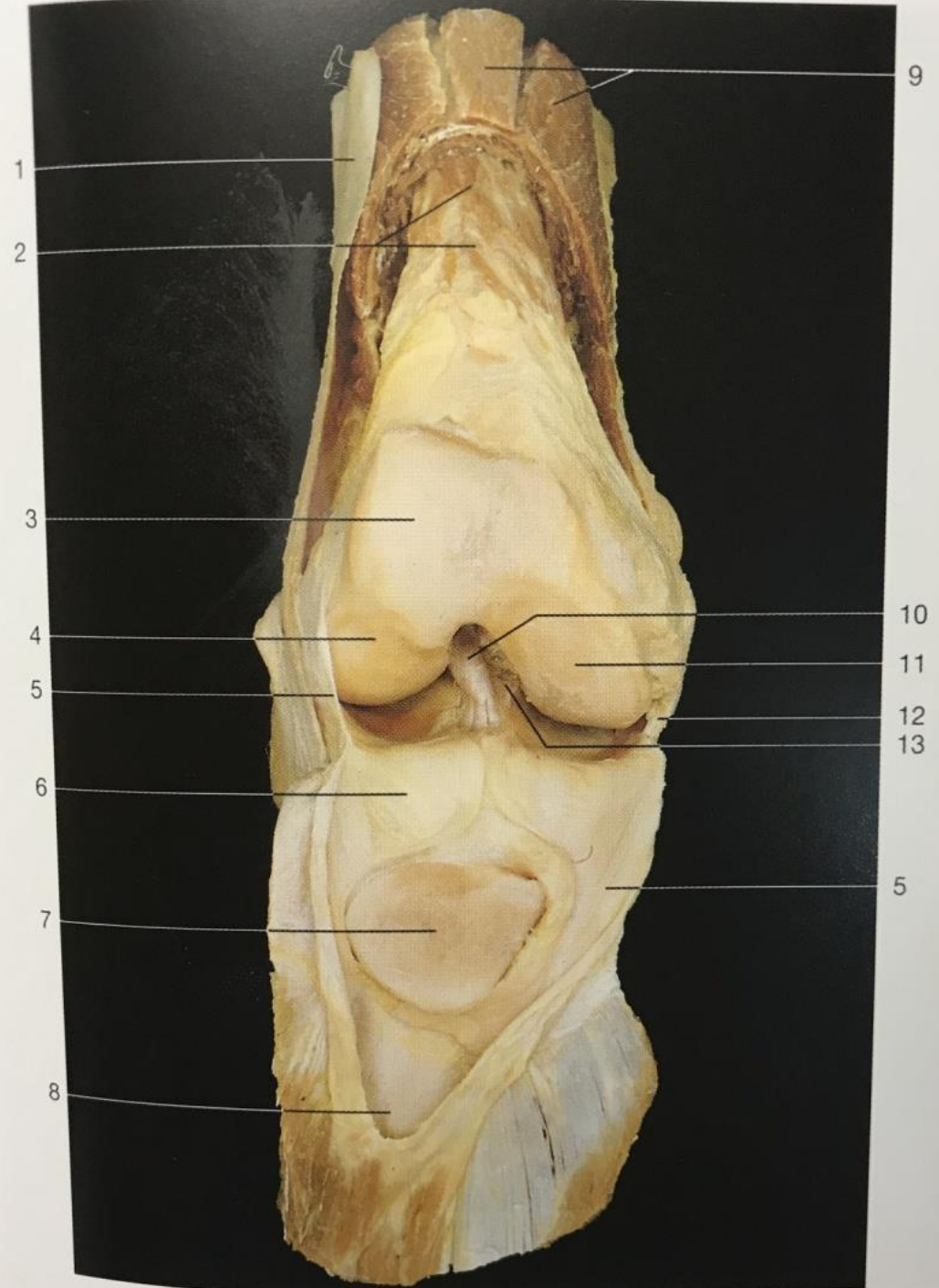
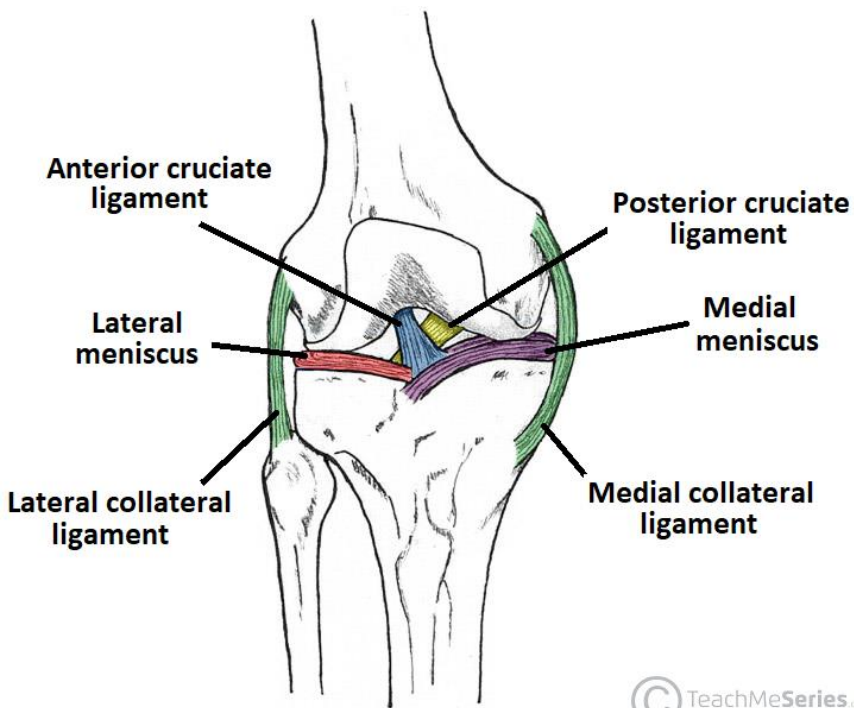
Transvers stabilizer

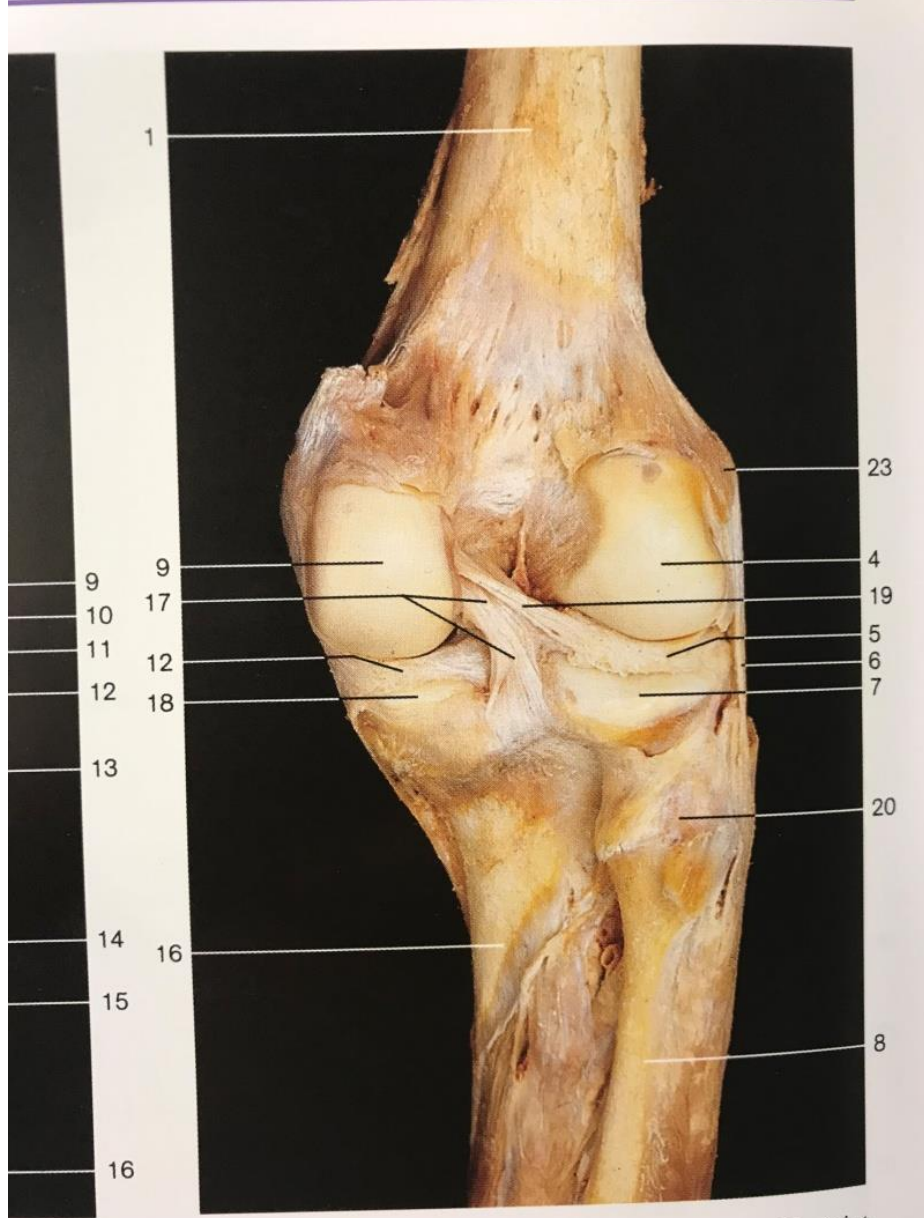
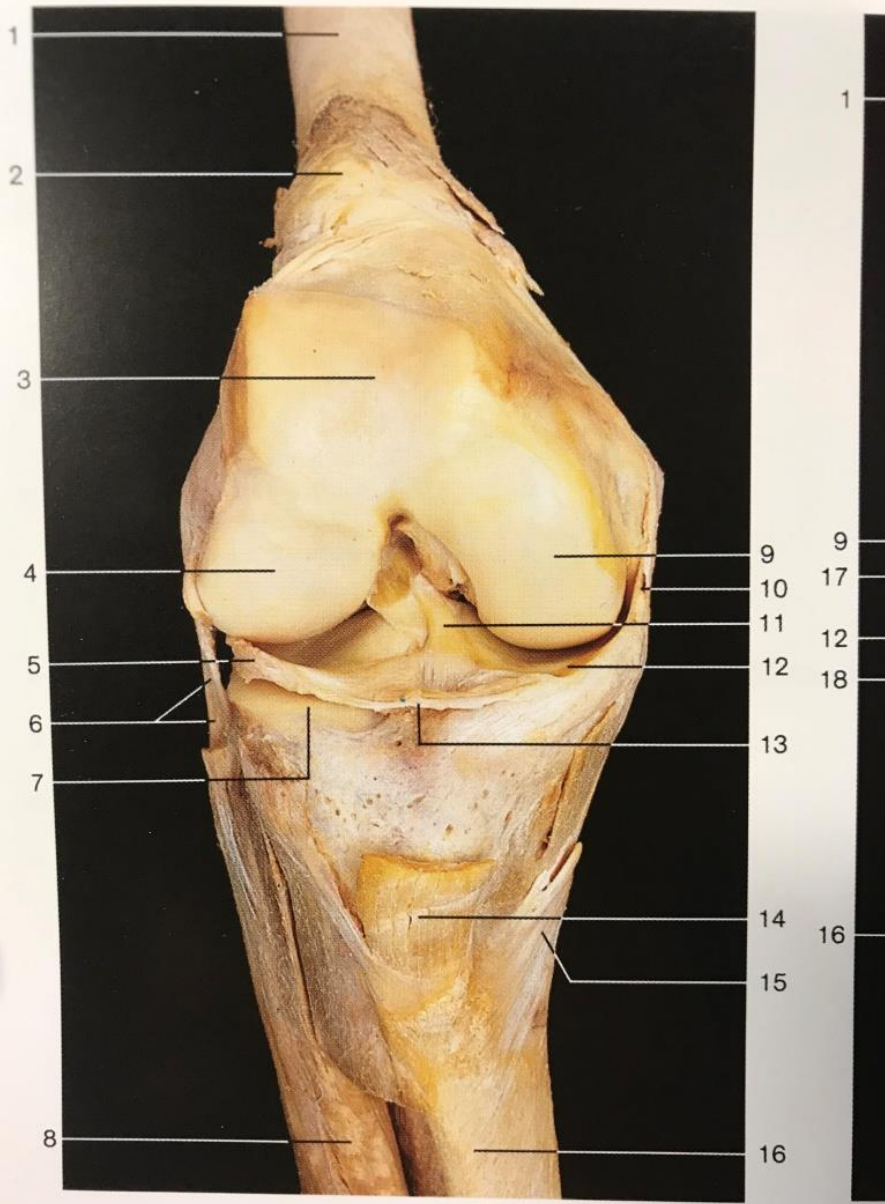
- Medial & lateral retinaculum
- Vastus Medialis & Lateralis
- The lateral PF ligament contributes 53% of total force when in full extension of knee.

Longitudinal stabilizer

- Patellar tendon – inferiorly
- Quadriceps tendon – superiorly



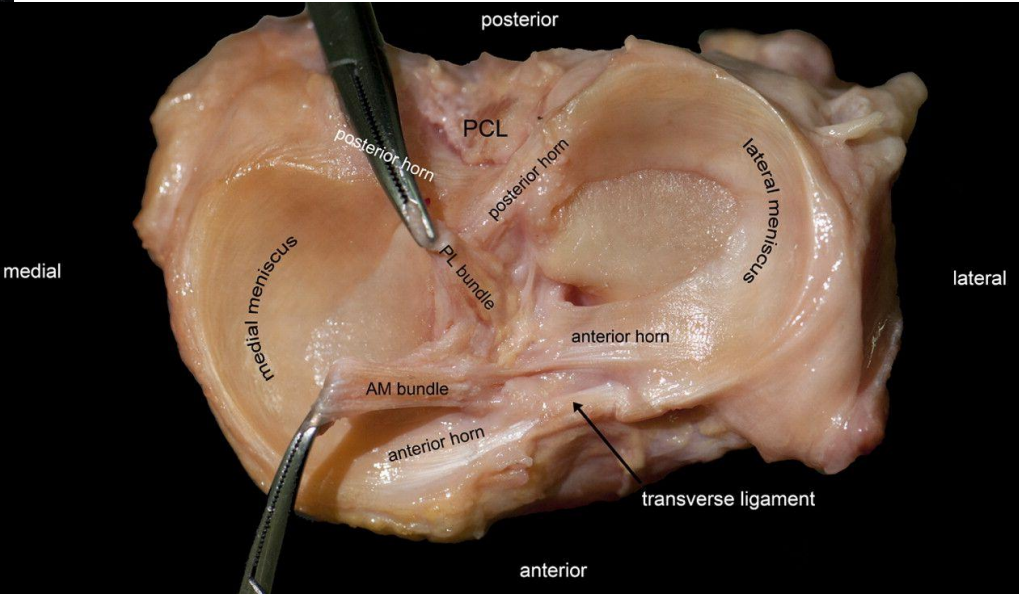
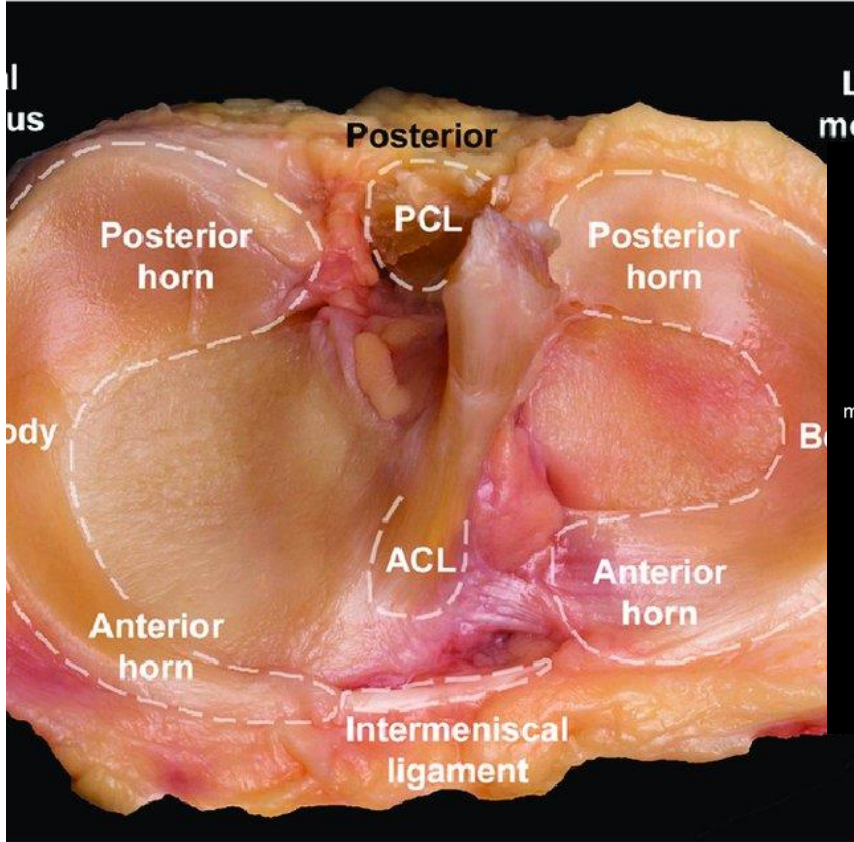




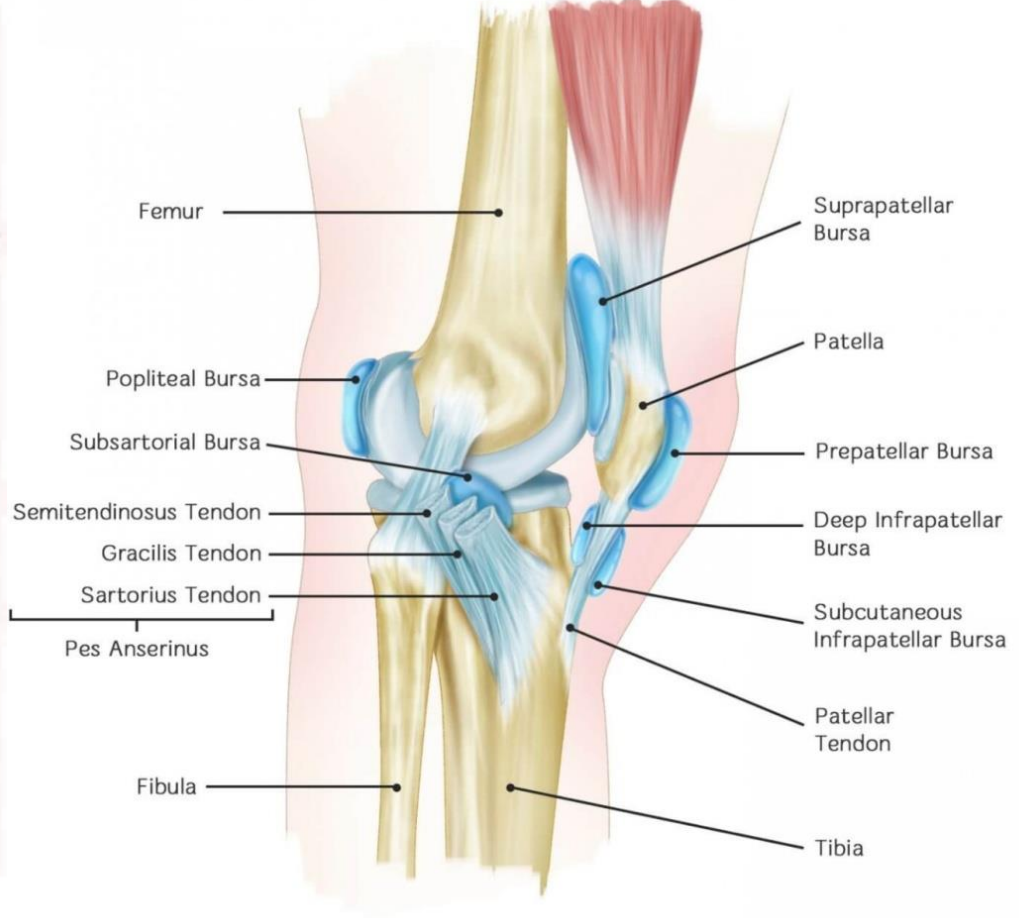
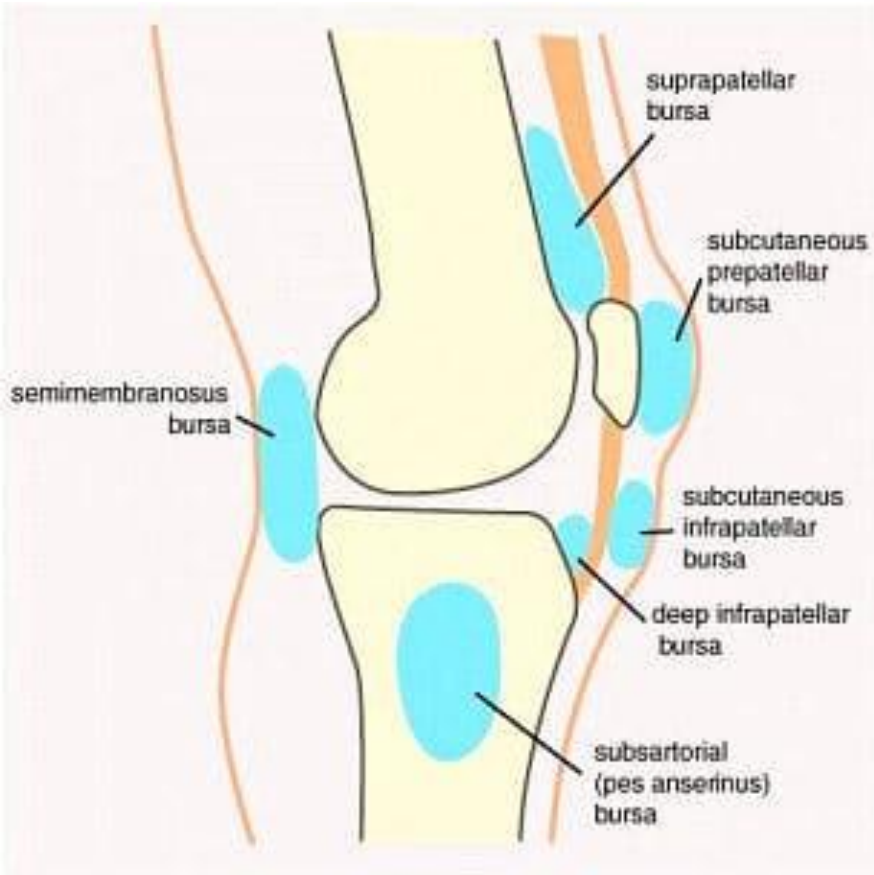
Right knee joint (opened) with ligaments (anterior aspect).

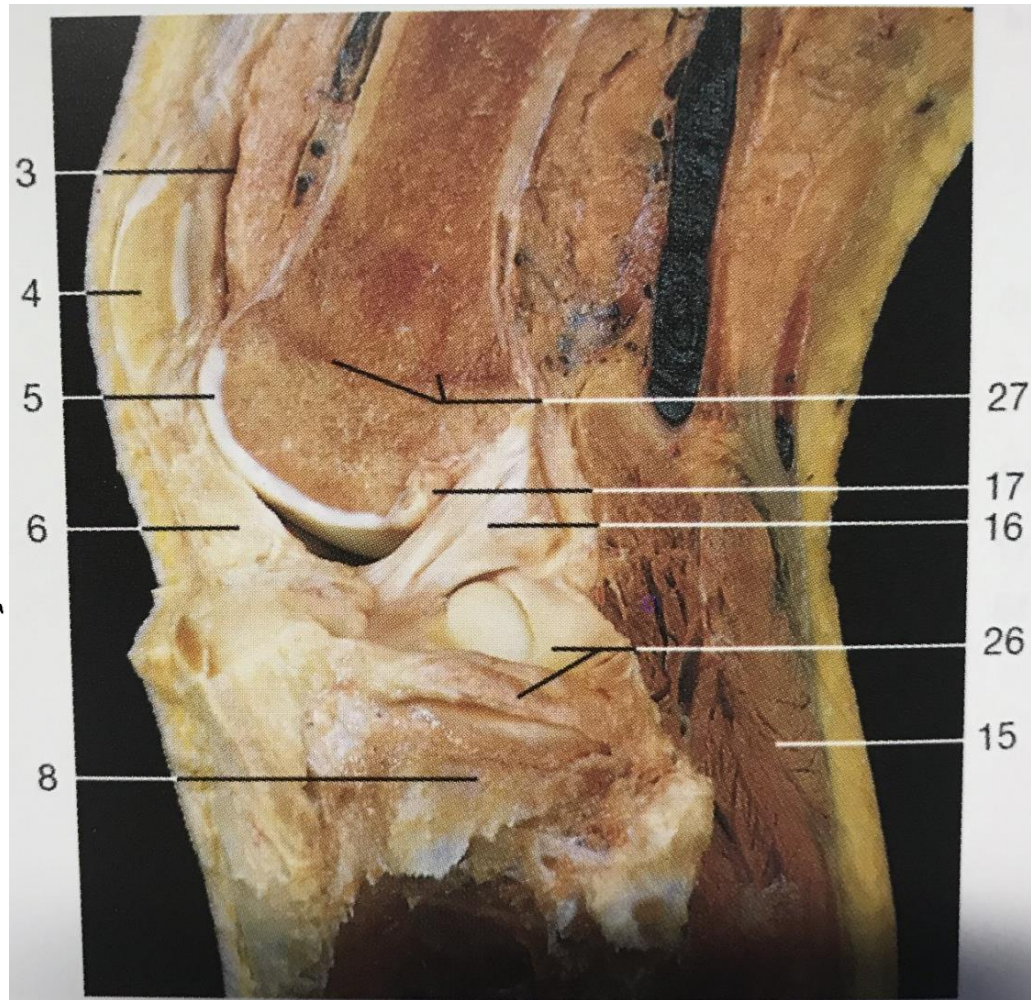
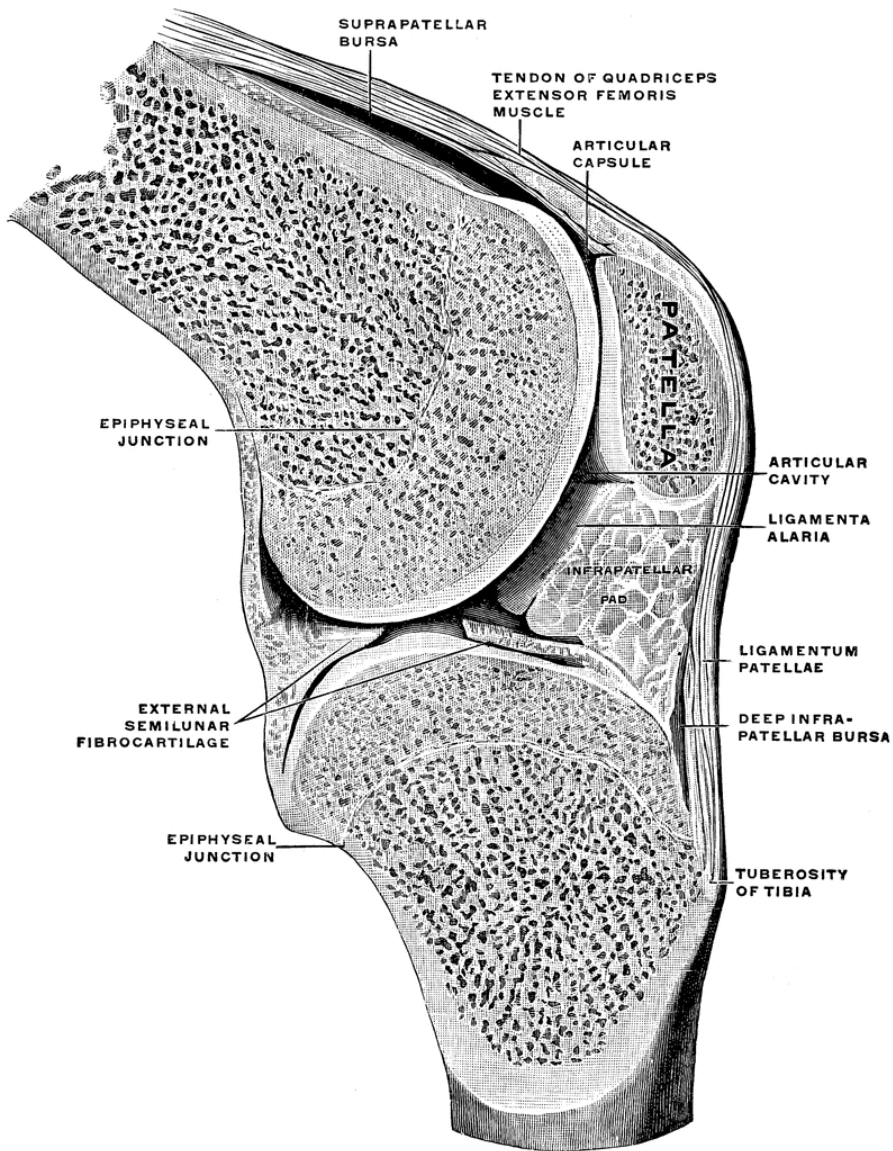
Right knee joint with ligaments (posterior aspect).

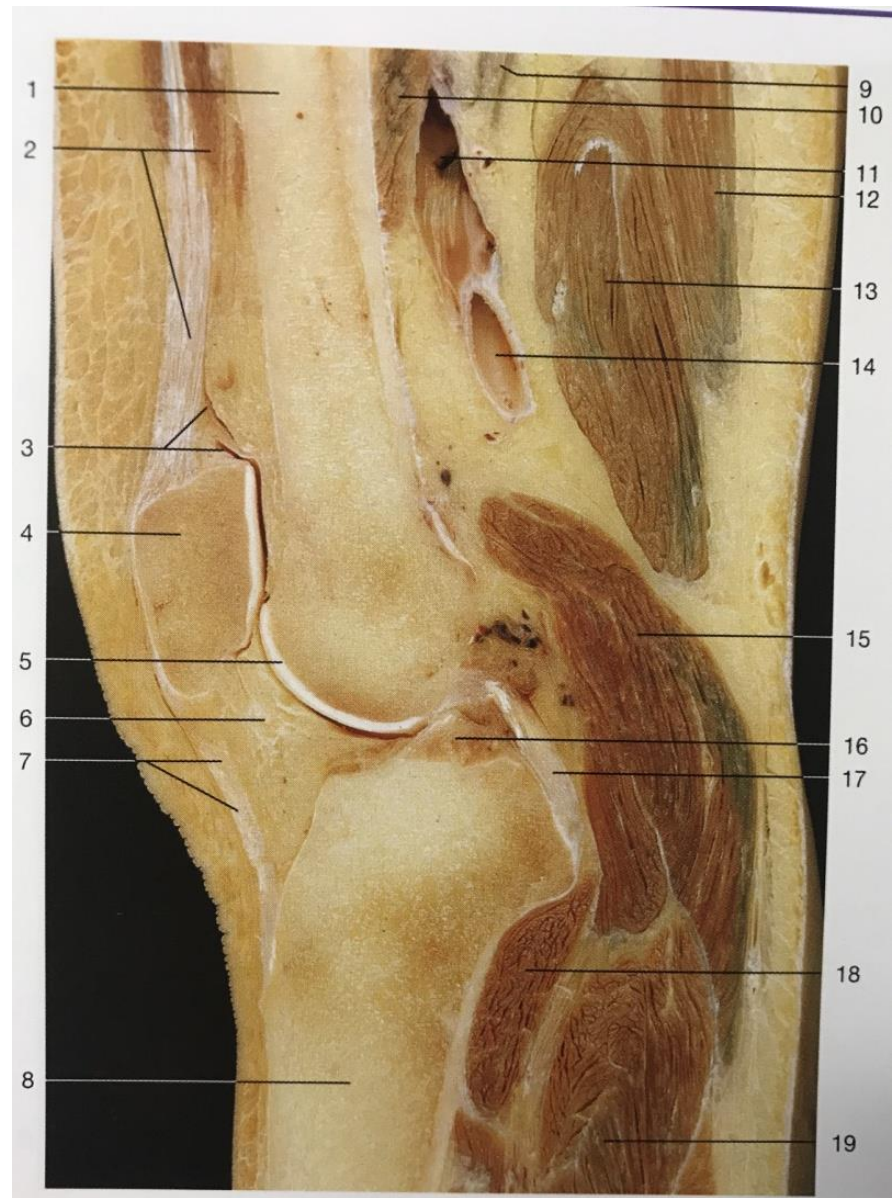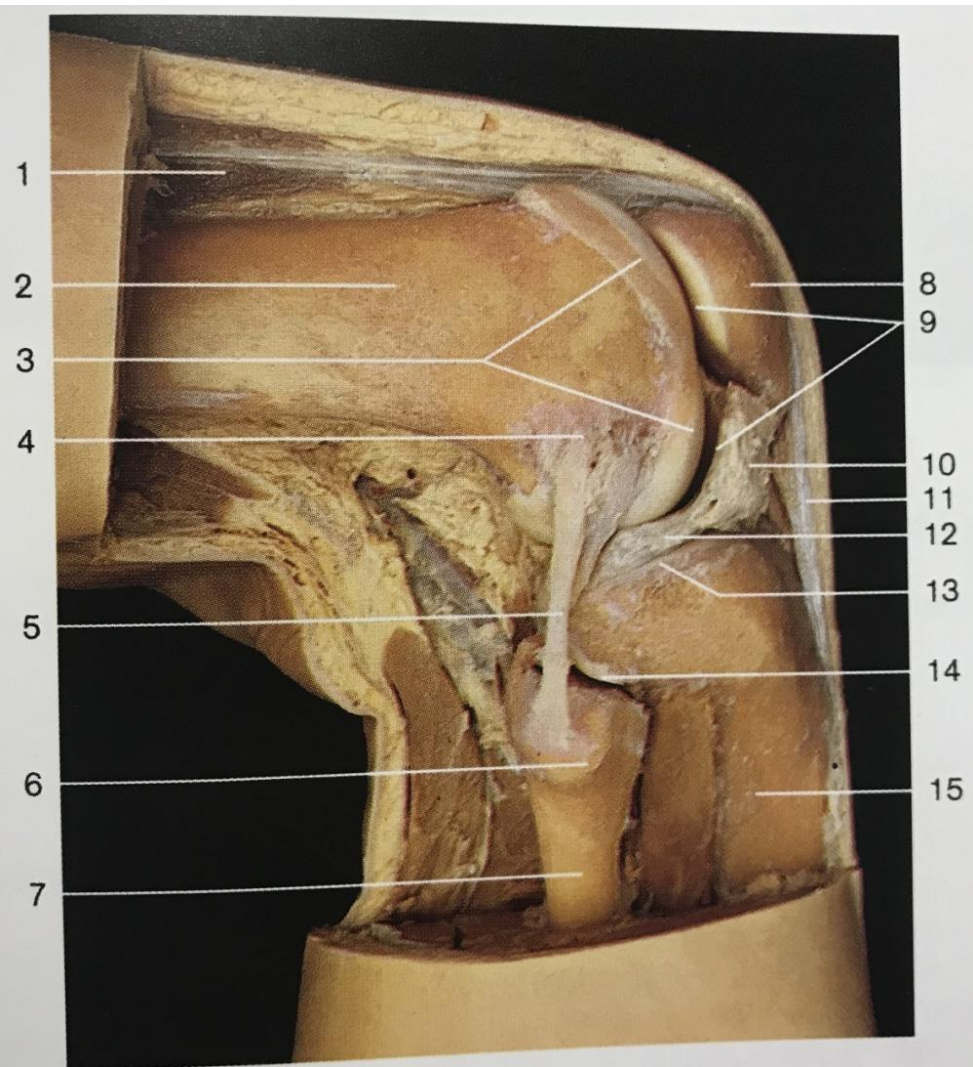
Right knee joint with ligaments (posterior aspect). The joint

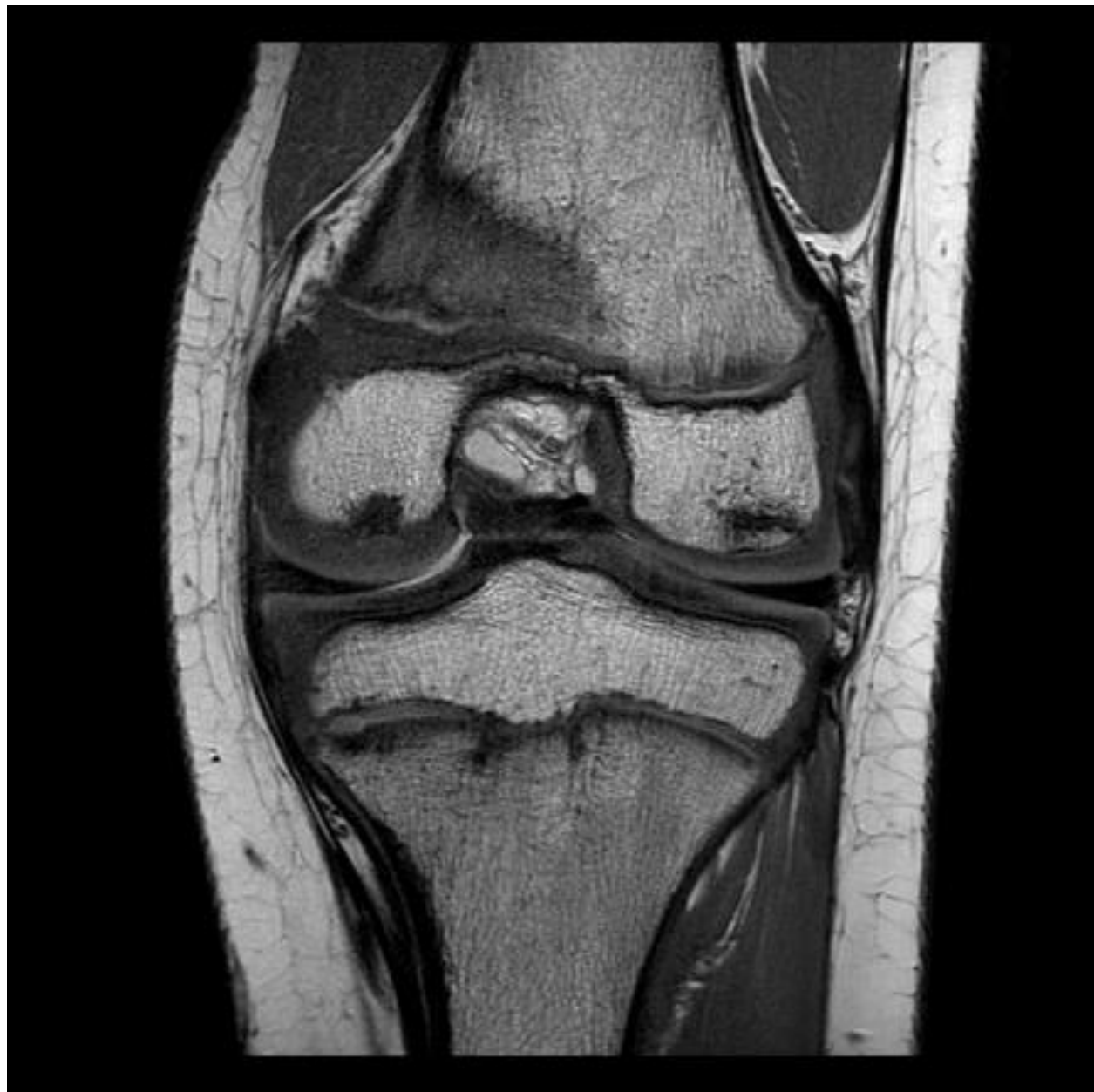

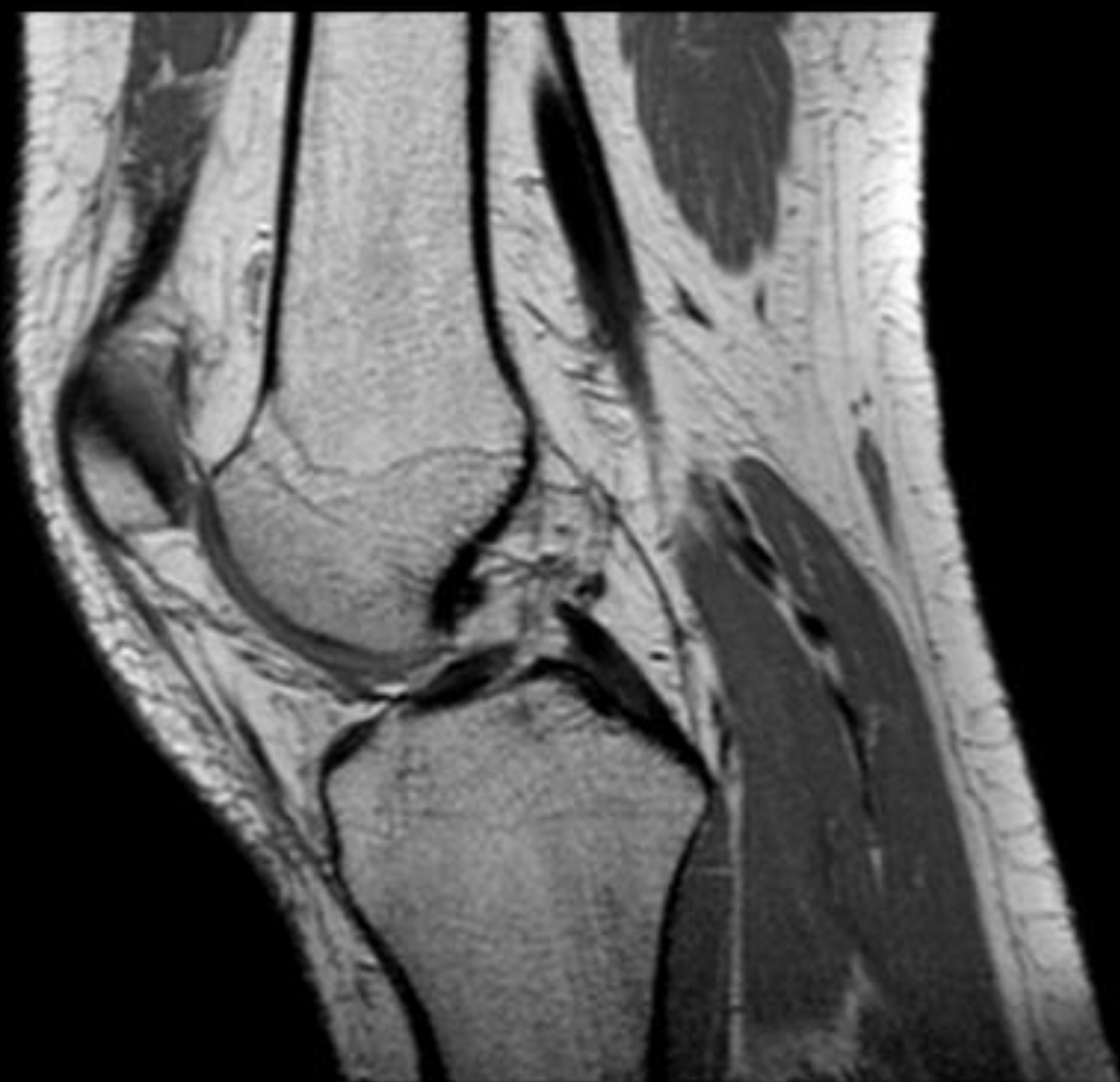Knee Bursitis

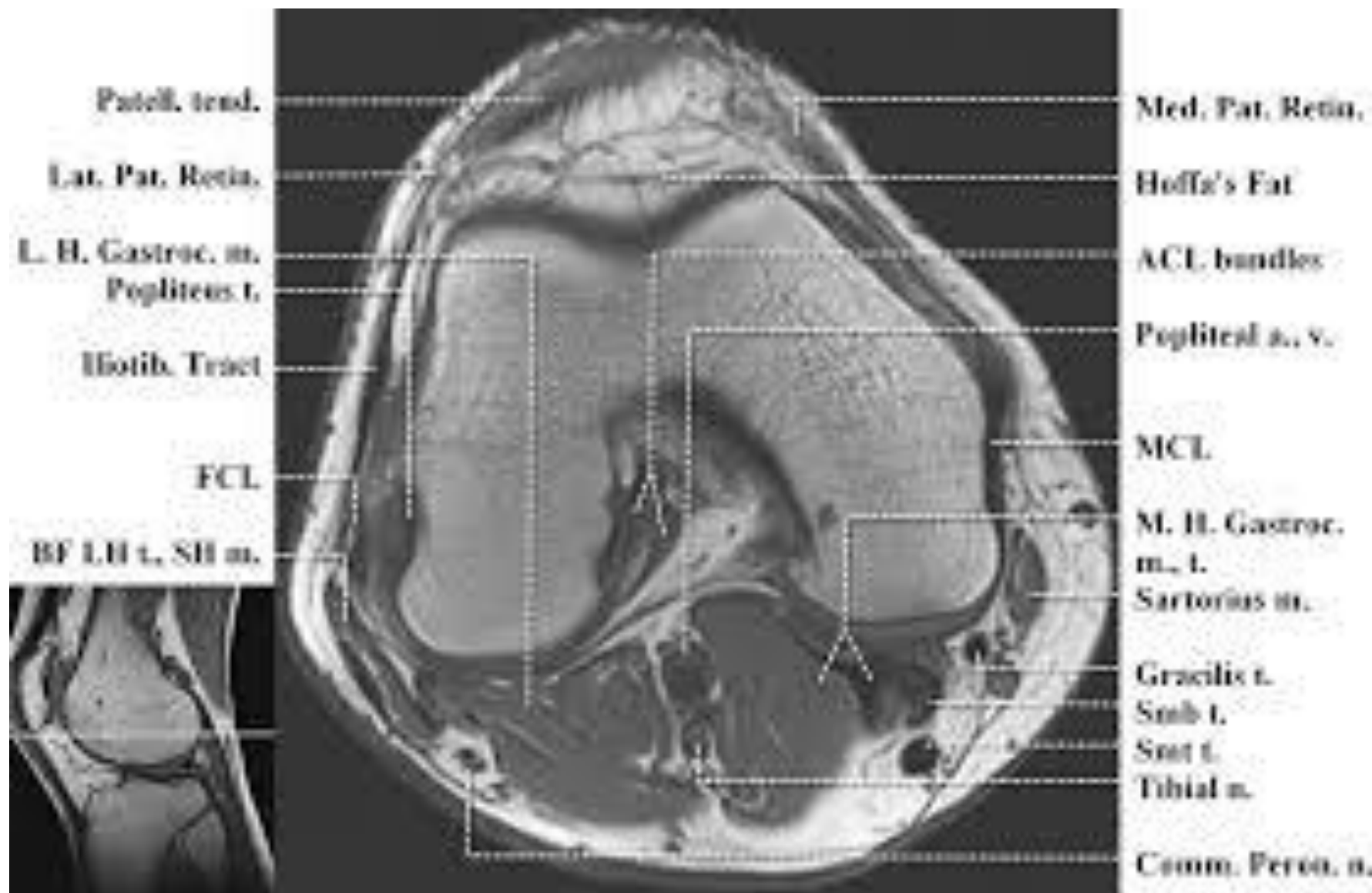




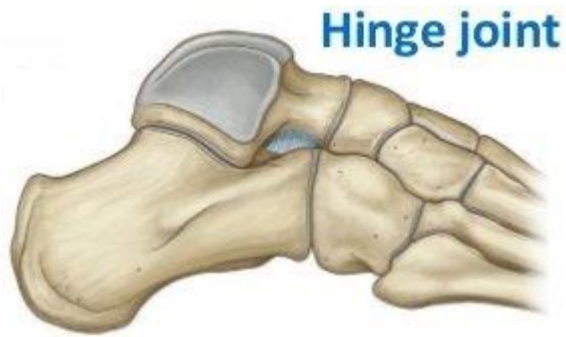



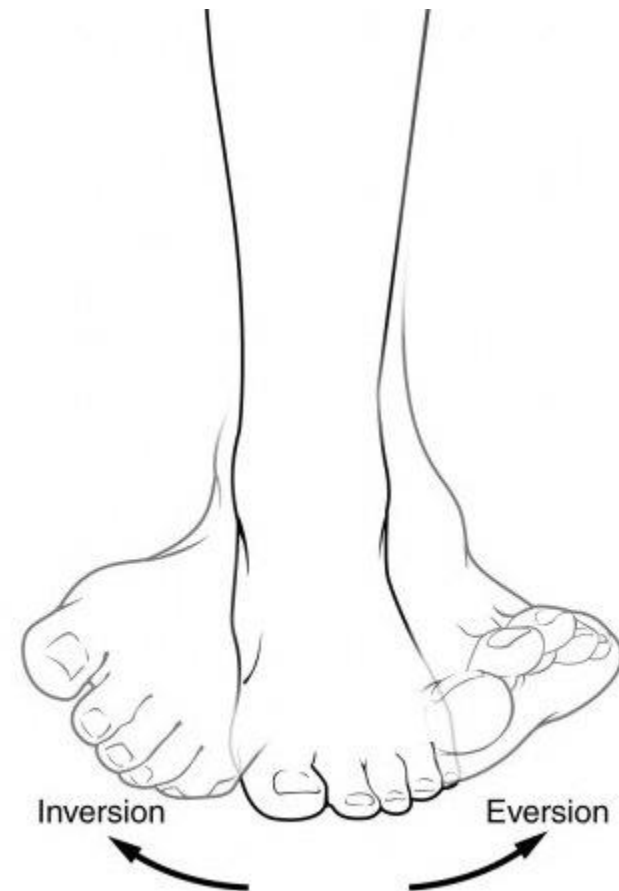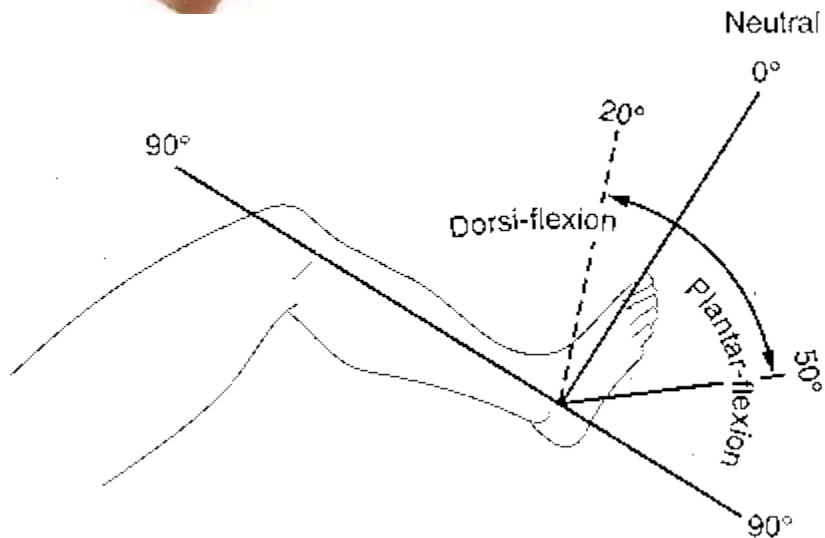


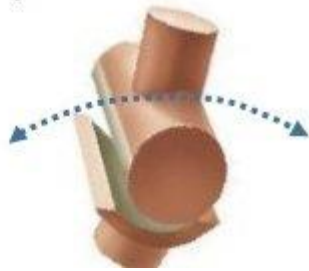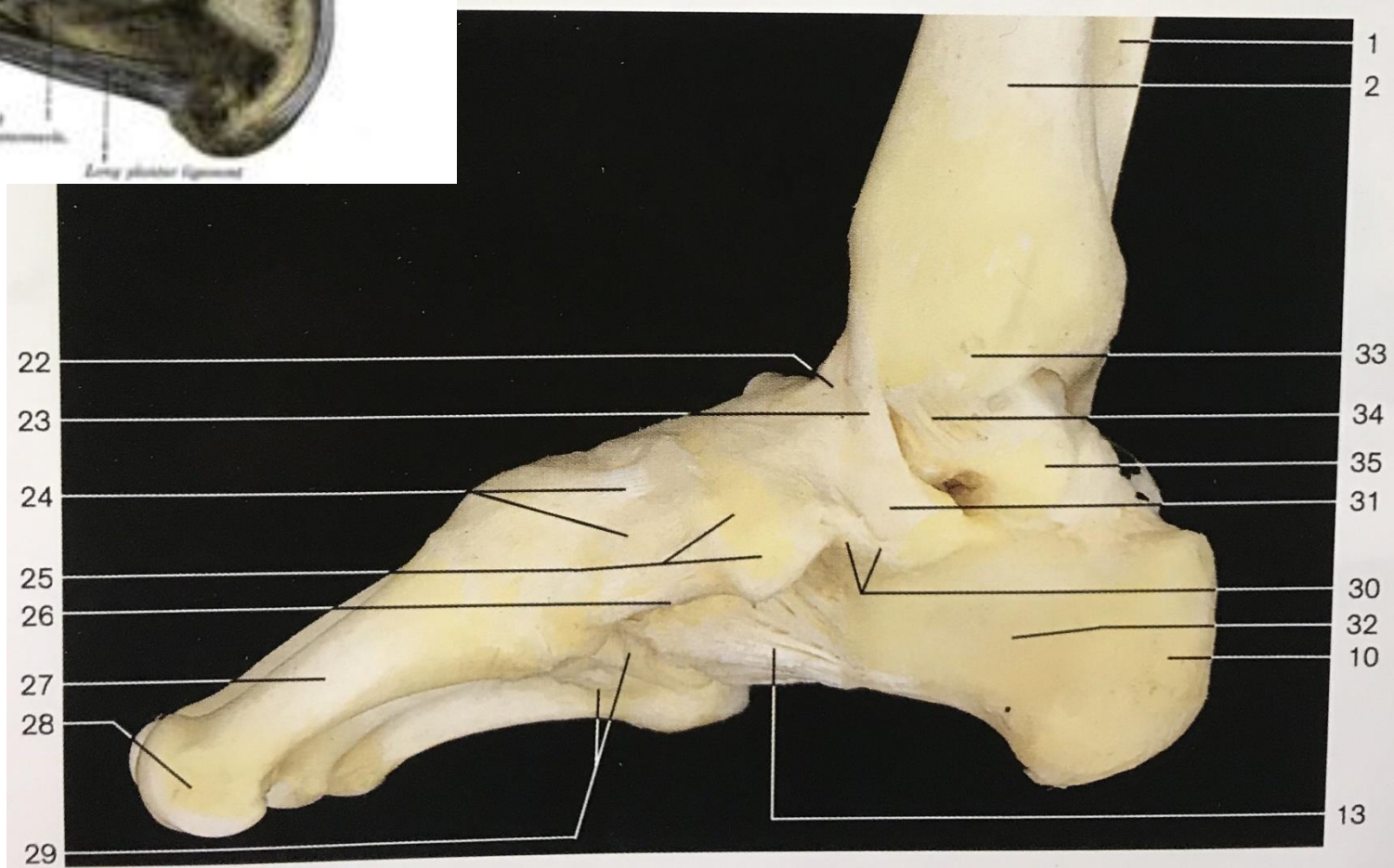
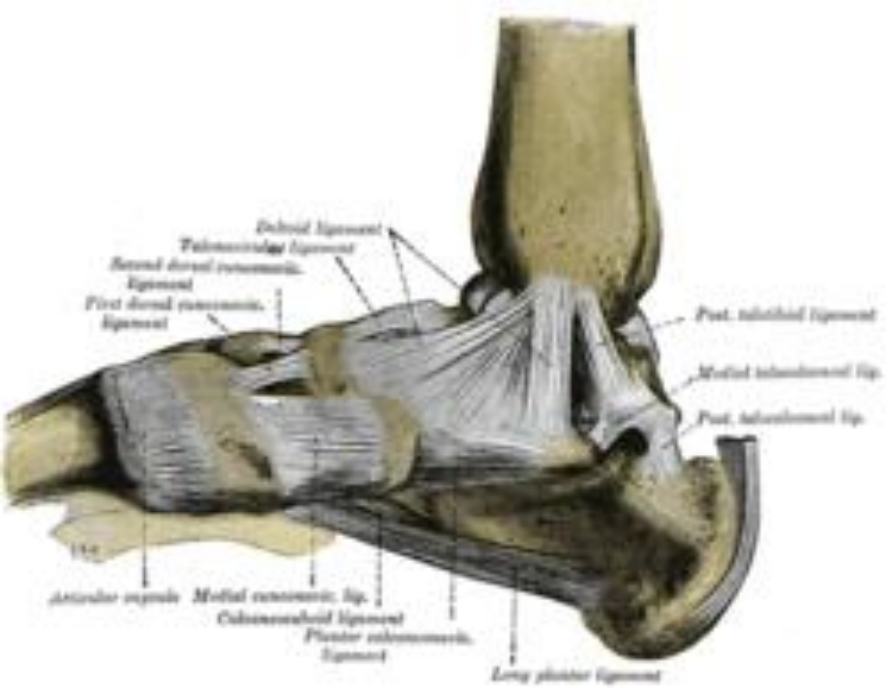


The Ankle joint (*Articulatio talocruralis*)

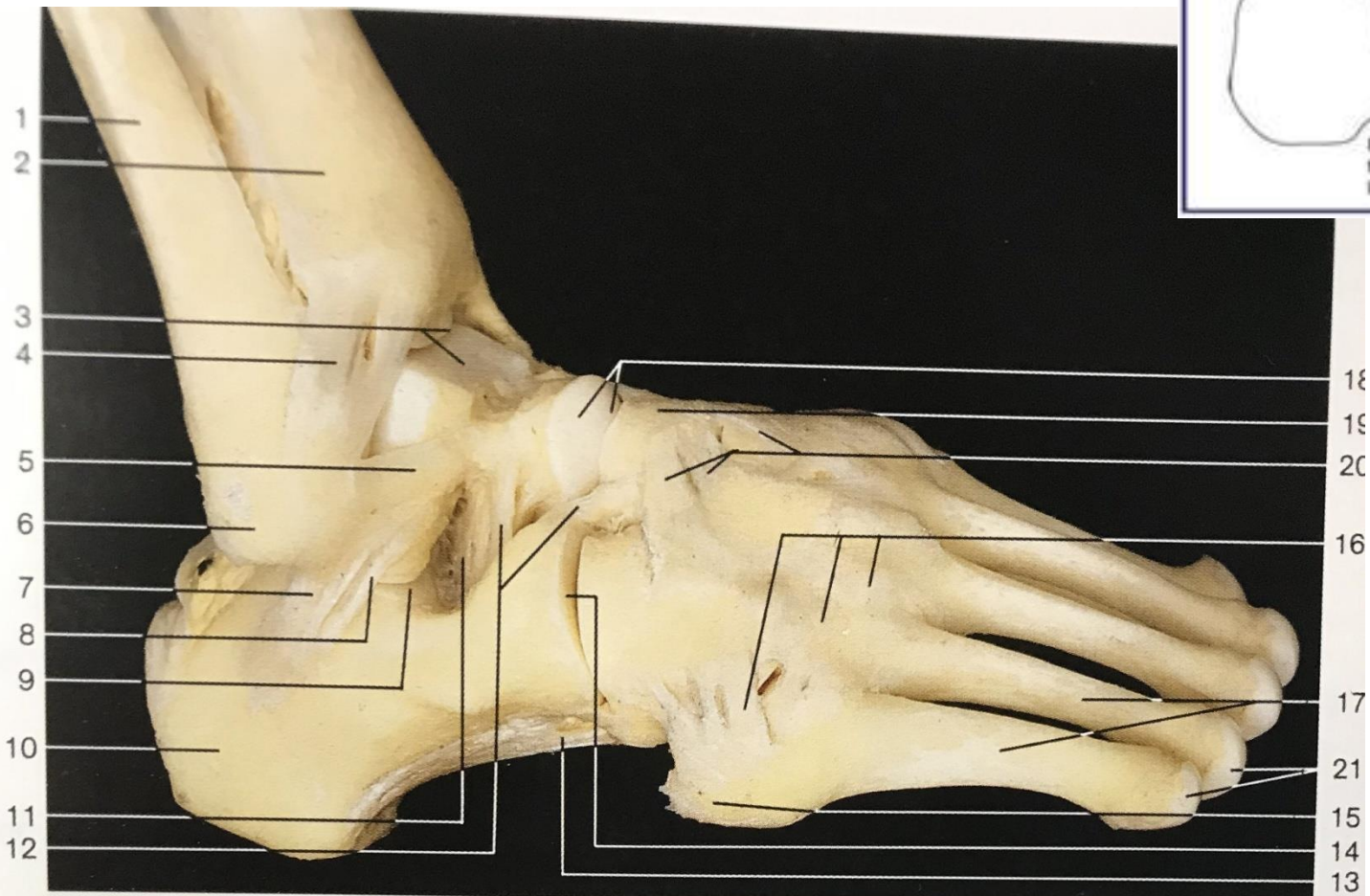
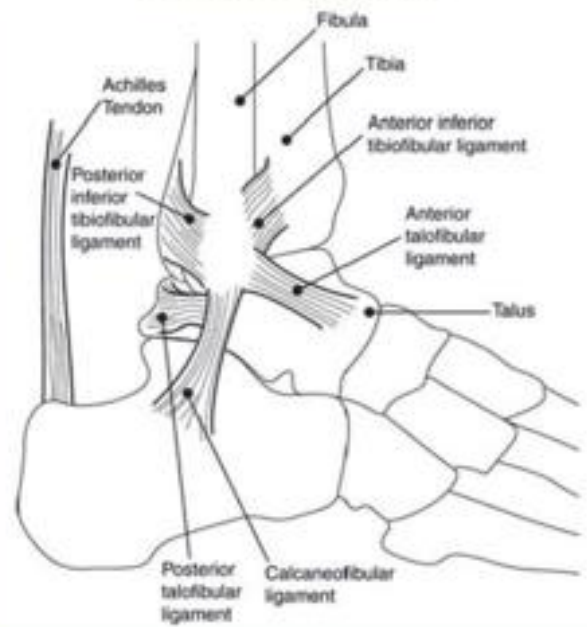


Ankle joint

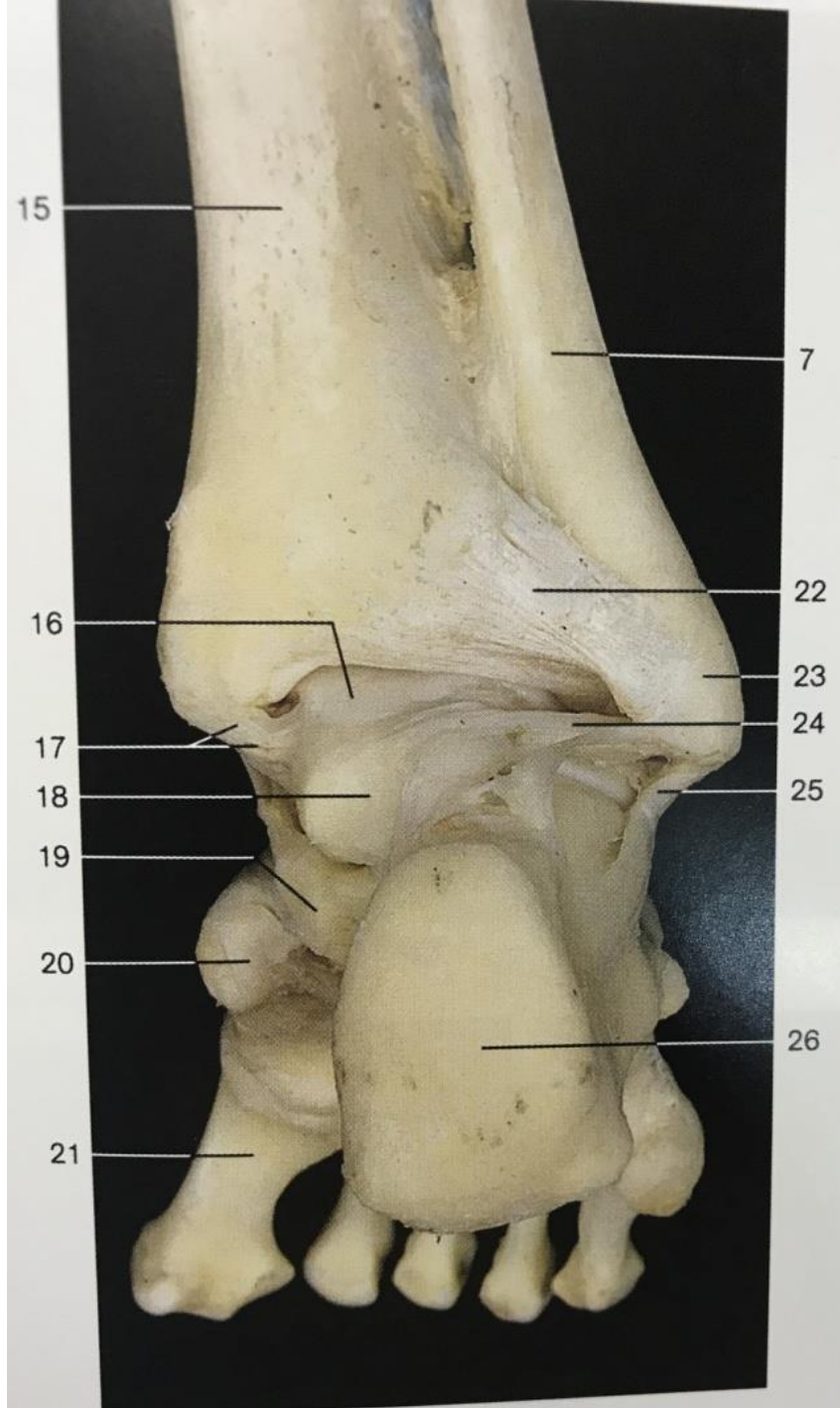
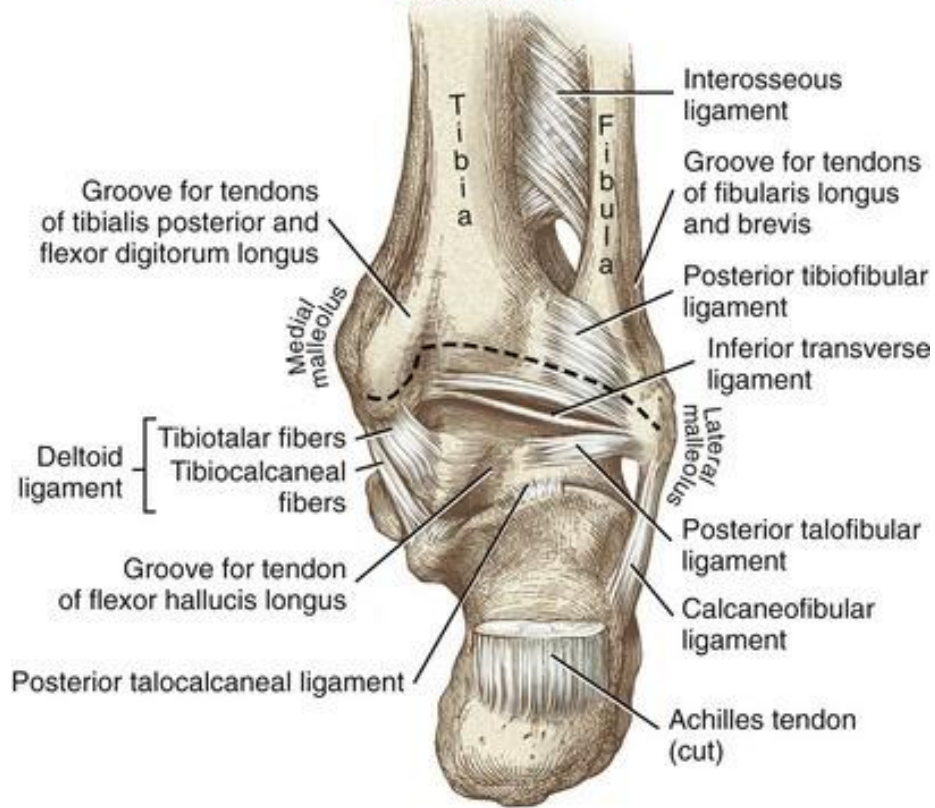


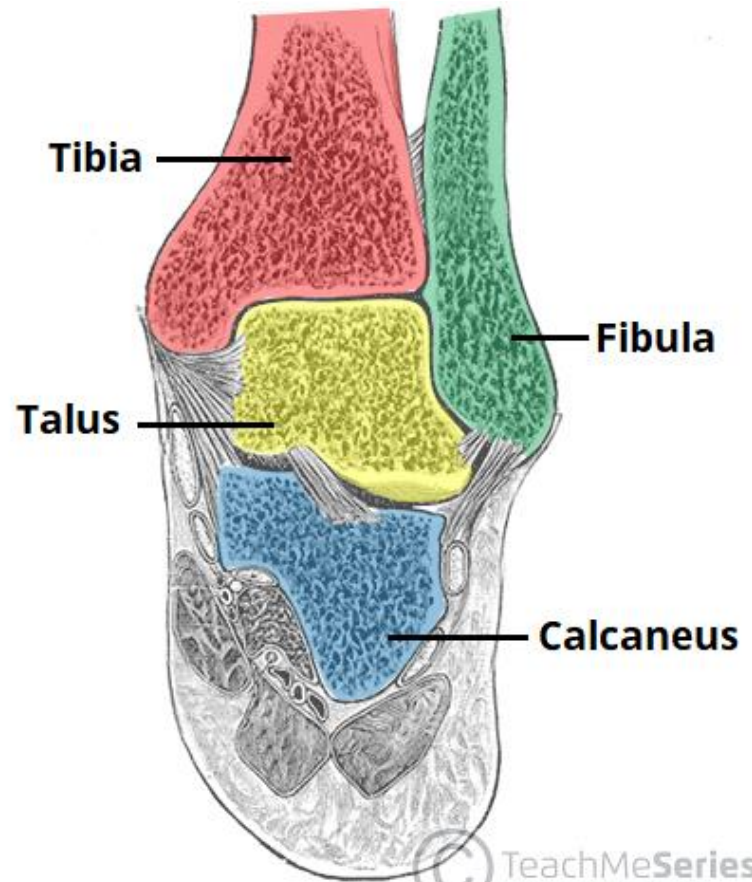
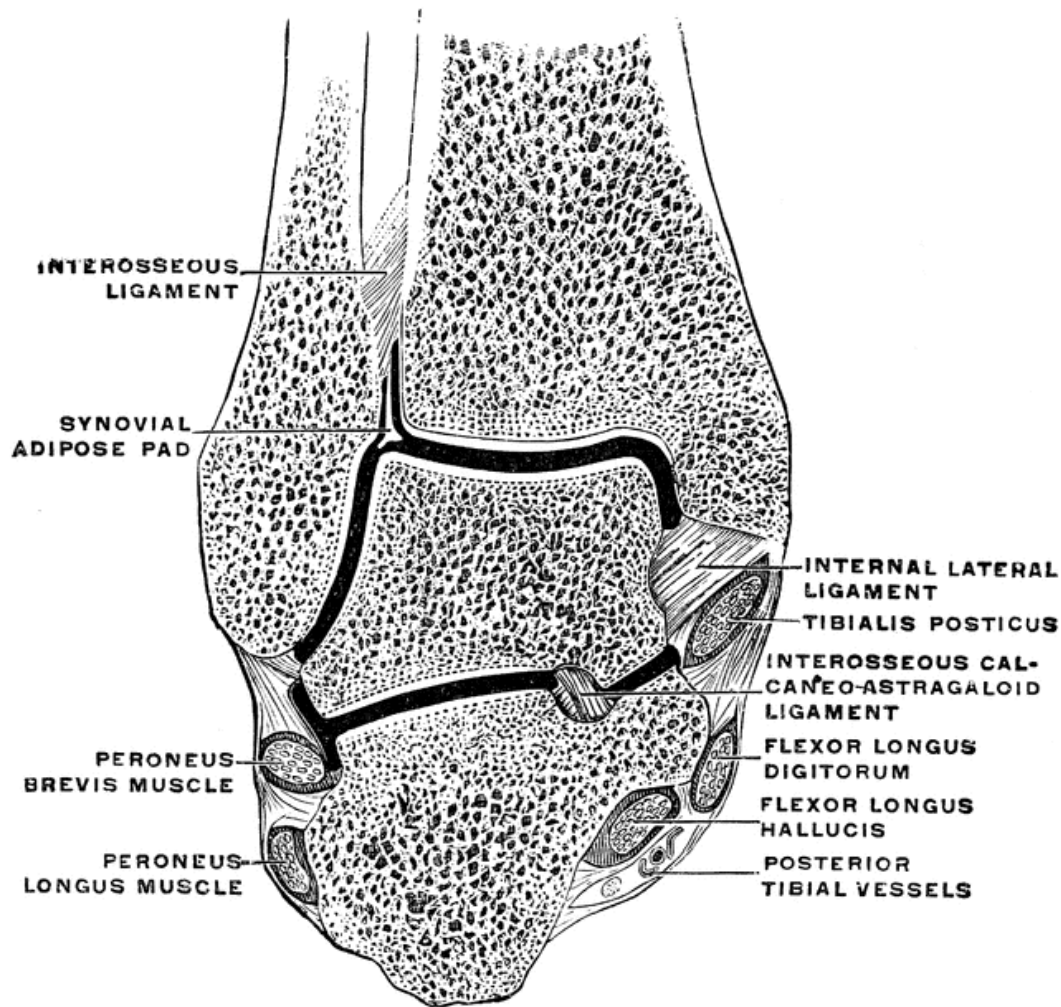


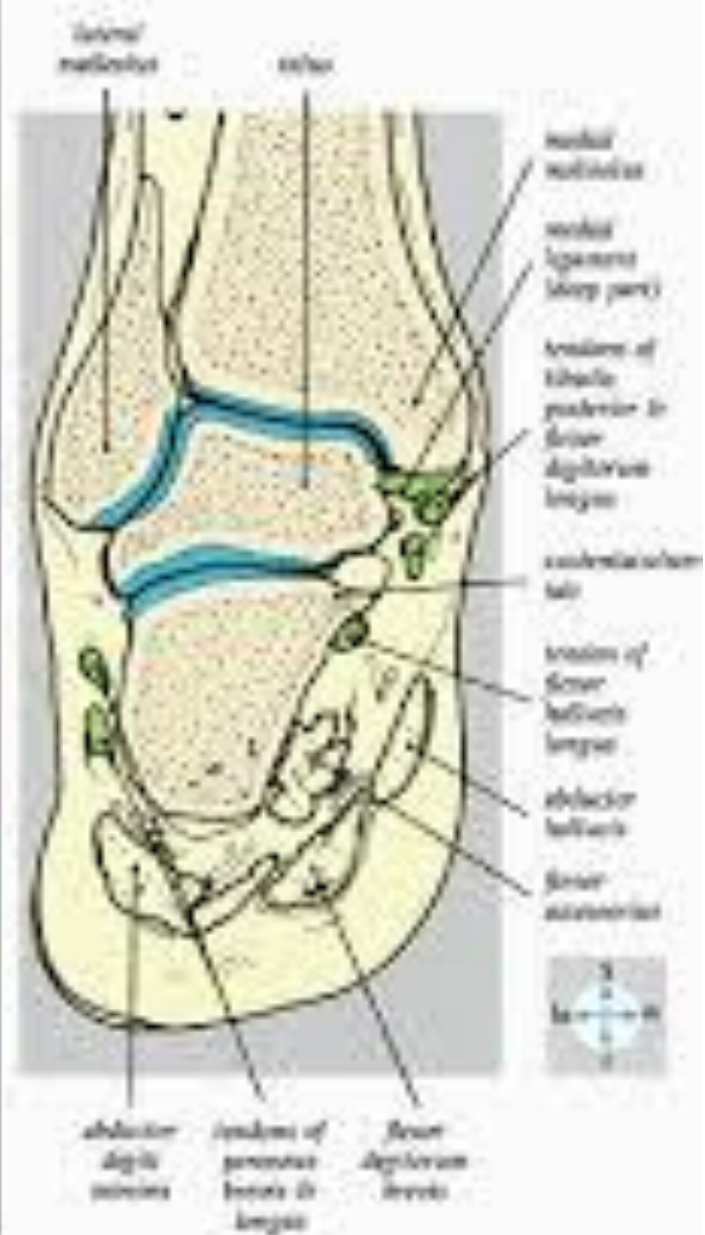
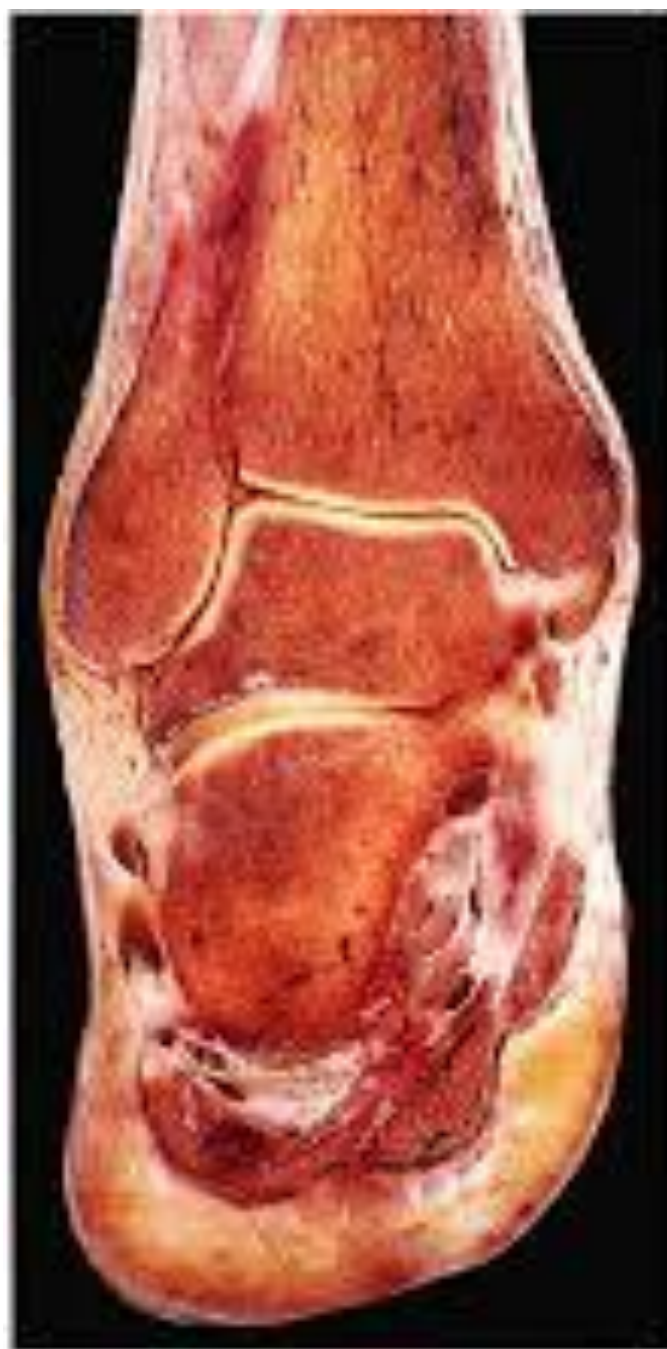Lateral View of the Ankle

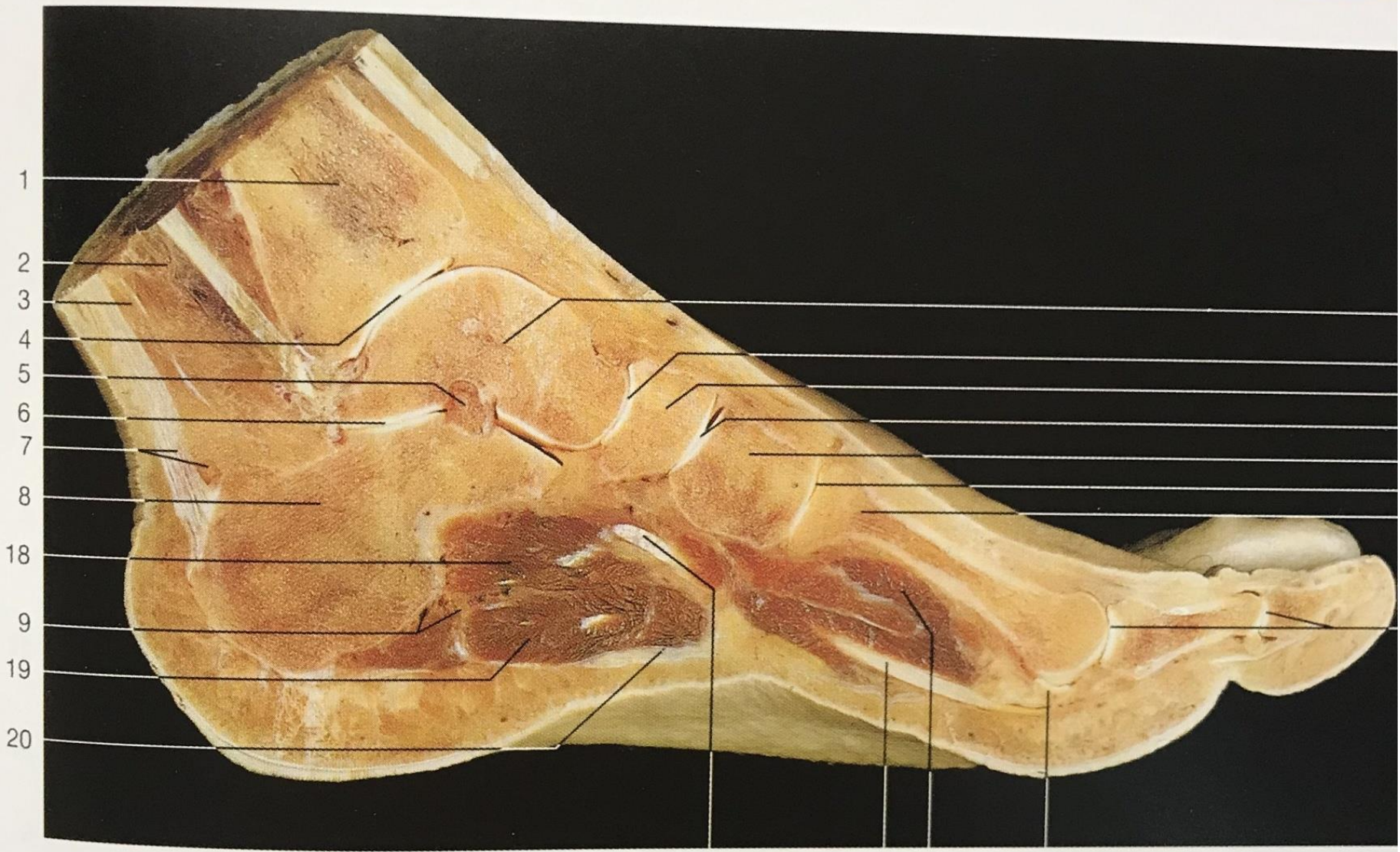

Posterior view









1

2

3

4

5

6

7

8

18

9

19

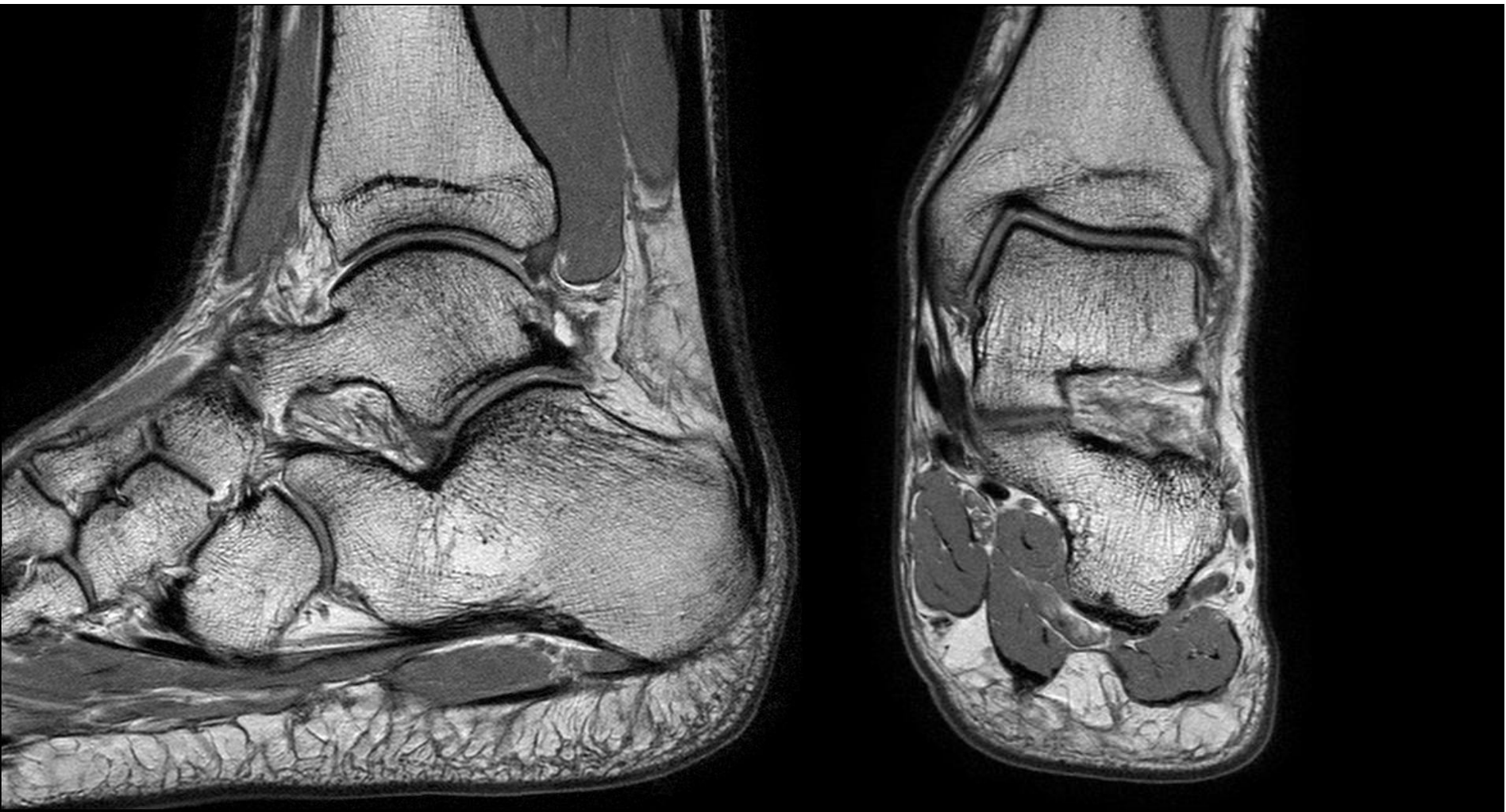
20

25

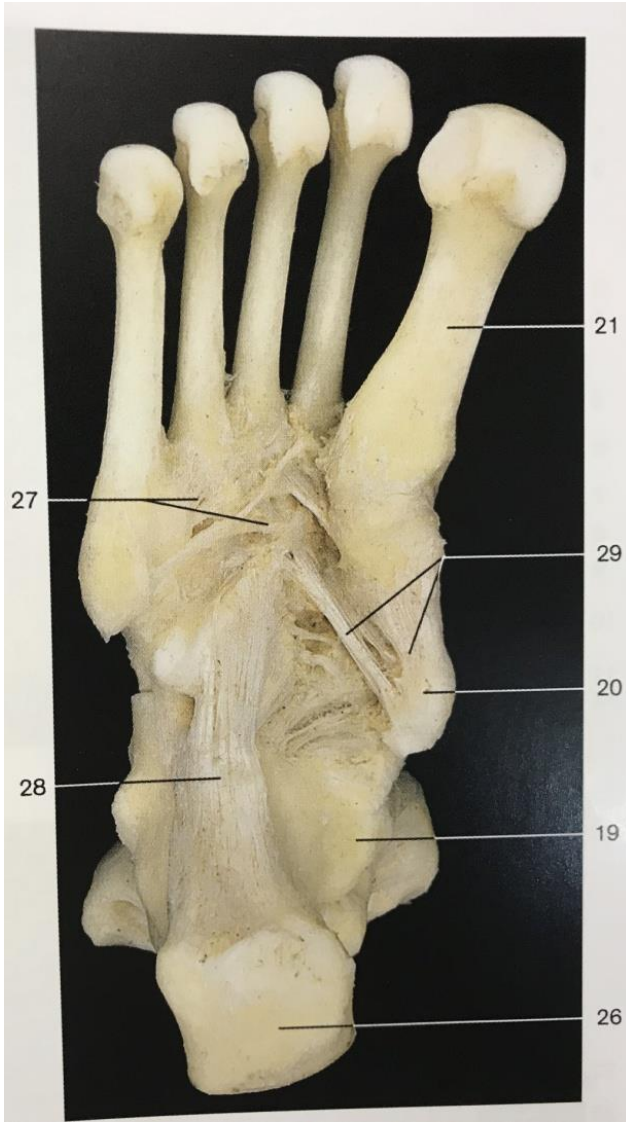
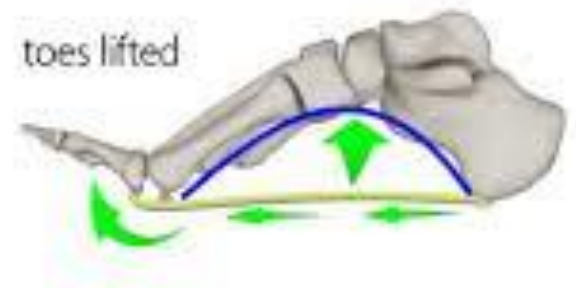
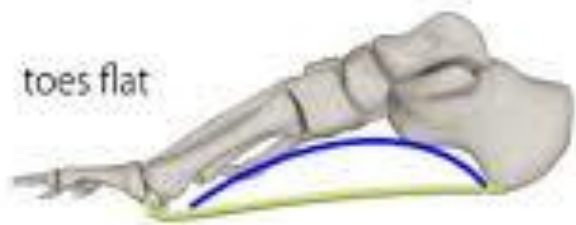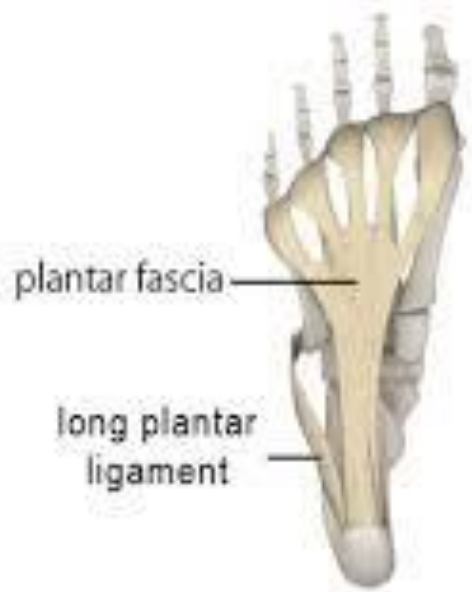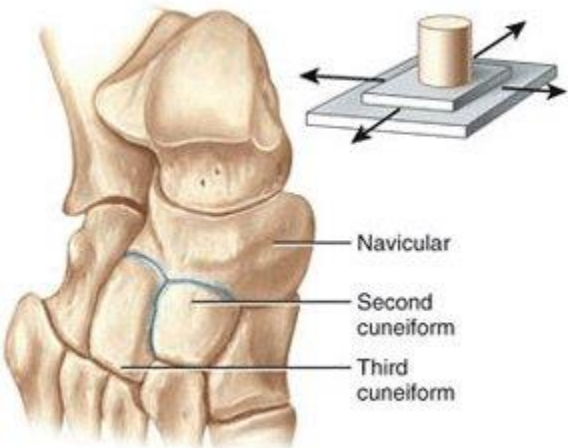
26

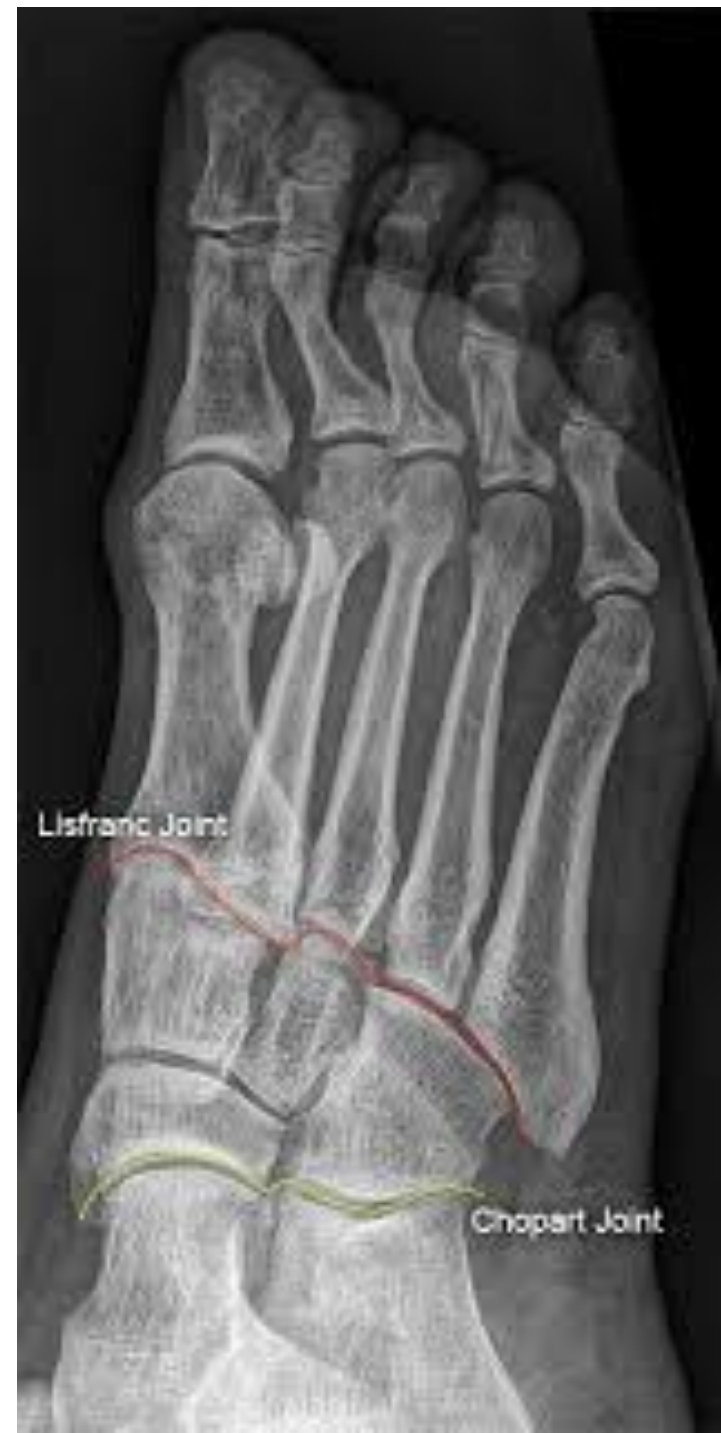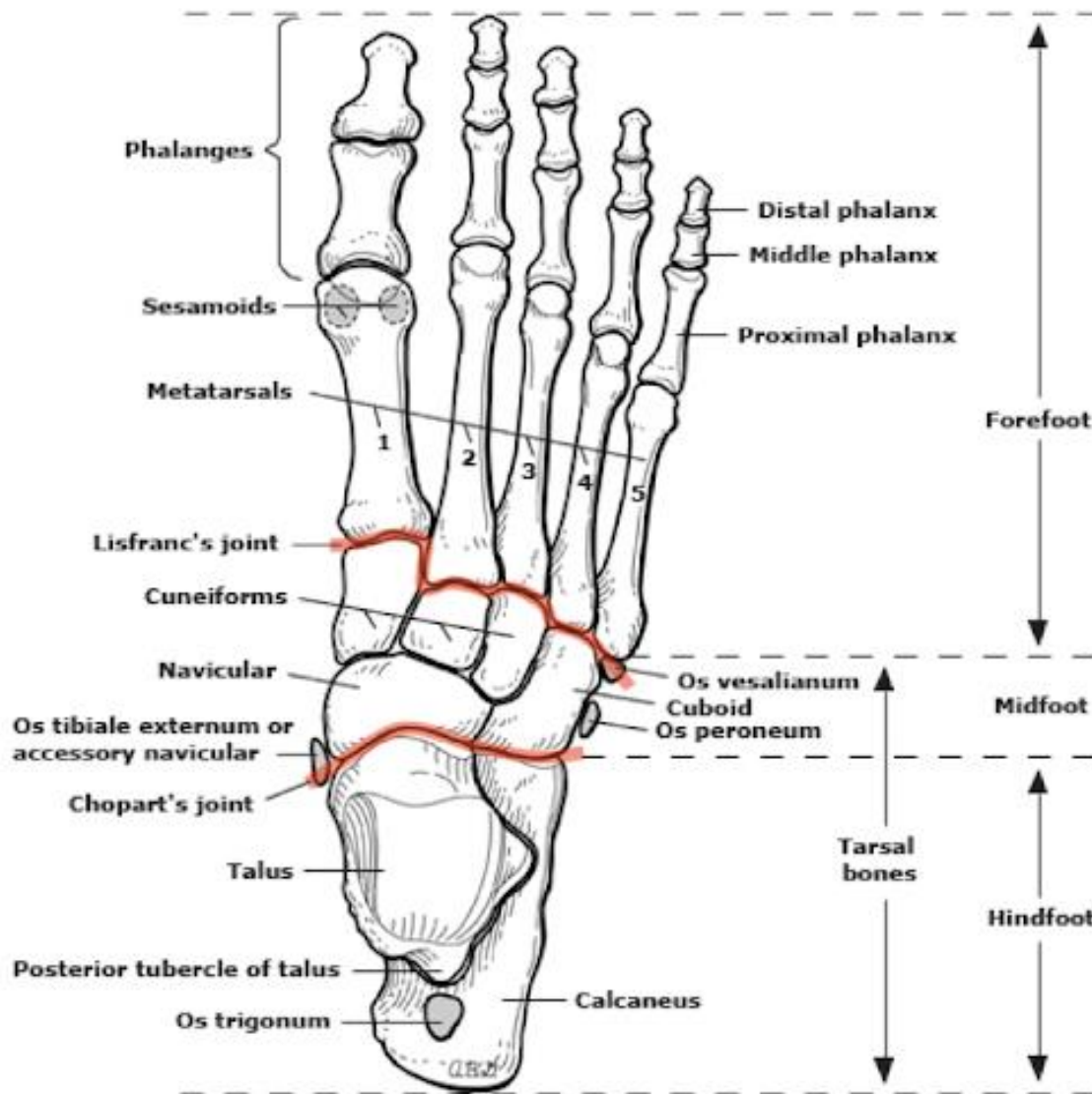
27

28

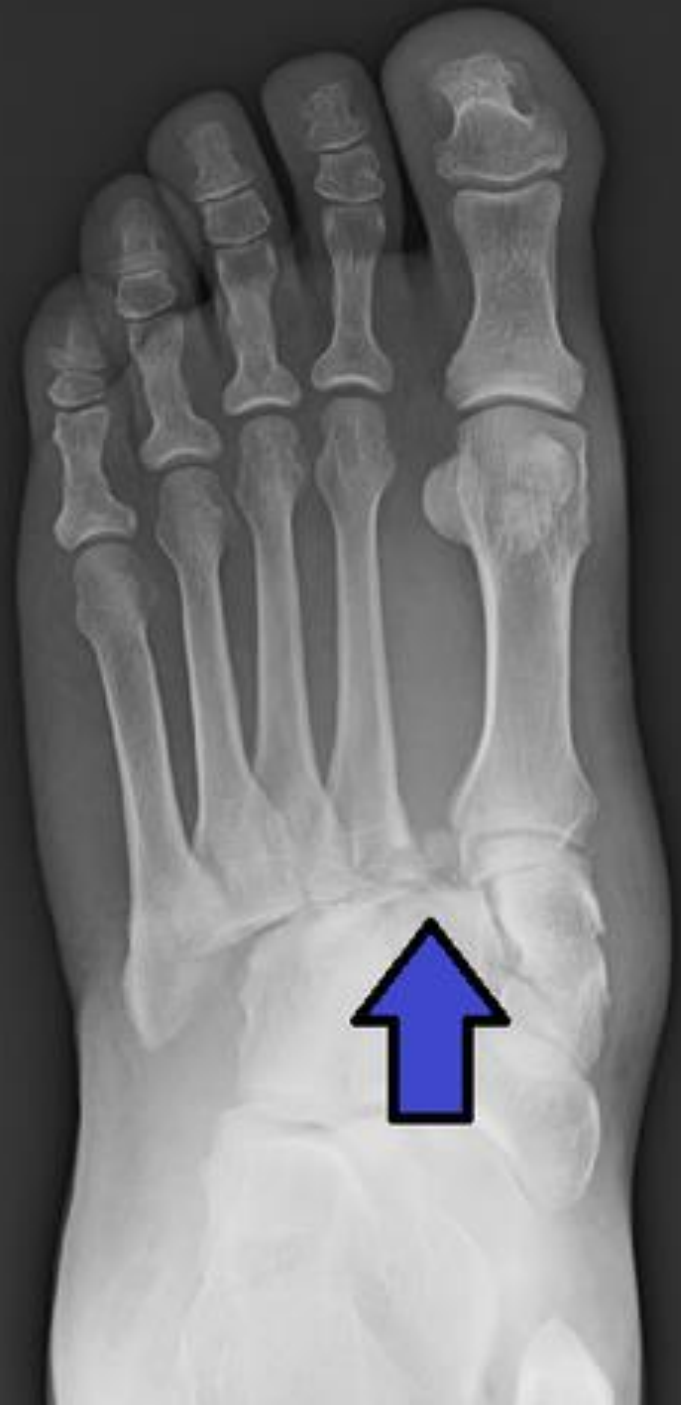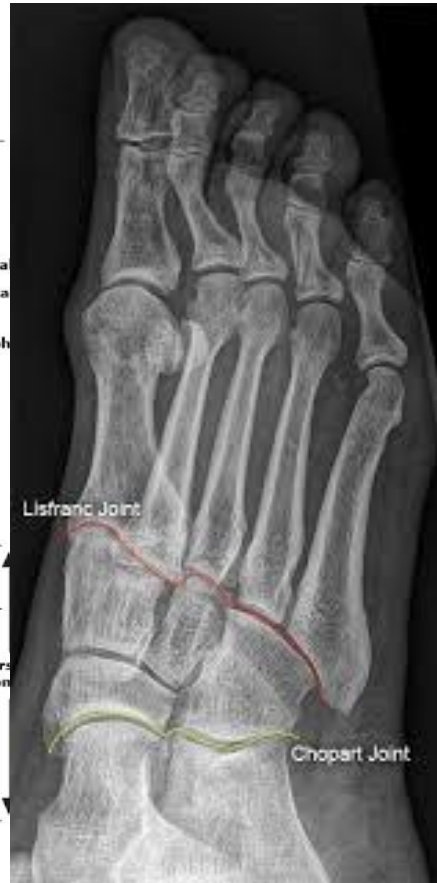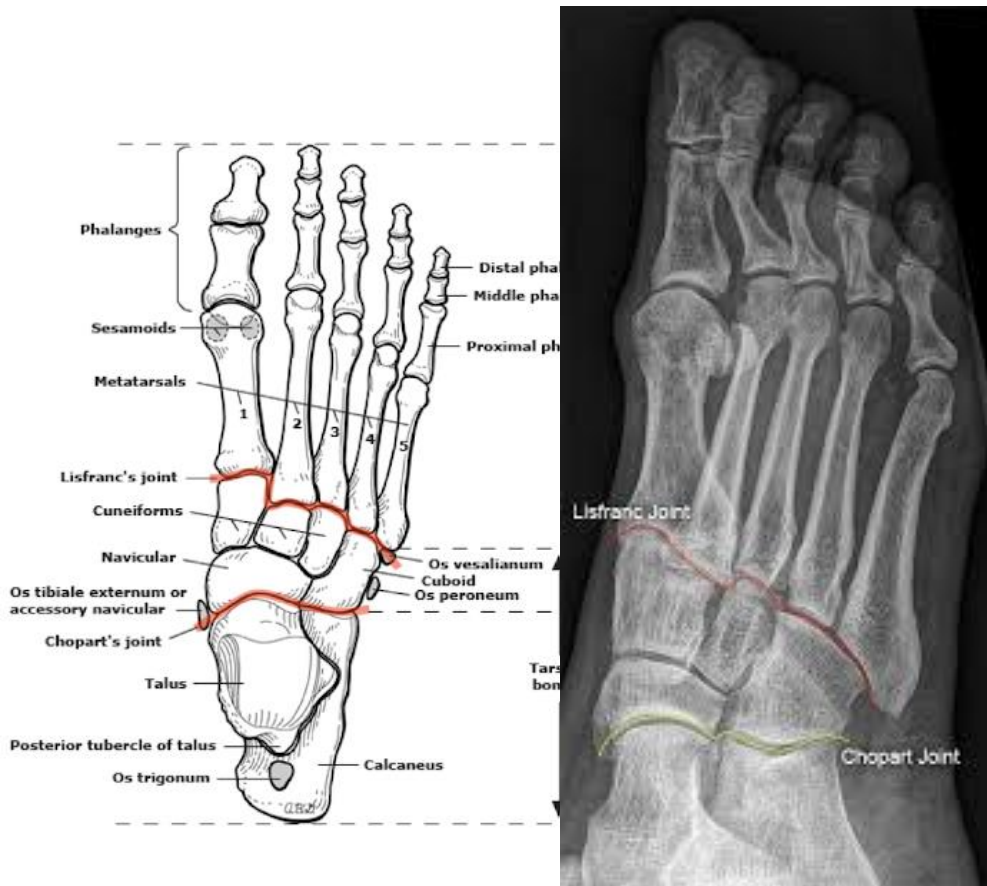


Joints of foot (*Articulationes pedis*)



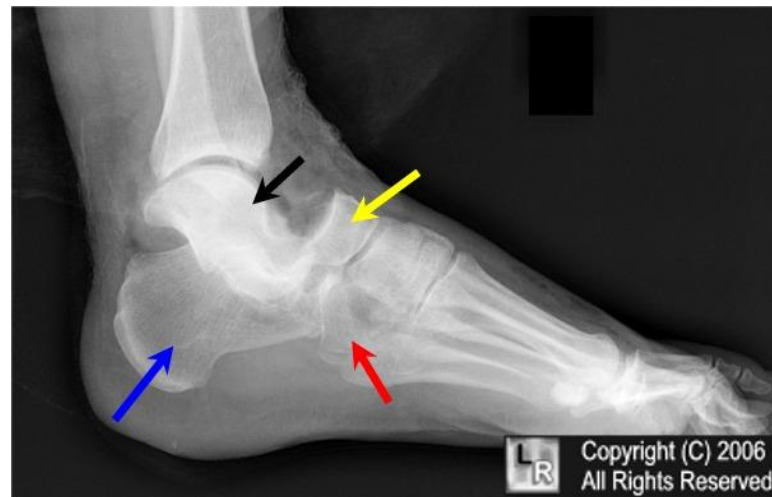
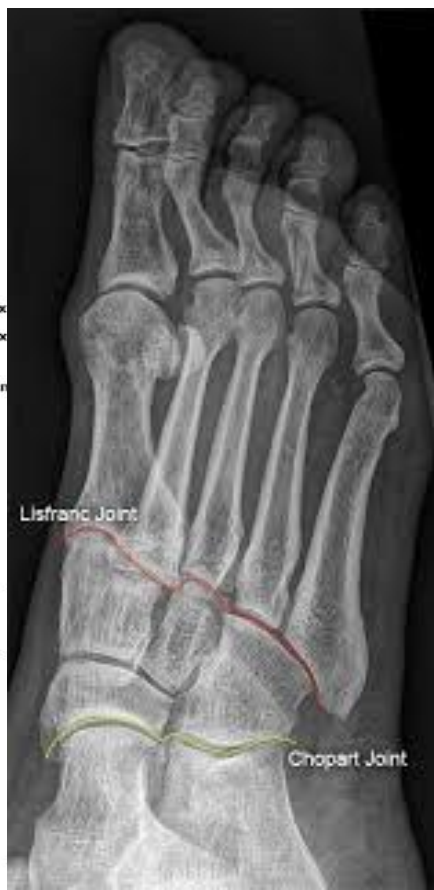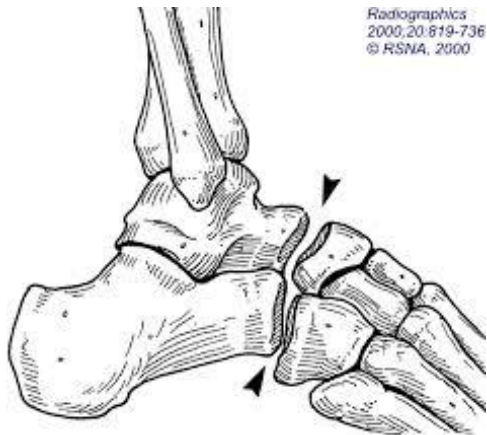


lisfranc's line fracture

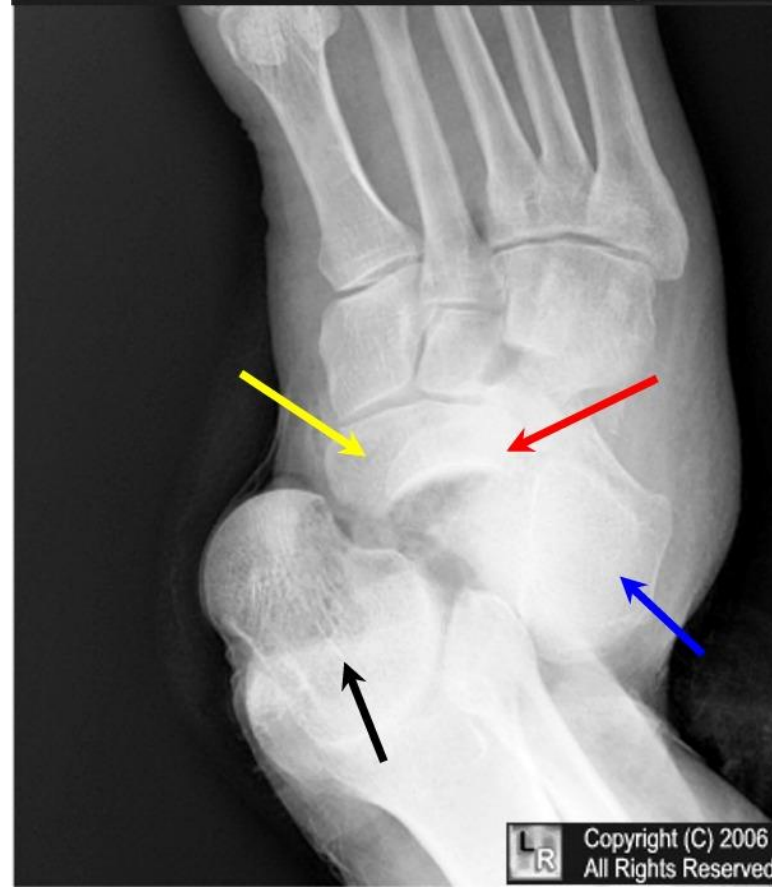
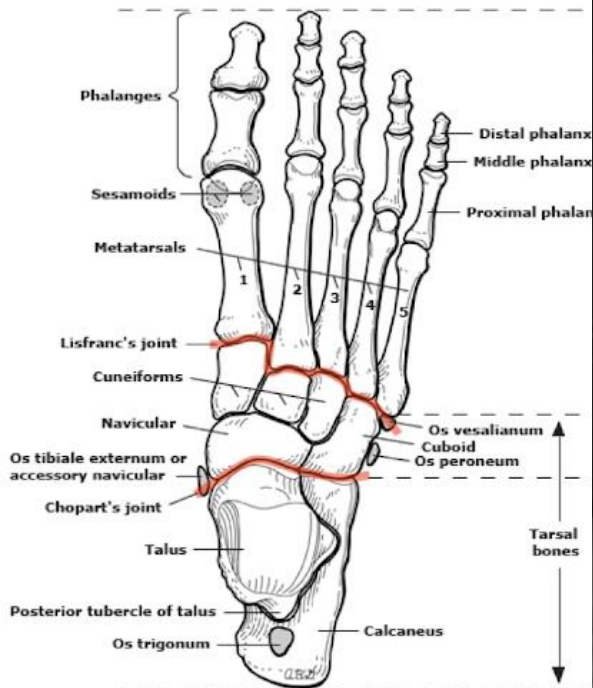


Chopart's line fracture

Radiographics
2000;20:819-736
© RSNA, 2000



LR Copyright (C) 2006
All Rights Reserved



LR Copyright (C) 2006
All Rights Reserved