

CRANIAL NERVES

2nd part

David Kachlík

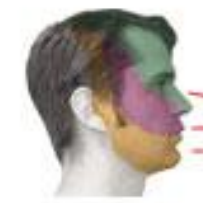— sensory fibres
— motor fibres

Optic (II)
sensory: eye



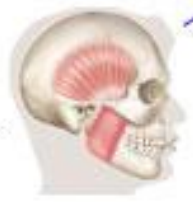
Trochlear (IV)
motor: superior oblique muscle

Abducent (VI)
motor: external rectus muscle

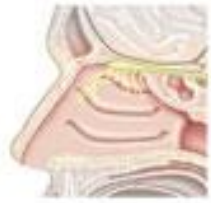

Trigeminal (V)
sensory: face, sinuses, teeth, etc.
motor: muscles of mastication

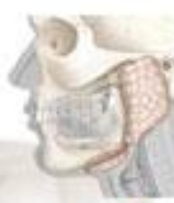Oculomotor (III)
motor: all eye muscles except those supplied by IV and VI



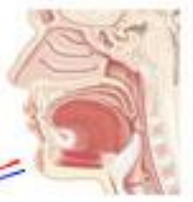Olfactory (I)
sensory: nose



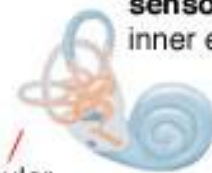Intermediate motor: submaxillary and sublingual gland
sensory: anterior part of tongue and soft palate



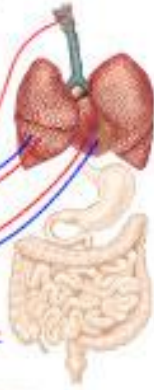Glossopharyngeal (IX)
motor: pharyngeal musculature
sensory: posterior part of tongue, tonsil, pharynx



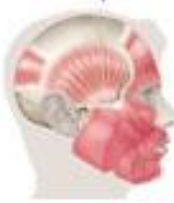Vestibulocochlear (VIII)
sensory: inner ear



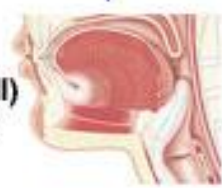Vagus (X)
motor: heart, lungs, bronchi, gastrointestinal tract
sensory: heart, lungs, bronchi, trachea, larynx, pharynx, gastrointestinal tract, external ear



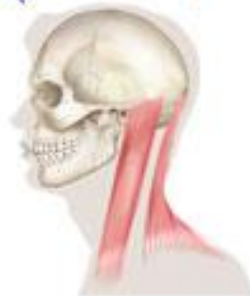Facial (VII)
motor: muscles of the face



Hypoglossal (XII)
motor: muscles of the tongue

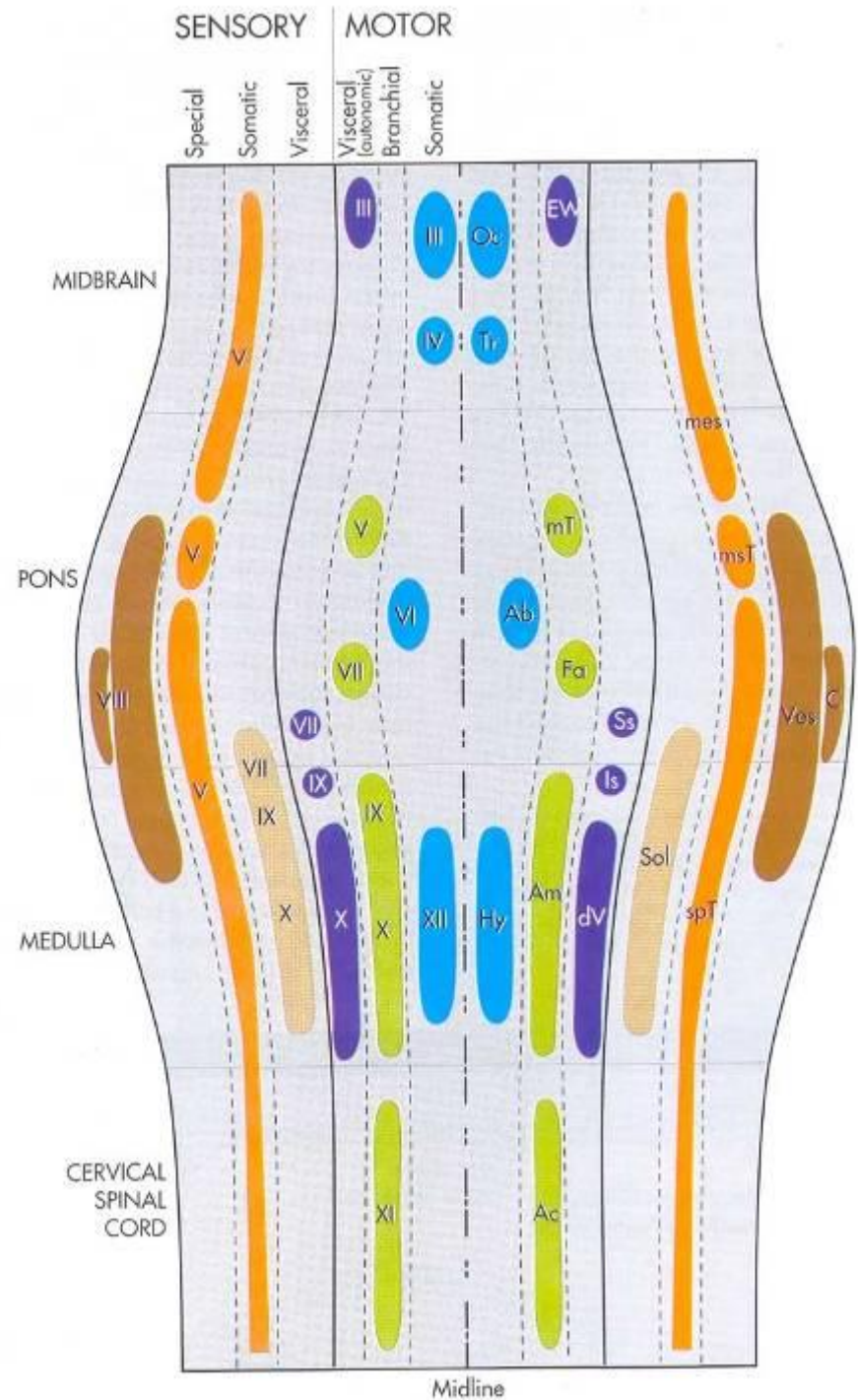


Accessory (XI)
motor: sternocleidomastoid and trapezius muscles

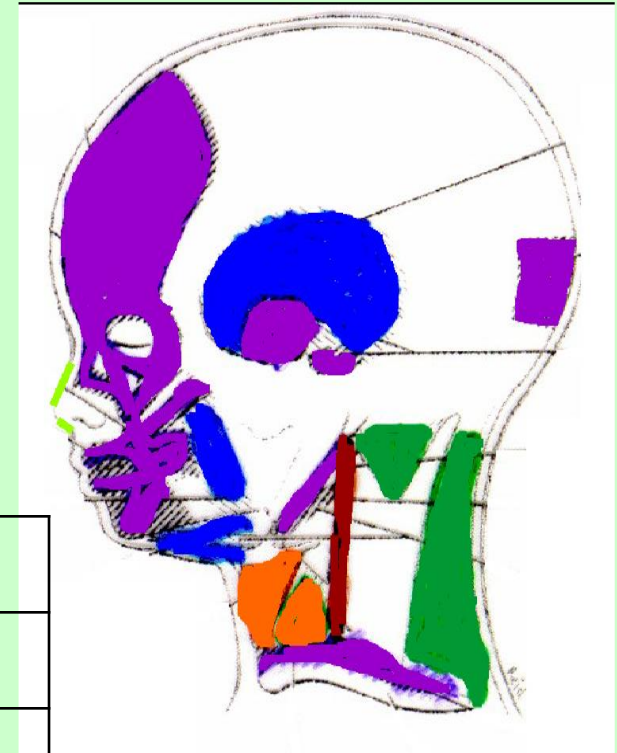



Developmental classification *mediolaterally*

- somatomotor somatic
- somatomotor branchial
- visceromotor
- viscerosensory
- somatosensory
- special sensory



SomatoMotor Branchial CN



1st arch	V.
2nd arch	VII.
3rd arch	IX.
4th arch	X. – n. laryngeus sup.
6th arch	r. int. XI. - n. lar. recurrens

General scheme for CN study

1. number, Latin and English term
2. developmental type of CN
3. nuclei + their location
4. transmitted modalities
5. where CN submerge into skull
6. course of CN + topography
7. branches
8. overview of supplied area
9. clinical examination, reflexes
10. palsy / irritation

VII. = N. facialis

lateral view (r.).

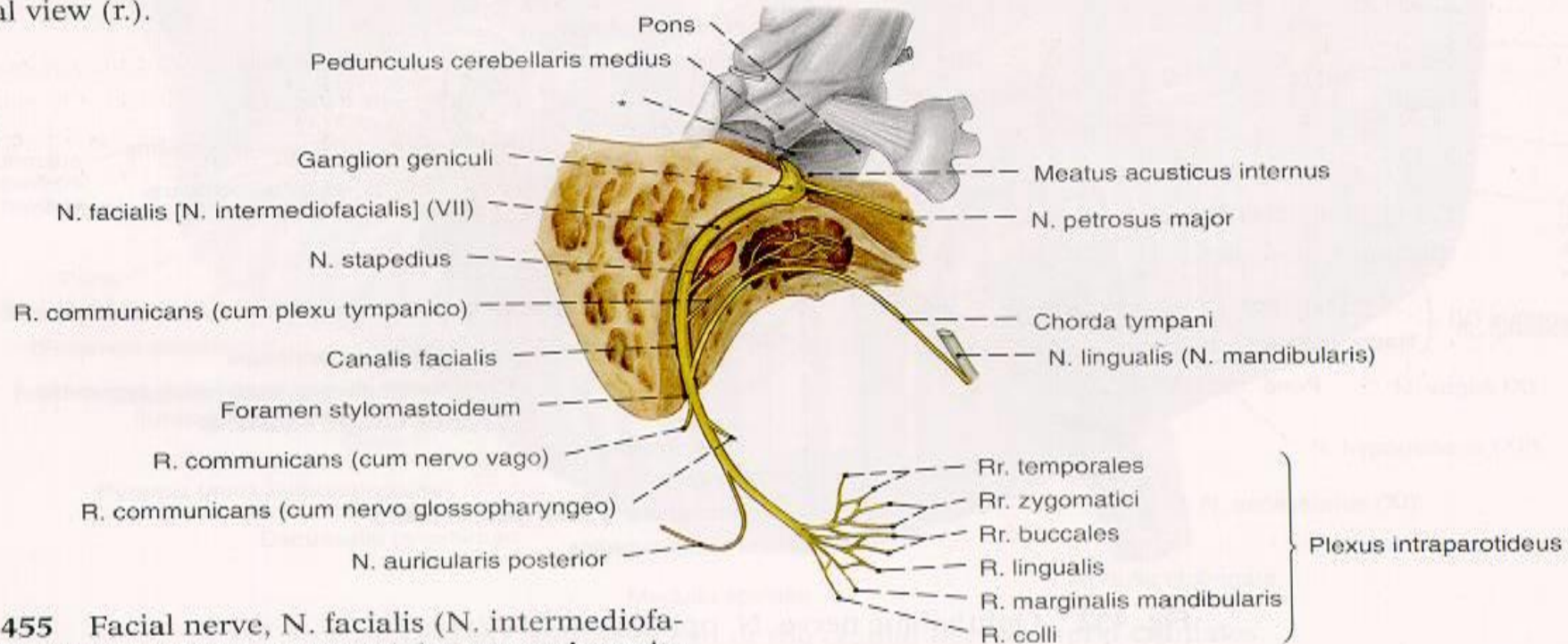


Fig. 455 Facial nerve, N. facialis (N. intermediofacialis) (VII); the facial canal and the tympanic cavity have been exposed; lateral view (r.).

* clinically: cerebellopontile angle

VII. = N. facialis

3 nuclei in pons

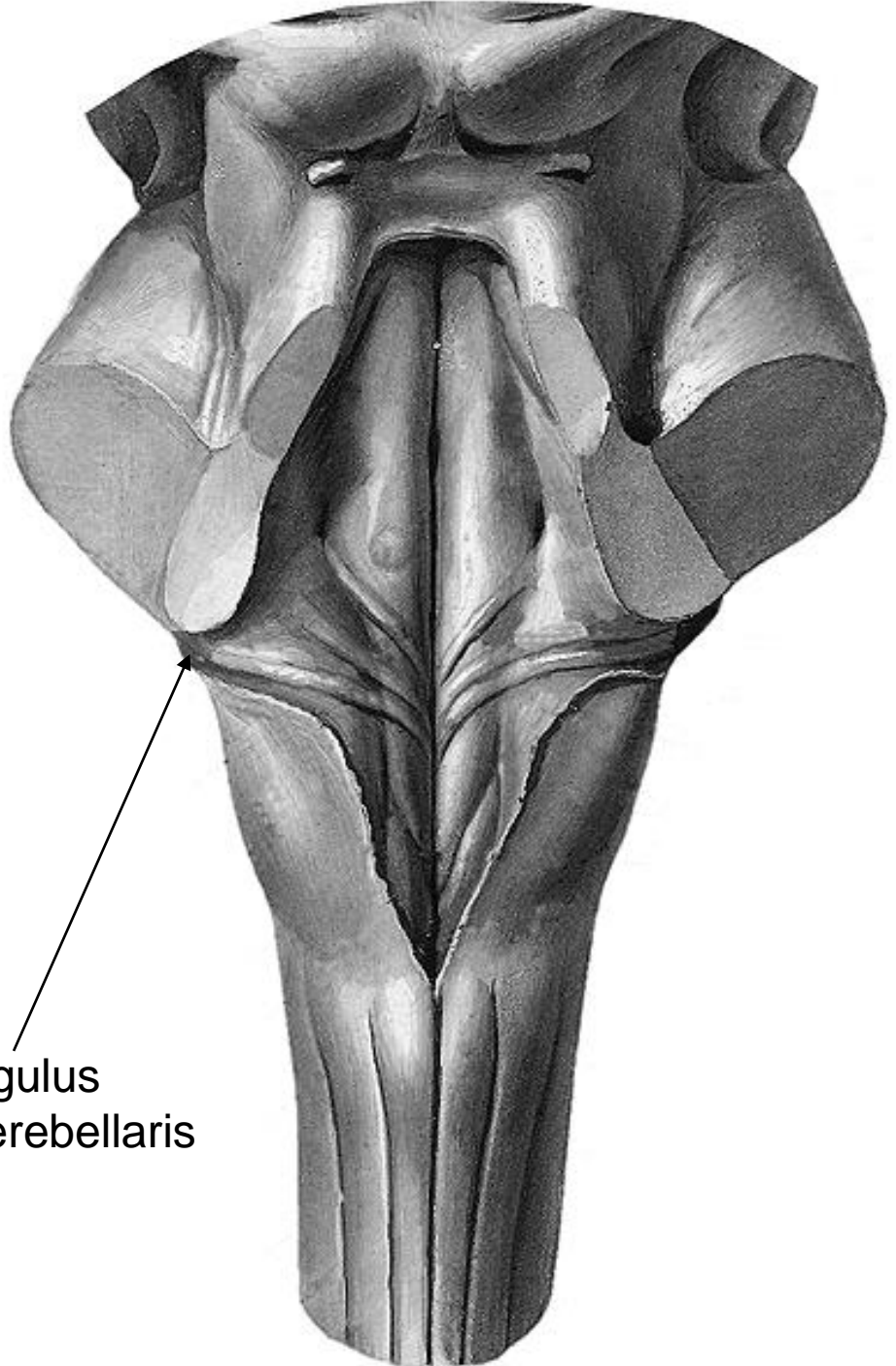
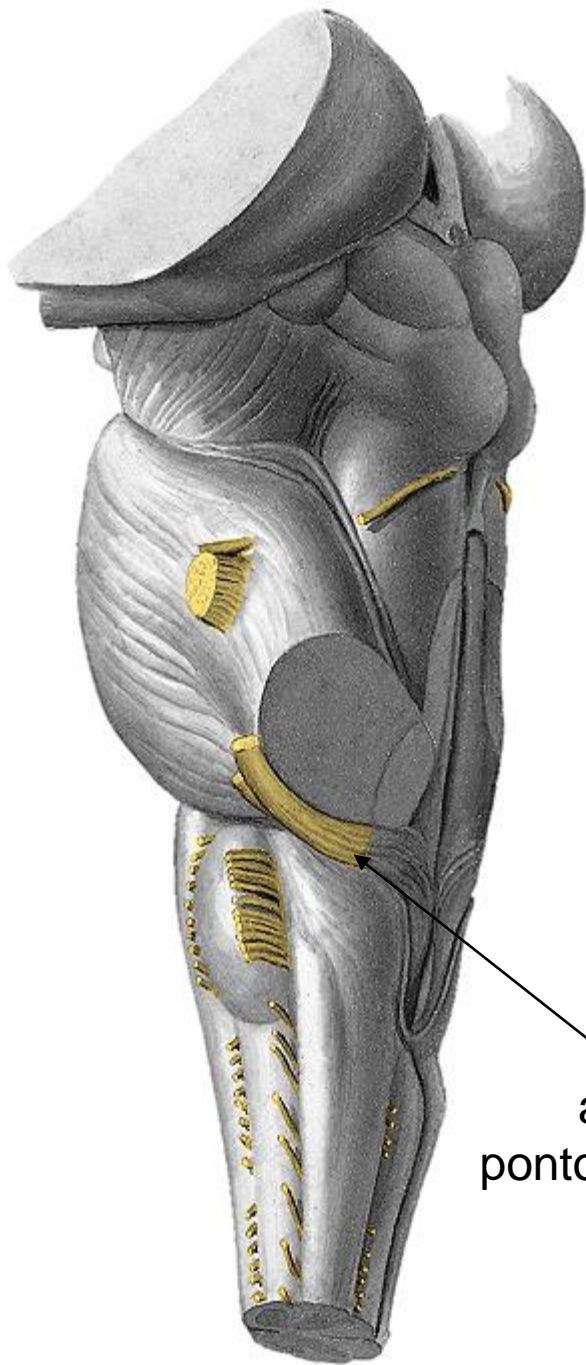
- *somatomotor branchial* (2nd arch) → **ncl. n. VII**
- *visceromotor* (parasympathetic) → **ncl. salivatorius superior**
- **ncl. gustatorius** (rostral part of ncll. tractus solitarii) → *sensory* (taste)

n. intermedius = VM fibres + taste fibres

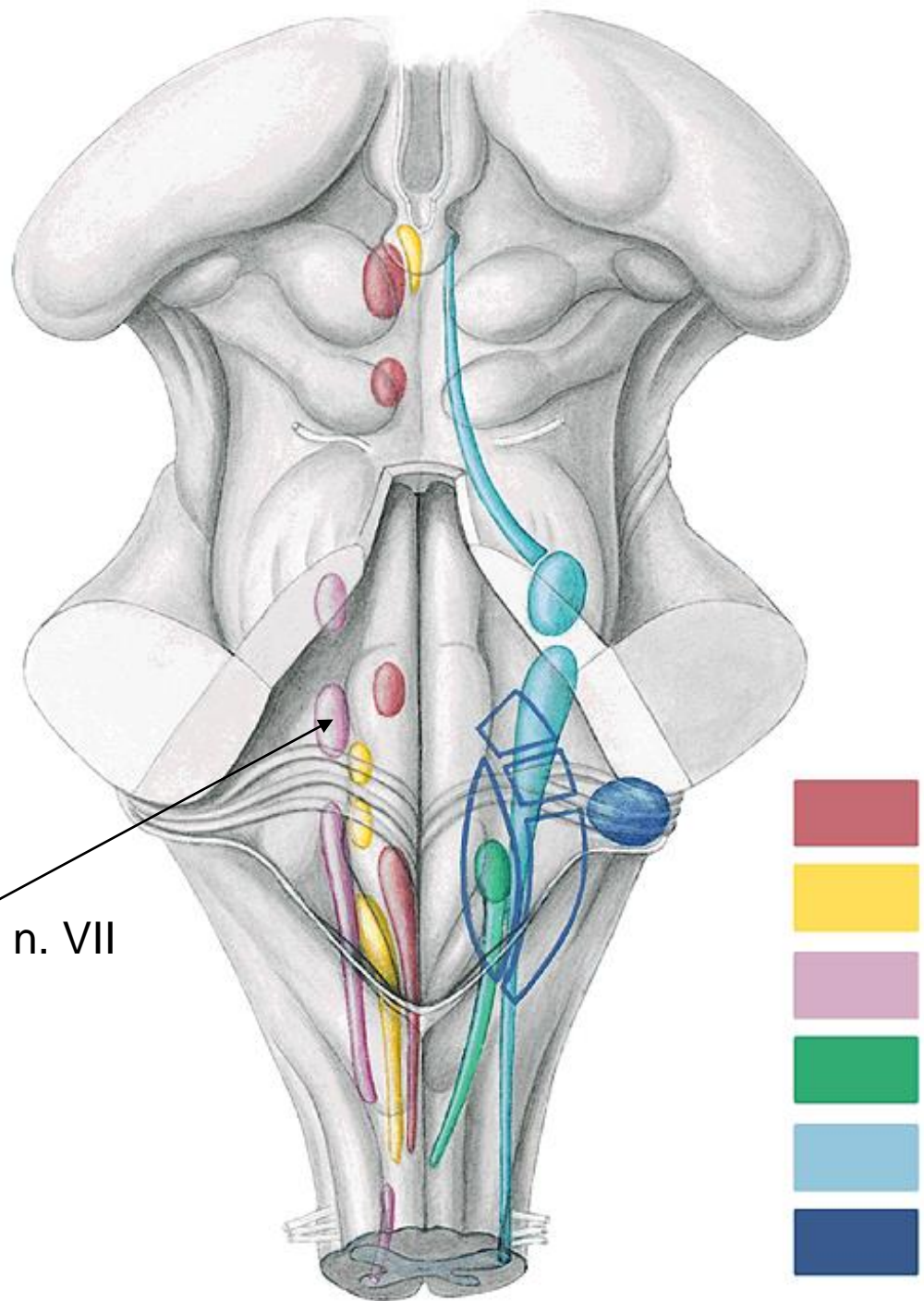
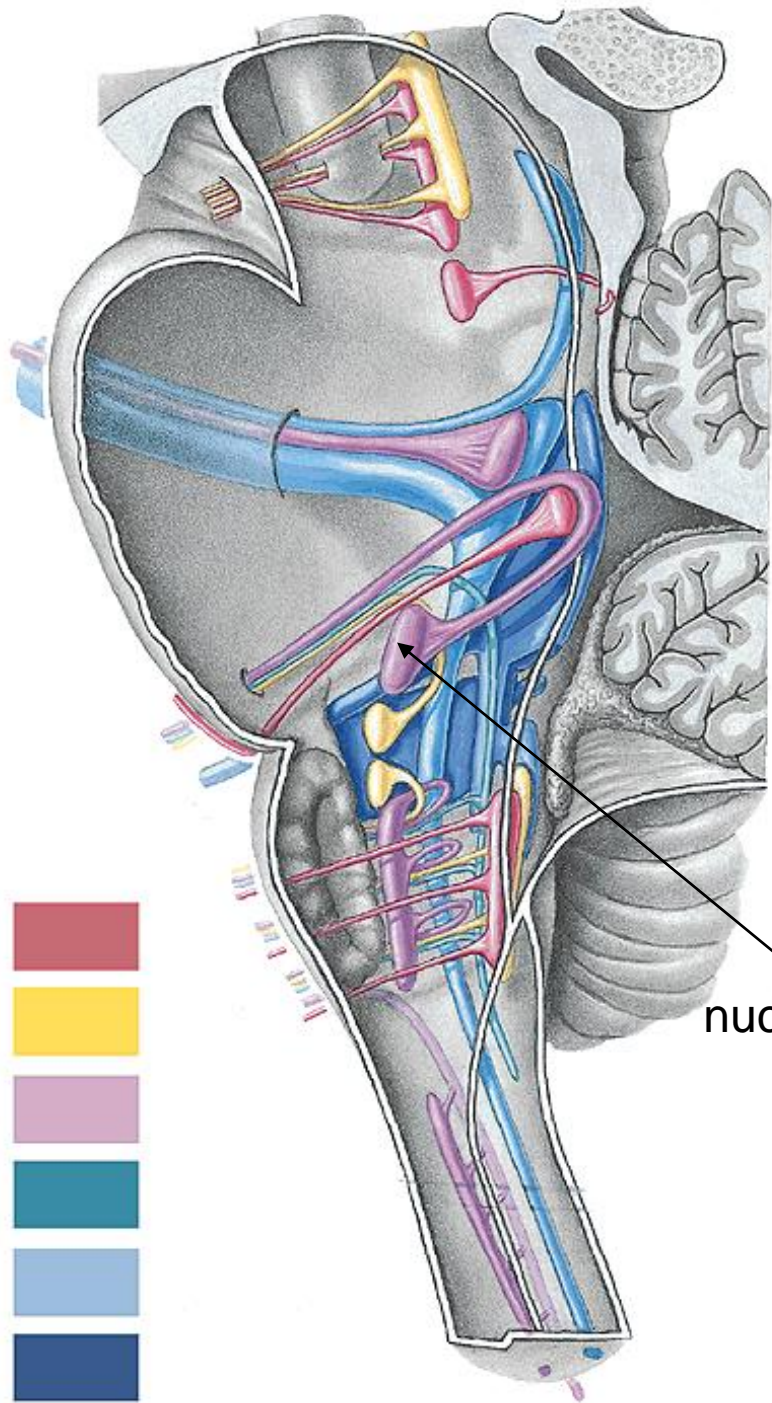
10.000 neurons

70% somatomotor

30% visceromotor + taste = **n. intermedius**

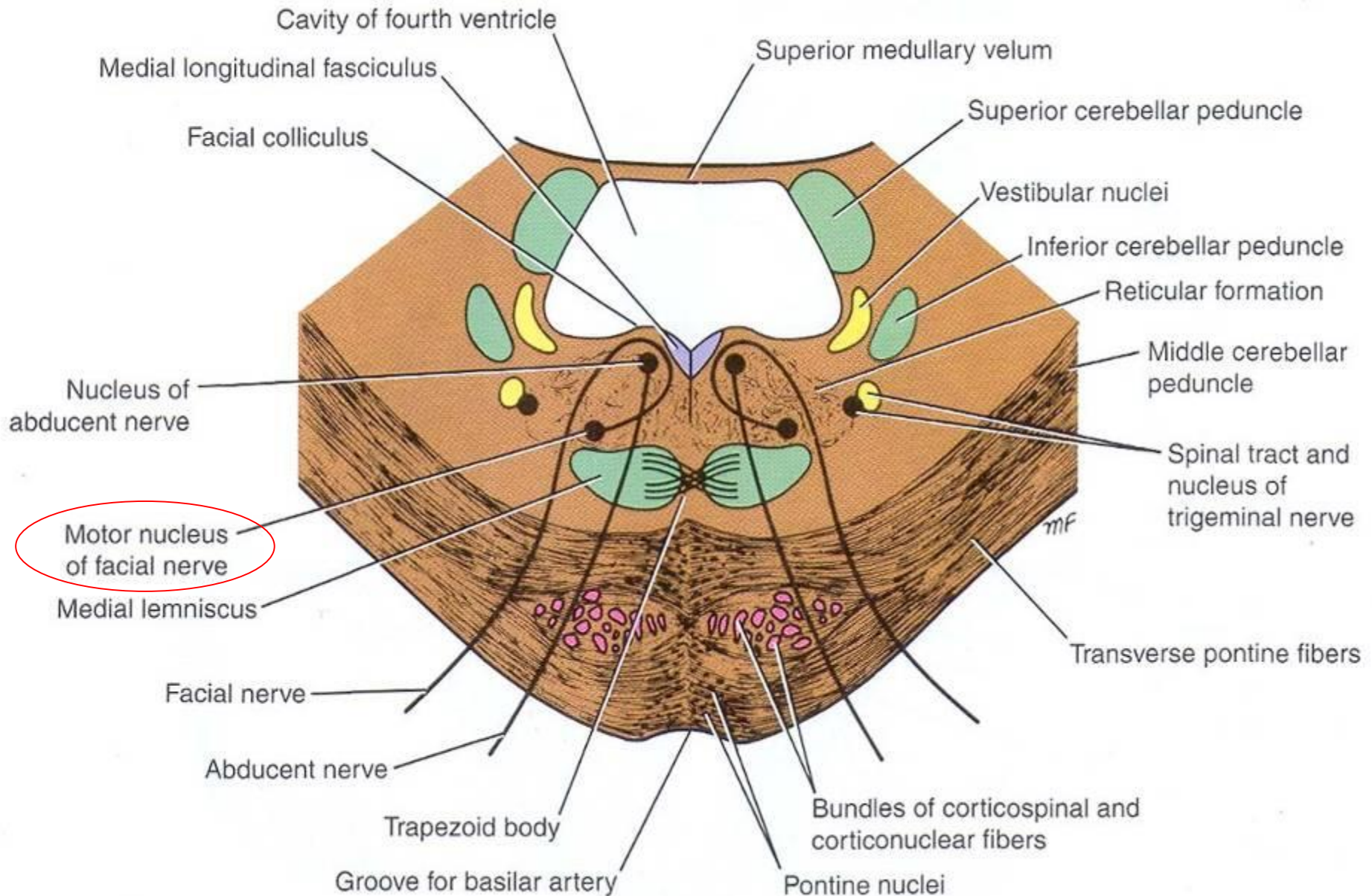


angulus
pontocerebellaris



nucleus n. VII

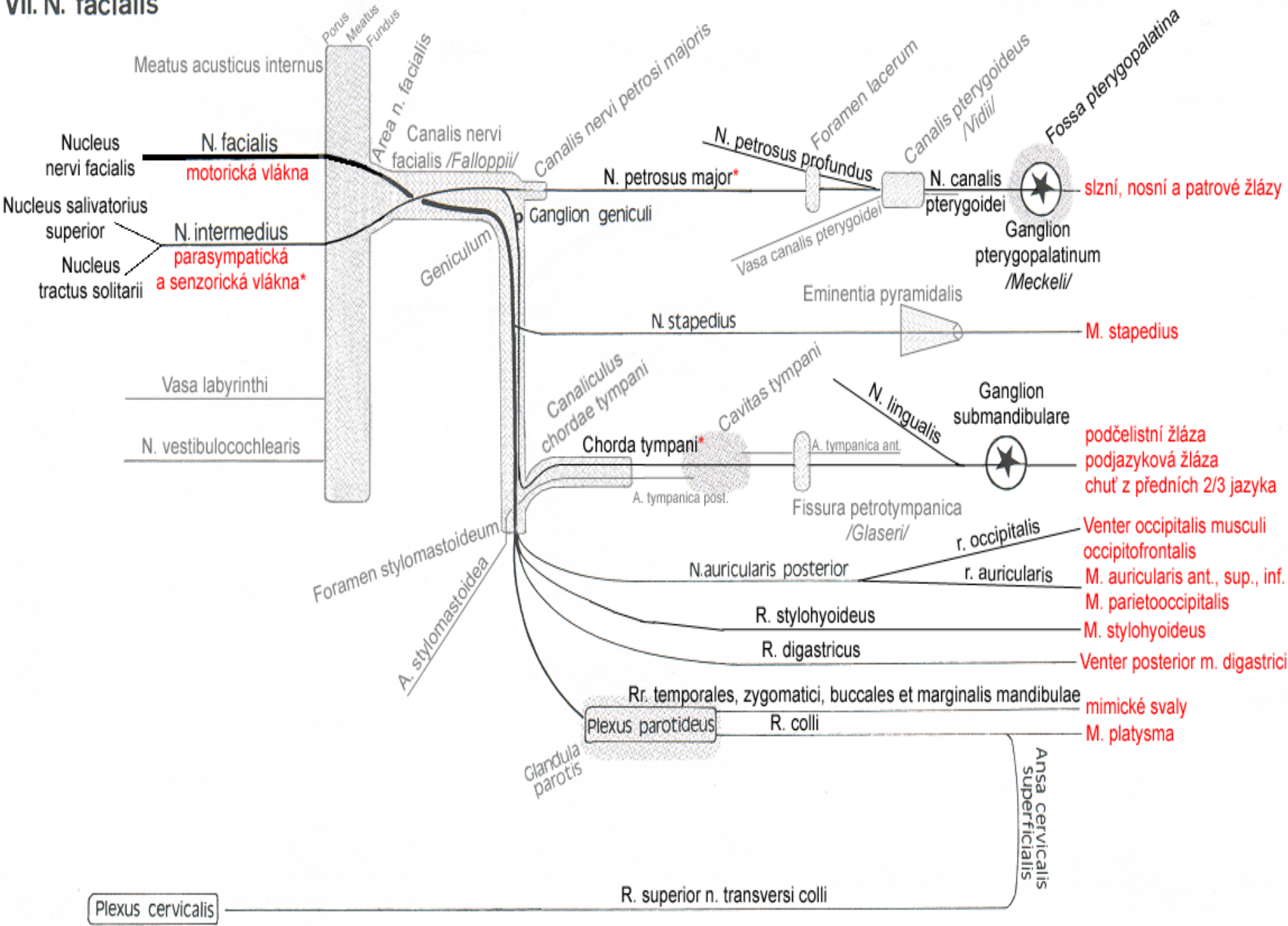
Pons - sectio in collicule faciale



Course

- angulus pontocerebellaris
 - fossa cranii posterior (cisterna pontocerebellaris)
 - porus acusticus internus (cisterna meatus acustici interni)
 - meatus acusticus internus
 - fundus m.a.i. (upper anterior quadrant)
 - canalis nervi facialis *Fallopian*
 - foramen stylomastoideum
 - glandula parotidea

VII. N. facialis



motorická vlákna

parasympatická
a senzoriclá vlákna*

slzní, nosní a patrové žlázy

podčelistní žláza
podjazyková žláza
chut' z předních 2/3 jazyka

Venter occipitalis musculi
occipitofrontalis
M. auricularis ant., sup., inf.
M. parietooccipitalis

M. stylohyoideus
Venter posterior m. digastrici

mimické svaly
M. platysma

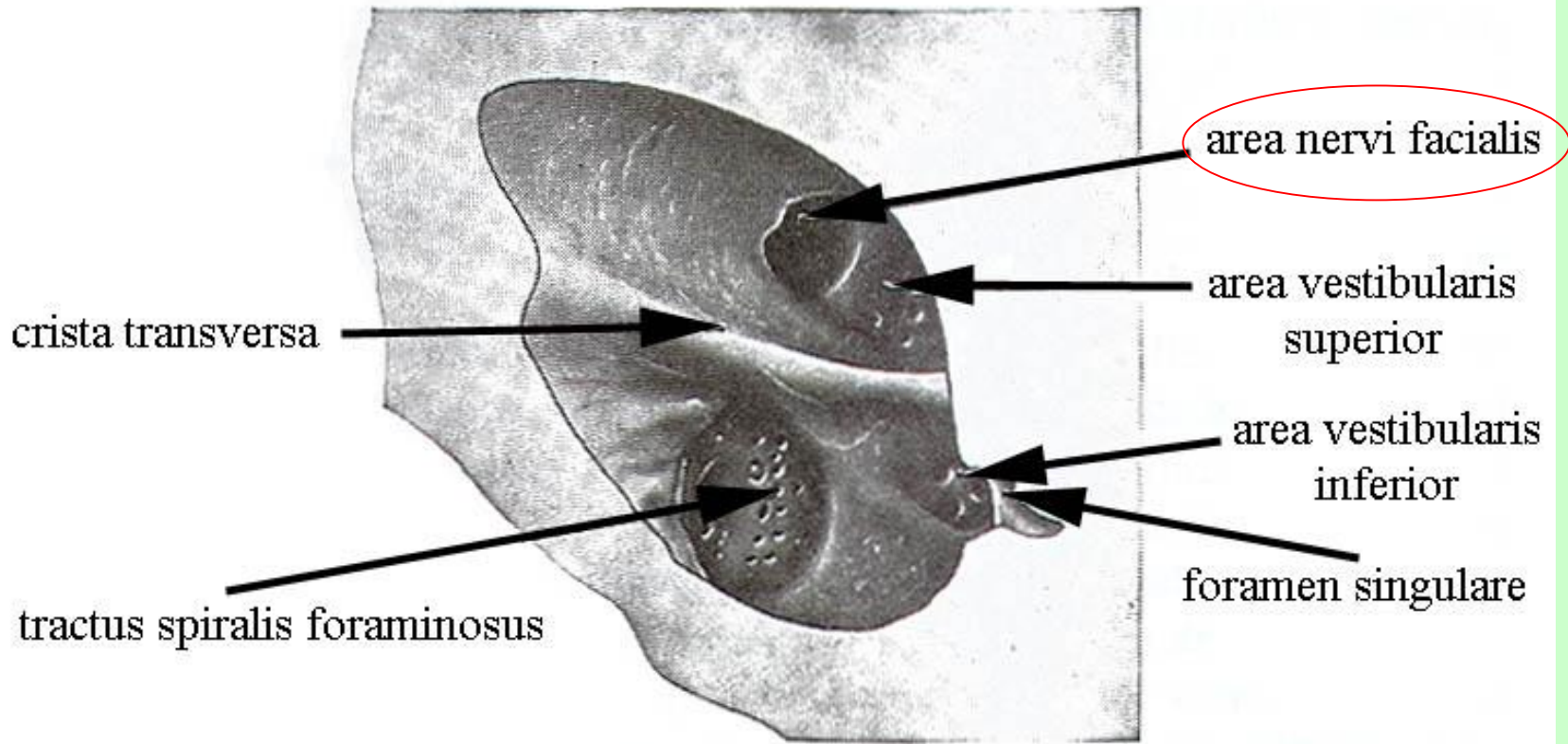
Plexus cervicalis

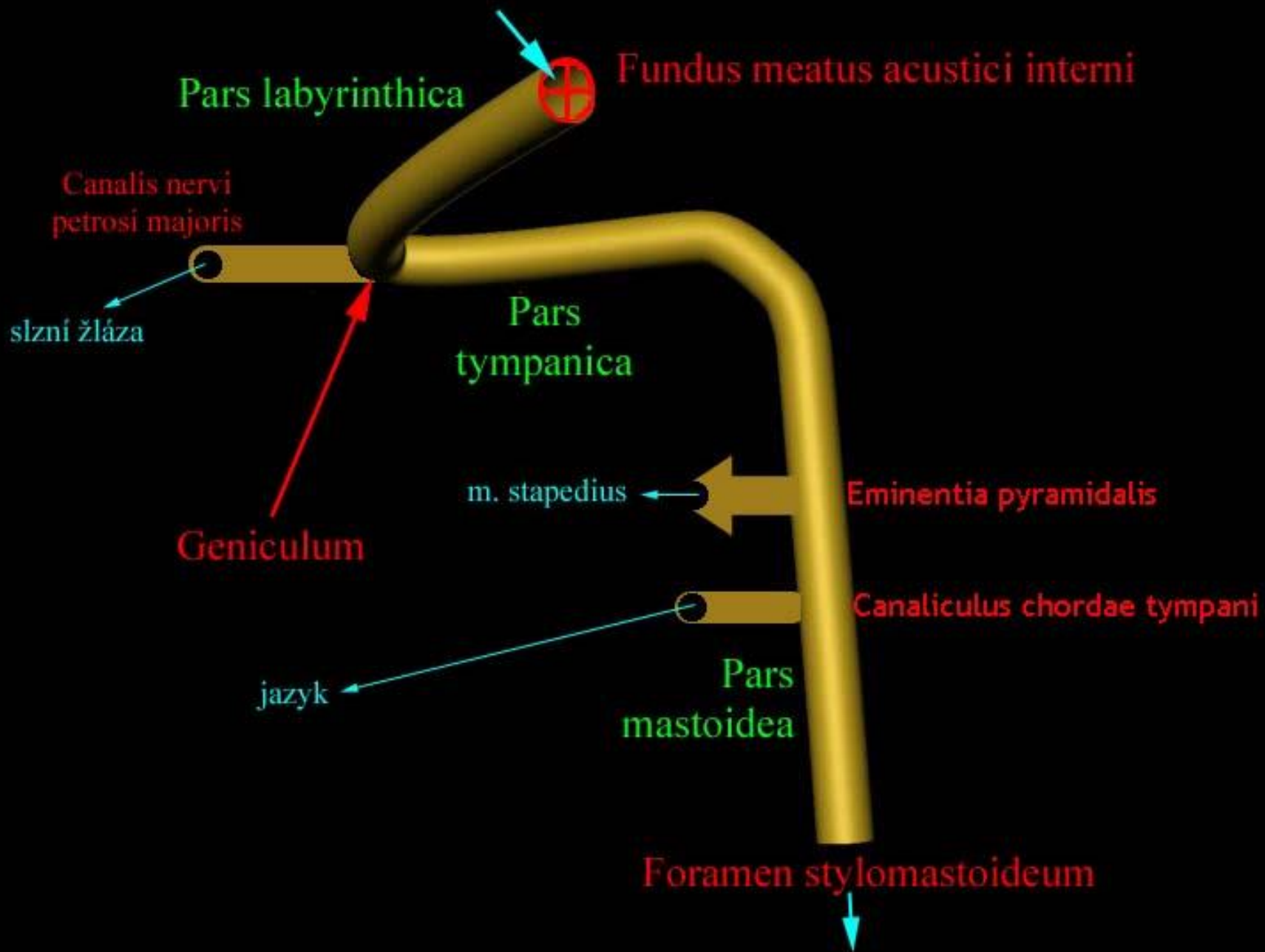
R. superior n. transversi colli

Ansa cervicalis
superficialis

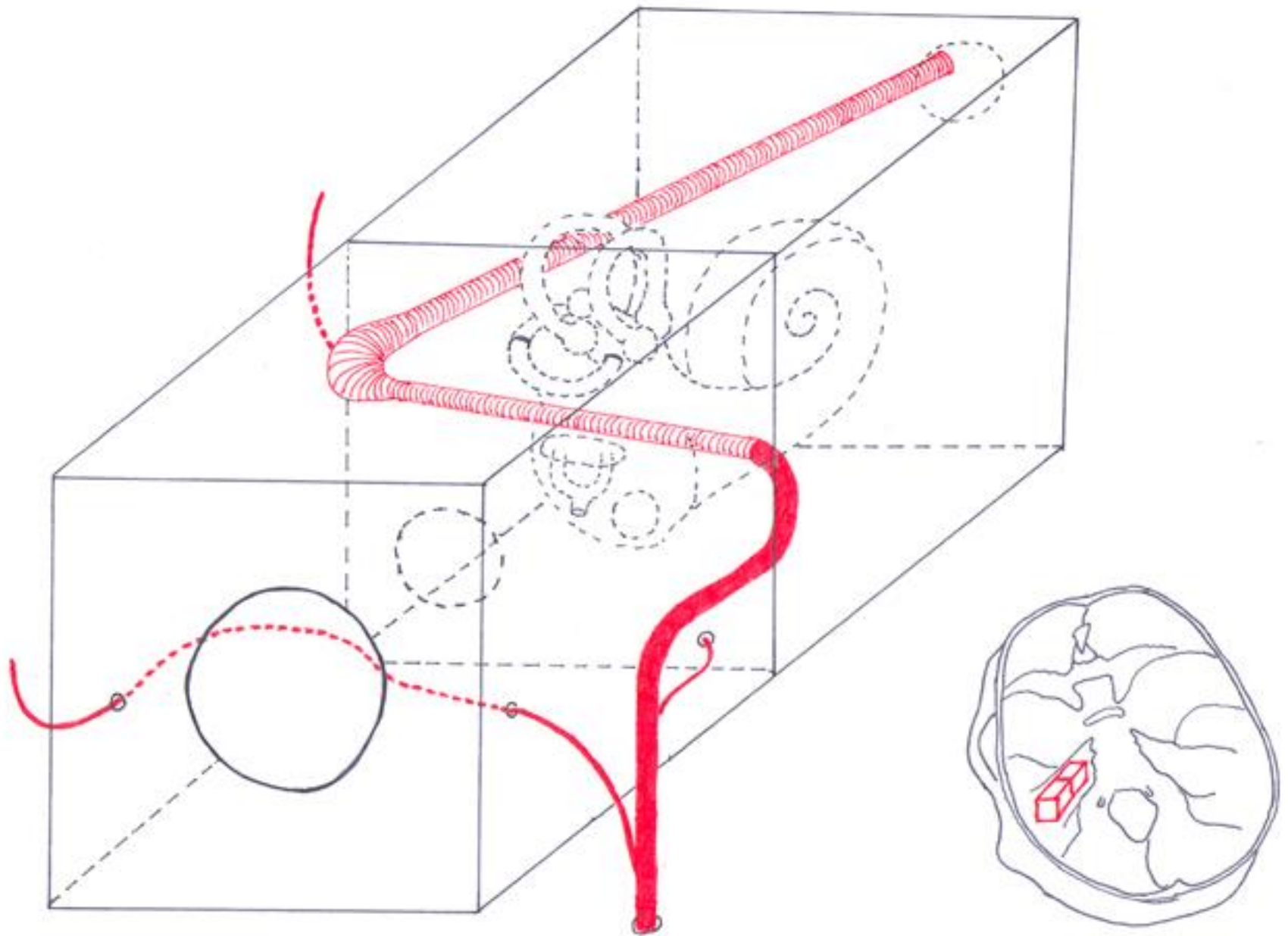
Canalis nervi facialis *Fallopiani*

MEATUS ACUSTICUS INTERNUS (fundus meatus acustici interni)





CANALIS NERVI FACIALIS *FALLOPPII* l. sin.



VII. = N. facialis – branches

in canalis nervi facialis

- **n. petrosus major** – *parasympathetic fibres* → **gll. lacrimalis, nasales, palatinae, nasopharyngeae**
- **n. stapedius** → **m. stapedius**
- **chorda tympani**
 - *parasympathetic fibres* → **gll. linguales, submandibularis + sublingualis**
 - **taste** → ventral 2/3 of tongue = **dorsum linguae**

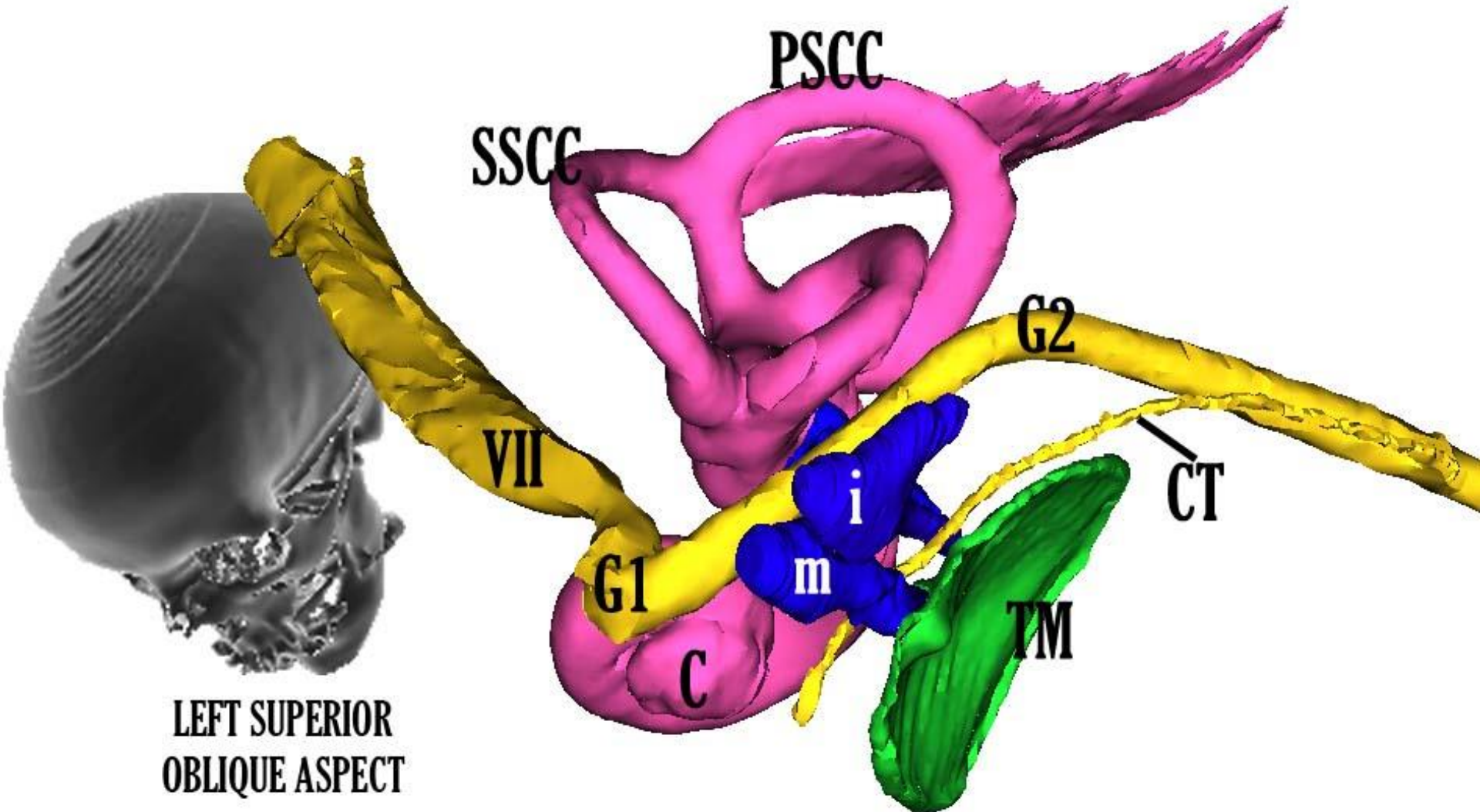
outside skull

- **n. auricularis posterior** – *somatomotor fibres* → rudimentary muscles of auricle + 3 mm. **auriculares**
- **nn.** for m. stylohyoideus + venter post. m. digastrici
- **plexus intraparotideus – 5 branches**

VII. = N. facialis – branches courses

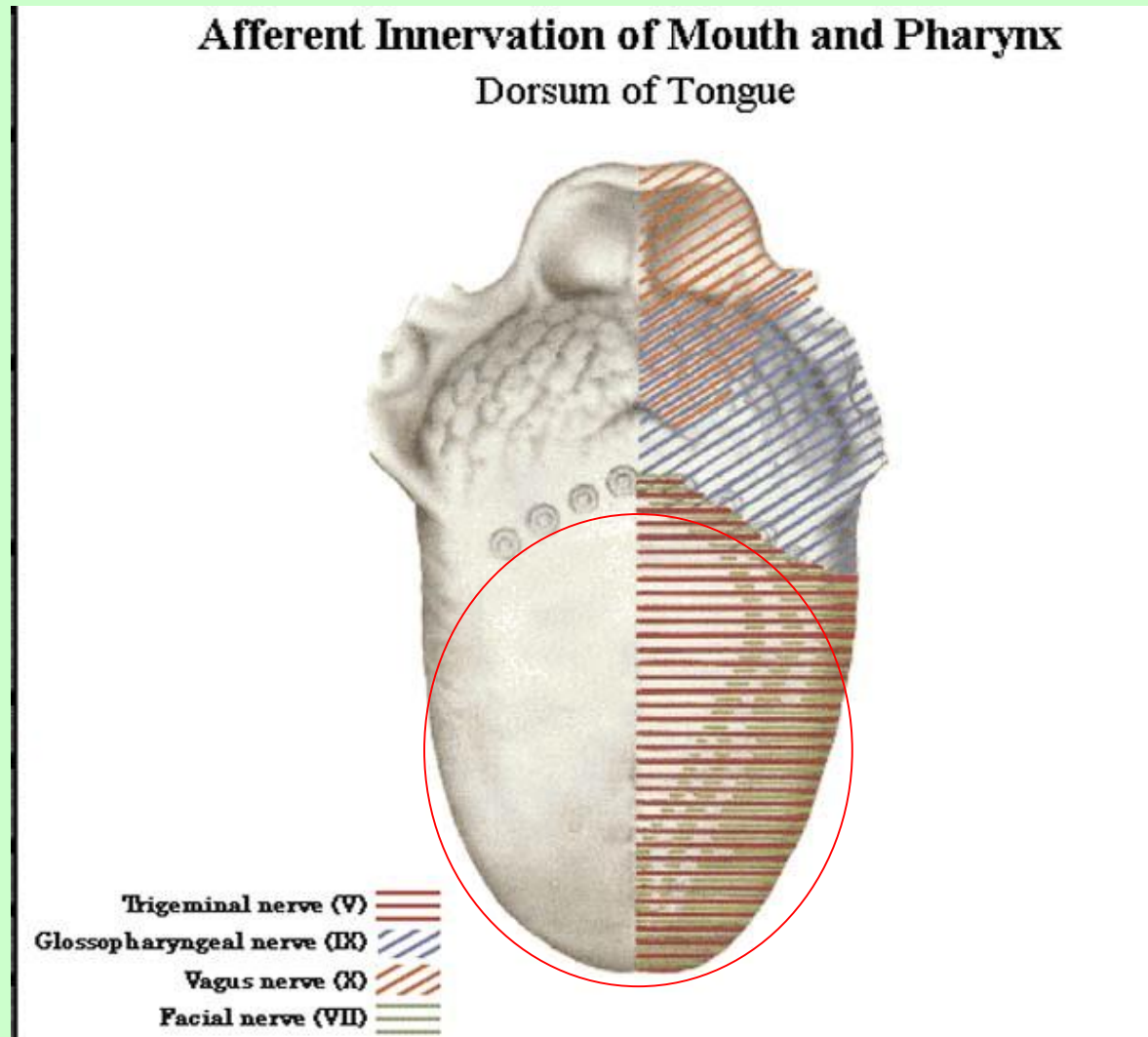
- n. petrosus major – *parasympathetic*
 - canalis n.p.m. → sulcus n.p.m. → foramen lacerum → canalis pterygoideus *Vidii* → fossa pterygopalatina → ggl. pterygopalatinum → via branches of n.V2 to gll. lacrimalis, nasales, palatinae, nasopharyngeae
- n. stapedius – *somatomotor*
 - eminentia pyramidalis: m. stapedius
- chorda tympani – *parasympathetic* + *taste*
 - canaliculus ch.t. posterior → cavitas tympani → canaliculus ch.t. anterior → fissura petrotympanica *Glaseri* → fossa infratemporalis → n. lingualis
 - → gg. submandibulare → via branches of n. V3 to gll. linguales, submandibularis + sublingualis
 - → ventral 2/3 of tongue = dorsum linguae – *taste*

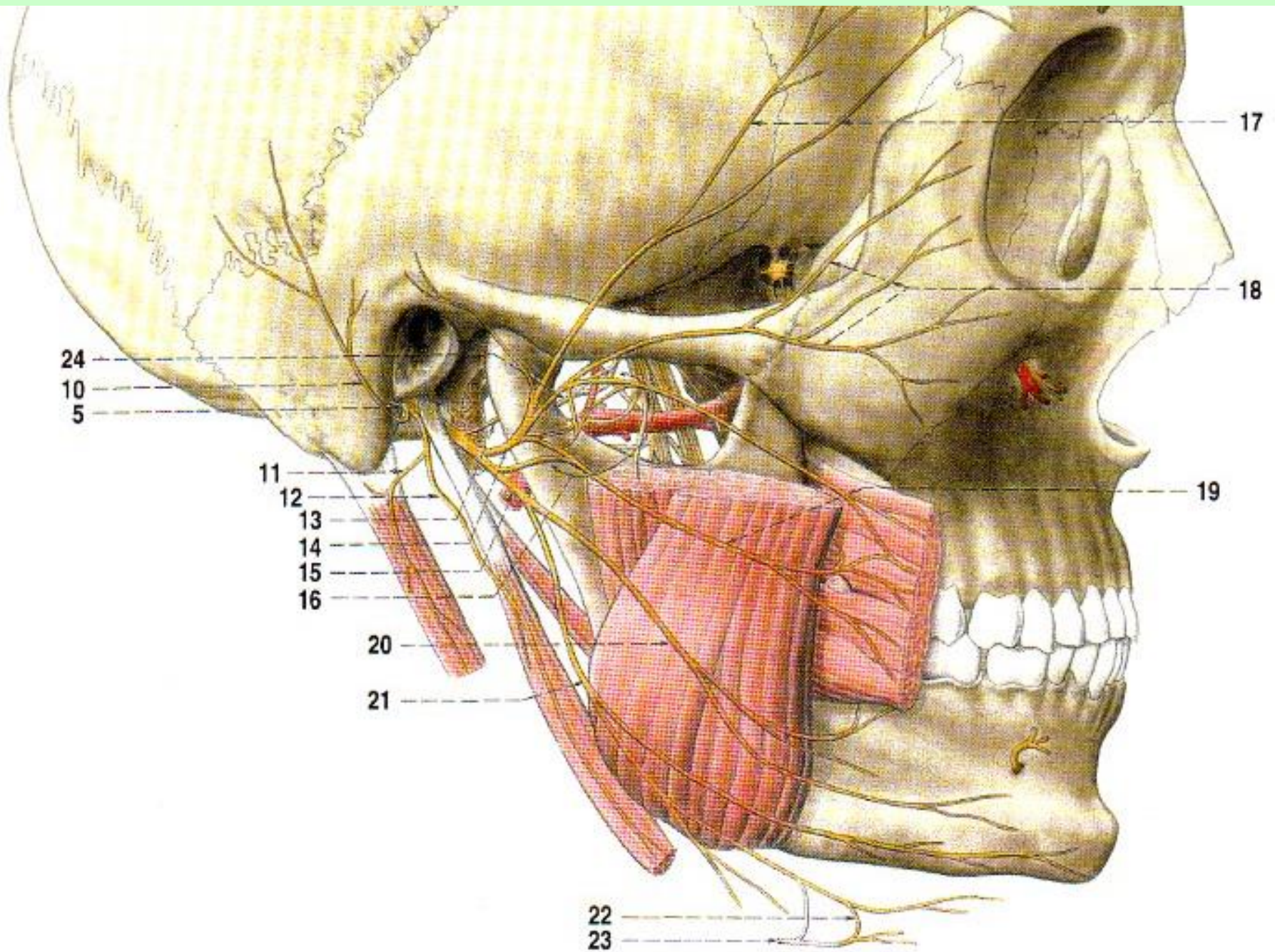
Canalis nervi facialis *Fallopiani*



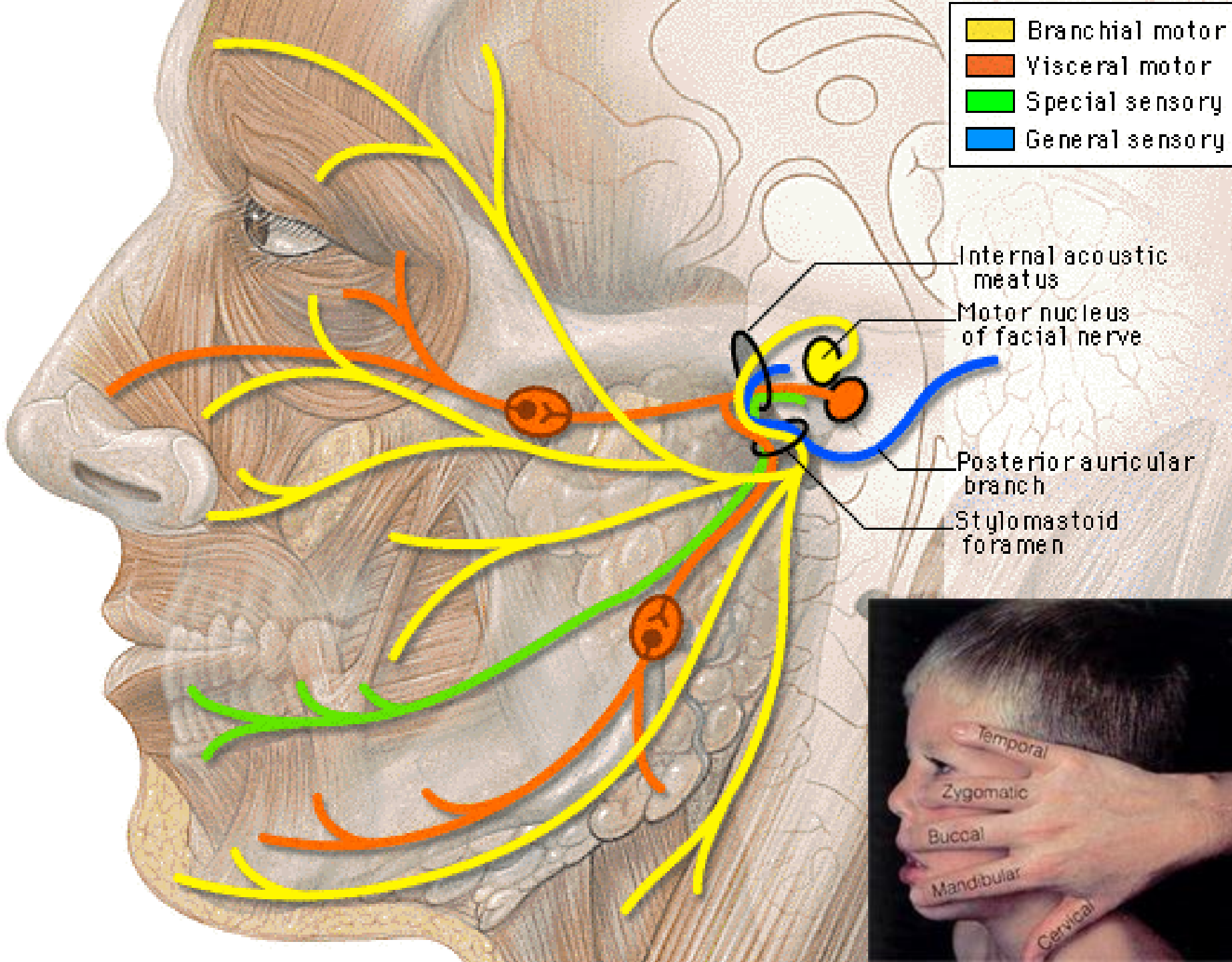
Innervation of tongue

somatosensory x sensory (taste)





- Branchial motor
- Visceral motor
- Special sensory
- General sensory

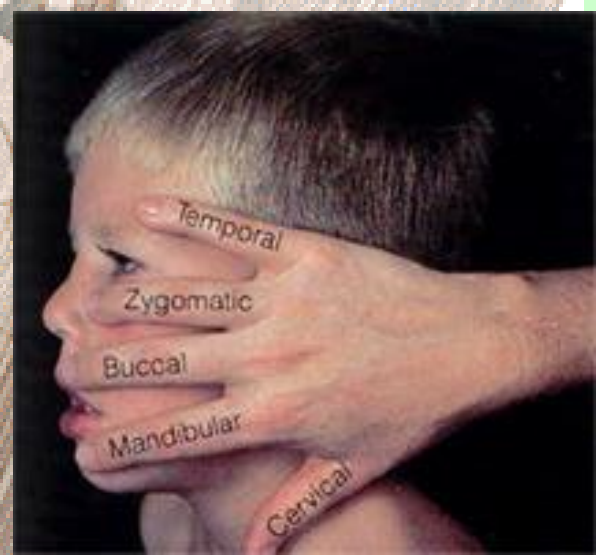


Internal acoustic meatus

Motor nucleus of facial nerve

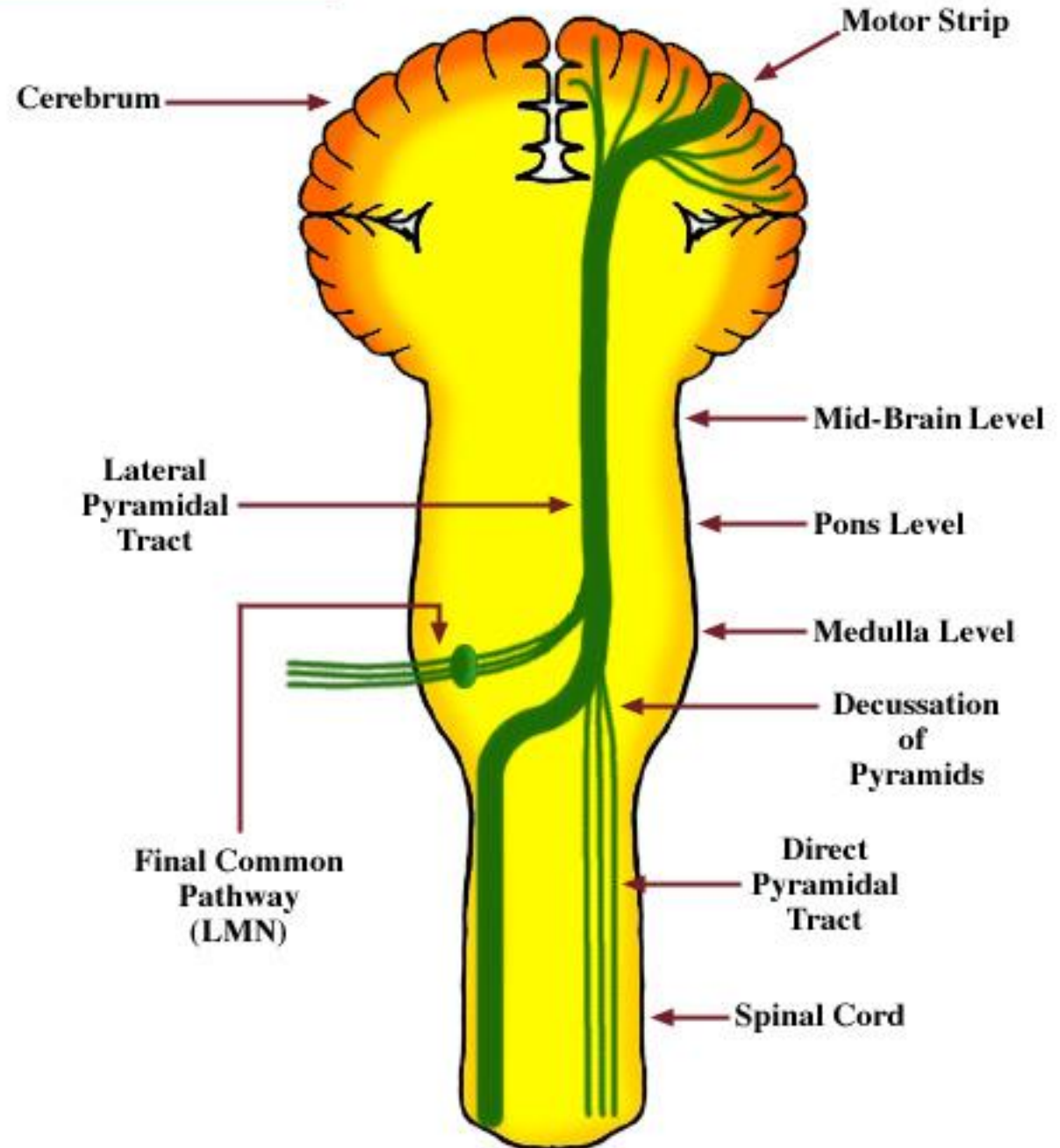
Posterior auricular branch

Stylomastoid foramen



Motor pathway

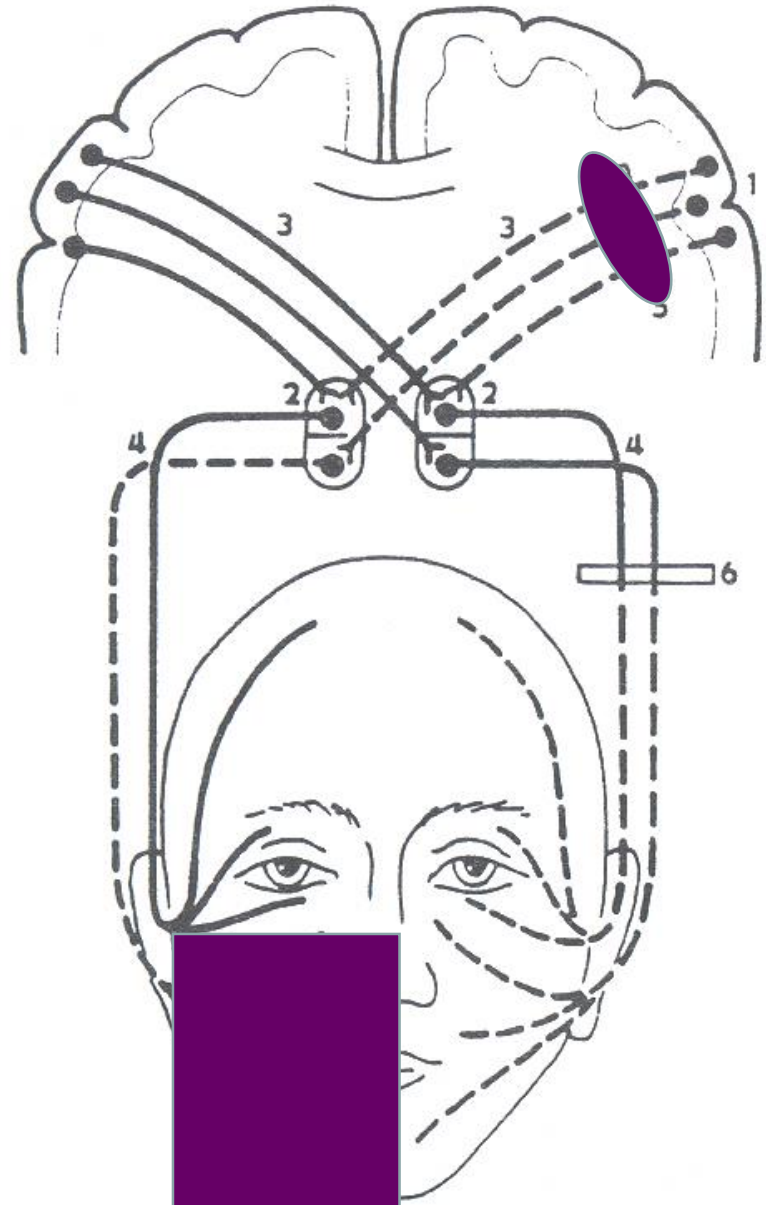
PYRAMIDAL TRACT



- tractus pyramidalis
- fibrae cortico-nucleares
- decussated

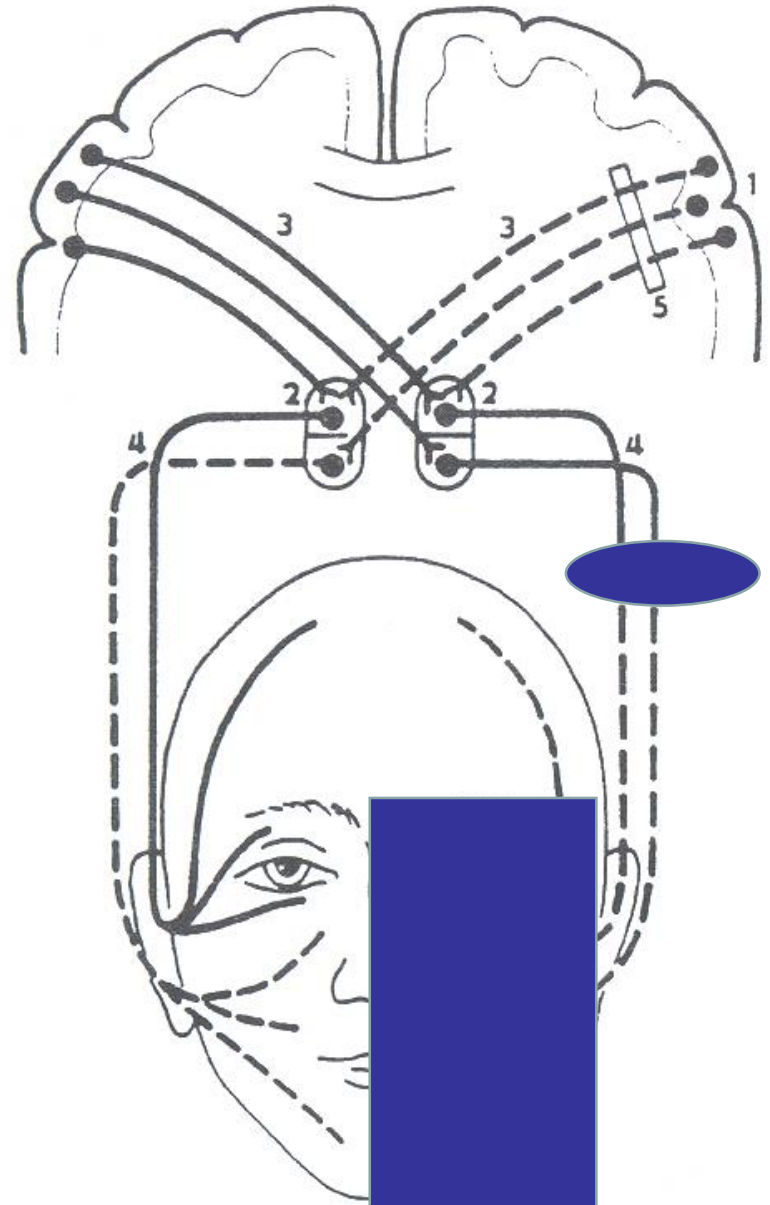
Central palsy

- supranuclear lesion = affected pathway between cerebral cortex and nucleus in brain stem
- palsy of **only lower quadrant of face !!!**
- **contralateral side !!!**



Peripheral palsy

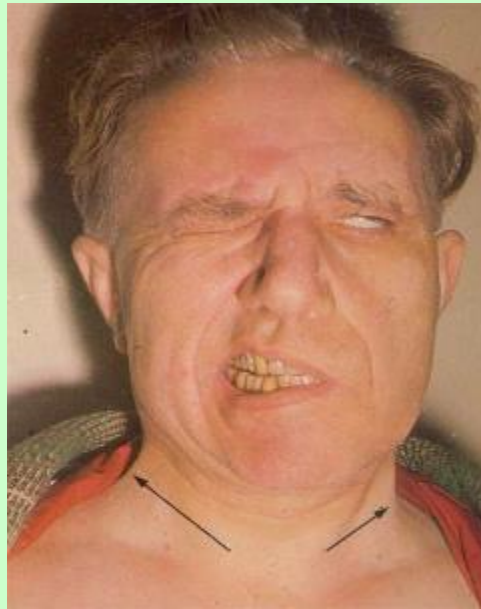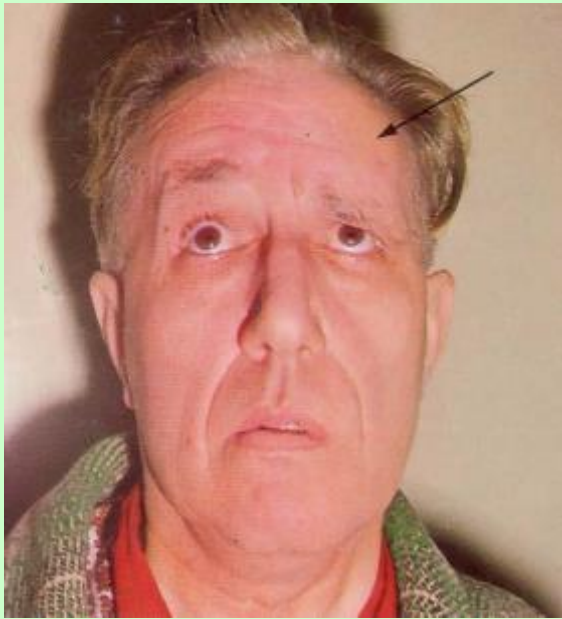- nuclear lesion
= affected neuron (body or fibers) between nucleus in brain stem and effectors/receptors
- palsy of ***whole half of face !!!***
- ***ipsilateral (homolateral) side !!!***



Peripheral palsy – ipsilateral

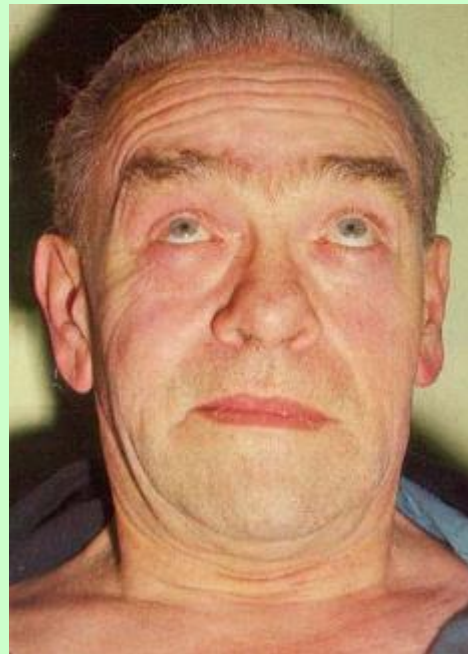
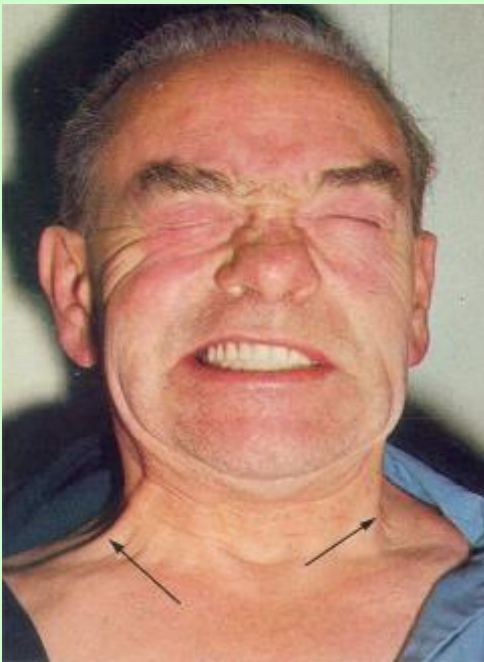
symptoms related to level of affection and branches of n. VII

- Bell's palsy = palsy of **all ipsilateral facial muscles**
(sagged mouth angle + dribbling saliva, drooped lower lid = lagophthalmus, no gathers on forehead, smoothed nasolabial groove, no frowning and whistling)
- affection of chorda tympani
 - no taste on ventral 2/3 of tongue = hypogeusia → ageusia
 - dry mouth – no secretion from gl. submandibularis + sublingualis = xerostomia) – *weak symptom*
- affection of m. stapedius (sharp/painful = hyperacusis)
- affection of n. petrosus major
 - dry eye - no secretion from lacrimal gland, dry conjunctiva = xerophthalmia
 - no secretion of gl. nasales, palatinae, nasopharyngeae – *weak symptom*

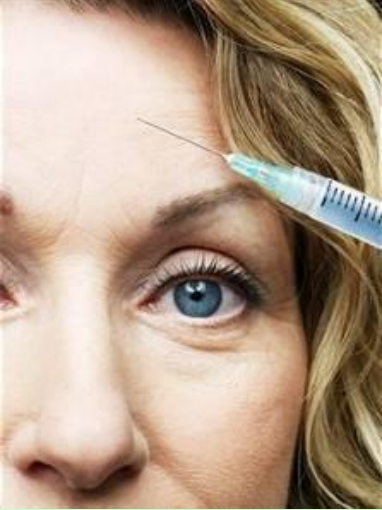

**peripheral
„Bell´s“ palsy**


n. VII



central palsy



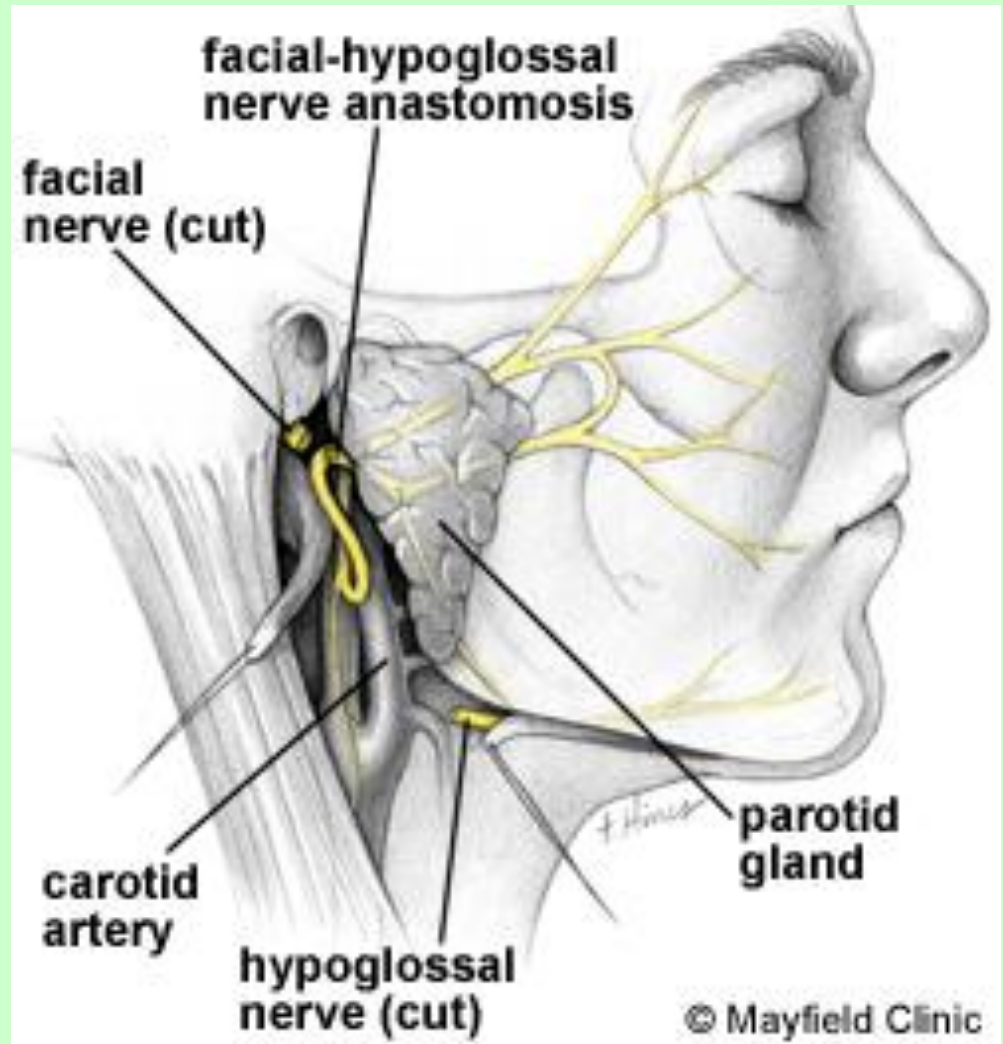
Spasmus hemifacialis = Hemispasmus faciei



- mostly: compression in border of CNS and PNS – contact of sheath of oligodendrocytes and Schwann cells = „Obersteiner-Redlich´s zone)
 - mostly loop of a. cerebelli inferior anterior
 - treatment: microvascular decompression

Treatment of n.VII traumatic injury

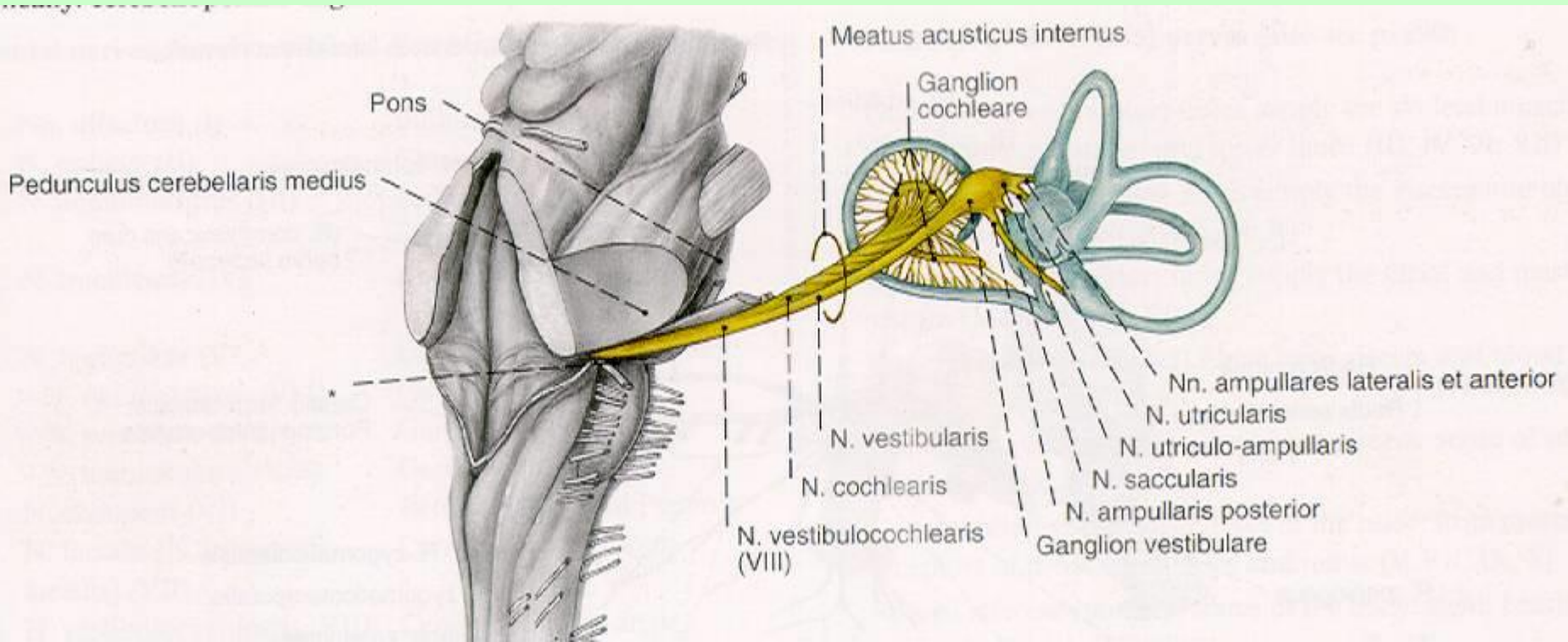
- transplantation
 - n. suralis
- usage of other close nerve
 - n. XII
 - n. auricularis magnus



VIII. - Nervus vestibulocochlearis

obsolete term: n. statoacusticus

- *special sensory – hearing + balance*



VIII. - Nervus vestibulocochlearis

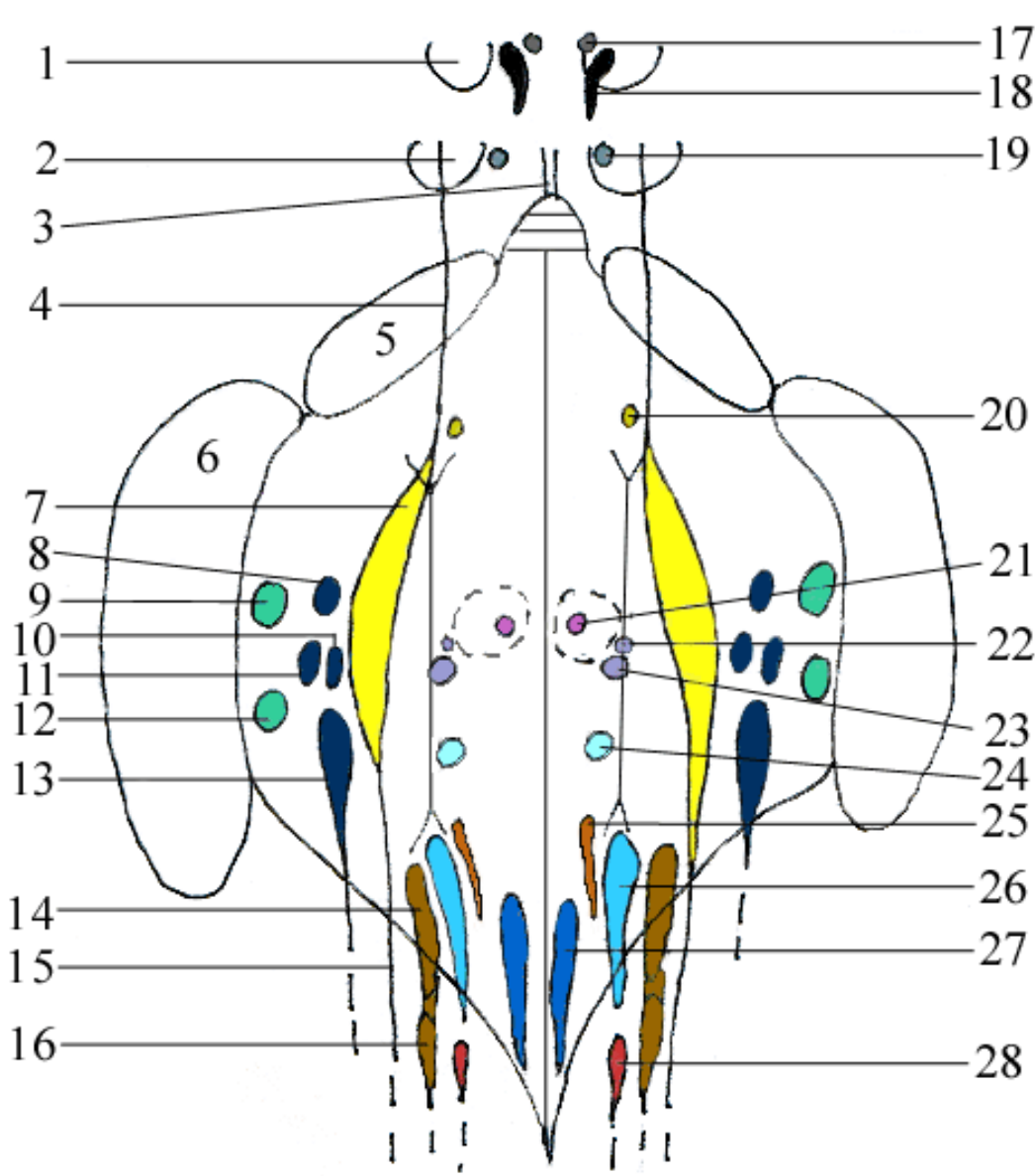
6 nuclei in pons (under recessus lat. fossae rhomboidae)

- 2 cochlear: ncl. cochlearis ant.+post.
- 4 vestibular: ncl. vestibularis sup.+inf.+med.+lat.

course: angulus pontocerebellaris → fossa cranii posterior → porus acusticus internus → meatus a.i. → fundus m.a.i.

- pars vestibularis – ganglion vestibulare *Scarpa* on floor of meatus.a.i. (bipolar neurons)
- pars cochlearis – ganglion cochleare *Corti* inside bony cochlea (spiral shape, bipolar neurons)

FLOOR OF FOURTH VENTRICLE (RHOMBOID FOSSA) WITH SURFACE PROJECTION OF CRANIAL NERVE NUCLEI



- 1 - superior colliculus
- 2 - inferior colliculus
- 3 - frenulum of superior medullary velum
- 4 - mesencephalic tract of n. V.
- 5 - superior cerebellar peduncle
- 6 - middle cerebellar peduncle
- 7 - principal nucleus of n. V.
- 8 - superior vestibular nucleus /Bechtëtrev/
- 9 - posterior cochlear nucleus
- 10 - medial vestibular nucleus /Schwalbe/
- 11 - lateral vestibular nucleus /Deiters/
- 12 - anterior cochlear nucleus
- 13 - inferior vestibular nucleus /Roller/
- 14 + 16 - nuclei tractus solitarii
- 15 - spinal tract of n. V.
- 17 - accessory nucleus of n. III. /Edinger-Wesphal/
- 18 - nucleus of n. III.
- 19 - nucleus of n. IV.
- 20 - motor nucleus of n. V.
- 21 - nucleus of n. VI.
- 22 - superior salivatory nucleus
- 23 - nucleus of n. VII.
- 24 - superior salivatory nucleus
- 25 - posterior nucleus of n. X.
- 26 - nucleus ambiguus
- 27 - nucleus of n. XII.
- 28 - nucleus of n. XI.

(= part of nucleus ambiguus and retroambiguus)

Auris interna = Inner ear

Labyrinthus membranaceus = Membranous l.

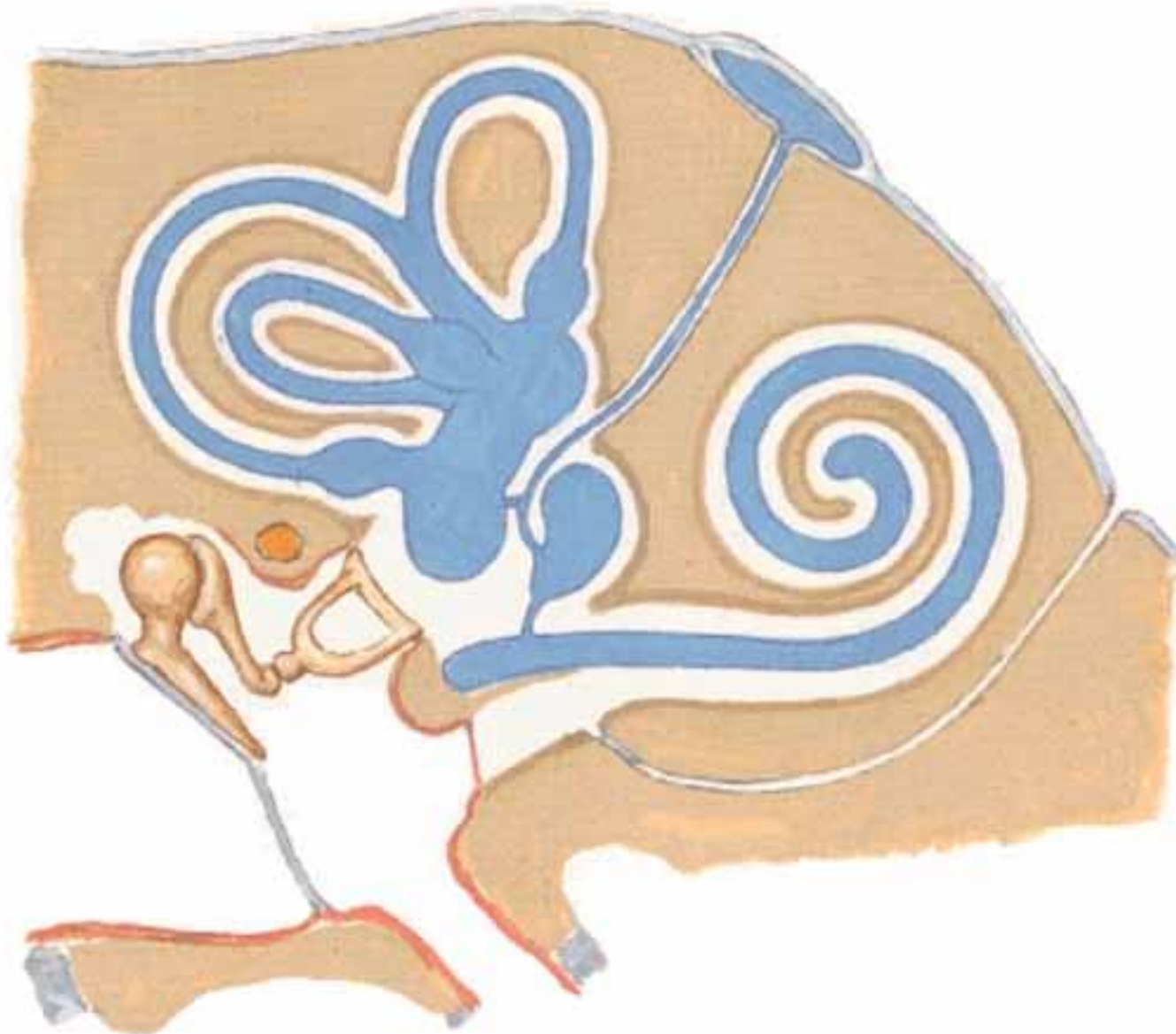
- Utriculus – *horizontal movements*
- Sacculus – *vertical movements*
- Ductus semicircularis anterior, lateralis, posterior (ampulla + crura) – *angle acceleration and deceleration*
- Cochlea – *hearing*

sensory organs:

- macula utriculi / sacculi
- crista ampullaris
- organum spirale *Corti*

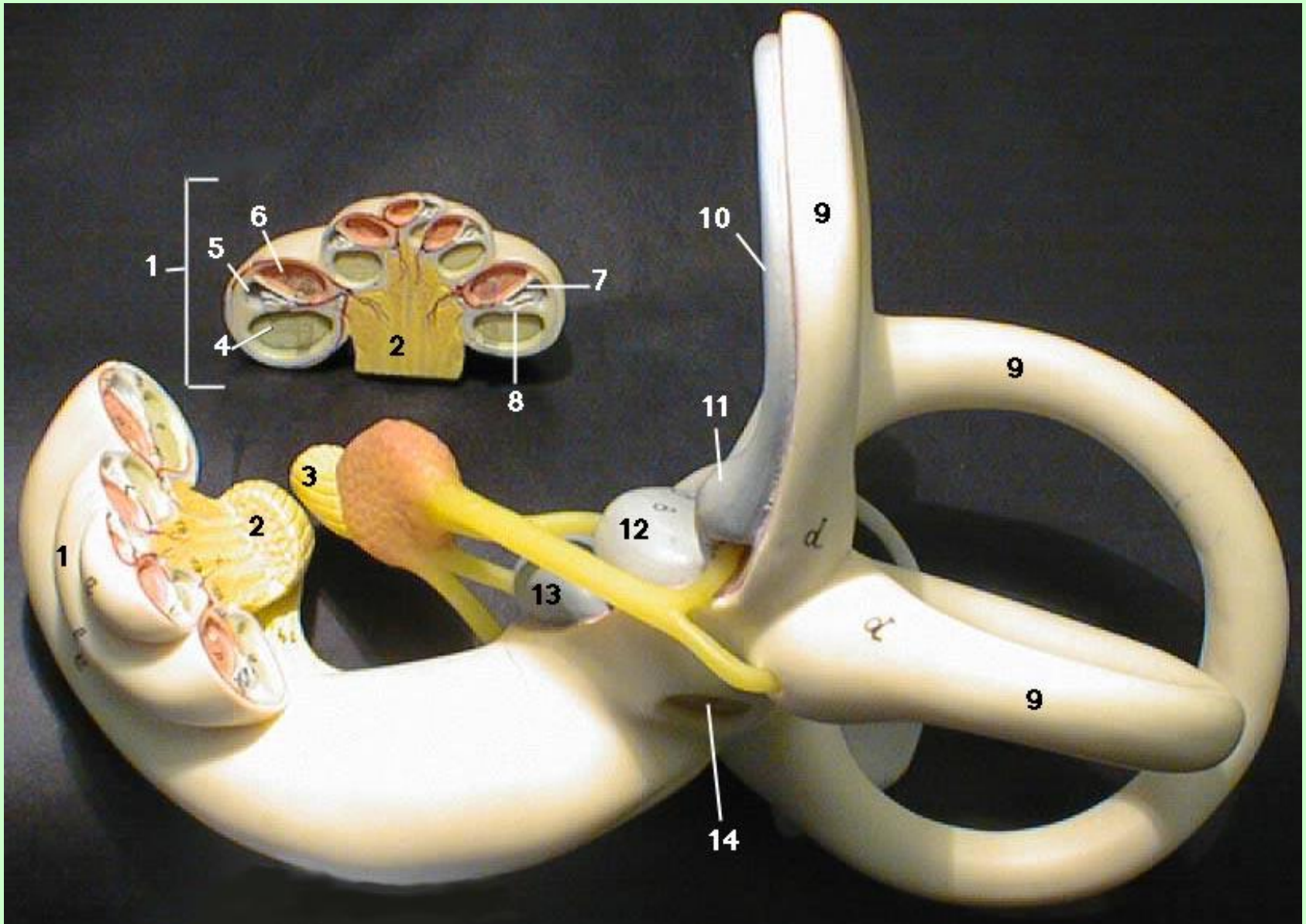
Auris interna = Inner ear

Labyrinthus membranaceus = Membranous l.

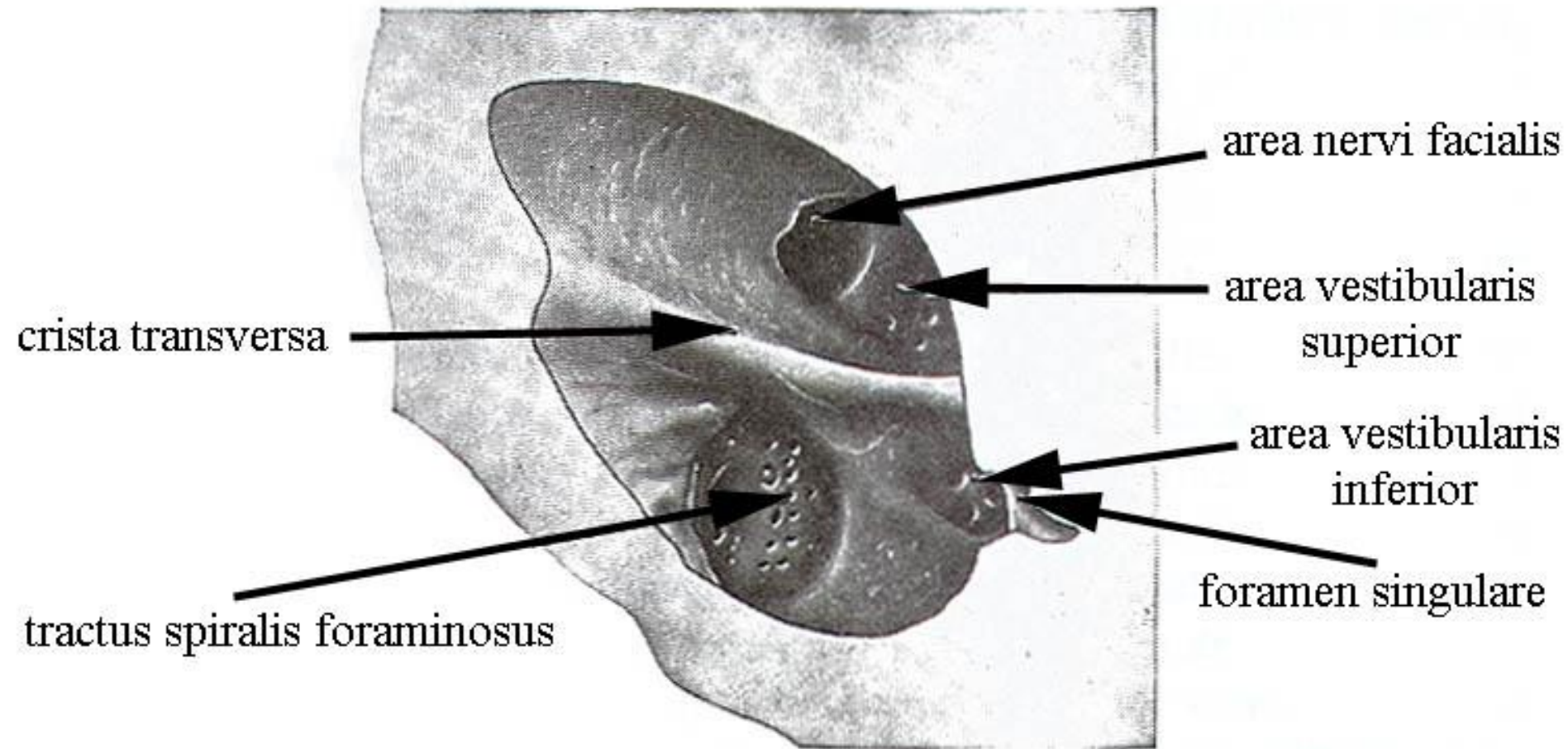


Auris interna = Inner ear

Labyrinthus membranaceus = Membranous l.



MEATUS ACUSTICUS INTERNUS (fundus meatus acustici interni)



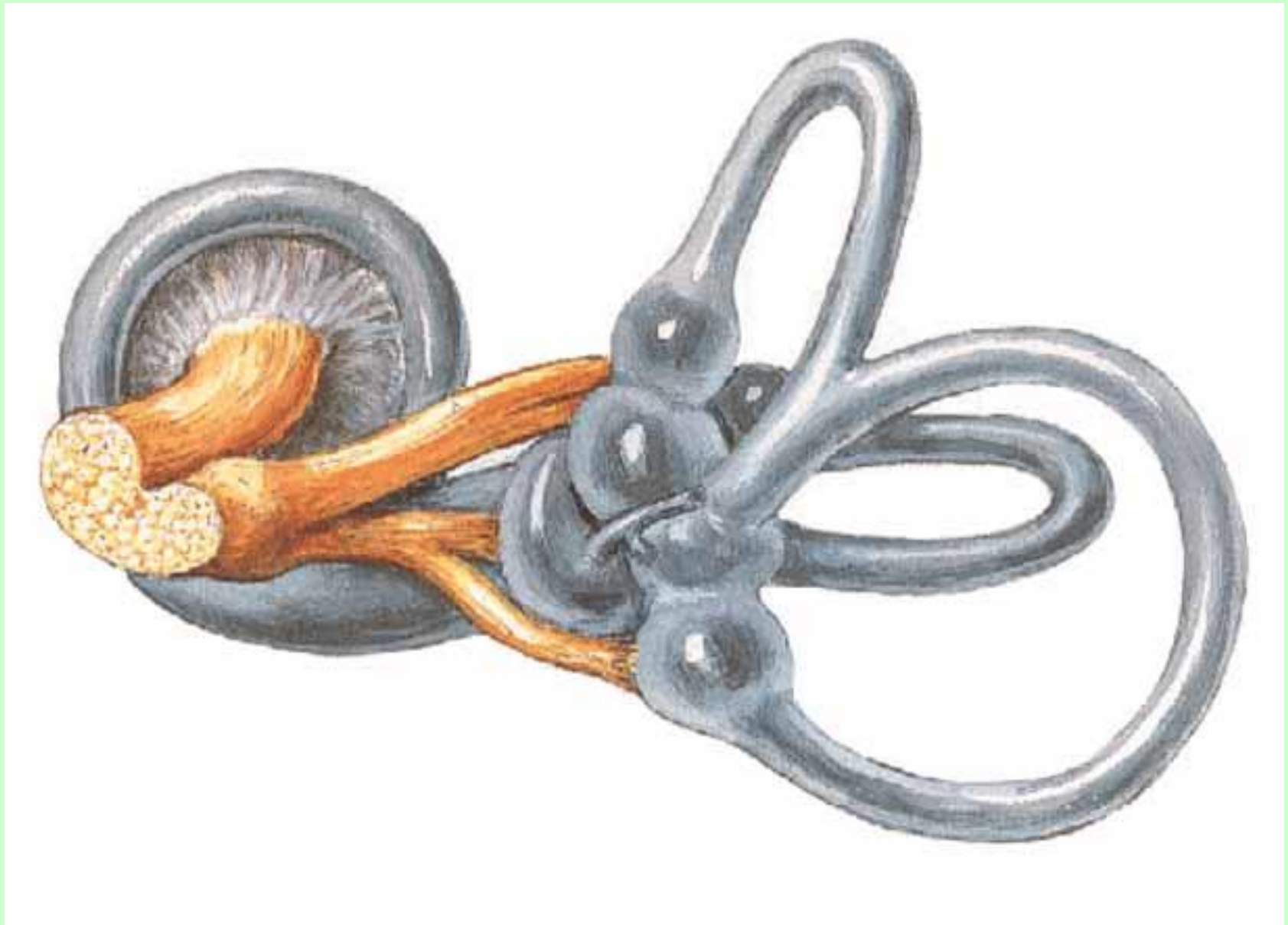VIII. - Nervus vestibulocochlearis

Nervus vestibularis – ggl. vestibulare *Scarpae*
inside meatus a.i.

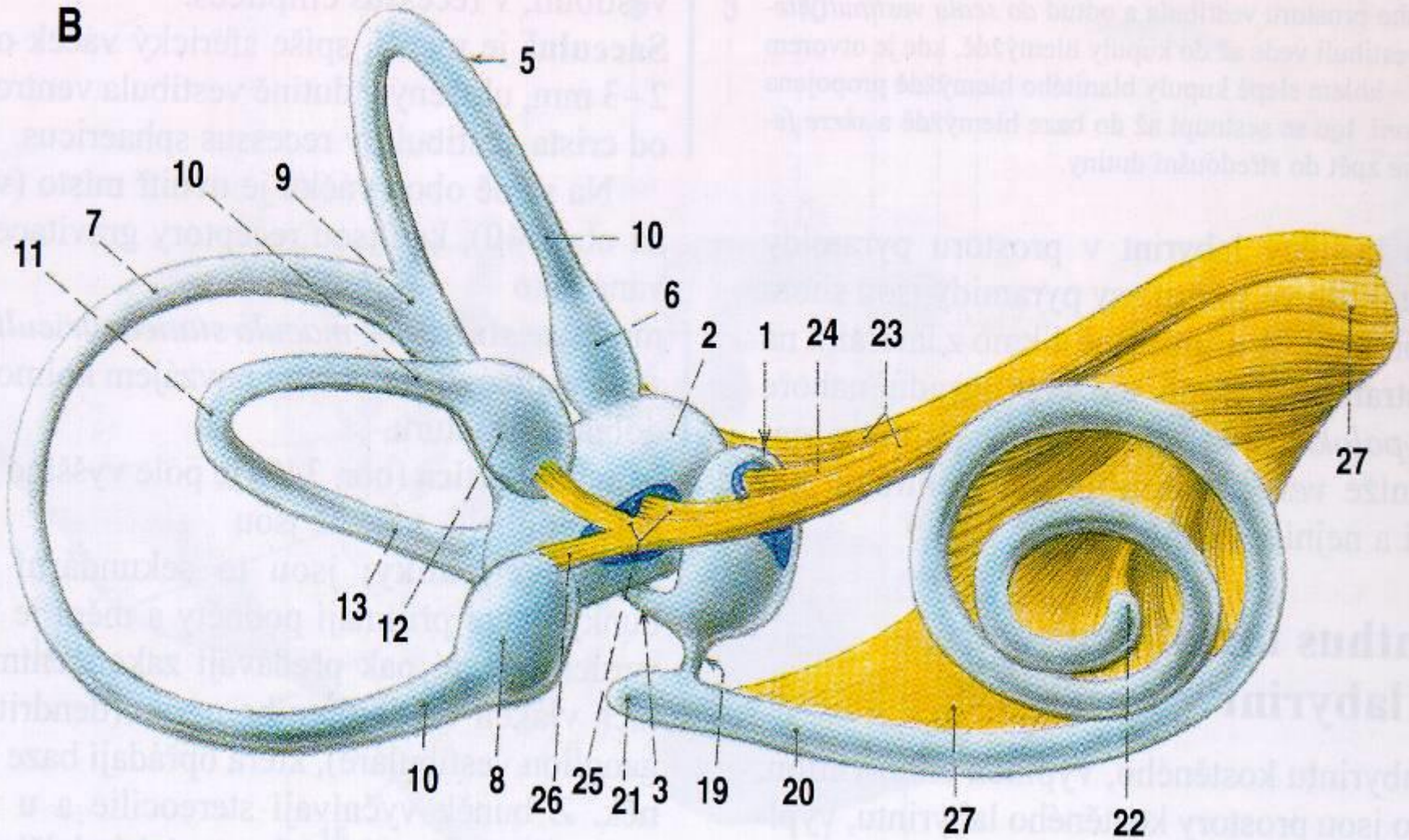
- pars superior – *dorsocranial quadrant*
 - n. utriculoampullaris
- pars inferior
 - n. saccularis – *dorsocaudal quadrant*
 - n. ampullaris posterior – foramen singulare

Nervus cochlearis – *ventrocaudal quadrant* –
ggl. cochleare *Corti inside bony cochlea*

VIII. - Nervus vestibulocochlearis

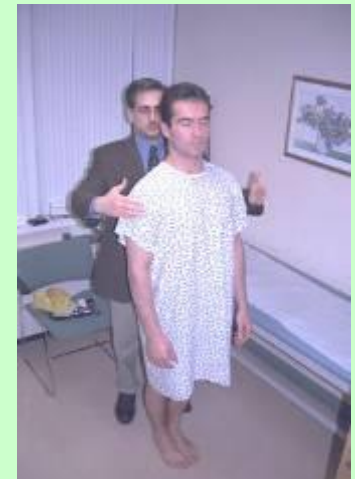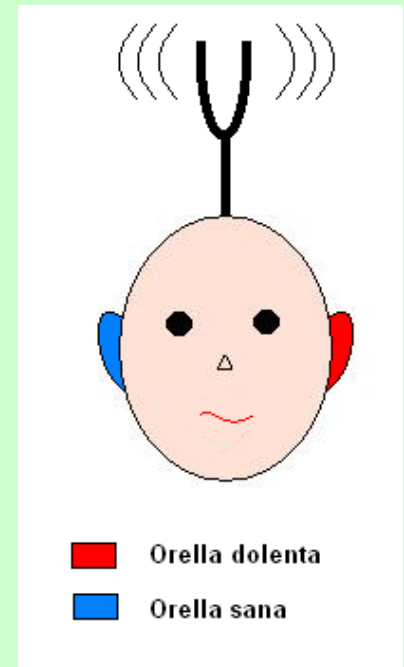


VIII. - Nervus vestibulocochlearis



VIII. - Nervus vestibulocochlearis examination

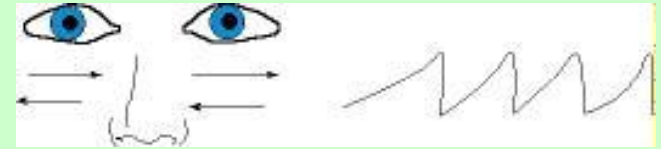
- tuning-fork examination (Rinné, Weber, Schwabach)
- examination of nystagmus (9 direction after Hering)
- Romberg – stand with closed eyes
- Hautant – sit, stretch arms forwards and close eyes
- Unterberger – close eyes and march on site for 30 s



VIII. - Nervus vestibulocochlearis

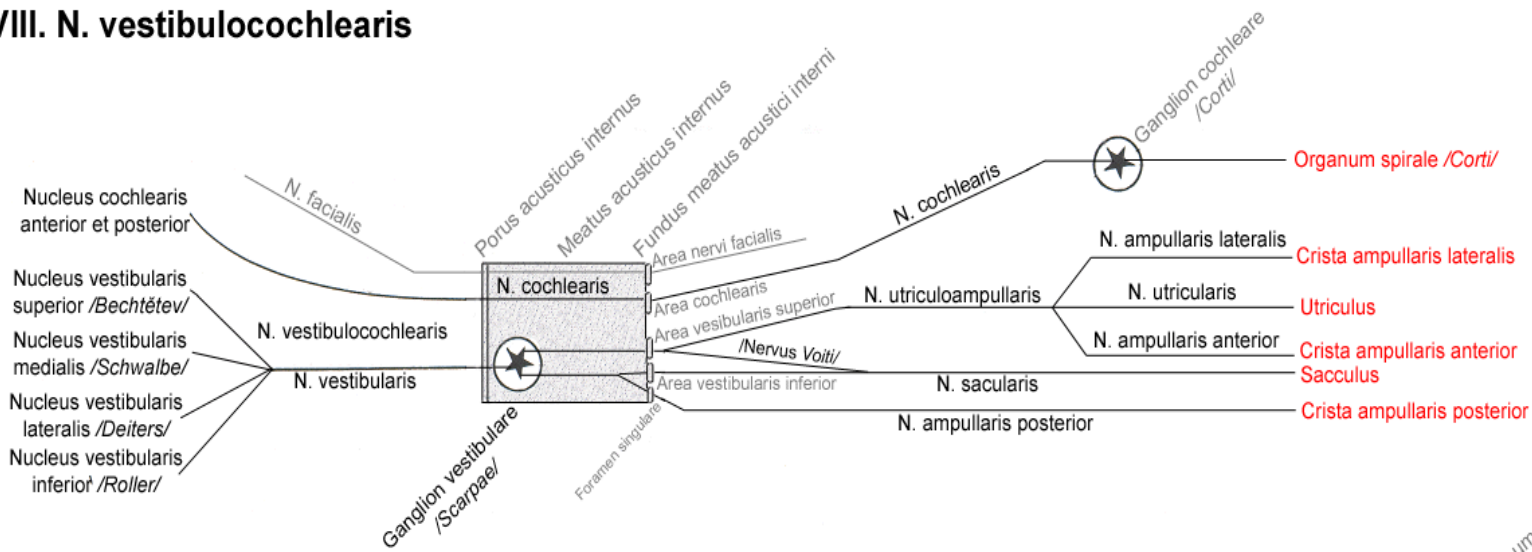
irritation / palsy

- affection of hearing (= hypacusis → anacusis)
 - deafness (= surditas)

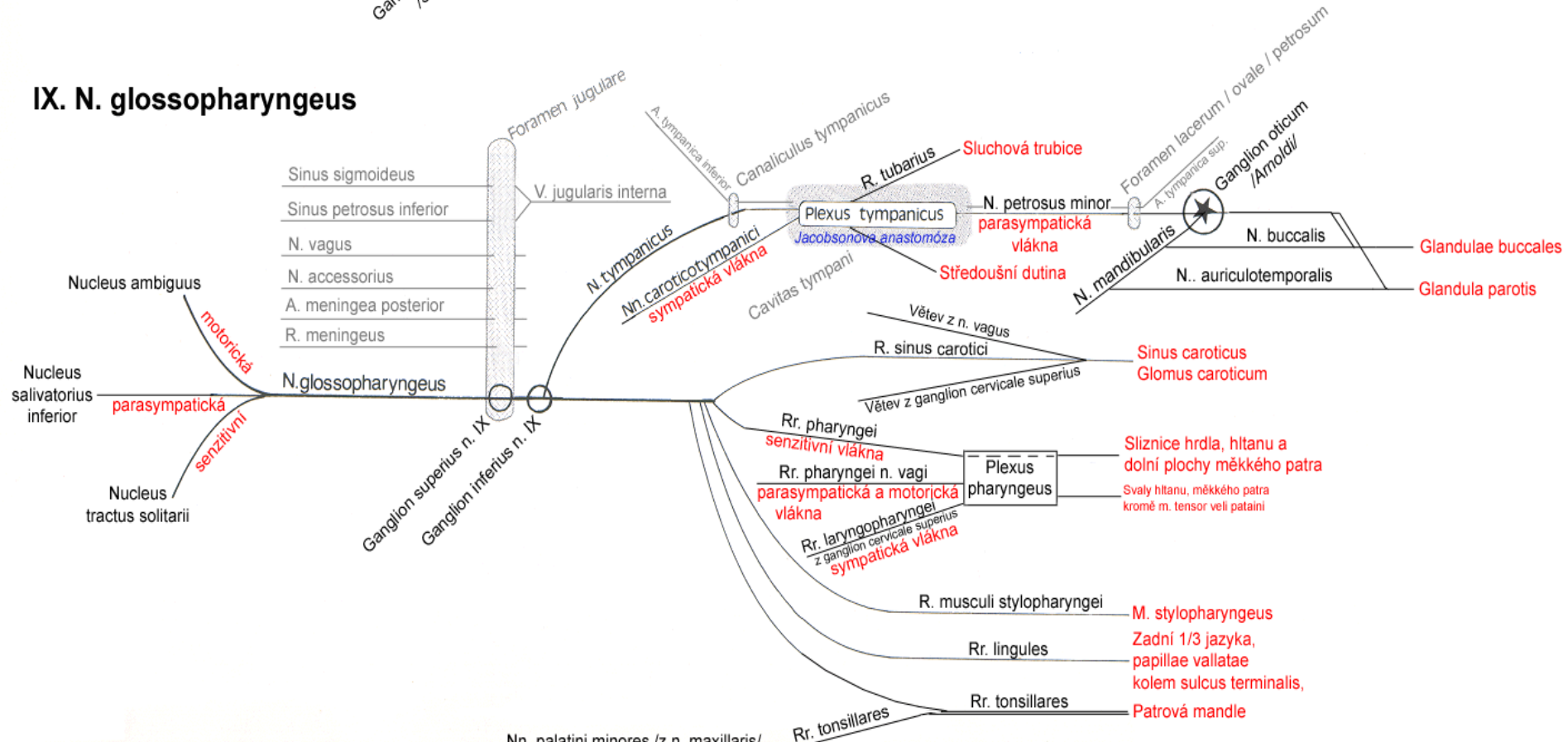


- tinnitus – humming, screeching, ringing...
- dizziness (= vertigo)
- involuntary eye movement (= nystagmus)
 - = alternating smooth pursuit in one direction and saccadic movements in the other direction.
 - slow-phase – stronger side suppresses the weaker one
 - fast-phase – compensatory movements back – serve for description of nystagmus
- disorders of stand and gait (= ataxia)

VIII. N. vestibulocochlearis

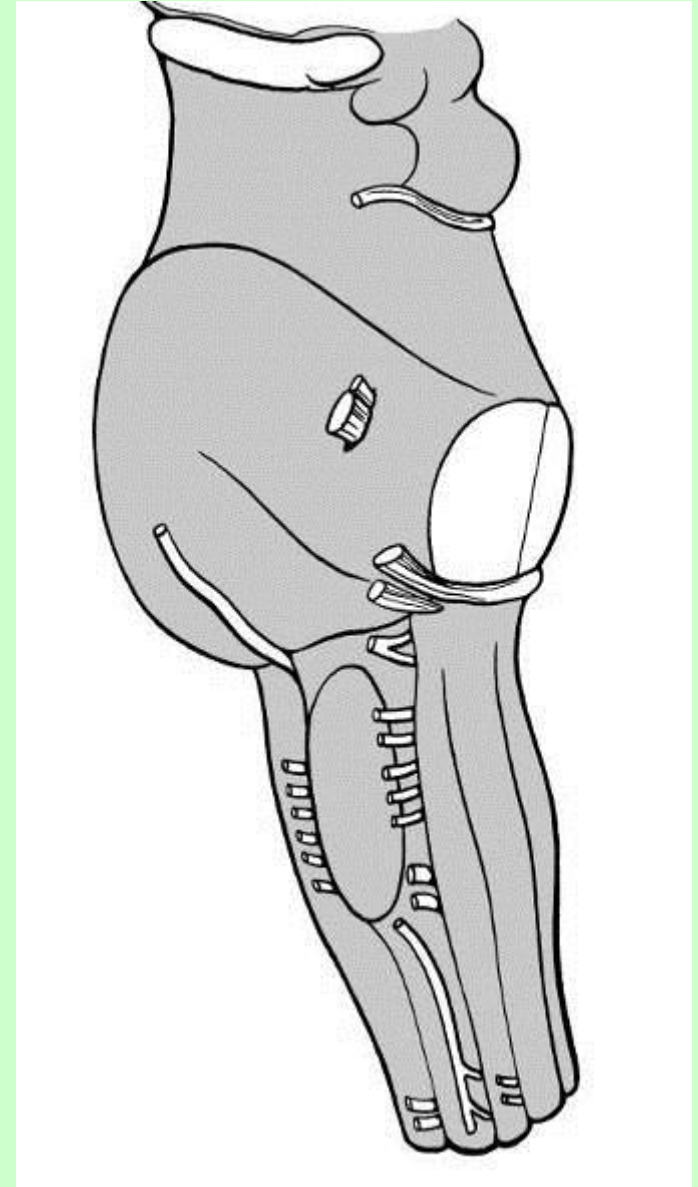


IX. N. glossopharyngeus



Lateral mixed system

- **n.IX + n.X + n.XI**
- roots emerge dorsally to olive from medulla oblongata (= *sulcus retroolivaris*)
- common nuclei
- transmit all types of modalities except sympathetic fibres
- leave skull via foramen jugulare

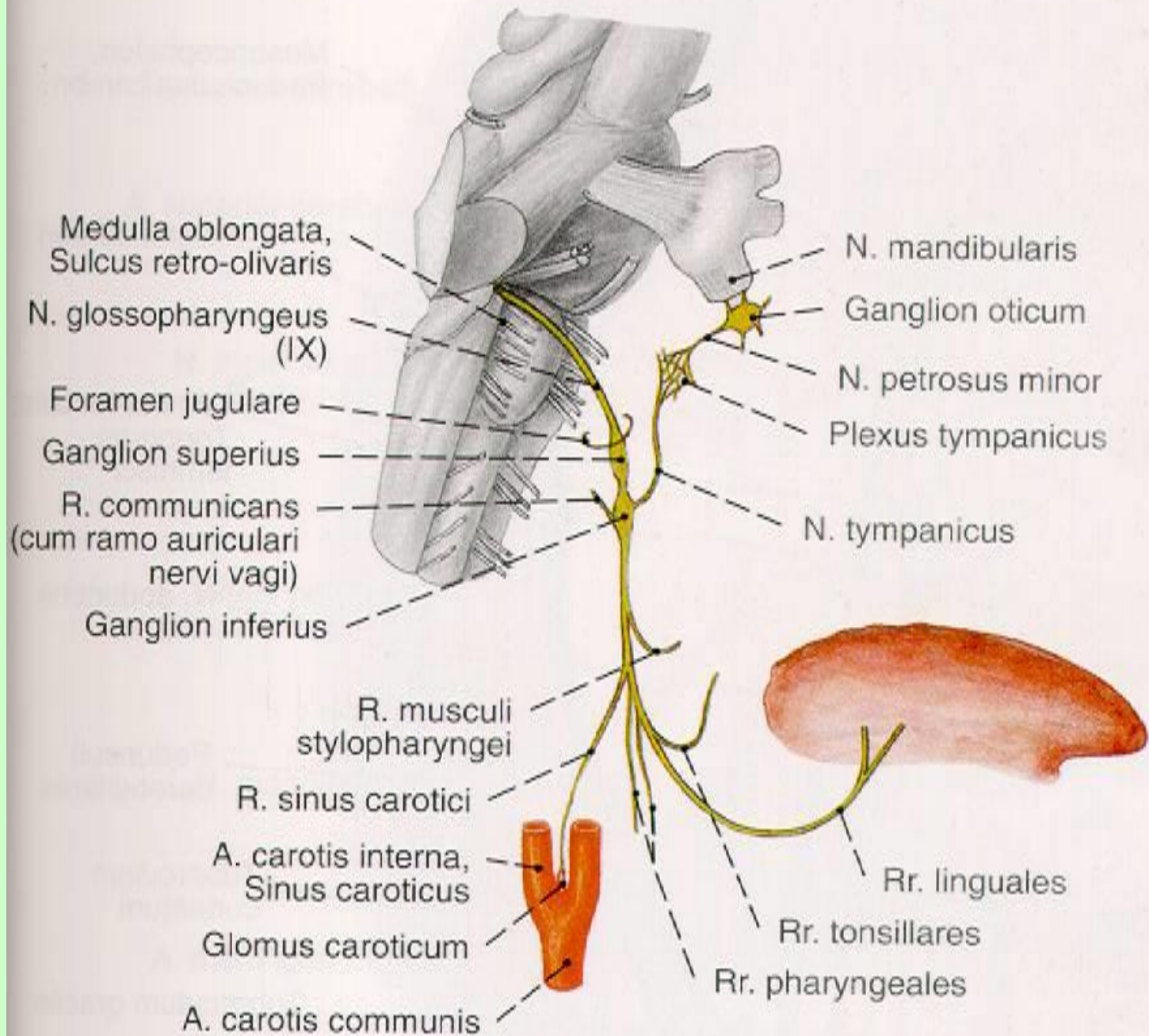


Lateral mixed system

- **Ncl. ambiguus**
 - *somatomotor nucleus*
 - muscles of soft palate, pharynx, larynx, upper oesophagus
- **Ncl. salivatorius inf. (n.IX)**
 - *visceromotor nucleus – parasympathetic*
 - parotid and buccal glands (synapsed in ggl. oticum)
- **Ncl. posterior n. X**
 - *visceromotor nucleus – parasympathetic*
 - glands and smooth muscles of pharynx, lower respiratory tract, foregut and midgut, heart, thymus
- **Ncll. tractus solitarius**
 - its rostral part is called **ncl. gustatorius (n. VII)**
 - *viscerosensory nucleus*
 - taste
 - information from lower respiratory tract, foregut and midgut, spleen, kidneys, suprarenal glands, testes/ovaries, uterine tubes; thymus, heart baroreceptor and chemoreceptors
- **Ncl.spinalis n.V**
 - *somatosensory nucleus*
 - touch from external acoustic meatus, meninges and pharynx

n. IX

- SM
- VM
- SS
- taste
- VS

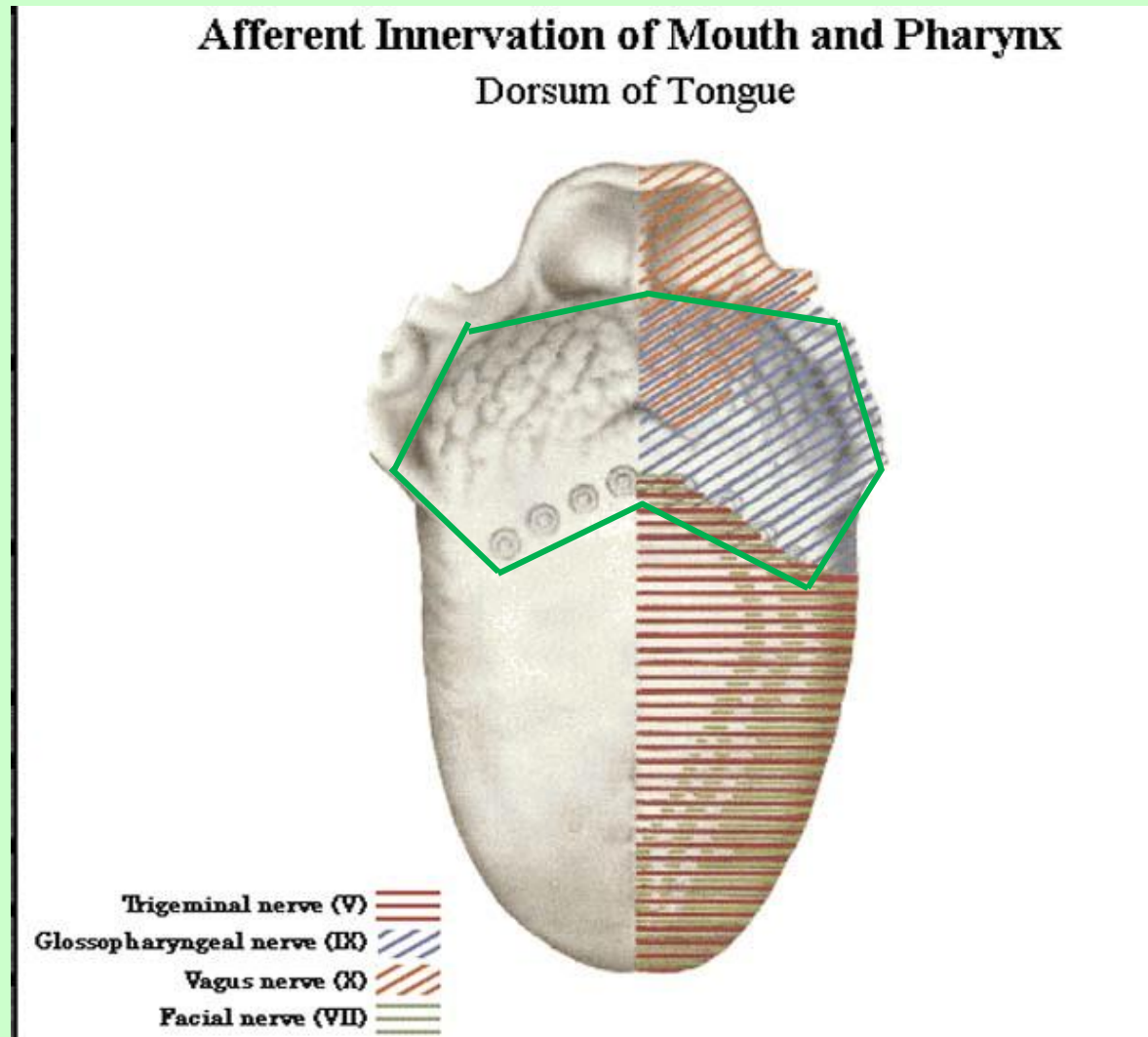


IX. - N. glossopharyngeus

- SM: m. stylopharyngeus – *3rd arch*
- SS-VS: upper half of pharynx, root of tongue, tympanic cavity, ½ tonsilla palatina, sinus caroticus (Hering's nerve)
- ggl. superius n.IX + inferius n.IX.
- VM: gl. parotidea + gll. buccales
- taste: posterior third of tongue = root of tongue
- Jacobson's anastomosis: n.IX → n. tympanicus → plexus tympanicus → n. petrosus minor → gll. oticum (→ *gl. parotidea + gll. buccales*)

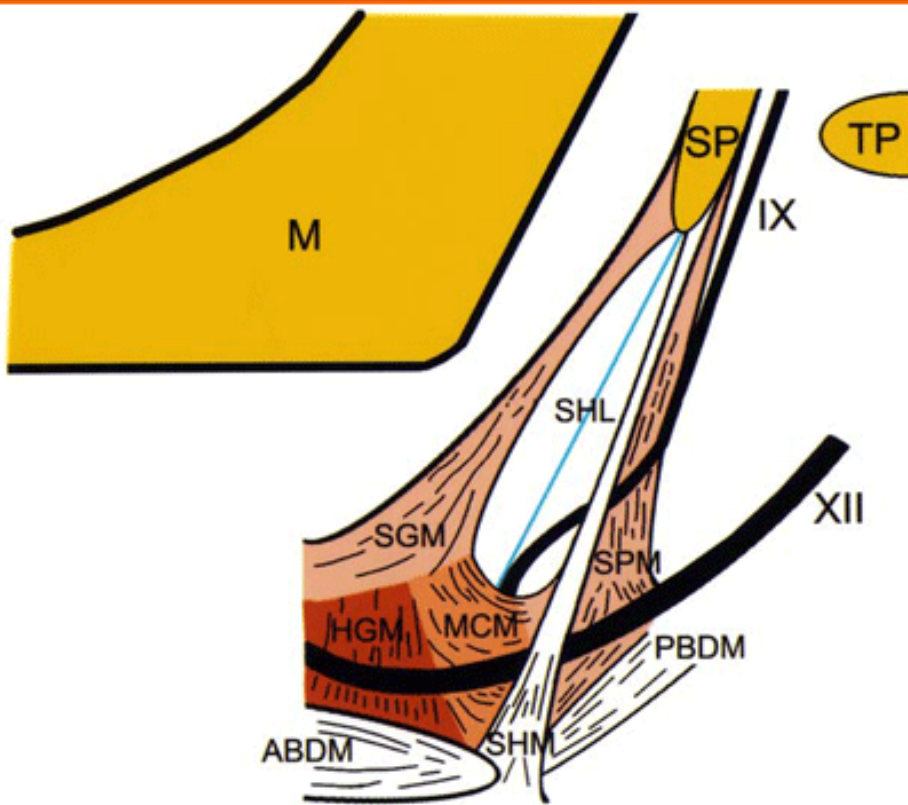
Innervation of tongue

somatosensory + sensory (taste)

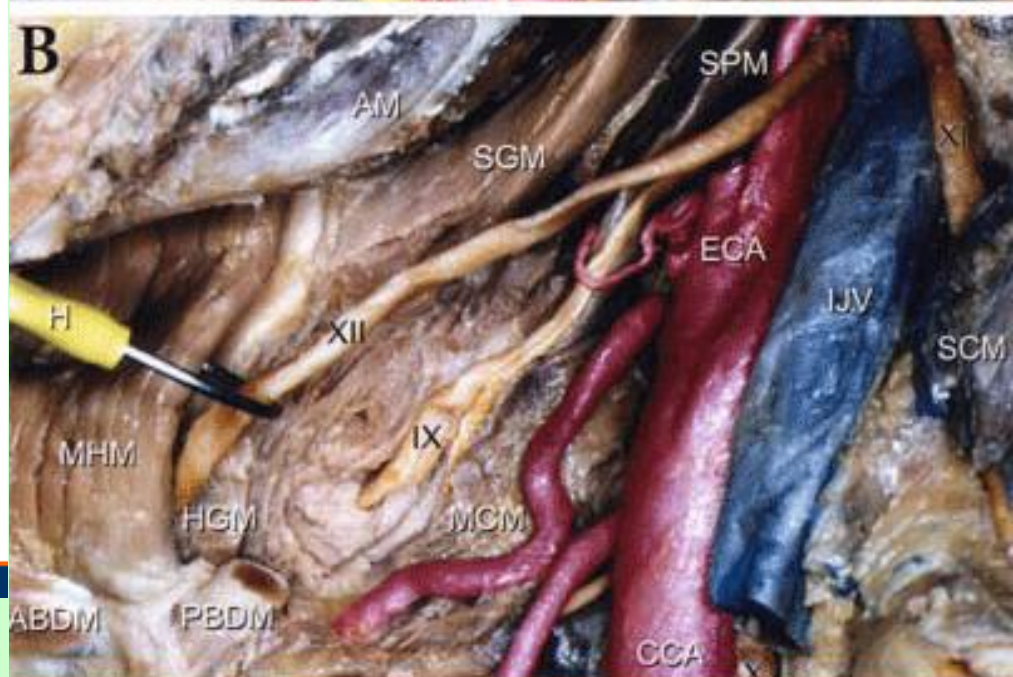
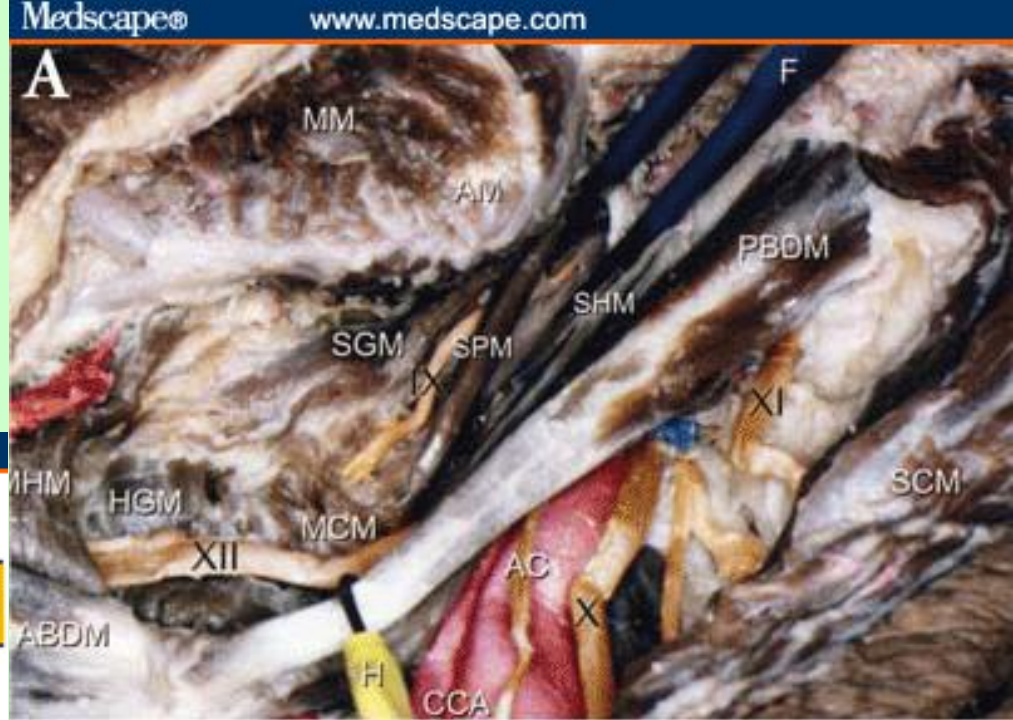


n. IX

Medscape® www.medscape.com



Source: Neurosurg Focus © 2004 American Association of Neurological Surgeons



Source: Neurosurg Focus © 2004 American Association of Neurological Surgeons

IX. - N. glossopharyngeus

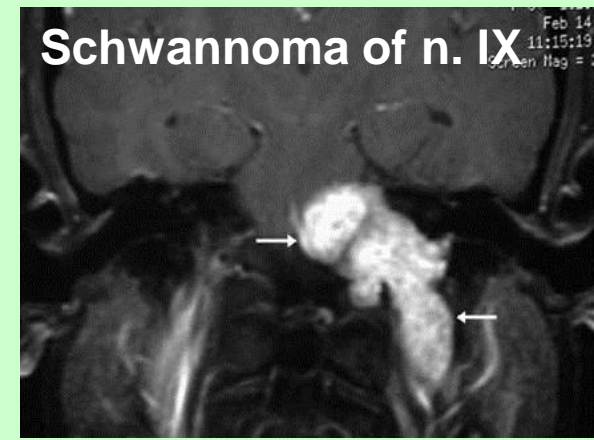
Palsy

unilateral

- affected swallowing (= mild dysphagia)
- affected vomiting (no afferentation of vomiting reflex)
- affected sensory fibres, taste and glands – *weak symptom*

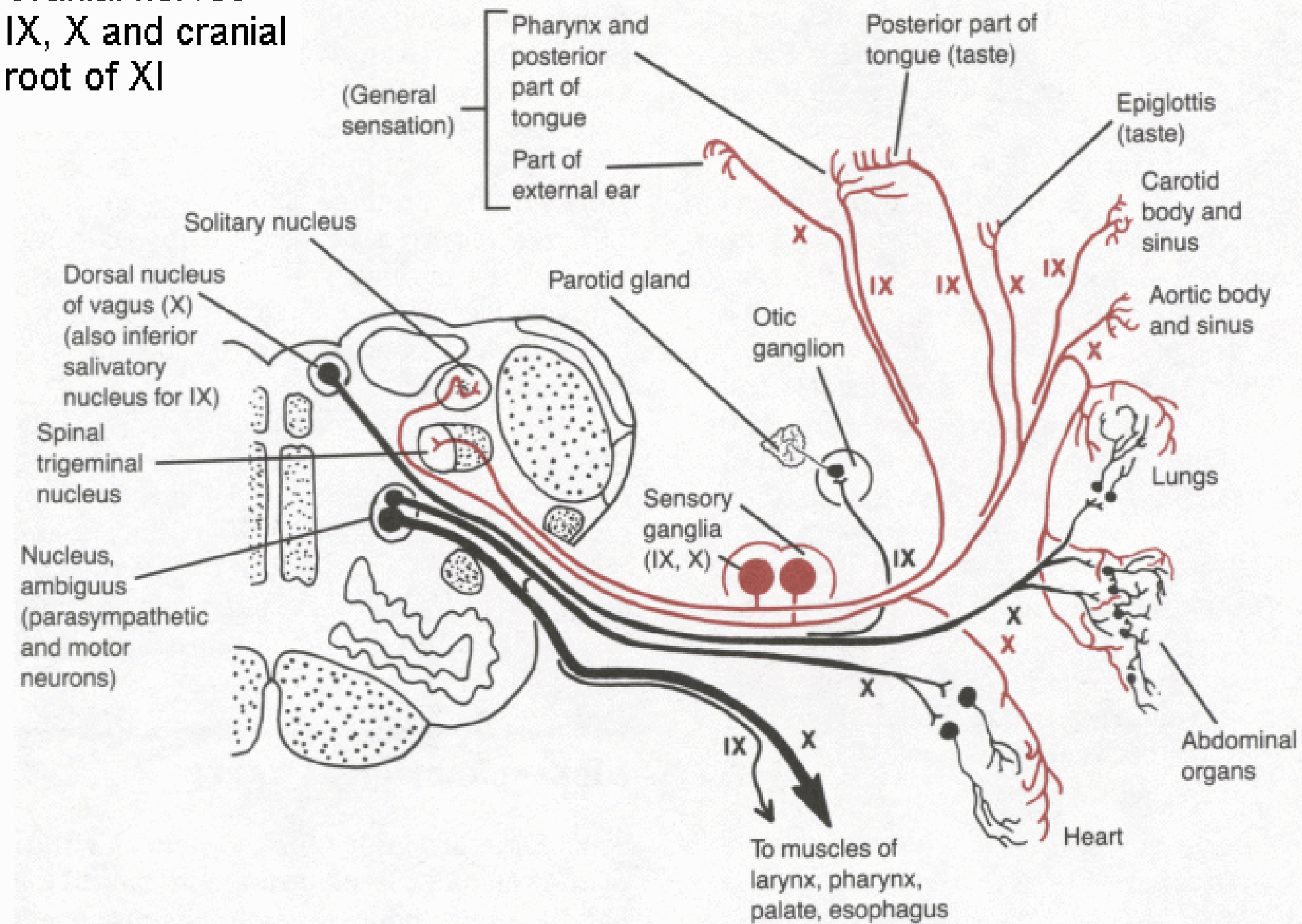
Neuralgia glossopharyngea

*irritation pain in area innervated
by sensory fibres
(ear, palatine tonsil)*



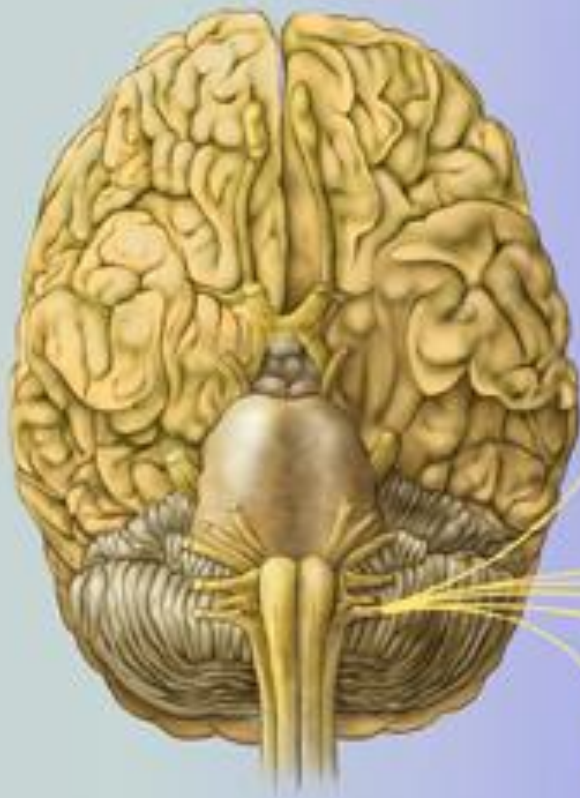Cranial nerves IX, X and cranial root of XI

IX, X and cranial root of XI



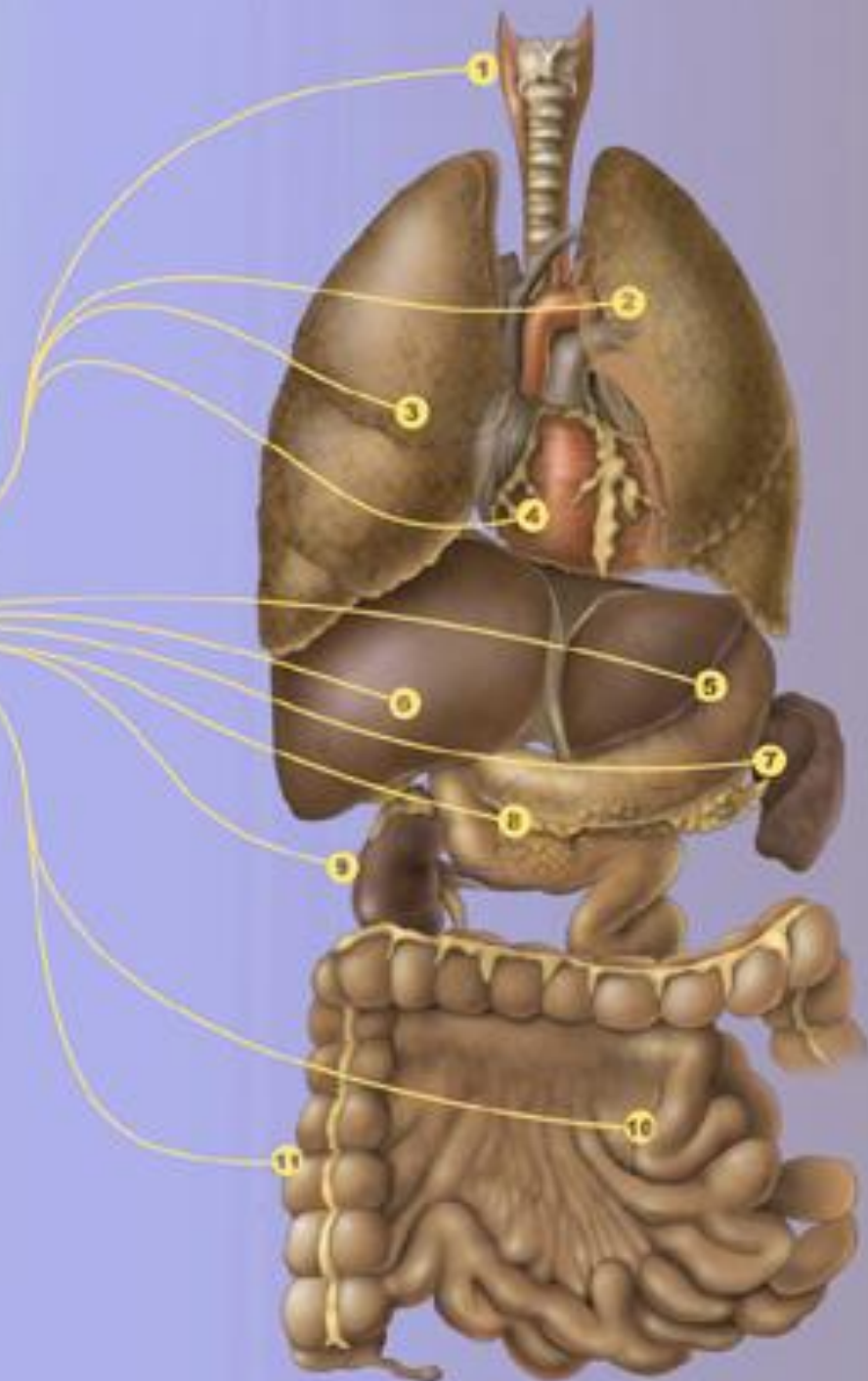
X. - N. vagus

- SM: pharynx (*except m. stylopharyngeus*), soft palate (*except m. tensor veli palatini*), larynx (*4th arch*), upper half of oesophagus
- SS: part of meatus acusticus externus + of meninges, lower $\frac{1}{2}$ of pharynx
- VS: ggl. superius n.X + inferius n.X. (non-painful stimuli)
- mucosa of lower respiratory tract, foregut and midgut + liver, gallbladder, pancreas; spleen, kidneys, suprarenal glands, testis/ovaries, $\frac{1}{2}$ of uterine tube; heart, glomera aortica (baroreceptors), glomus caroticum (chemoreceptor)
- taste: part of root of tongue, epiglottis
- VM: glands and smooth muscles of pharynx, lower respiratory tract, foregut and midgut, heart, thymus



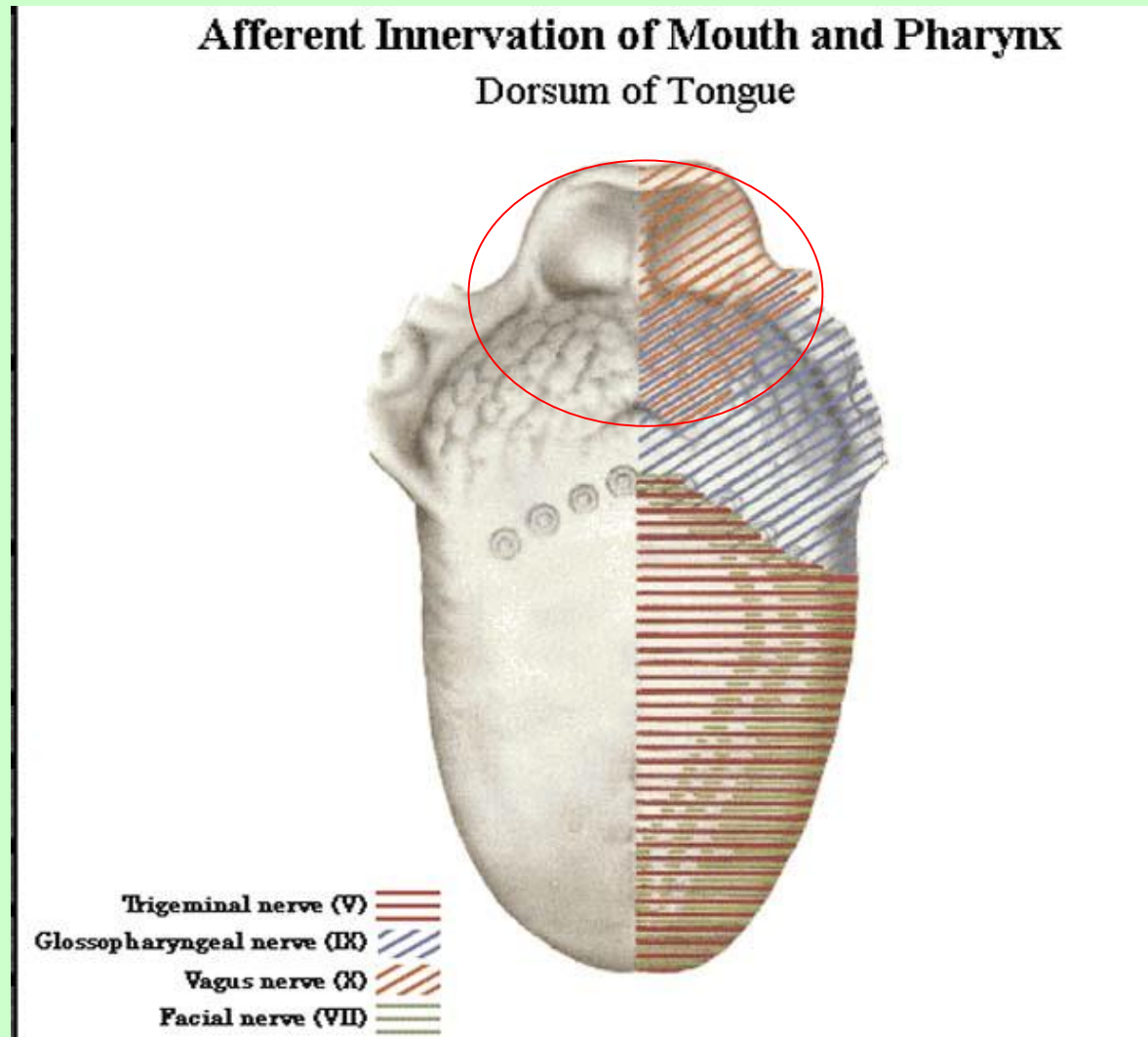
Vagus Nerve Innervation

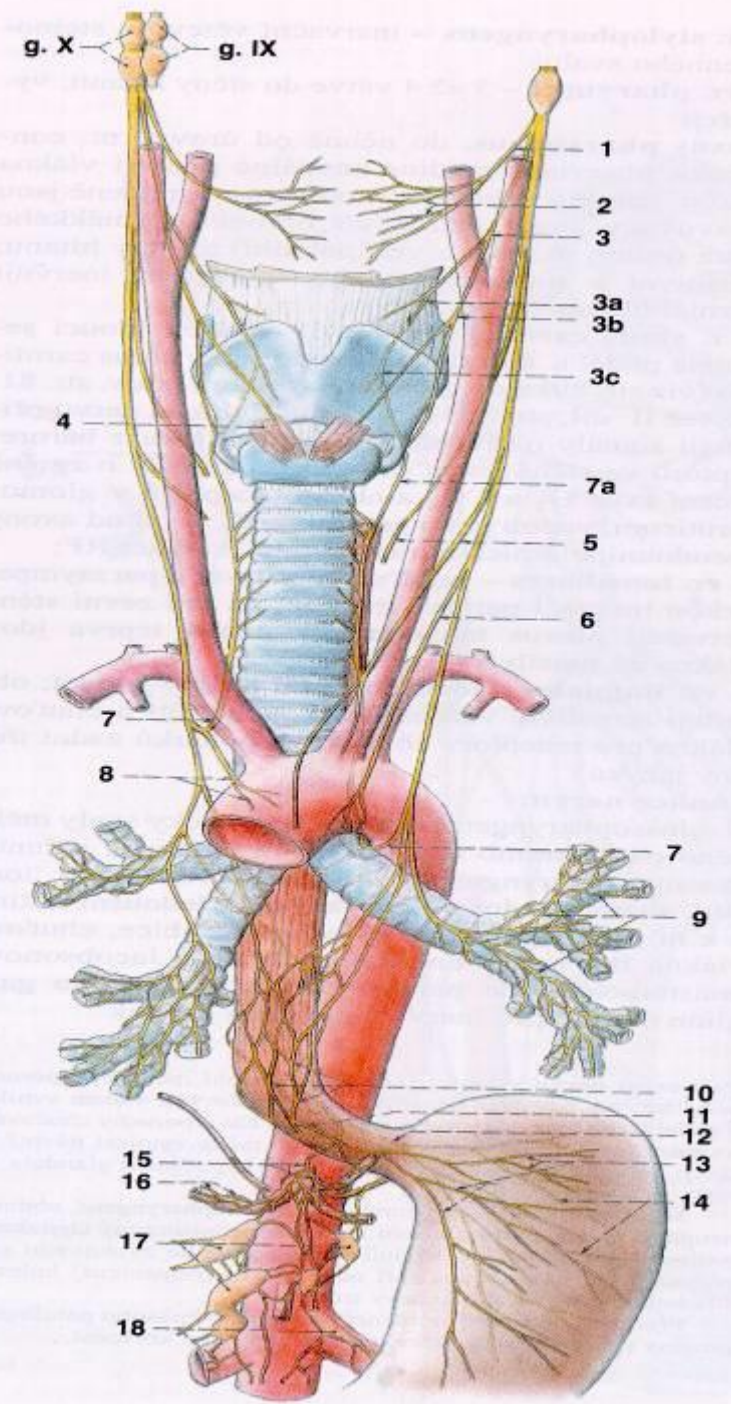
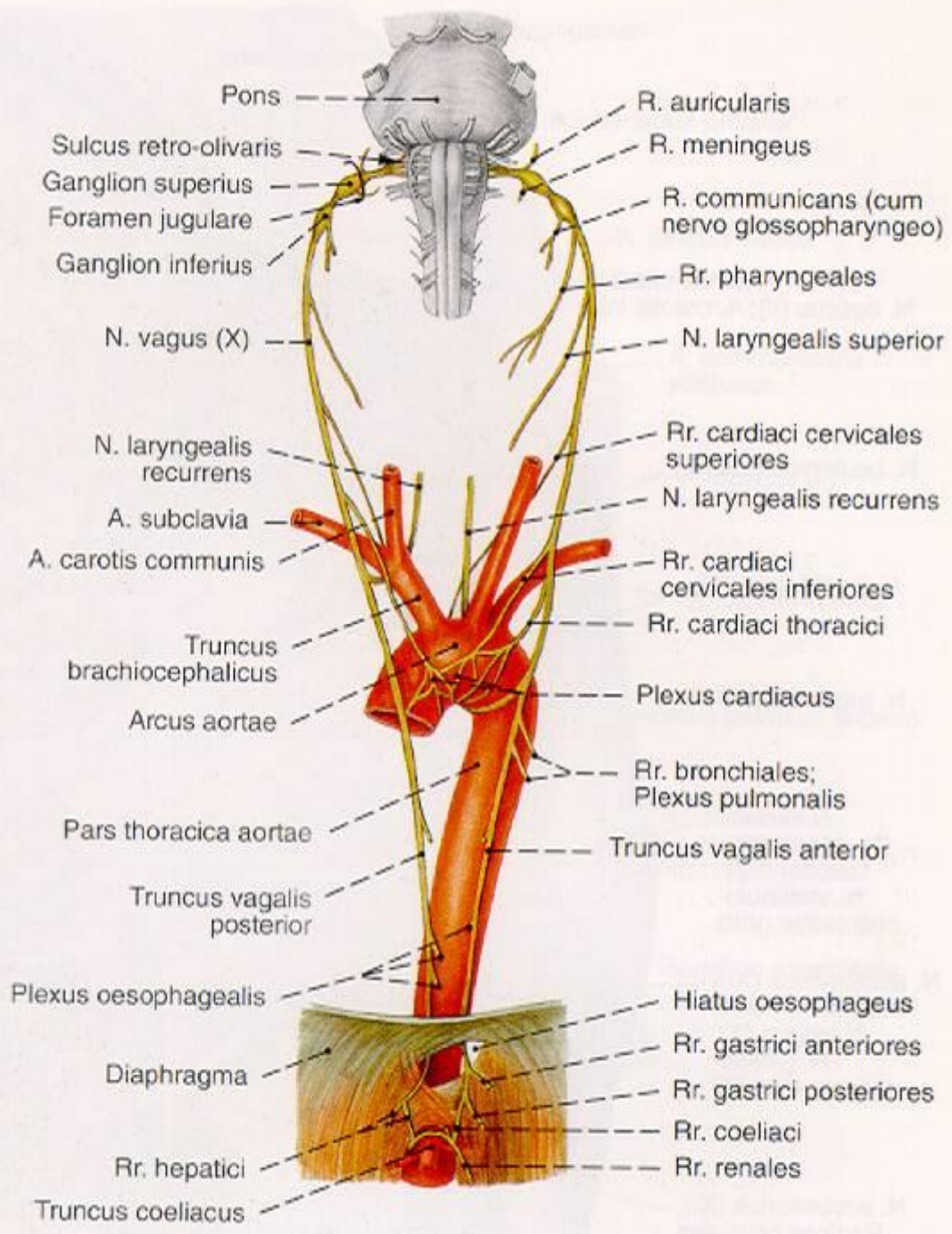
1. Pharynx
2. Left Lung
3. Right Lung
4. Heart
5. Stomach
6. Liver
7. Spleen
8. Pancreas
9. Right Kidney
10. Small Intestine
11. Large Intestine



Innervation of tongue

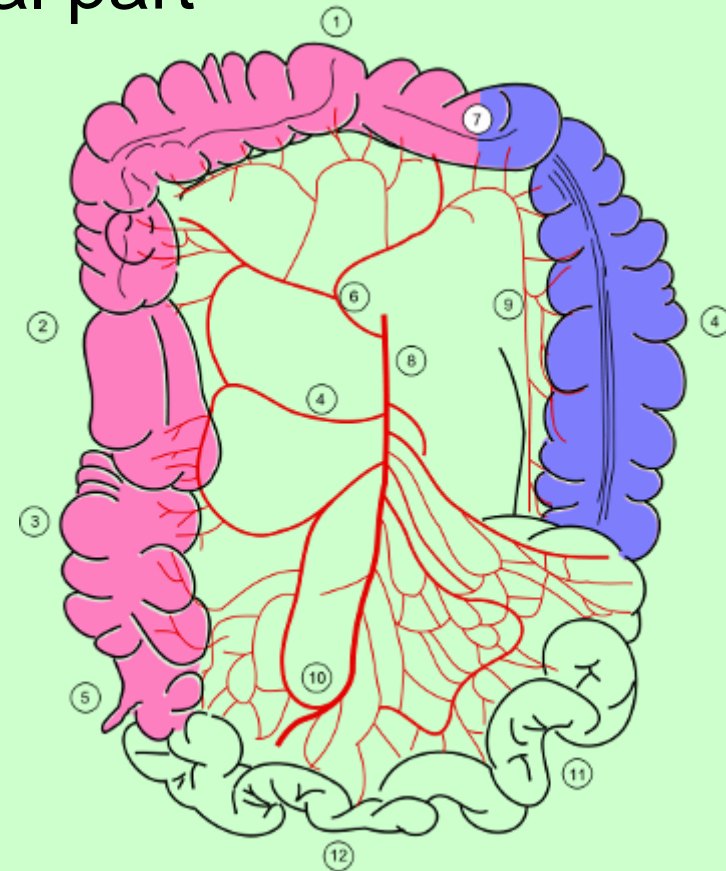
somatosensory x sensory (taste)



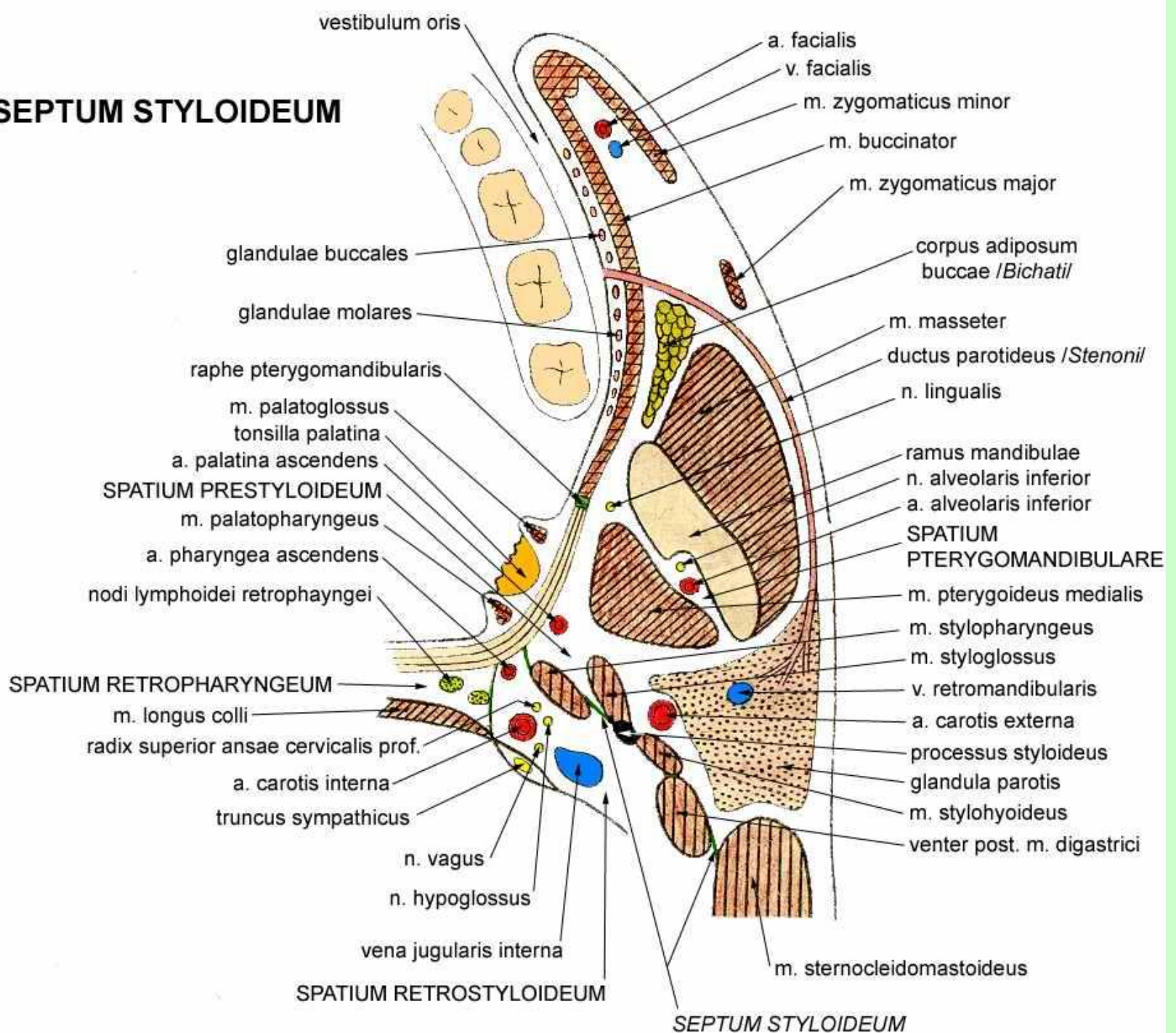


X. - N. vagus - course

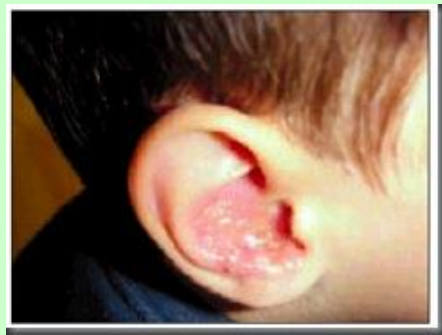- fossa cranii posterior
- foramen jugulare – ventromedial part
- spatium retrostylodeium
- spatium parapharyngeum
- apertura thoracis superior
- mediastinum superius
 - plexus oesophageus → truncus vagalis ant.+post.
- mediastinum inferius posterius
- hiatus oesophageus
- Cannon-Böhm's point



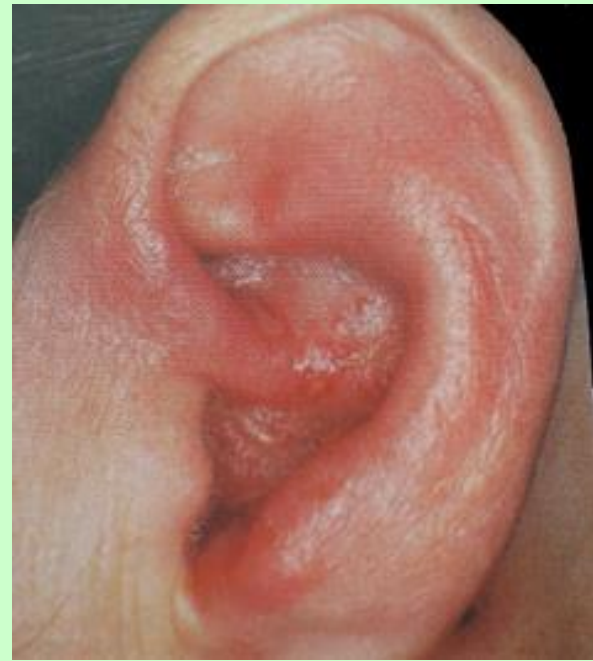SEPTUM STYLOIDEUM



X. - N. vagus - braches



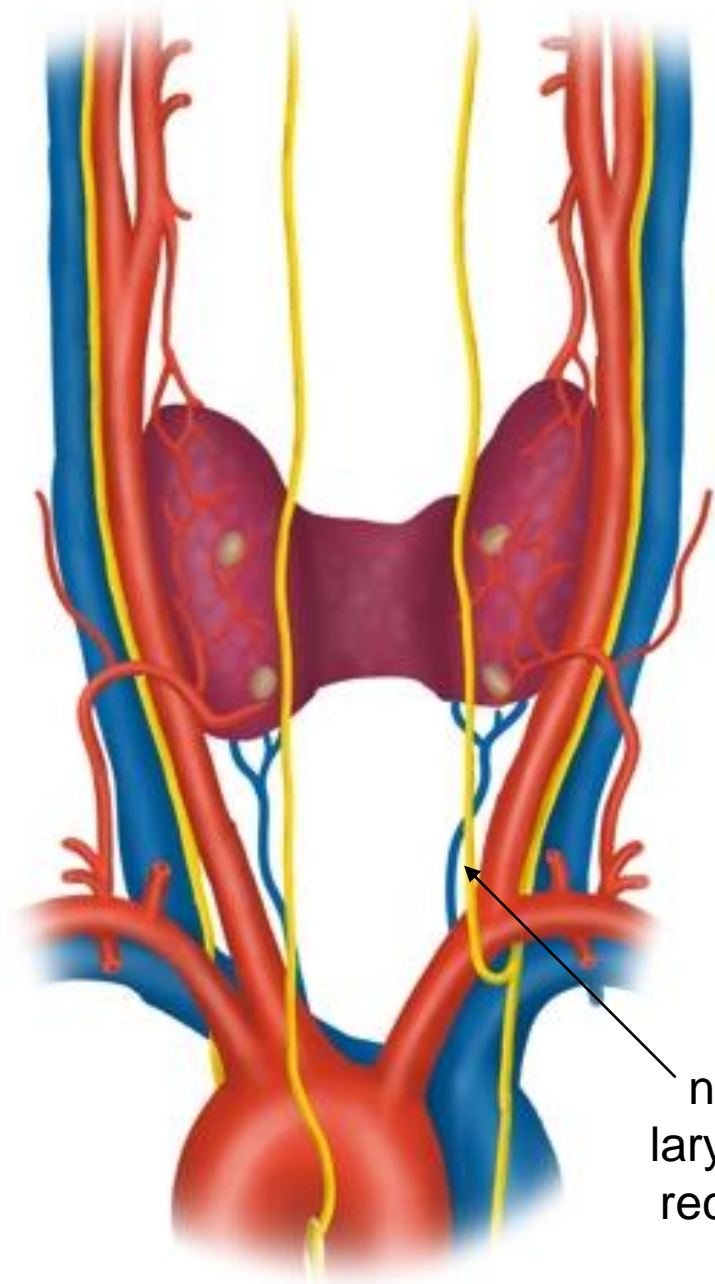
- r. meningeus
- r. auricularis (Arnold's; Alderman's nerve) – *Ramsay-Hunt's zone*



„ALDERMAN (honorary member of the municipal council of the British administrative system) in the times of the Anglo-Saxon empire was habitually eating and then putting some cold water in the ear to stimulate this nerve to initiate vomiting. In this way he could empty his stomach quickly and restart eating“.

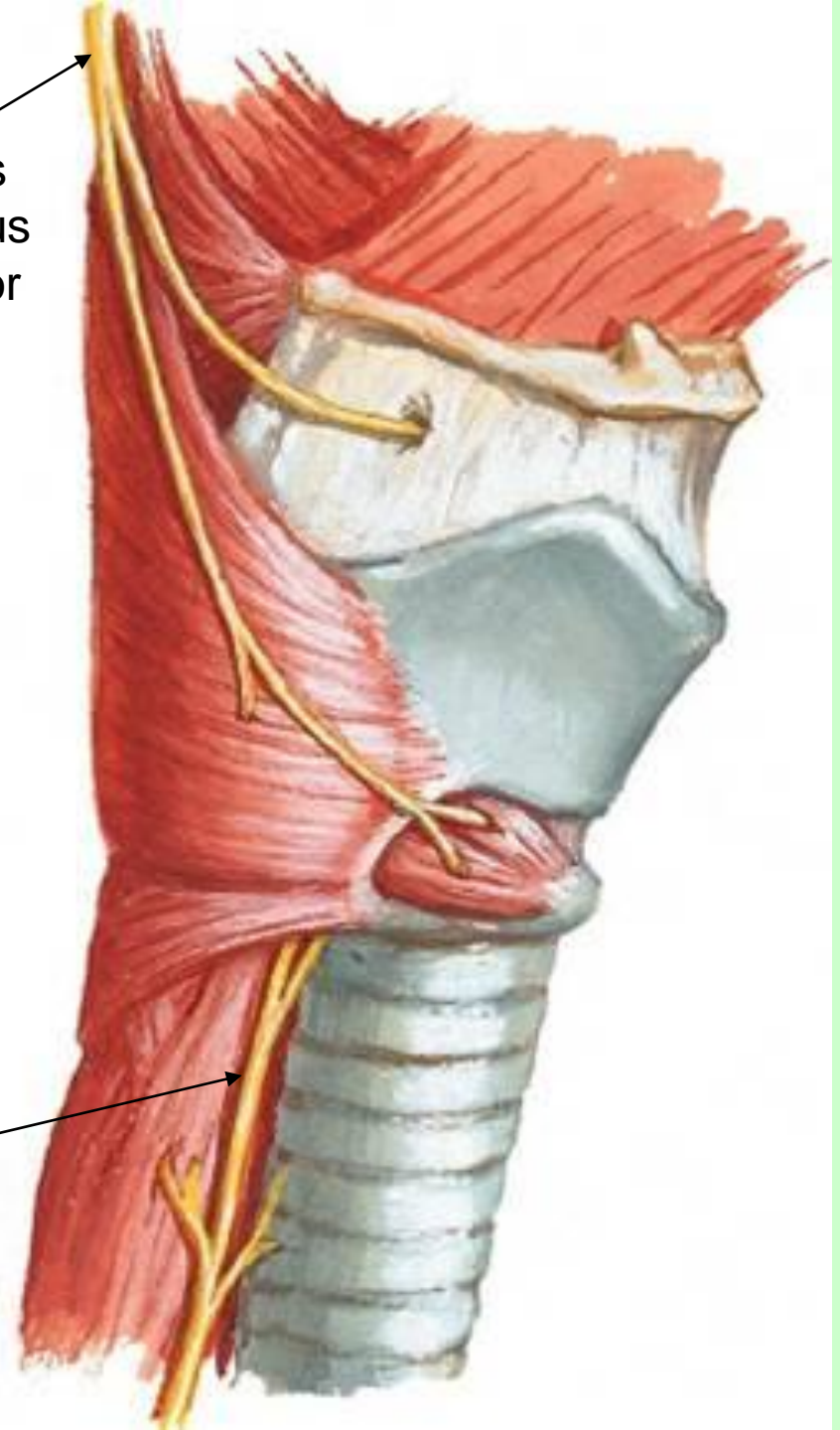
X. - N. vagus - branches

- **rr. pharyngei** – mucosa, glands, muscles
- **n. laryngeus superior** – mucosa, glands, muscles
- **n. laryngeus recurrens** – *idem*
 - right is shorter and passes under a. subclavia dextra
 - left is longer and passes under arcus aortae
- **rr. cardiaci** cervicales sup.+inf., thoracici
- **rr. bronchiales**
- **rr. coeliaci, hepatici, renales, gastrici ant.+post.**

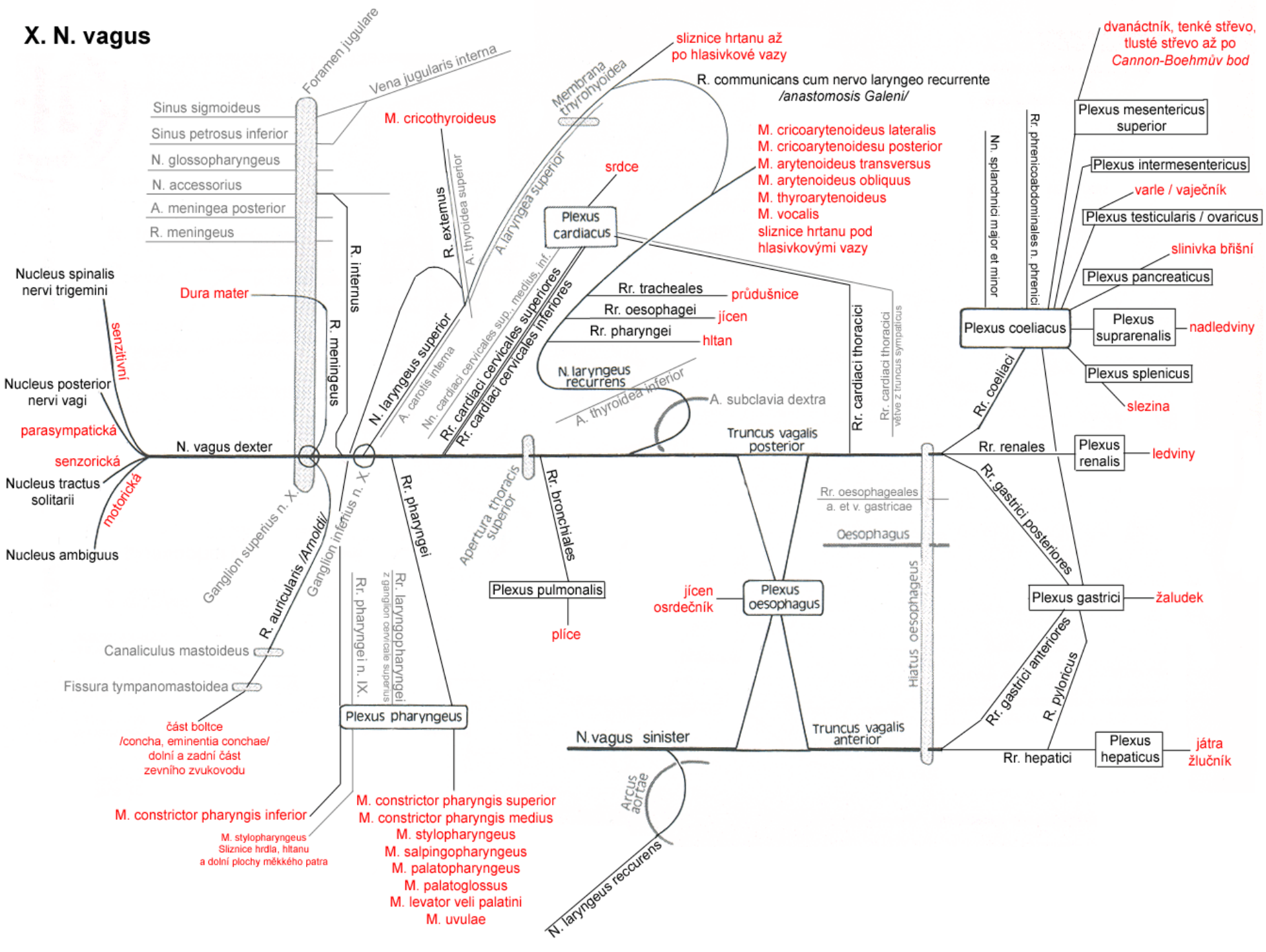


nervus
laryngeus
superior

nervus
laryngeus
recurrens



X. N. vagus



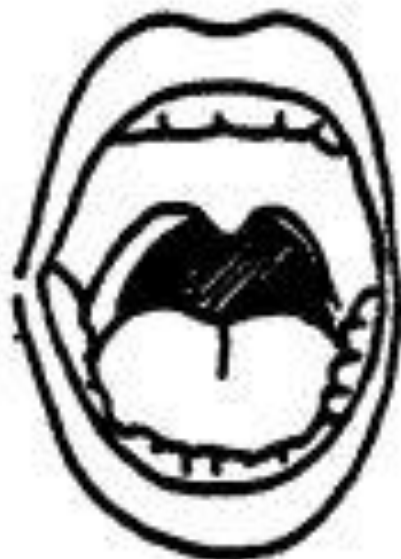X. - N. vagus

Palsy

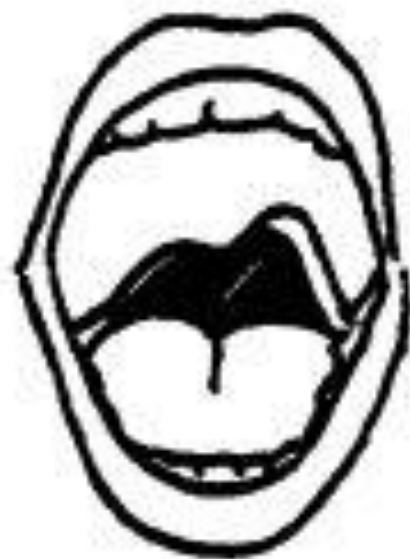- unilateral
 - affected swallowing (= dysphagia), hoarseness, blood pressure changes, deviation of uvula
- bilateral
 - rhinolalia (= nasal speech), speech disorders (= dysarthria), hypertension, resp. stopped breathing

Irritation of n.X

- bradycardia, spasms of digestive tube (laryngospasmus, oesophagospasmus, pylorospasmus)



Normal



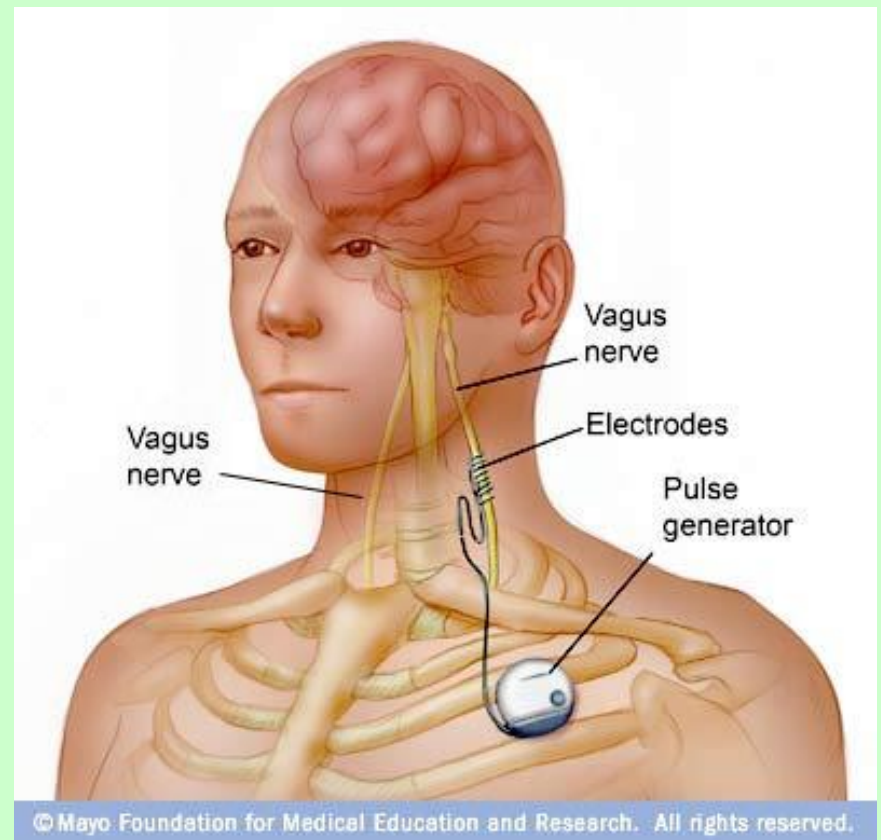
Palsy of right palate

Figure 2-15: A normal soft palate is illustrated on the left. On the right, a right palatal palsy from a lower motor neuron X nerve lesion has resulted in deviation of the uvula to the left.

X. - N. vagus

Clinical notes

- examination: vomiting reflex
- reflexes:
 - oculocardial
(Aschner-Dagnini's reflex)
- stimulation of n.X
epilepsy, depression



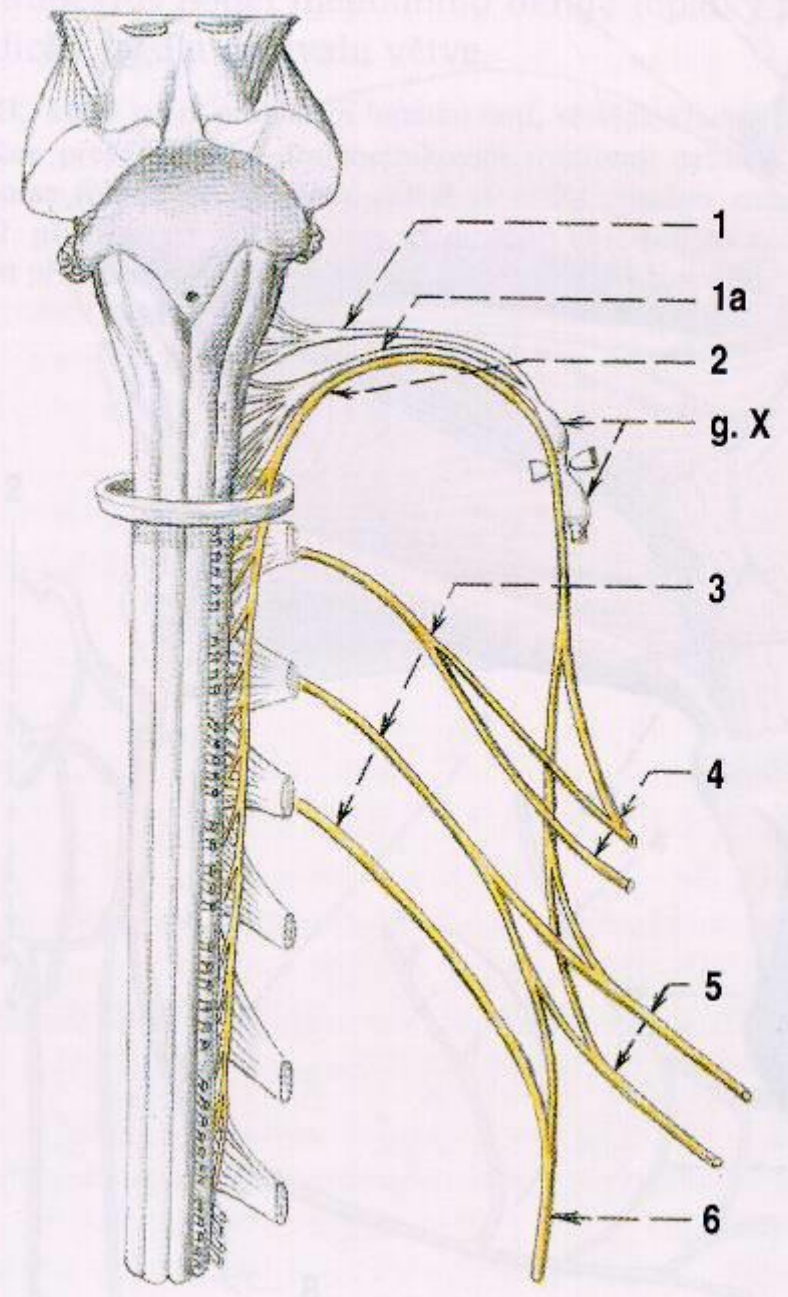
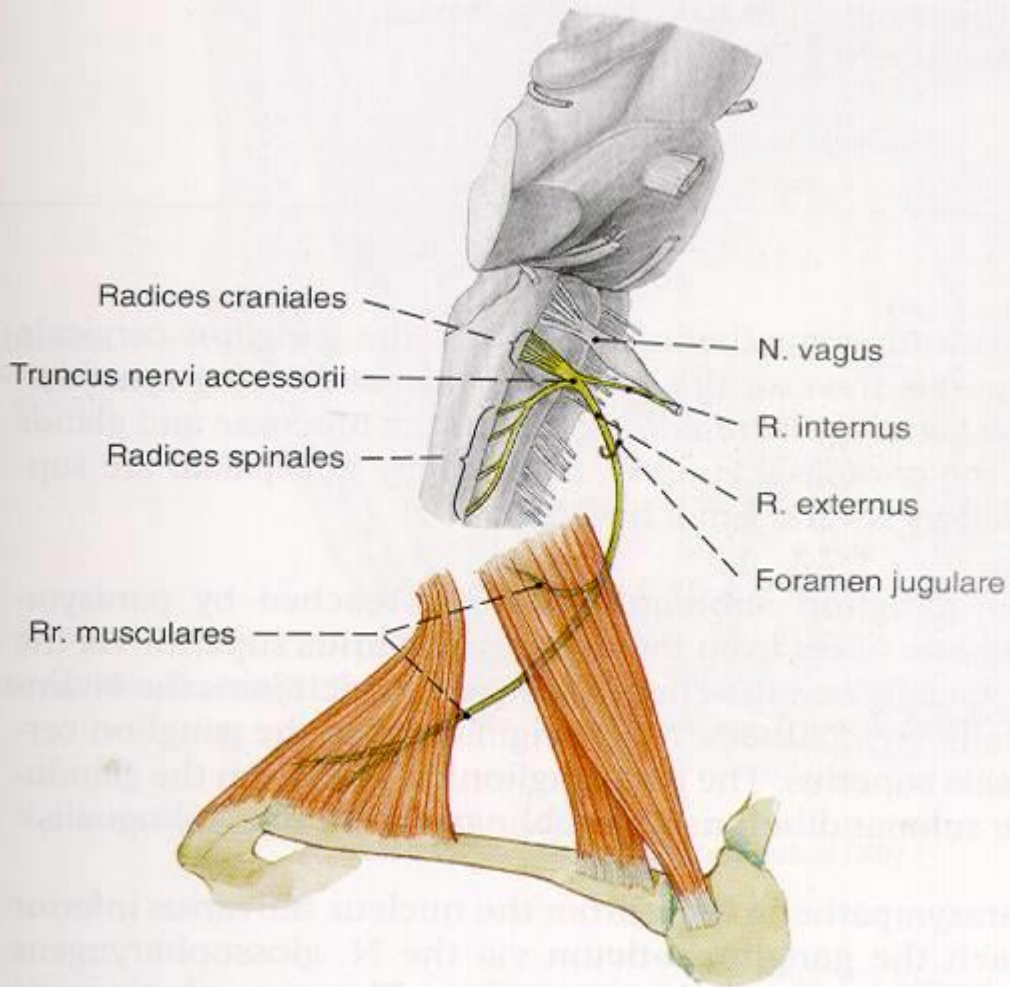
XI. = N. accessorius

combined nerv (2 independent components grown in one trunk)

2 nuclei → 2 roots → **1 trunk** → 2 branches

- *somatomotor branchial* (6th arch)
 - nucleus in medulla oblongata: ncl. ambiguus → radix cranialis → truncus n.XI → ramus internus → n. X → soft palate muscles (4) + lateral muscle group of larynx (3)
- *somatomotor somite (cervical somites)*
 - nucleus in cervical spinal cord: ncl. n. XI. medullae spinalis → radix spinalis → truncus n.XI → ramus externus → m. sternocleidomastoideus + m. trapezius
 - direct fibres via n. spinalis C2-4 → loop between both ways = *ansa Maubraci*

XI. = N. accessorius



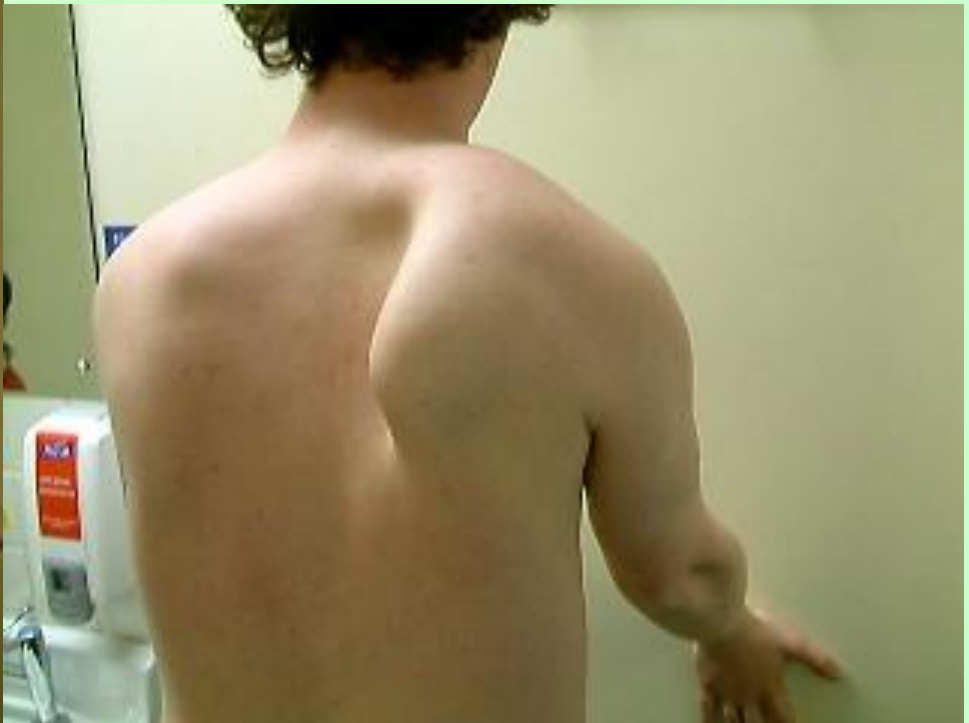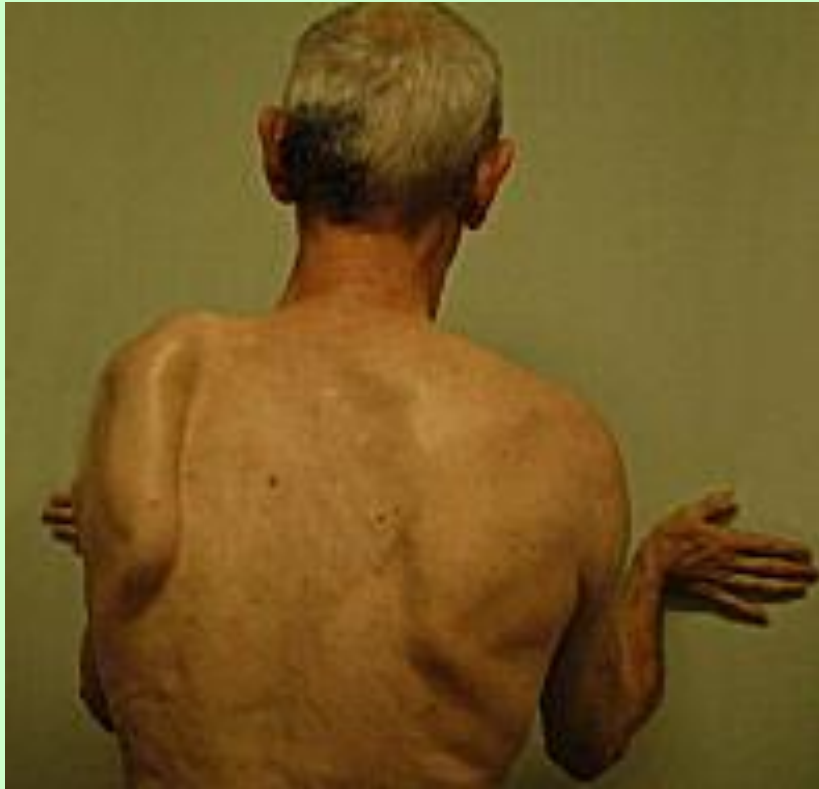XI. - N. accessorius

Palsy

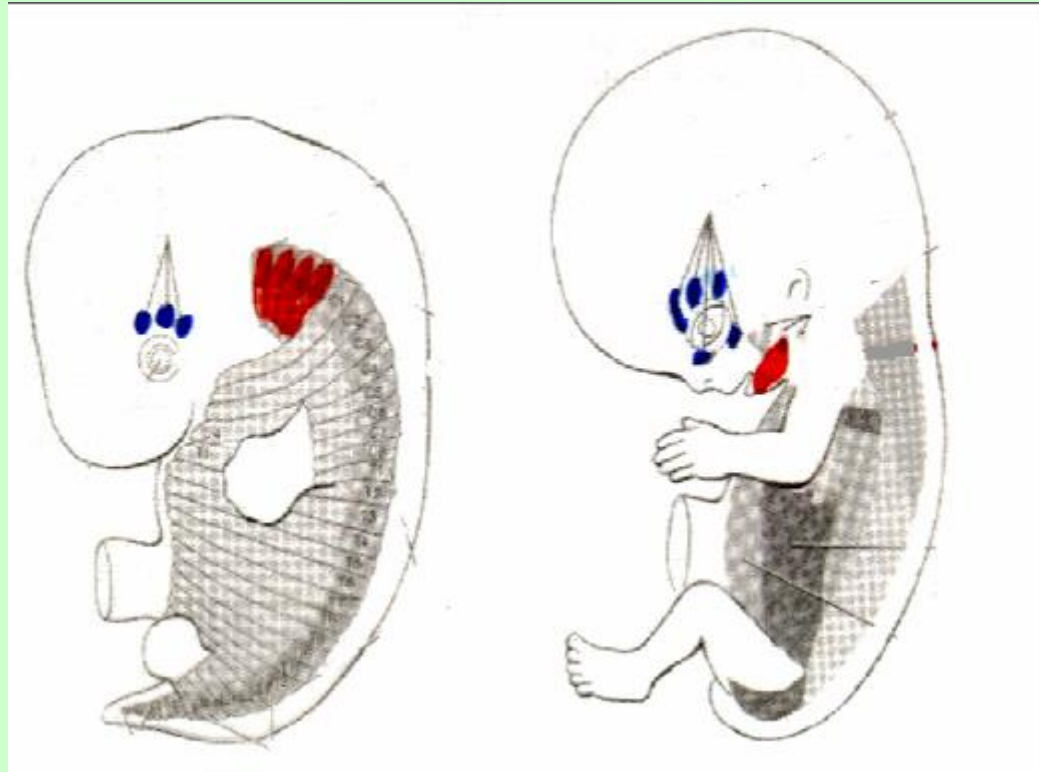
unilateral

- palsy of r. internus (*Avelis' syndrome*)
 - affected soft palate (depressed pharyngeal arches, depressed uvula, affected swallowing and speech)
- palsy of r. externus
 - depressed shoulder, almost no abduction above horizontal plane, affected heard, rotation, winged scapula (= scapula alata)
- palsy of whole nerve (*Schimdt's syndrome*)
 - very rare!

Winged scapula (= scapula alata)



SomatoMotor somatic CN

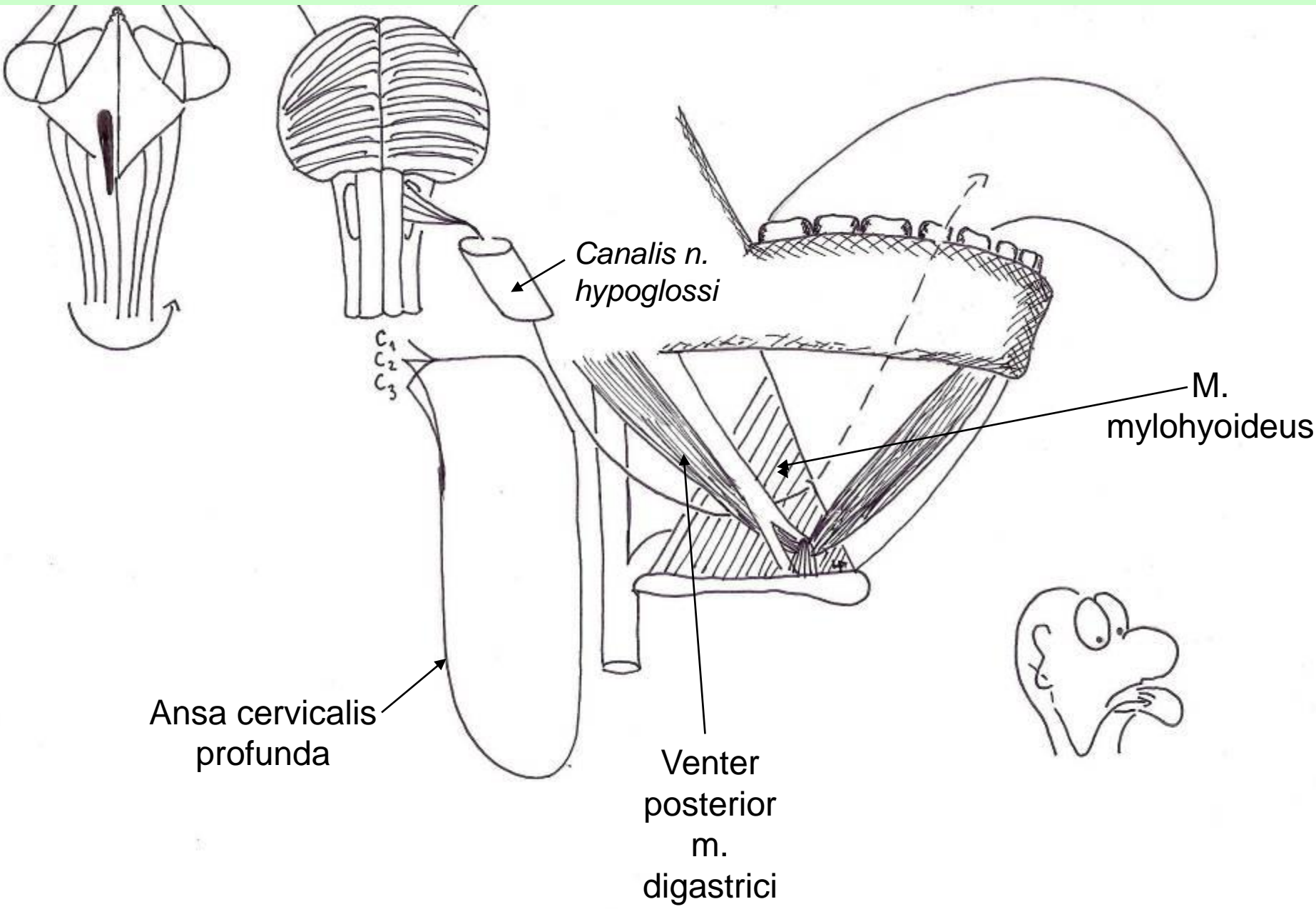


- preotic myotoms (somitomers) form external muscles of eyeball – n. III, IV, VI
- **occipital somites form muscles of tongue – n. XII**

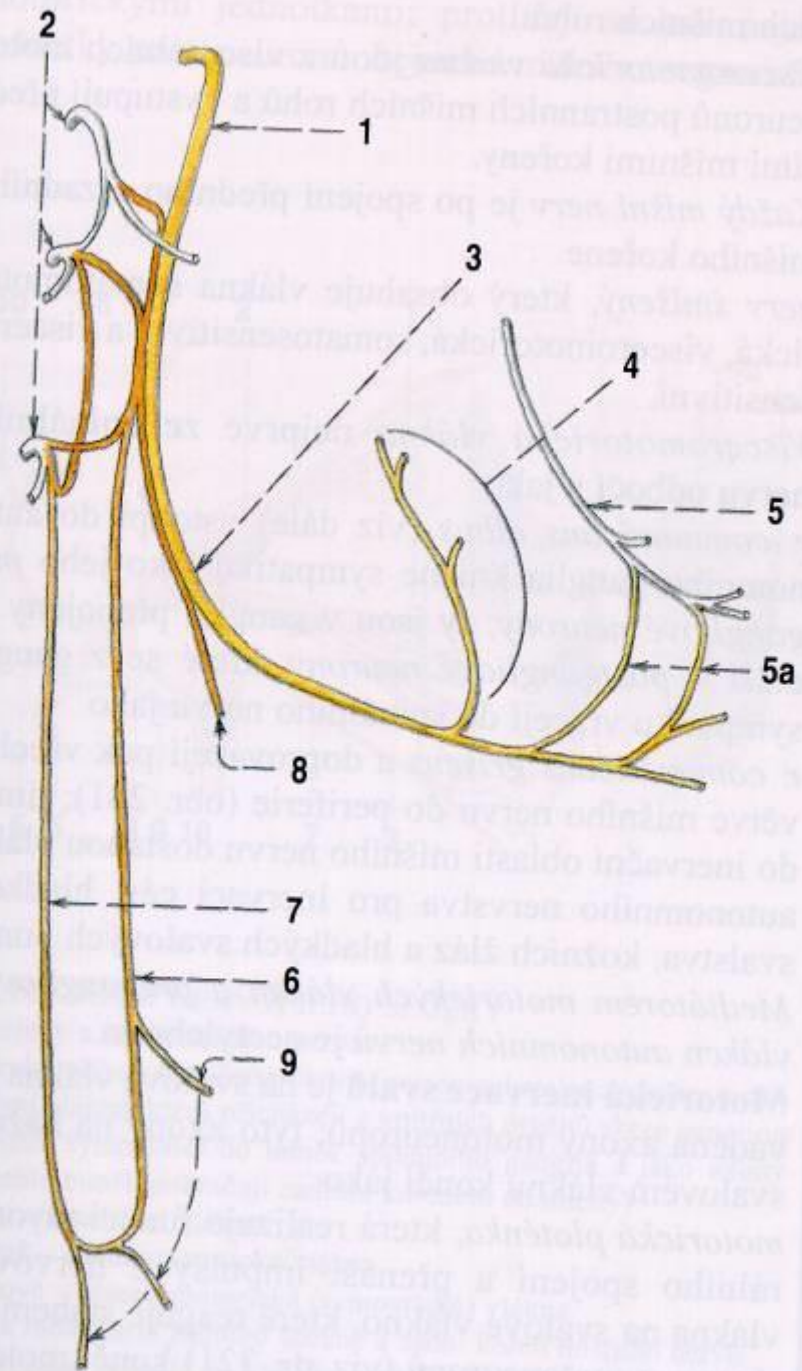
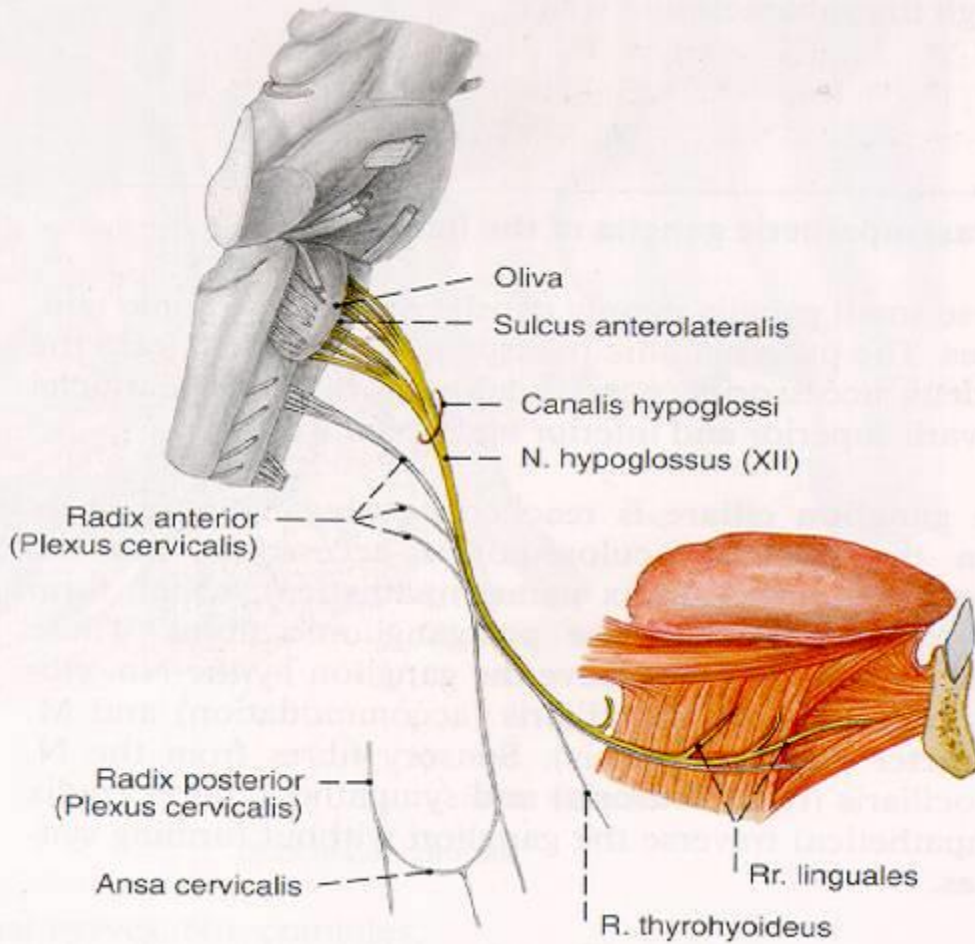
XII. = N. hypoglossus

- *somatomotor somite* (occipital somites)
- 1 nucleus in medulla oblongata: ncl. n. XII
course: ventrally to olive from medulla oblongata (= *sulcus preolivaris*) → fossa cranii posterior → canalis nervi hypoglossi → spatium retrostyloideum (spatium parapharyngeum) → trigonum caroticum → trigonum submandibulare → tongue
- **7 muscles of tongue**
 - 3 extraglossal and 4 intraglossal

XII. = N. hypoglossus



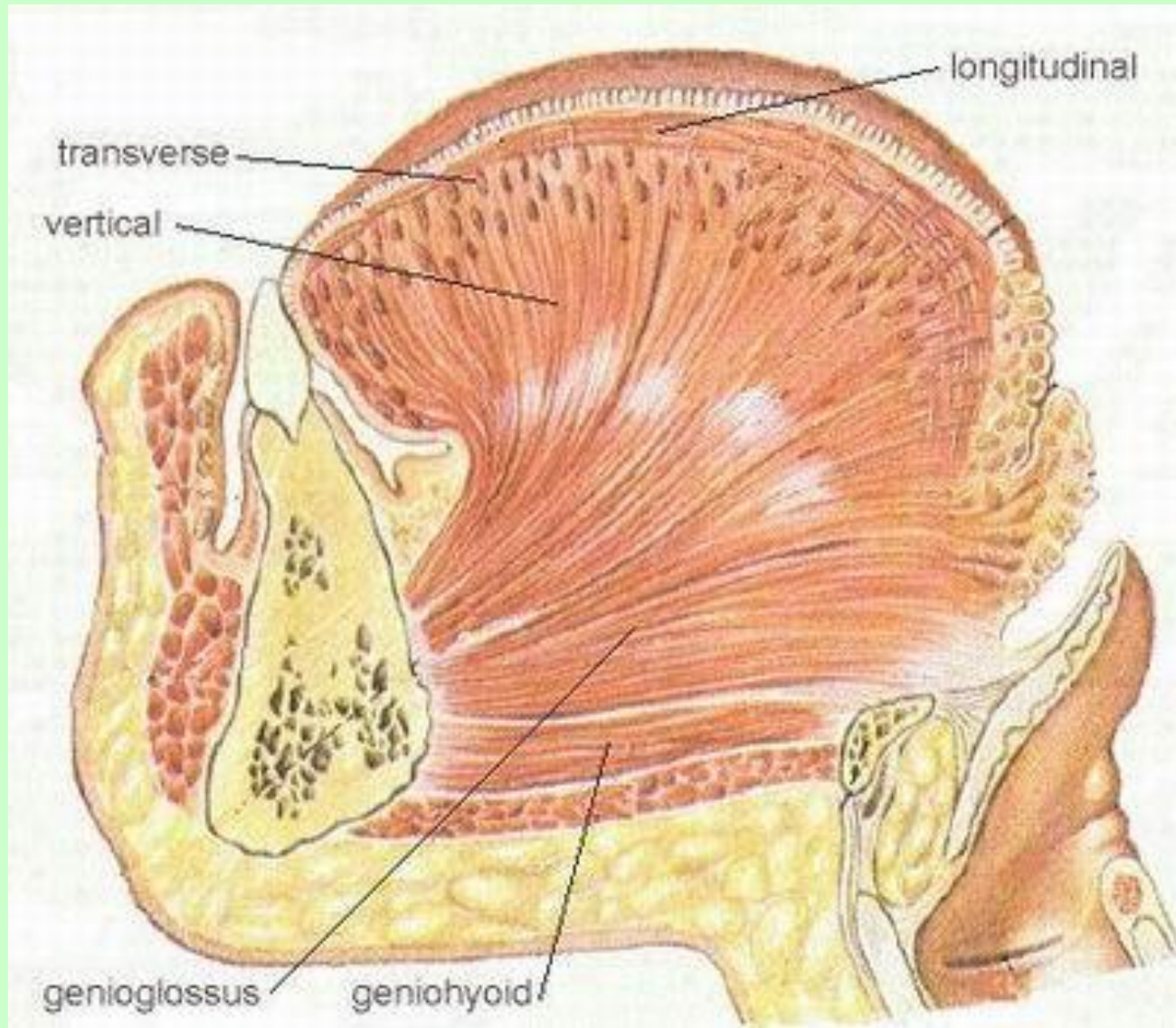
XII. = N. hypoglossus



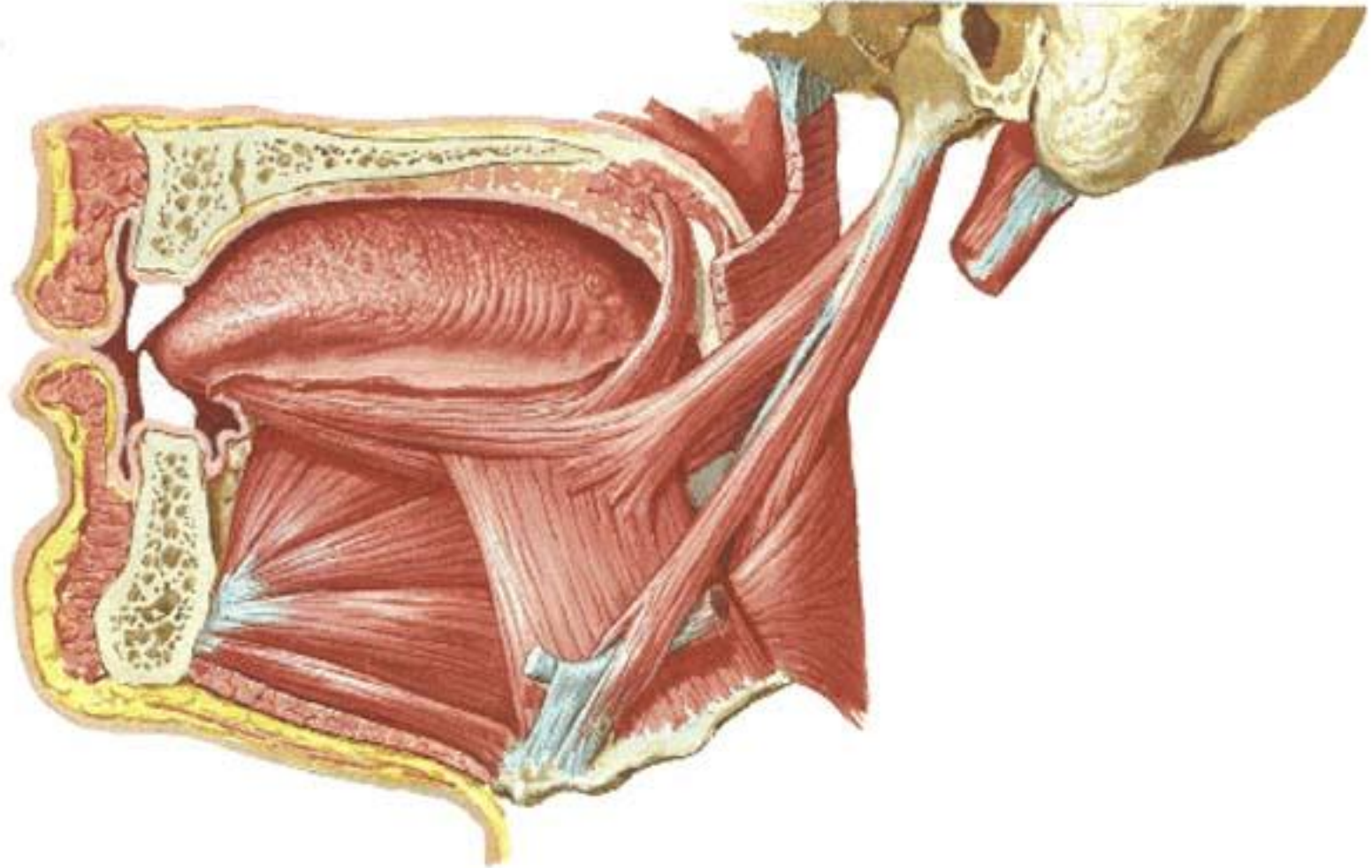
Muscles of tongue

- aponeurosis, septum (*incomplete!*)
- intraglossal – **n. hypoglossus /n. XII/**
 - m. longitudinalis sup. et inf.
 - transversus
 - verticalis
- extraglossal – **n. hypoglossus /n. XII/**
 - m. genioglossus /n.XII./
 - hyoglossus /n.XII./
 - styloglossus /n.XII./
 - palatoglossus - **!exception! – n. vagus /n.X./**

Muscles of tongue



Muscles of tongue



Hemiglossoplegia

