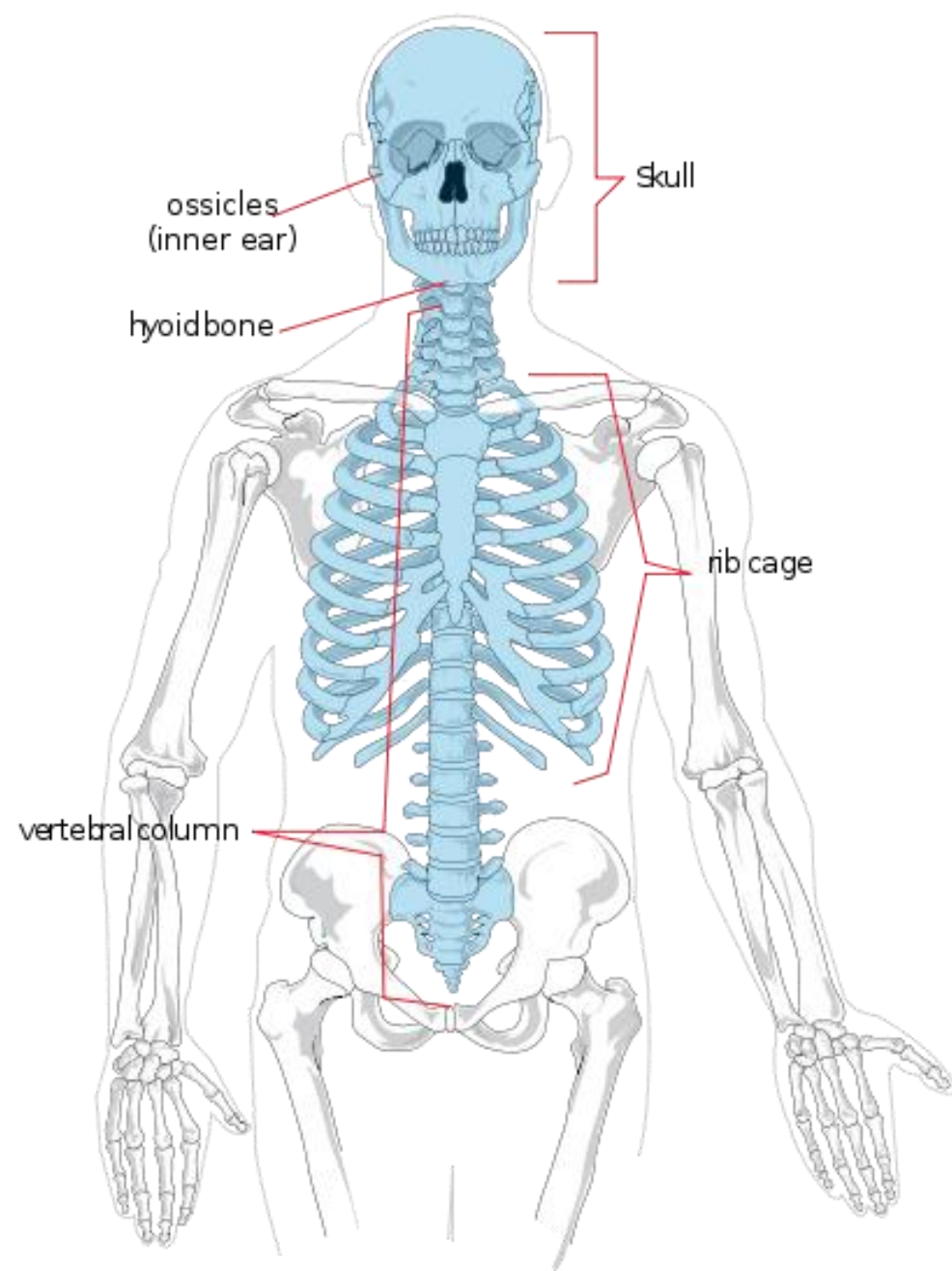
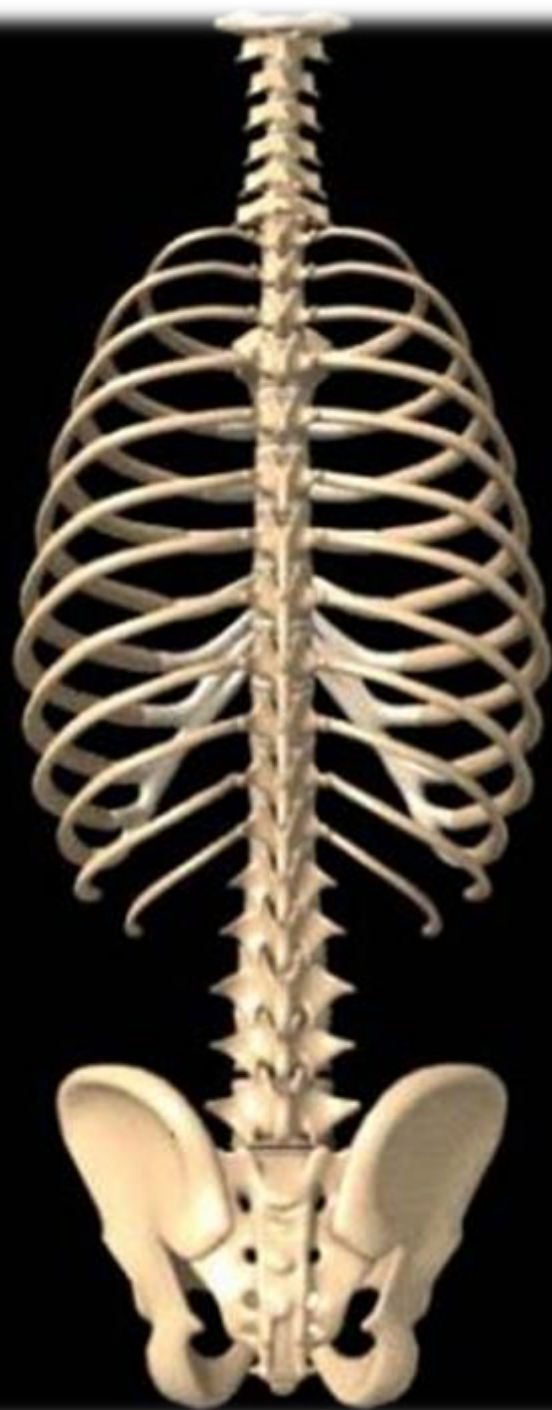
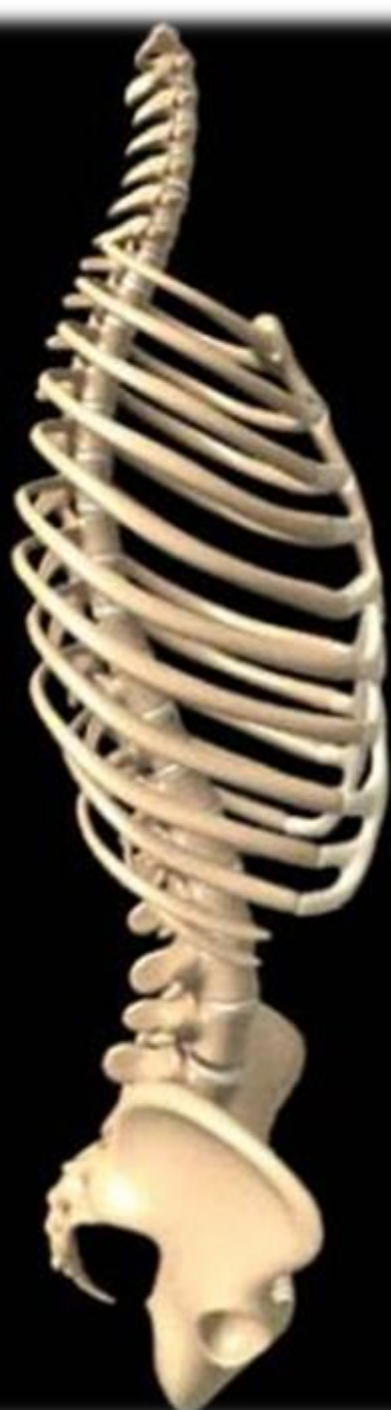
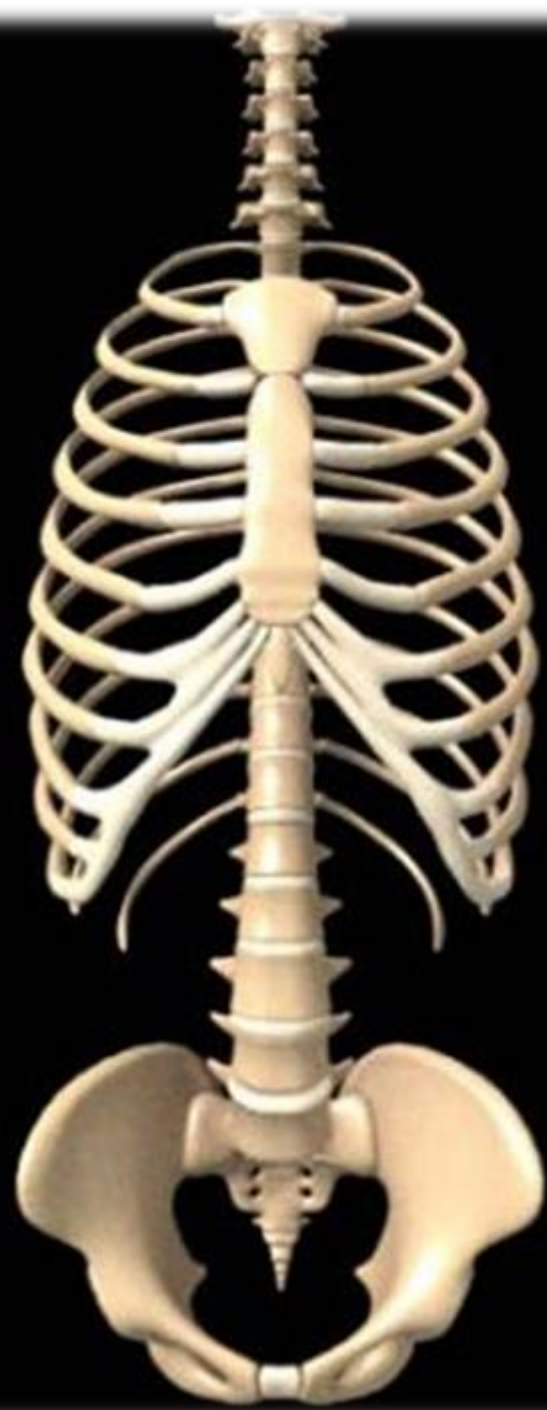Vertebral column Thorax Pelvis as a whole

Columna vertebralis
Skeleton thoracis
Pelvis

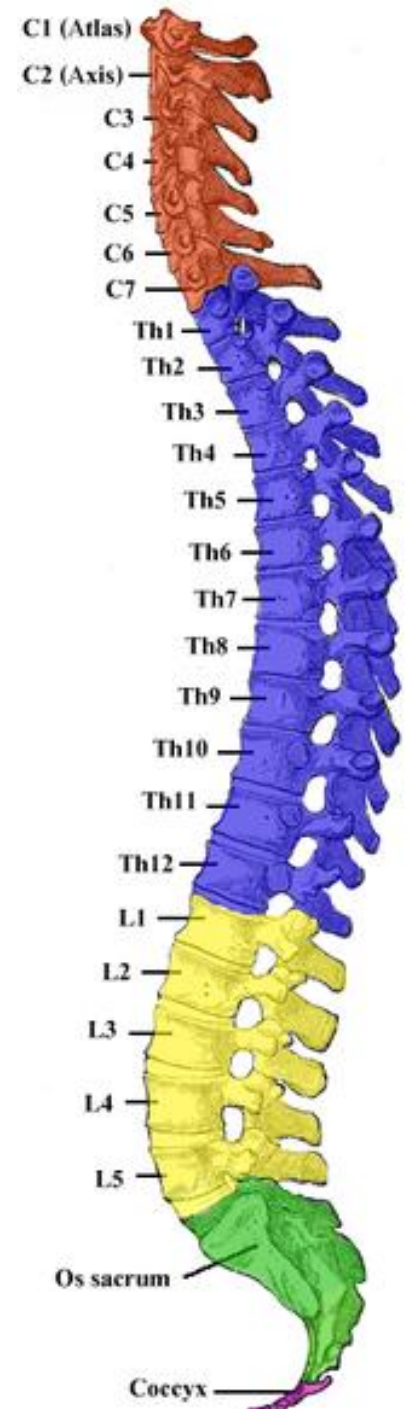




Vertebral column *columna vertebralis*

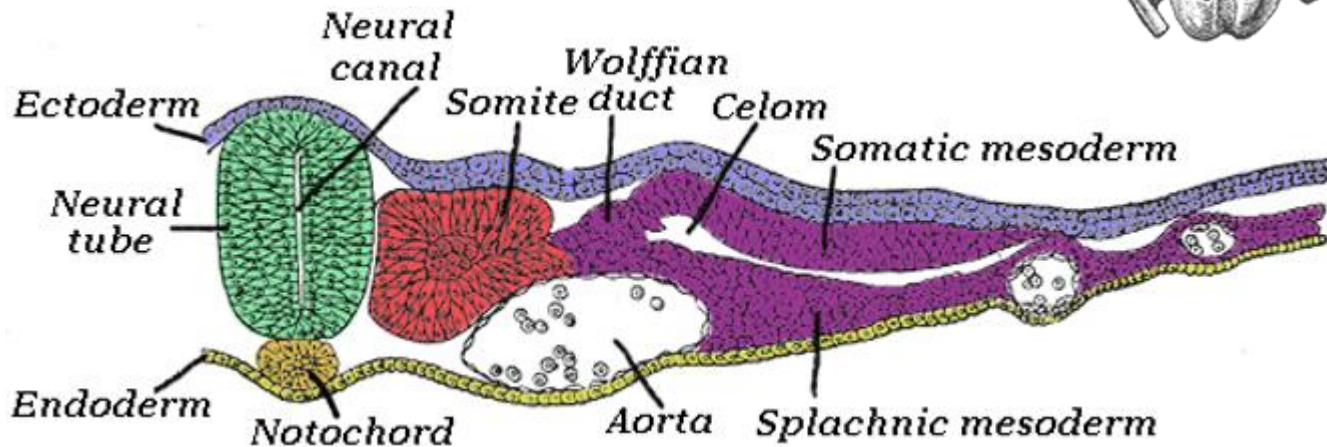
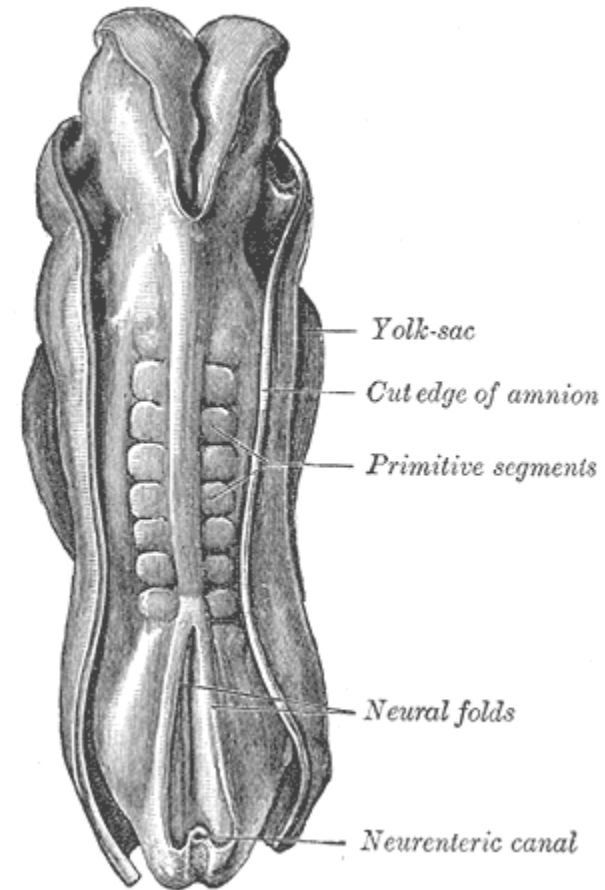
composed of vertebrae:

- 7 cervical
- 12 thoracic
- 5 lumbar
- 5 sacral (fused into sacral bone)
- 4-5 coccygeal (atretic, fused into coccyx)

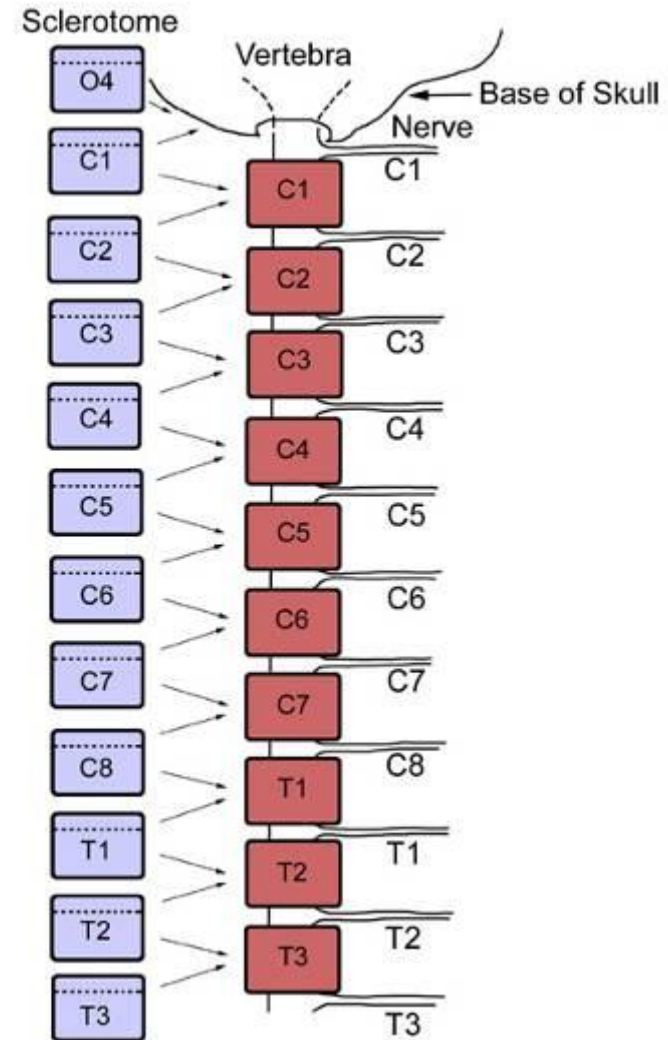
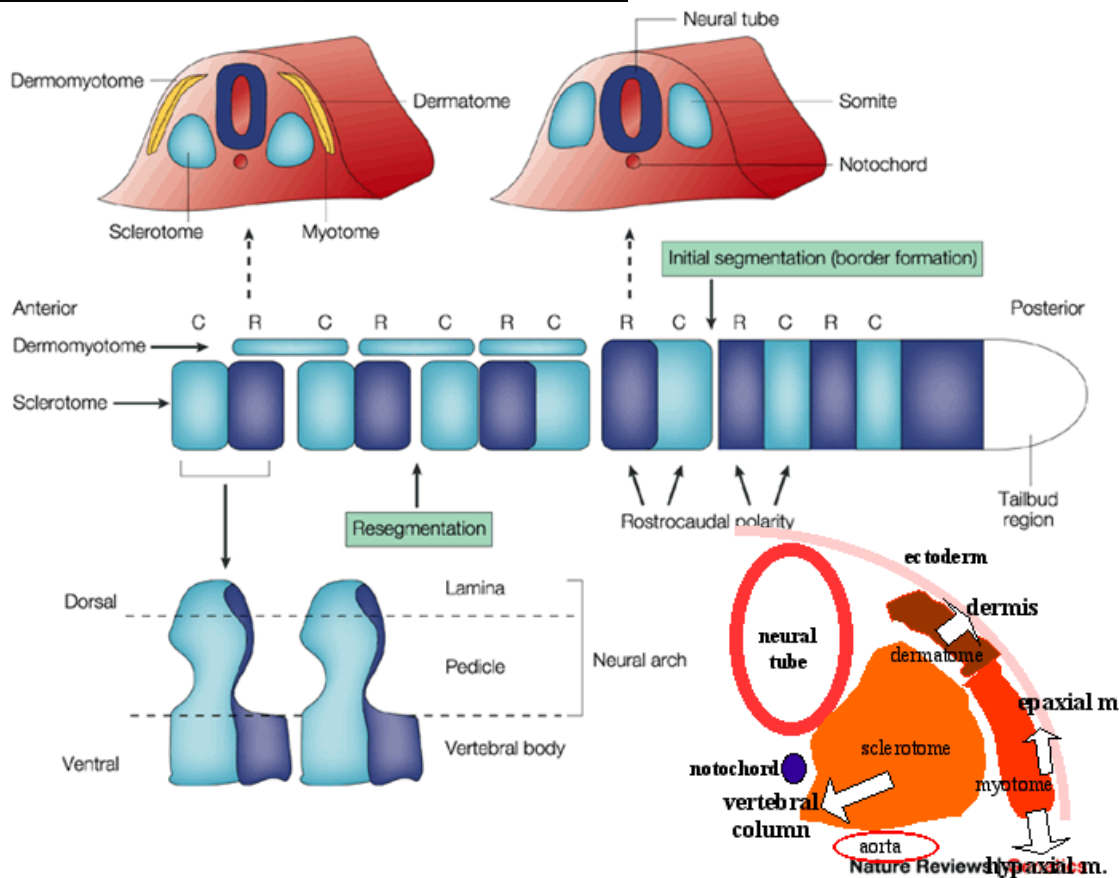
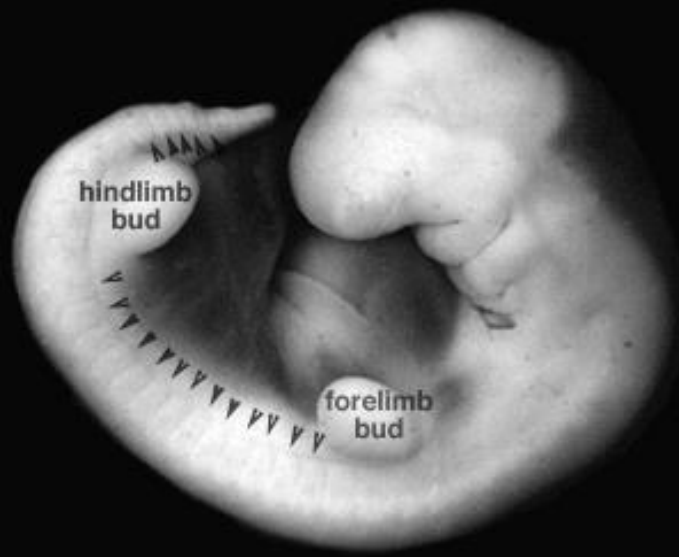


Vertebral column development

- somites
- exits of spinal nerves
- „occipital vertebra“
- notochord (dorsal string)




Somites



SOMITE

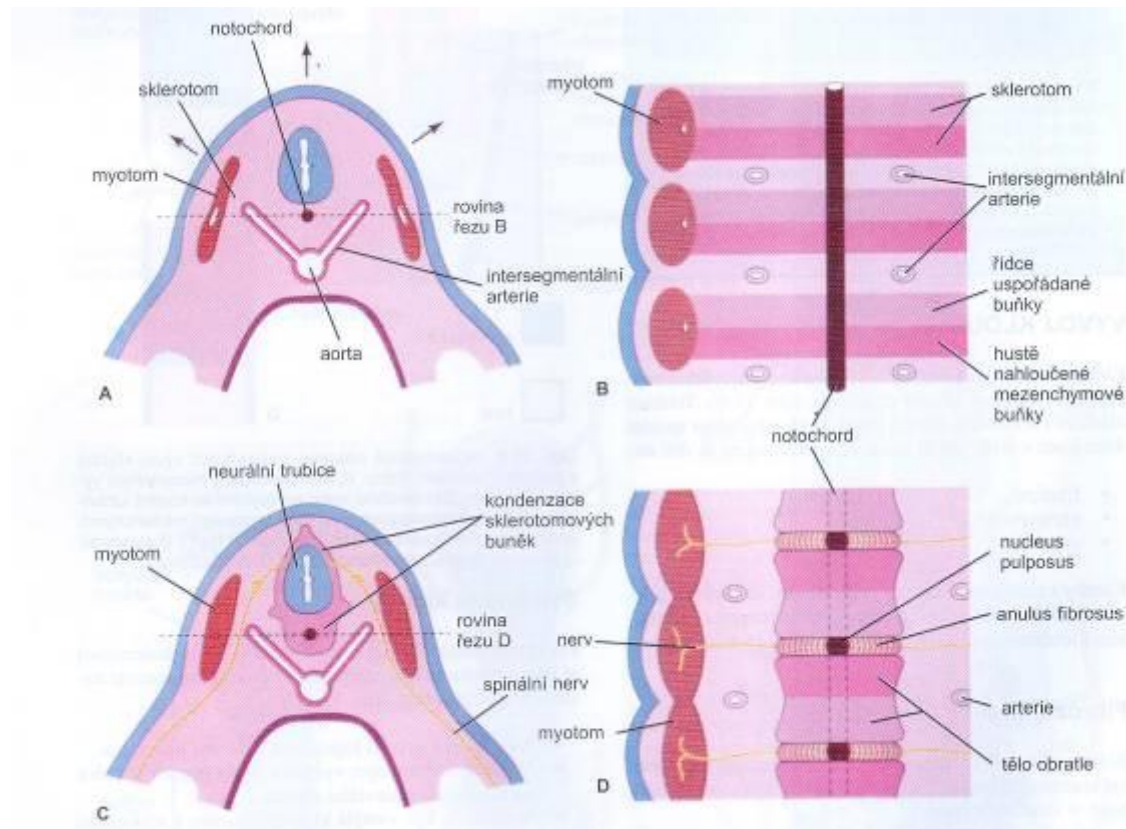


- dermatome
- myotome
- sclerotome



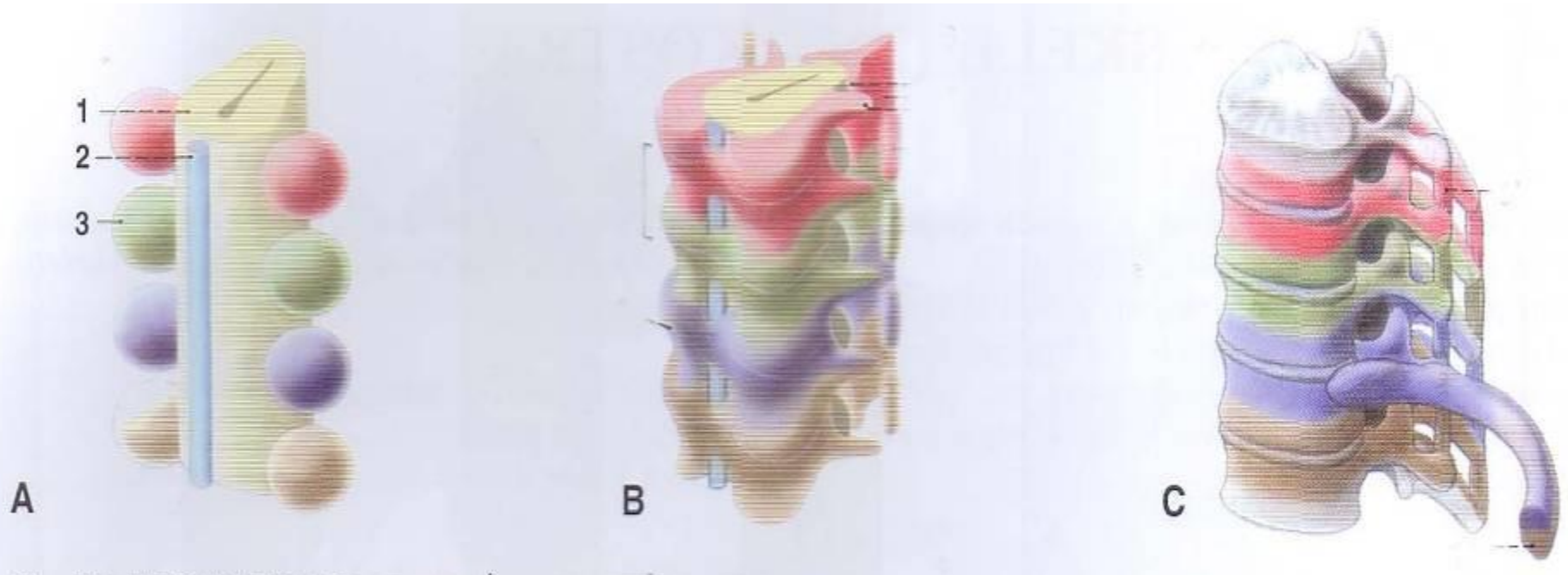
Development of vertebral column

- notochord
- myotome
- intersegmental arteries
- sclerotome
 - loosely structured part
 - densely structured part



Development of vertebrae

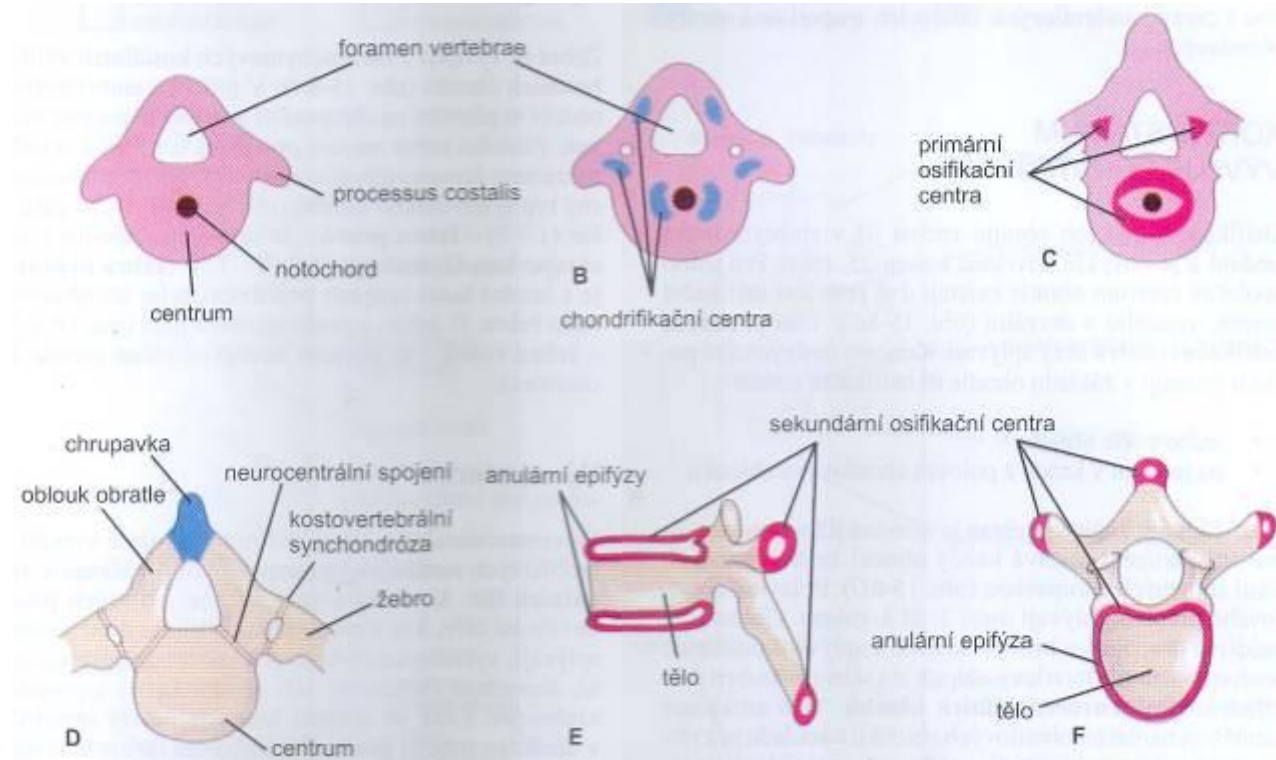
- sclerotome
- resegmentation



Development of vertebral column

- stages of development:

- primary chord
- mesenchymal
- cartilaginous
- ossification

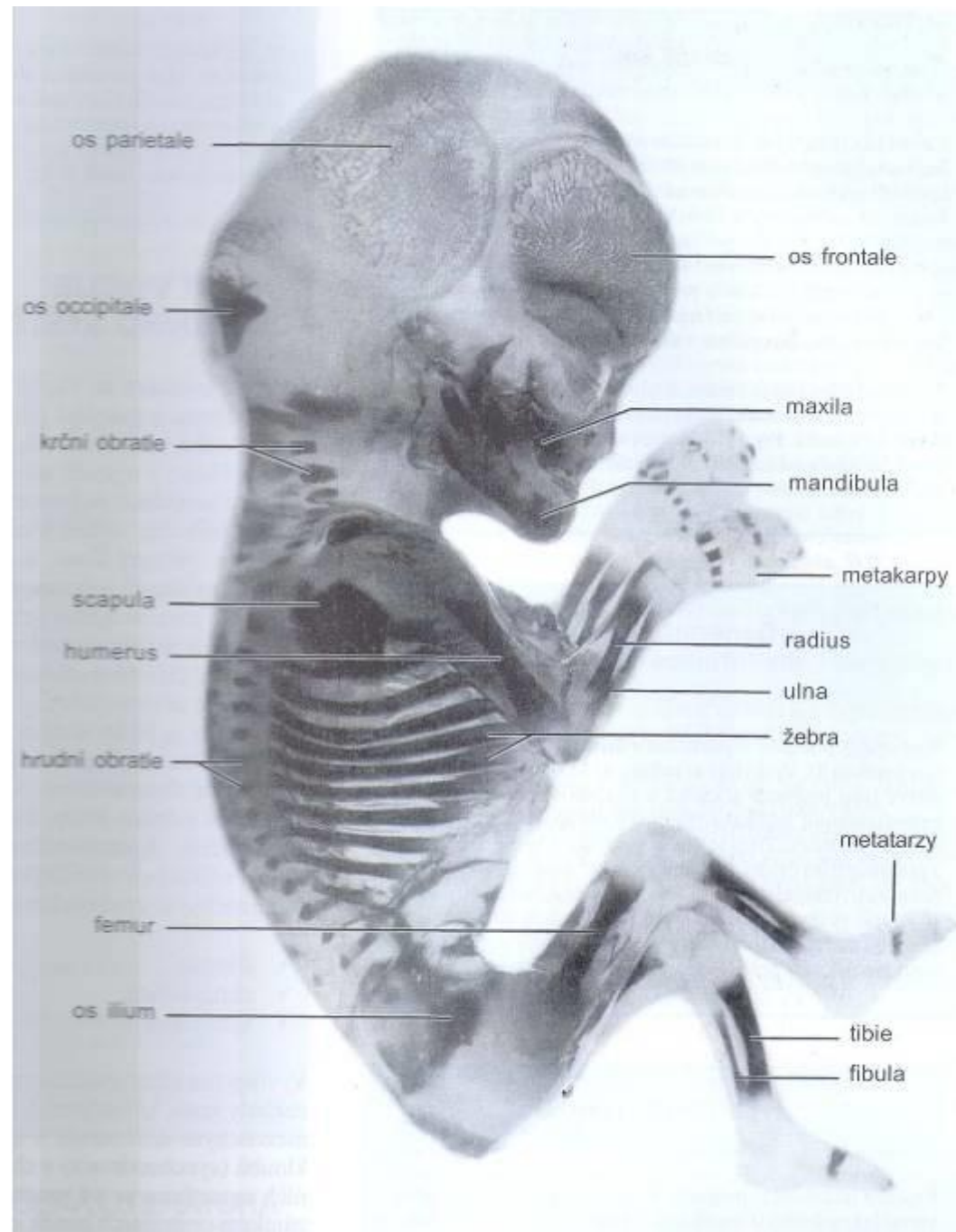


- centers of ossification:

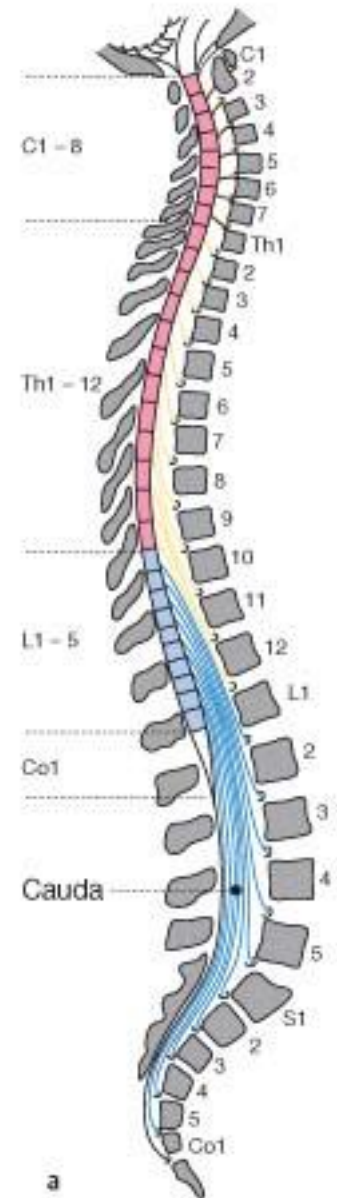
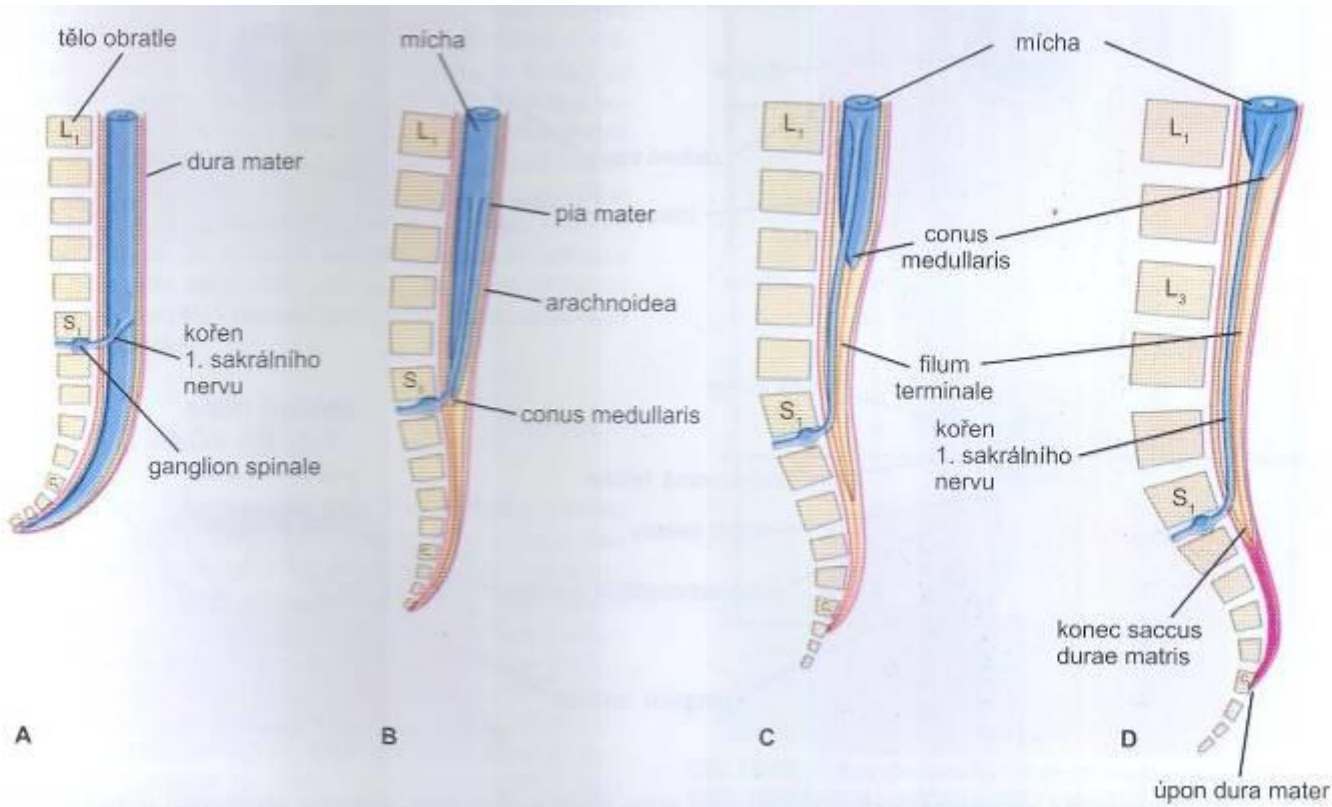
- primary
- secondary

Ossification

12 weeks old fetus



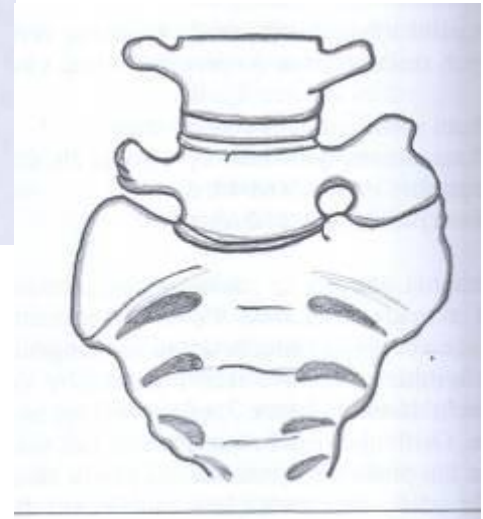
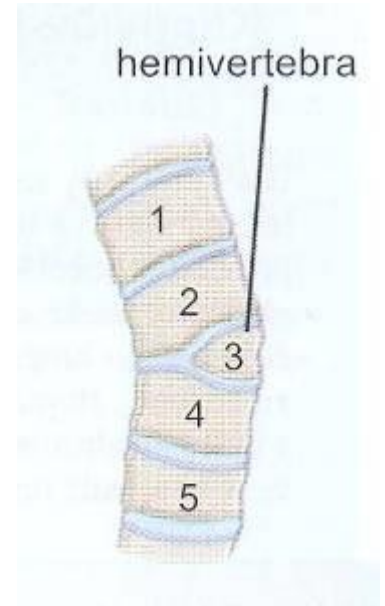
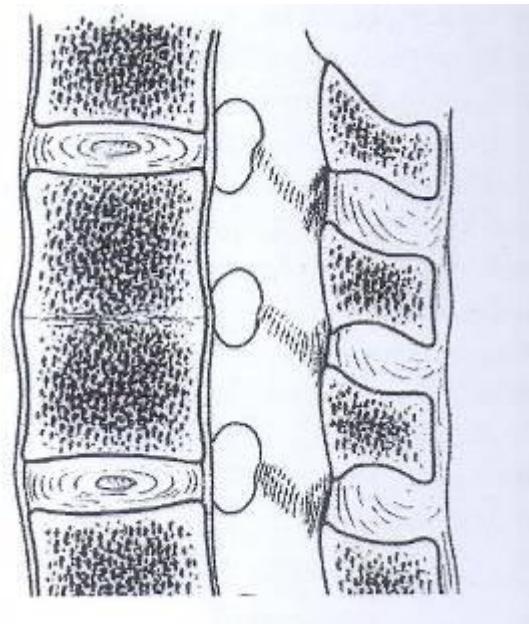
Development of vertebral canal



Development defects

basic abnormalities in segmentation:

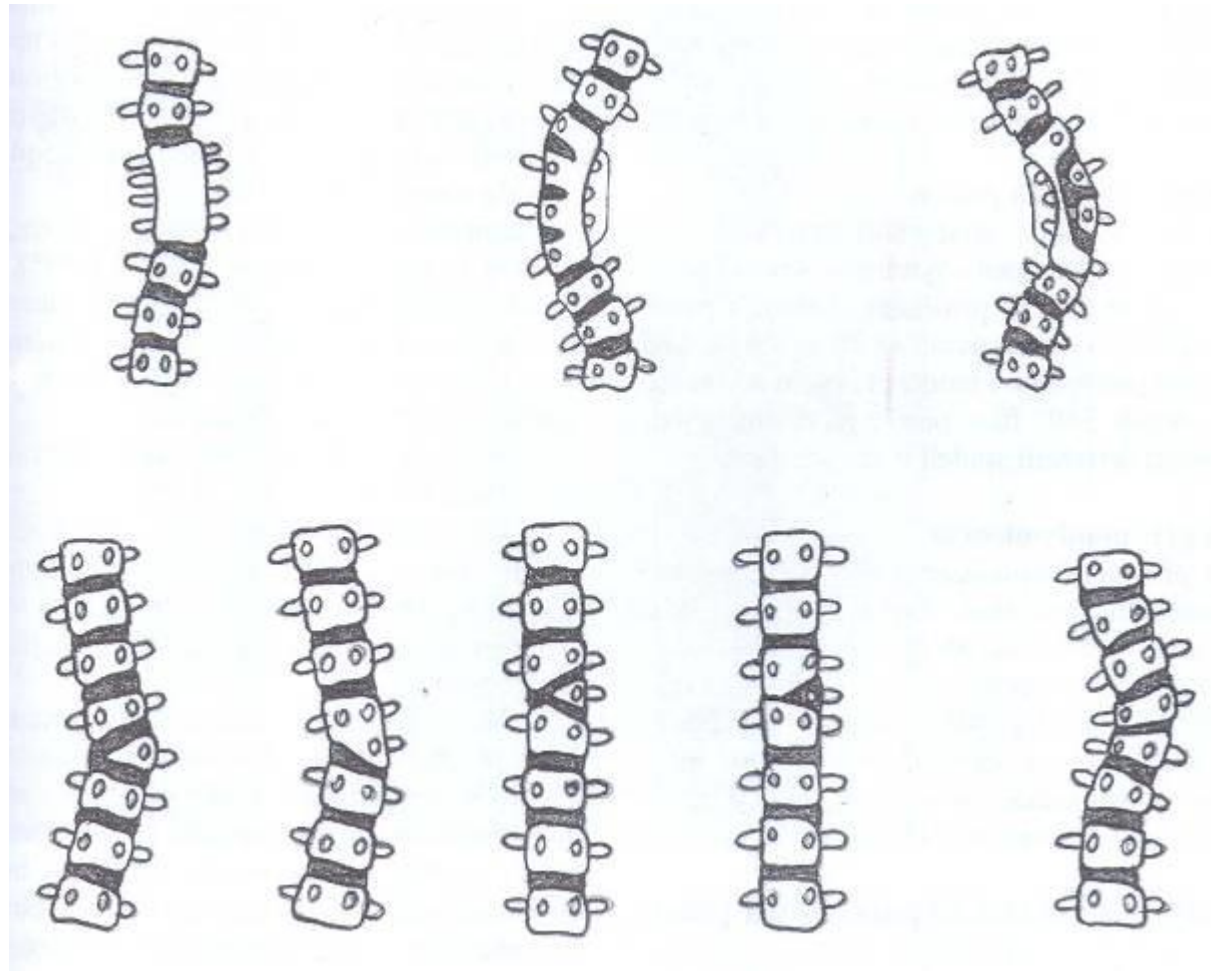
- hemivertebra
- congenital block
- sacralization x lumbalization



Development defects

abnormalities in segmentation and formation

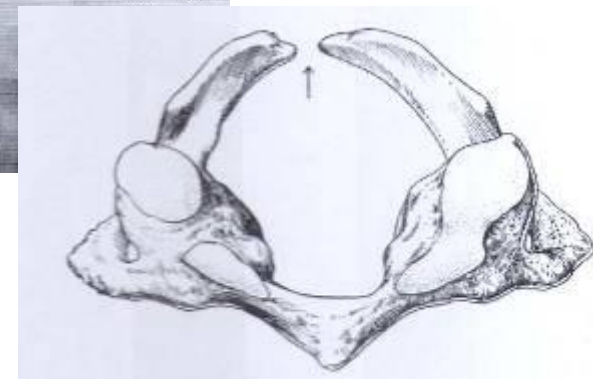
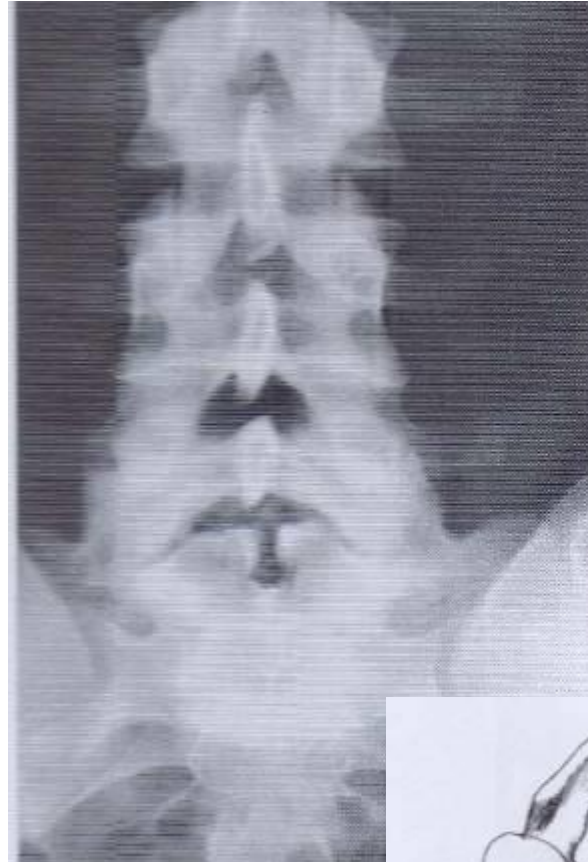- non-segmented ridge
- wedge-shaped vertebra
- hemivertebra
- quartervertebra
- corner vertebra



Development defects

abnormalities in vertebral arch closure:

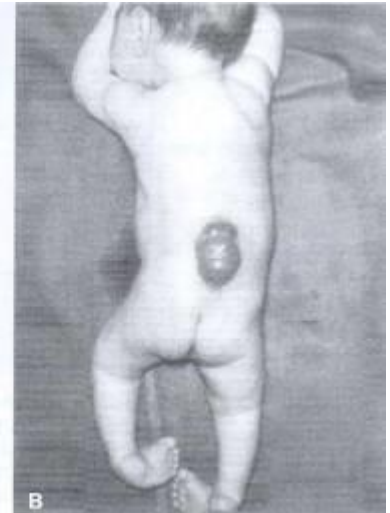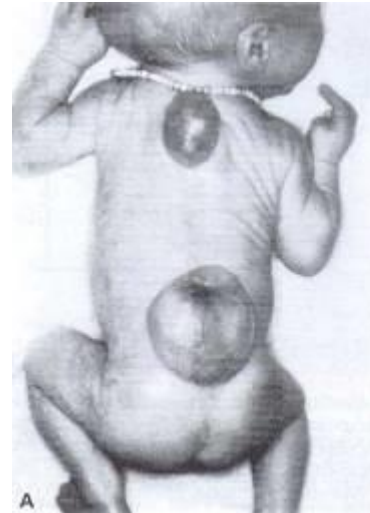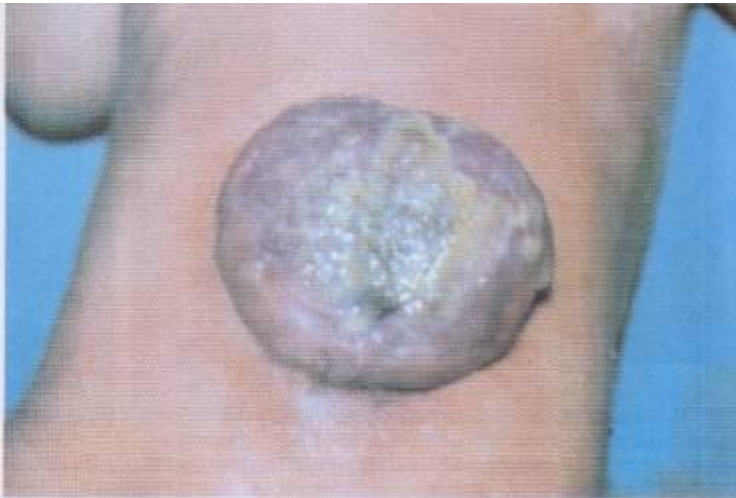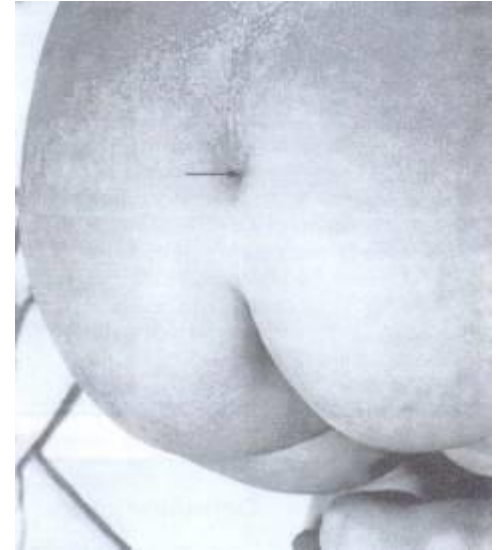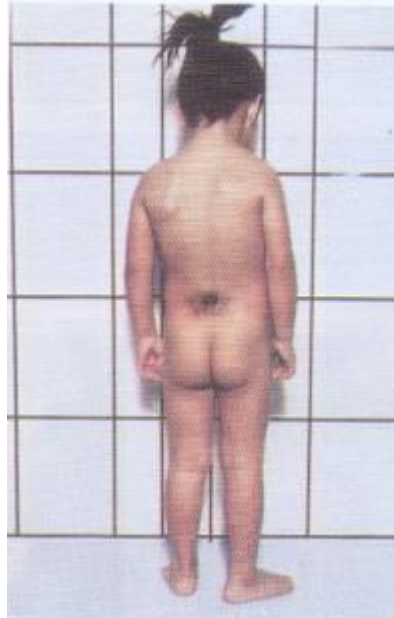
- majority in lumbar and sacral parts
- frequently accompanying with abnormalities of neural tube



Development defects

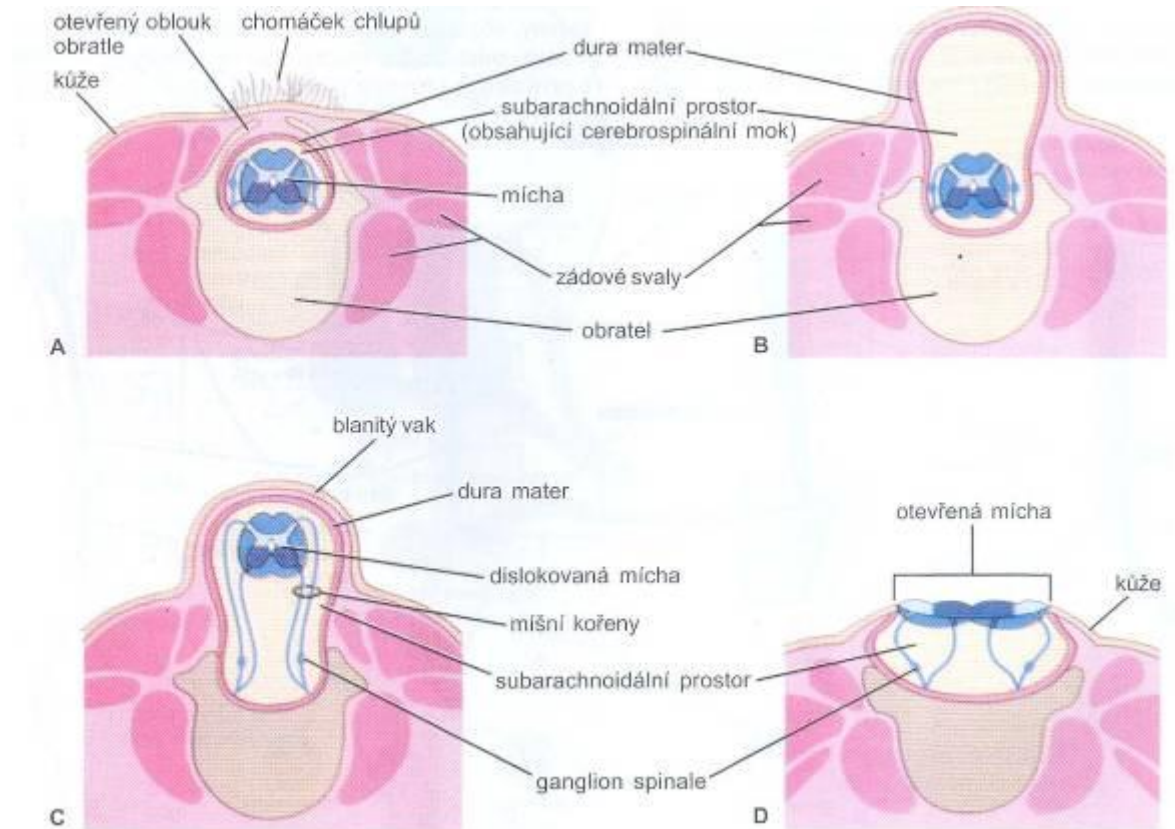
spina bifida:

- occulta
- dermal sinus
- cystica



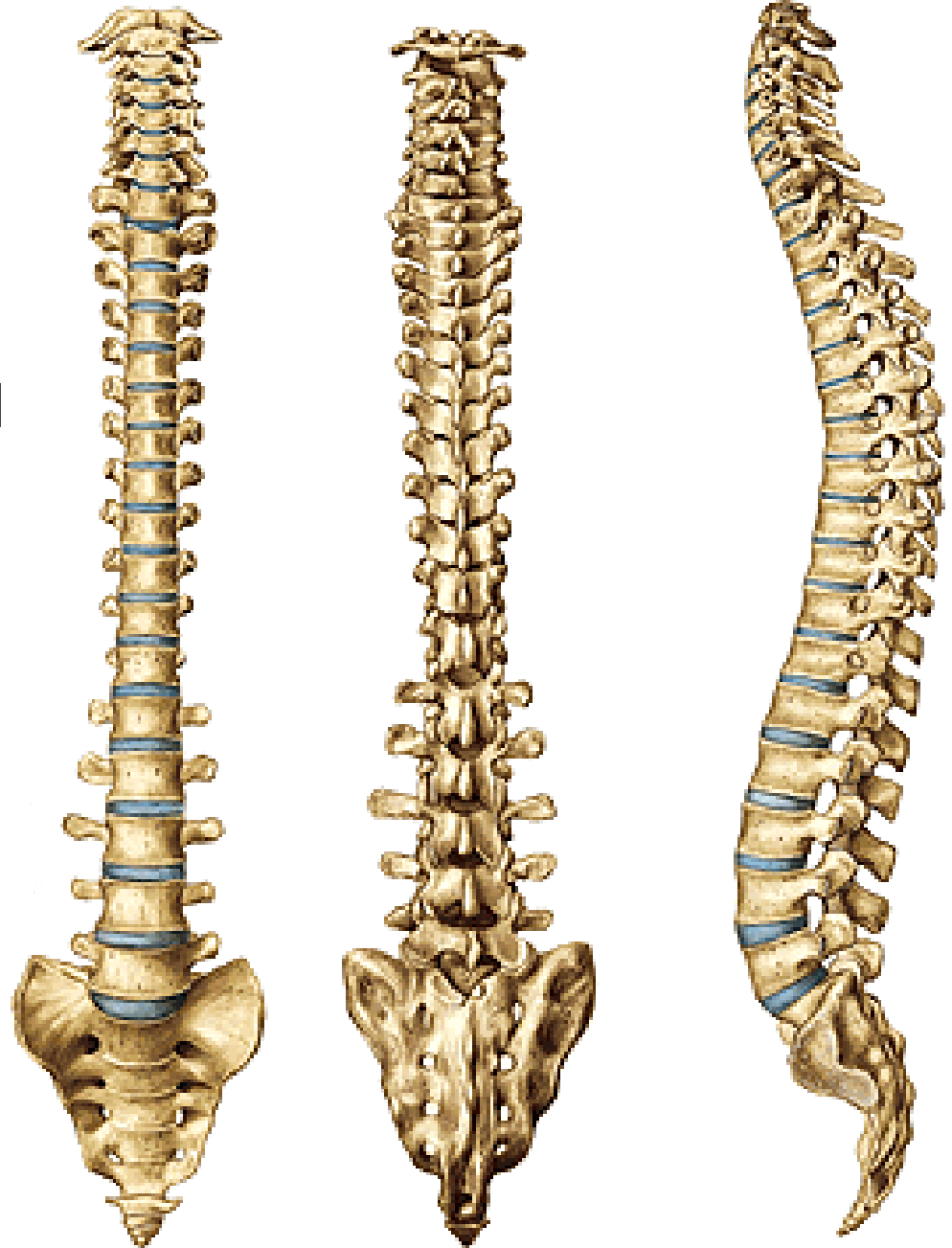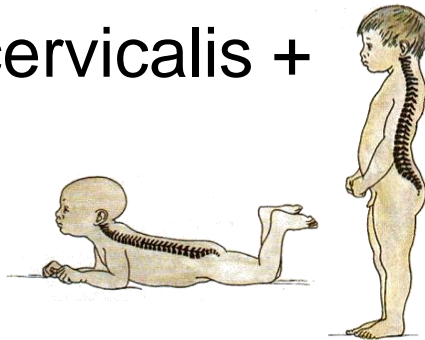
Development defects

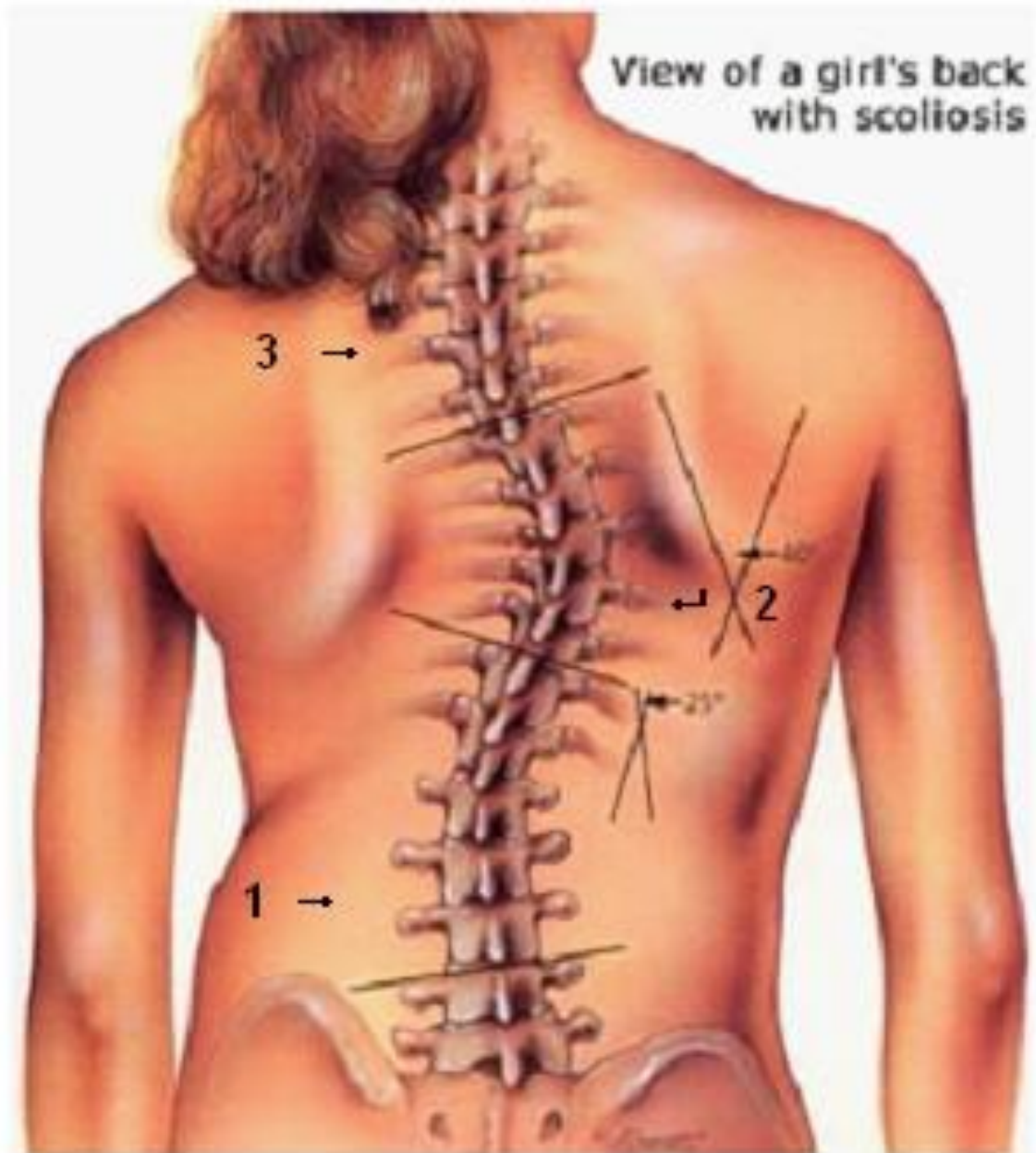
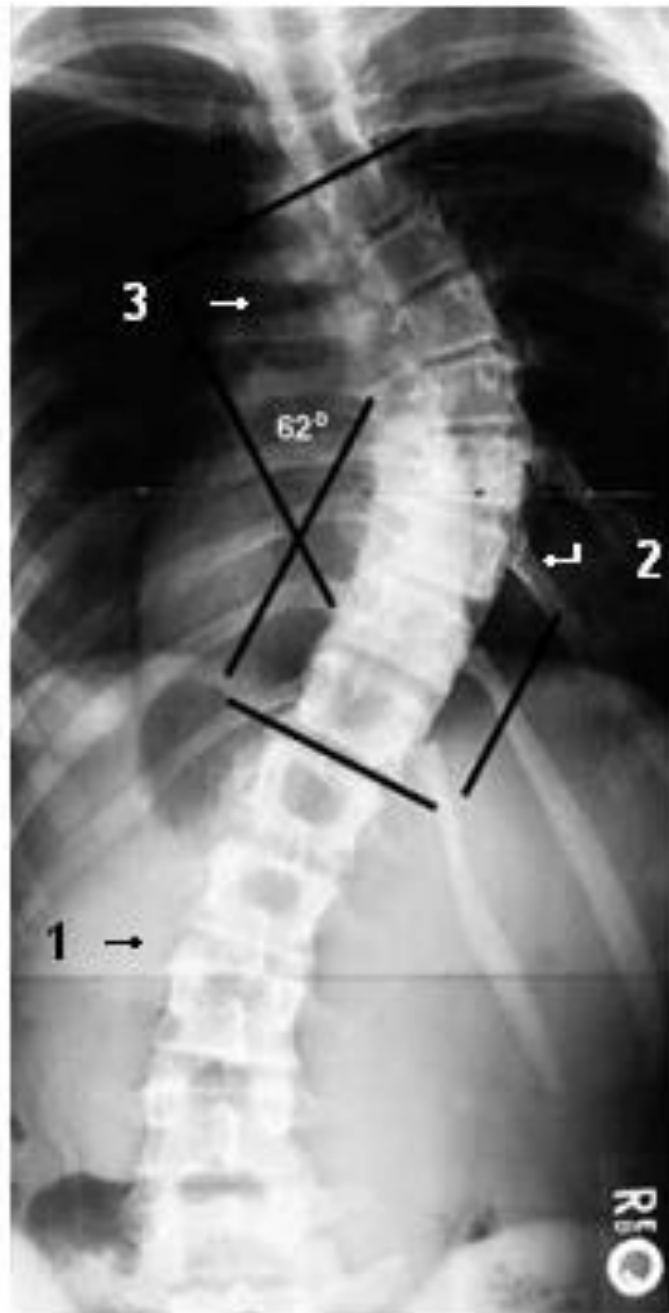- meningocele
- meningocele
- myeloschisis



Vertebral column

- column length – 35% of body height
- 1/5 to 1/4 length is formed by intervertebral discs
- kyphosis thoracica + sacralis
- lordosis cervicalis + lumbalis
- scoliosis
- canalis vertebralis
- foramen intervertebrale



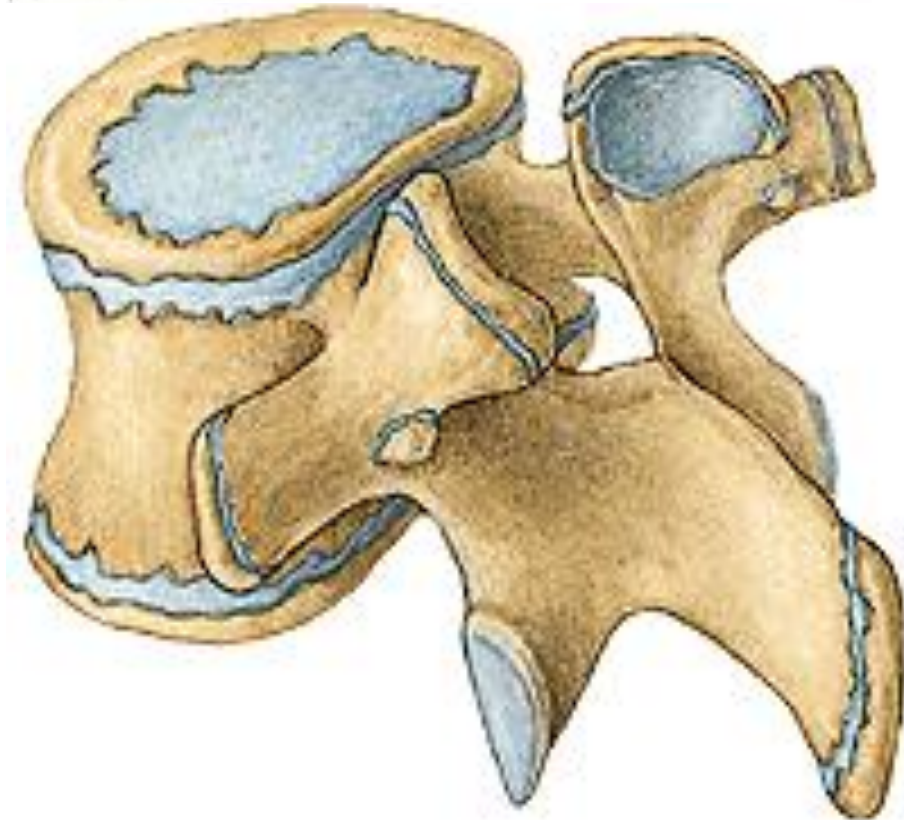
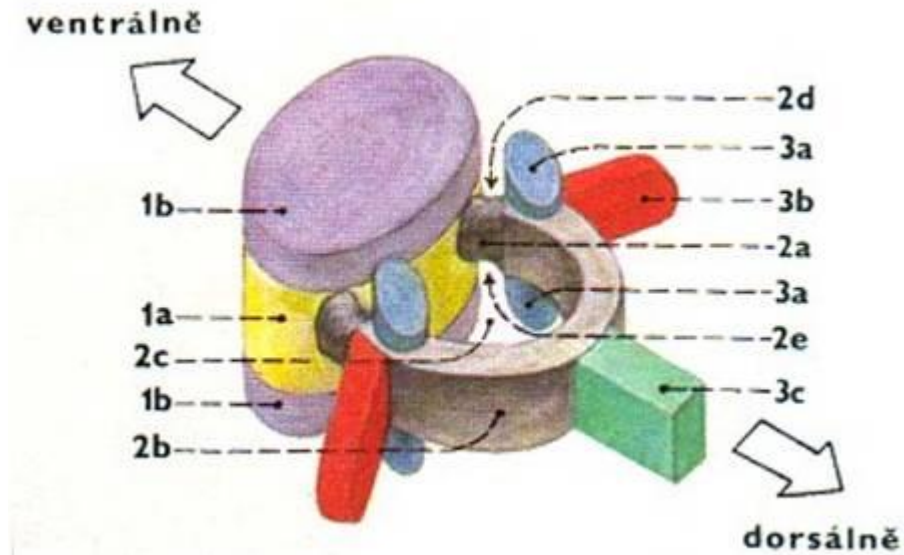


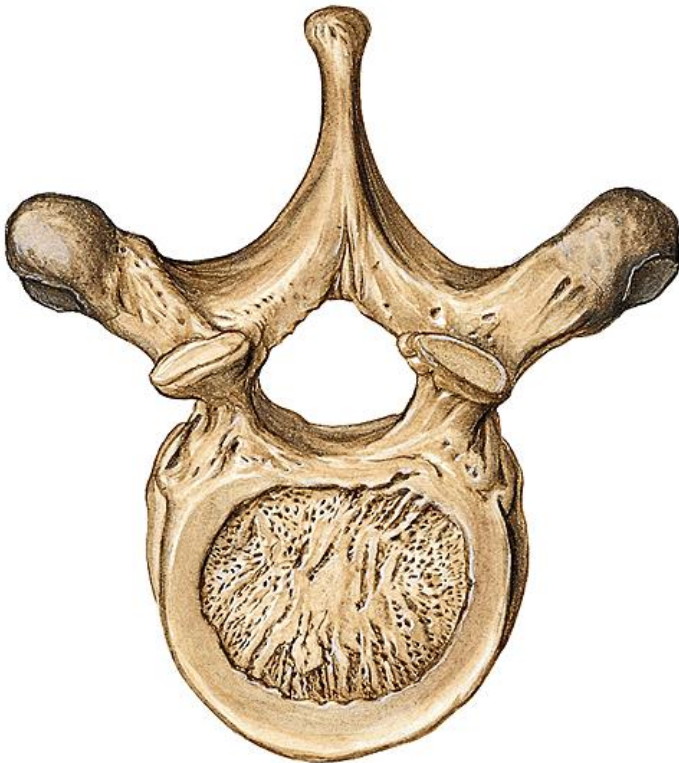
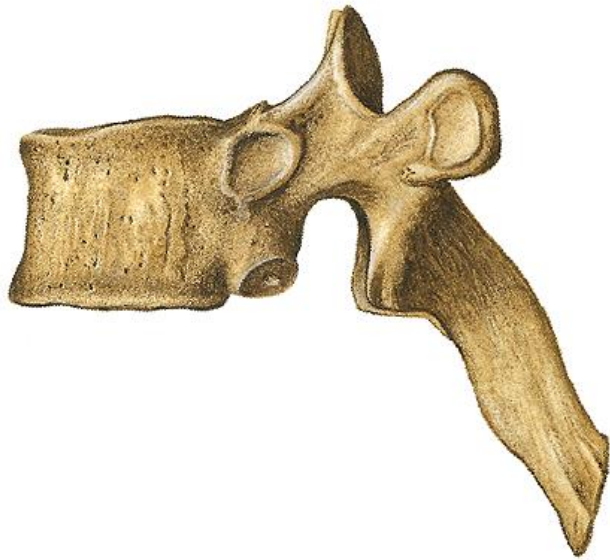


Vertebra (*Vertebra*)

- corpus vertebrae
- arcus vertebrae
 - pediculus
 - lamina
- foramen vertebrale
- processus spinosus
- processus transversus
- processus articularis

- *epiphysis anularis*





Vertebra

Corpus vertebrae

Facies intervertebralis

Arcus vertebrae

Pediculus arcus vertebrae

Lamina arcus vertebrae

Foramen intervertebrale

Incisura vertebralis superior

Incisura vertebralis inferior

Foramen vertebrale

Processus spinosus

Processus transversus

Processus articularis superior;
Zygapophysis superior

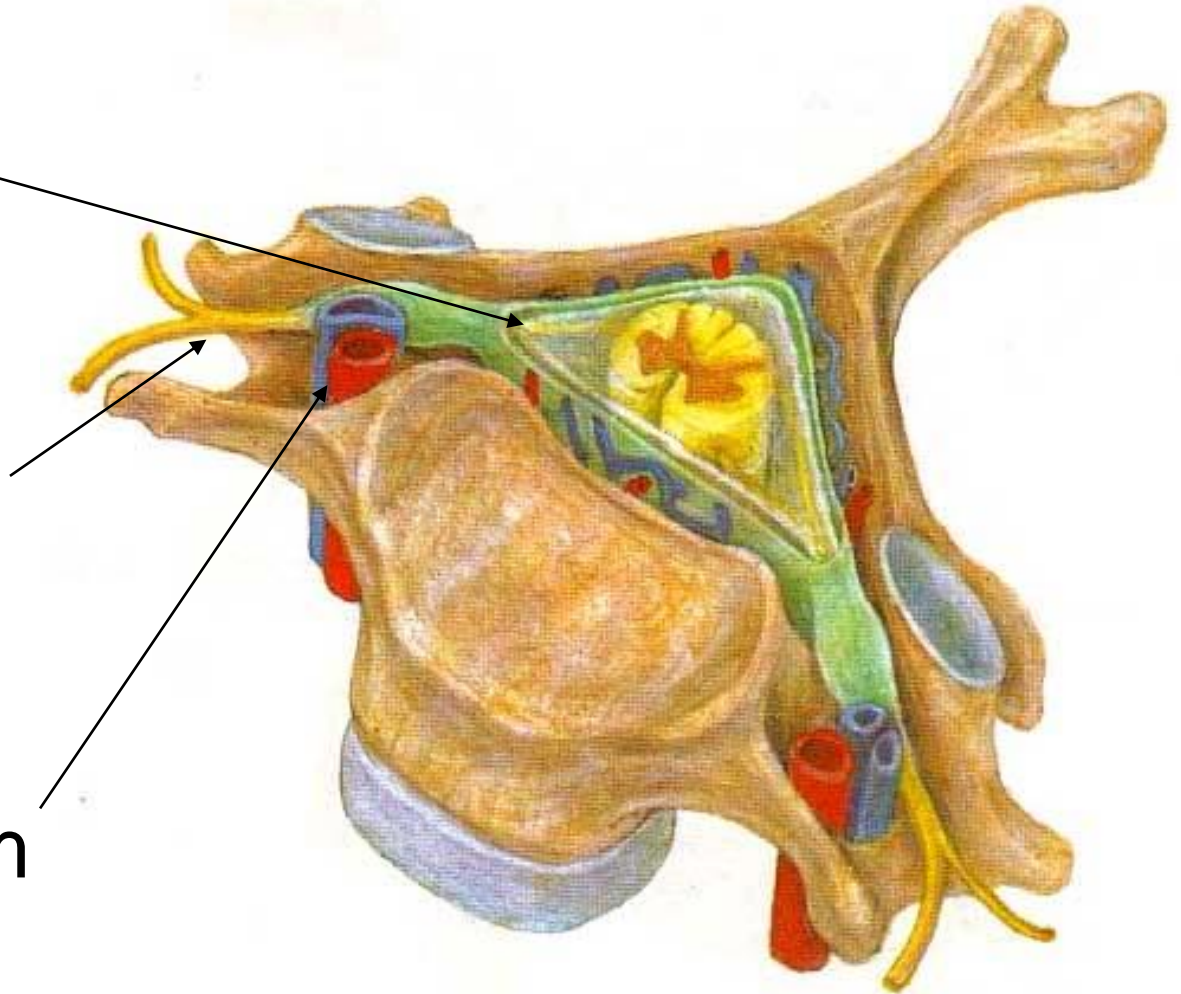
Facies articularis superior

Processus articularis inferior;
Zygapophysis inferior

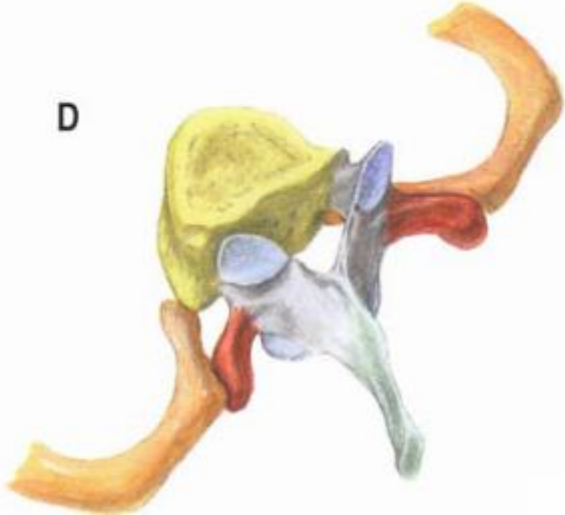
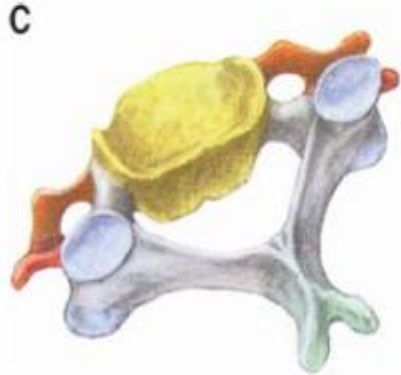
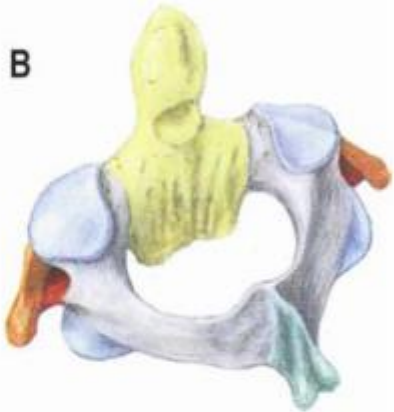
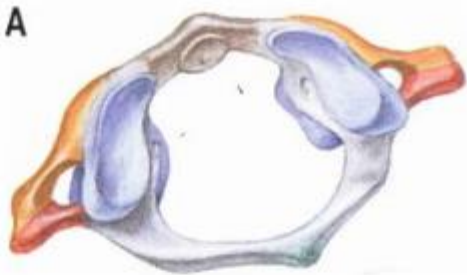
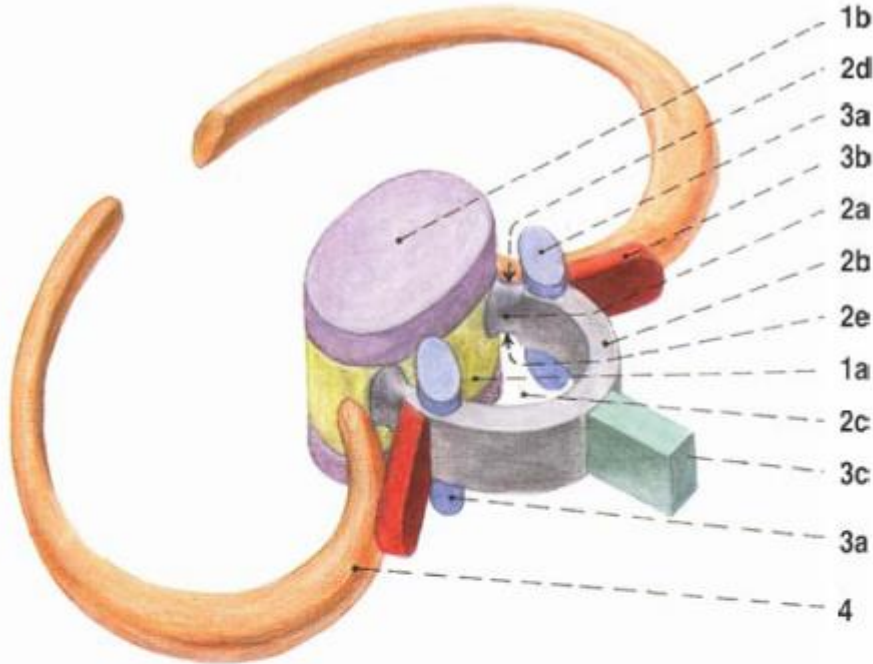
Facies articularis inferior

Vertebrae *topographical site*

- canalis vertebralis
- foramen intervertebrale
- foramen transversarium

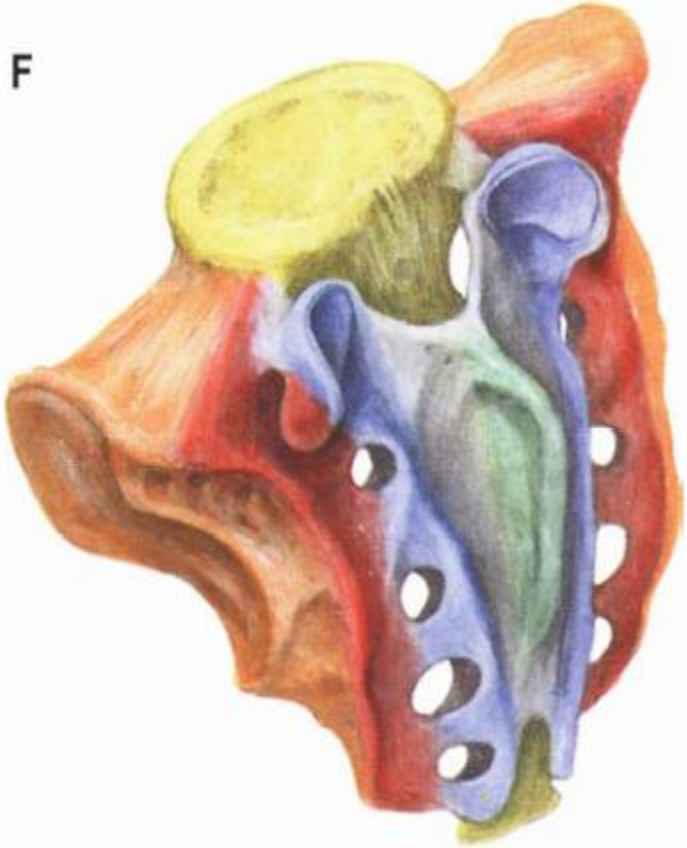


Local differences between vertebrae

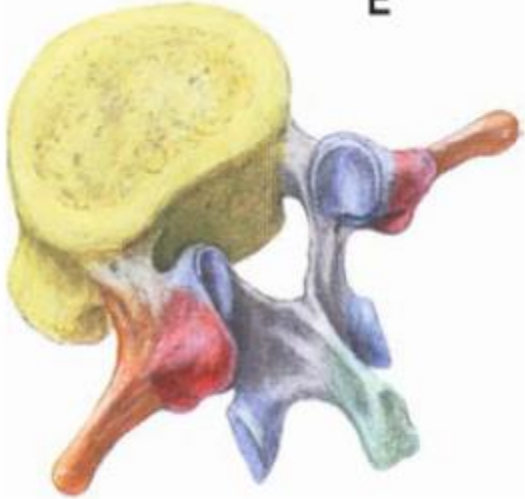


Local differences between vertebrae

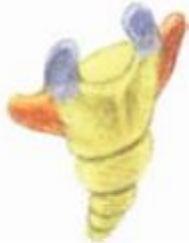F



E

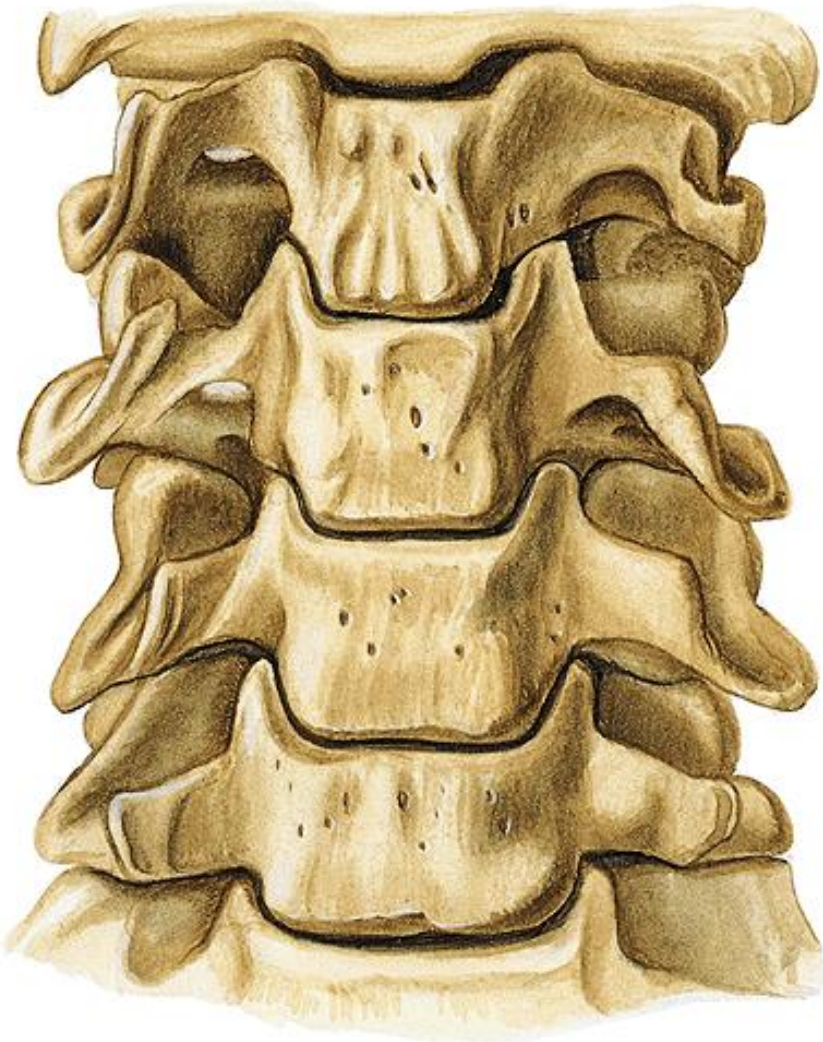

G

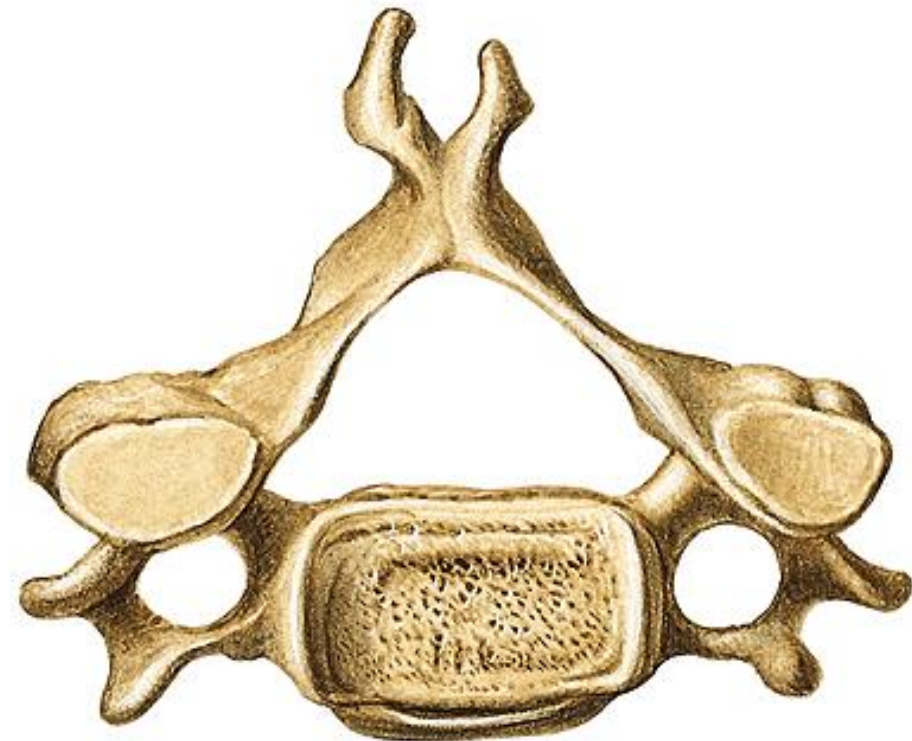


Cervical vertebrae (*Vertebrae cervicales*)

CI – CVII

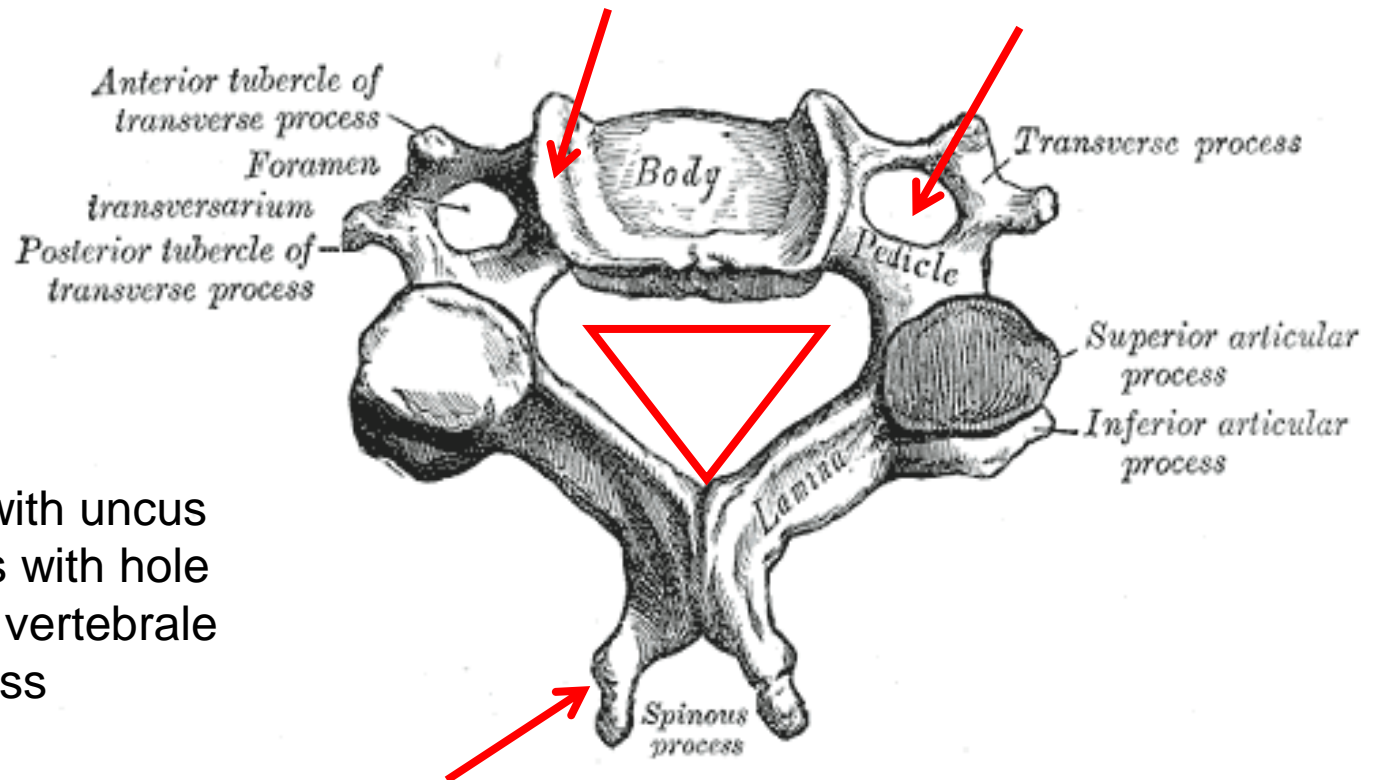


Uncus corporis; Processus uncinatus
Foramen transversarium
Tuberculum anterius
Tuberculum caroticum
Tuberculum posterius
Sulcus nervi spinalis



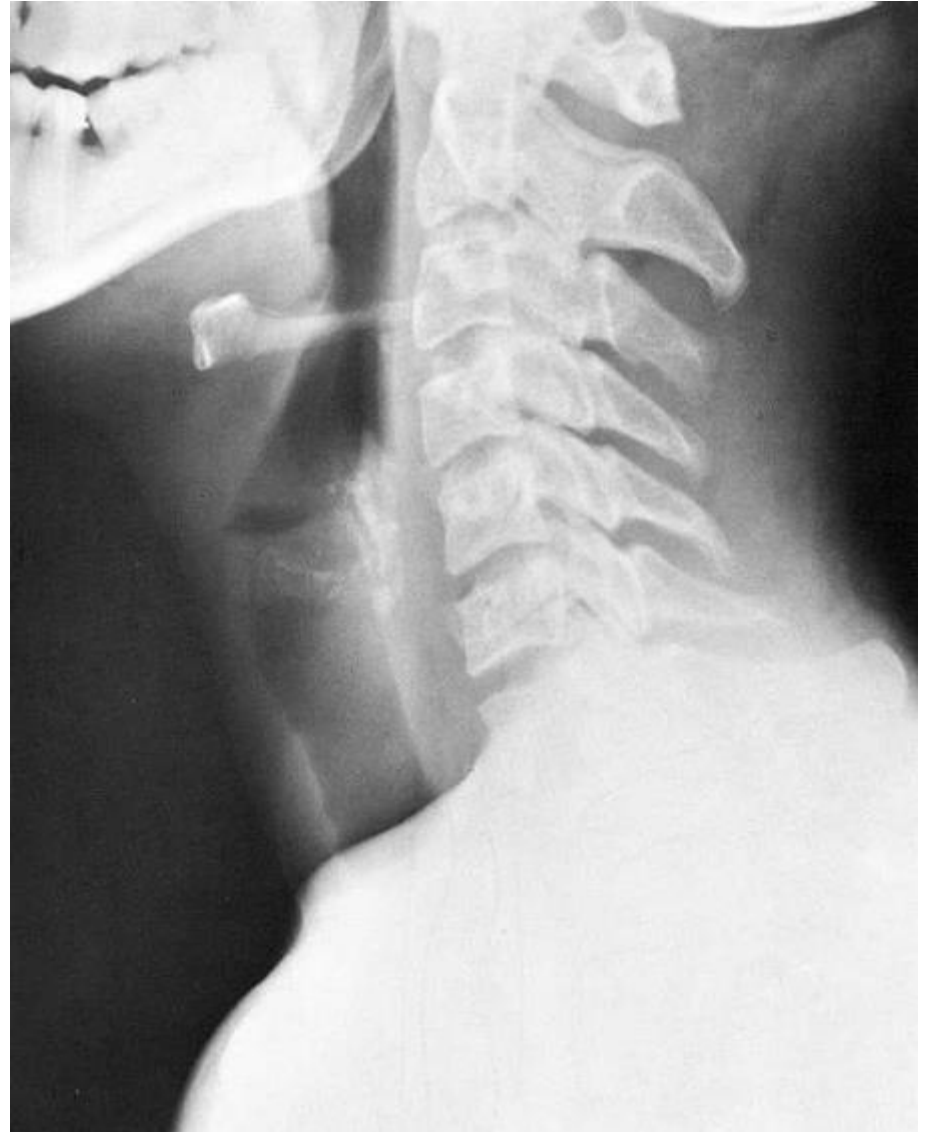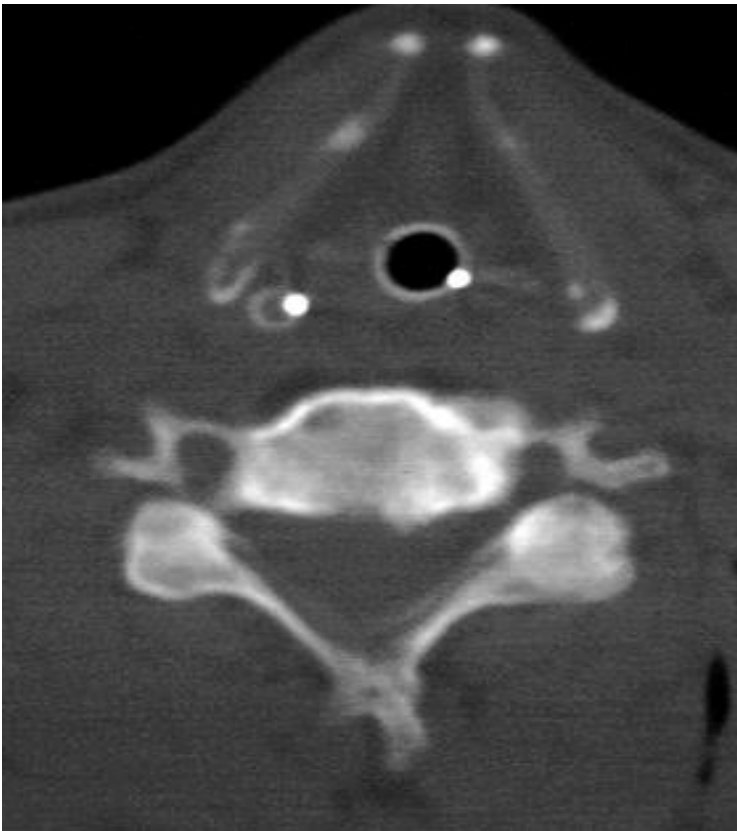
Cervical vertebrae

- ! difference in numbering of vertebrae and spinal nerves !
 - vertebrae C1-CVII
 - spinal nerves C1-C8

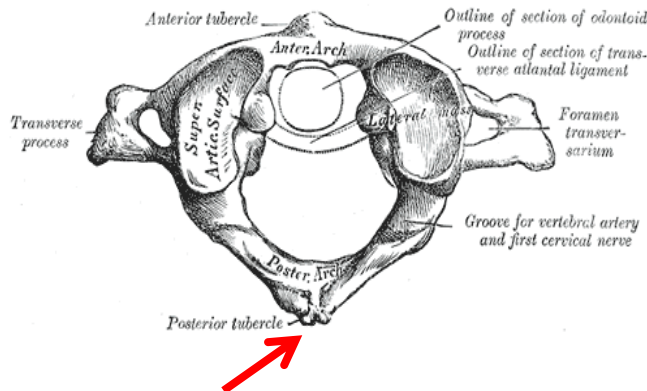
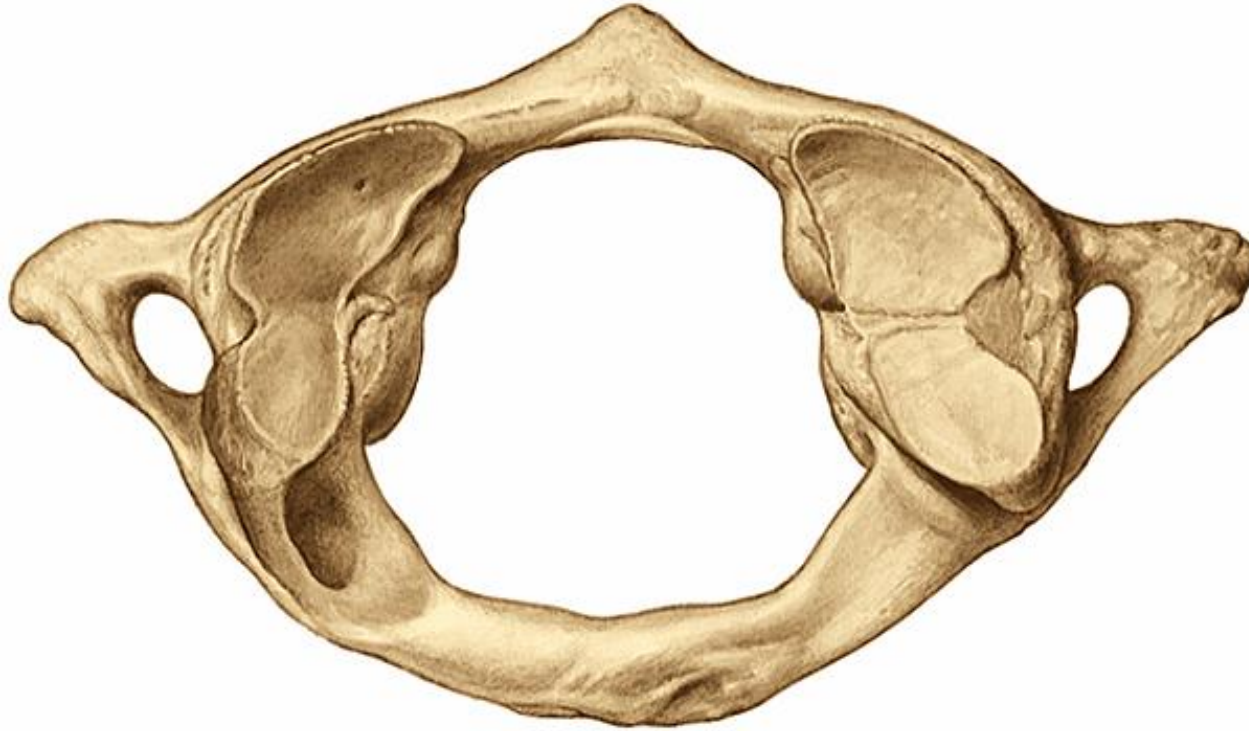

- small round body with uncus
- transverse process with hole
- triangular foramen vertebrale
- split spinous process

Vertebra cervicalis



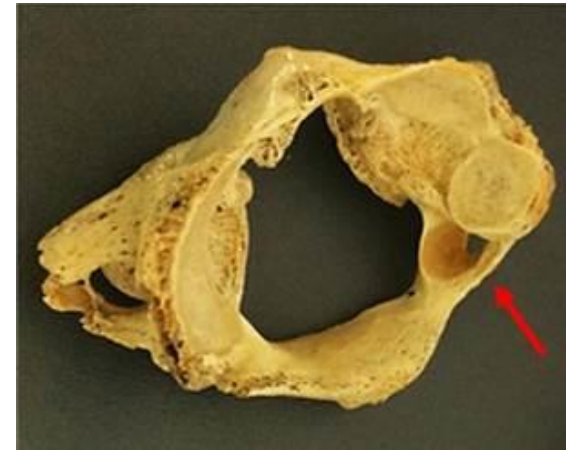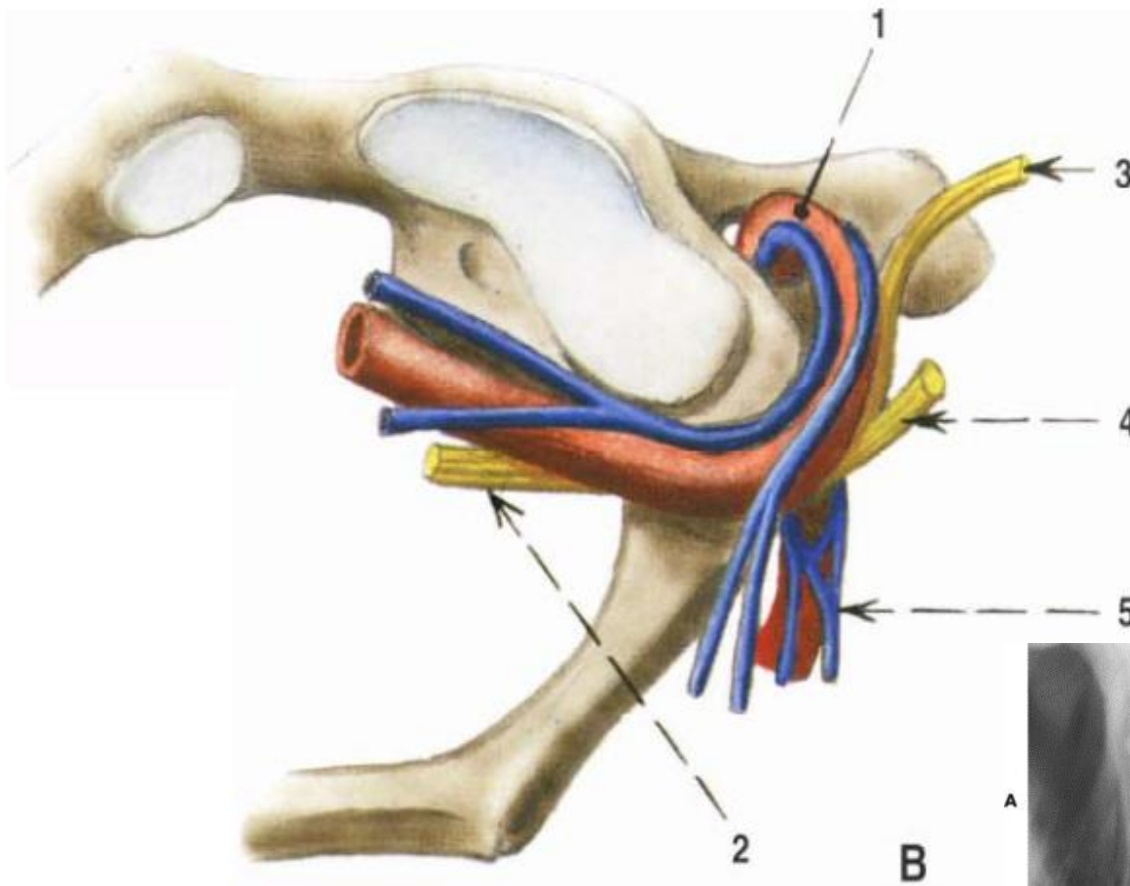
Atlas = Atlas (C1)



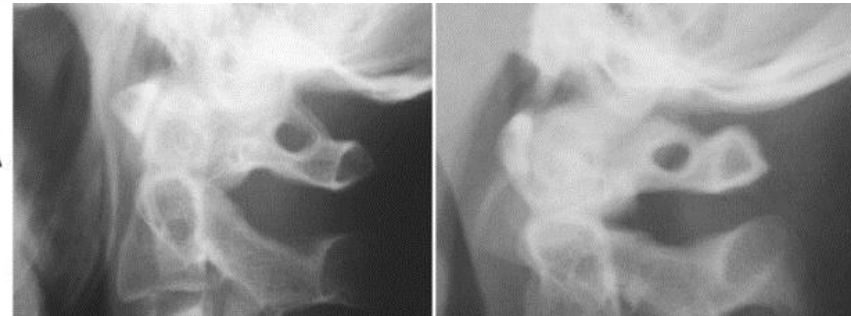Massa lateralis atlantis
Facies articularis superior
Facies articularis inferior
Arcus anterior atlantis
Fovea dentis
Tuberculum anterius
Arcus posterior atlantis
Sulcus arteriae vertebralis
(Canalis arteriae vertebralis)
Tuberculum posterius

Atlas

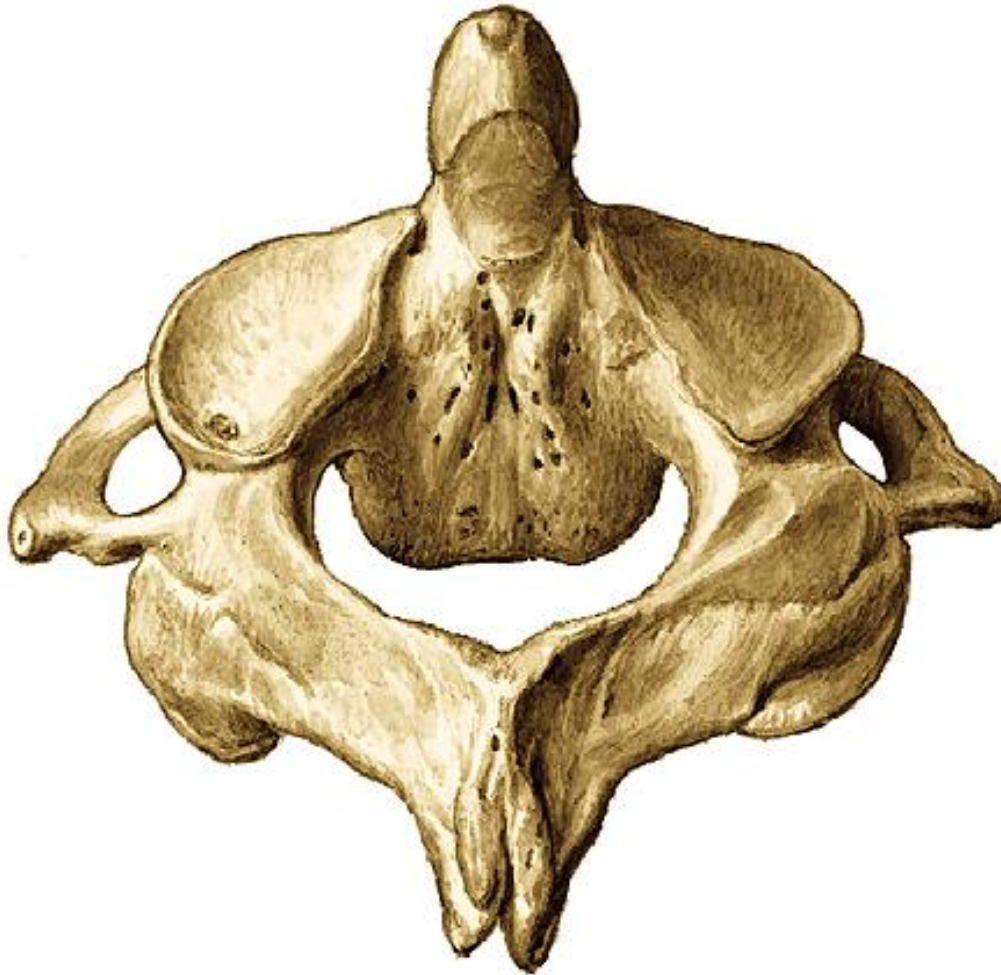
- course of a. vertebralis within *sulcus arteriae vertebralis*



**Canalis arteriae vertebralis
variae v 10 %**



Axis = Axis (CII) formerly „epistropheus“

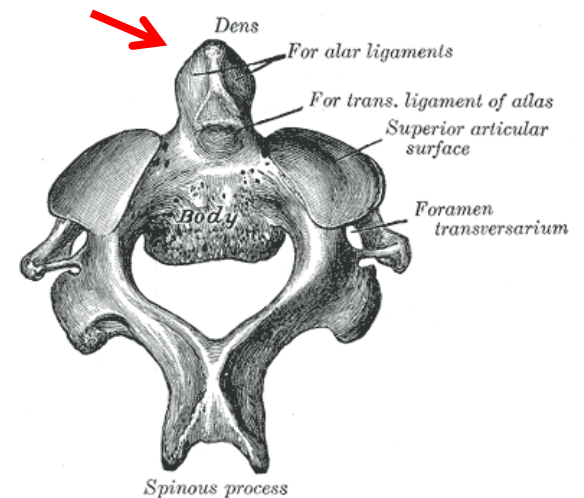


Dens axis

Apex dentis

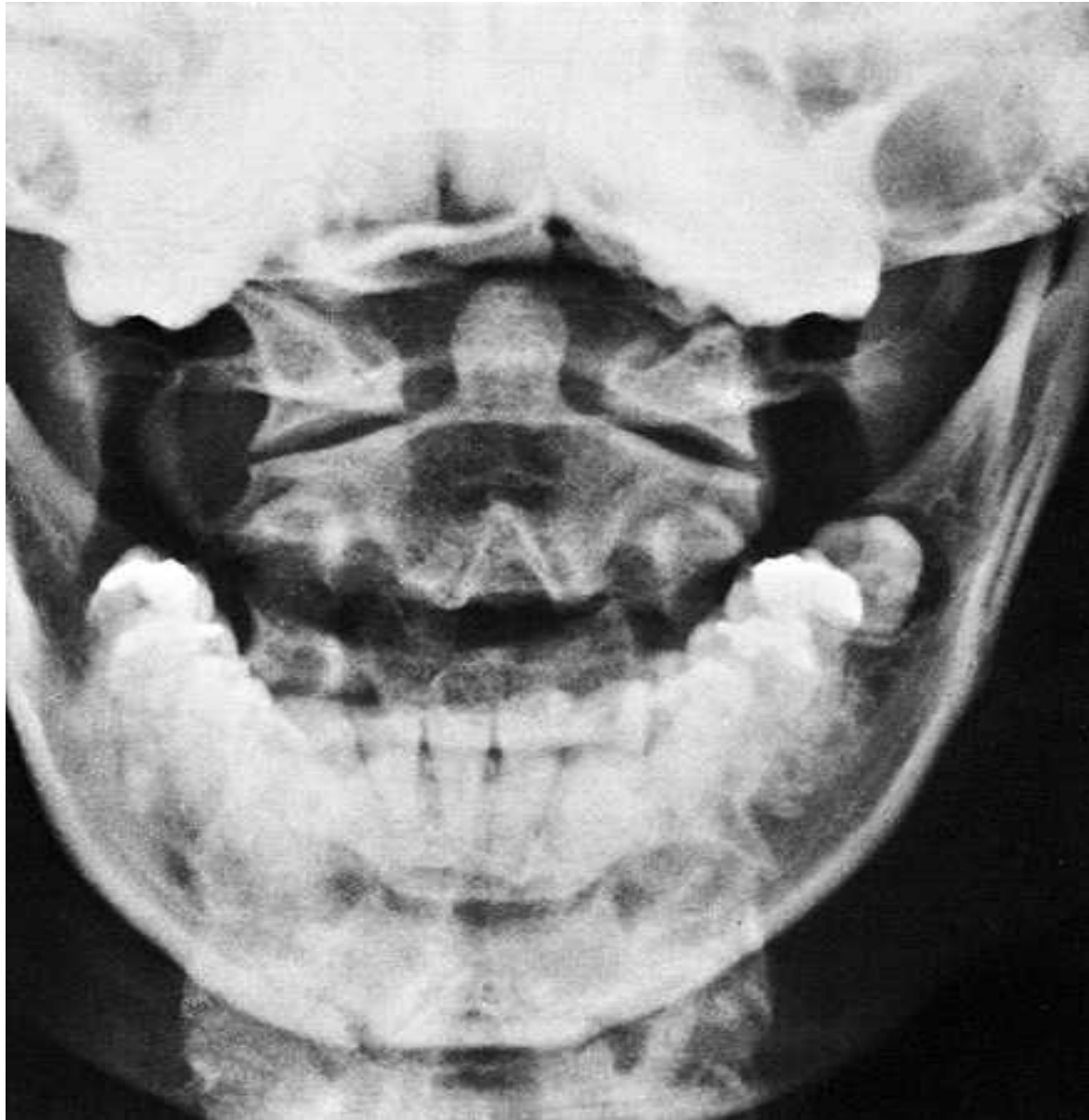
**Facies articularis
anterior**

**Facies articularis
posterior**



X-ray picture of the skull, frontal view

Sandberg's projection with opened mouth to show dens axis



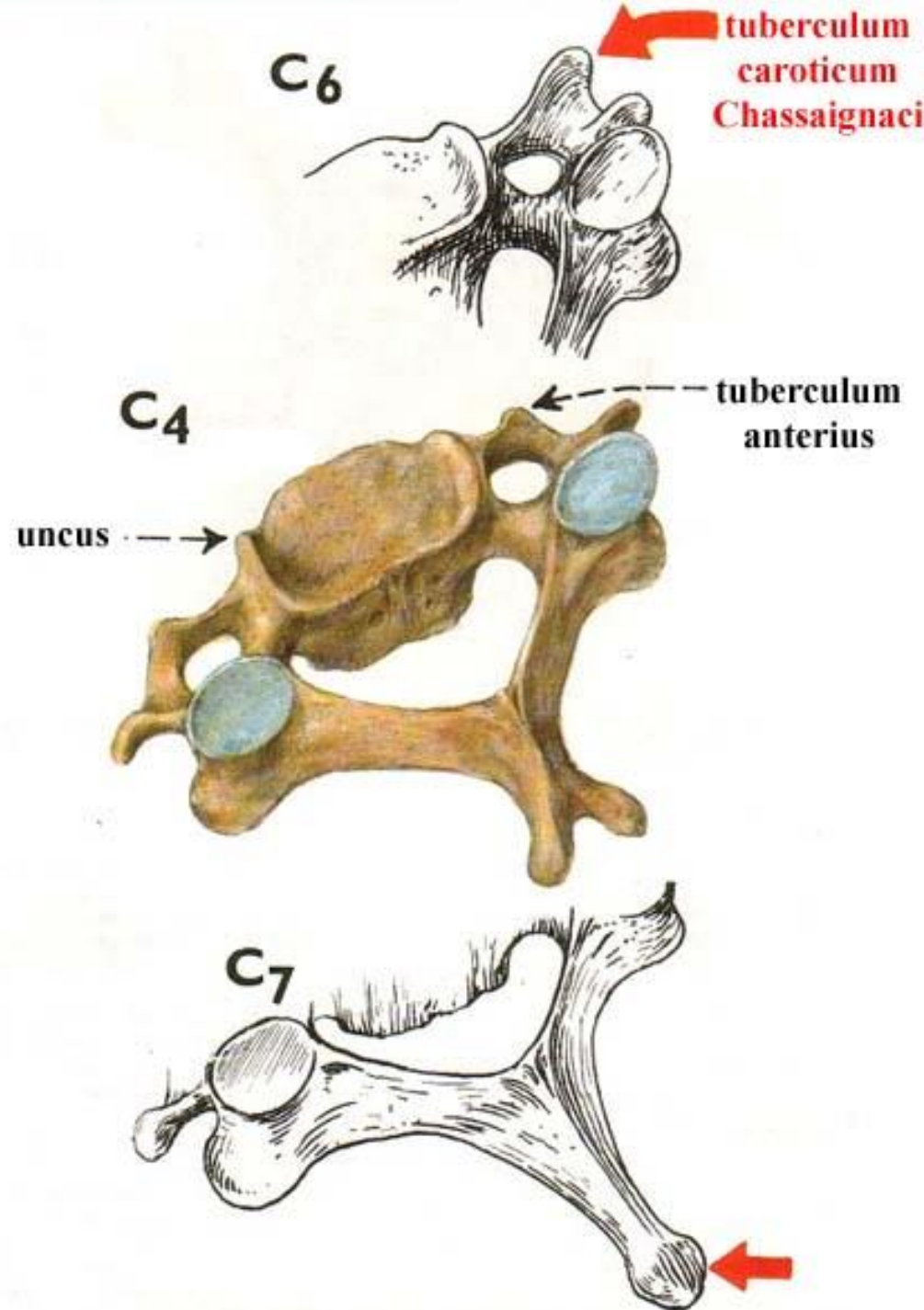
Other vertebrae

- **C VI**

- prominent
tuberculum anterius
= t. **caroticum**
Chassaignaci

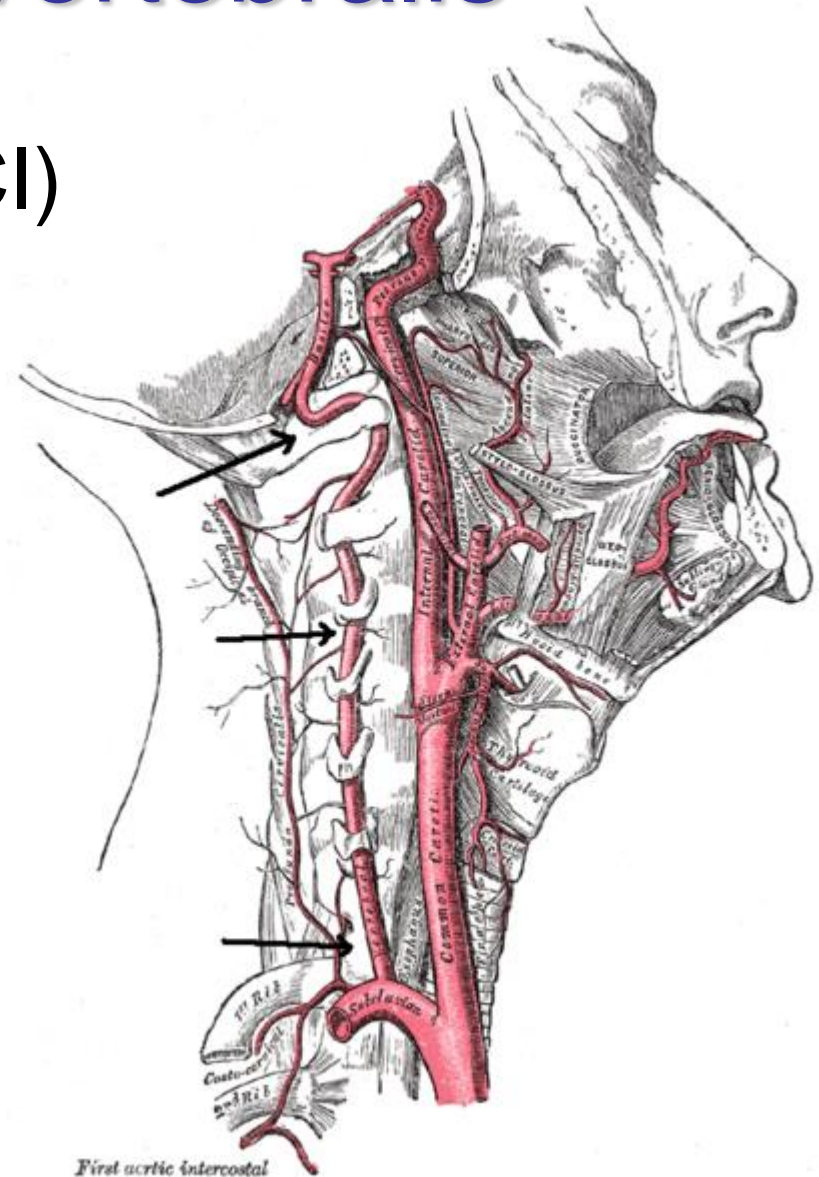
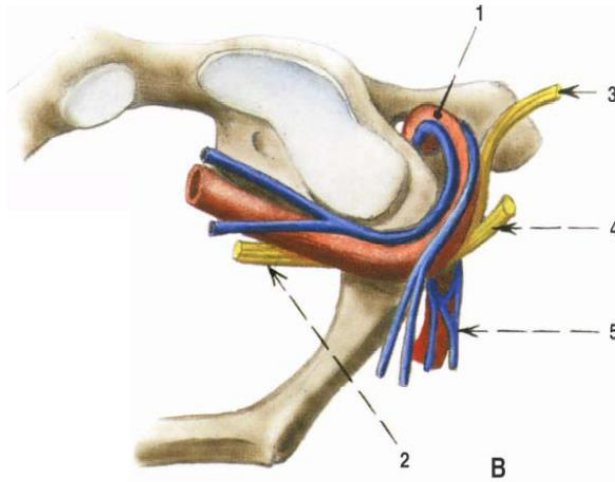
- **C VII**

- prominent
hammer-like
processus spinosus

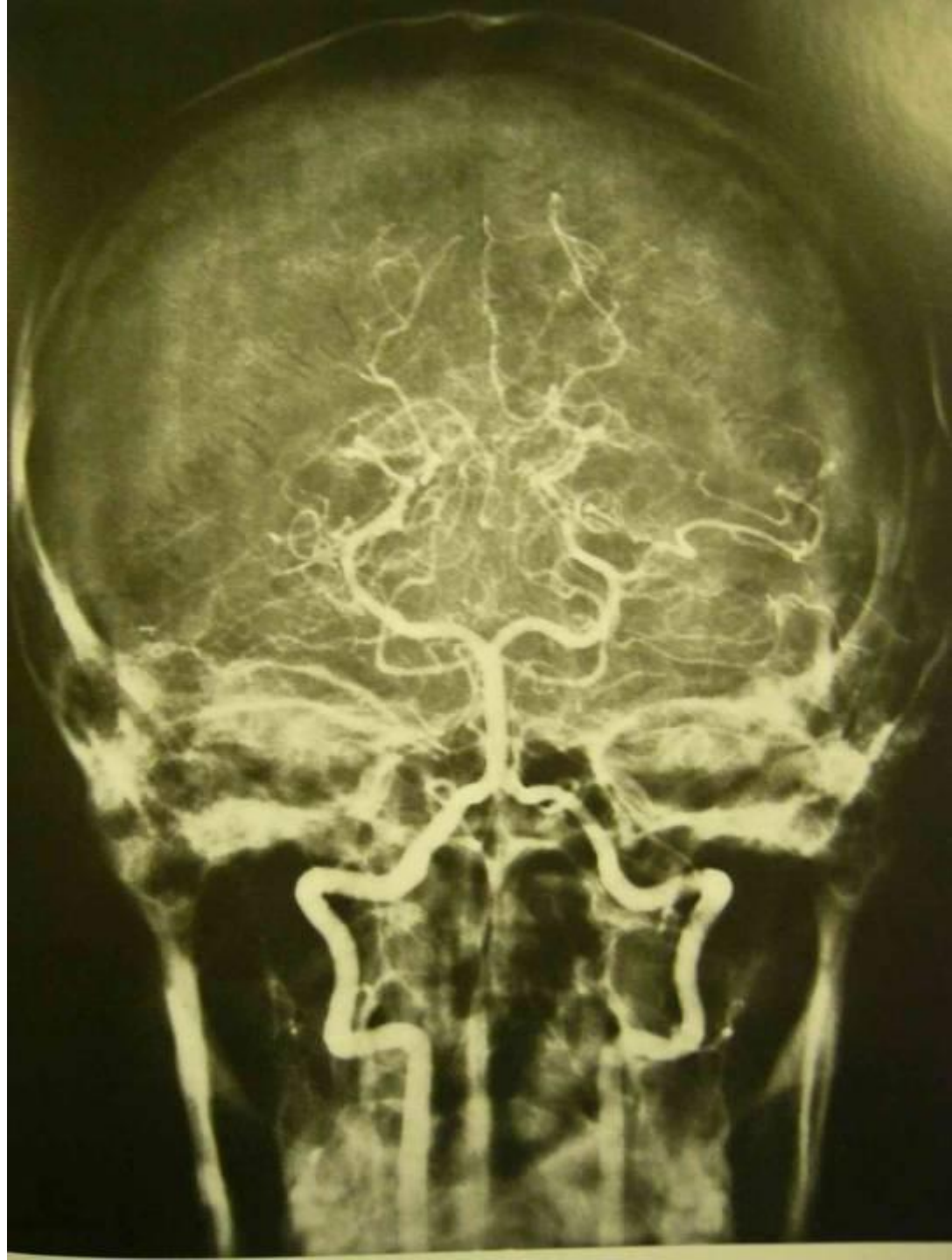

Course of a. vertebralis

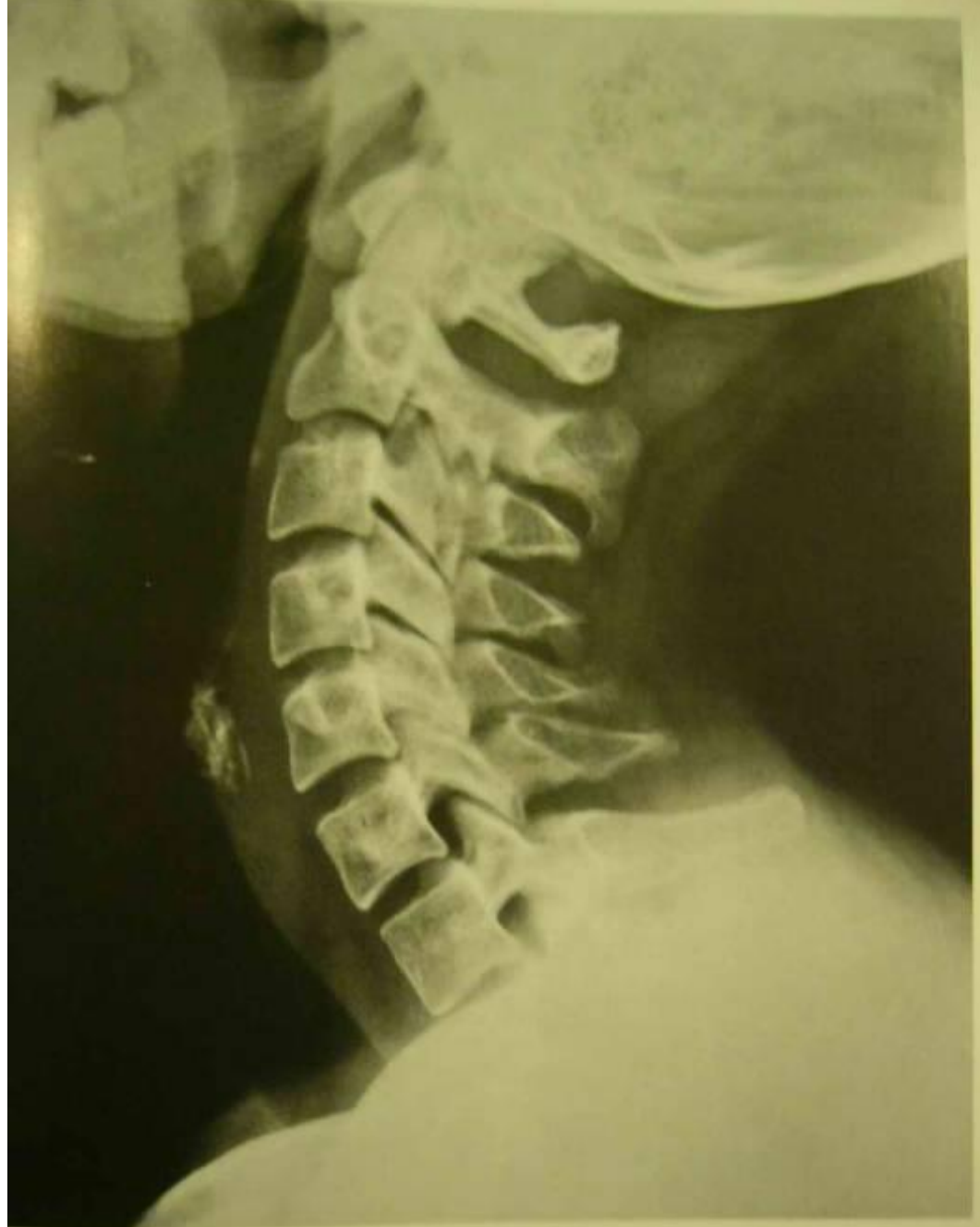- pars cervicalis (CVI→CI)
- pars atlantica (CI)
- „viewing cathedrals“ syndrome



Arteriogram of arteriae vertebrales

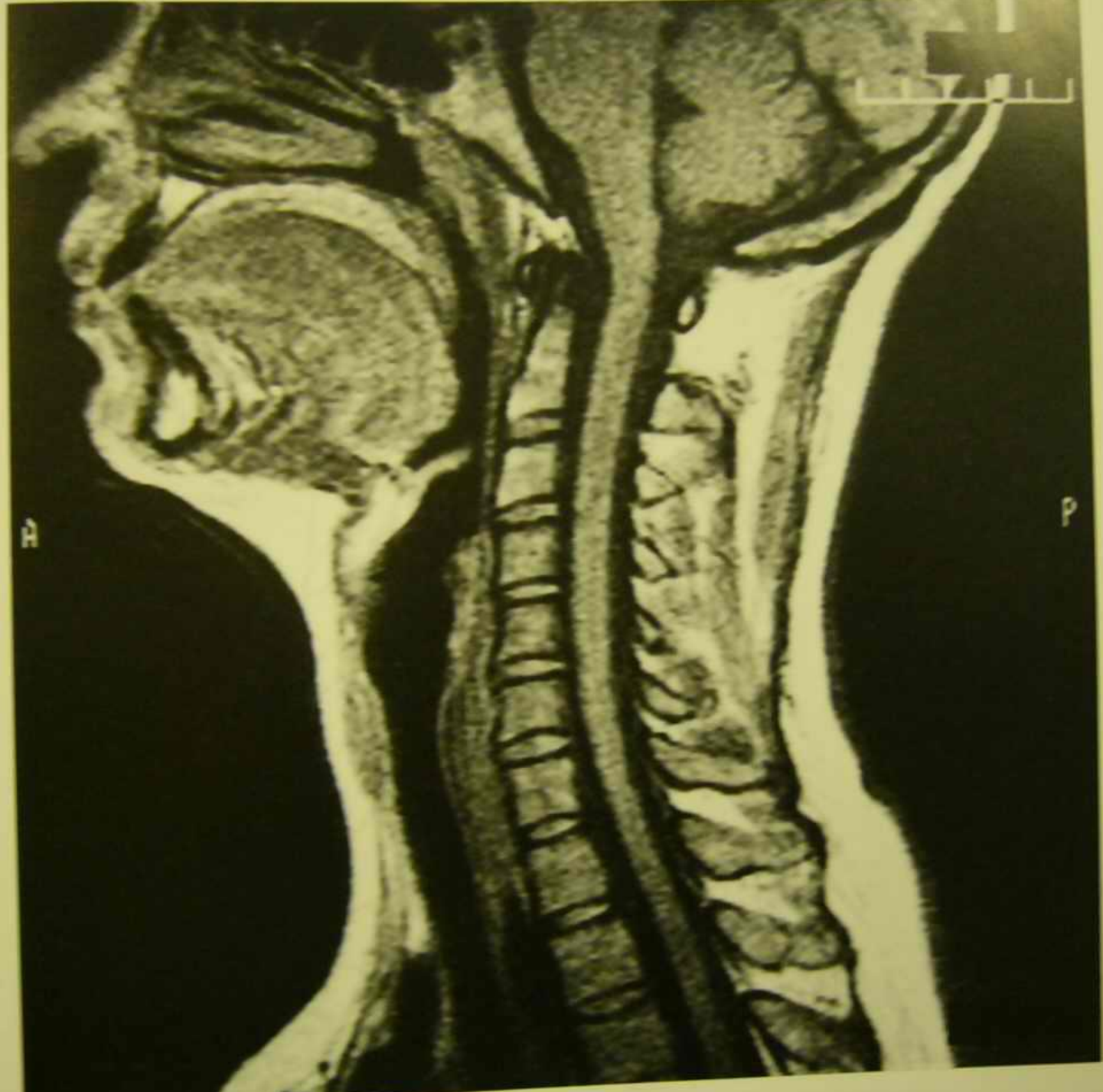

X-ray of cervical vertebrae



28. Halswirbelsäule, seitlich

anterior
anterior
sum
s
C-VII

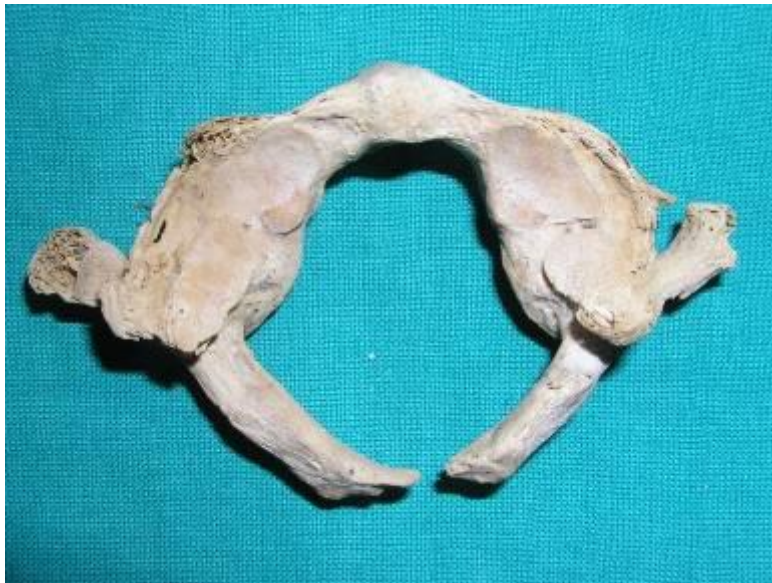

R

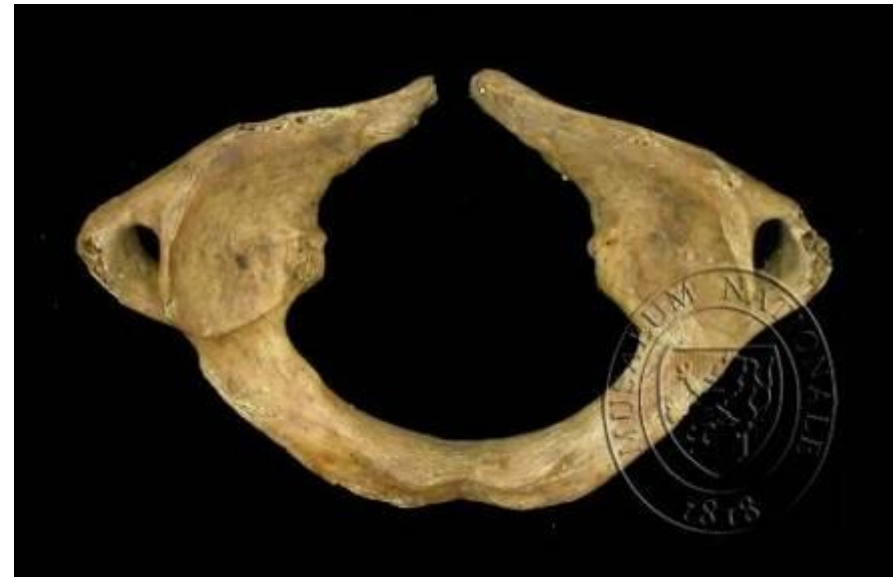P

Developmental defects of cervical vertebral column

spina bifida posterior



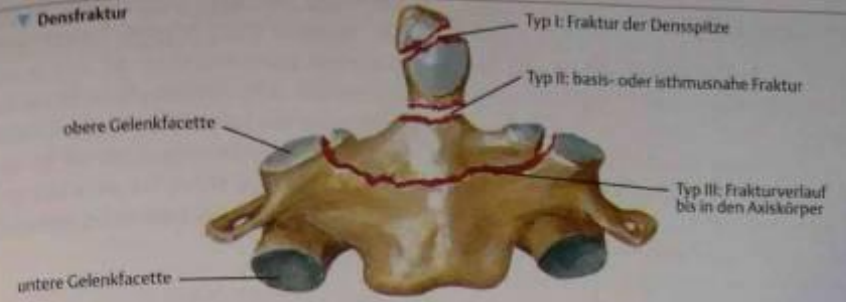
spina bifida anterior



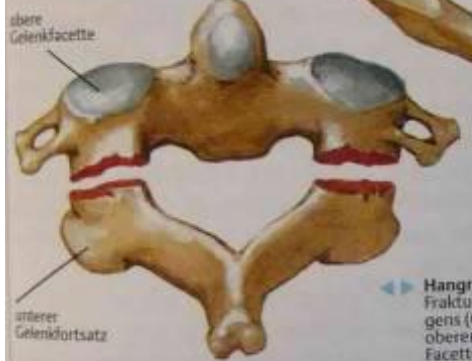
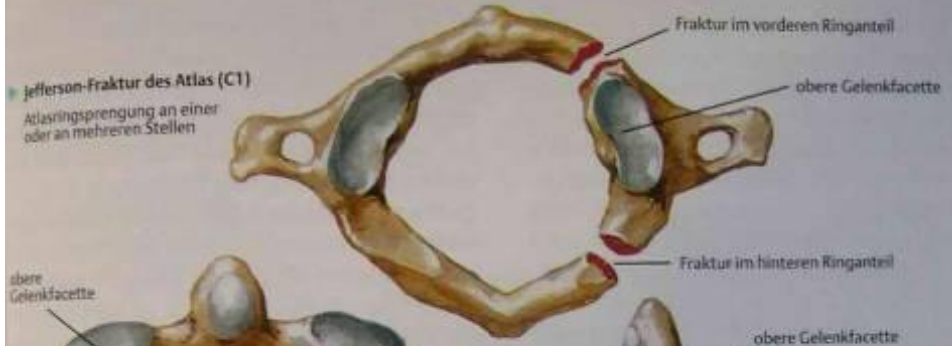Clinical notes

- **fracture of C1** (Jefferson's fracture)
 - reposition from posterior approach
- **fracture of *dens axis***
 - anterior transoral approach (compressive osteosynthesis by two screws)
- *cave*: surrounding structures (cervical neurovascular bundle, *arteria vertebralis*, spinal cord)
- **cervical rib**
 - *variations*, most common in C7 – pressure on surroundings
- cervical segment of vertebral column: upper part C1+2, lower part C3-7

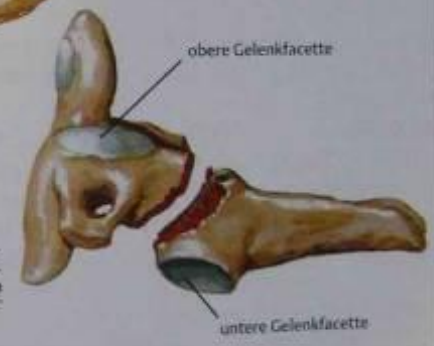
Densfraktur



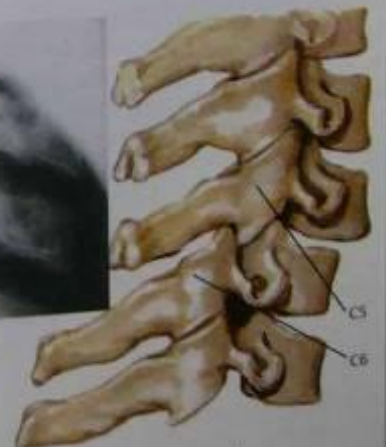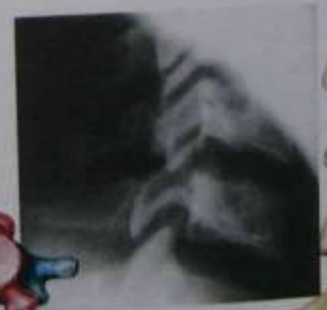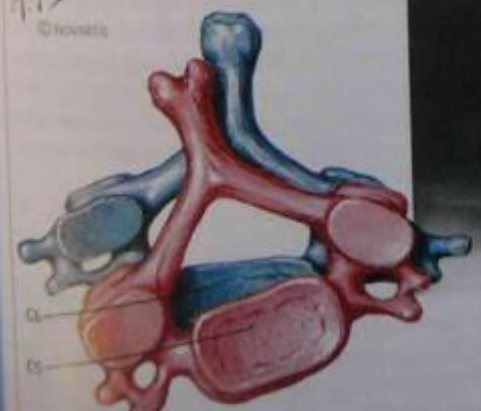
Jefferson-Fraktur des Atlas (C1)
 Atlasringsprengung an einer oder an mehreren Stellen

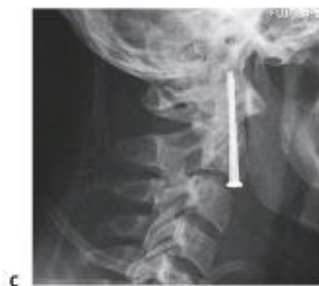
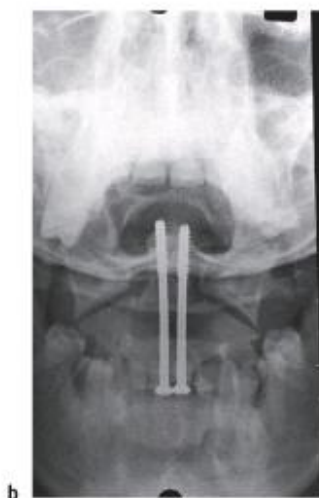
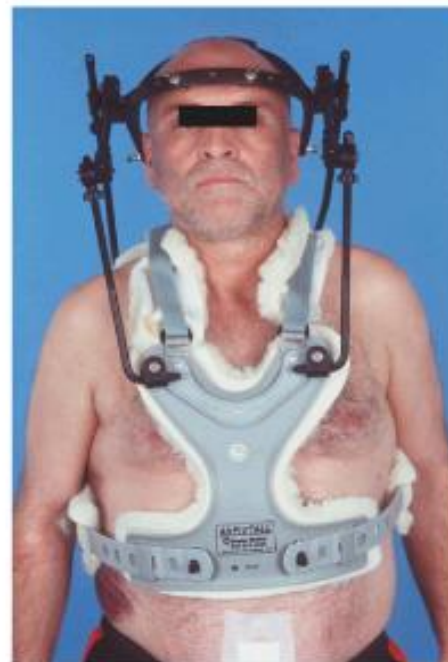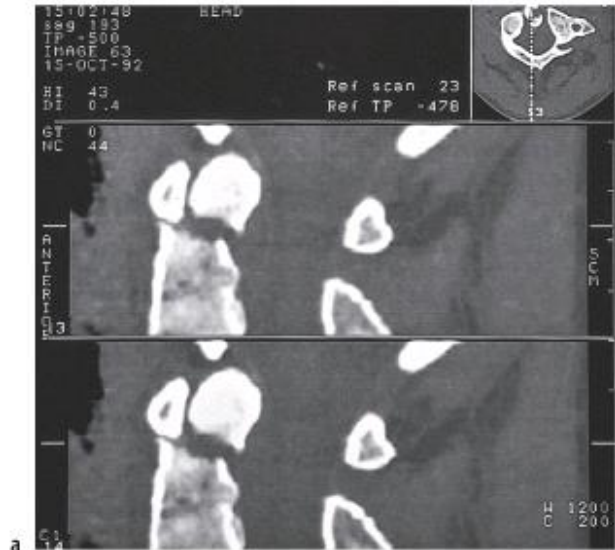Hangman-Fraktur
 Fraktur des Axisbogens (C2) zwischen oberer und unterer Facette

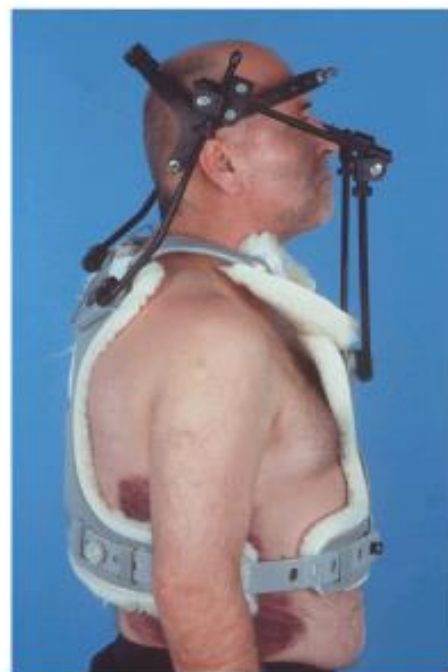

F. Netter
 © Elsevier



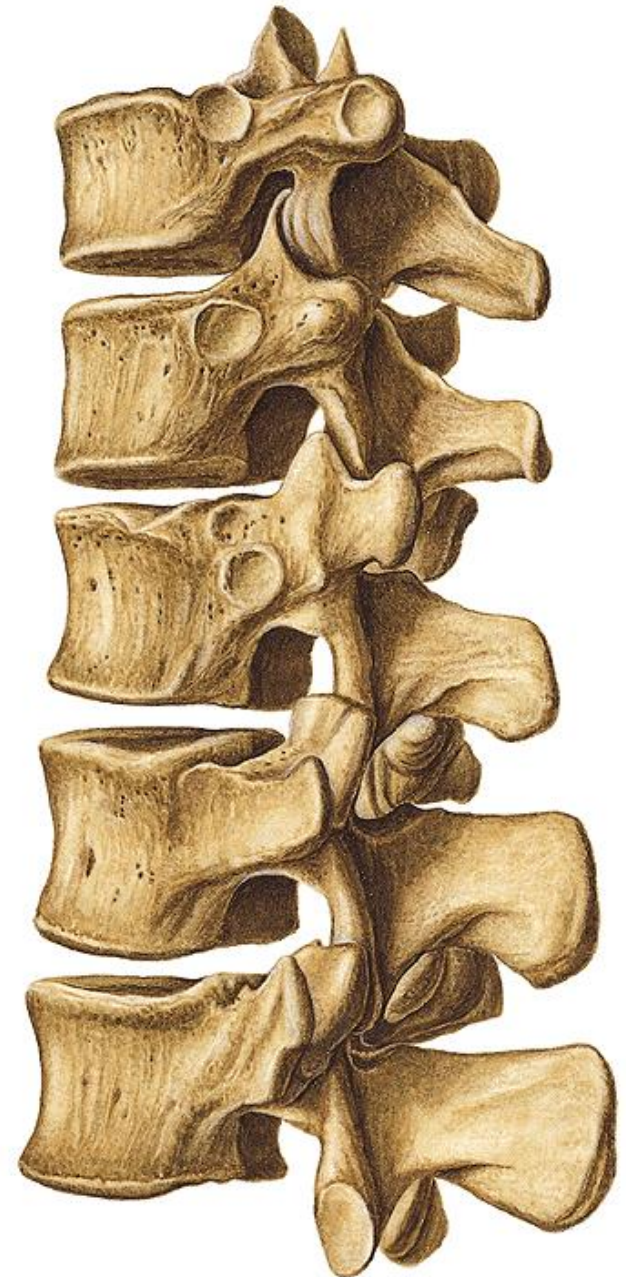
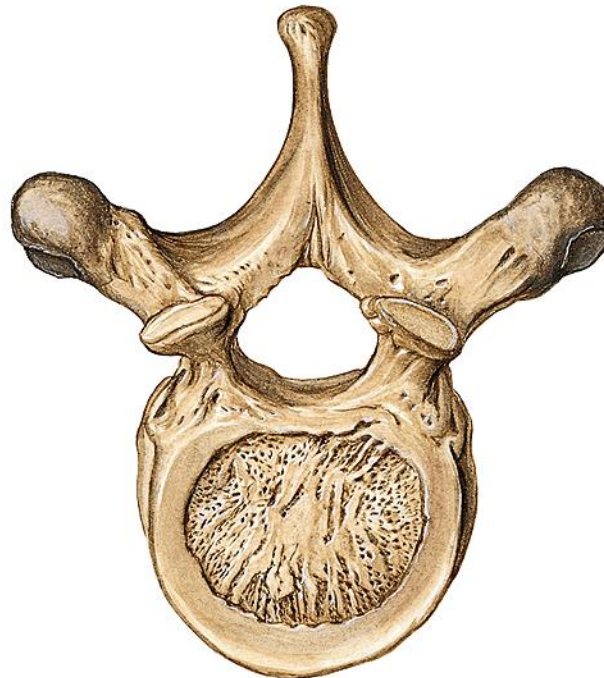
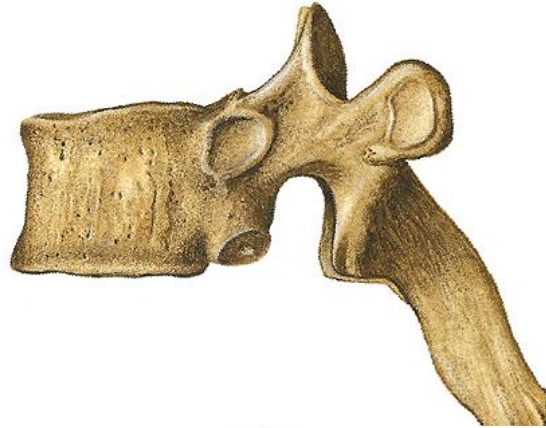

Fracture of dens axis



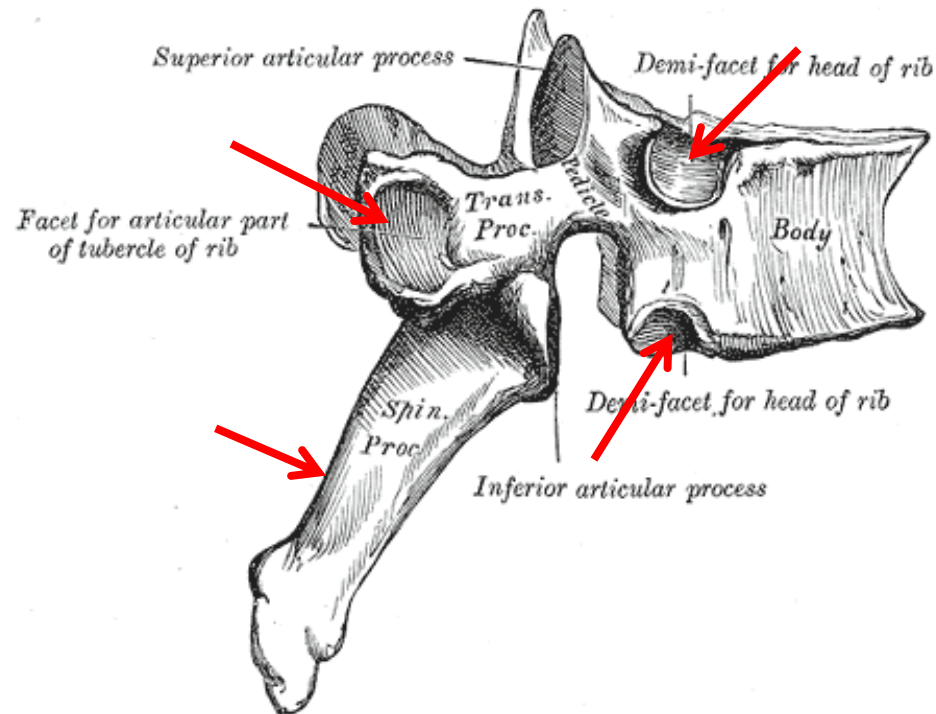
Vertebrae thoracicae

Thoracic vertebra [T I – T XII]
Fovea costalis superior
Fovea costalis inferior
Fovea costalis processus transversi

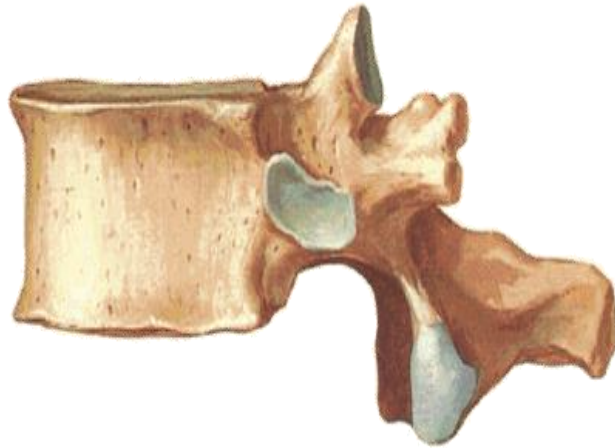


Thoracic vertebra

- T1 – TXII
- articular facets for ribs
- „diagonal“ spinous process

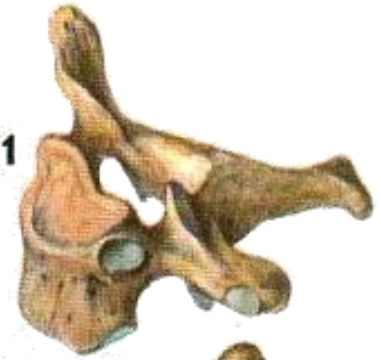

Thoracic vertebra



T12

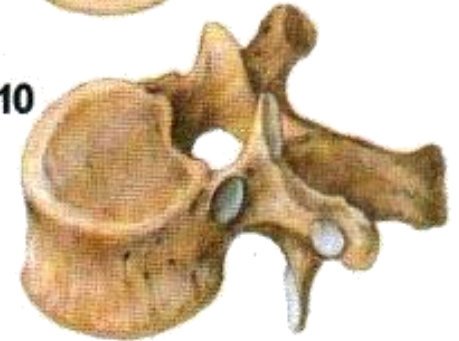Th1



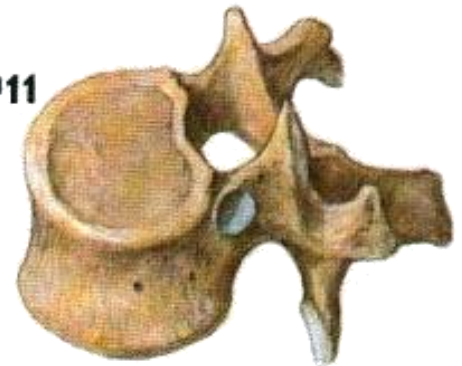Th9



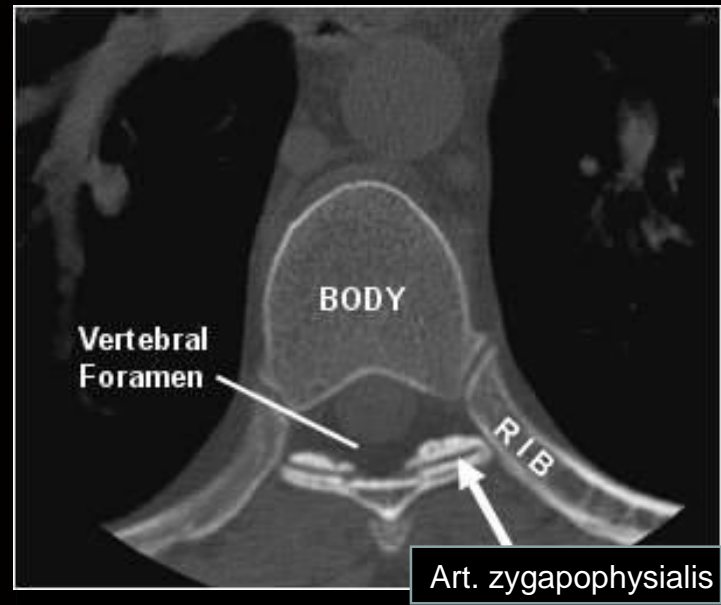
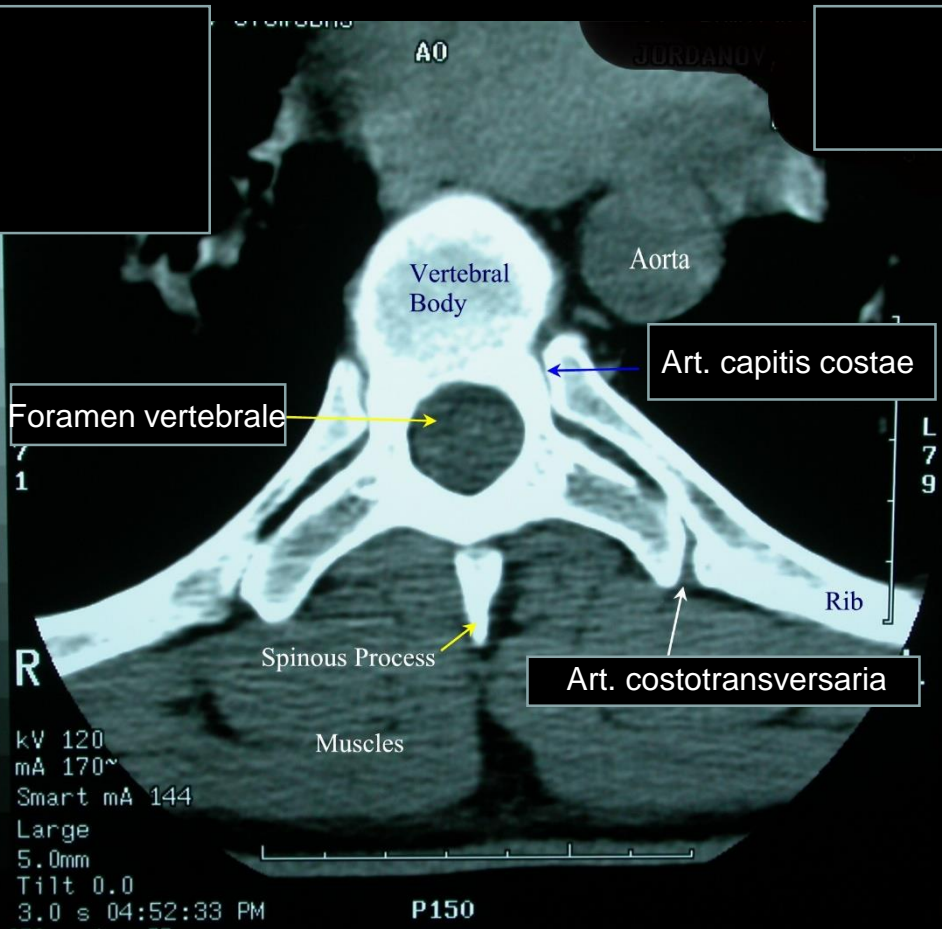
Th10



Th11



CT of thoracic vertebra



X-ray of thoracic vertebrae

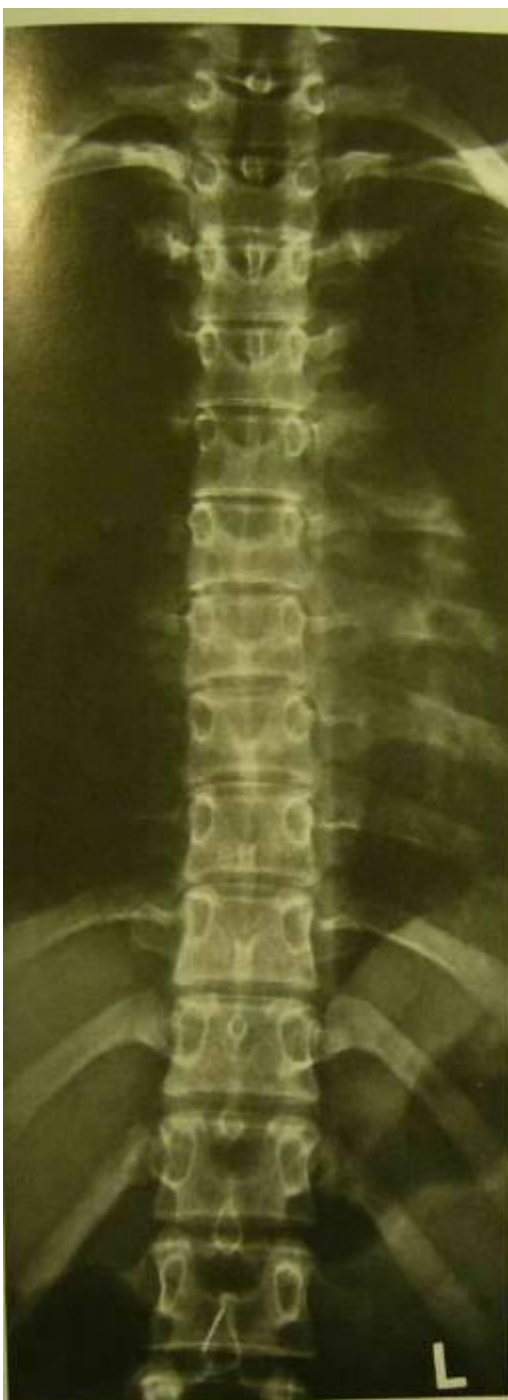

Abb. 32. Brustwirbelsäule a. p.

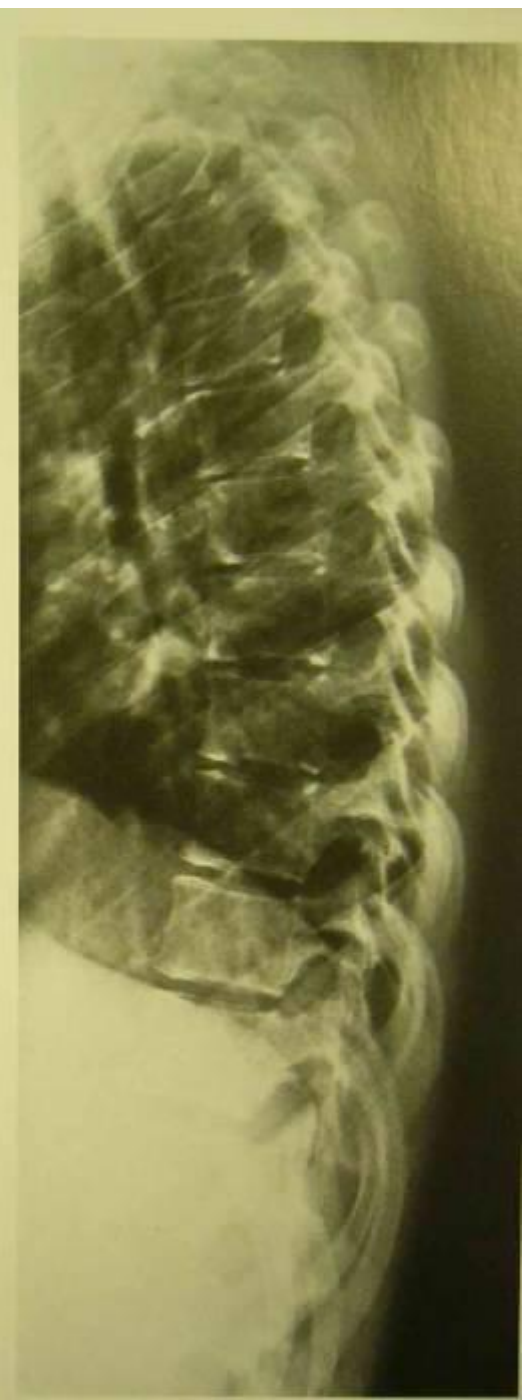
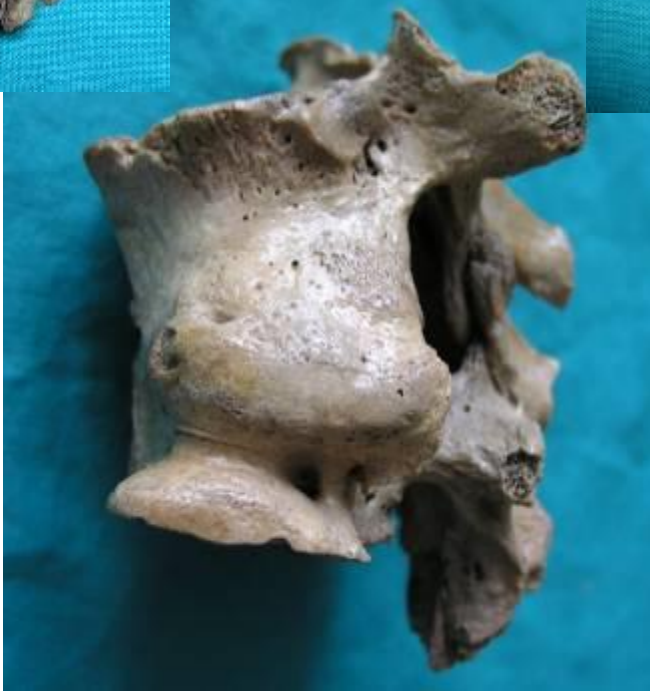
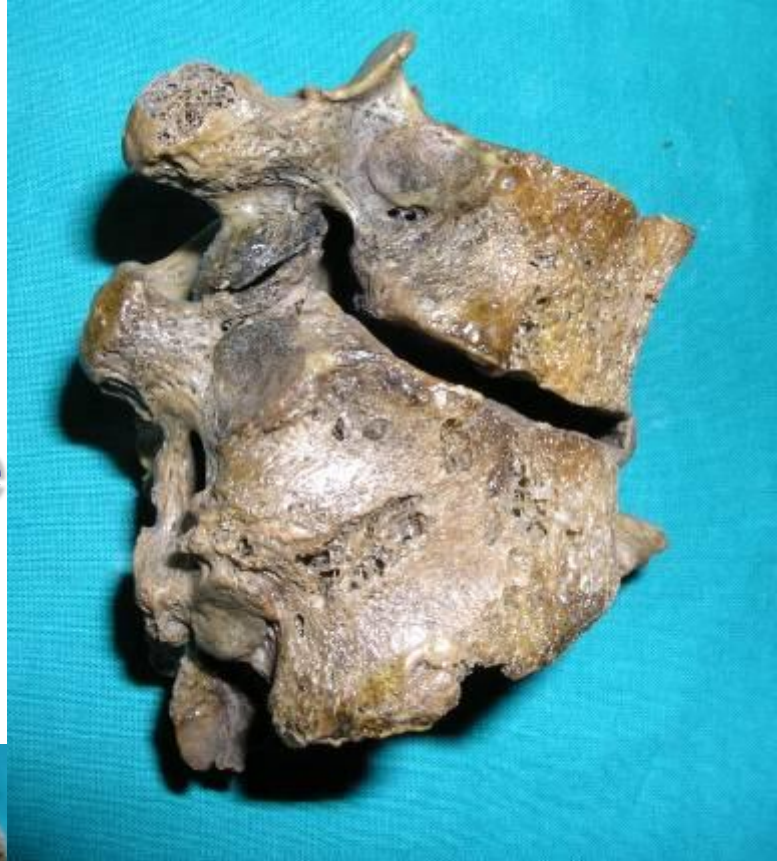
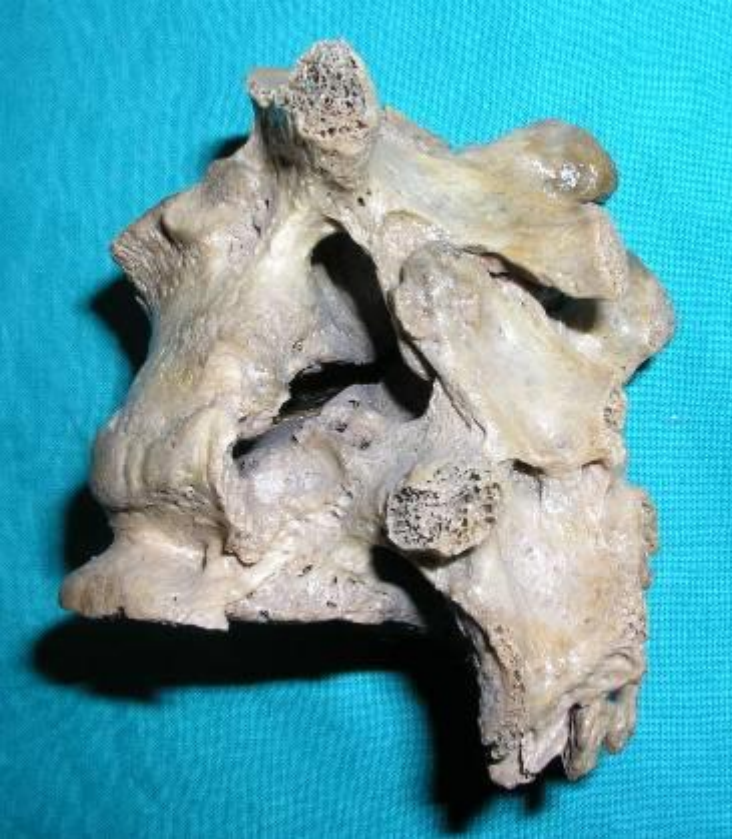Abb. 33. Brustwirbelsäule, seitlich

Fused
thoracic
vertebrae



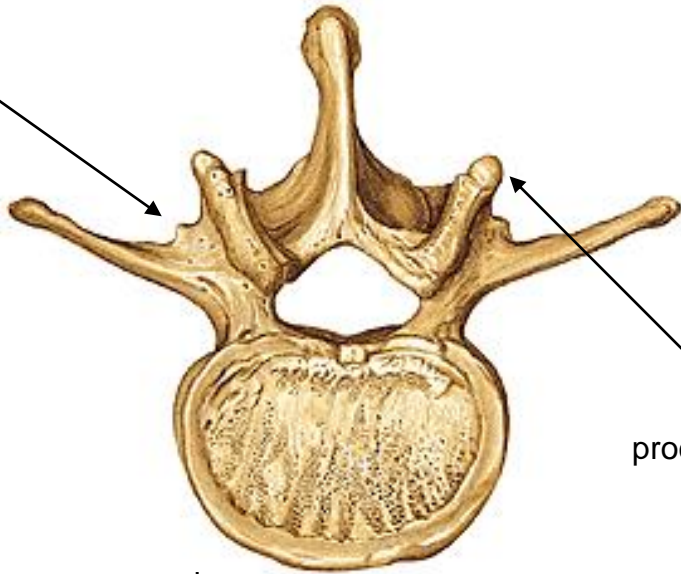
Vertebrae lumbales

Lumbal vertebra [L I - L V]

Processus accessorius
(caudally)

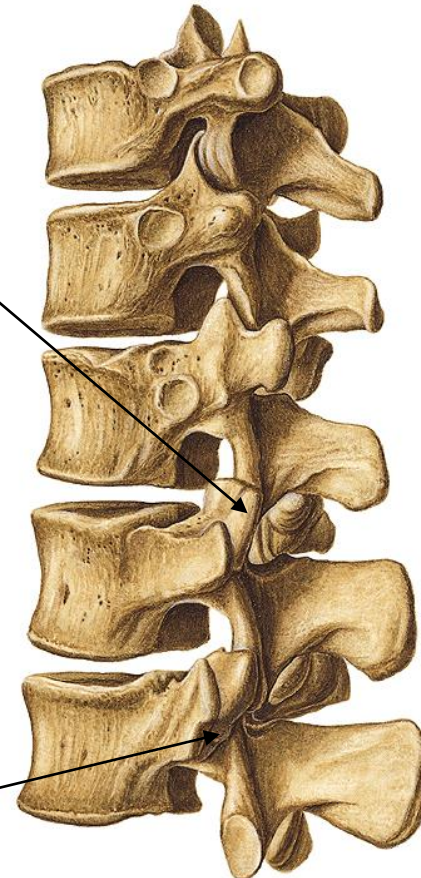
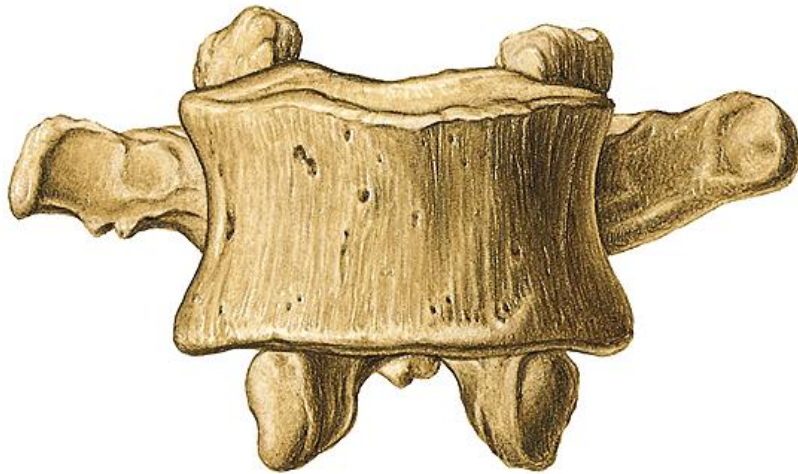Processus costalis (formerly
costarius)

Processus mammillaris
(cranially)



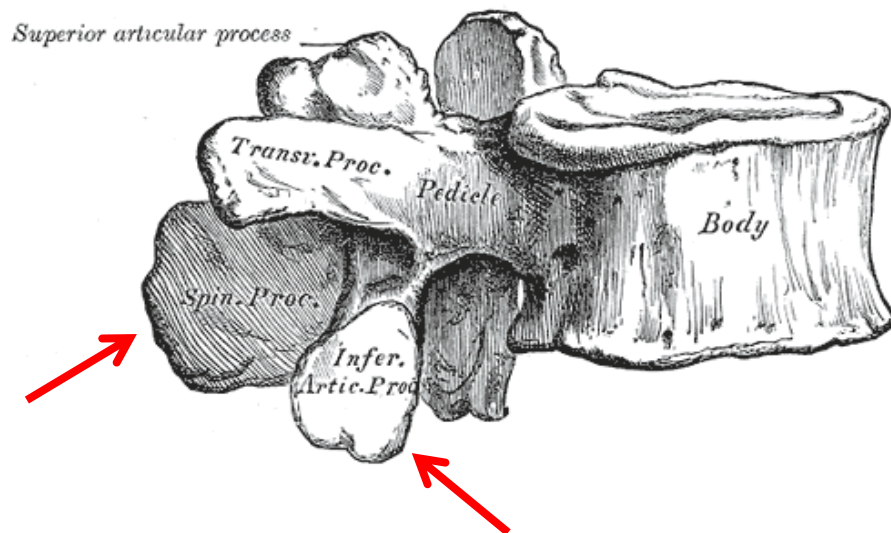
processus mammillaris

processus accessorius

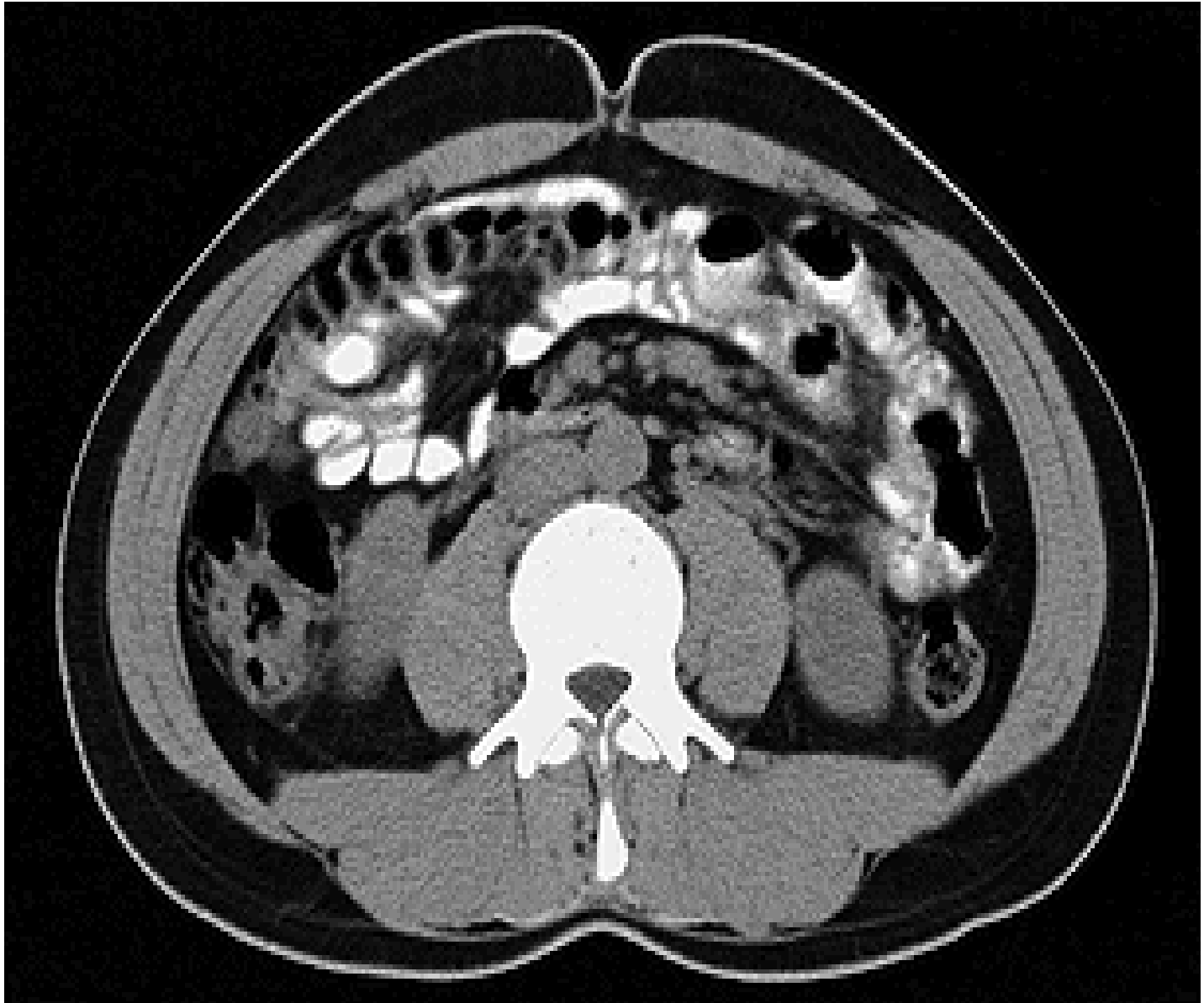


Lumbar vertebra

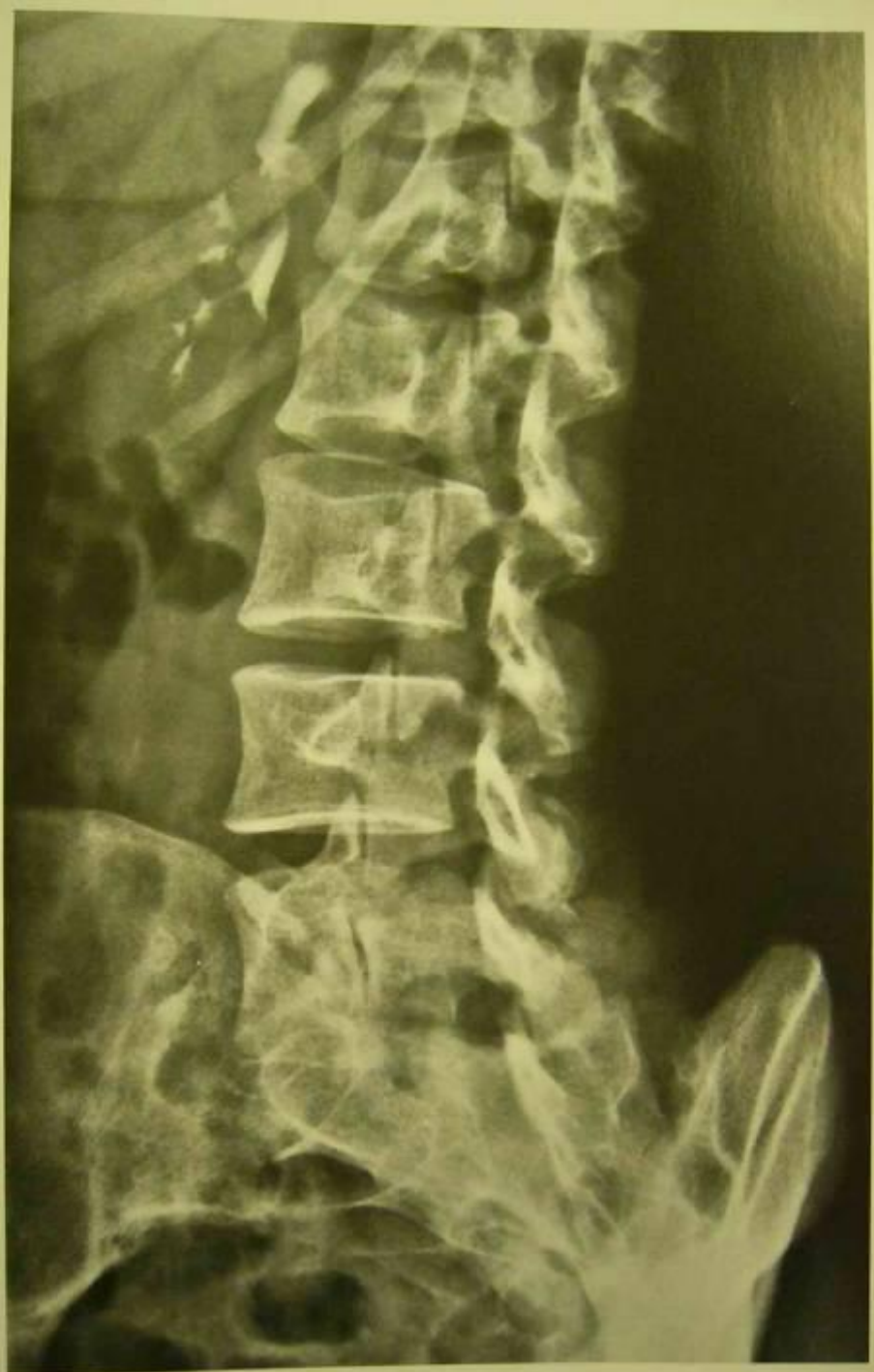- L1 – L5
- flat, wide, quadrangular spinous process
- rather sagittally oriented articulation facets
- triangular vertebral foramen
- big high round body



CT of lumbar vertebra



X-ray of lumbar vertebra

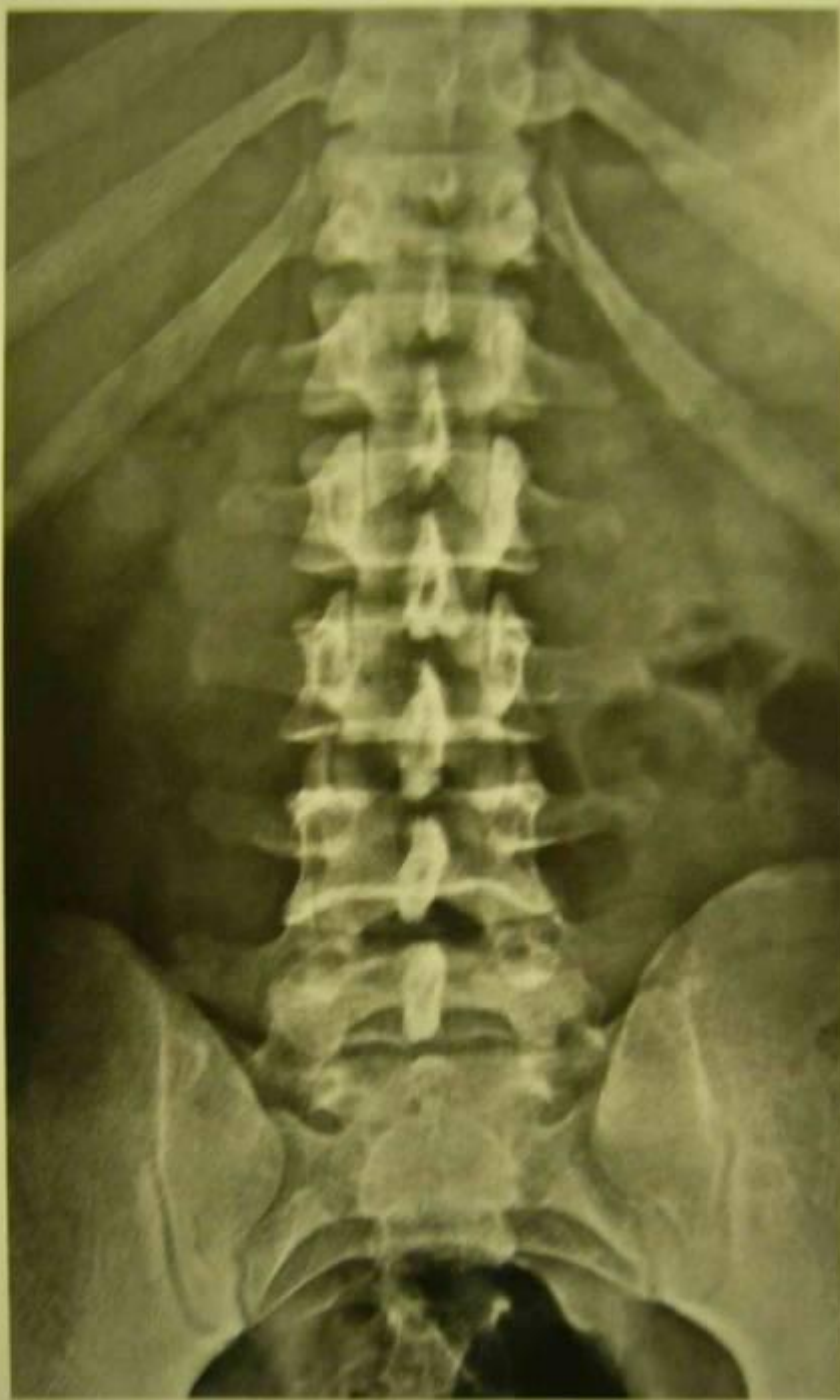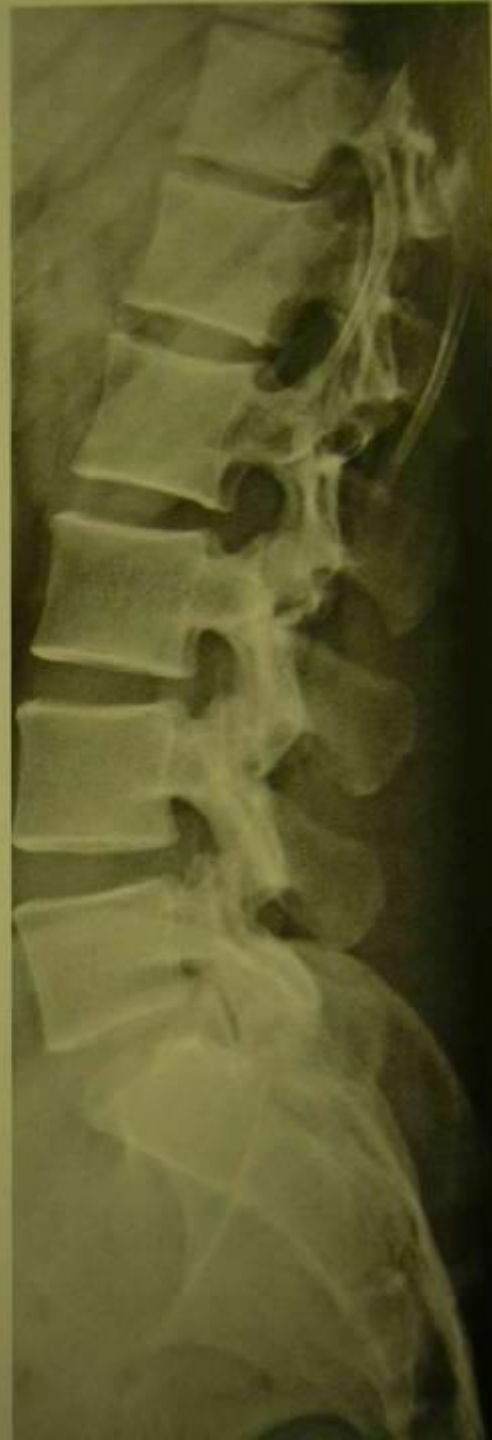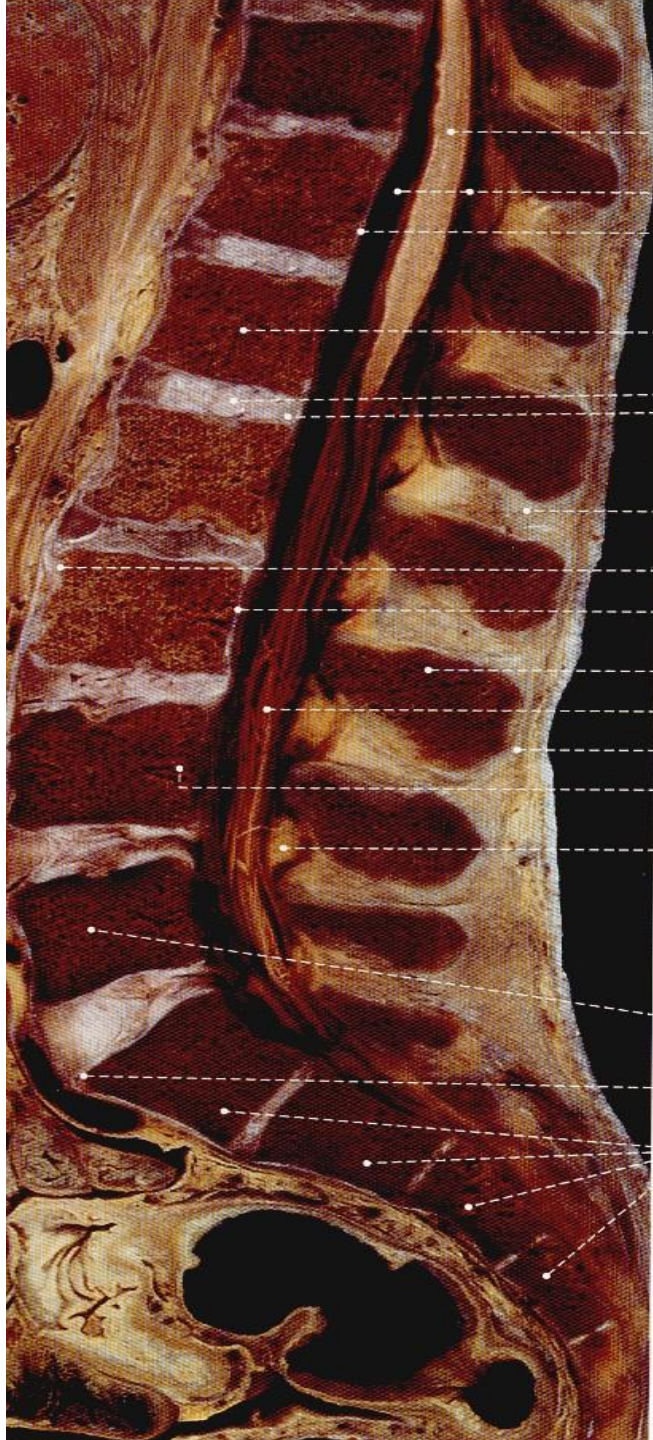




Abb. 34. Lendenwirbelsäule a.p.



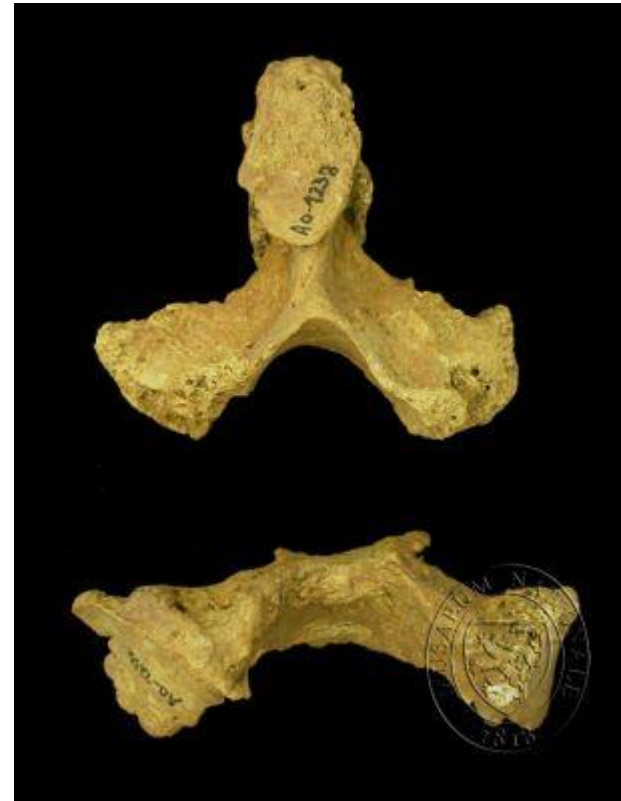Spüle, seitlich



Developmental defects of lumbar vertebrae

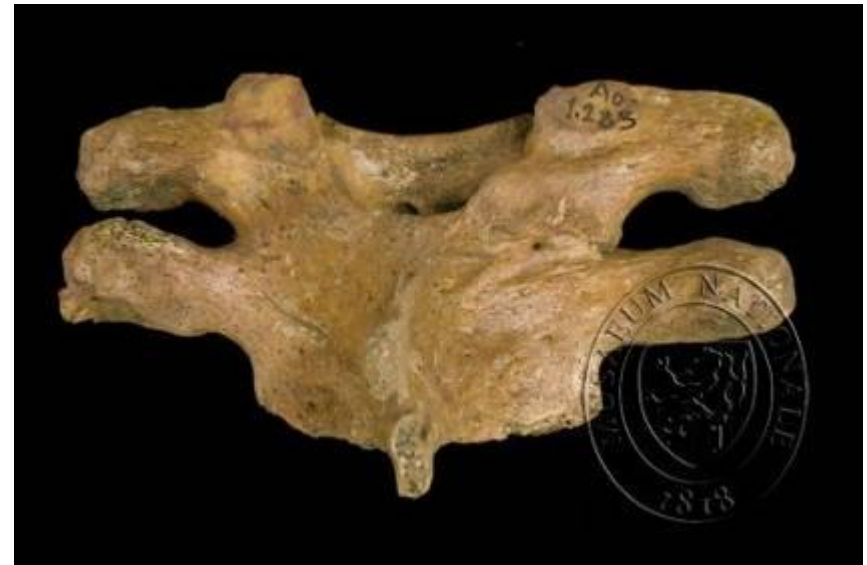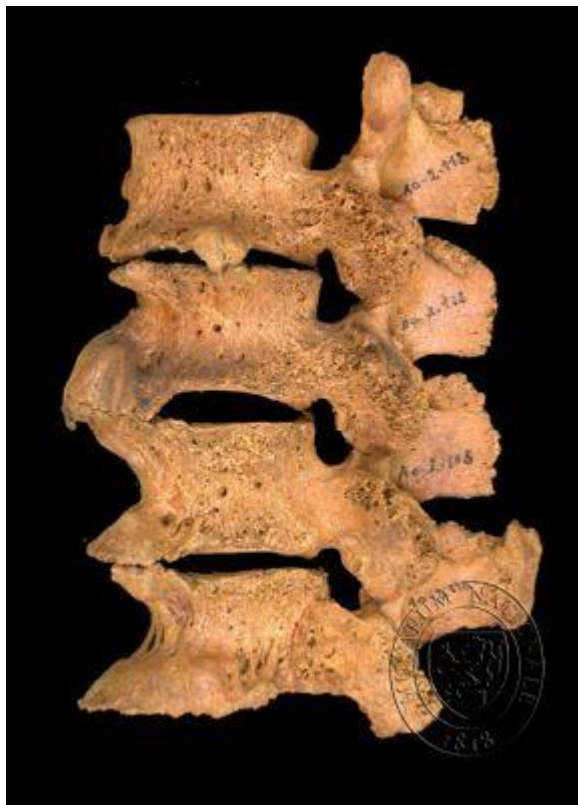Spondylolysis

= non-closed posterior arch
- 4th and 5th lumbar vertebra



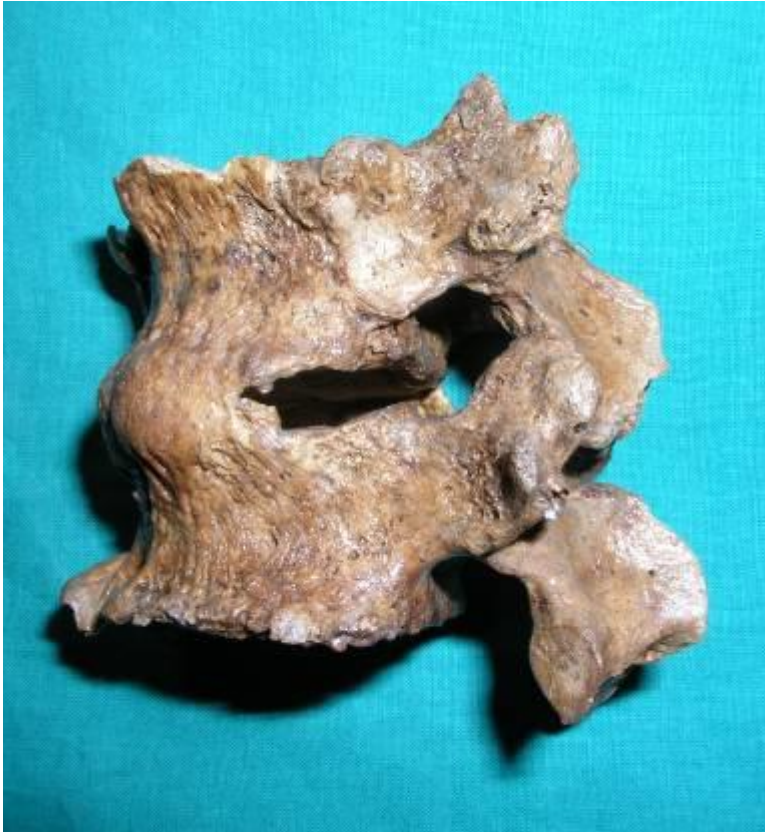Patological states in lumbar vertebrae

Spondylarthritis of lumbar vertebra L1-L4



Fusion of two thoracic vertebrae

Pathological states in lumbar spine

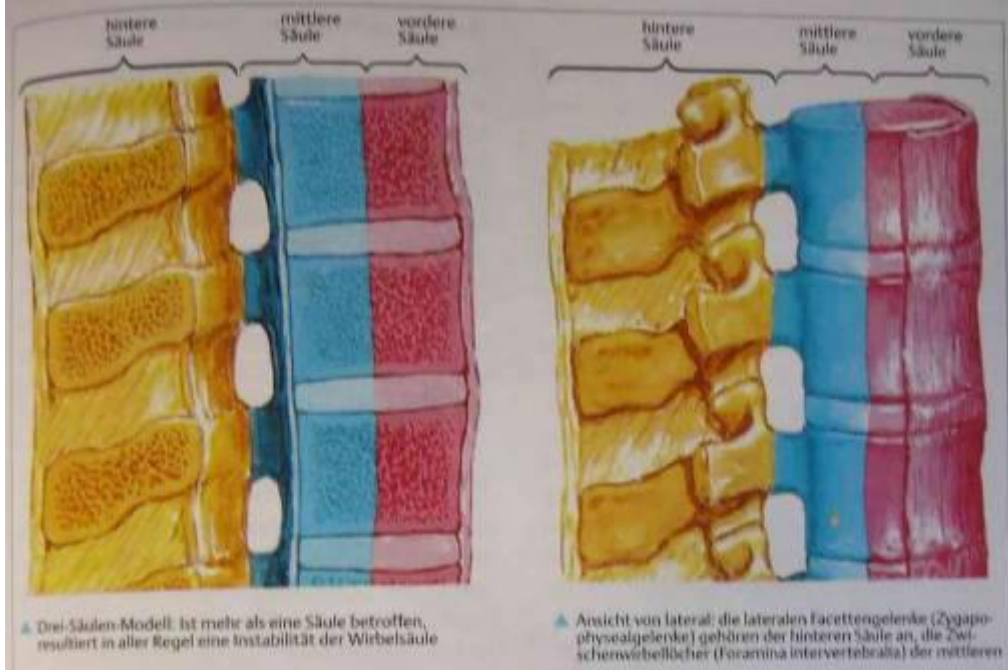


Clinical notes

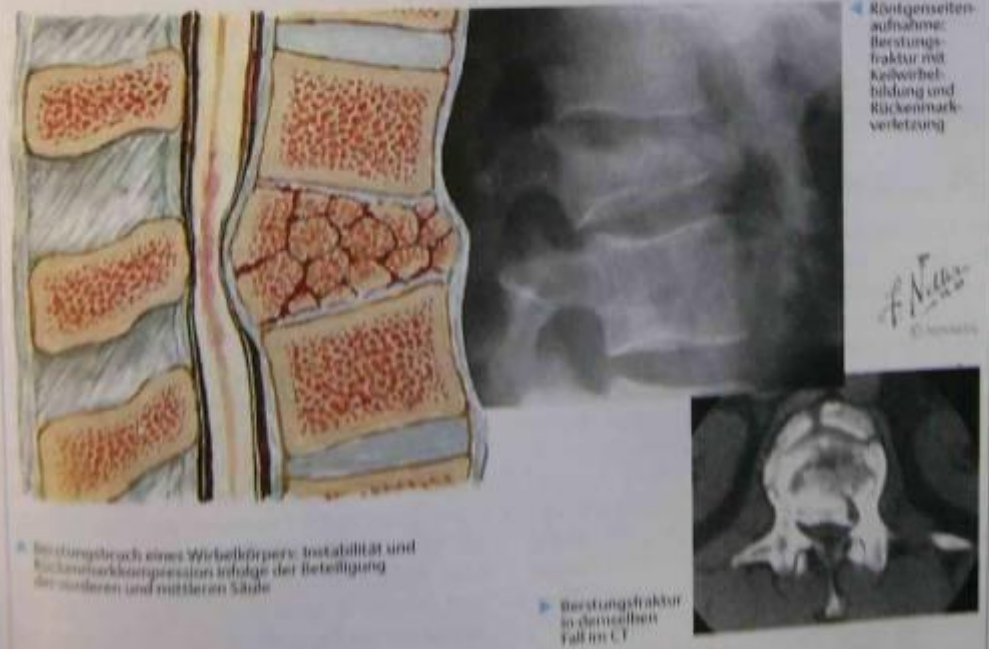
- most frequent fracture of vertebrae in transition of T and L (T12–L2)
- fracture classification – 3 columns following Denis
- compressive fractures (osteoporosis, metastasis of tumors), splinter fractures, (Chance's fracture)
- surgical treatment only in case of non-stable fractures (posterior approach)
- damage to nervous structures !
 - (Brown-Séguard's syndrome)
- later consequences

- fracture classification

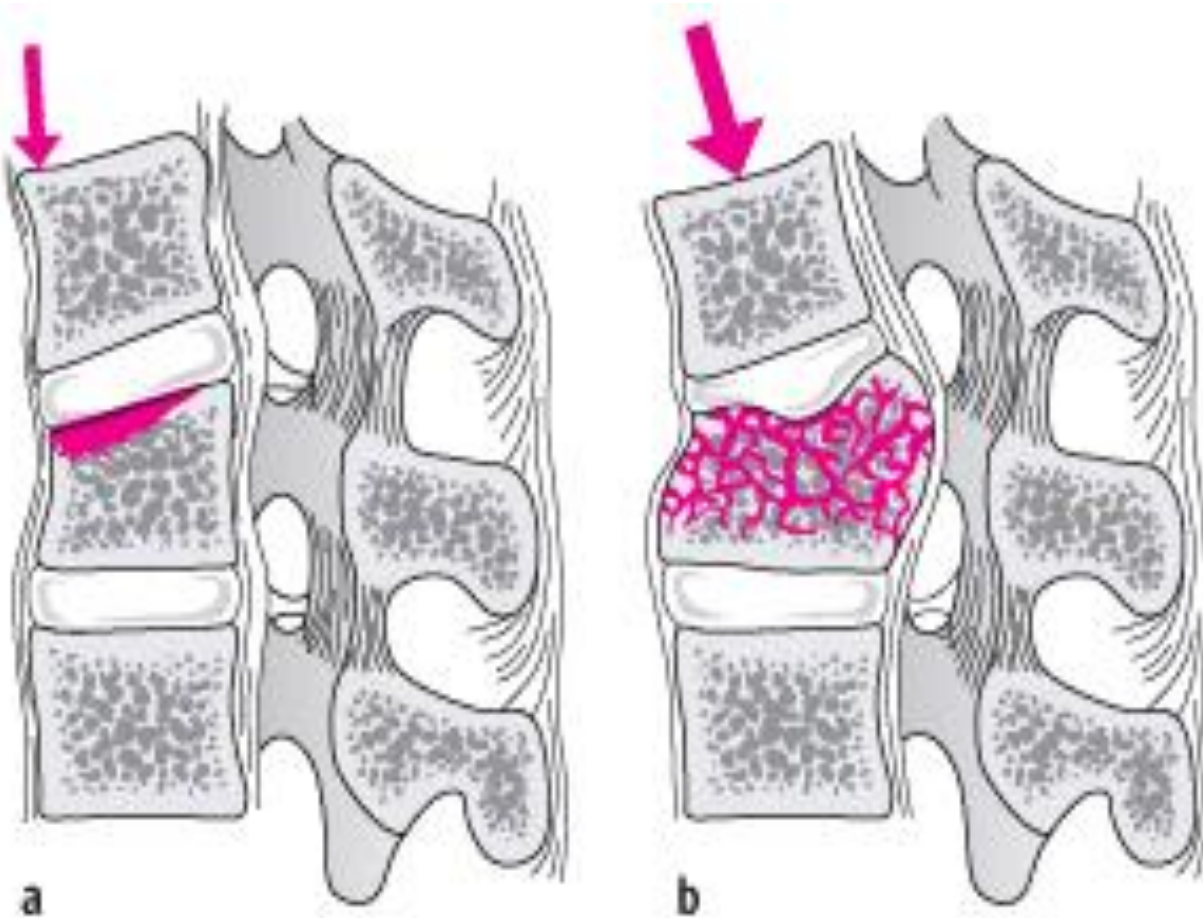
3 columns following Denis



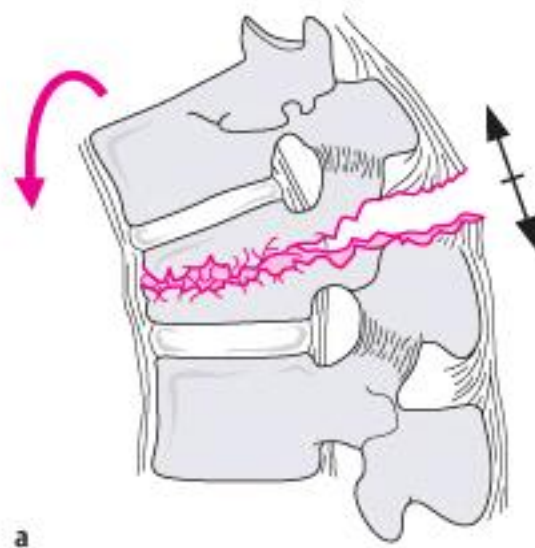
- compressive fracture



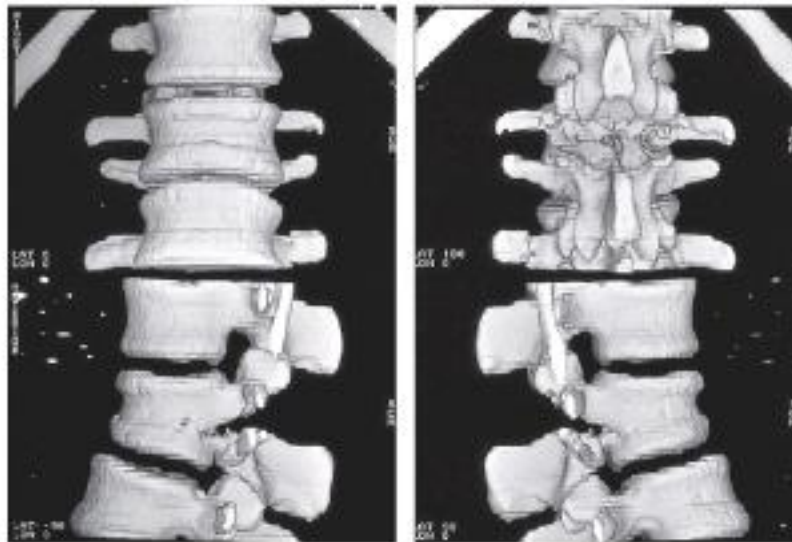
Stabile and non-stabile fracture



Chance's fracture

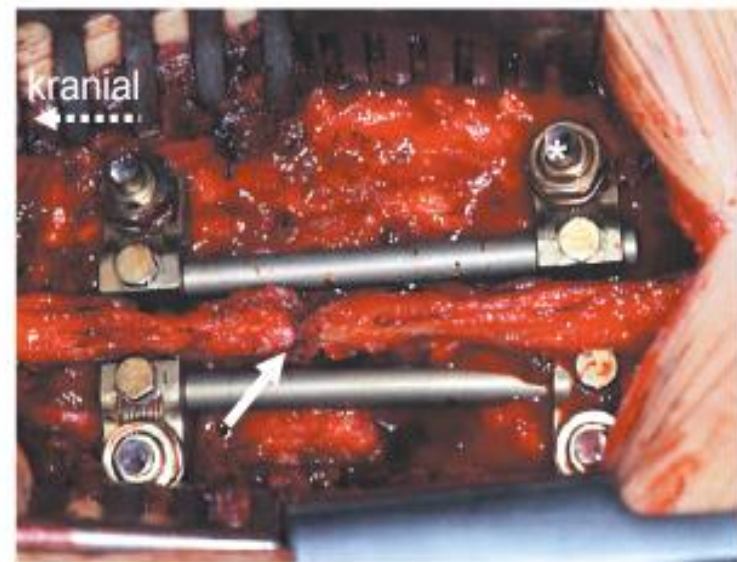


a

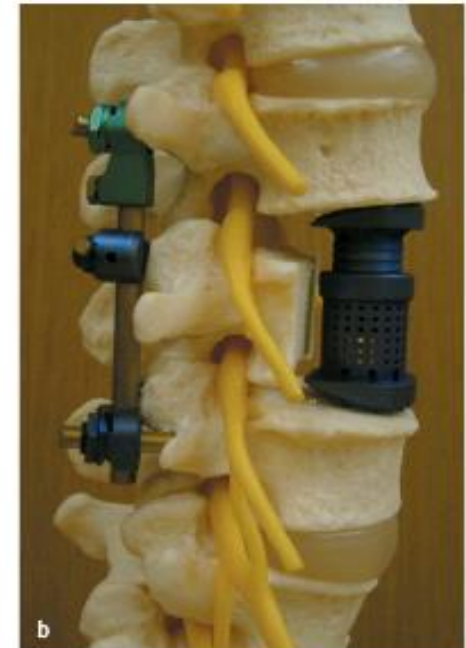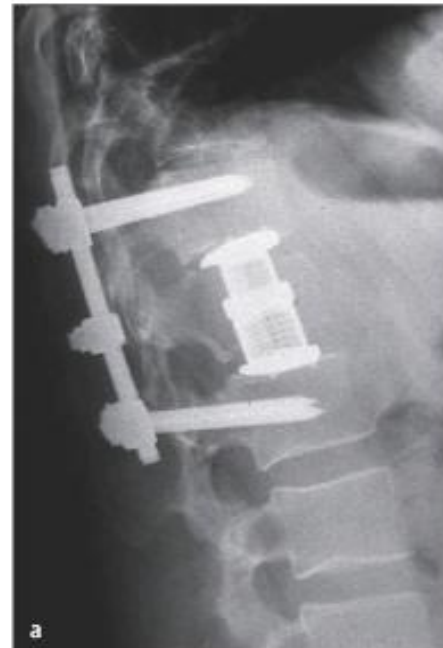

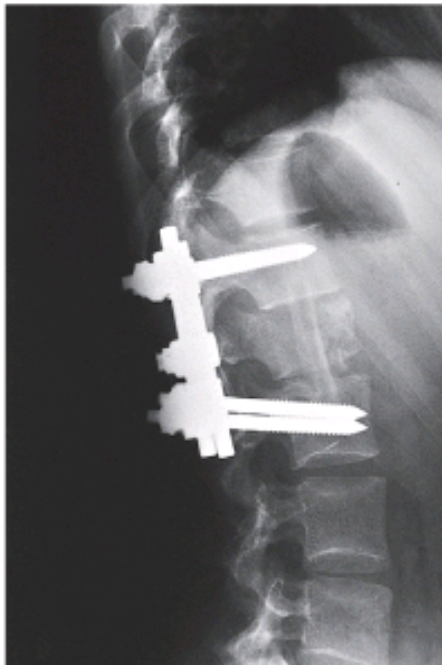
b

Fracture treatment

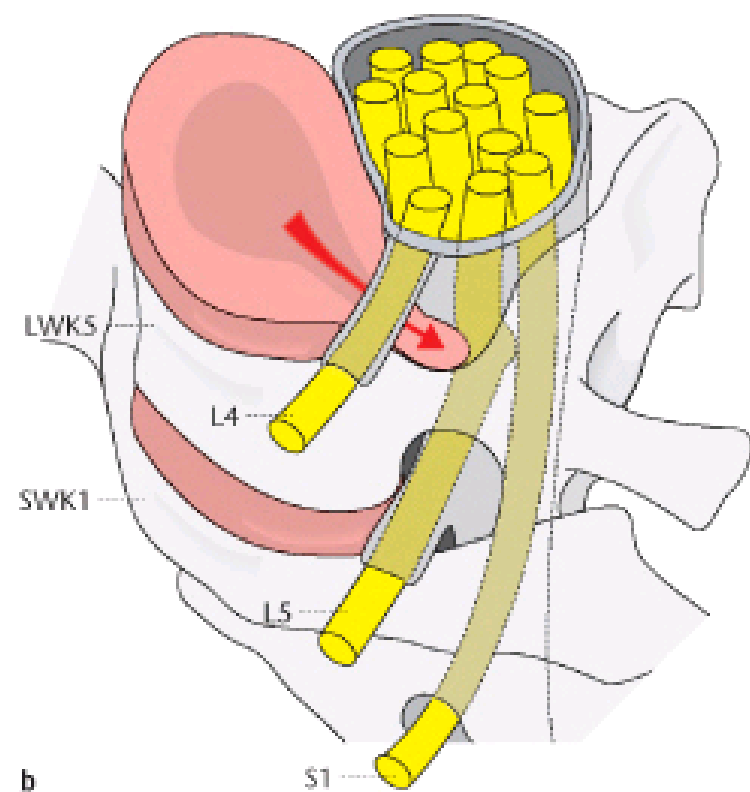
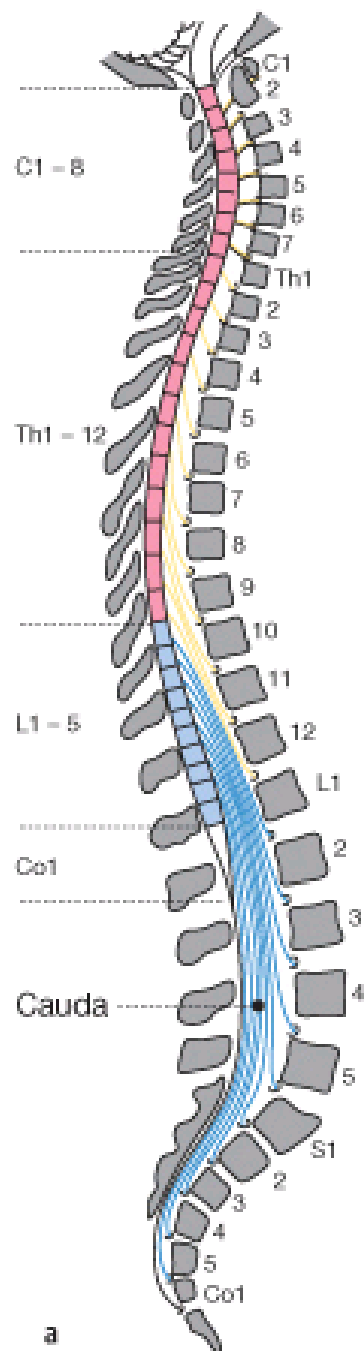


Berchtold/Bruch/Trentz: Chirurgie, 5.A. © Elsevier GmbH. www.studentconsult.de



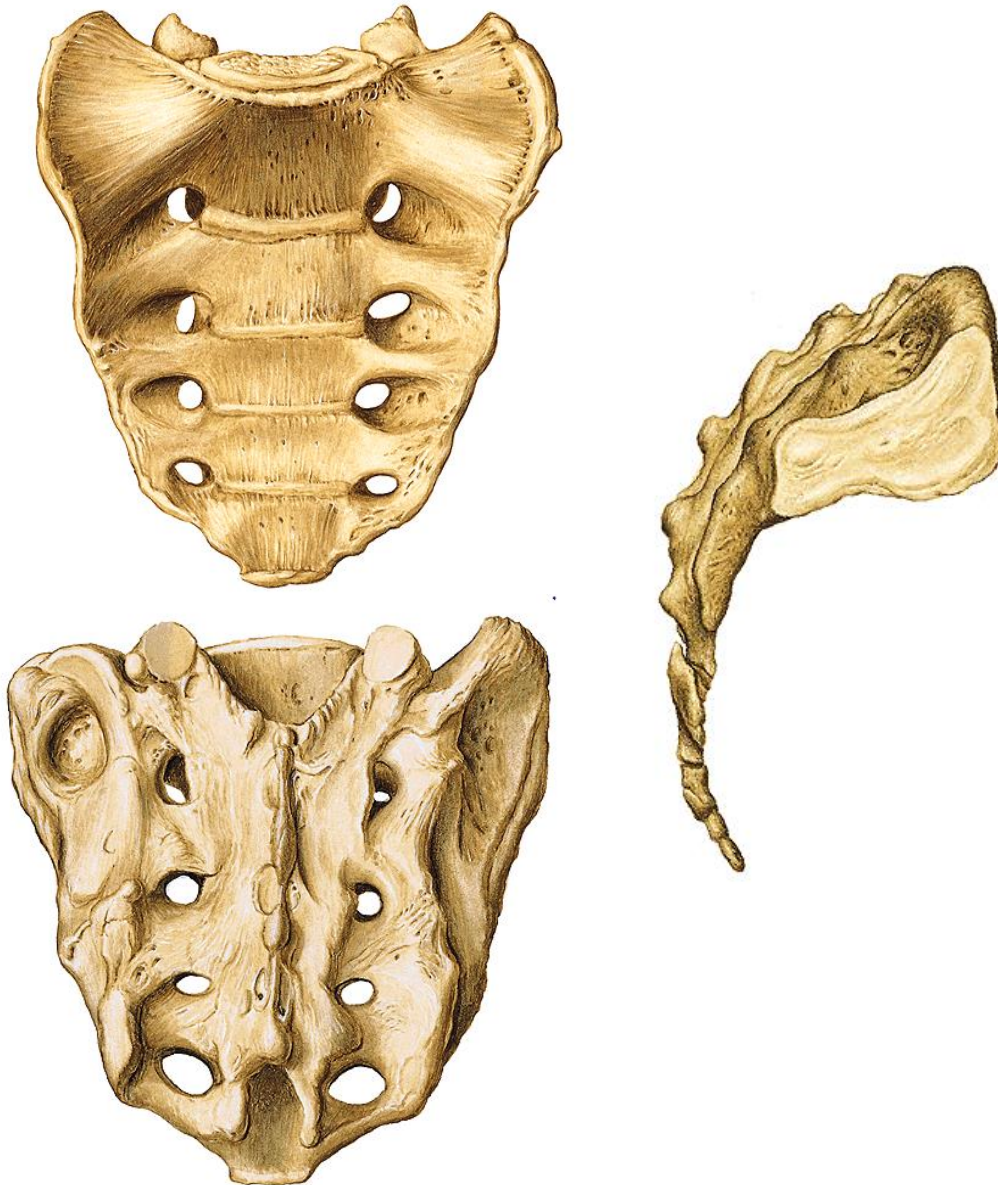
Berchtold/Bruch/Trentz: Chirurgie, 5.A. © Elsevier GmbH. www.studentconsult.de

Disc protrusion



Os sacrum

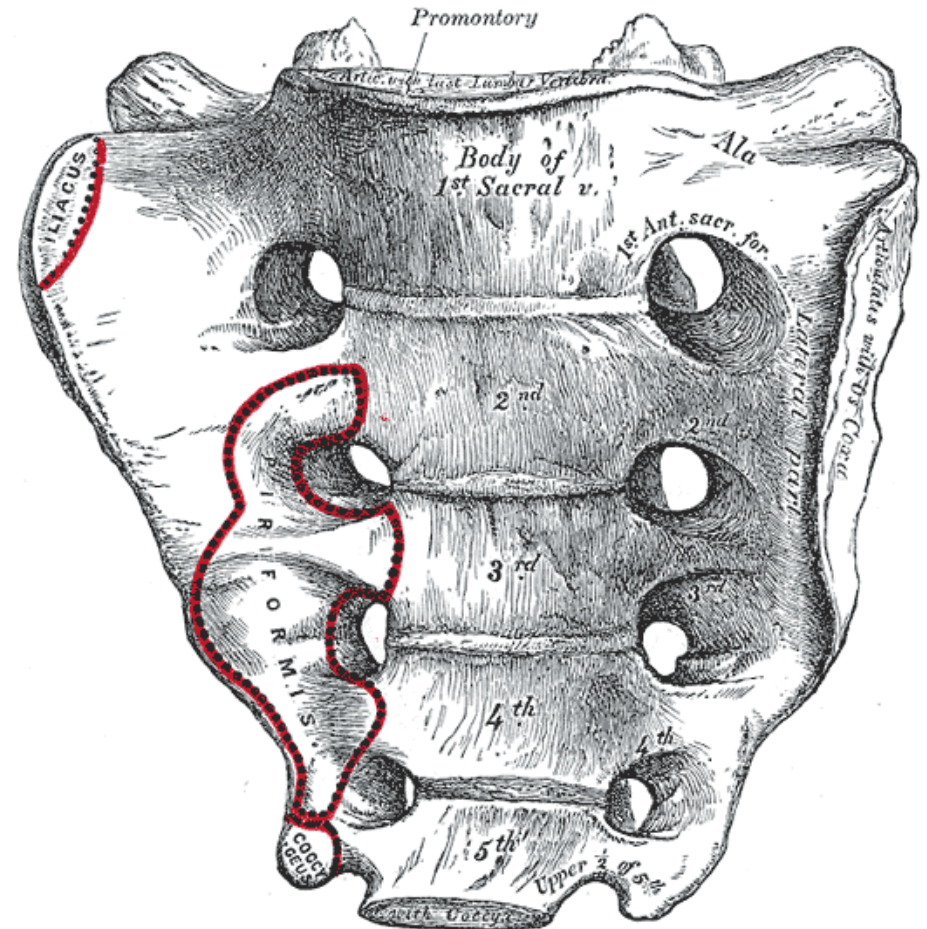
(vertebrae sacrales SI – SV)



Sacral bone
Basis ossis sacri
Promontorium
Ala ossis sacri
Processus articularis superior
Pars lateralis
Facies auricularis
Tuberositas ossis sacri
Facies pelvica
Lineae transversae
Foramina intervertebralia
Foramina sacralia anteriora
Facies dorsalis
Crista sacralis mediana
Foramina sacralia posteriora
Crista sacralis medialis
Crista sacralis lateralis
Cornu sacrale
Canalis sacralis
Hiatus sacralis
Apex ossis sacri

Os sacrum

- 5 fused sacral vertebrae
- developmental origin of its parts
- sacralization of lumbar vertebrae
- lumbalization of sacral vertebrae

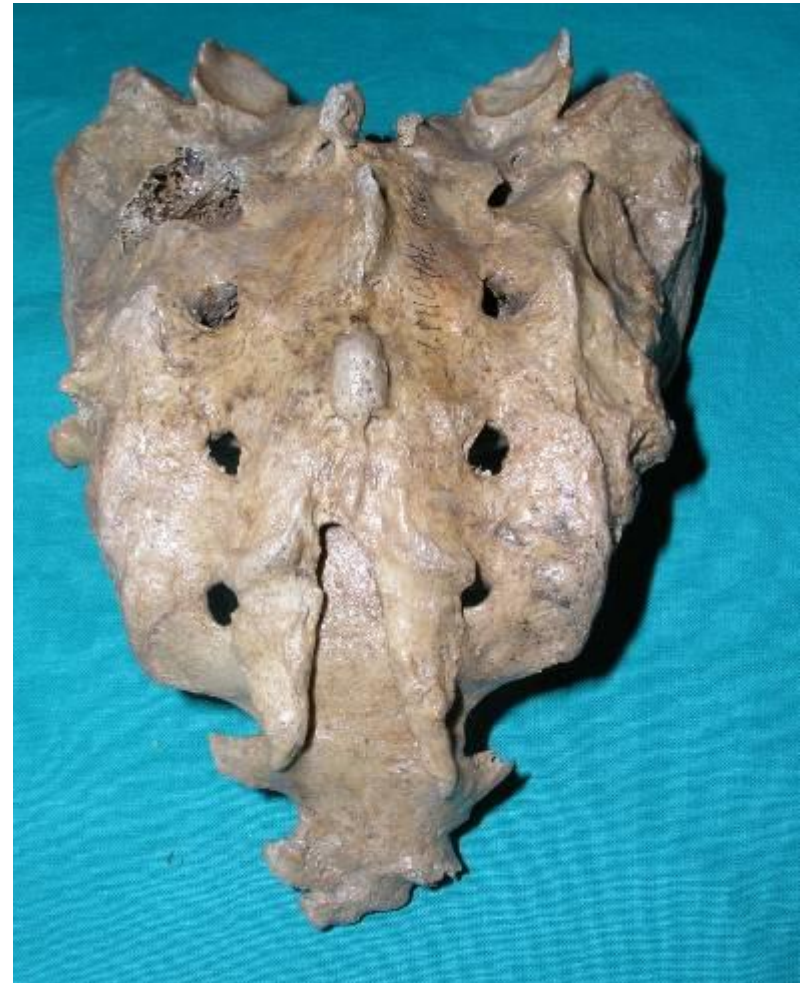
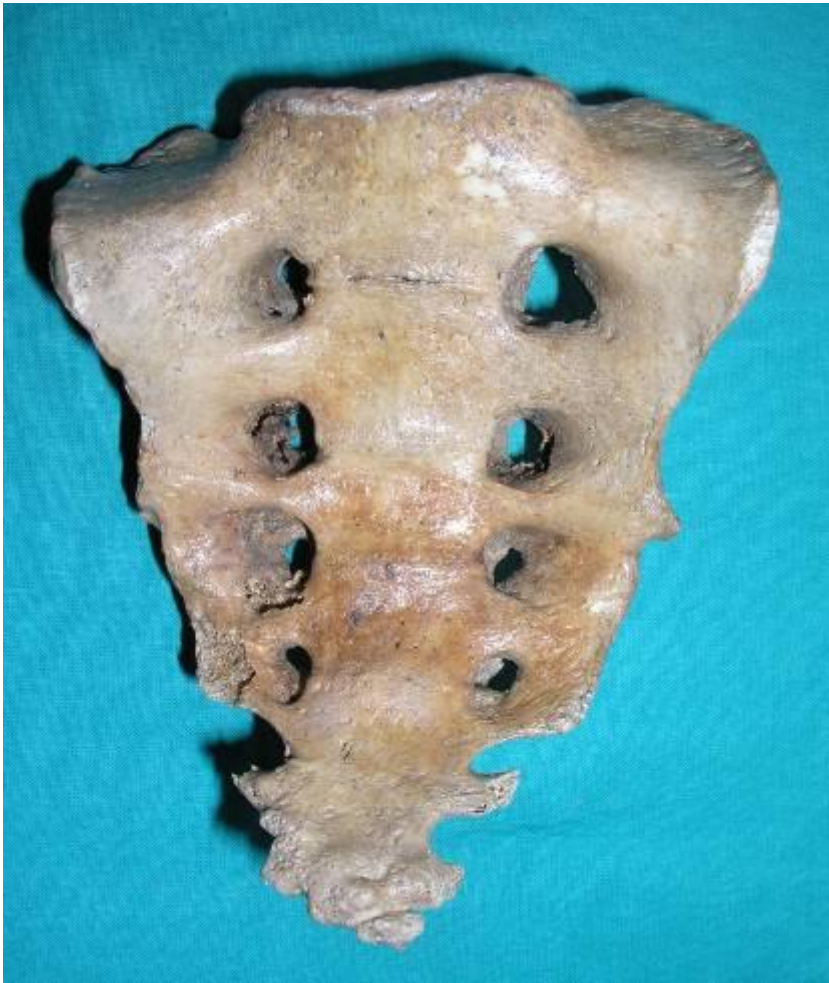
Coccyx (Os coccygis)



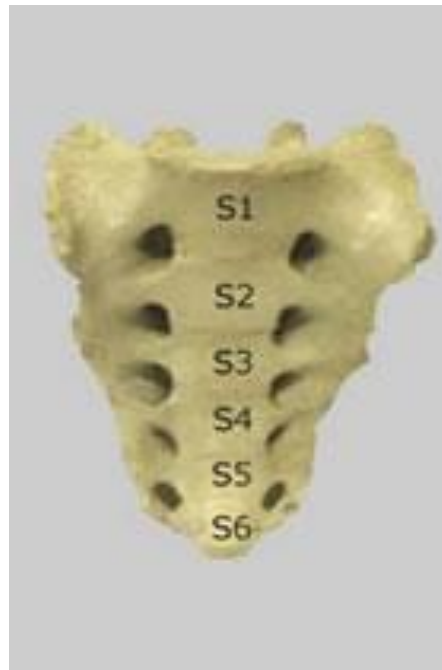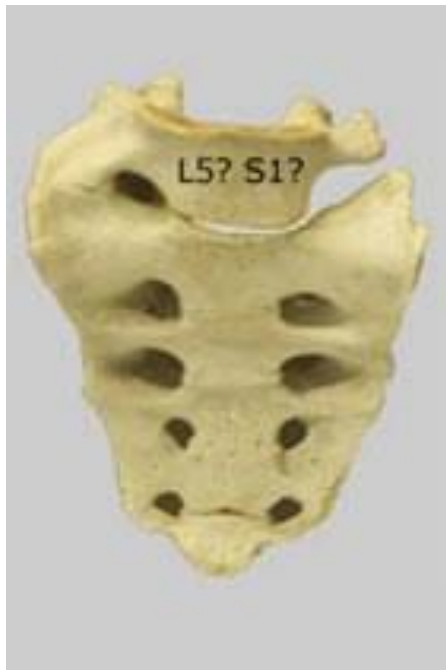- cornua coccygea
- 3-5 fused vertebrae (Co)
- rudimentary part of vertebral column
- 1 pair of spinal nerves
- *examination per rectum*

Developmental defects of sacral bone and coccyx synostosis sacrococcygea



Developmental defects of sacral bone and coccyx

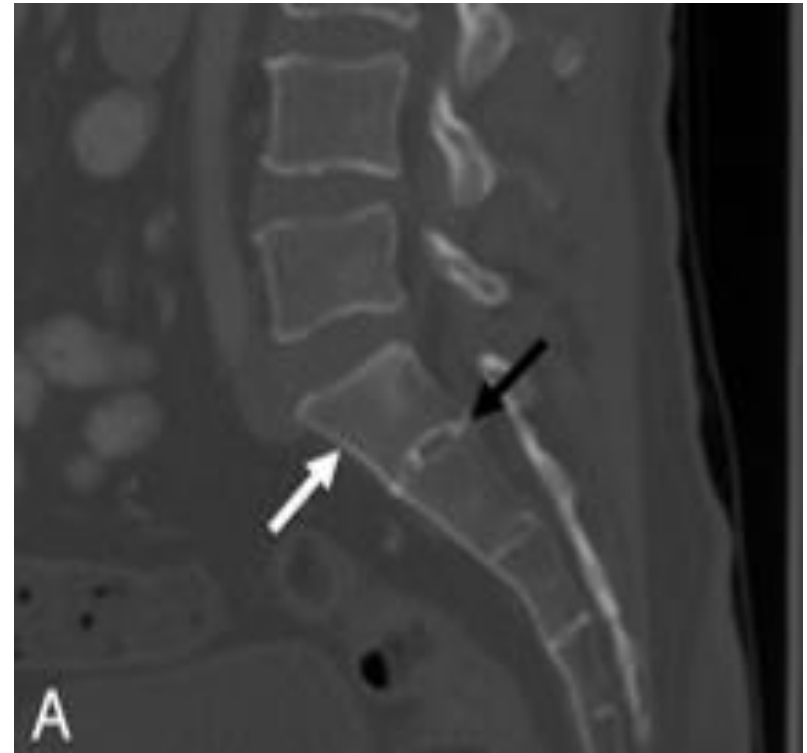
lumbalization / sacralization



canalis sacralis apertus
opened vertebral canal



Sacralization of L5



Sacralization of L5 – white arrow
Disappeared intervertebral disc – black arrow

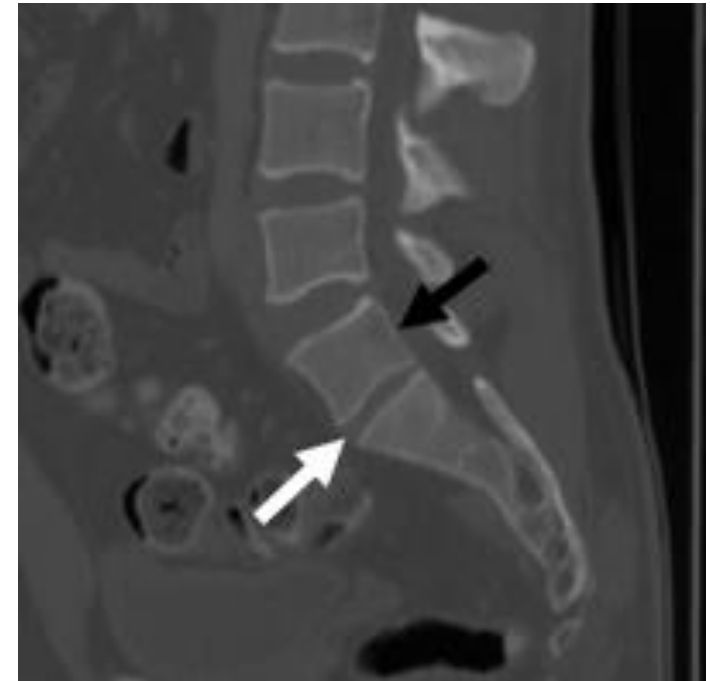

Lumbalization of S1

Complete lumbalization of S1

+

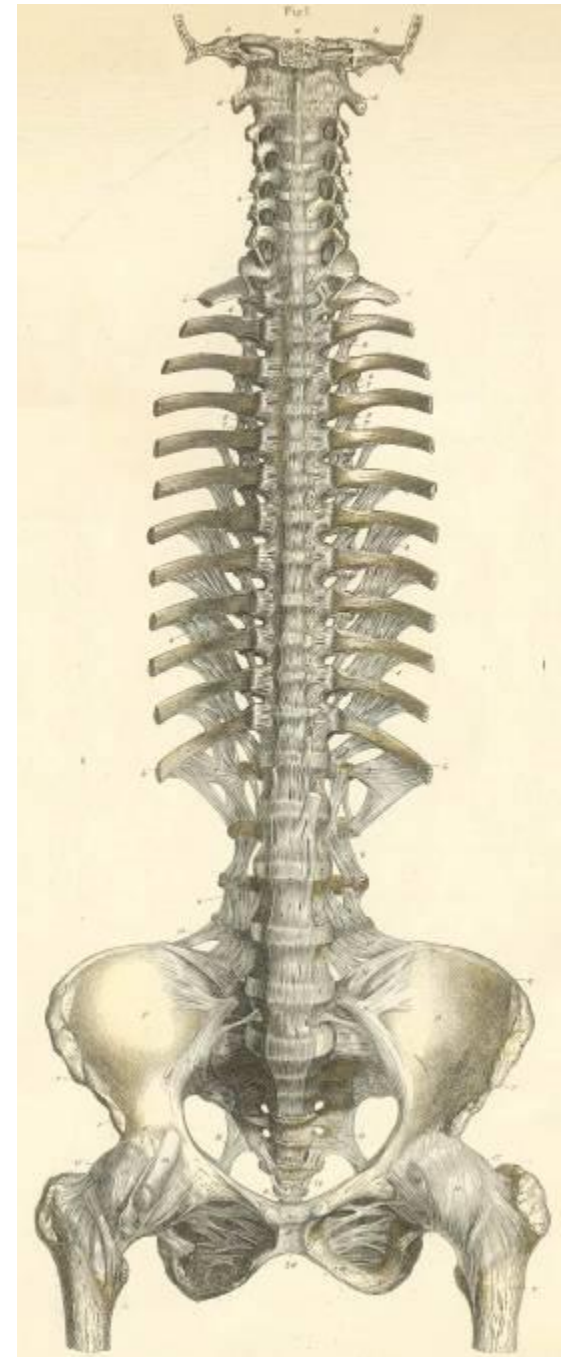
Spina bifida lateralis (spondylolysis) S₁

Numerous osteophytes as a mark of originating spondylolysis

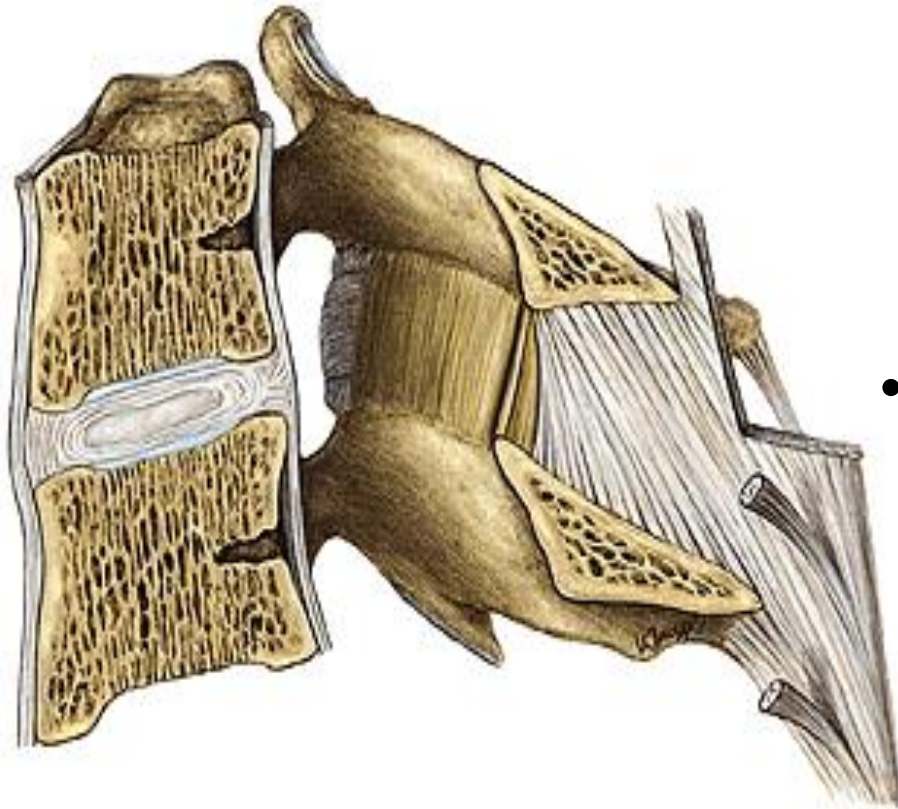


Lumbalization of S1 – black arrow
Well developed intervertebral disc – white arrow

Vertebral joints



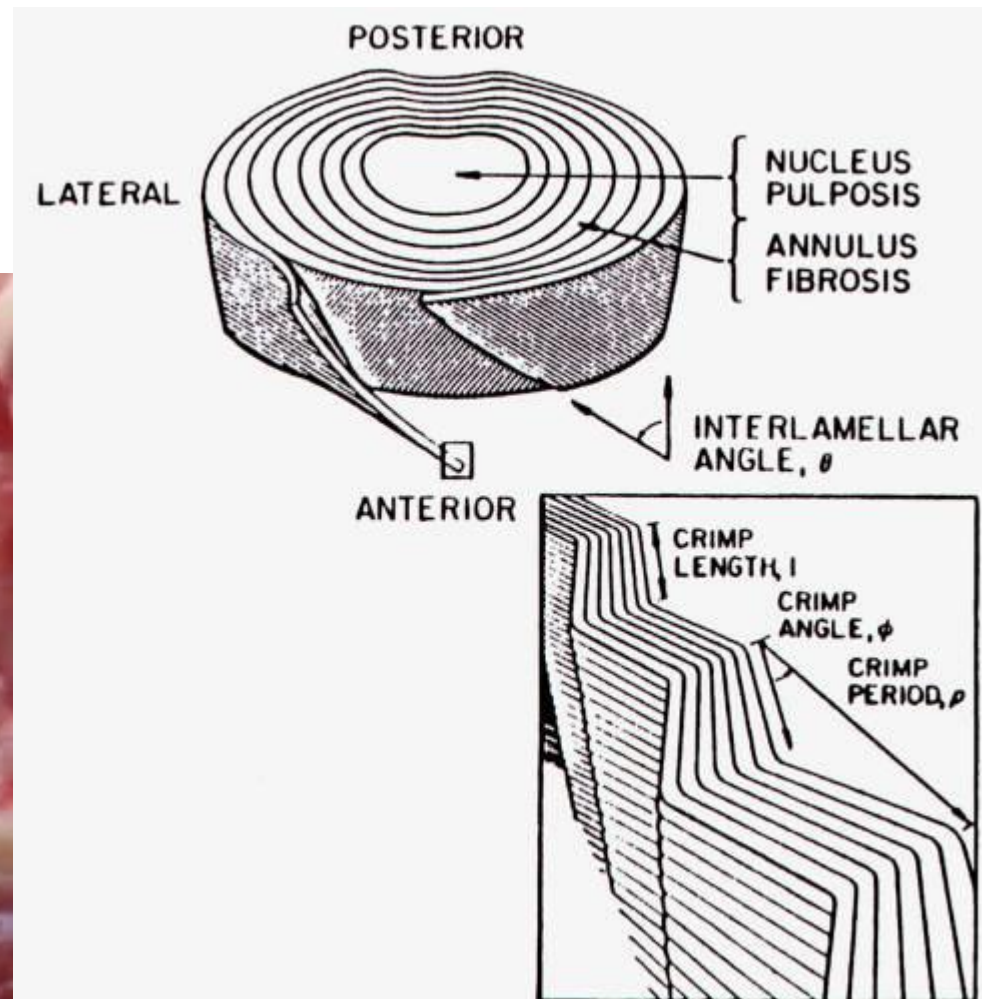
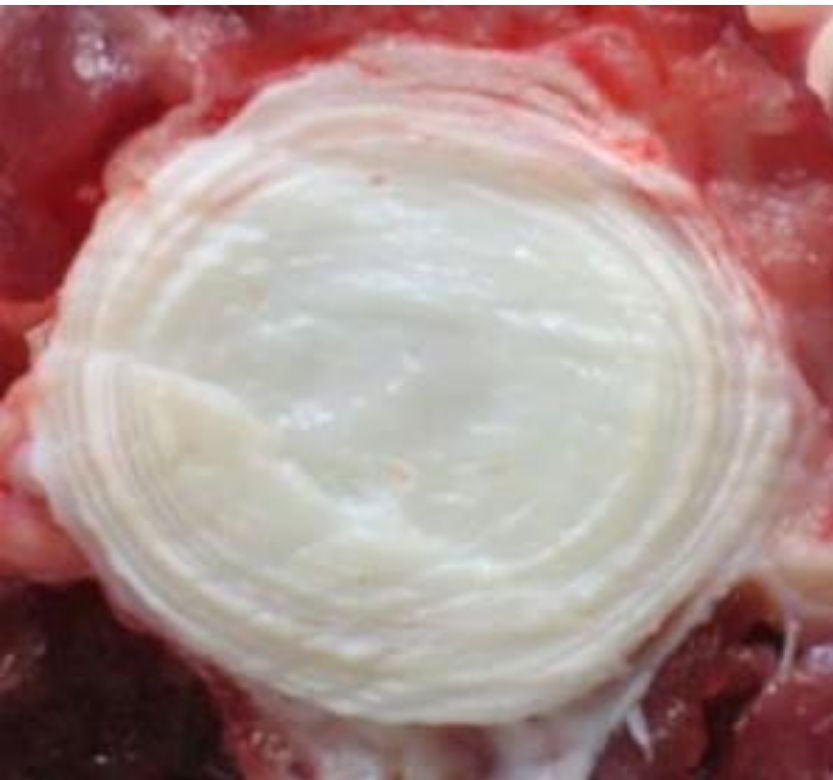
Vertebral joints



- **Synarthroses**
 - syndesmoses = ligaments
 - long
 - short
 - symphyses = disci intervertebrales
 - symphysis intervetebralis
 - symphysis sacrocyoccygea
- **Diarthroses** = joints
 - artt. atlantoaxiales
 - artt. zygapophysiales
 - art. lumbosacralis

Symphyses intervertebrales

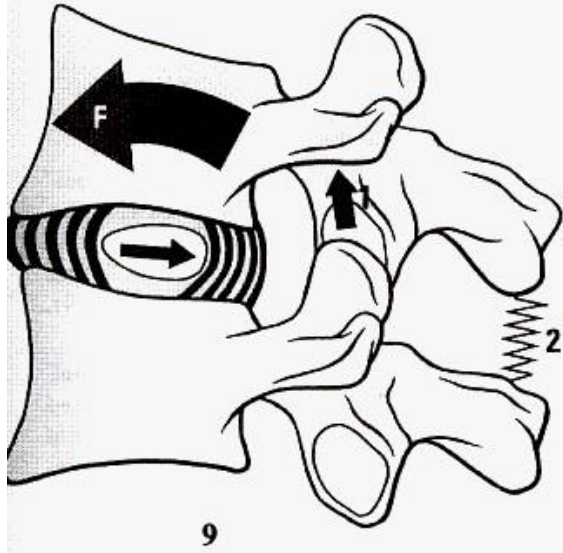- discus intervertebralis = intervertebral disc
- anulus fibrosus
- nucleus pulposus



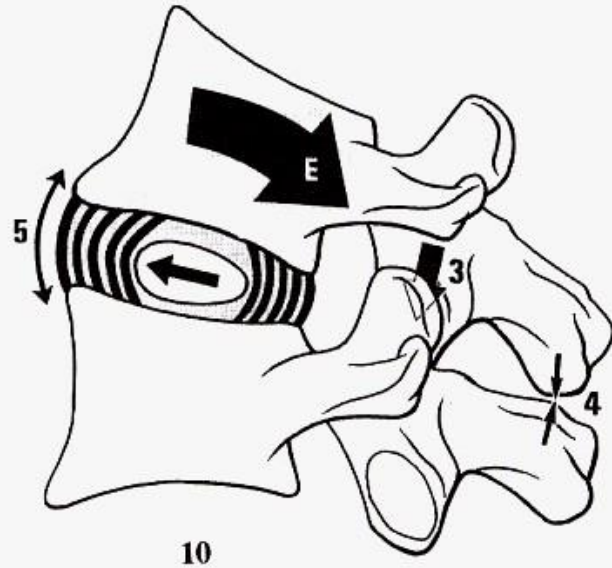
Symphyses intervertebrales

Intervertebral joints

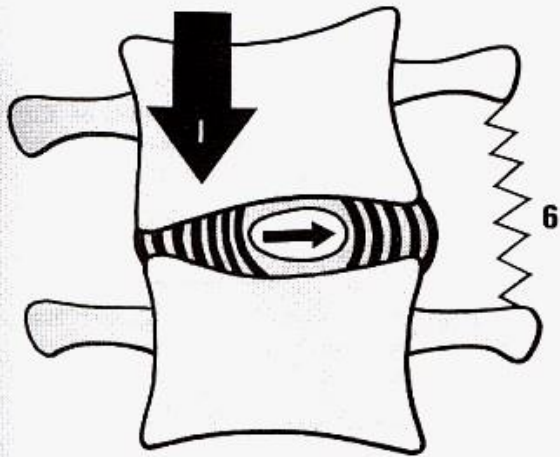
- interconnect movable part of vertebral column
- 23 discs
- first between C2 and C3, pre-last between L5 and S1, last between S5 and Co1
- craniocaudally increase in size
- **anulus fibrosus** – external part of discus formed by elastic cartilage, on the surface hyaline cartilage
- **nucleus pulposus** – fluidy nucleus of round shape approximately in the middle
 - due to impossibility of fluid compression, vertebrae move around this nucleus
- note:
 - in the later age body has less fluid → decrease of the discus size → column decreases size and bends
 - disci decrease in size proportionally to load → in the morning we are taller then in the evening



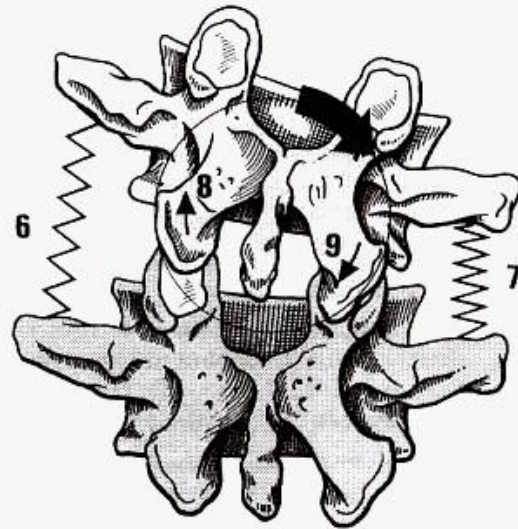
9



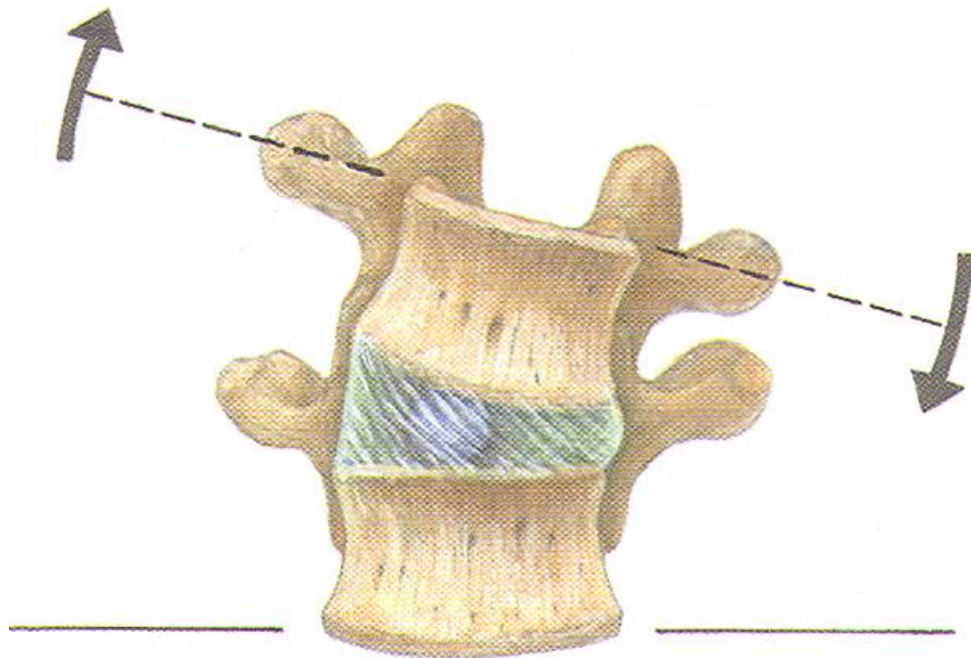
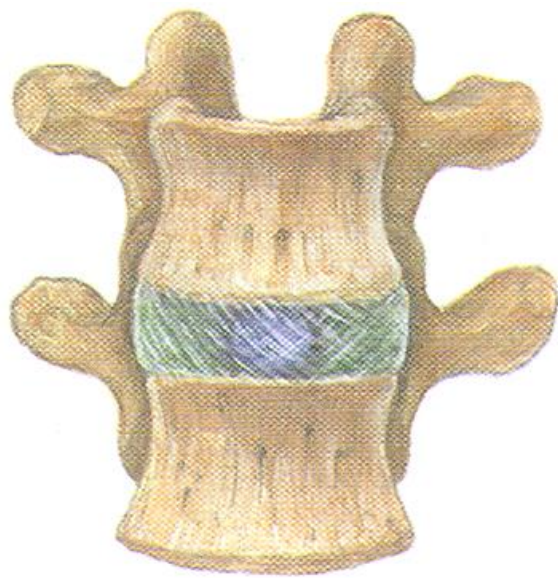
10



11

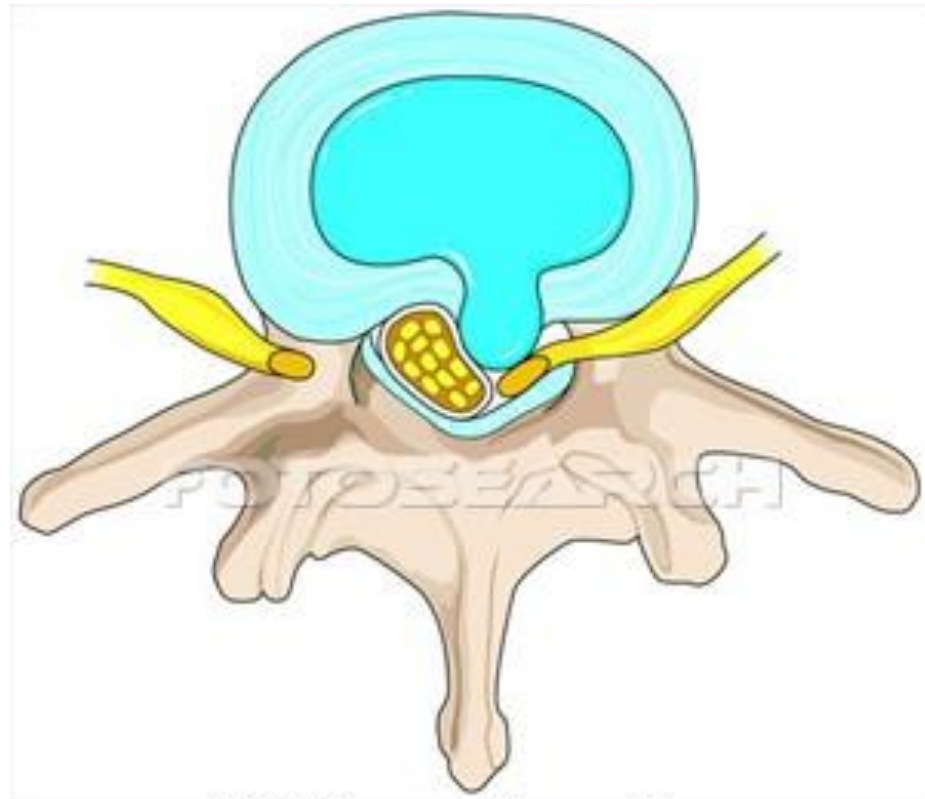

12

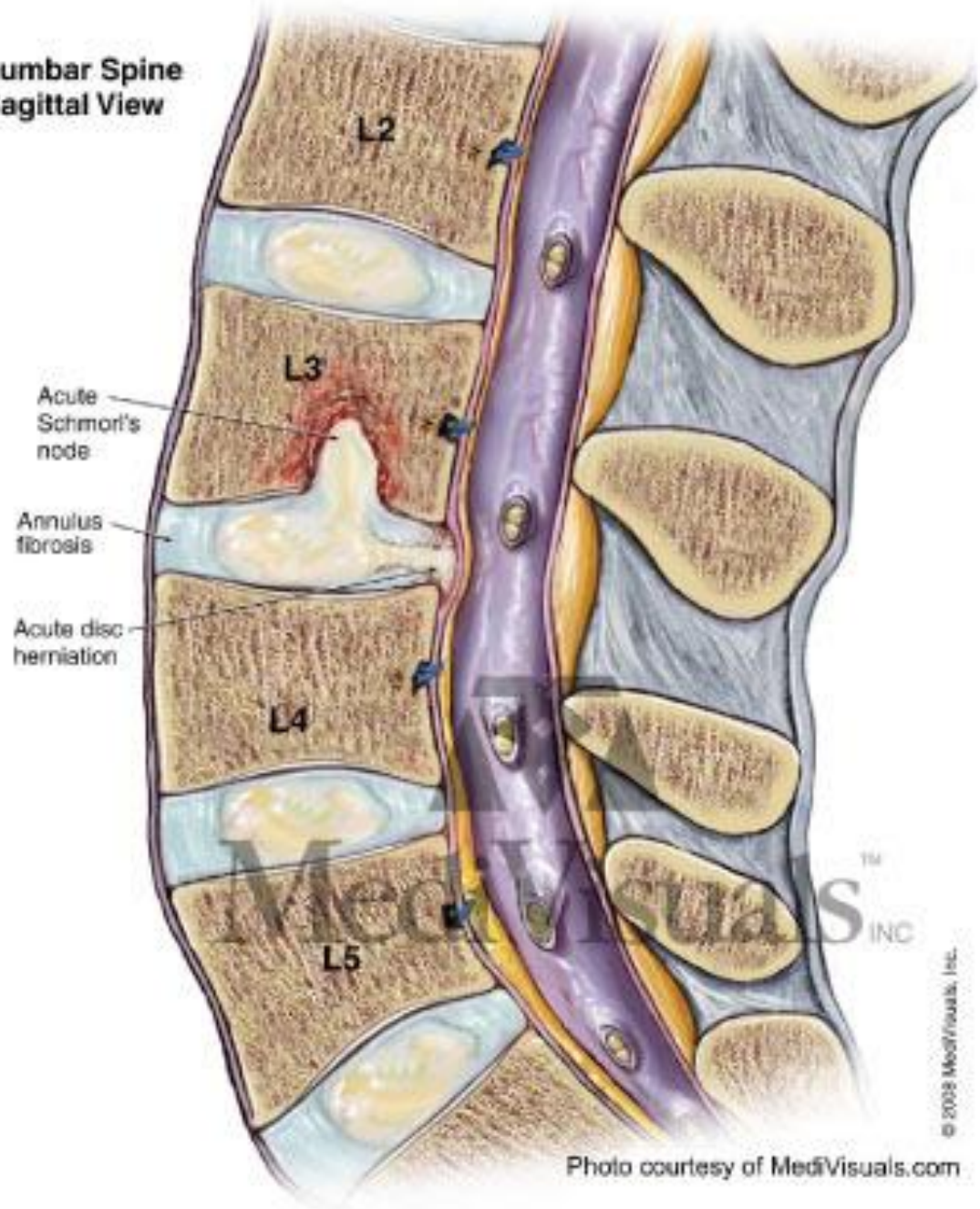


Prolapsus of disc

- Schmorl's node (morbus Scheuermann)
- inside vertebral canal (compression of spinal cord)



Lumbar Spine Sagittal View



© 2008 MediVisuals, Inc.

Photo courtesy of MediVisuals.com

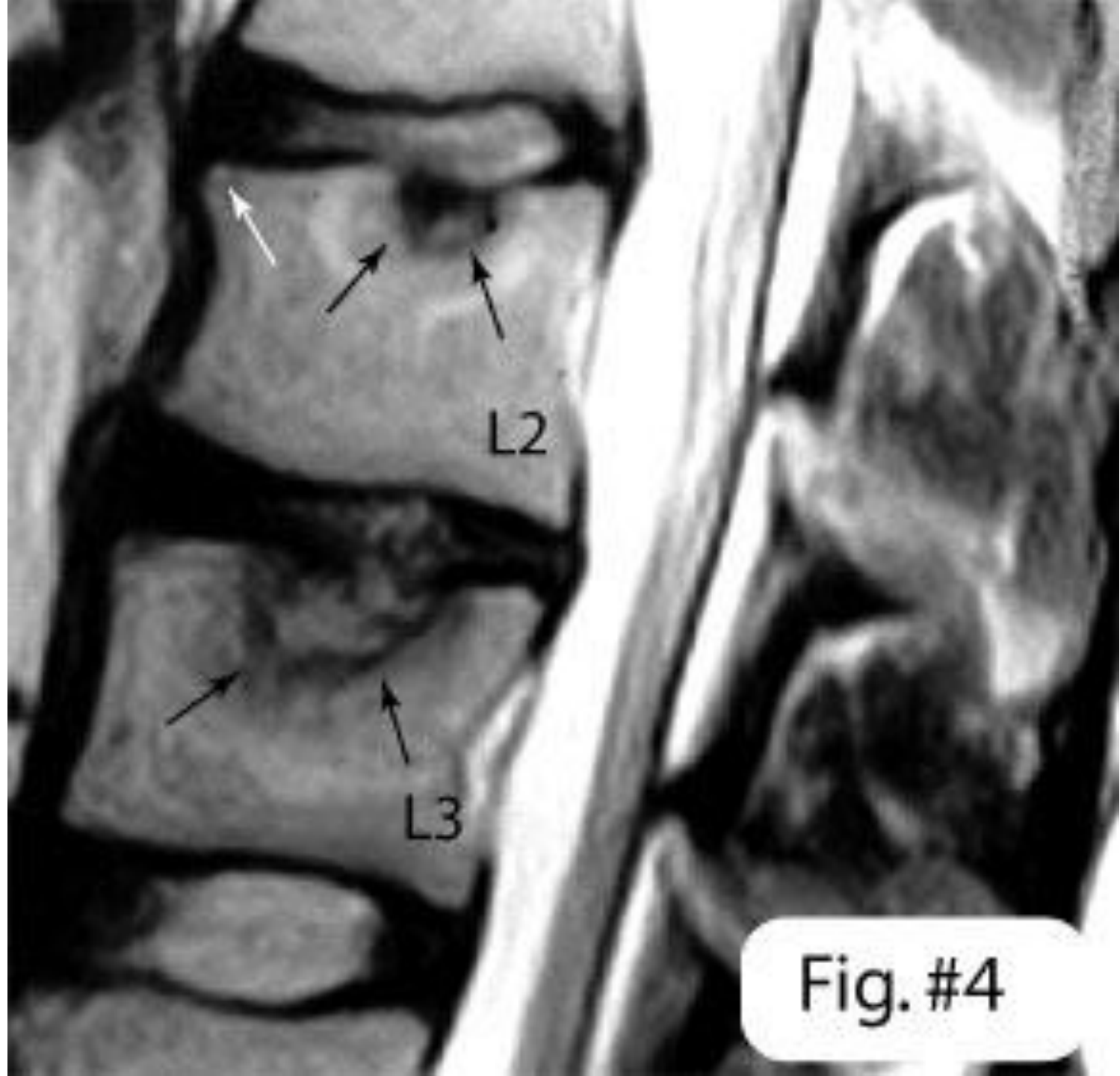
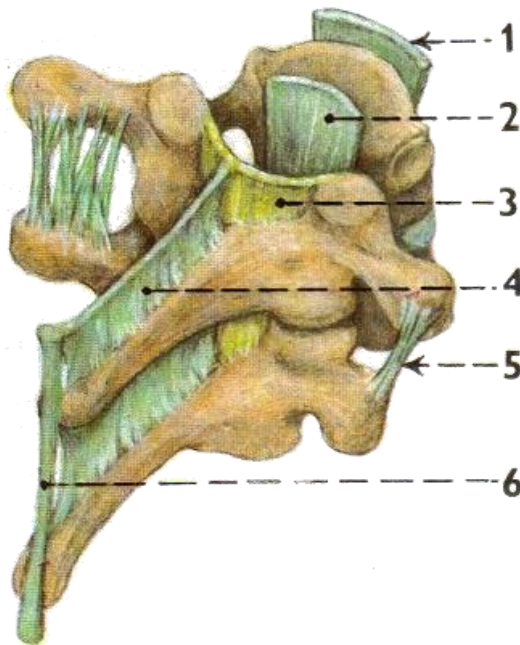
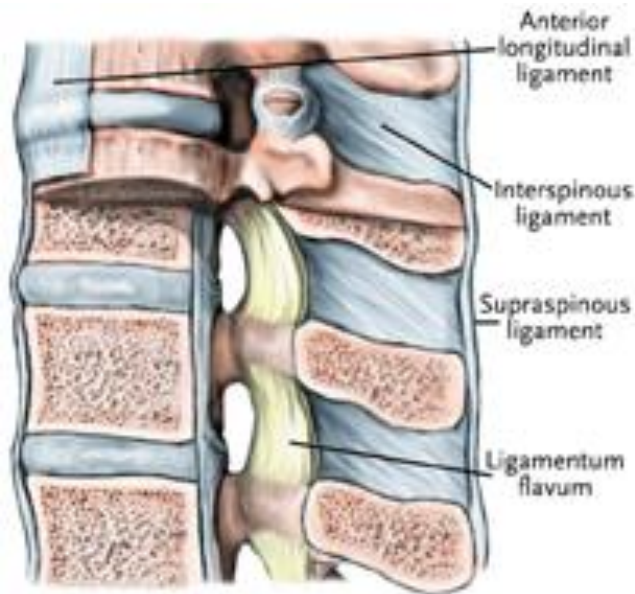


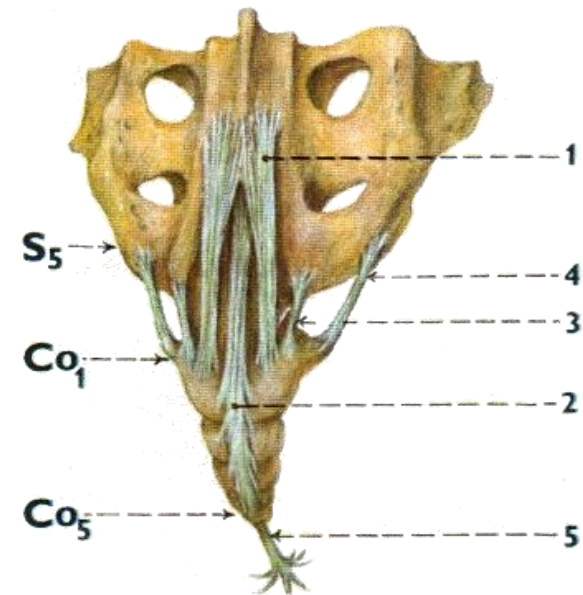
Fig. #4

Long ligaments of vertebral column

- lig. longitudoinale anterius
- lig. longitudoinale posterius
- lig. sacrococcygeum posterius superficiale



135. LIGAMENTA PÁTERE v úseku hrudní páteře – pohled zprava zezadu
 1/ ligamentum longitudoinale anterius
 2/ ligamentum longitudoinale posterius
 3/ ligamenta interarcualia
 4/ ligamenta interspinalia
 5/ ligamenta intertransversaria
 6/ ligamenta supraspinalia




136. LIGAMENTA KŘÍŽOVÉ KOSTI A KOSTRČE – pohled zezadu
 1/ ligamentum sacrococcygeum dorsale superficiale (uprostřed vyfyznuté, aby bylo vidět do hiatus sacralis)
 2/ ligamentum sacrococcygeum dorsale profundum
 3/ vazivové přemostění mezi cornu sacrale a cornu coccygeum
 4/ ligamentum sacrococcygeum laterale
 5/ retinaculum caudale cutis

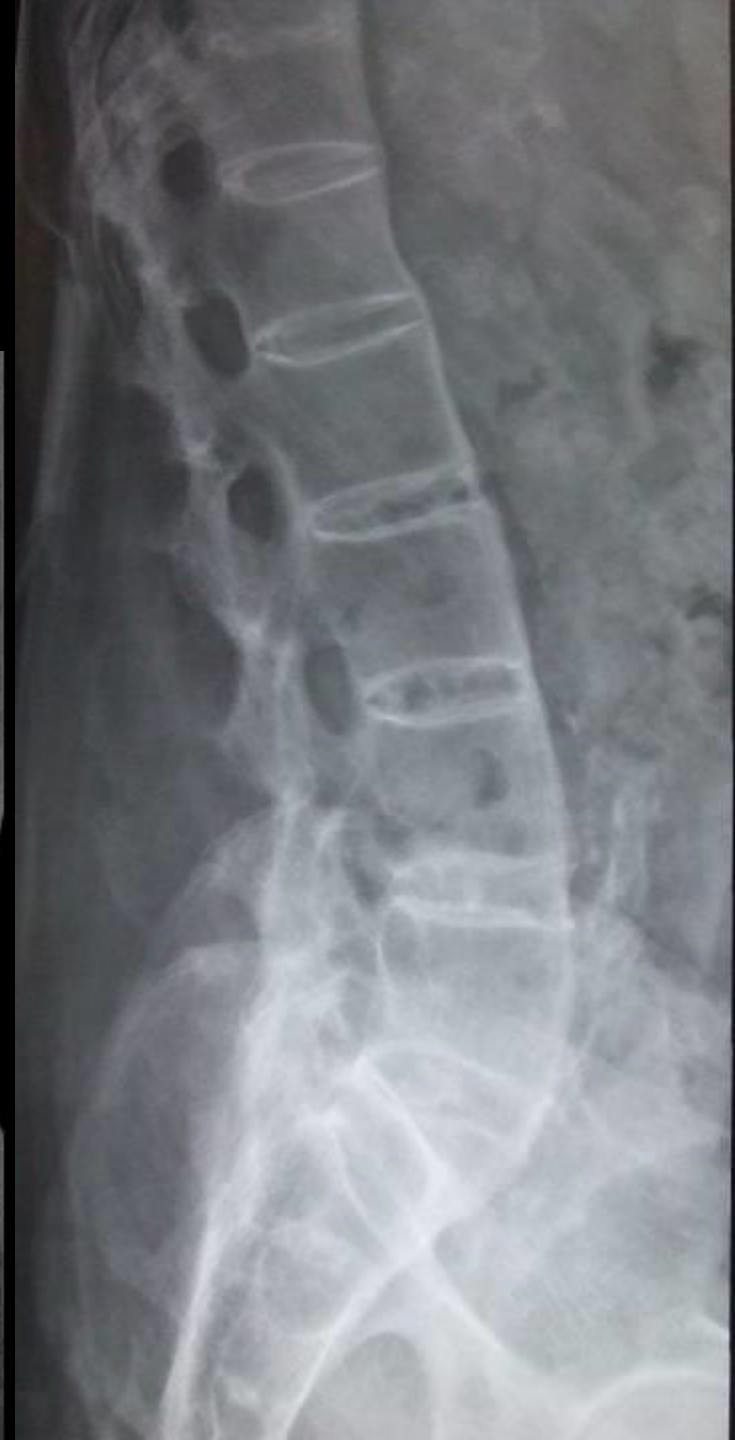
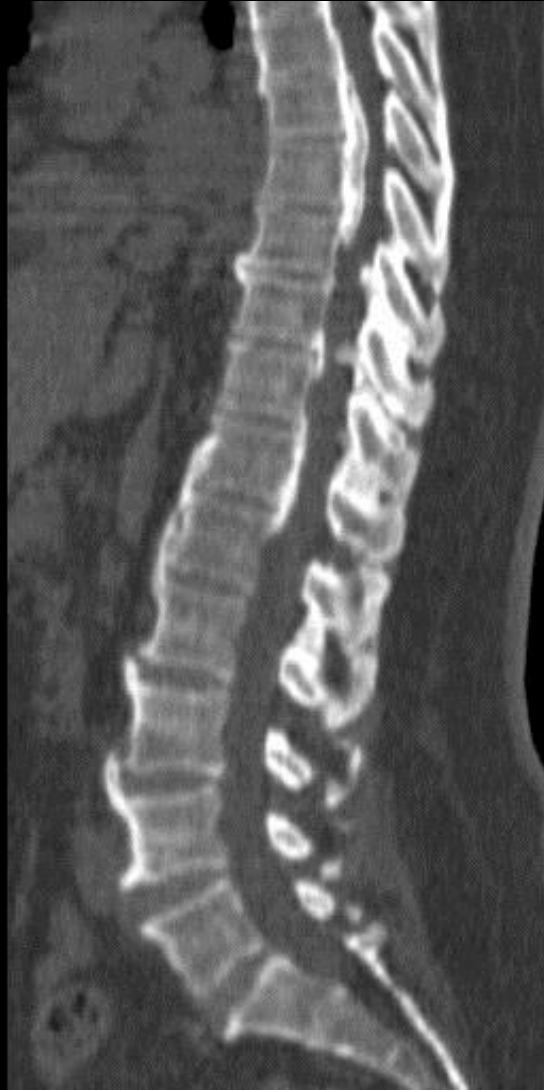
Morbus Bechterevi

- ankylotic spondylitis, morbus of Bechterew
- hereditary inflammatory chronic disease of vertebrae
- 1% of population, males 2-3x more often
- onset often between 18th and 30th year of age
- antigen HLA-B27 (7% of inhabitants of Czech Republic)
- in ill people in 90% cases
- in people with antigen HLA-B27 is the disease probability 300x higher
- chronic pain and **stiffness** in caudal part of column
- syndesmophytes → ankylosis of column („bamboo column“)
- *treatment: regular exercise*

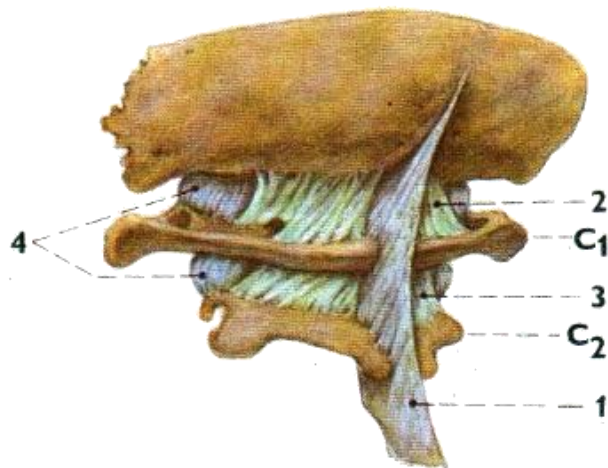


Morbus Bechterevi

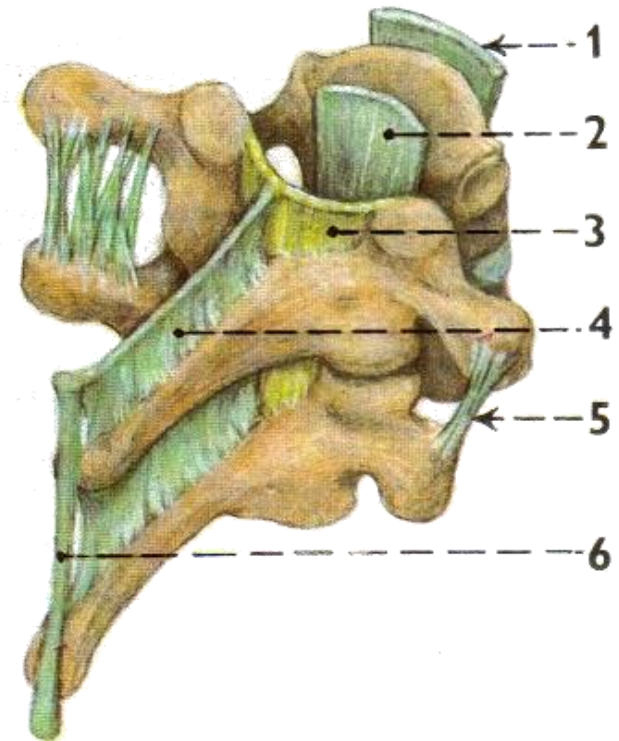


Short ligaments of column

- ligamenta flava – *elastic*, between arches
- ligg. intertransversaria
- ligg. interspinalia



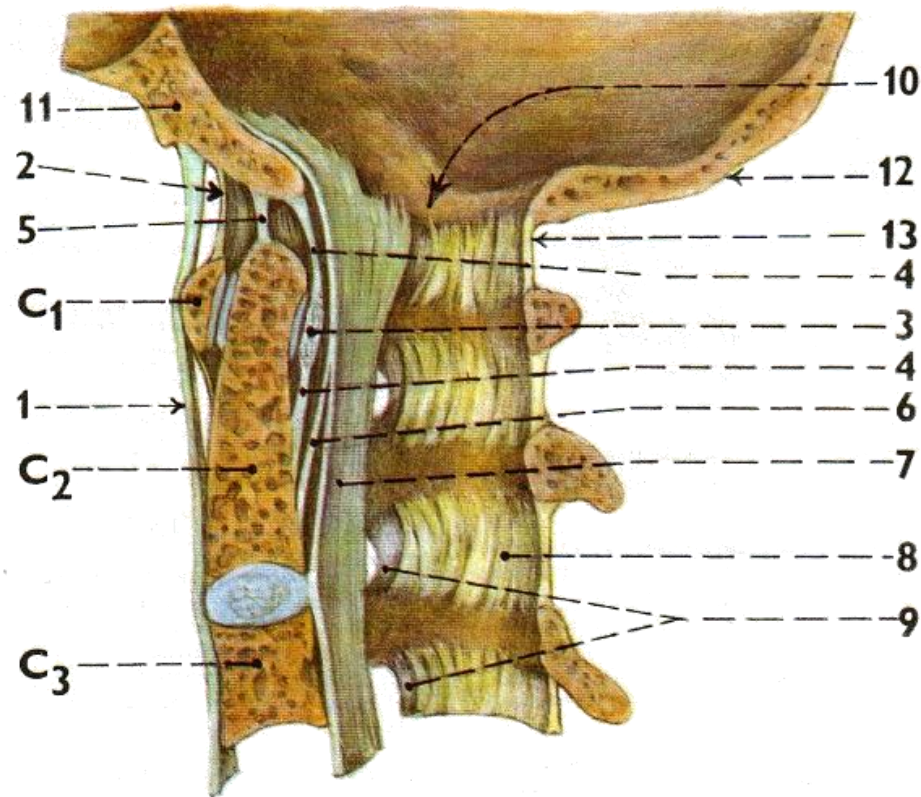
137. SPOJENÍ NA PÁTEŘI od týlní kosti po obratel C₂ (dorsální strana) – pohled zleva zezadu
 1/ ligamenta supraspinalia a lig. nuchae
 2/ membrana atlantooccipitalis posterior
 3/ ligamenta interarcualia mezi zadním obloukem atlasu a obloukem axis
 4/ kloubní pouzdra atlantookcipitálního a postranního atlantoaxiálního kloubu



135. LIGAMENTA PÁTEŘE v úseku hrudní páteře – pohled zprava zezadu
 1/ ligamentum longitudinale anterior
 2/ ligamentum longitudinale posterior
 3/ ligamenta interarcualia
 4/ ligamenta interspinalia
 5/ ligamenta intertransversaria
 6/ ligamenta supraspinalia

Articulatio atlantooccipitalis

- elipsoid joint
- condyli occipitales
- facies articularis superior atlantis
- membrana atlantooccipitalis ant. + post.
- lig. atlantooccipitale lat.



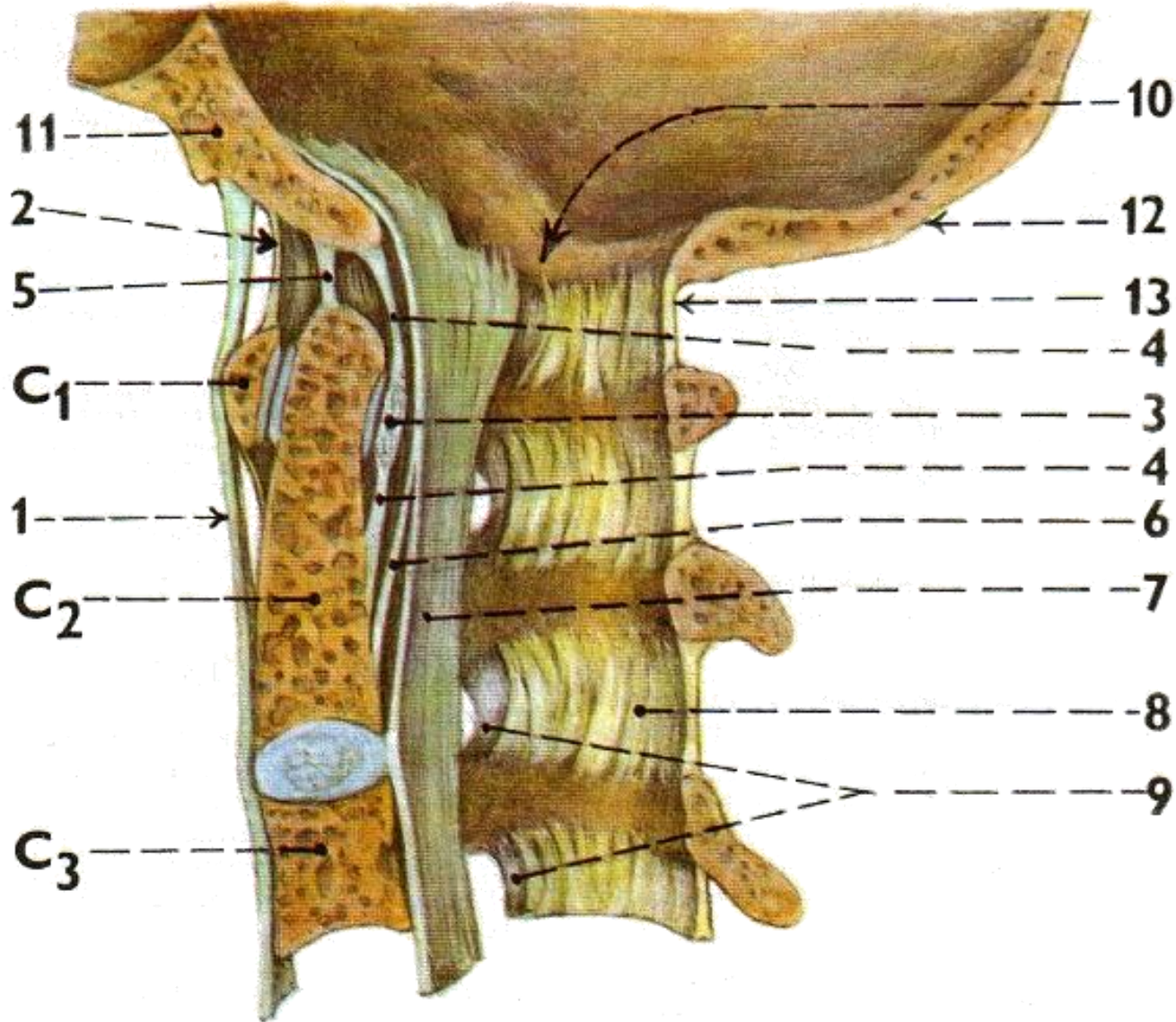
140. PODÉLNÝ ŘEZ KRANIOVERTEBRÁLNÍM SPOJENÍM (až po obratel C₃) – pohled zleva; (mírně zvětšeno)

- 1/ ligamentum longitudinale anterius
- 2/ membrana atlantooccipitalis anterior
- 3/ ligamentum transversum atlantis
- 4/ podélné snopce ligamentum cruciforme
- 5/ ligamentum apicis dentis
- 6/ membrana tectoria
- 7/ ligamentum longitudinale posterius

- 8/ ligamenta interarcualia
- 9/ pouzdra meziobratlových kloubů
- 10/ okraj foramen magnum
- 11/ tělo kosti týlní
- 12/ šupina kosti týlní
- 13/ membrana atlantooccipitalis posterior

Articulatio atlantooccipitalis (atlantooccipital joint)

Joint type	Simple, biaxial, elipsoid, mobile
Head	Condyli occipitales
Cavity	Facies articulares superiores (massae lateralis) atlantis
Articular capsule and its ligaments	Membrana atlantooccipitalis an. et post., lig. atlantooccipitale lat.
Movements	Anteflexion+retroflexion (pendular movements – head and neck as a whole up to 90°), lateroflexion (small interval)
Middle position	= basic position



140. PODÉLNÝ ŘEZ KRANIOVERTEBRÁLNÍM SPOJENÍM (až po obratel C₃) – pohled zleva; (mírně zvětšeno)

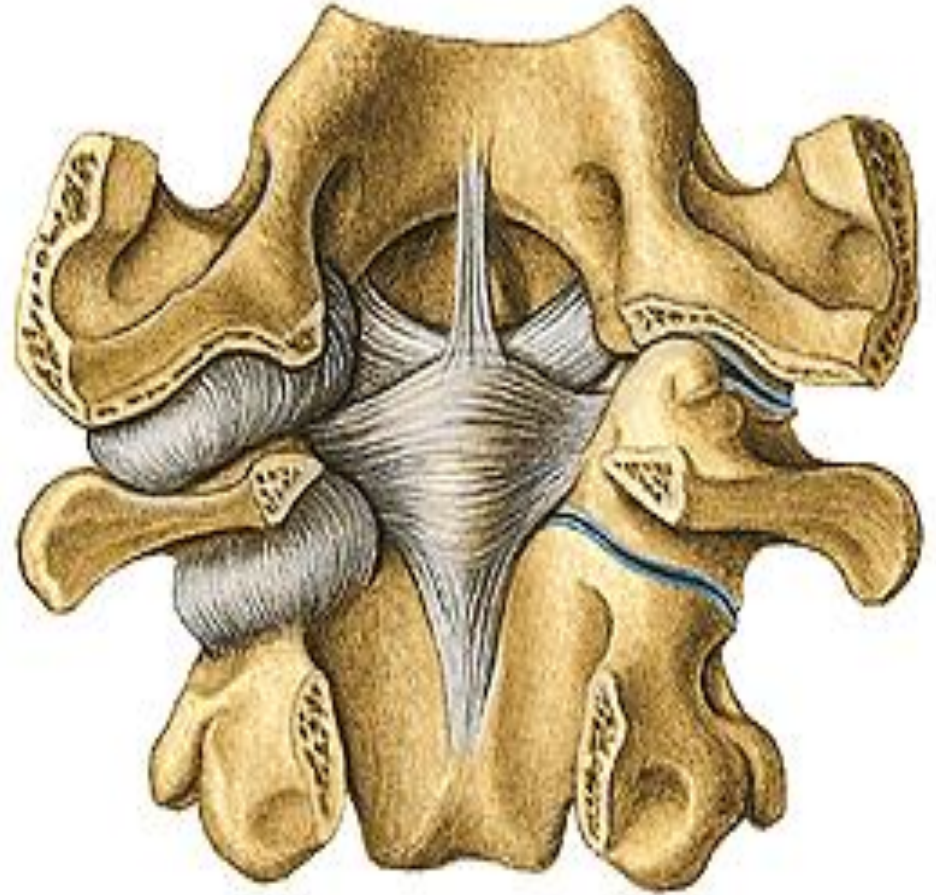
- | | |
|---|---|
| 1/ ligamentum longitudinale anterius | 8/ ligamenta interarcualia |
| 2/ membrana atlantooccipitalis anterior | 9/ pouzdra meziobratlových kloubů |
| 3/ ligamentum transversum atlantis | 10/ okraj foramen magnum |
| 4/ podélné snopce ligamentum cruciforme | 11/ tělo kosti týlní |
| 5/ ligamentum apicis dentis | 12/ šupina kosti týlní |
| 6/ membrana tectoria | 13/ membrana atlantooccipitalis posterior |
| 7/ ligamentum longitudinale posterius | |

Articulatio atlantoaxialis mediana + lateralis

AAAM – pivot joint

- ligg. alaria
- lig. apicis dentis
- lig. cruciforme atlantis
- lig. transversum atlantis
- fasciculi longitudinales
- membrana tectoria

AAAL – plane joint

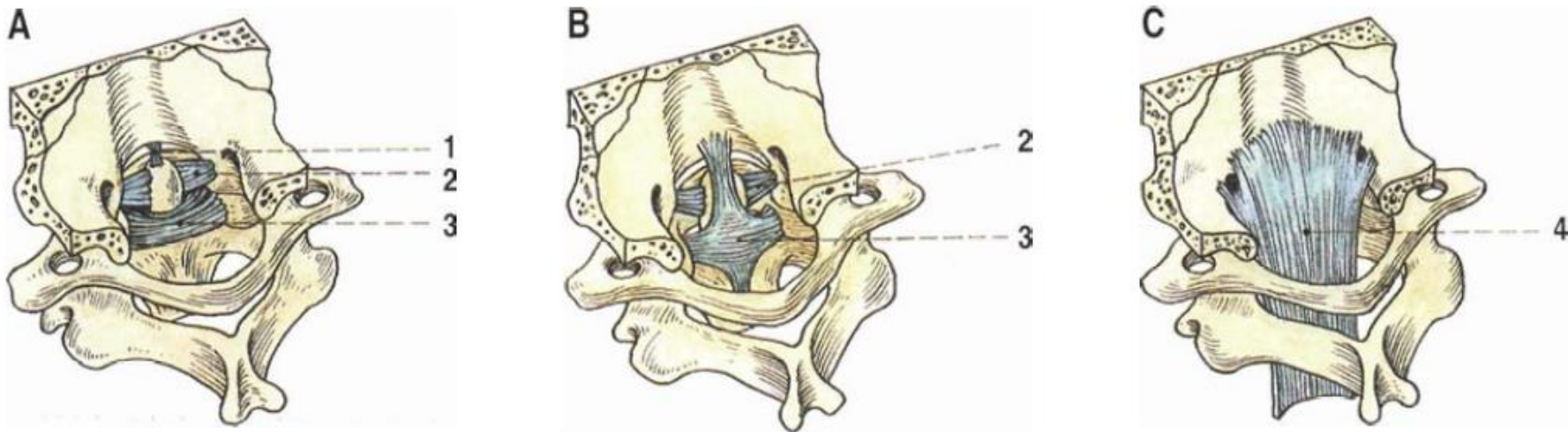


Articulatio atlantoaxialis mediana (Median atlantoaxial joint)

Joint type	Simple, 1-axial, pivot, mobile
Head	Dens axis
Cavity	Fovea dentis (arcus anterioris) atlantis
Articular capsule and its ligaments	Ligg. alaria, lig. apicis dentis, lig. cruciforme atlantis (fasciculi longitudinales + lig. transversum atlantis), membrana tectoria
Movements	Rotation (up to 30° on both sides)
Middle position	= basic position
Note	<i>Fractures of dens axis – danger of infraction to medulla oblongata</i>

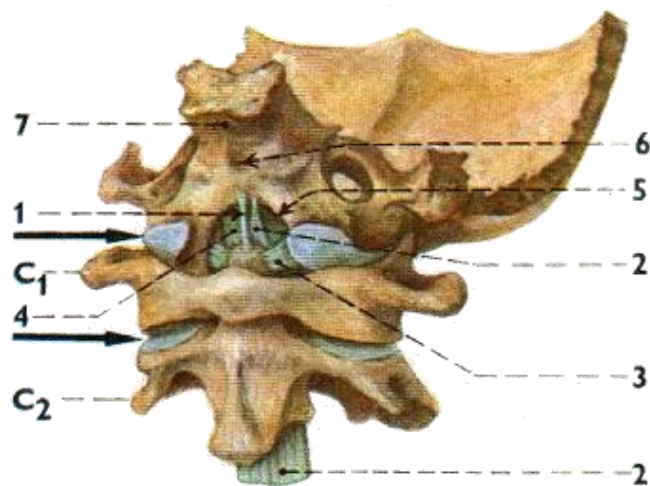
Articulatio atlantoaxialis lateralis (Lateral atlantoaxial joint)

Joint type	Simple, three-axial, flat, movable
(Head)	Facies articularis inferior axis
(Cavity)	Facies articularis inferior atlantis
Articular capsule and its ligaments	Ligg. alaria, lig. apicis dentis, lig. cruciforme atlantis (fasciculi longitudinales + lig. transversum atlantis), membrana tectoria
Notes	Anteflexion+retroflexion (head and neck as a whole up to 90°), lateroflexion (head and neck as a whole up to 45°), torsion (a+a up to °; head and neck as a whole 60-70°)



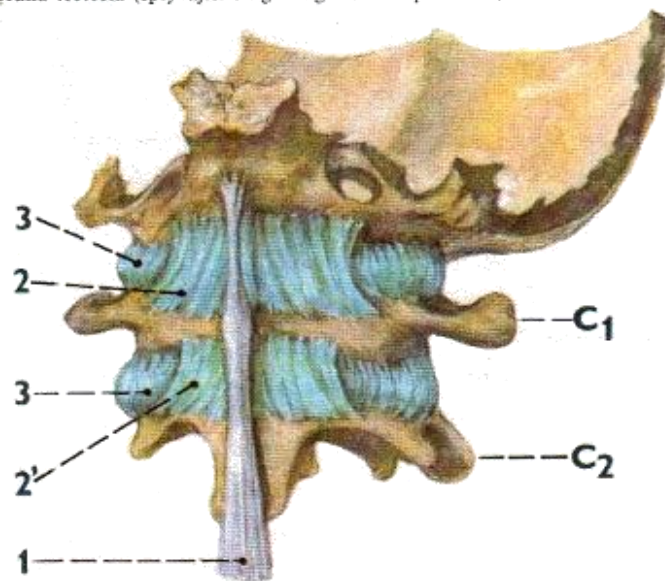
A. ventrální vrstva, B. střední vrstva, ligamentum transversum atlantis doplněné podélnými snopci v lig. cruciforme atlantis, C. dorsální vrstva oddělující skloubení od páteřního kanálu
 1/ ligamentum apicis dentis

2/ lig. alare
 3/ lig. transversum atlantis (na obr. A bez podélných pruhů, na obr. B jako lig. cruciforme)
 4/ membrana tectoria (splývající s lig. longitudinale posterius)



138. KRANIOVERTEBRÁLNÍ SPOJENÍ – pohled zepředu po odstranění části vazů, membrán a kloubních pouzder; articulatio atlantooccipitalis a articulatio atlantoaxialis lateralis (šipky)

- 1/ ligamentum apicis dentis
- 2/ ligamentum cruciforme atlantis, podélné pruhy (fasciculi longitudinales)
- 3/ ligamentum alare
- 4/ membrana tectoria
- 5/ okraj otvoru týlního
- 6/ tuberculum pharyngeum kosti týlní
- 7/ tělo kosti týlní



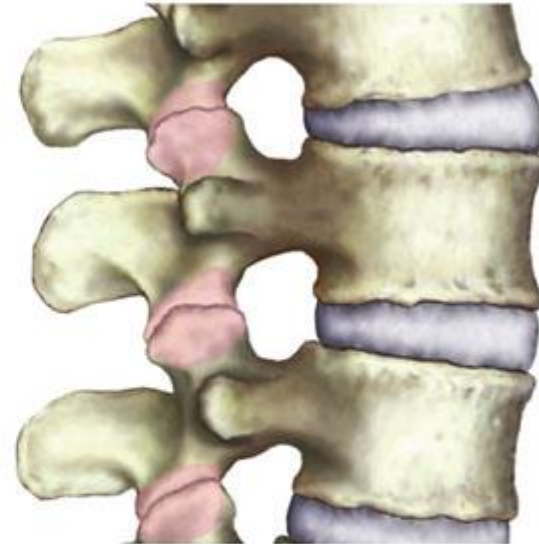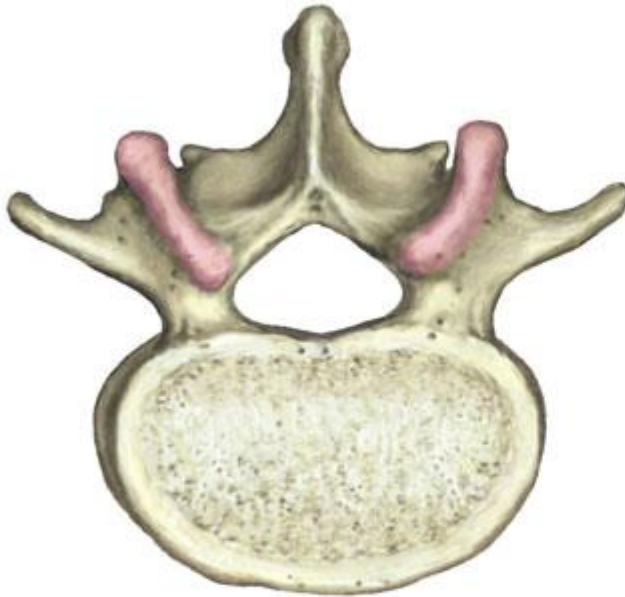
134. SPOJENÍ NA PÁTEŘI od týlní kosti po obratel C₂ – pohled z ventrální strany.

- 1/ ligamentum longitudinale anterius
- 2/ membrana atlantooccipitalis anterior
- 2/ obdoba předchozí membrány mezi atlasem a tělem axis
- 3/ kloubní pouzdro articulatio atlantooccipitalis a articulatio atlantoaxialis lateralis

Articulationes zygapophysiales

Zygapophysial joints

- plane
- in between processus articulares



Facet Joints

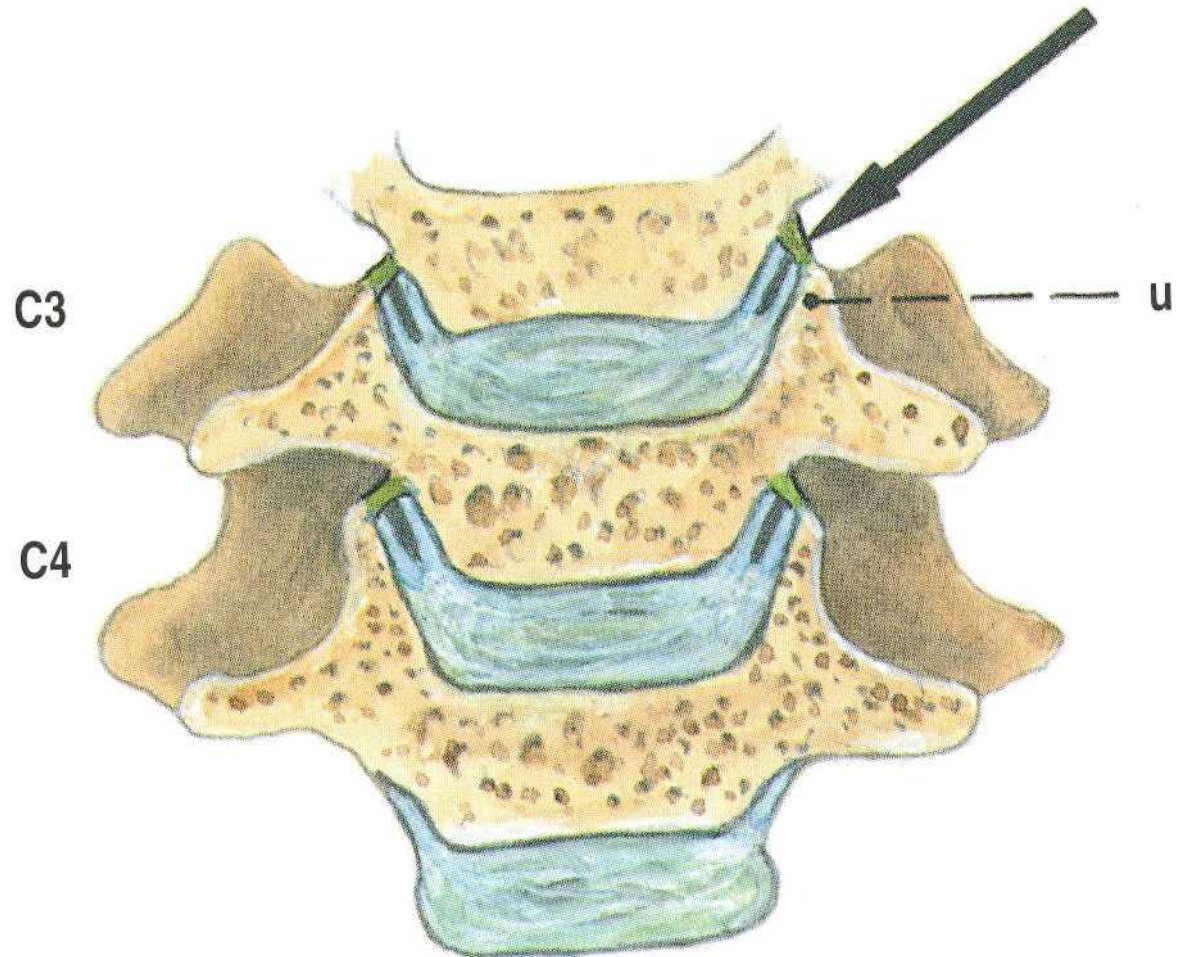
Articulationes zygapophysiales

Joint type	Simple, three-axial, plane, mobile
(Head)	Processus articularis superior
(Cavity)	Processus articularis inferior
Articular capsule and its ligaments	Ligg. interspinalia, ligg. flava, lig. supraspinale, lig. longitudinale anterius, lig. longitudinale posterius (reinforcing syndesmoses in vicinity); lig. iliolumbale
Movements	Anteflexion+retroflexion (head and neck as a whole up to 90°; thorax, especially last vertebrae 90°/45°, lumbar 90°/23°) lateroflexion (head and neck as a whole up to 30°; thorax limited by ribs, lumbar up to 35°) Torsion (a+a up to 30°; head and neck as a whole 60-70°, thorax up to 30°, lumbar 5-10°) spring movements
Middle position	= basic position
Note	<i>Meniscoid shapes</i> (special structure of joint) – extensions of synovial membrane (vasculated and innervated)

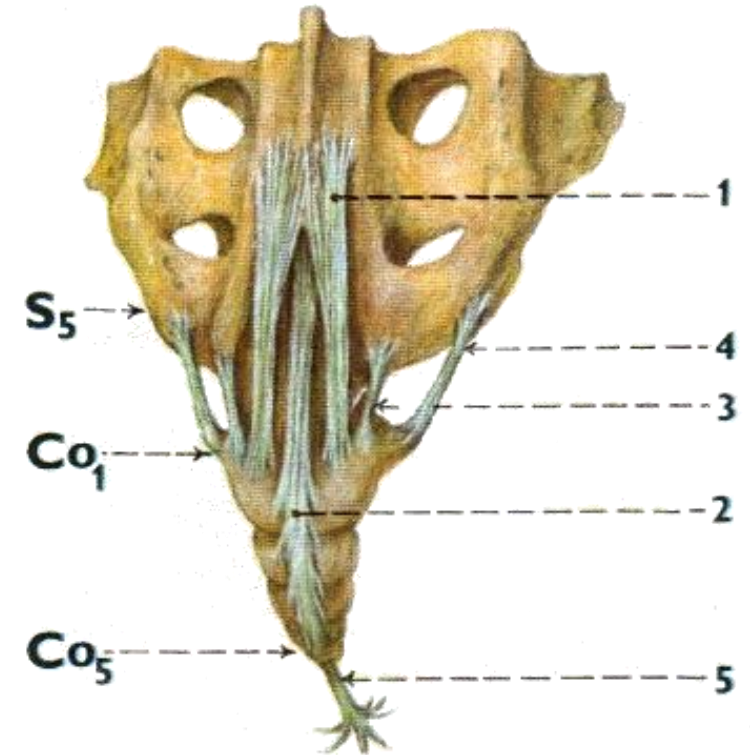
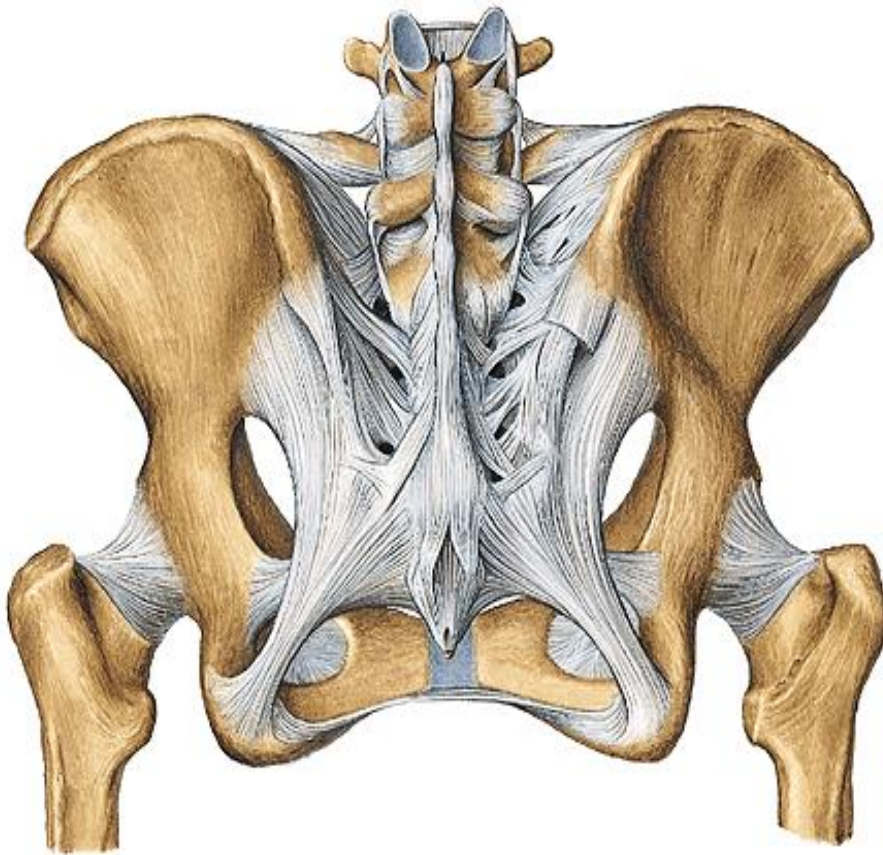
Articulationes uncovertebrales

Uncovertebral joints

- between *uncus corporis vertebrae* of the lower vertebra and lateral surface of the upper vertebra
- C2-C7 (T1)



- Articulatio lumbosacralis (lumbosacral joint)
- Symphysis sacrococcygea (sacrococcygeal joint)



136. LIGAMENTA KŘÍŽOVÉ KOSTI A KOSTRČE – pohled zezadu

- 1/ ligamentum sacrococcygeum dorsale superficiale (uprostřed vyříznuté, aby bylo vidět do hiatus sacralis)
- 2/ ligamentum sacrococcygeum dorsale profundum
- 3/ vazivové přemostění mezi cornu sacrale a cornu coccygeum
- 4/ ligamentum sacrococcygeum laterale
- 5/ retinaculum caudale cutis

Articulatio lumbosacralis (lumbosacral joint)

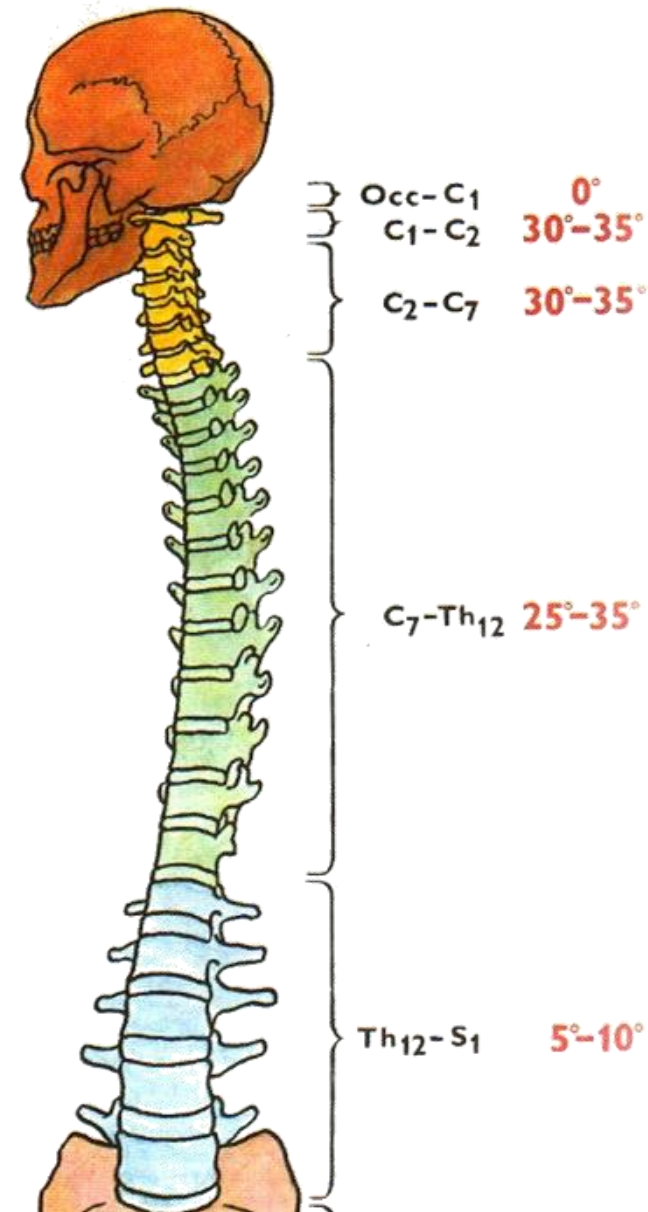
Joint type	Simple, three-axial, plane, mobile
Head	Facies articularis superior vertebrae (on processus articularis superior)
Cavity	Facies articularis inferior vertebrae (on processus articularis inferior)
Articular capsule and its ligaments	Ligg. interspinalia, ligg. flava, ligg. intertransversaria, lig. supraspinale, lig. longitudinale anterius, lig. longitudinale posterius (reinforcing syndesmoses in vicinity)
Movements	Minimal in all directions
Middle position	= basic position

Symphysis sacrococcygea (sacrococcygeal joint)

Joint type	Usually junctura cartilaginea - symphysis
Head	Apex ossis sacri
Cavity	Os coccygis (cranial end)
Ligaments	Lig. sacrococcygeum posterius superficiale et profundum, lig. sacrococcygeum anterius, lig. sacrococcygeum laterale
Movements	Minimal in all directions
Notes	Dissolves during pregnancy and delivery by relaxin May be replaced by synostosis or synovial joint

Movements of column as a whole

- **anteflexion/retroflexion** = bend forward/backward
 - C – 50° ventrally and 70° dorsally
 - T – minimal (ribs)
 - L – 25° ventrally, 90° dorsally
- **lateroflexion** = side bend
 - C – 45° to one side
 - T – minimal (due to ribs)
 - L – 35° to one side
- **torsion** (rotation of two structure against each other)
 - C – 70° (30° in artt. atlantoaxiales)
 - T – 30°
 - L – 10°
- **spring movements**

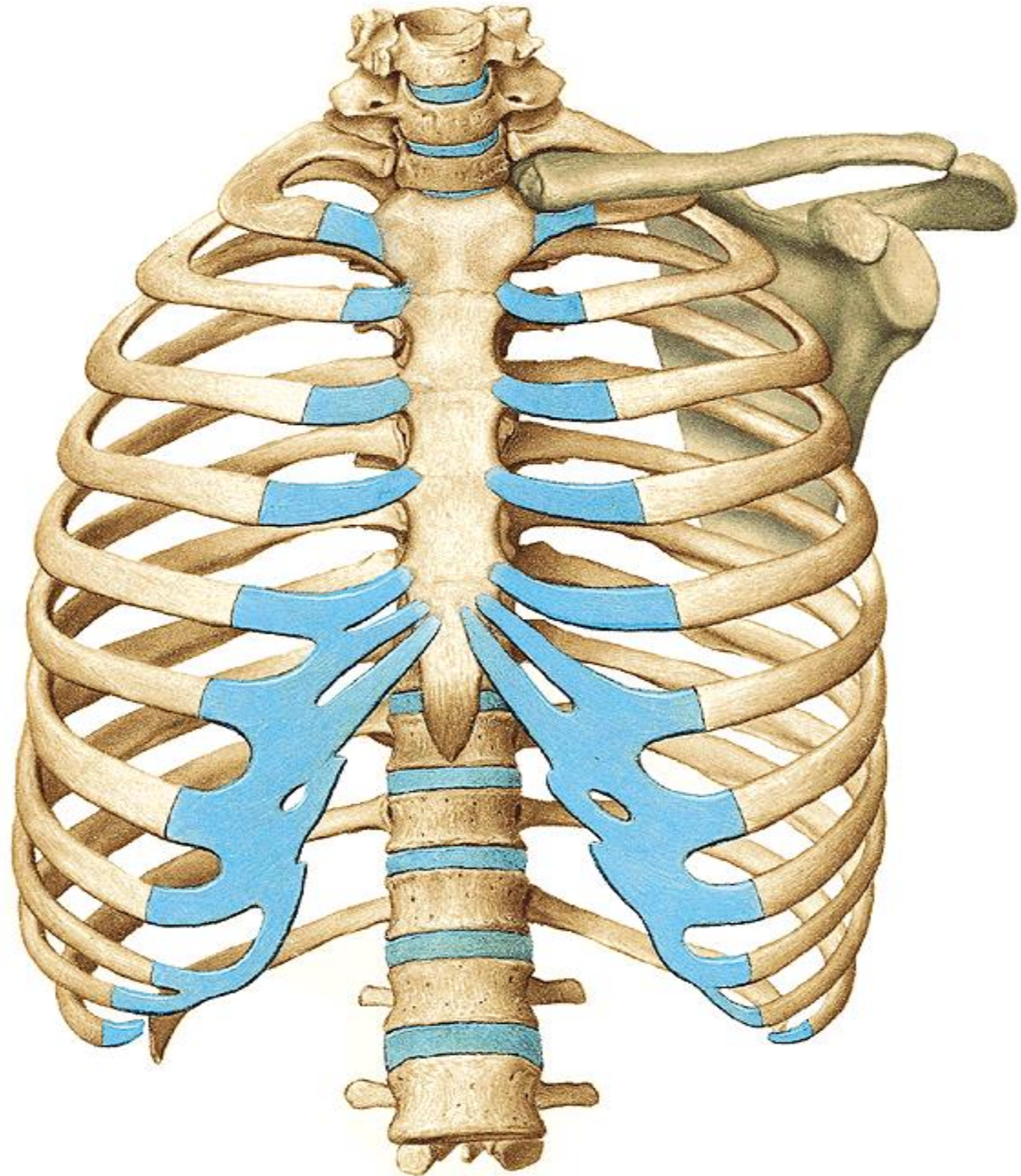


Thorax

Thorax

- true ribs (I-VII)
- false ribs (VIII-X)
- free ribs (XI, XII)

- cartilago costalis



Rib = *Costa*

Caput costae

Facies articularis capitis costae

Crista capitis costae

Collum costae

Crista colli costae

Corpus costae

Tuberculum costae

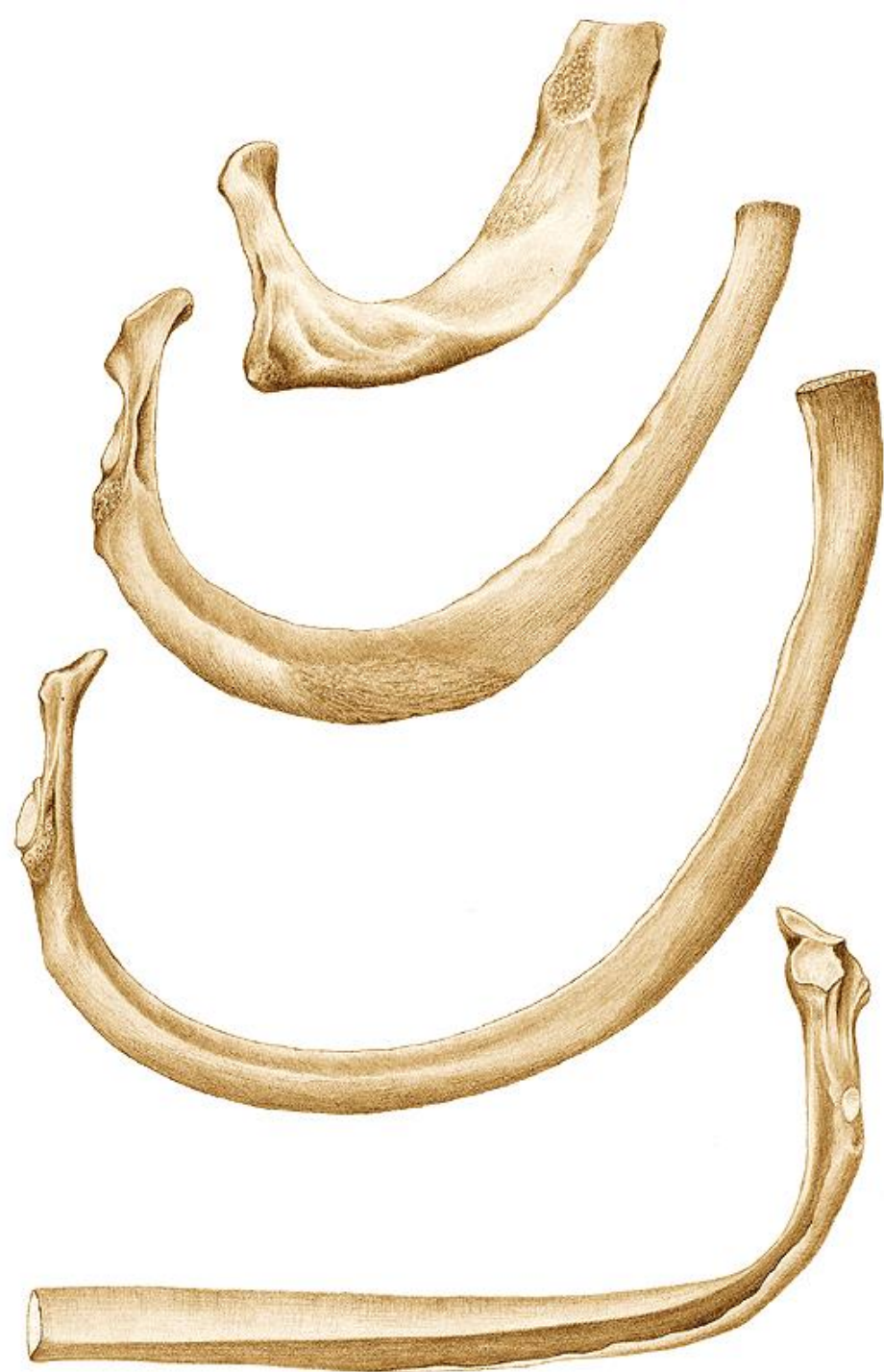Facies articularis tuberculi
costae

Angulus costae

Sulcus costae

Crista costae

(Costa cervicalis)



Different ribs

Costa prima [I]

Tuberculum musculi
scaleni anterioris

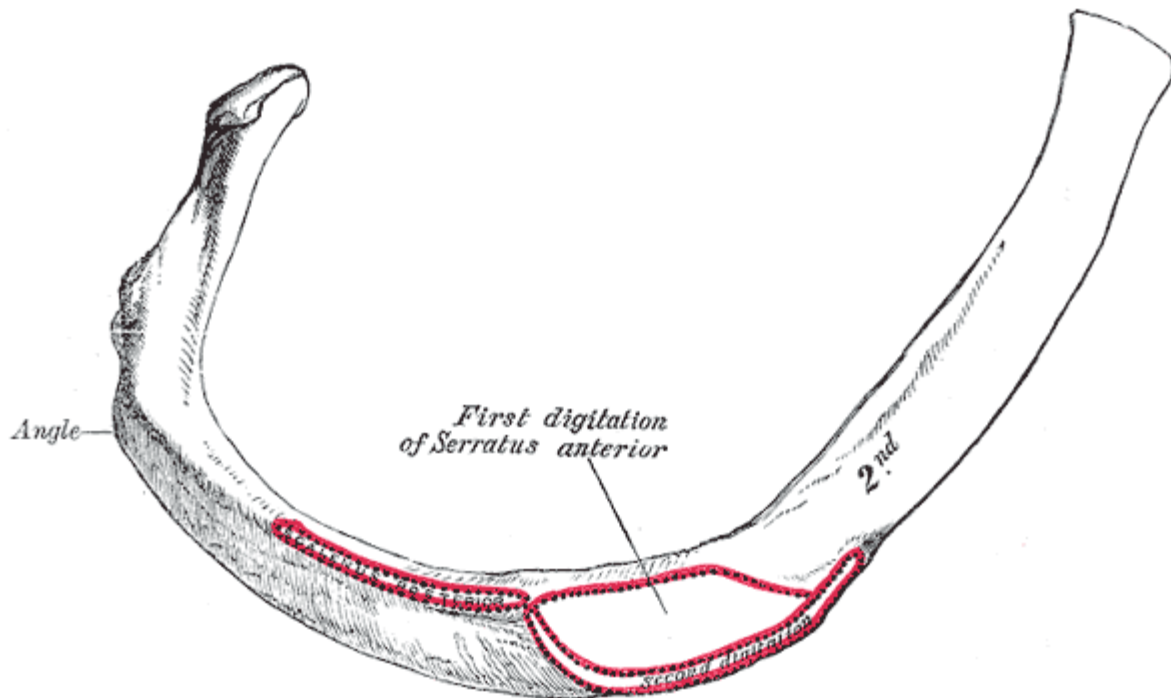
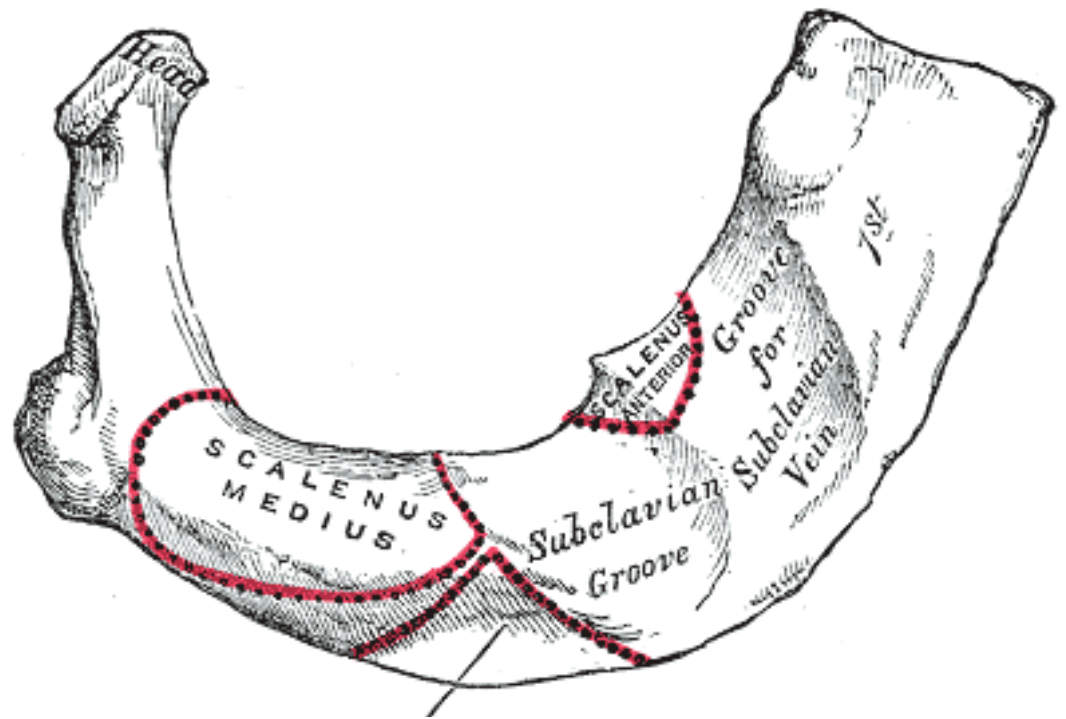
Tuberculum musculi
scaleni medii

Sulcus arteriae
subclaviae

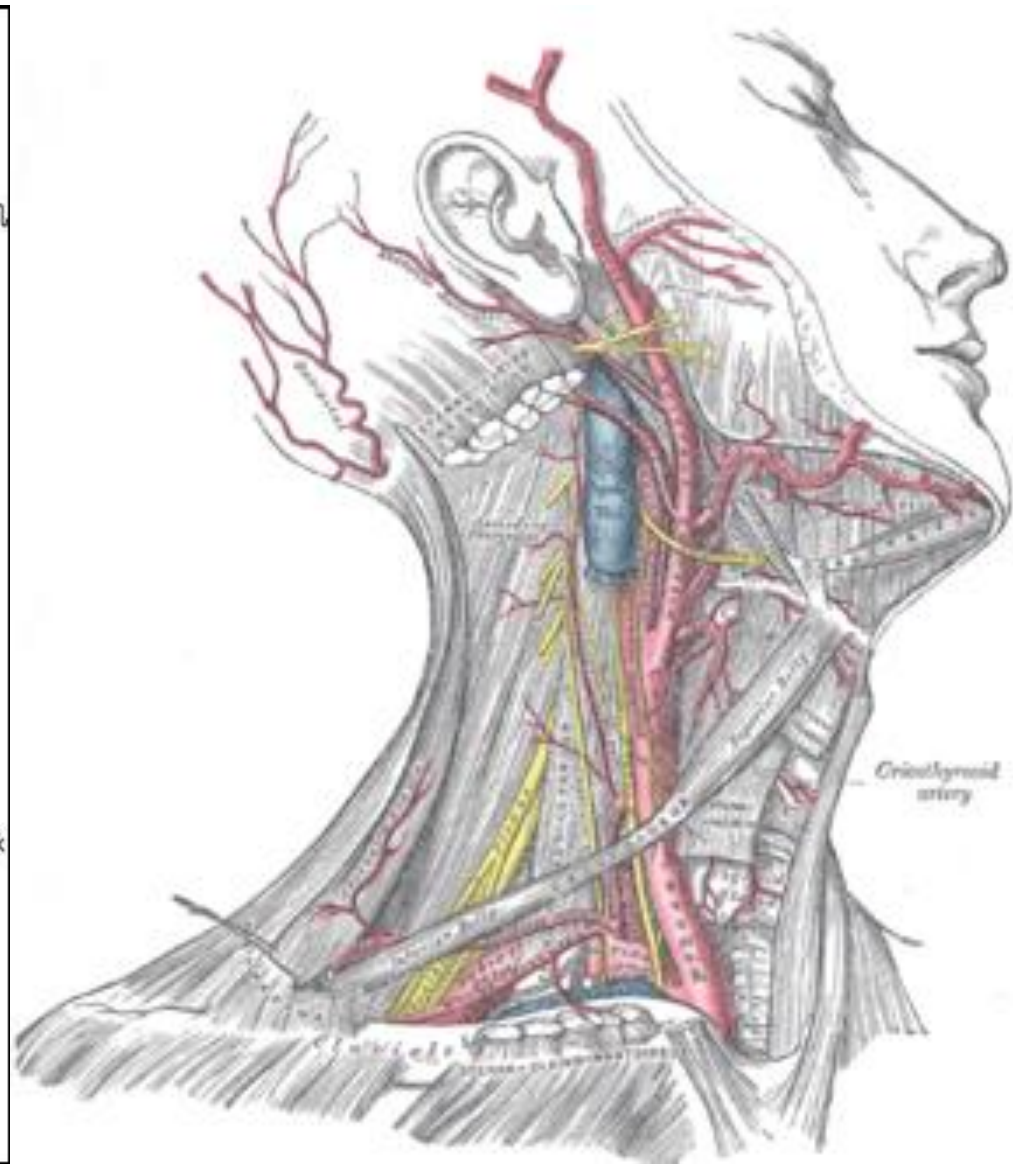
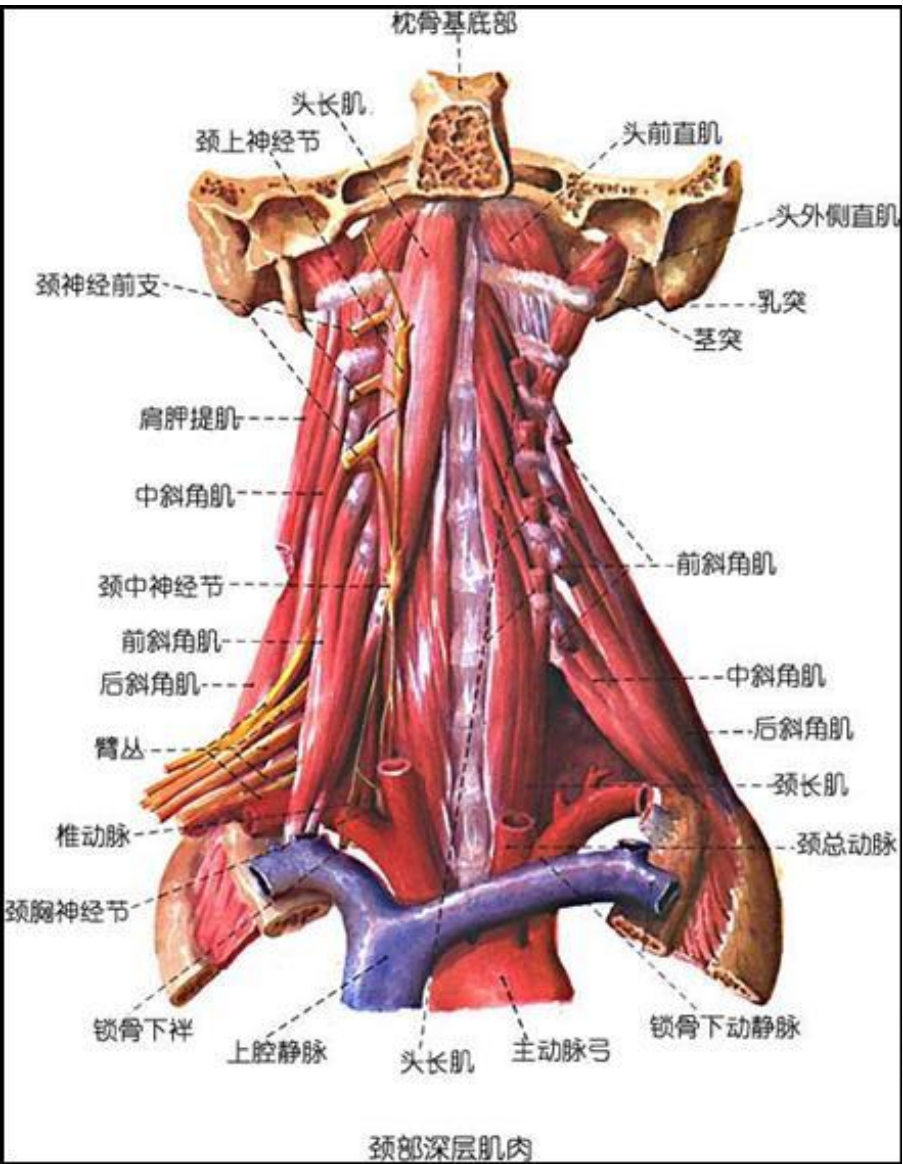
Sulcus venae
subclaviae

Costa secunda [II]

Tuberositas musculi
serrati anterioris

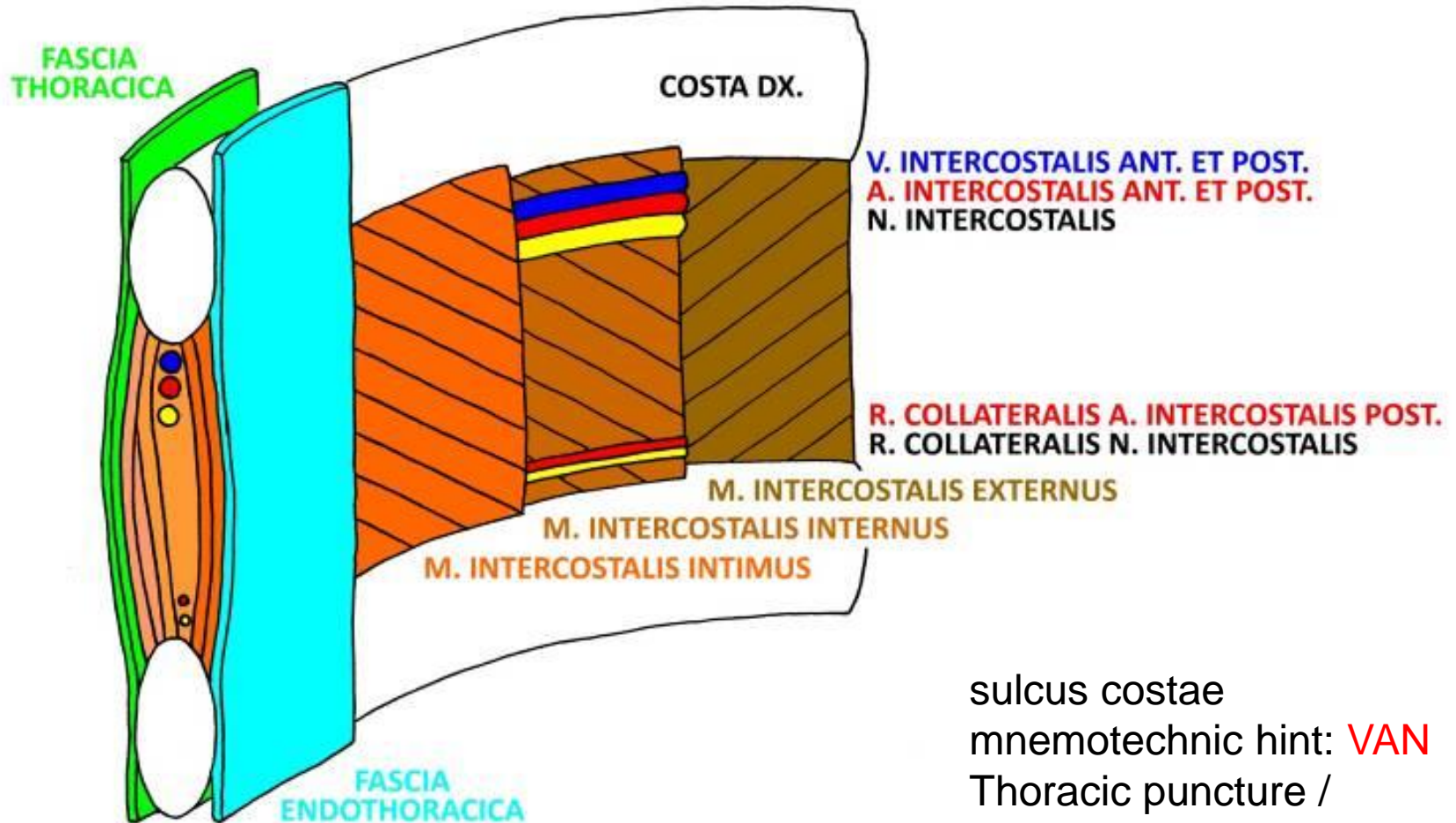


Fissura scalenorum



Spatium intercostale

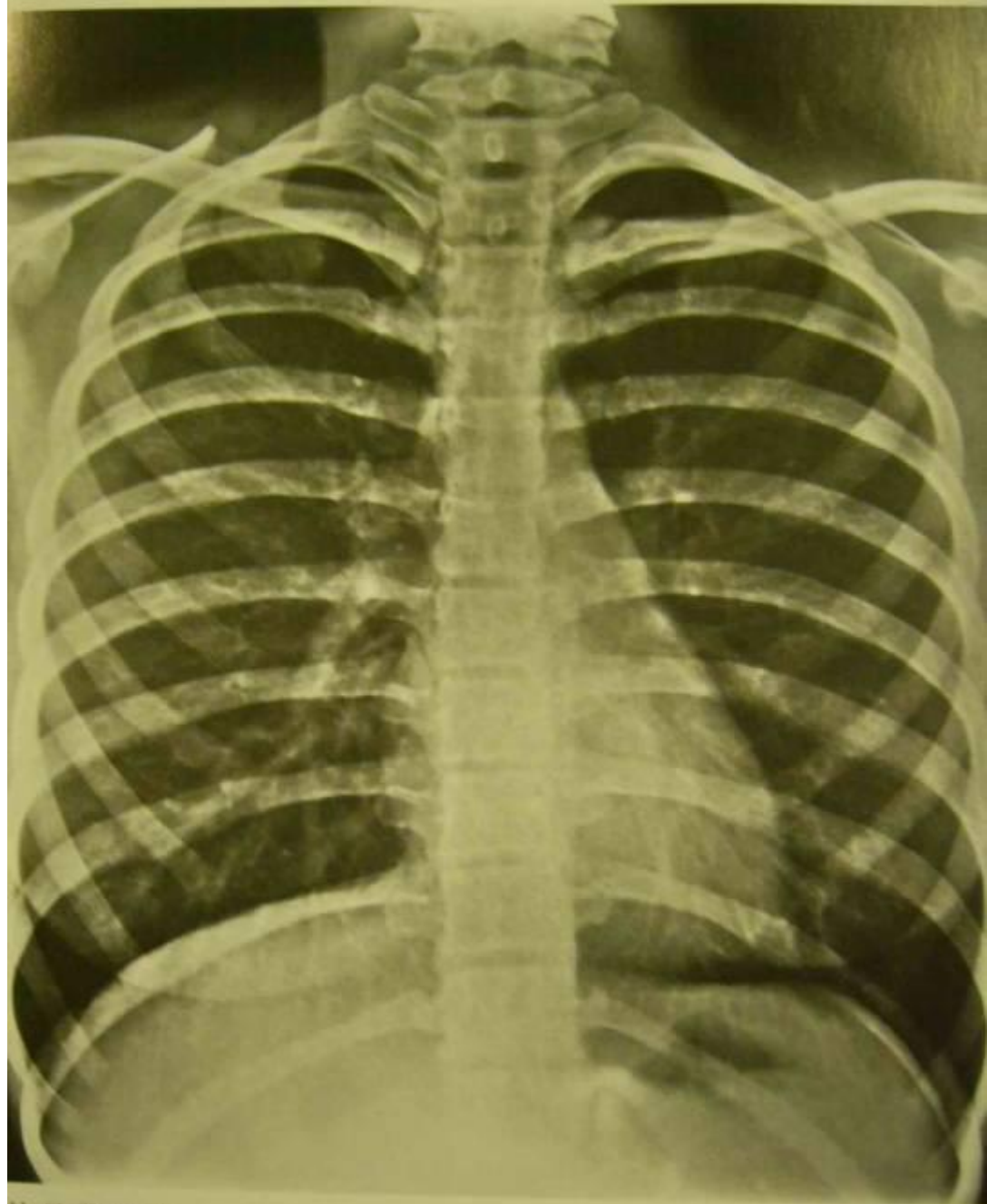
Intercostal space



sulcus costae
mnemotechnic hint: **VAN**
Thoracic puncture /
drainage

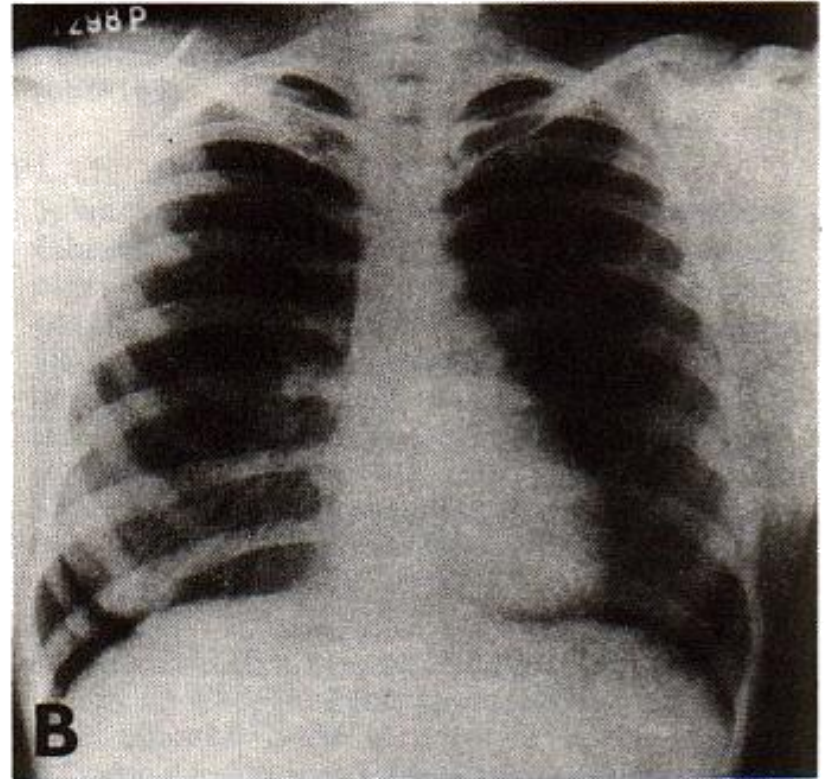
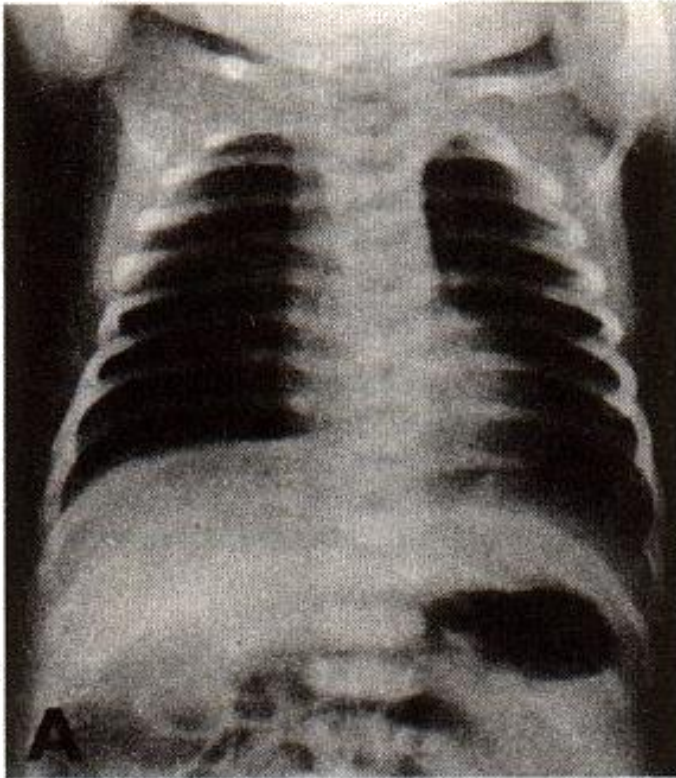
Thorax as a whole

- cavitas thoracis
- apertura thoracis superior + inferior
- arcus costalis
- angulus infrasternalis
- spatium intercostale



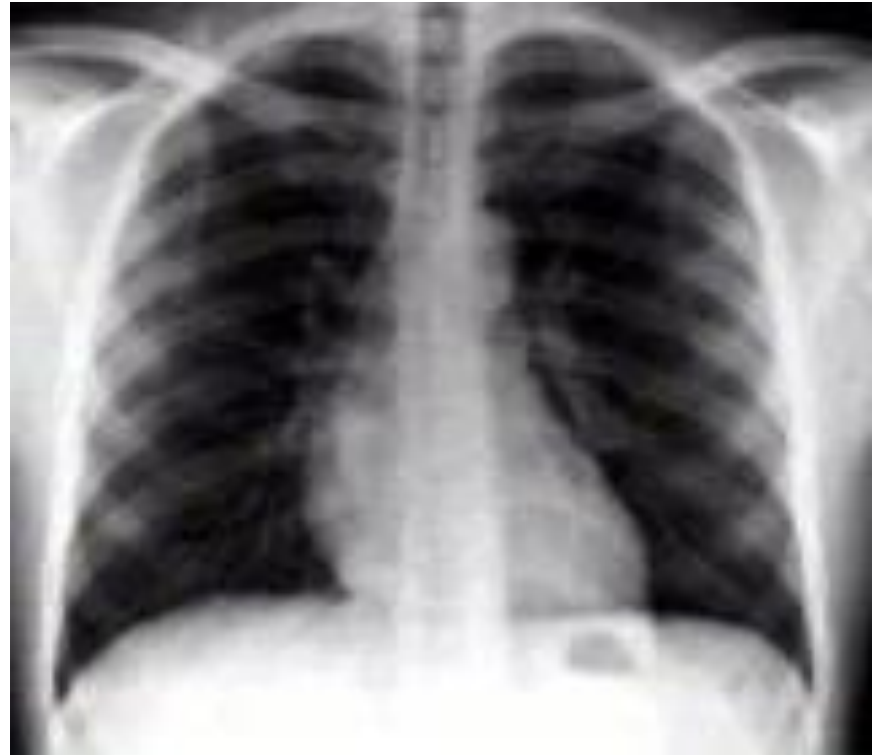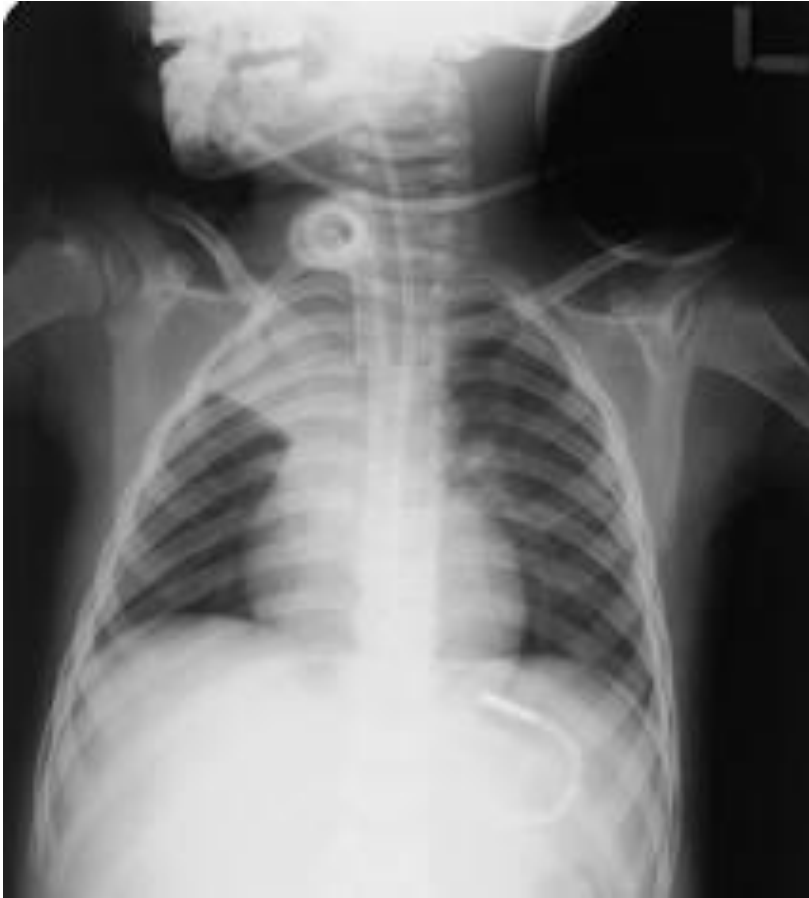bb. 61. Thorax p.a.

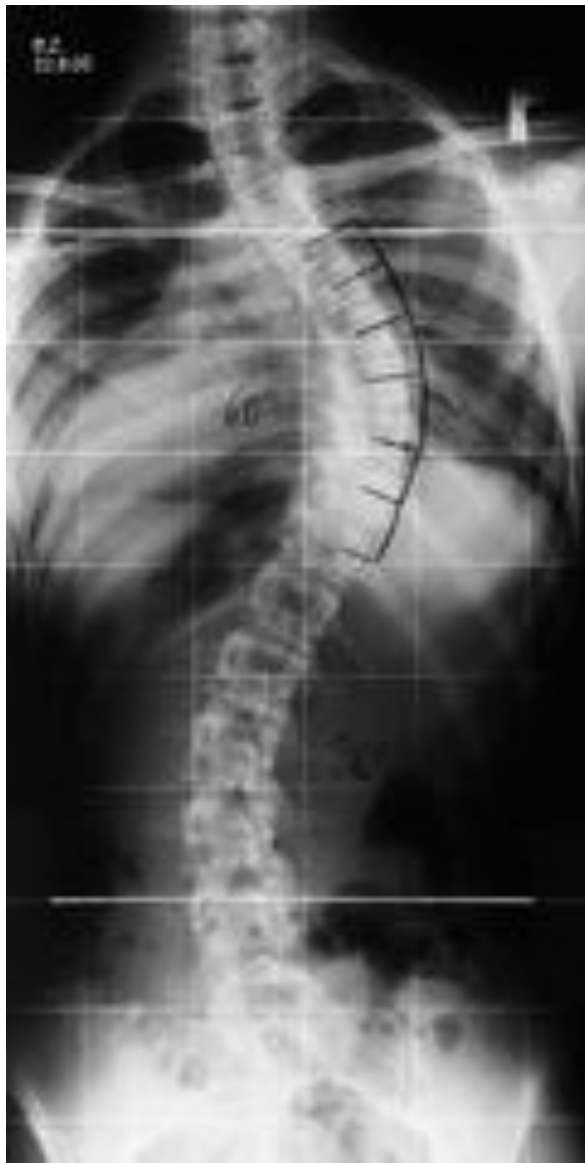X-ray of thorax



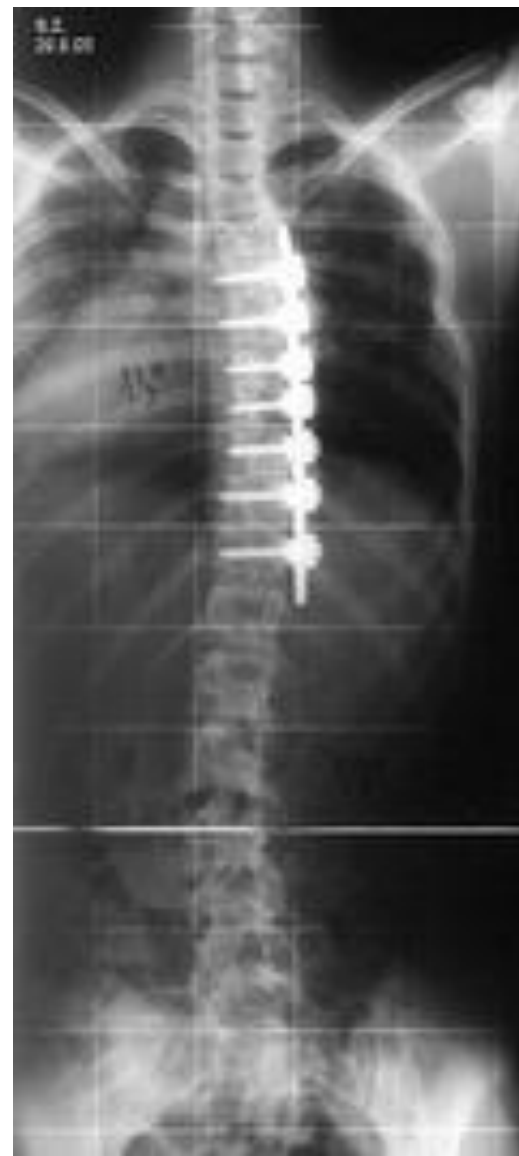167. ROZDÍL TVARU HRUDNÍKU NOVOROZENCE A HRUDNÍKU DOSPĚLÉHO na rtg snímku (předozaďní projekce):
A. novorozenec, B. dospělý

X-ray of thorax



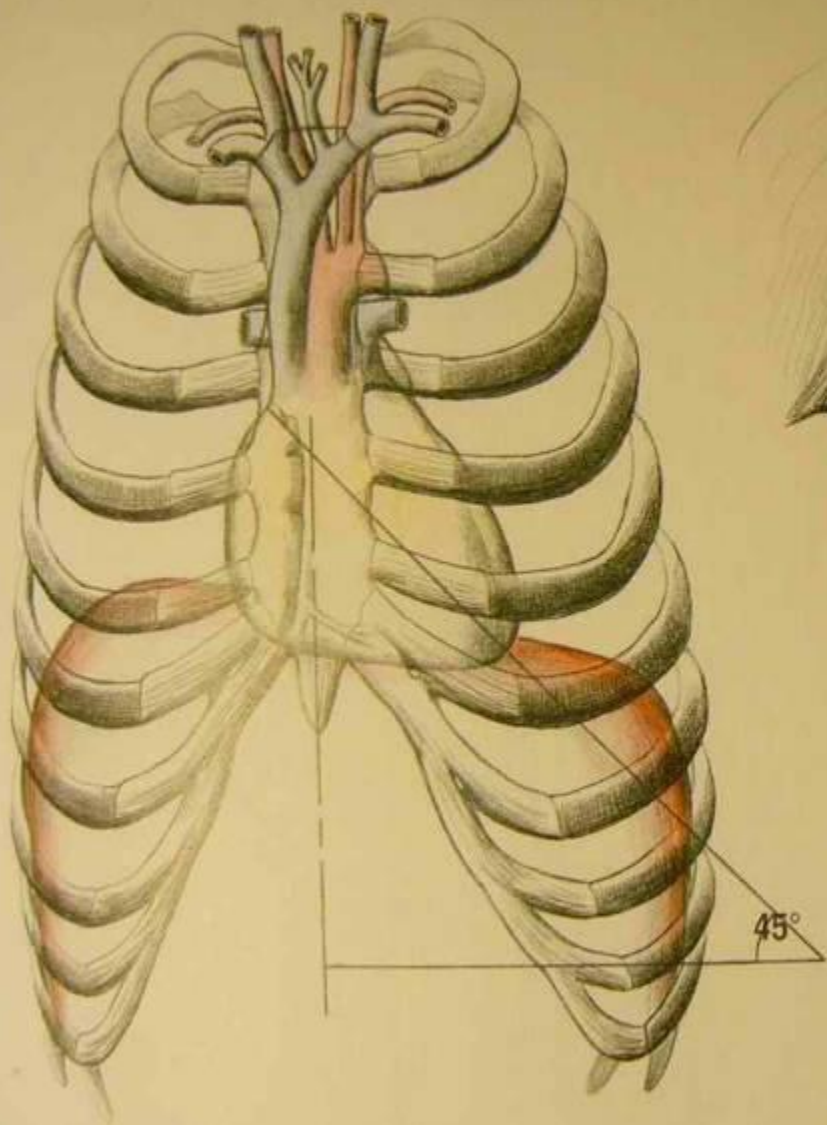


Anteroposterior x-ray of idiopathic thoracic scoliosis before operation – thoracic curve 60°

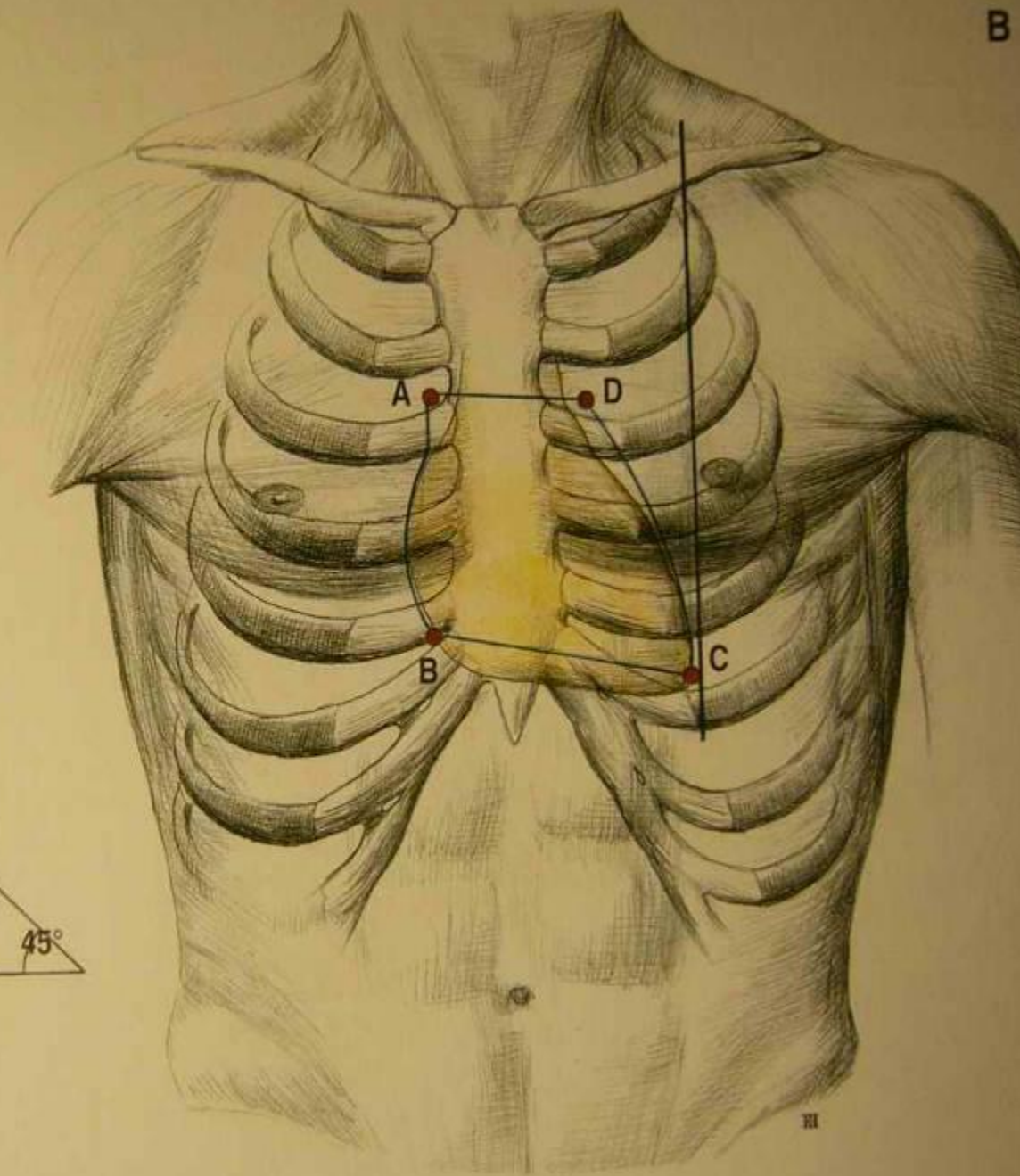


Anteroposterior x-ray of idiopathic thoracic scoliosis after operation from ventral approach with instrumentation – correction on 13°

A



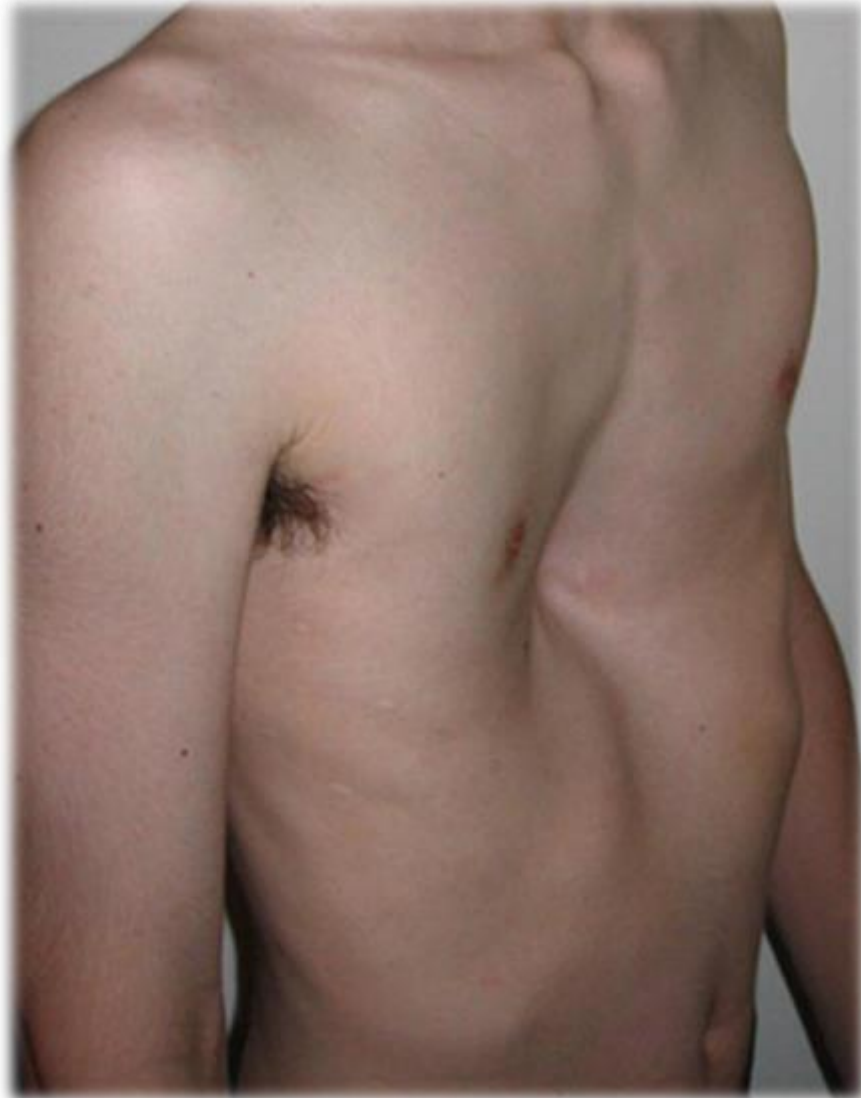
B



HI

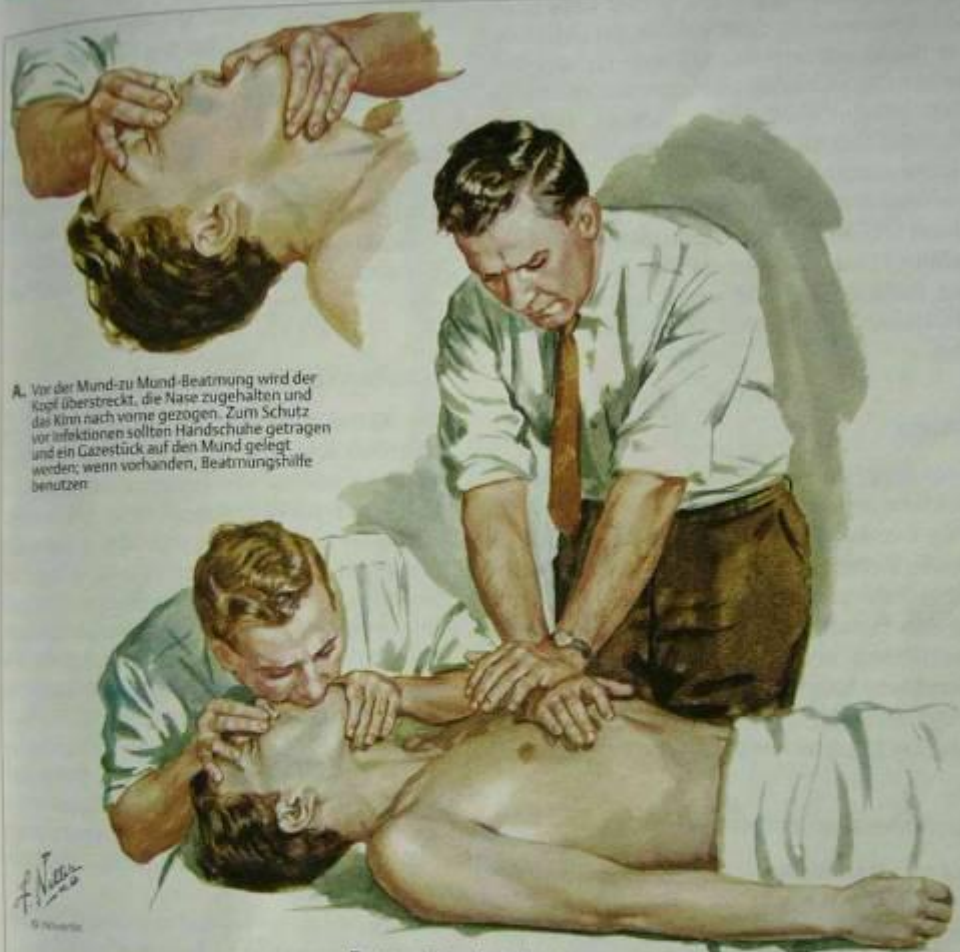Pectus excavatum

Inward chest



Clinical notes

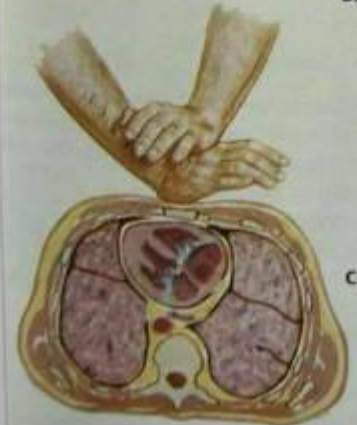
- individual ribs cross each other on X-ray
- isolated injury of the 1st rib is frequent, treatment usually conservative
- *cave*: pneumothorax, haemothorax, rupture of pericardium
- segmental fracture, serial fracture, door fracture (non-stabile thorax → life danger)
- fractures by CPR



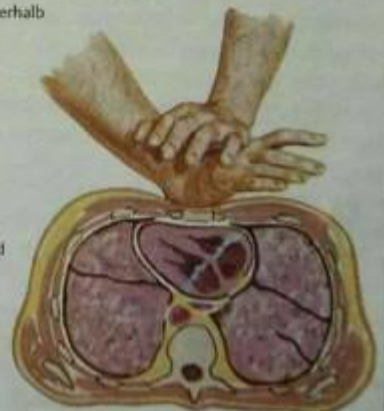
A. Vor der Mund-zu-Mund-Beatmung wird der Kopf überstreckt, die Nase zugehalten und das Kinn nach vorne gezogen. Zum Schutz vor Infektionen sollten Handschuhe getragen und ein Gazestück auf den Mund gelegt werden; wenn vorhanden, Beatmungshilfe benutzen.

F. Neugebauer
© 1974/1975

B. Intermittierend wird mit dem Handballen Druck auf das untere Sternumdrütel ausgeübt; Druckpunkt: 2 Querfinger oberhalb des unteren Sternumrandes

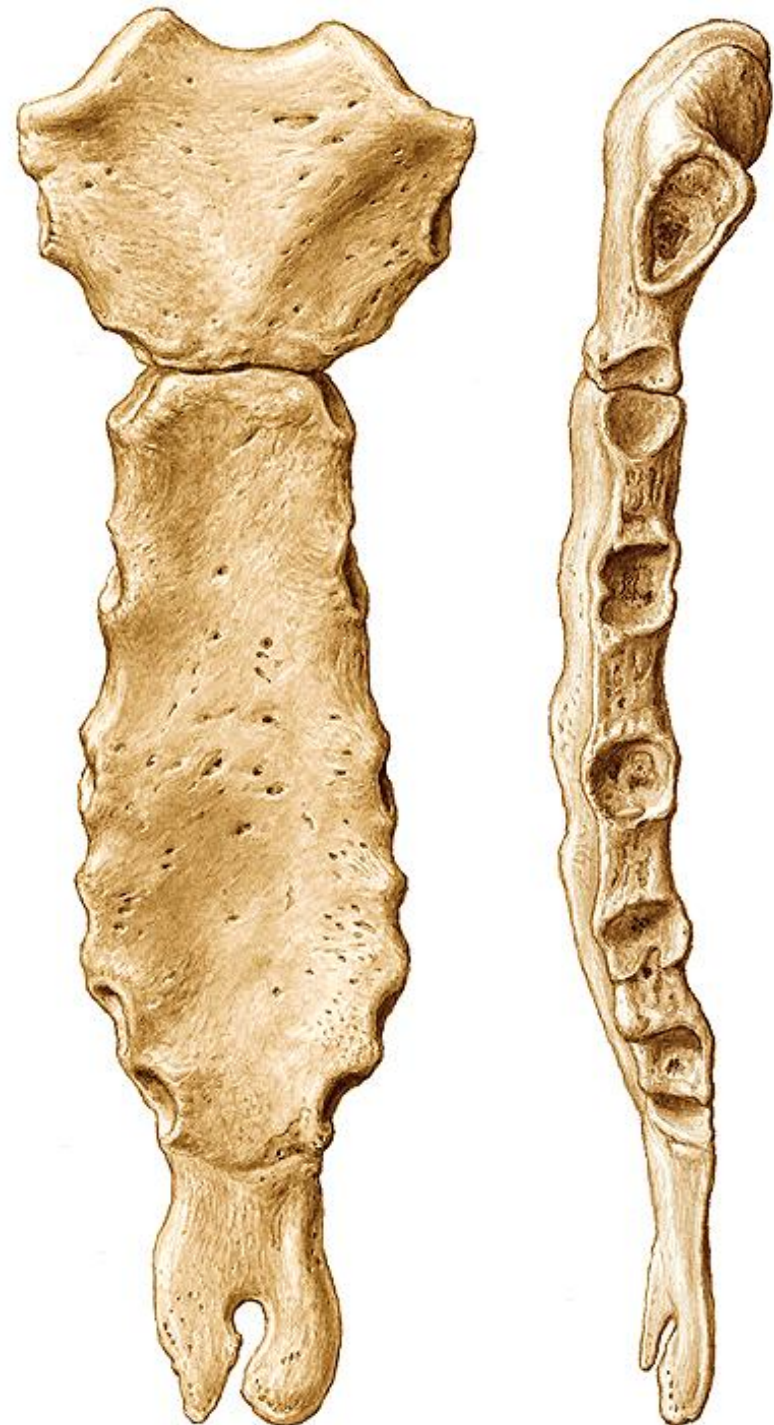


C. Das Herz wird intermittierend zwischen Brustbein und Wirbelsäule komprimiert

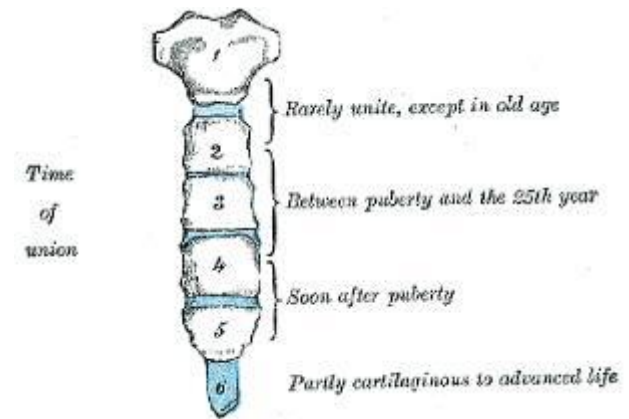


Sternum (*Sternum*)

Manubrium sterni
Incisura clavicularis
Incisura jugularis
Angulus sterni <i>Ludovici</i>
Corpus sterni
Processus xiphoideus
Incisurae costales



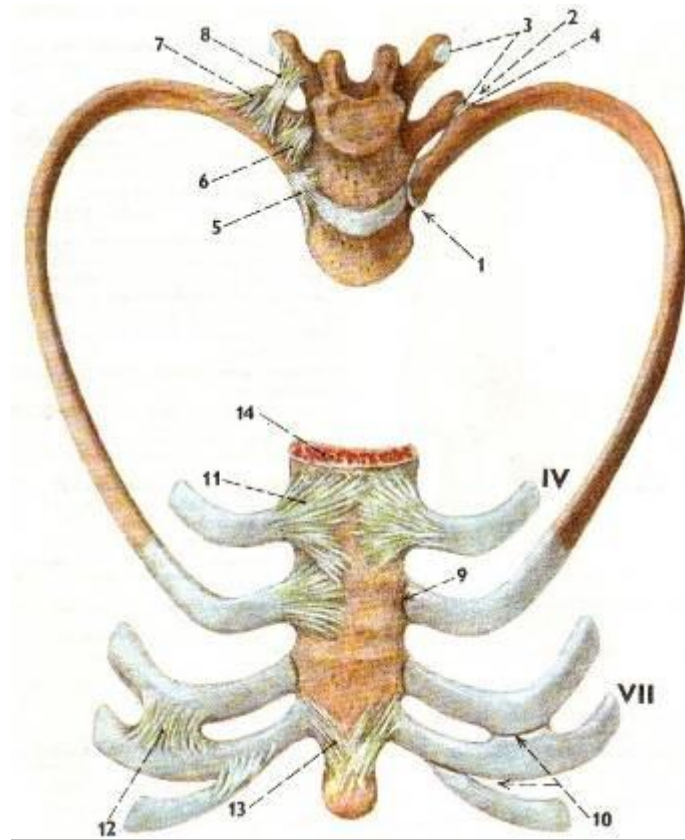
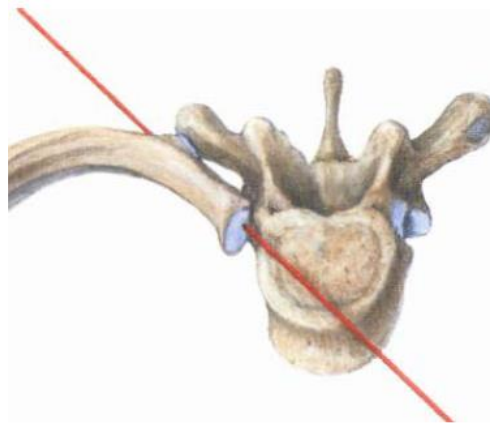
Clinical notes



- a hole in the sternum as a result of impaired fusion of sternal segments = *sternebrae*
- fractures of sternum are not common
 - only in case of great violence (contusion S+P, fractures of T column)
- sternotomy – cardiosurgery (rigid fixation)
- puncture of bone marrow
- CPR

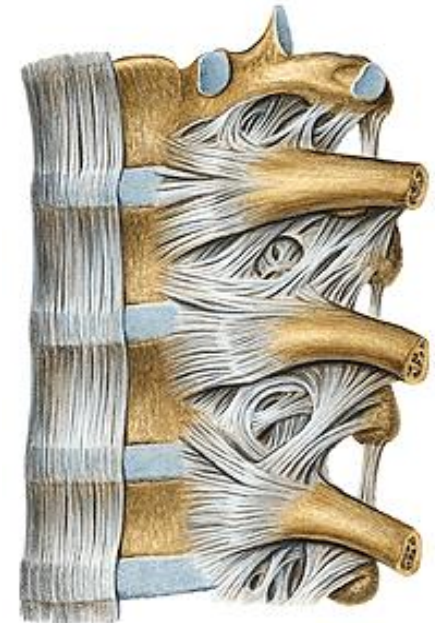
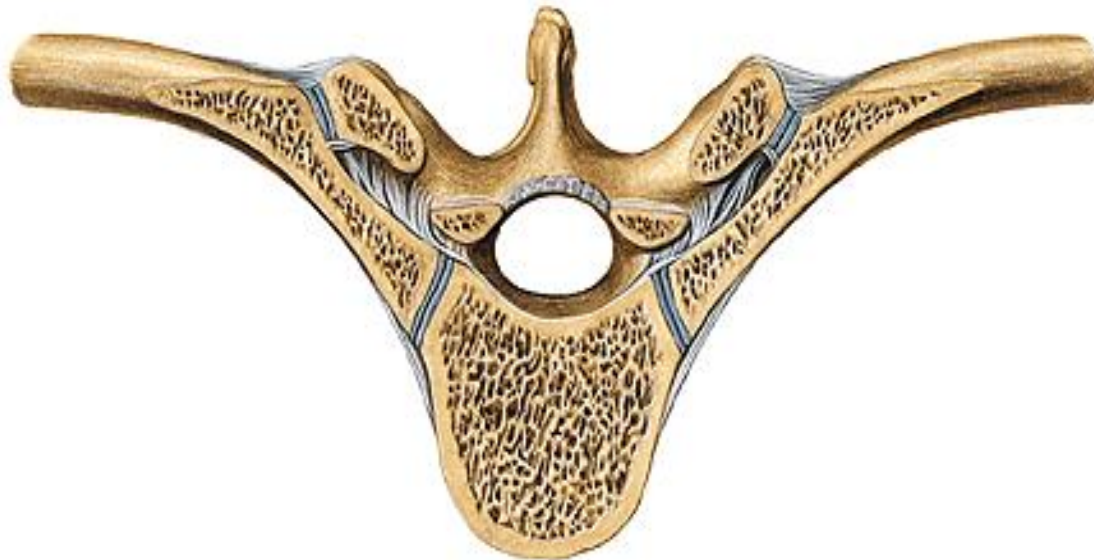
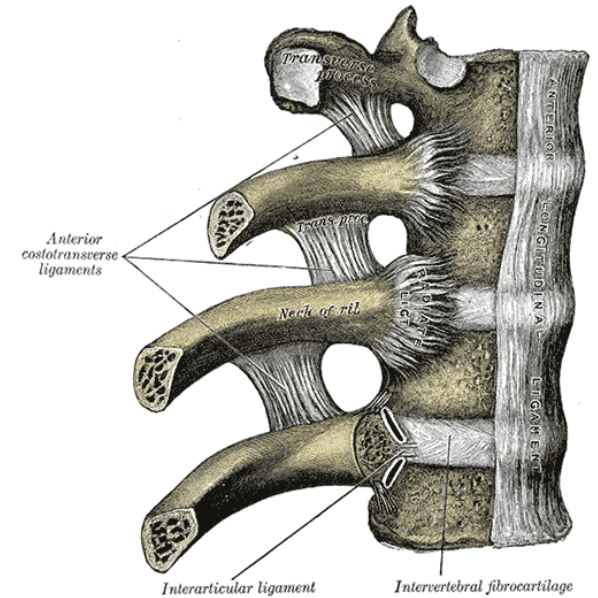
Synarthroses of thorax

- membrana intercostalis interna + externa
 - synchondroses costosternales
 - synchondrosis costae primae
 - symphysis xiphosternalis + manubriosternalis
-
- 4 joints



Articulationes costovertebrales

- **Articulatio capitis costae**
 - lig. capitis costae radiatum
 - lig. capitis costae intraarticulare
- **Articulatio costotransversaria**
 - ligg. costotransversaria



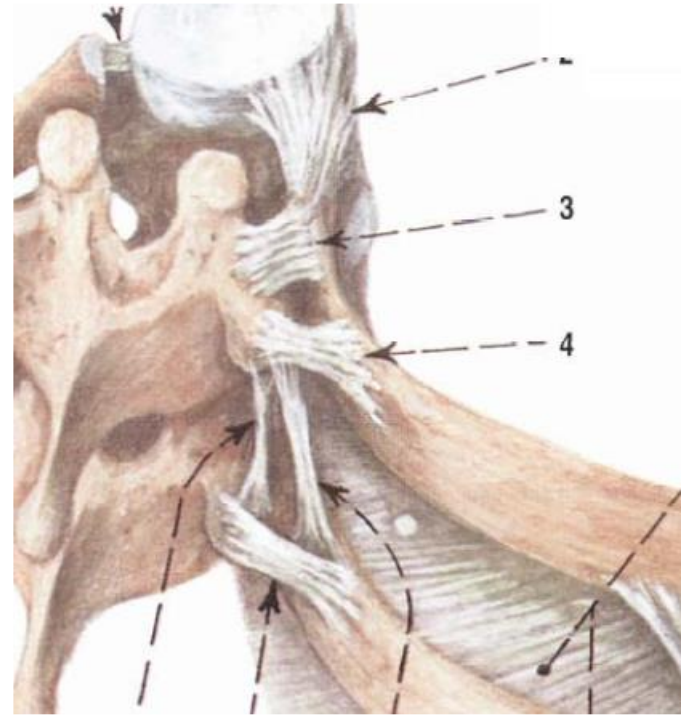
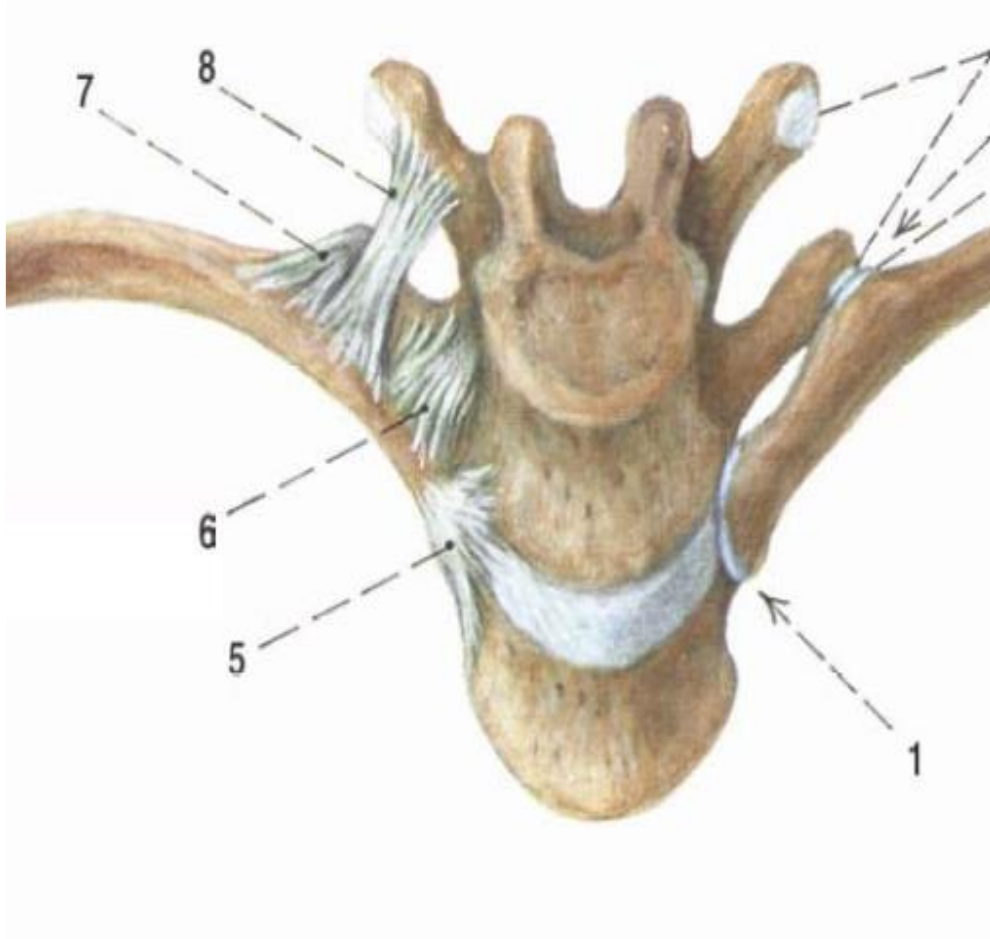
Articulatio capitis costae (joint of head of head)

Joint type	Compound, mobile, rather elipsoid then plane – 2 facets (forming blunt angle)
Head	Facies articularis capitis costae (2 facets – crista capitis costae) 1st, (10th), 11th, 12th have one facet w/o margin
Cavity	Fovea costalis corporis vertebrae (usually composed of two cavities of neighbouring vertebrae and from the margin of intervertebral disc) T1, (T10), T11, T12 have simple cavity
Articular capsule and its ligaments	Lig. capitis costae radiatum, lig. capitis costae intraarticulare (divide joint into two cavities in 2nd-10th ribs)
Movements	Rotation of rib (prominent in 1st-6th rib, minimal in 7th-12th rib) Elevation-depression of rib (minimal in 1st-6th rib, prominent in 7th-12th rib)
Middle position	= basic position

Articulatio costotransversaria (costotransversal joint)

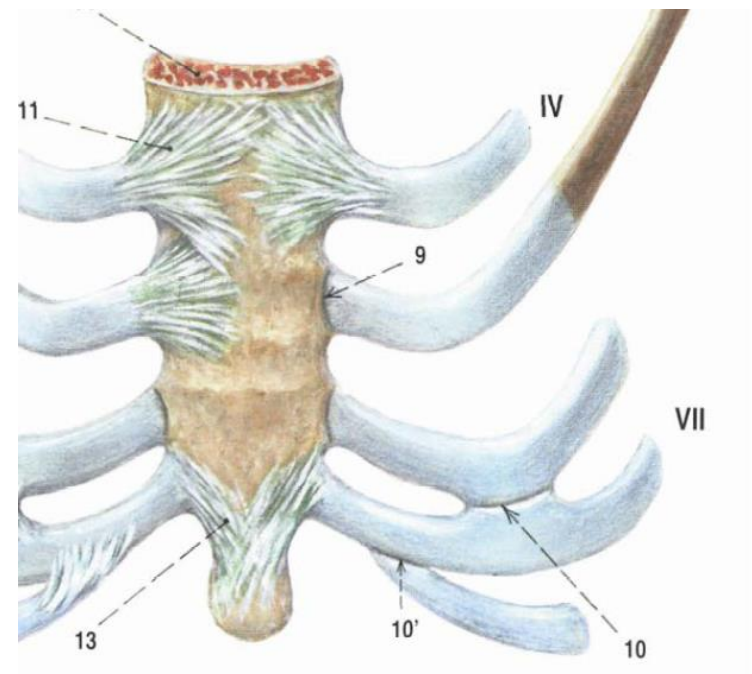
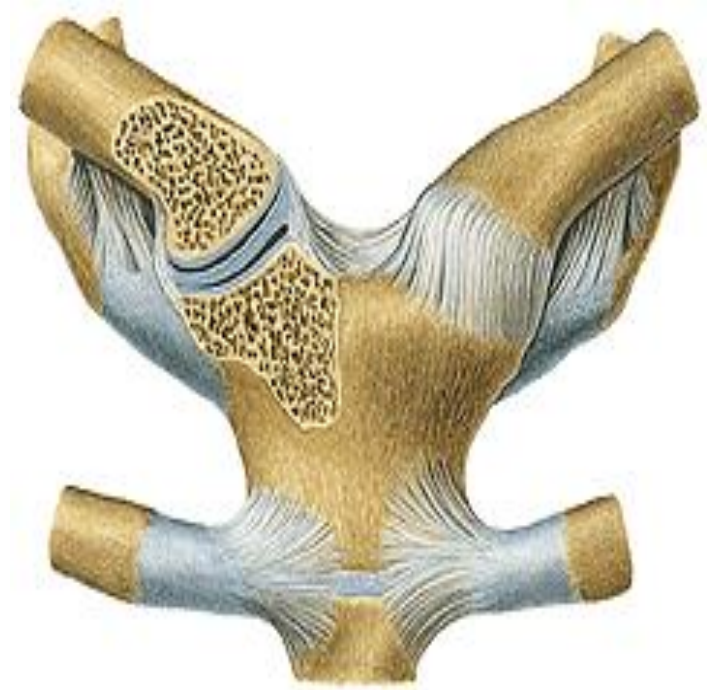Joint type	Simple, movable (approx. flat)
Head	Facies articularis tuberculi costae (1.-10.)
Cavity	Fovea costalis processus transversi vertebrae (T1-T10)
Articular capsule and its ligaments	Lig. costotransversarium, lig. costotransversarium superius et laterale Lig. lumbocostale
Movements	Rotation of rib (prominent in 1st-6th rib, minimal in 7th-12th rib) Elevation-depression of rib (minimal in 1st-6th rib, prominent in 7th-12th rib)
Middle position	= basic position
Joint type	Foramen costotransversarium (w/o content)

Articulaciones costovertebrales



Articulationes sternocostales

- lig. sternocostale radiatum
- membrana sterni
- lig. sternocostale intraarticulare
- ligg. costoxiphoidia
- Articulationes interchondrales



Articulatio sternocostalis (sternocostal joint)

Joint type	Compound, mobile
Head	Cartilago costalis costae 2nd-7th (2 facets on ventral end)
Cavity	Incisurae costales sterni
Articular capsule and its ligaments	Lig. sternocostale radiatum, lig. sternocostale intraarticulare (in 2nd and 3rd joint), ligg. costoxiphoida
Movements	Small in all directions
Middle position	= basic position
Note	Sliding movements for breathing Missing cavity always in 1st joint and especially in caudal ones – here a fibrocartilago connects continuously both bones

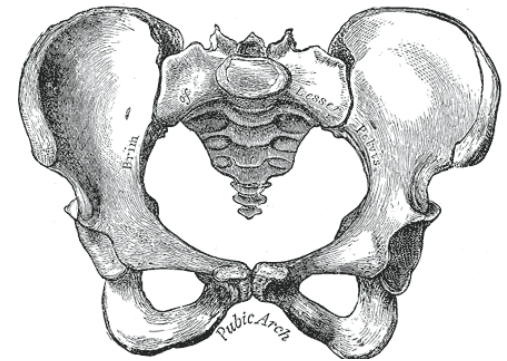
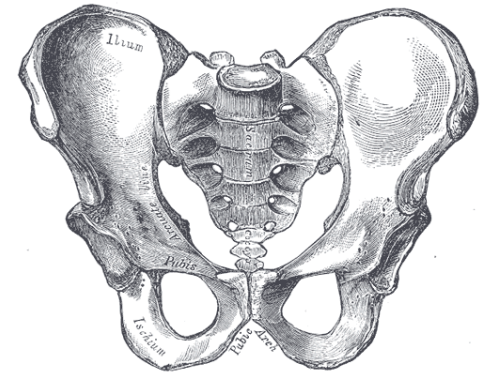
Articulatio interchondralis (interchondral joint)

Joint type	Simple, mobile
Head	Cartilago costalis costae 8th-10th
Cavity	Cartilago costalis costae 7th-9th
Articular capsule and its ligaments	Ligg. interchondralia
Movements	Small in all directions
Middle position	= basic position
Note	Joints often missing articulation cavity, between 9th and 10th rib always missing

Pelvis as a whole

Pelvis

- sexual dimorphism
- linea terminalis
- greater pelvis:
 - ala ossis ilii above lineae terminales
 - basis ossis sacri
- lesser pelvis:
 - os sacrum and coccyx
 - os ischii and os pubis with membrana obturatoria
 - symphysis pubica



Pelvic declination

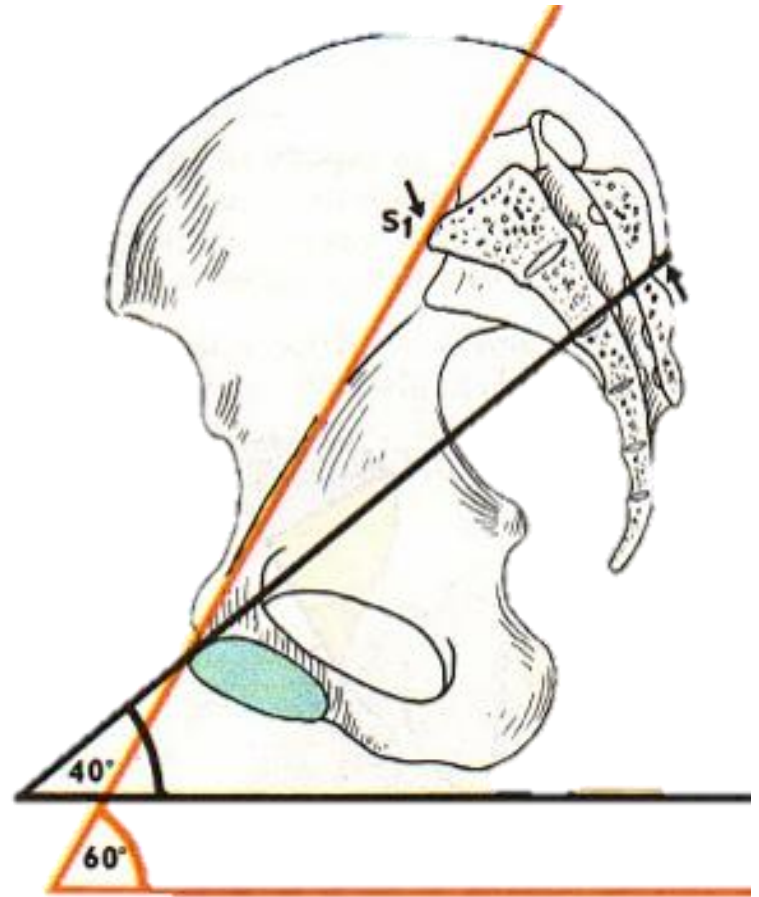
- **inclinatio pelvis normalis**

(red angle):

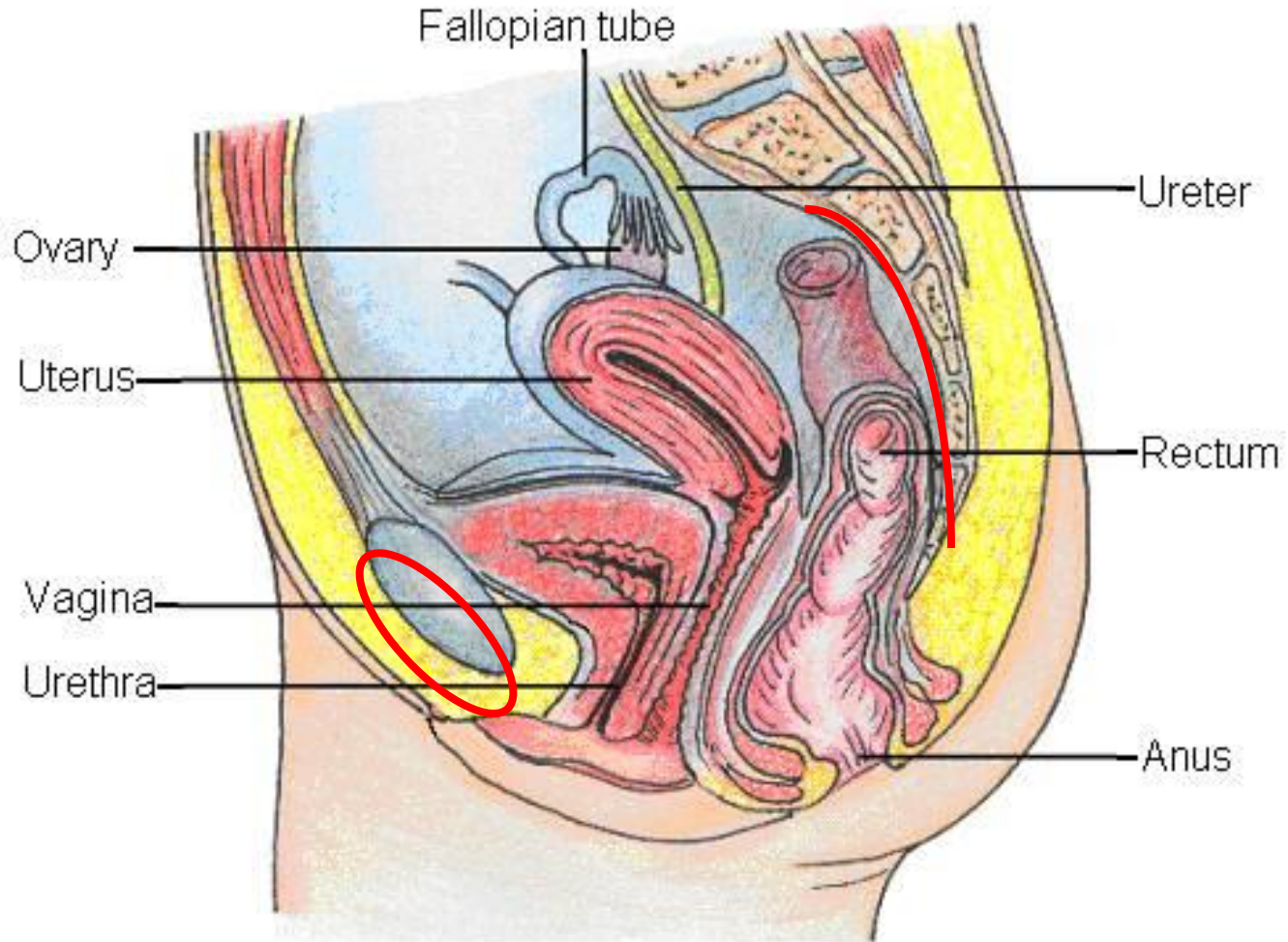
- plane via: promontorium + lineae terminales + upper margin of pubic bone
- horizontal plane
- **60°** – only on X-ray

- **inclinatio coxae** (black angle):

- plane via: spina iliaca posterior superior + upper margin of pubic bone
- horizontal plane
- **40°**



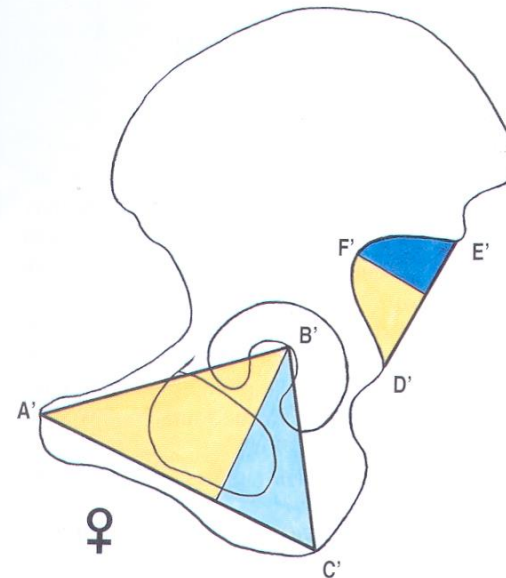
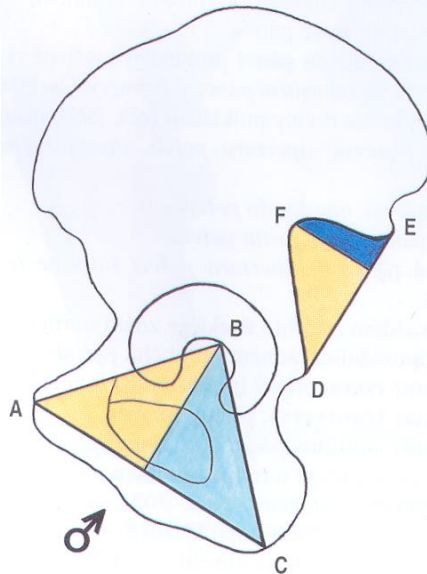
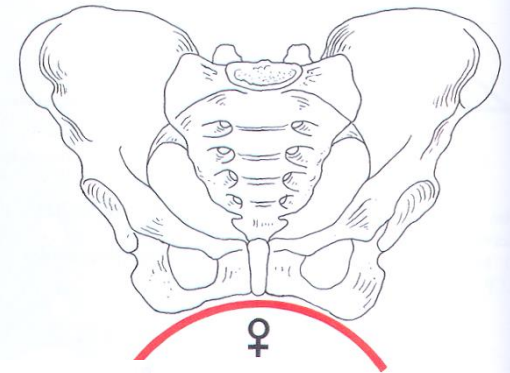
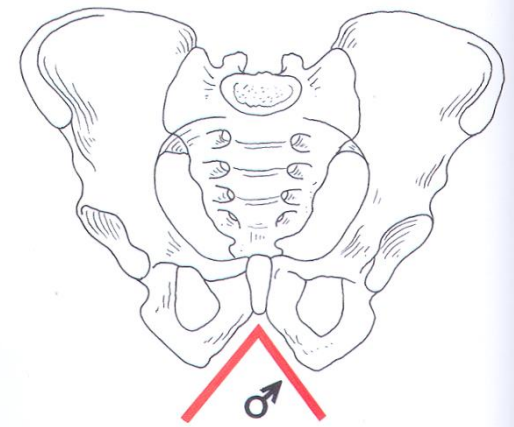
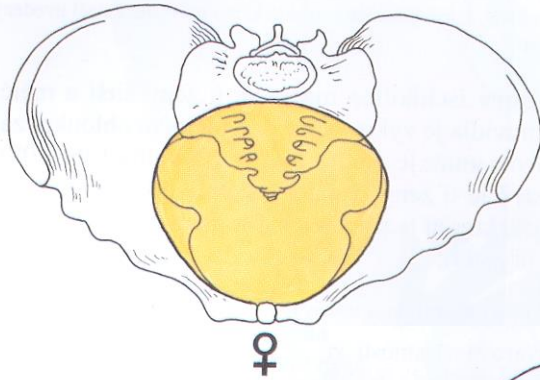
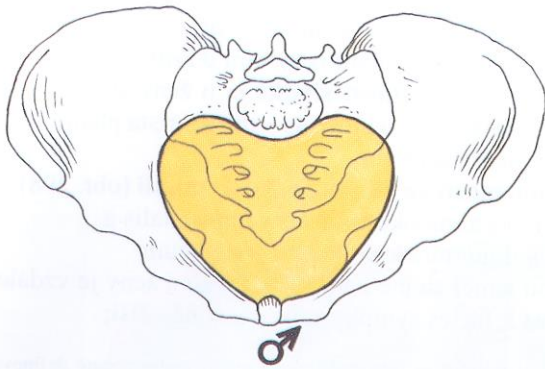
Syntopy to organs



Sexual dimorphism on pelvis

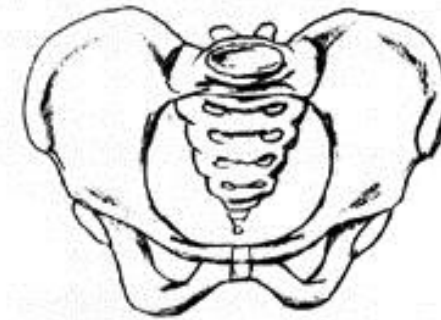
- promontorium – round ♀ x ♂ hearty
- symphysis pubica – lower in females (♀ 4,5 cm x ♂ 5,5 cm)
- rami inferiores ossis pubis – different angles
 - arcus pubicus ♀
 - angulus pubicus ♂
- incisura ischiadica major – larger and flatter in females ♀
- coccyx – shorter and more movable in females ♀
- foramen obturatorium – triangular ♀ x round ♂
- alae ossis ilii – more open in females ♀

Sexual dimorphism on pelvis

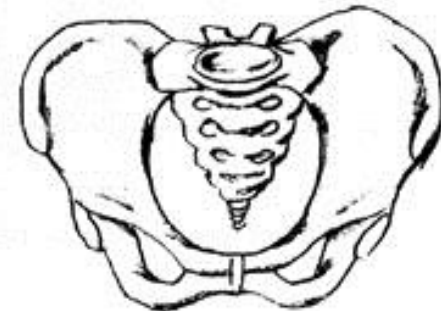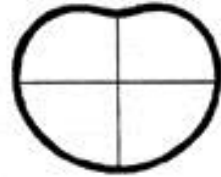


Types of pelvis

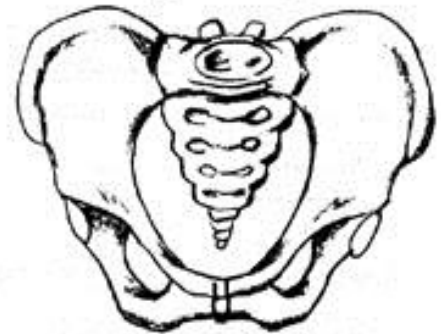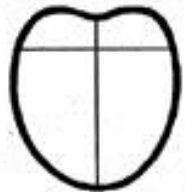
- gynoid – circular aditus
- android – heart-shaped aditus
- anthropoid – oval aditus, long os sacrum with 6 vertebrae
- platypeloid – transversally oval aditus, wide arcus pubicus



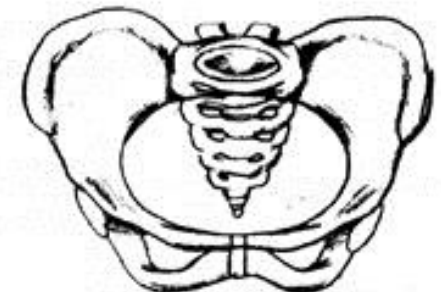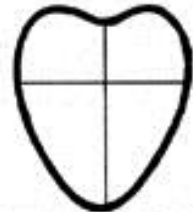
průměry
přímý transverzální
gynoidní
11 cm 12 cm



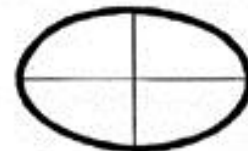
androidní
11 cm 12 cm



antropoidní
>12 cm >12 cm

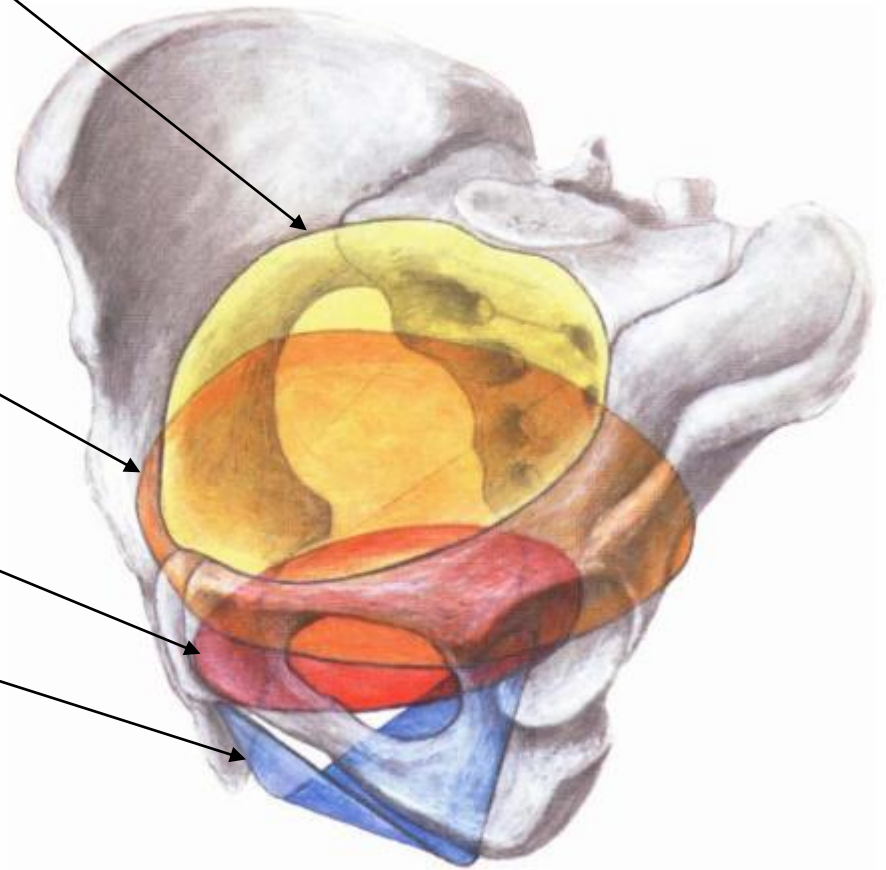


platypeloidní
10 cm 12 cm



Pelvic planes

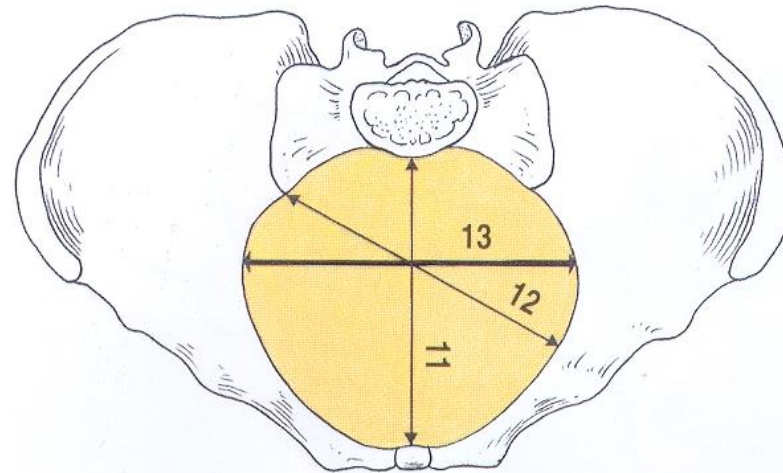
- Apertura pelvis superior
(aditus pelvis)
 - plane of pelvic inlet
- Amplitudo pelvis
 - plane of pelvic width
- Angustia pelvis
 - plane of pelvic isthmus
- Apertura pelvis inferior
(exitus pelvis)
 - plane of pelvic outlet



Pelvic inlet

= linea terminalis

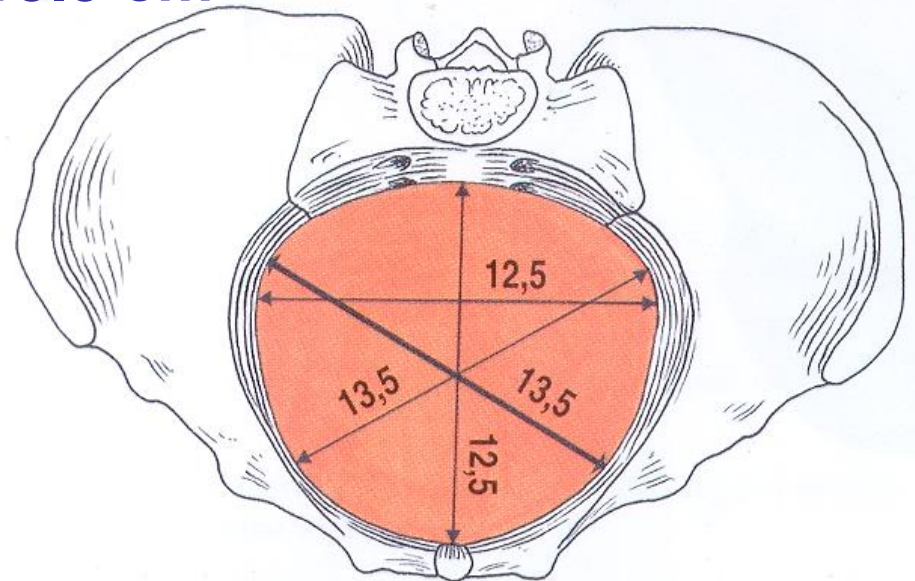
- diameter recta (conjugata anatomica): *promontorium* – *upper margin of symphysis pubica* = minimally 11 cm
- diameter obliqua: *articulatio sacroiliaca* – *eminentia iliopubica* = minimally 12 cm
- diameter transversa: *across between linea arcuata* (part of *linea terminalis*) = minimally 13 cm



ADITUS

Pelvic width

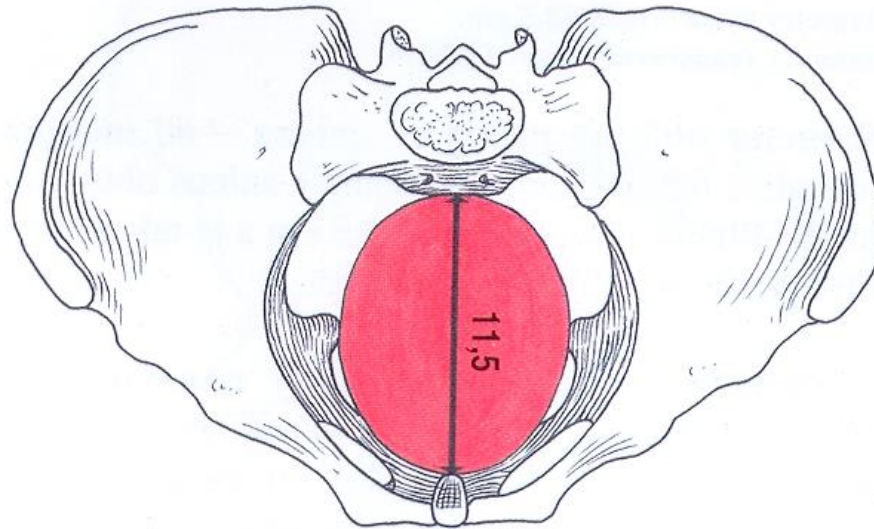
- = S2-S3 → middle of acetabulum → middle (posterior margin) of symphysis pubica
- diameter recta: 12.5 cm
 - diameter transversa: 12.5 cm
 - **diameter obliqua: insicura ischiadica major → sulcus obturatorius = minimally 13.5 cm**



AMPLITUDO

Pelvic isthmus

- = apex ossis sacri → spina ischiadica → lower margin of symphysis pubica
- narrowest part of small pelvis
 - diameter transversa: 10 cm
 - **diameter recta: 11.5 cm**



ANGUSTIA

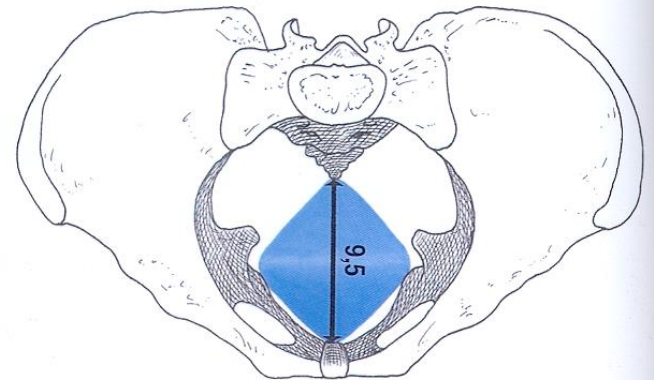
Pelvic outlet

= two triangular planes (trigonum urogenitale et anale)

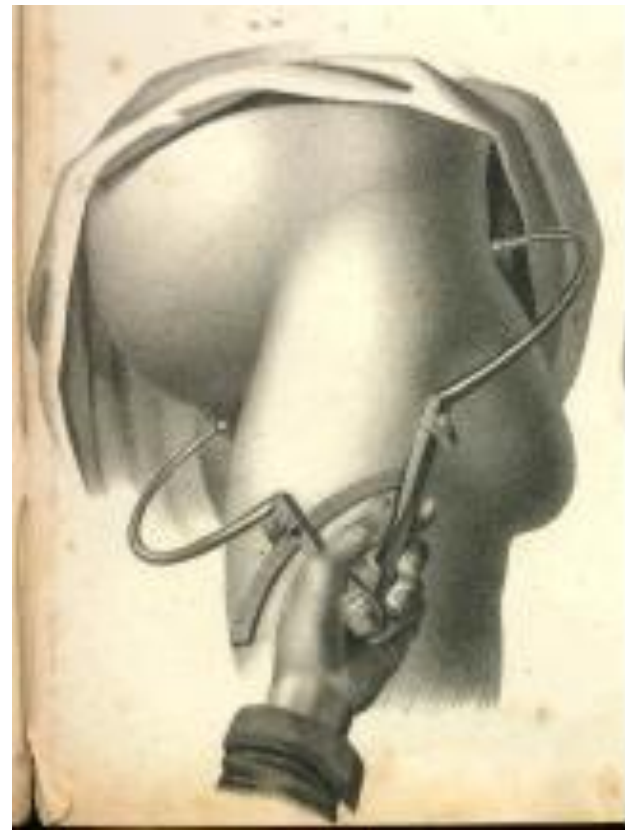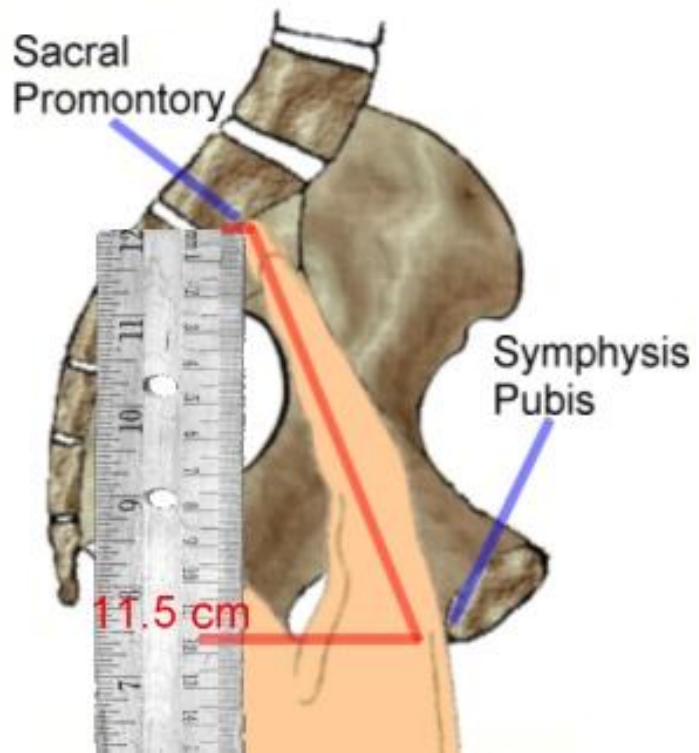
Lower margin of symphysis pubica → tubera ischiadica →
os coccygis

- diameter transversa: *between tubera ischiadica* = minimally 11 cm
- diameter recta: *apex ossis coccygis* → *posterior margin of symphysis pubica*

= minimally 9.5 cm, during delivery coccyx bends dorsally due to releasing of connection with sacral bone = minimally 11.5 cm

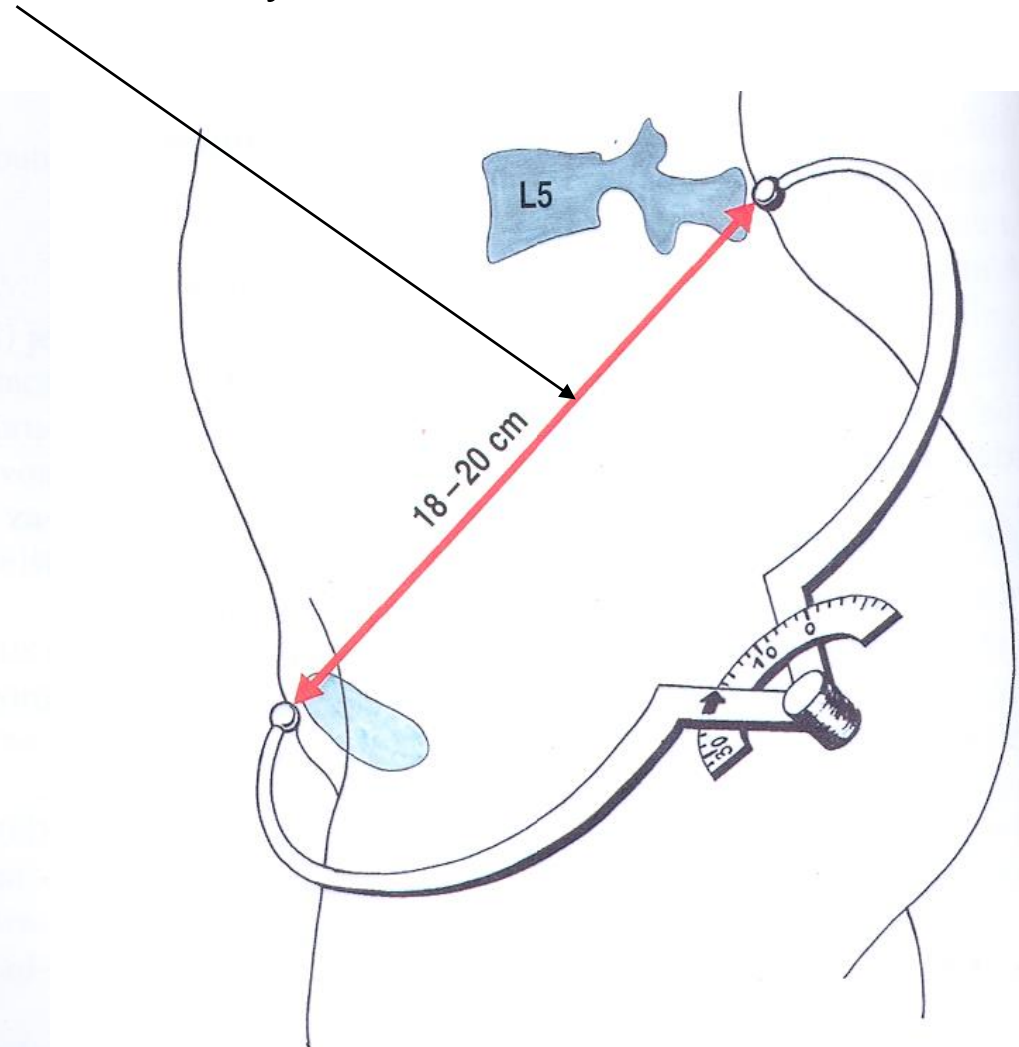
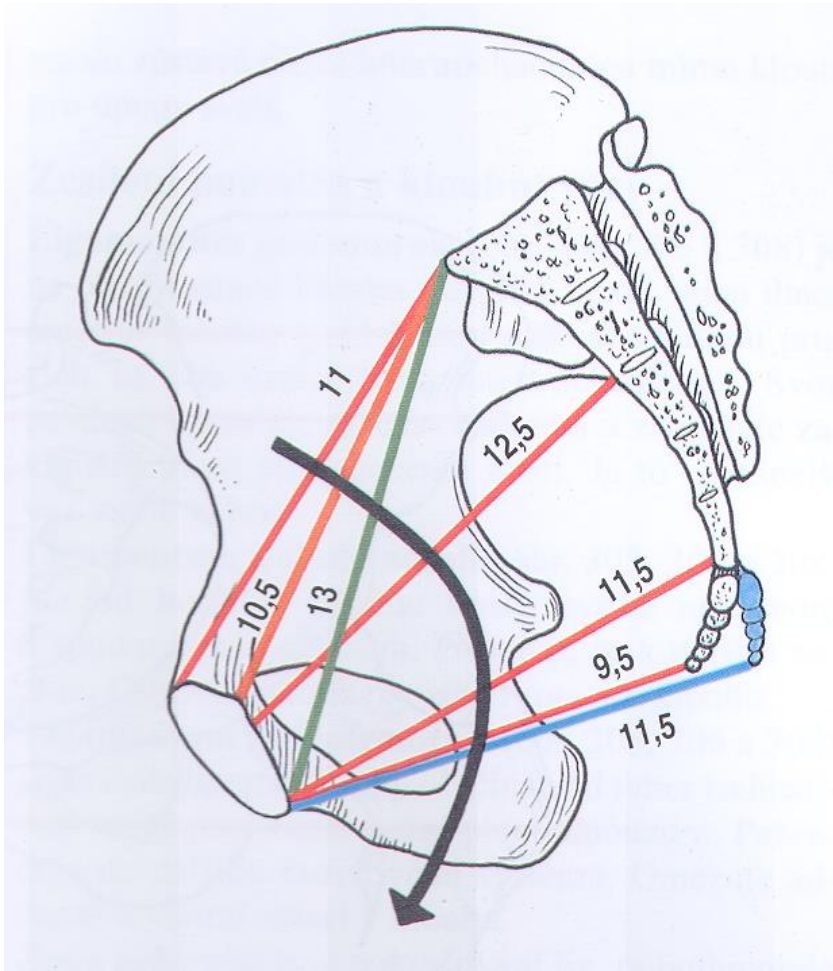


EXITUS



Delivery pelvic diameters

- conjugata obstetrica (orange) = minimally 10,5 cm
- conjugata diagonalis (green) = minimally 12 cm
- conjugata externa *Baudelocqui* = minimally 18 cm, better 20 cm – *external diameter !!!*



Delivery pelvic diameters - *external*

- conjugata obstetrica (vera):

promontorium → *eminetia retropubica*

- real anteroposterior diameter of pelvic entrance
- shorter than diameter recta (conjugata anatomica) – minimally 10.5 cm

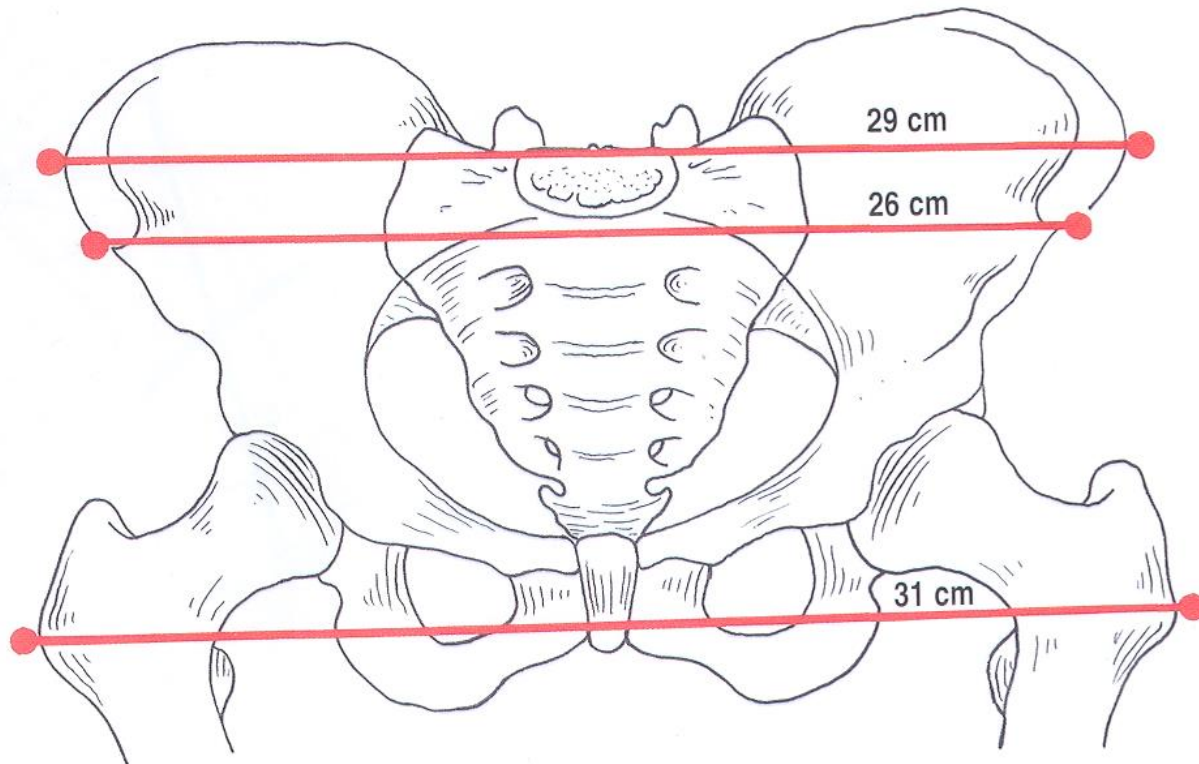
- conjugata diagonalis:

promontorium → *lower margin of symphysis pubica (lig. pubicum inf.)*

- minimally 13 cm for normal passage of head

Delivery pelvic diameters - *external*

- distantia interspinosa = minimally 26 cm
- distantia intercristalis = minimally 29 cm
- distantia intertrochanterica = minimally 31 cm



Delivery pelvic diameters - *external*

- distantia interspinosa:

between spinae iliacae ant. sup. (SIAS) = minimally 26 cm

- distantia intercrystalis:

between most distant margins of cristae iliacae = minimally 29 cm

- distantia intertrochanterica:

between most distant margins of trochanteres majores = minimally 31 cm

- conjugata externa (diameter Baudelocquei):

between processus spinosus L5 and upper margin of symphysis pubica = minimally 18 cm (better 20 cm)

Hard delivery canal

- delivery canal – 16 cm
- Michaelis' rhomboid:
 - L5 → symphysis sacrococcygea: 11 cm
 - spinae iliacae posteriores superiores: 10 cm
- fetus weight: 3400 g