

Ondřej Naňka

Institute of Anatomy

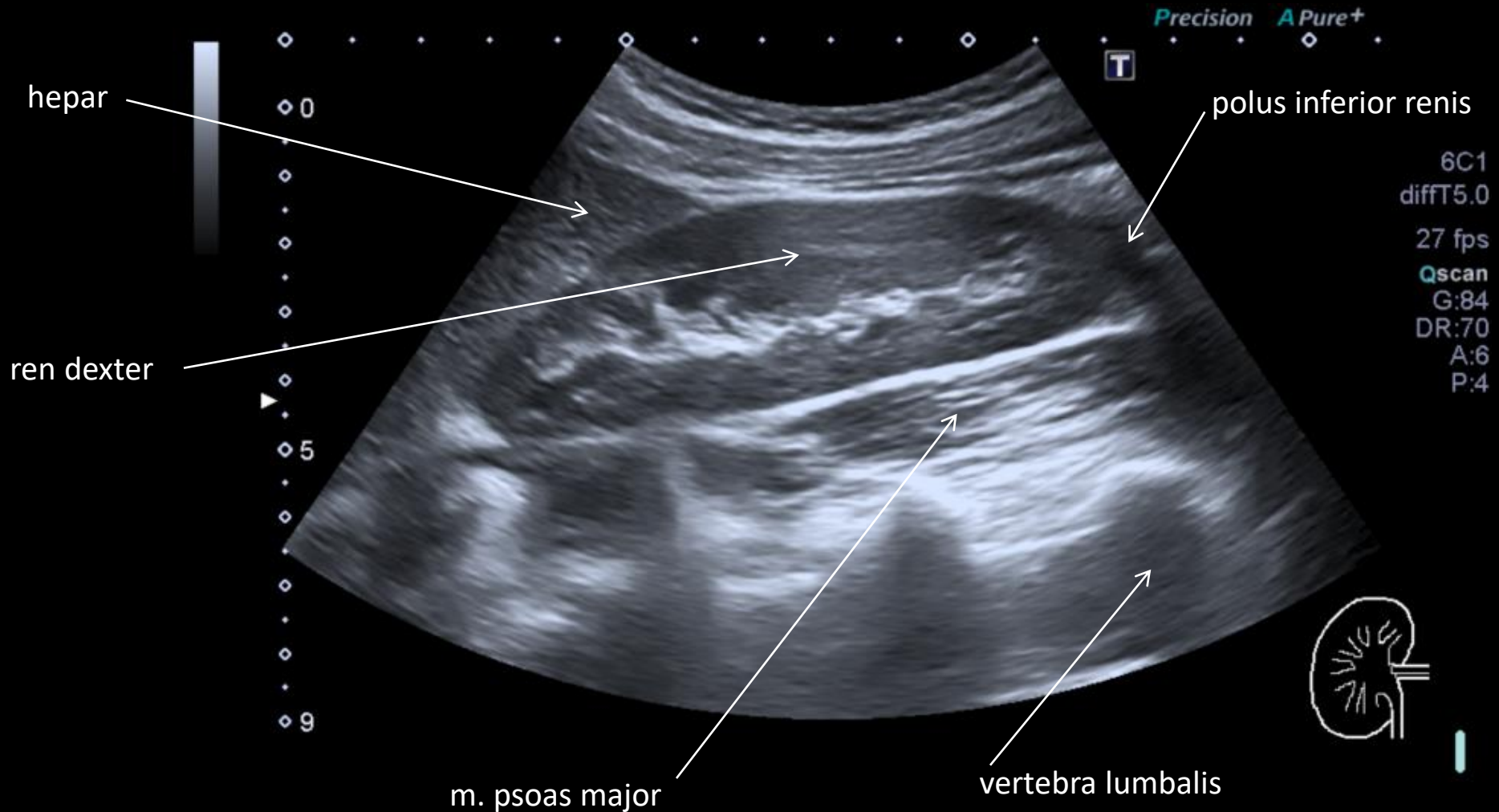


ZOBRAZOVACÍ METODY UROGENITÁLNÍHO SYSTÉMU

UROGENITAL SYSTEMS -
IMAGING METHODS

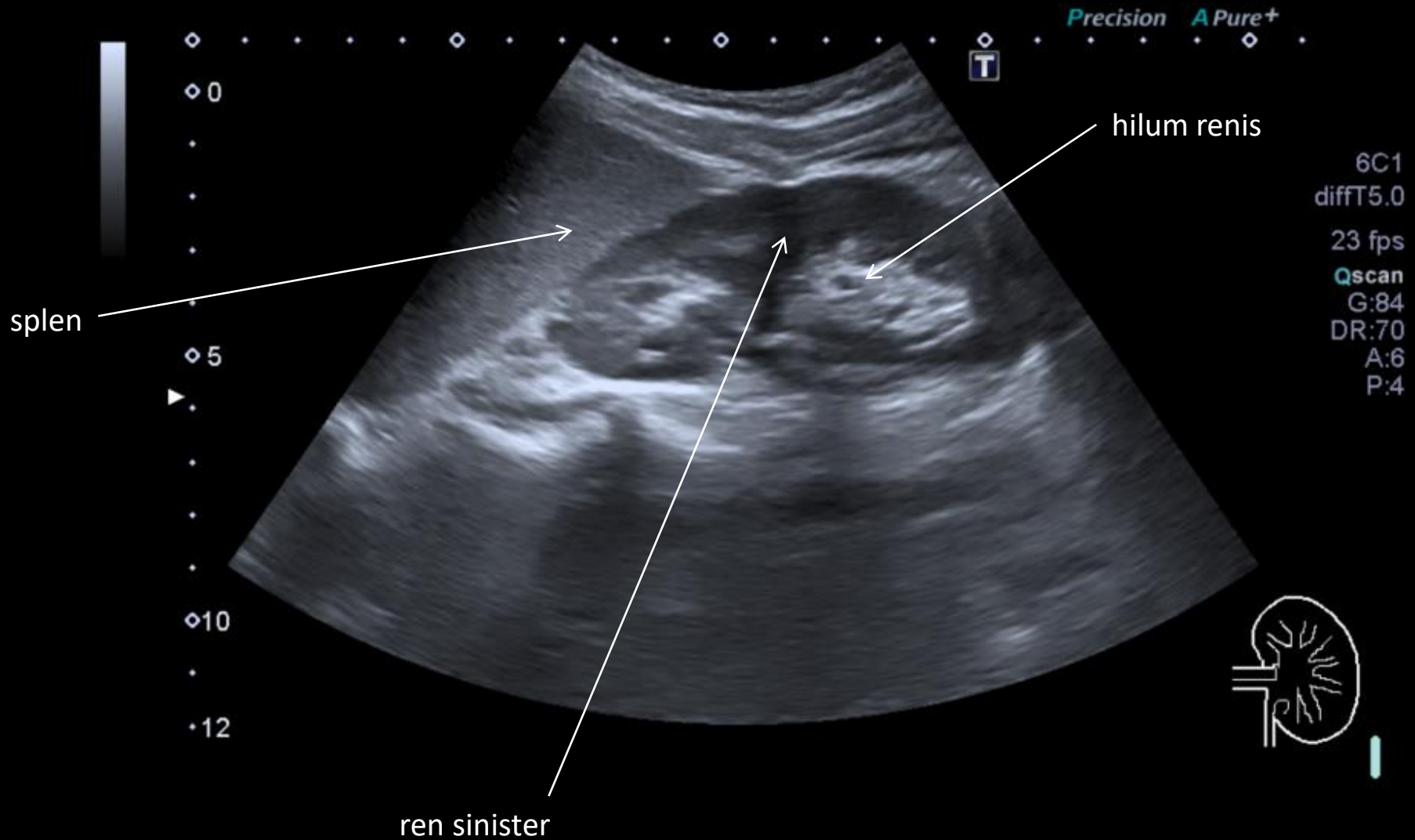
Ultrazvukové vyšetření ledvin

Ultrasound examination of kidney



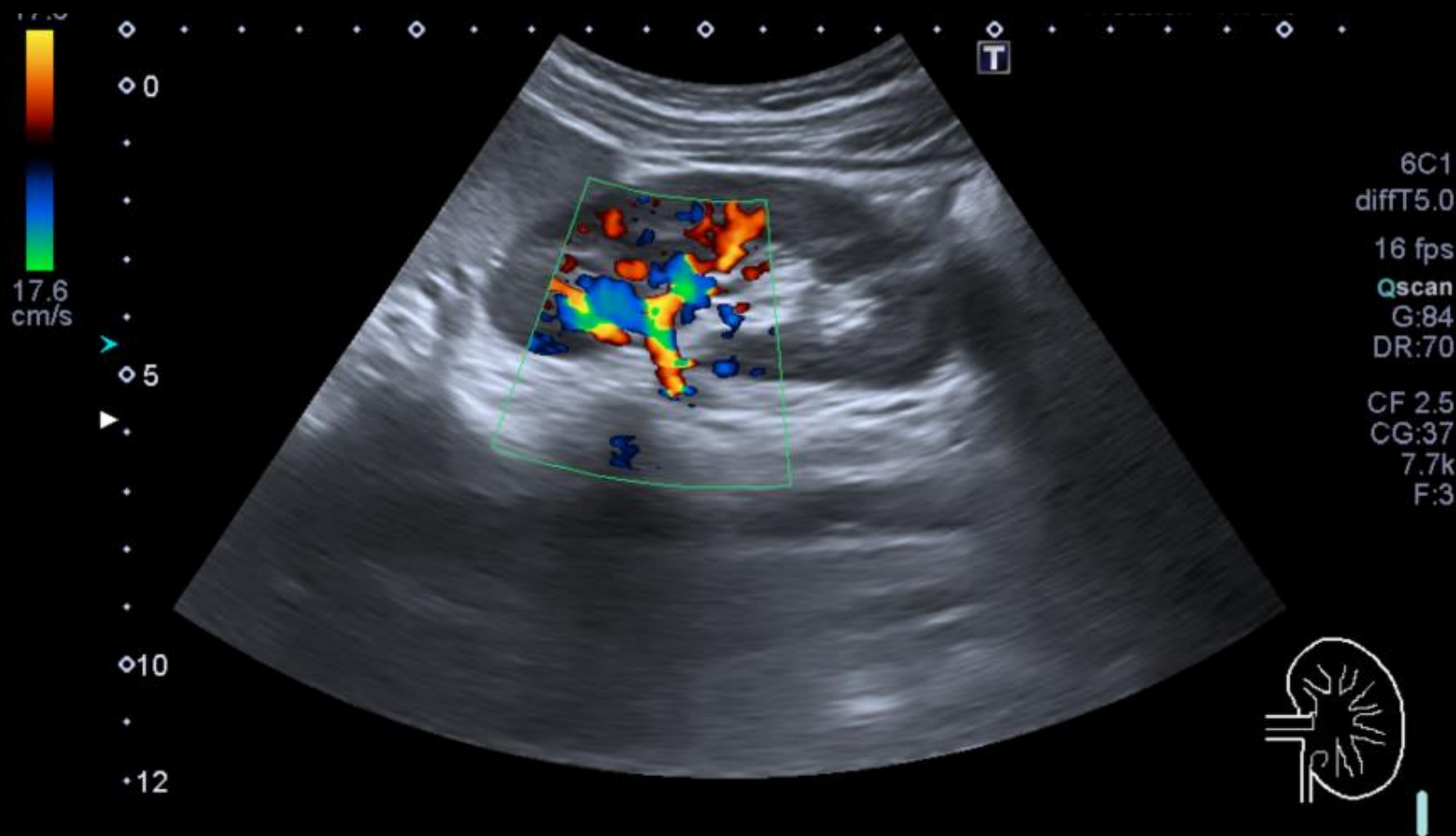
Ultrazvukové vyšetření ledvin

Ultrasound examination of kidney



Dopplerovské ultrazvukové vyšetření ledvin

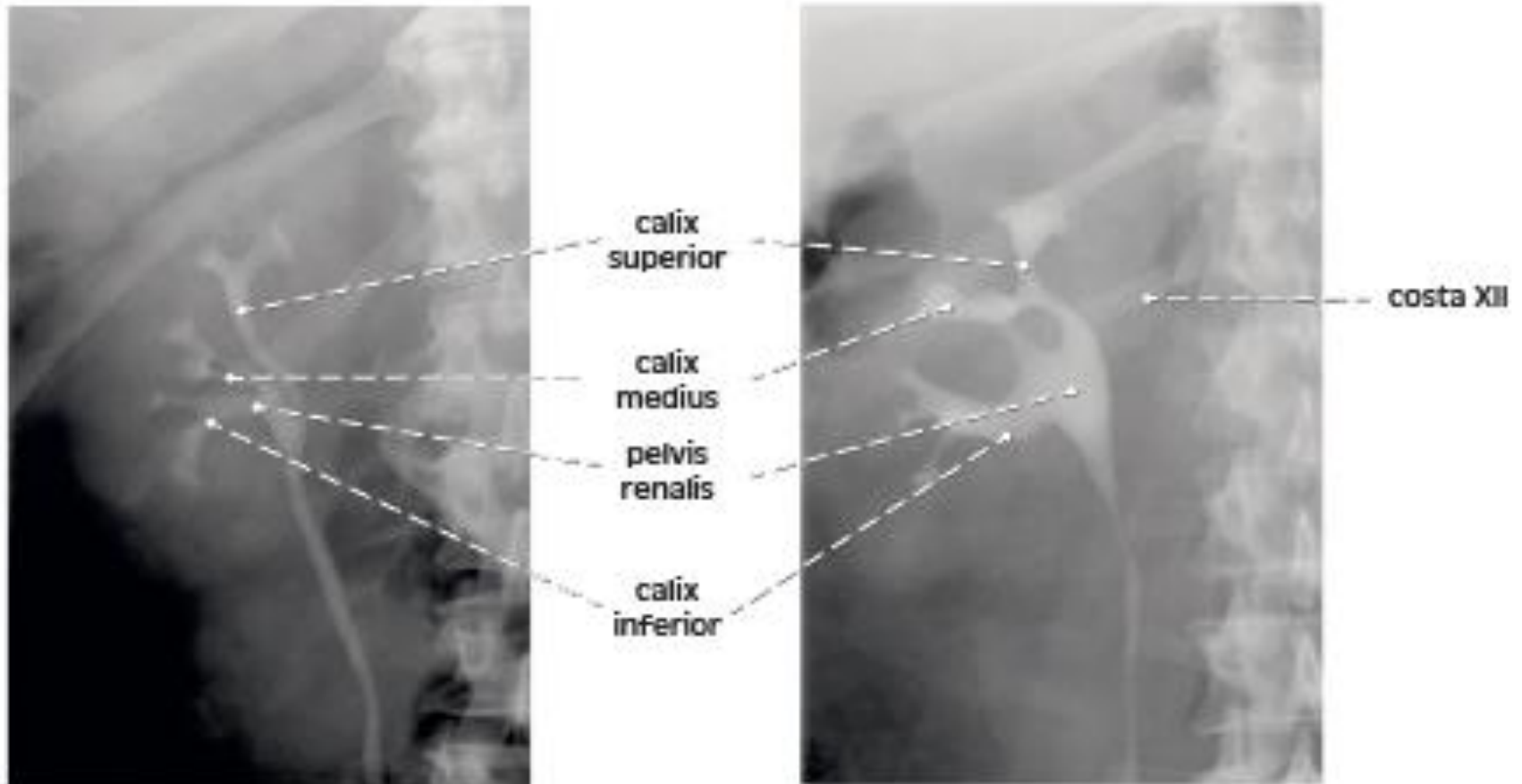
Ultrasound examination of kidney – Doppler's mode



Vylučovací urografie (s kontrastní látkou)

Urography with contrast medium

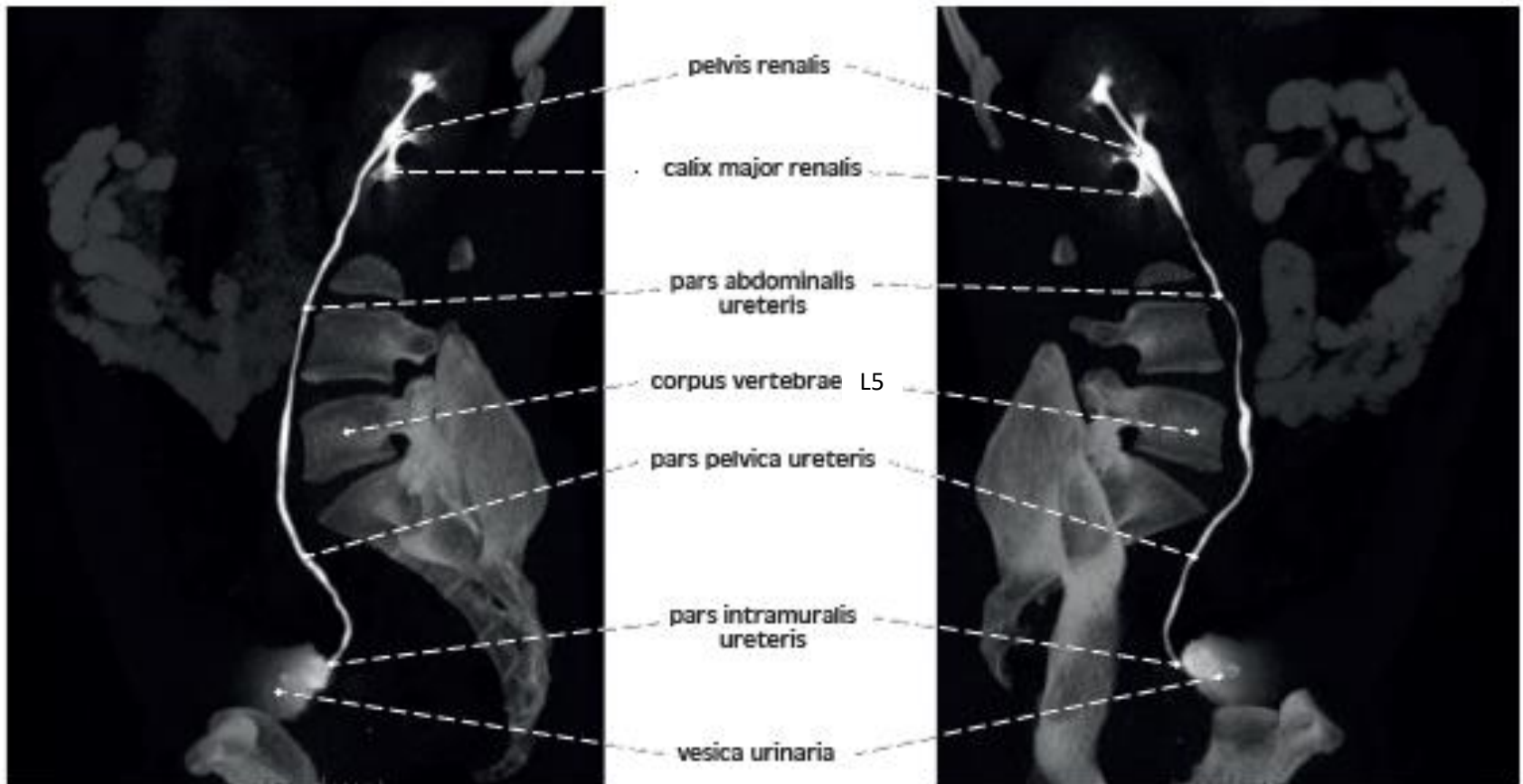
frontální řez / frontal section



Vylučovací MRI urografie (s kontrastní látkou)

MRI urography with contrast medium

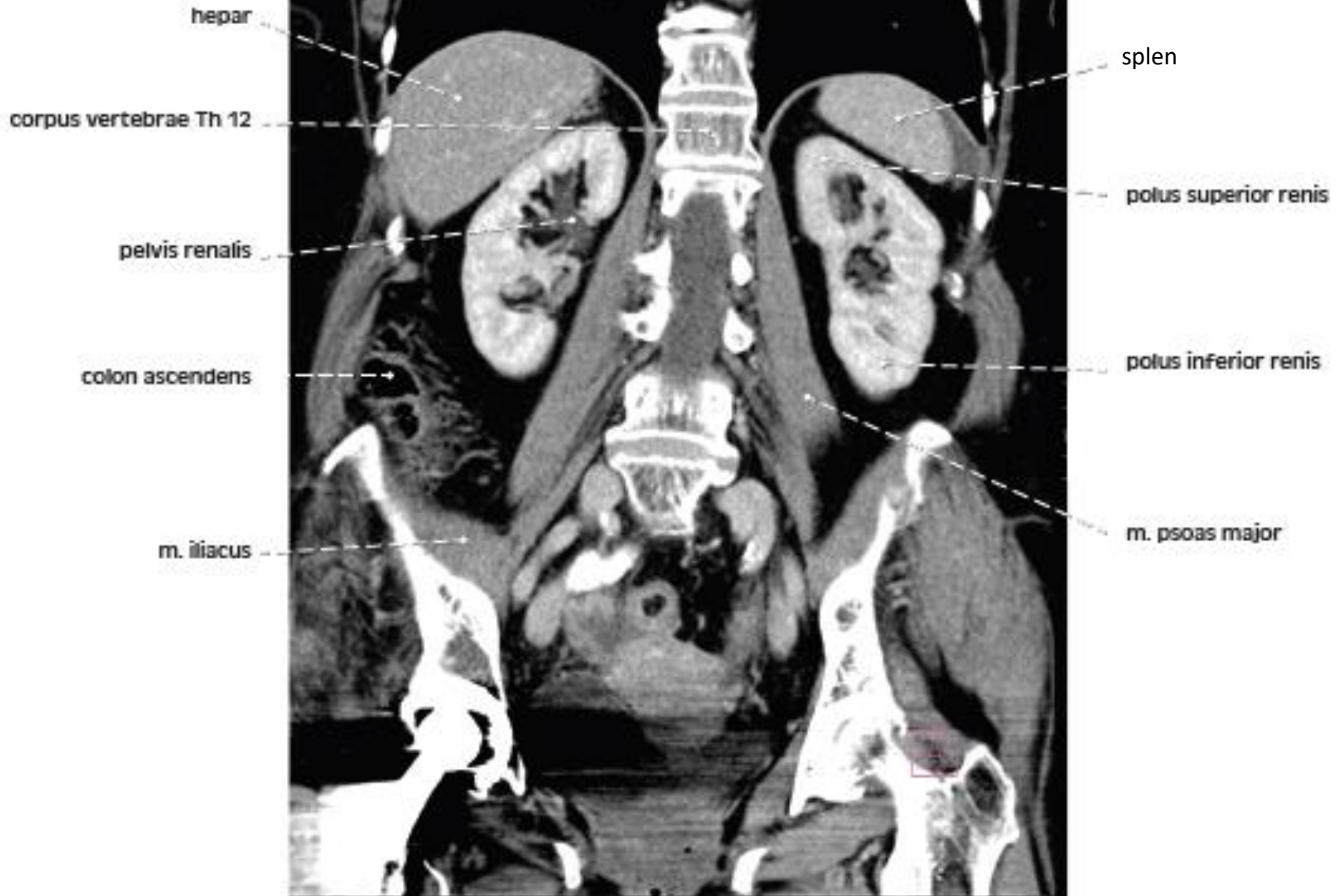
sagitální řez / sagittal section



CT břicha / CT of the abdomen

frontální řez / frontal section

a



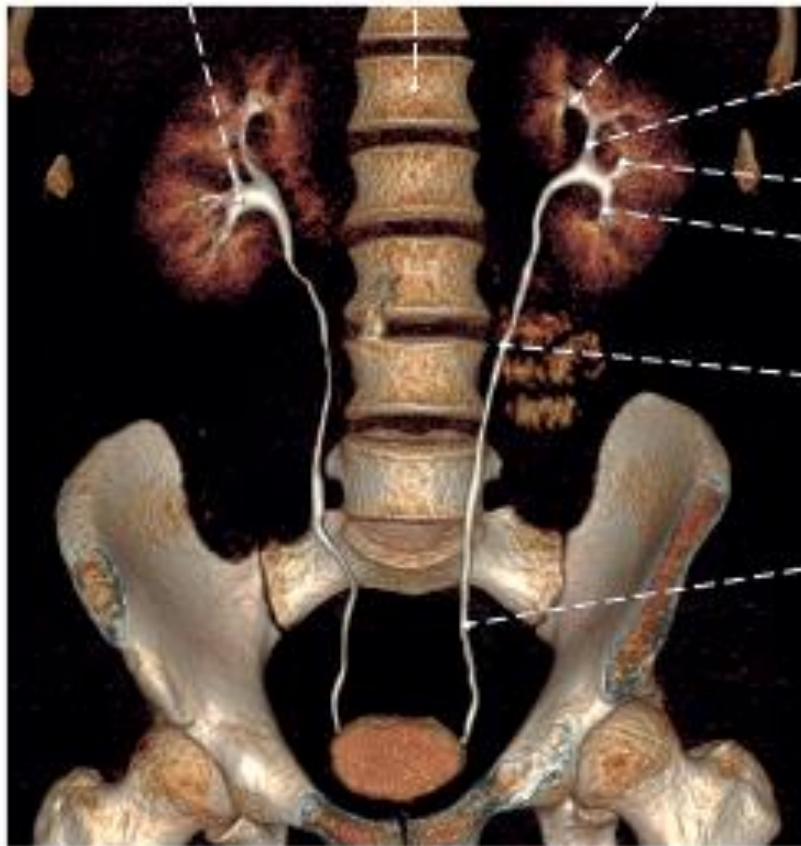
Vylučovací MRI urografie (s kontrastní látkou)

MRI urography with contrast medium

frontální řez / frontal section

a

Pelvis renalis
corpus vertebrae L1
calix renalis minor



calix superior

pelvis renalis

calix medius

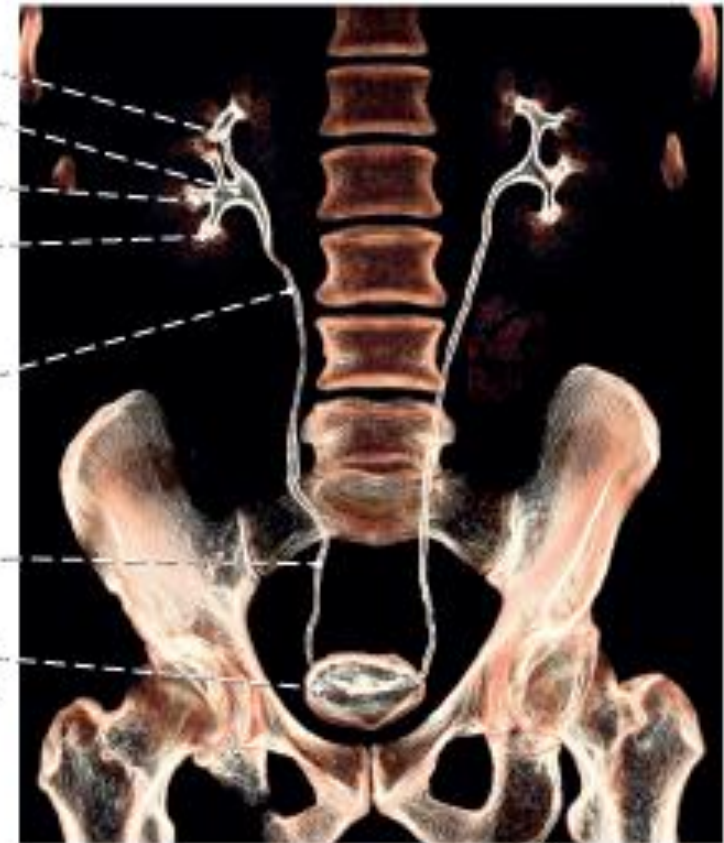calix inferior

pars abdominalis
ureteris

pars pelvica
ureteris

pars intramuralis
ureteris

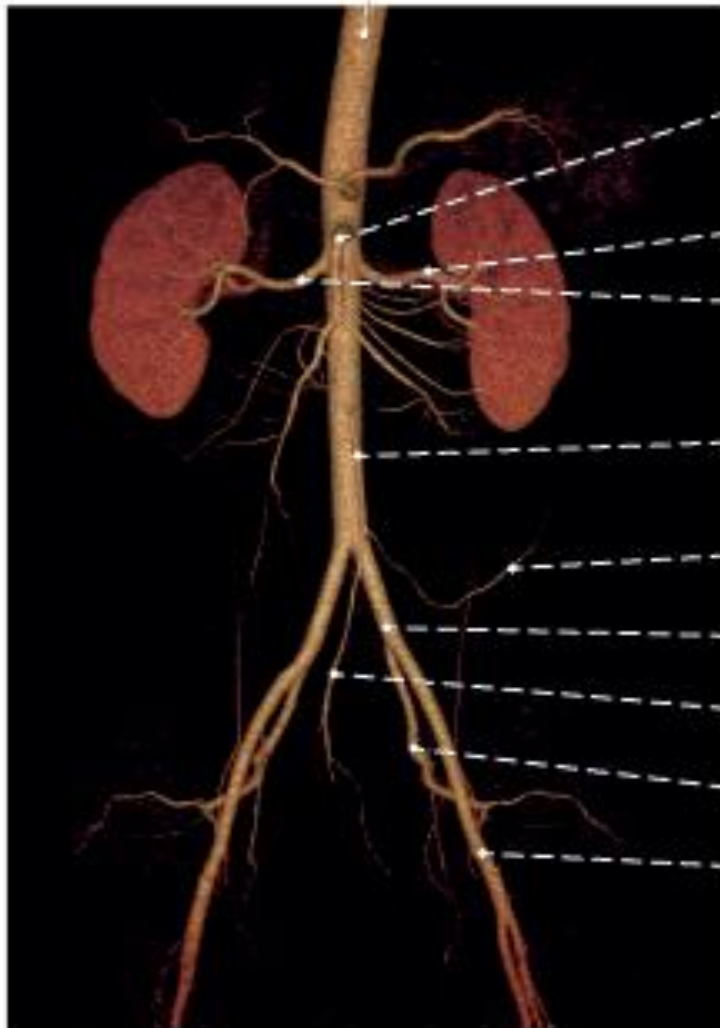
b



CT angiografie břišní aorty – 3D rekonstrukce

CT angiography of the aorta abdominalis – 3D reconstruction

truncus coeliacus



frontální řez / frontal section

a. mesenterica superior

a. renalis sin.

a. renalis dx.

a. mesenterica inferior

a. sigmoidea

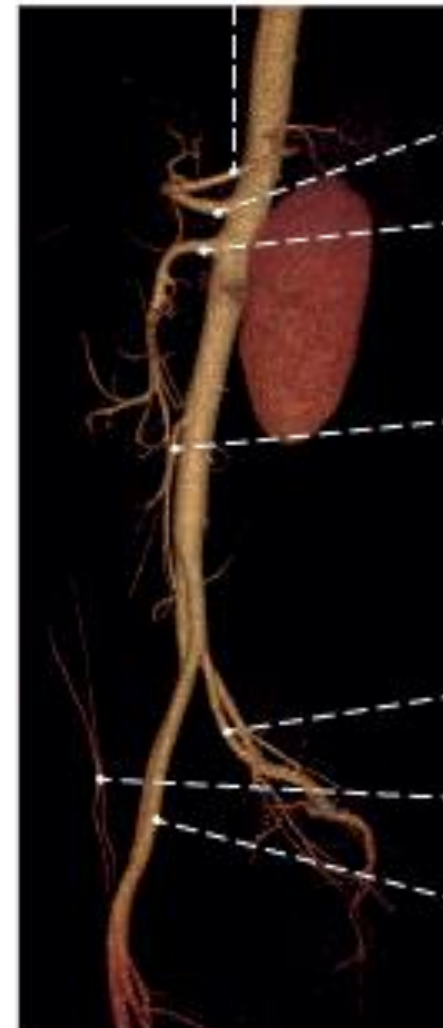a. iliaca communis

a. rectalis superior

a. iliaca interna

a. iliaca externa

a. splenica



truncus coeliacus

a. mesenterica superior

a. mesenterica inferior

a. iliaca interna

a. epigastrica inferior

a. iliaca externa

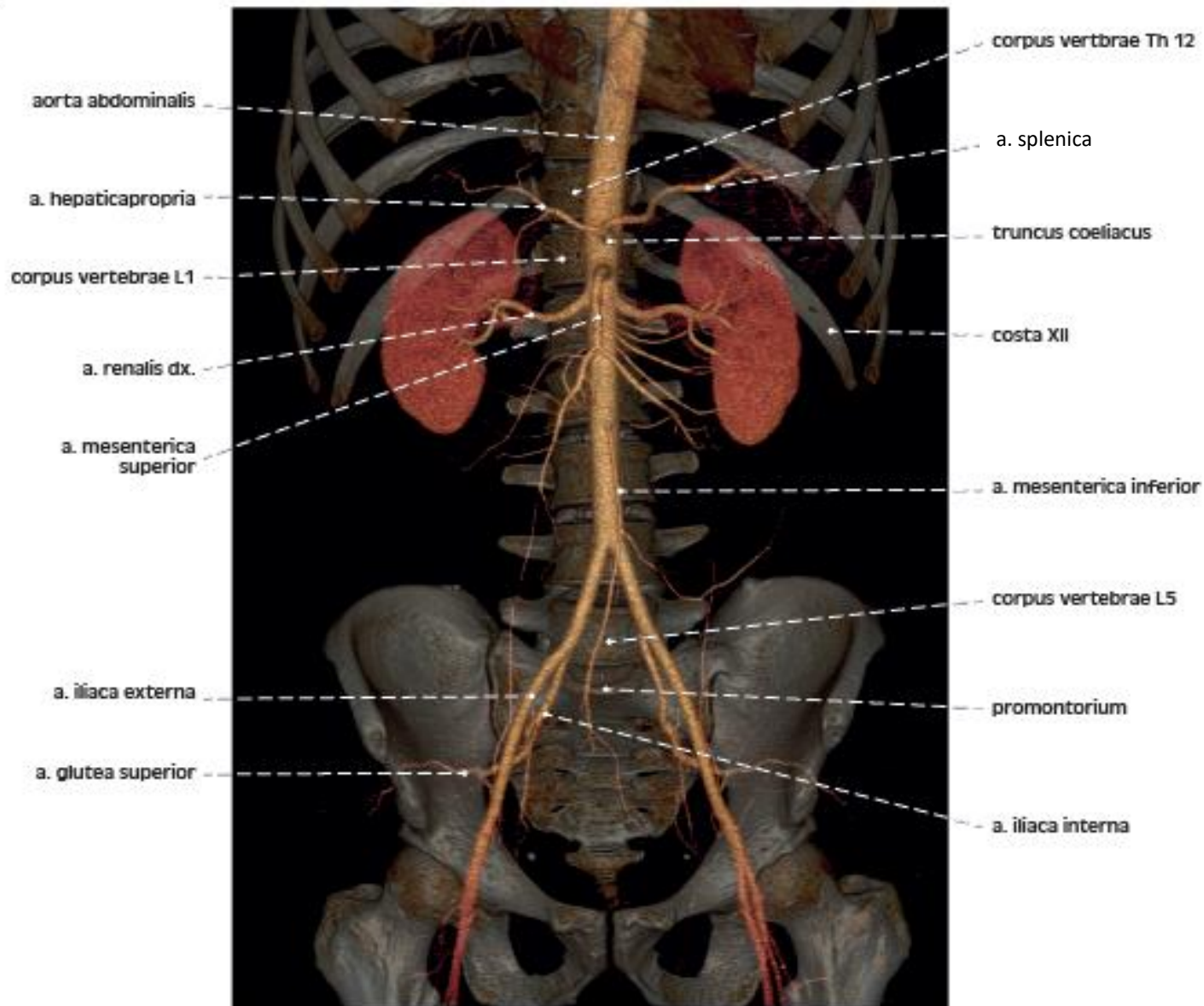
sagitální řez / sagittal section

CT angiografie břišní aorty – 3D rekonstrukce

CT angiography of the aorta abdominalis – 3D reconstruction

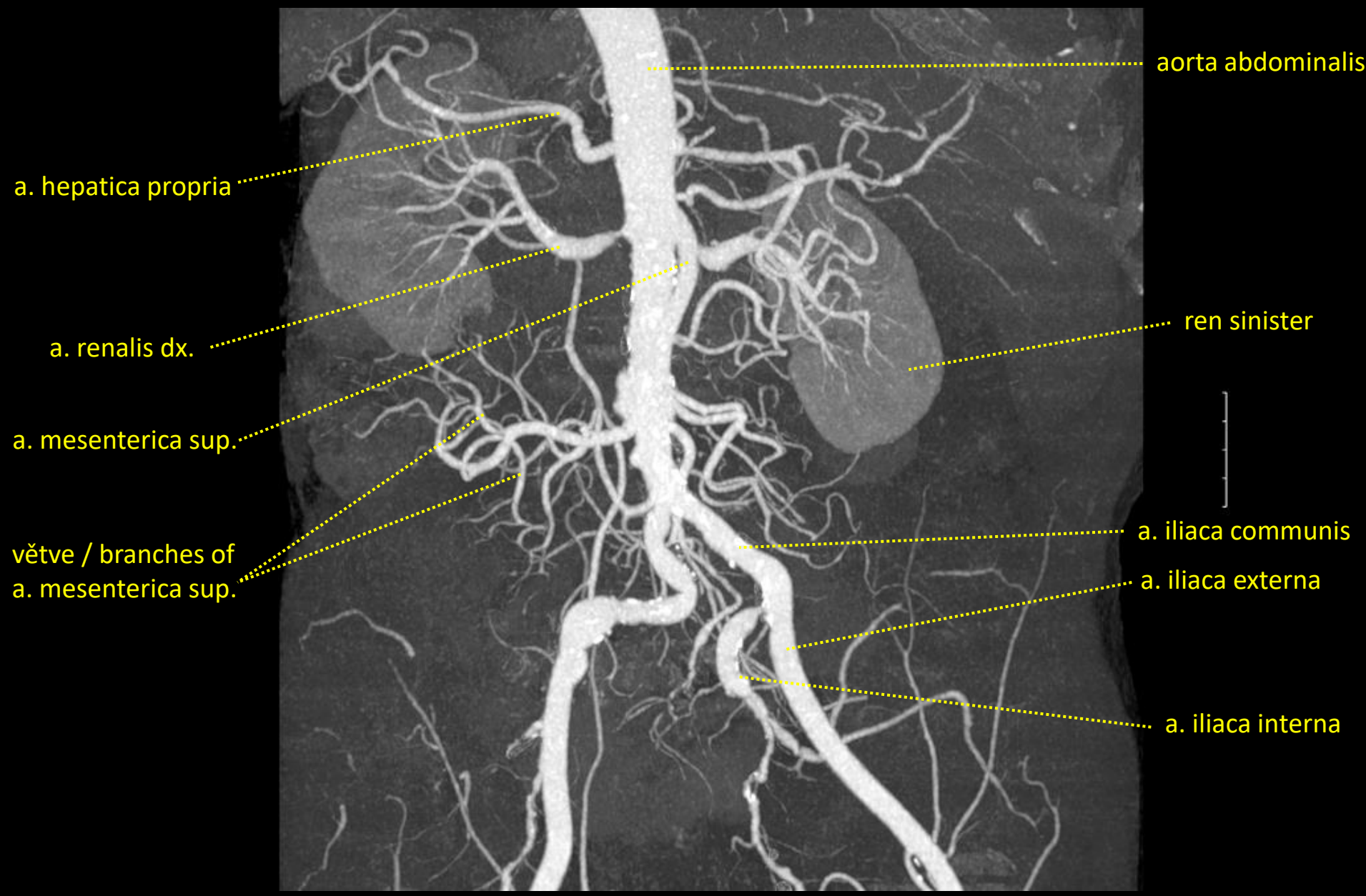
frontální řez / frontal section

a



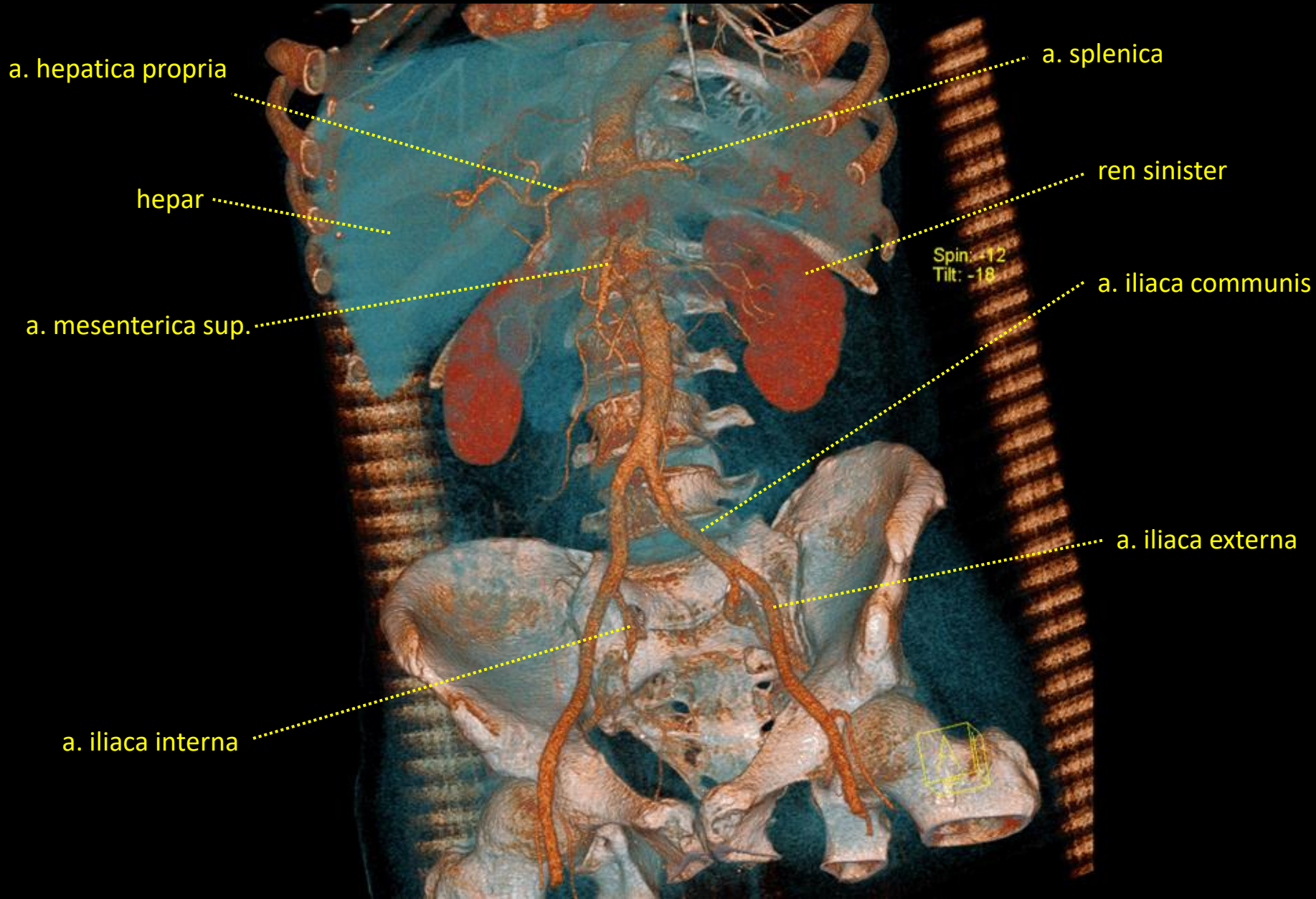
CT angiografie břišní aorty – 3D rekonstrukce

CT angiography of the aorta abdominalis – 3D reconstruction



CT angiografie břišní aorty – 3D rekonstrukce

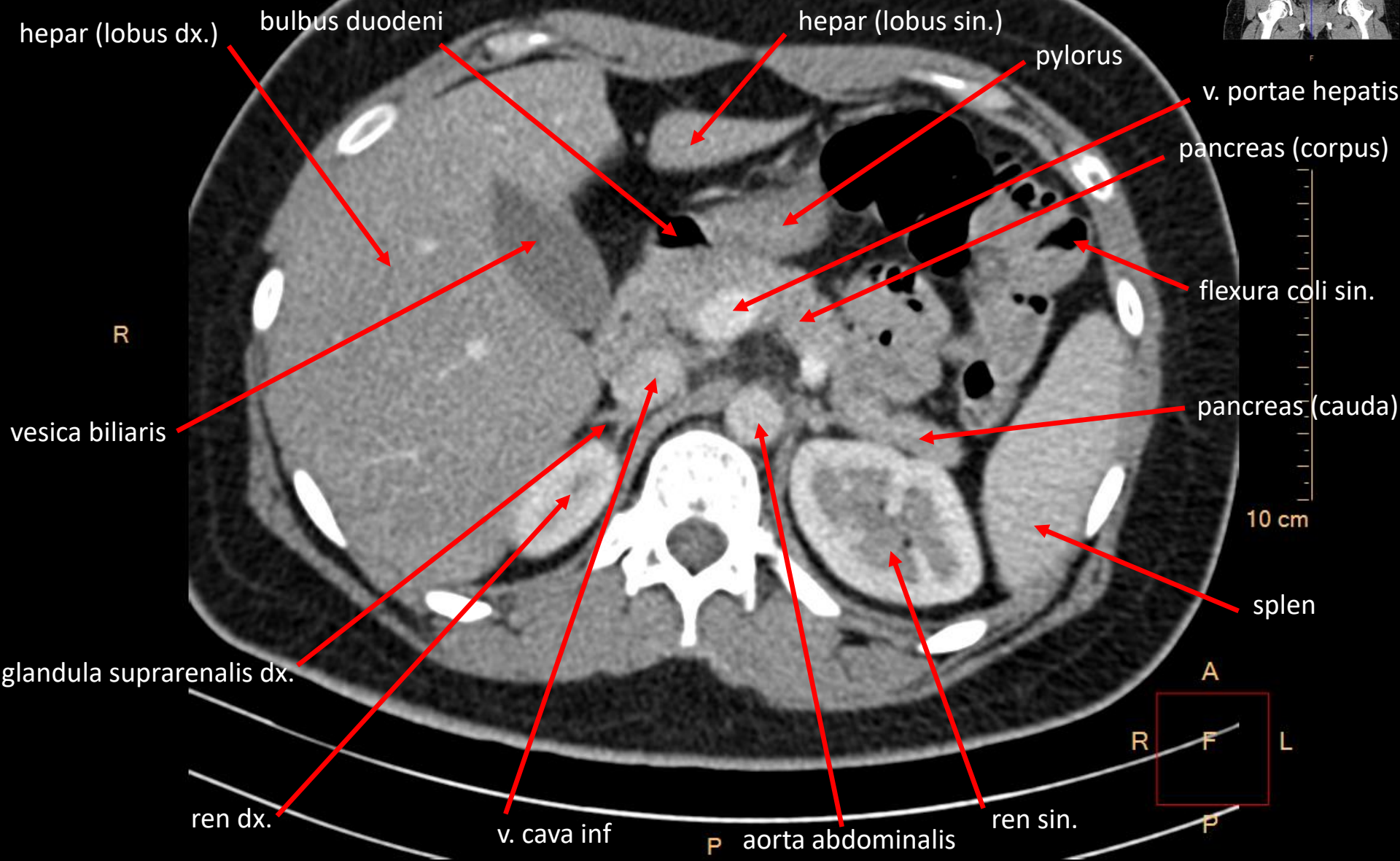
CT angiography of the aorta abdominalis – 3D reconstruction



CT břicha s kontrastní látkou ve střevech

CT of the abdomen with contrast fluid in the intestine

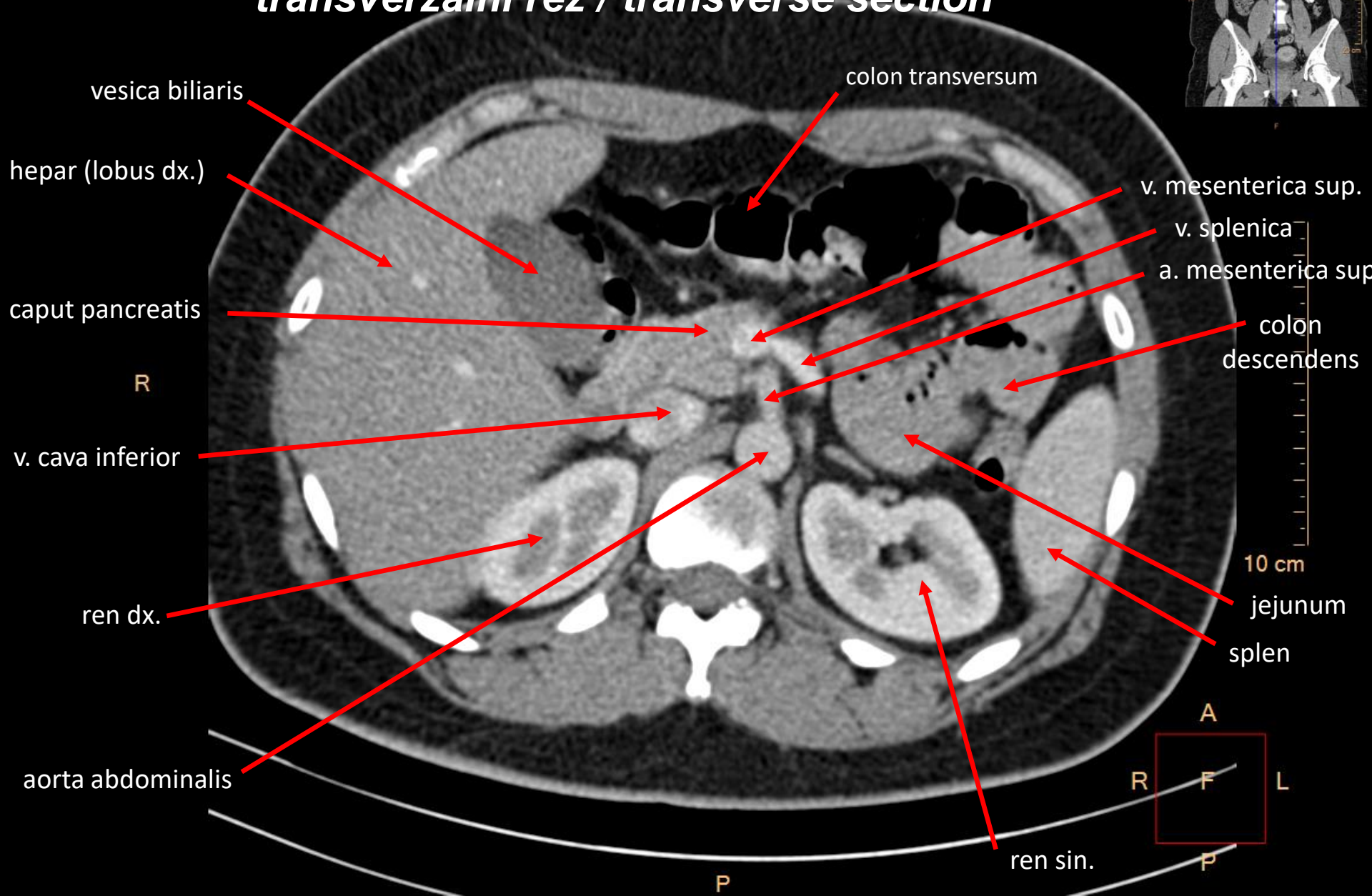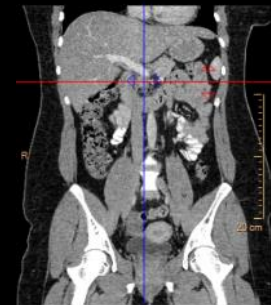
transverzální řez / transverse section



CT břicha s kontrastní látkou ve střevech

CT of the abdomen with contrast fluid in the intestine

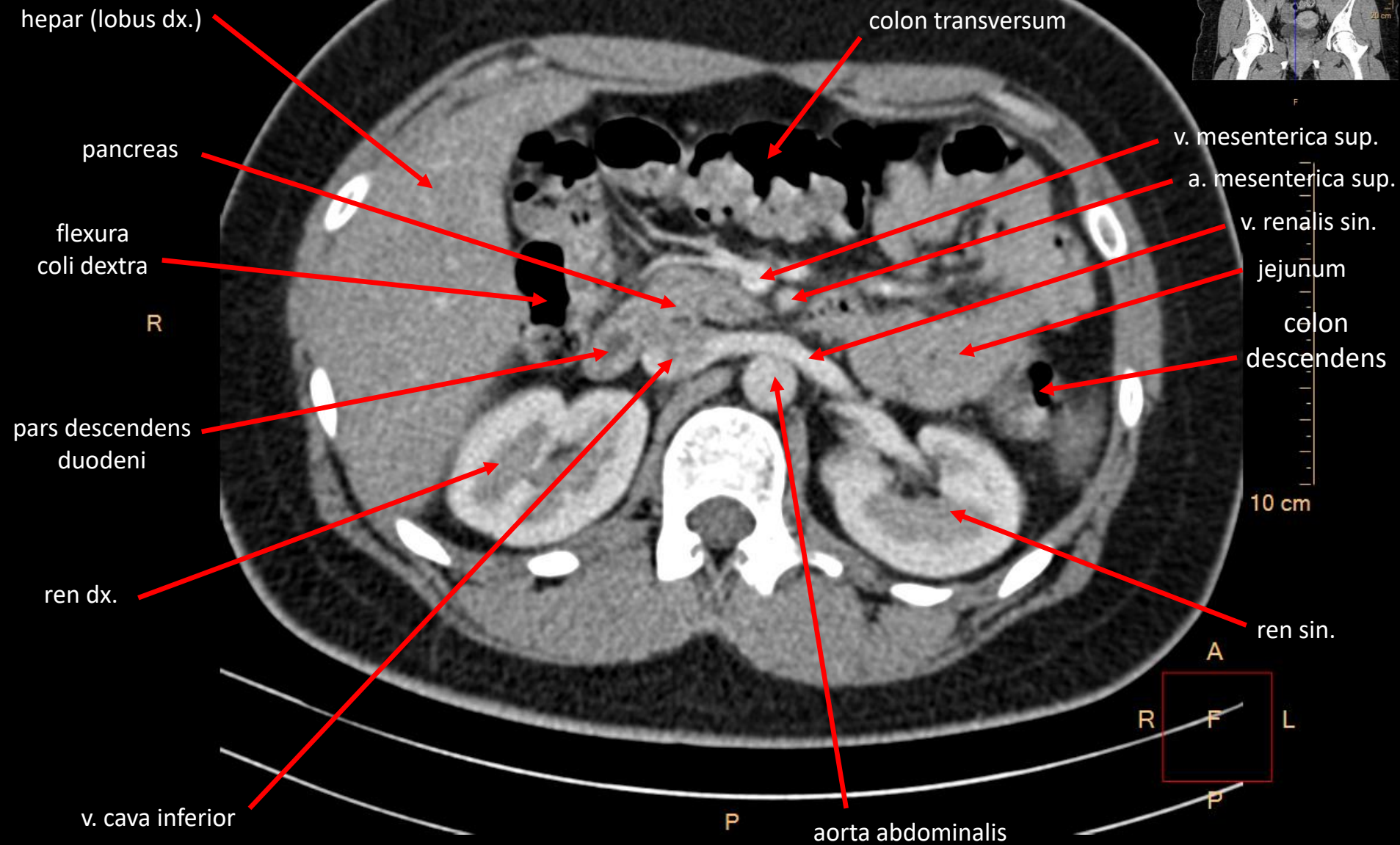
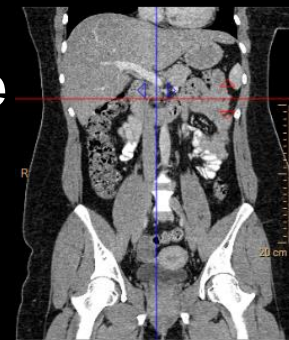transverzální řez / transverse section



CT břicha s kontrastní látkou ve střevech

CT of the abdomen with contrast fluid in the intestine

transverzální řez / transverse section



CT břicha s kontrastní látkou ve střevech

CT of the abdomen with contrast fluid in the intestine

transverzální řez / transverse section

colon ascendens

R

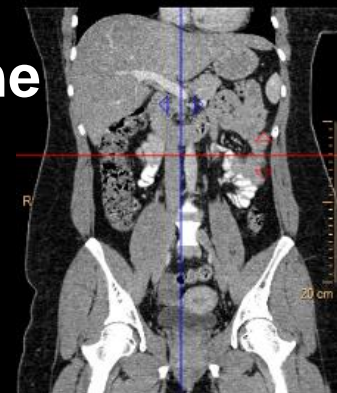ren dx.

v. cava inferior

m. psoas major

P

aorta abdominalis



intestinum tenue

10 cm

colon
descendens

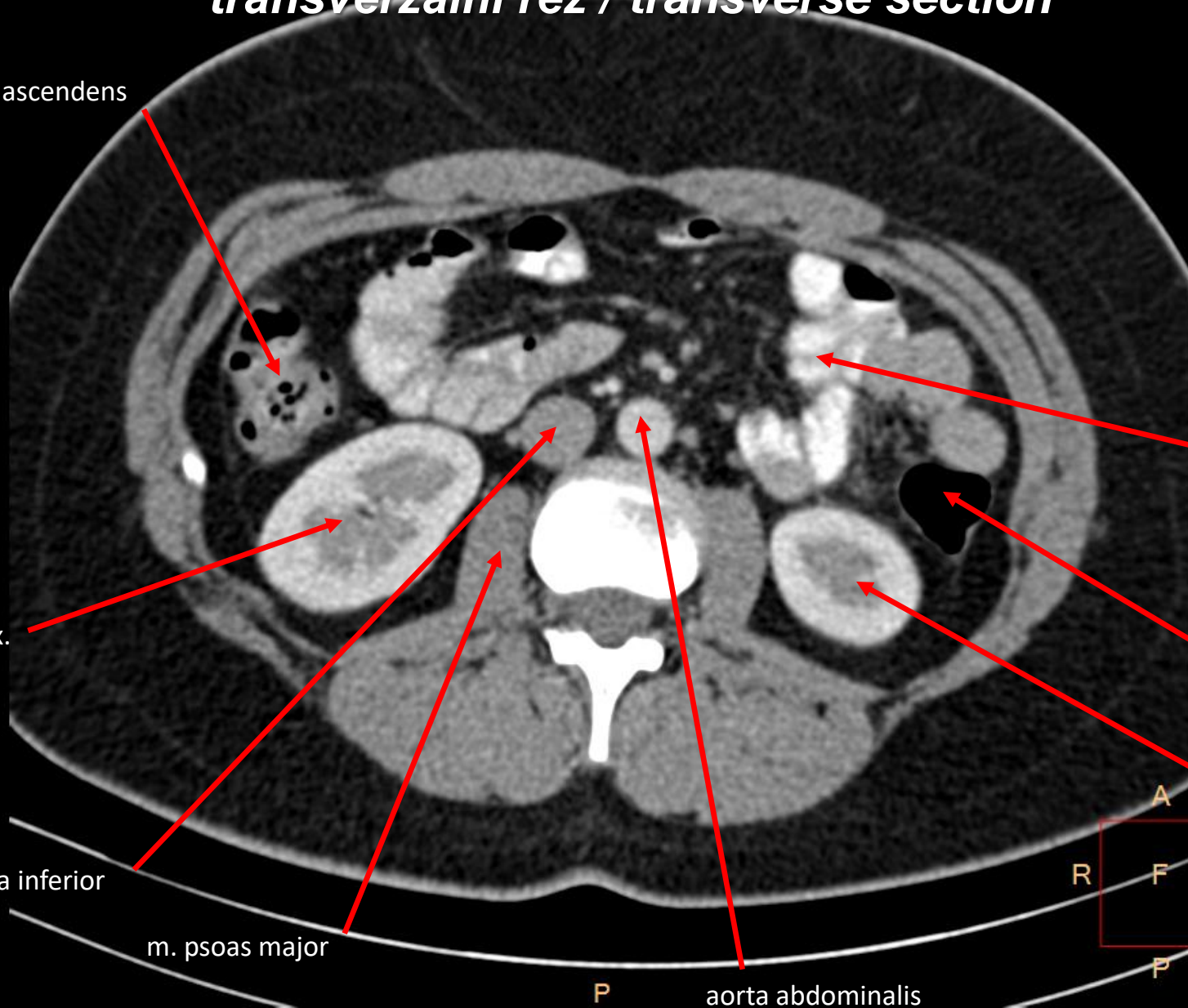ren sin.

R

F

L

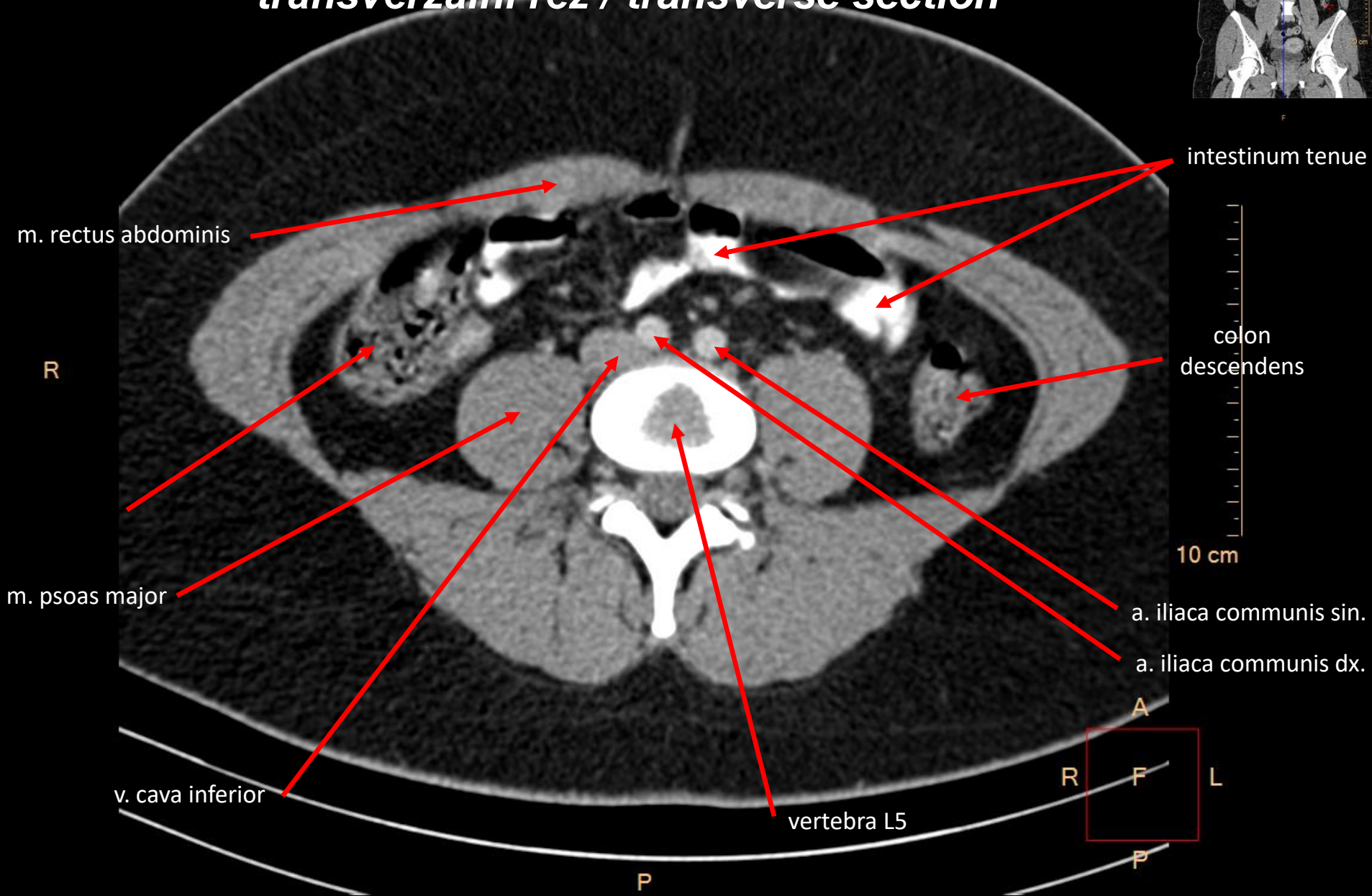
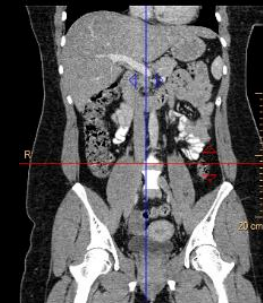
P



CT břicha s kontrastní látkou ve střevech

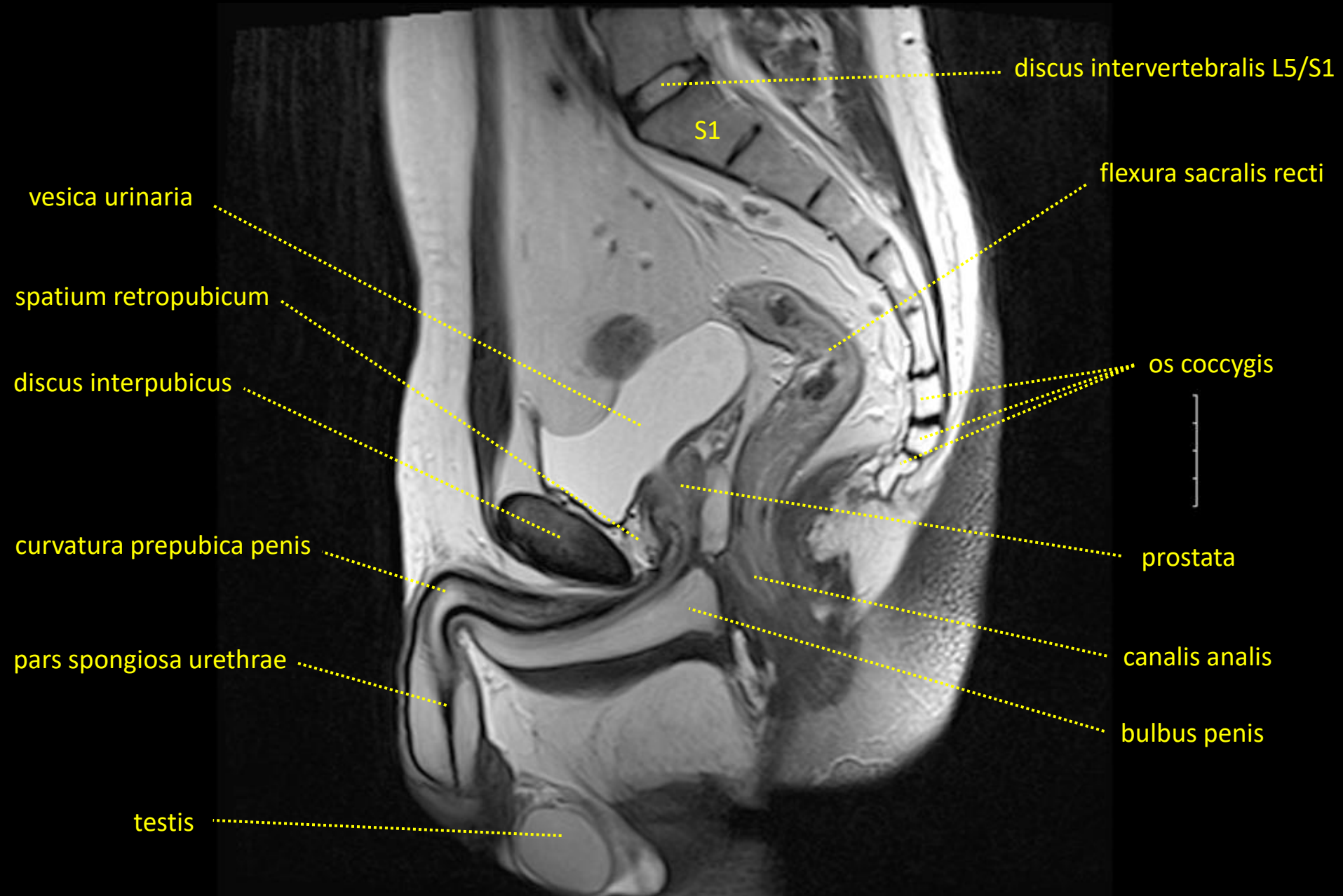
CT of the abdomen with contrast fluid in the intestine

transverzální řez / transverse section



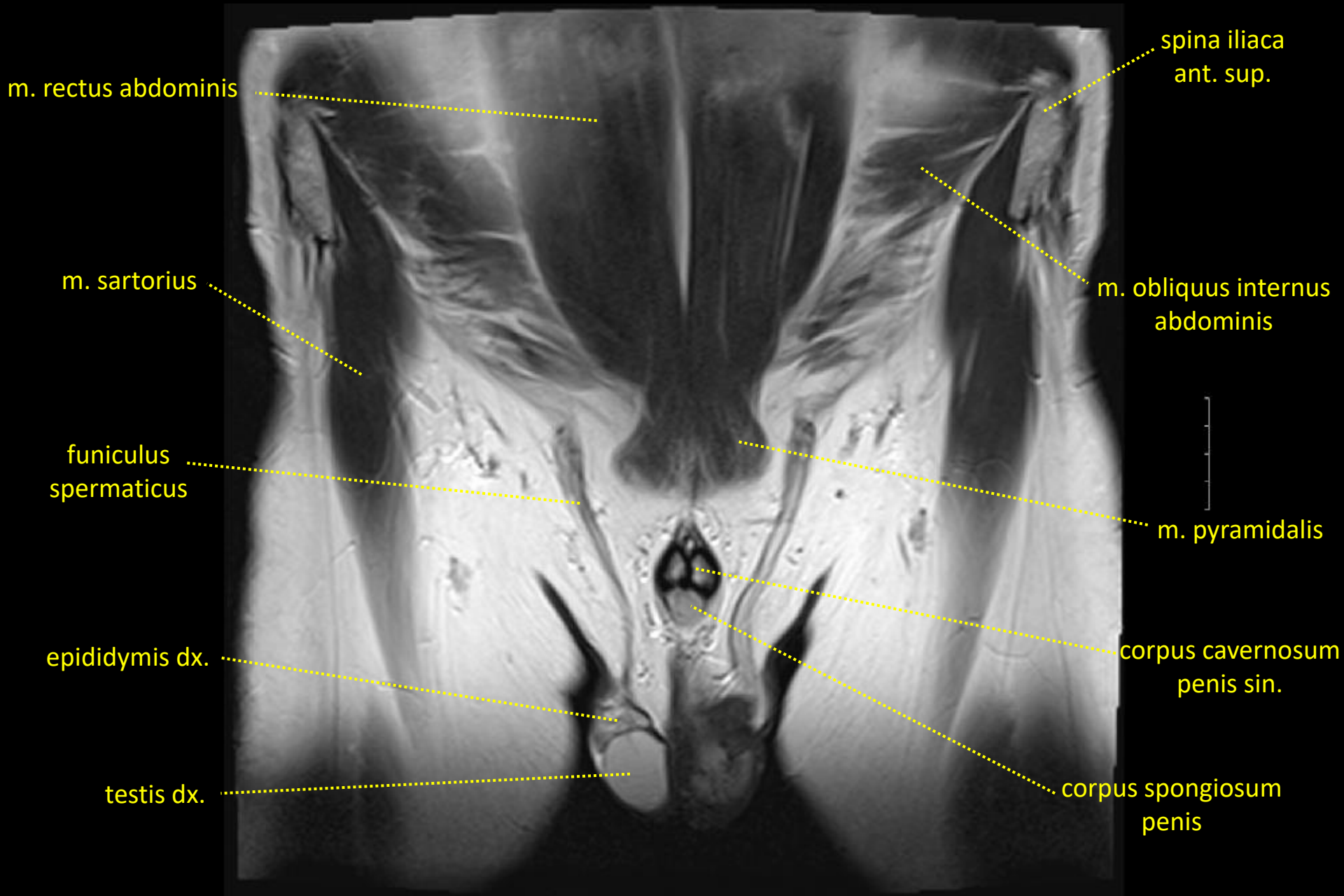
MR mužské pánve / MRI of the male pelvis

mediánní řez / median section



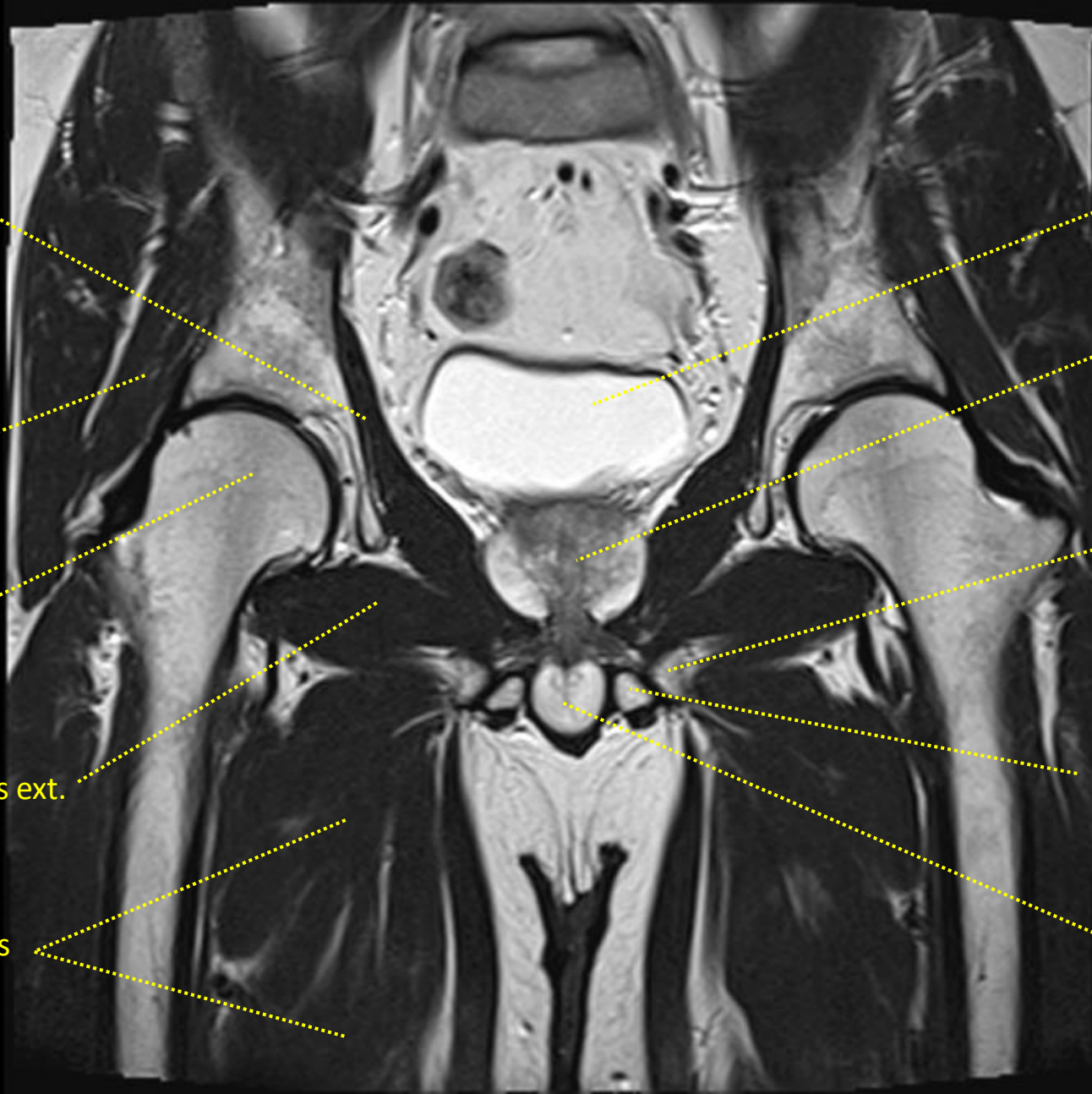
MR mužské pánve / MRI of the male pelvis

frontální řez / frontal section



MR mužské pánve / MRI of the male pelvis

frontální řez / frontal section



m. levator ani

m. gluteus minimus

caput femoris

m. obturatorius ext.

mm. adductores

vesica urinaria

prostata

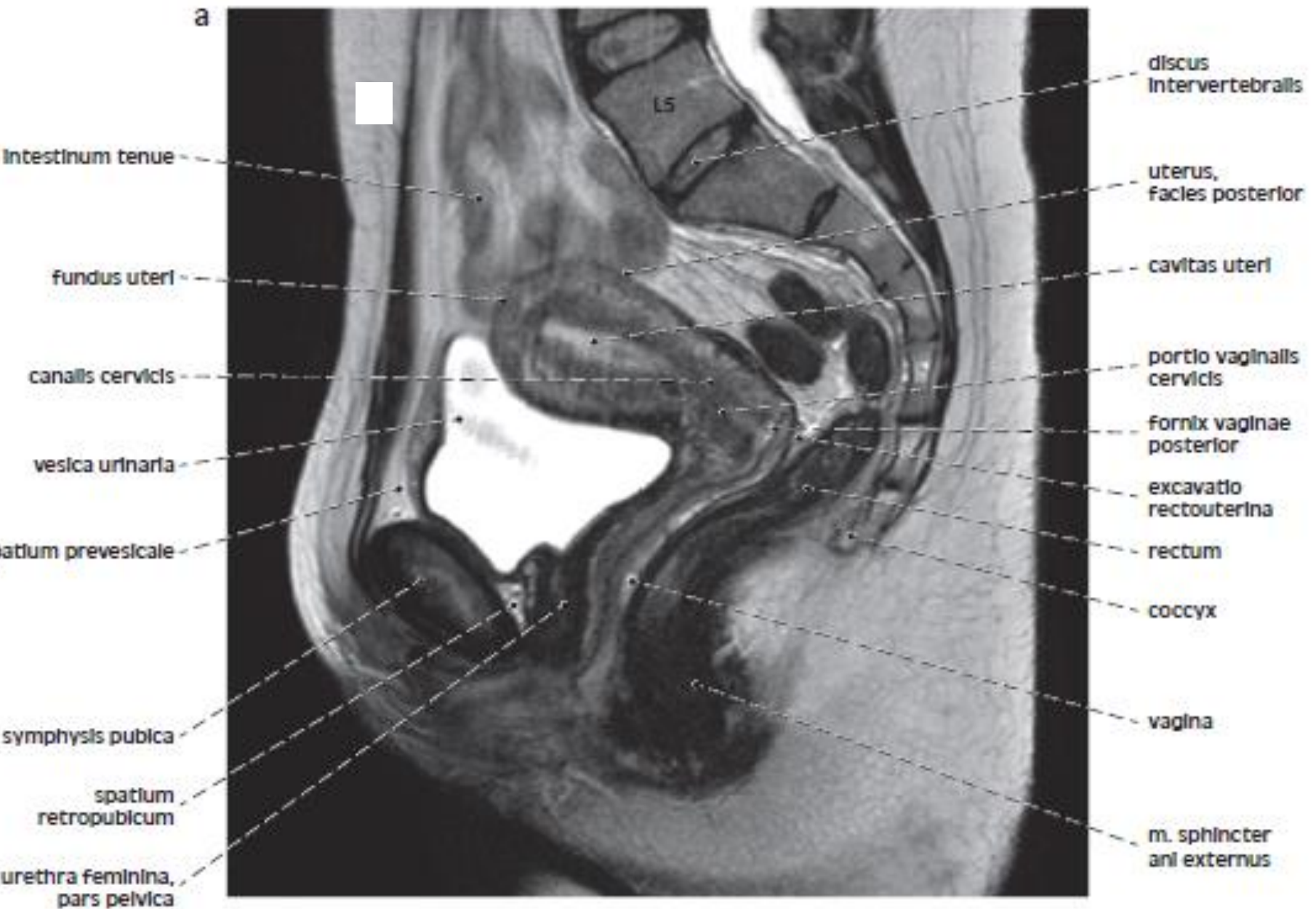
ramus inferior
ossis pubis

corpus cavernosum
penis sin.

bulbus penis

MR ženské pánve / MRI of the female pelvis

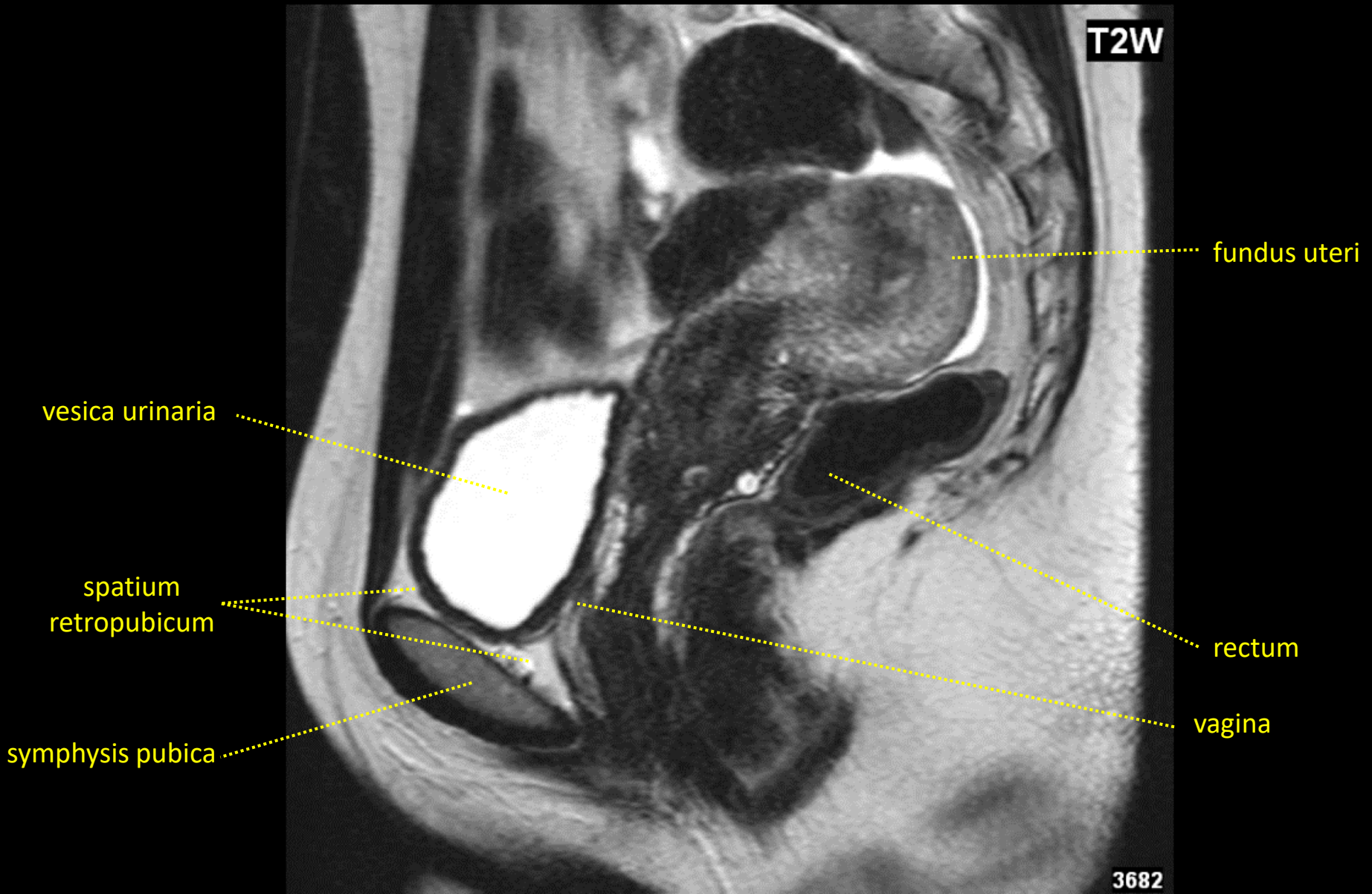
mediánní řez / median section



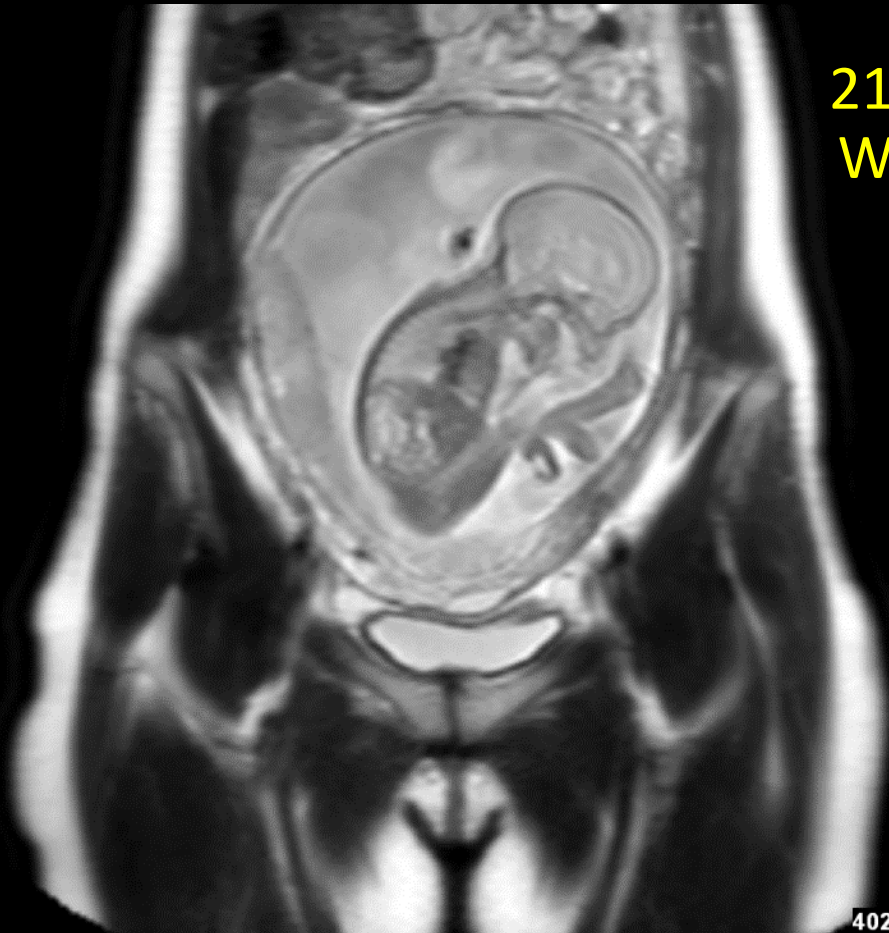
MR ženské pánve / MRI of the female pelvis

mediánní řez / median section

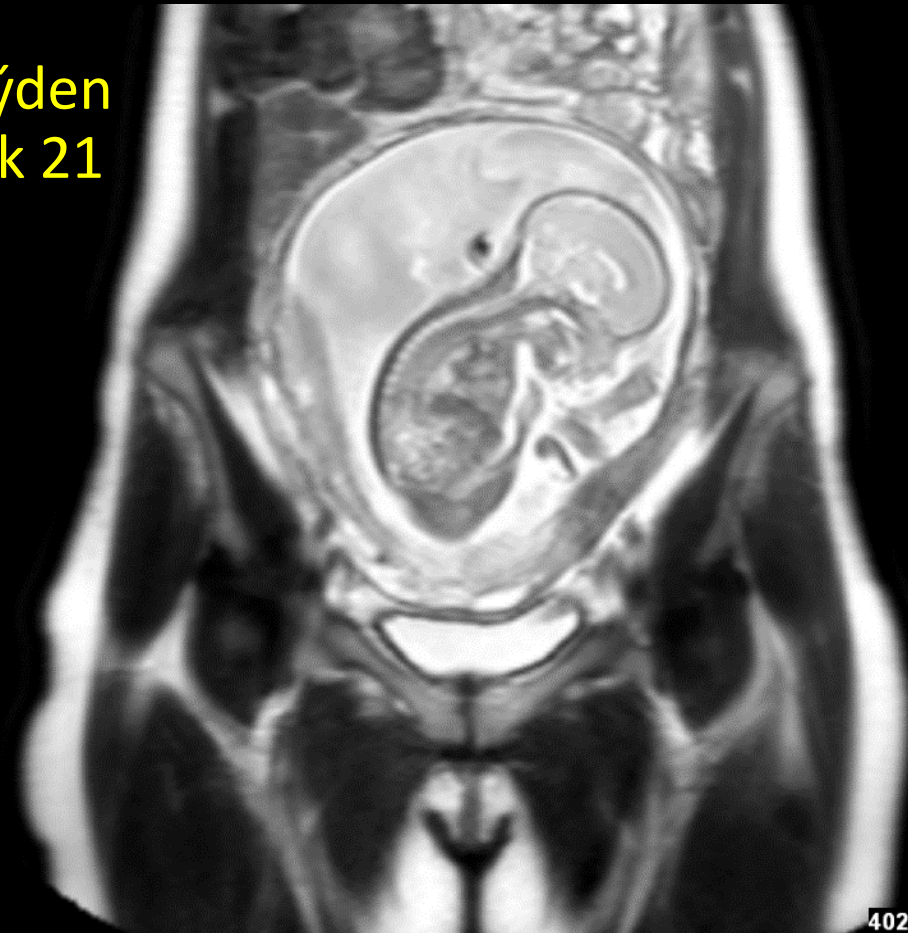
Retroverze + retroflexe dělohy / Retroversion + retroflexion of uterus



MR ženské pánve v těhotenství
MRI of the female pelvis in pregnancy
frontální řez / frontal section



21. týden
Week 21



MR ženské pánve v těhotenství

MRI of the female pelvis in pregnancy

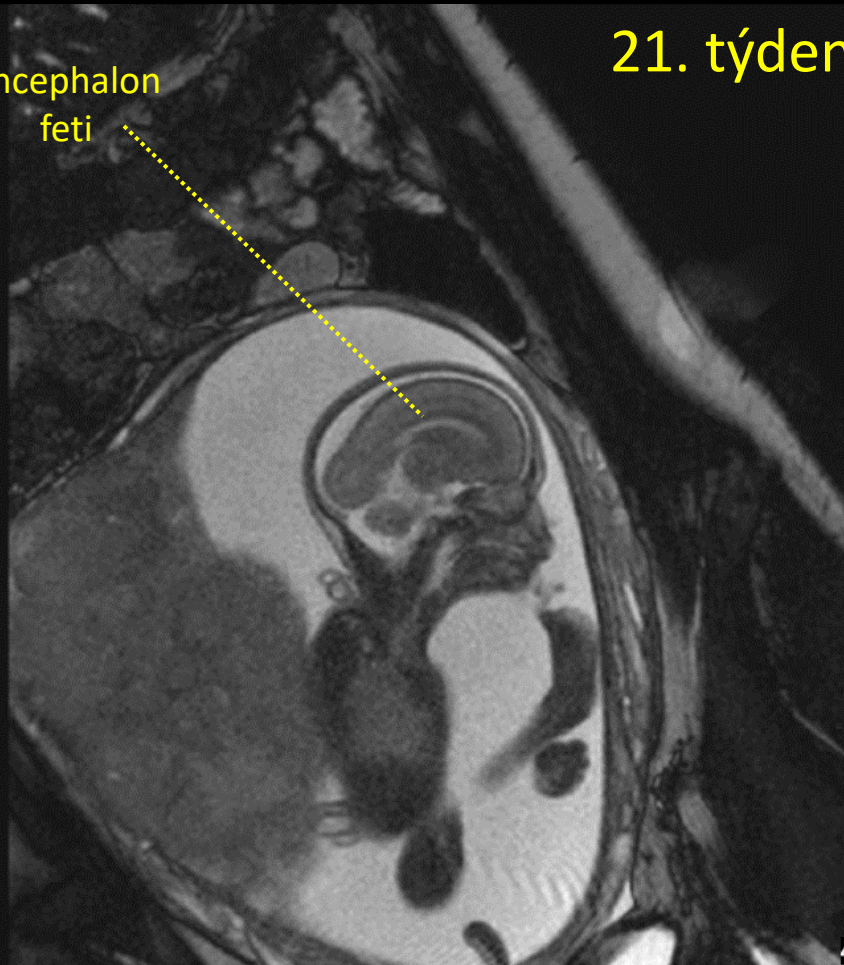
sagitální řez / sagittal section

příčný řez / transverse section

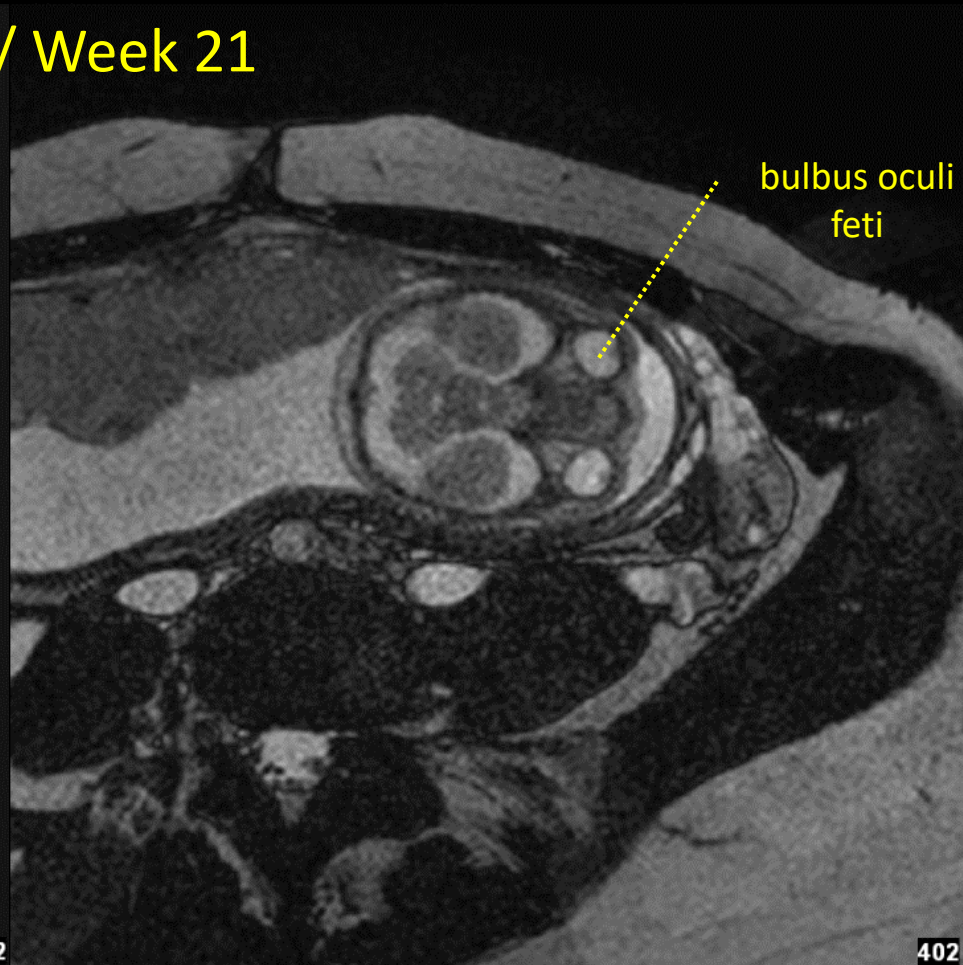
21. týden / Week 21

encephalon
feti

bulbus oculi
feti



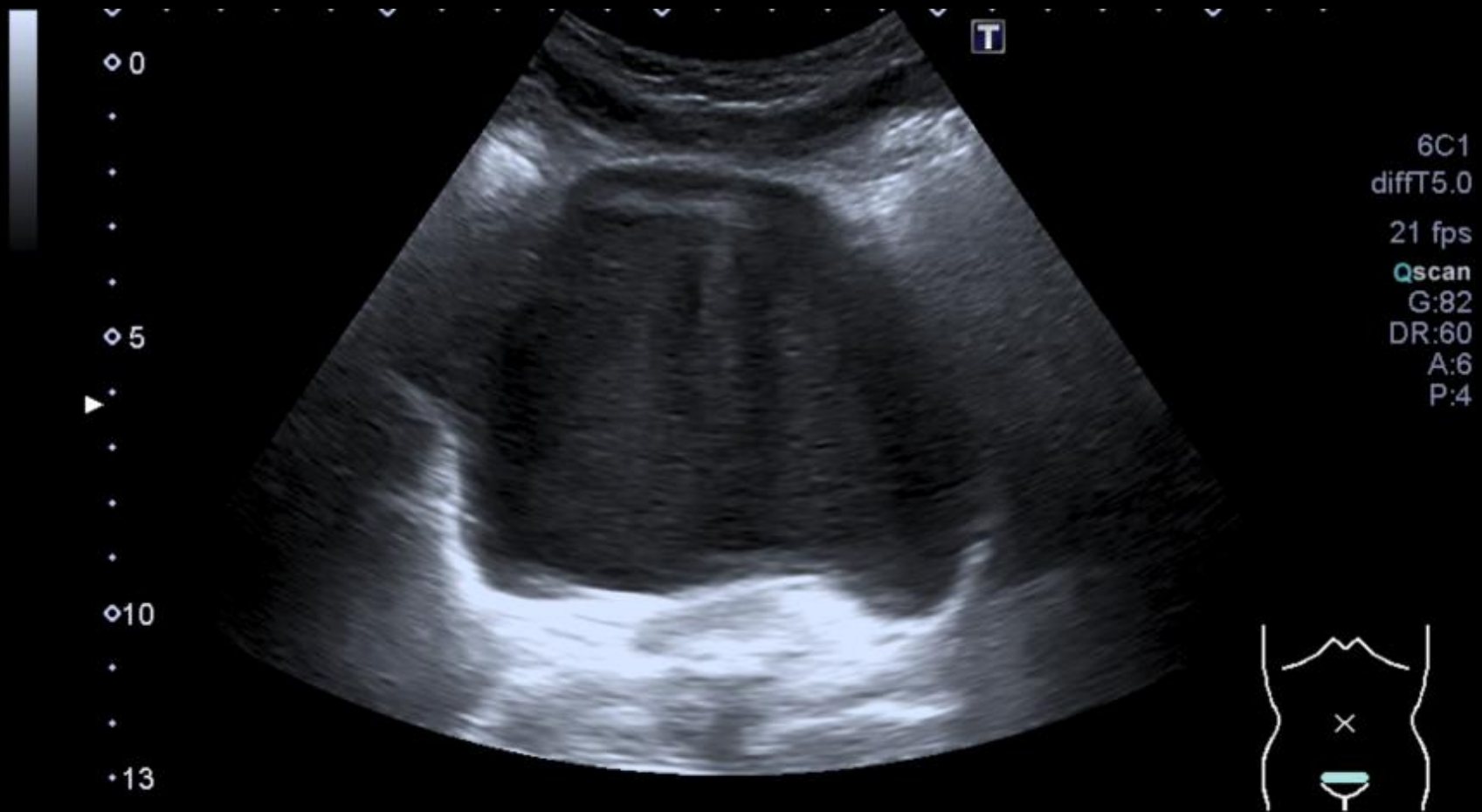
402



402

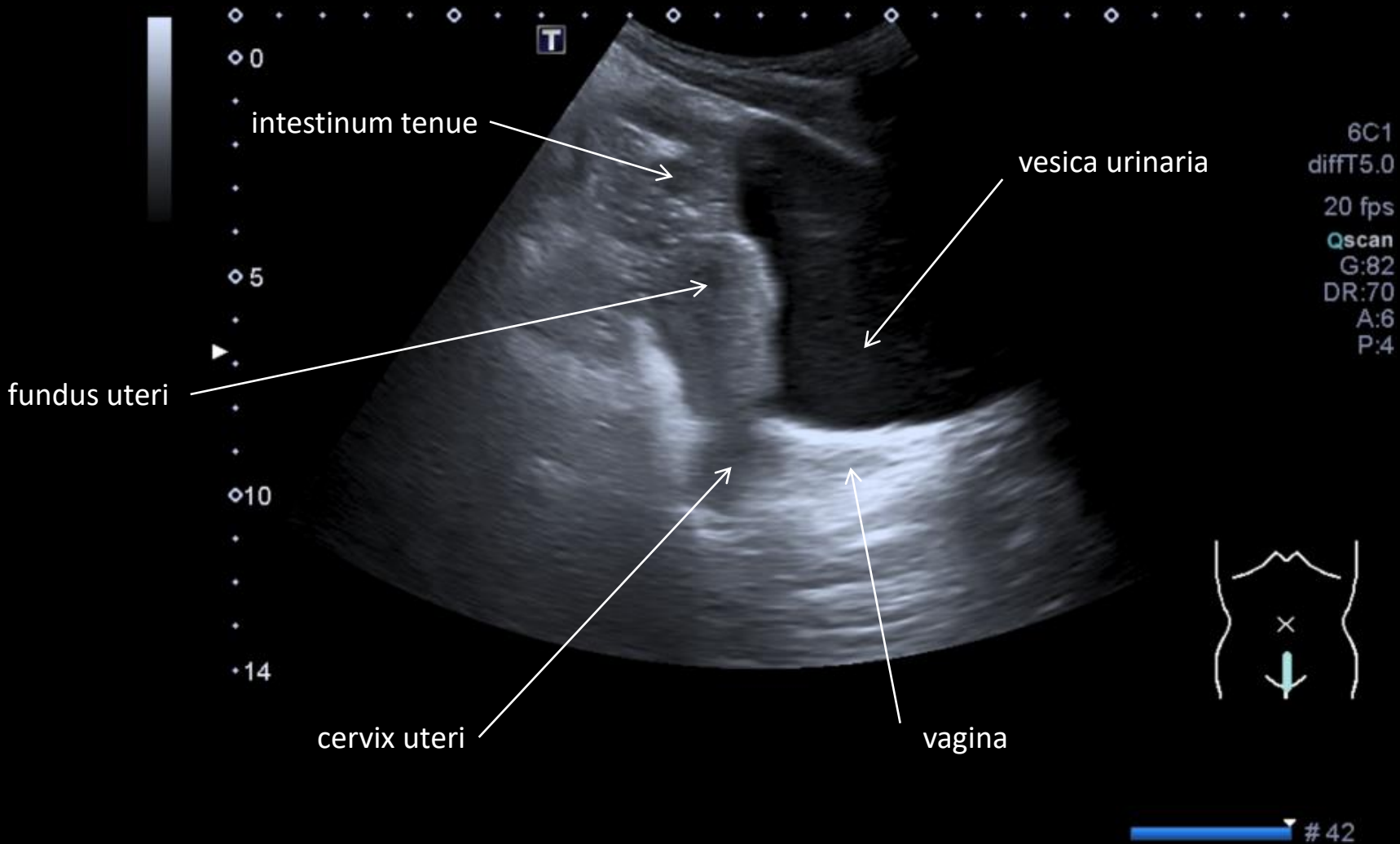
Ultrazvukové vyšetření močového měchýře

Ultrasound examination of the urinary bladder



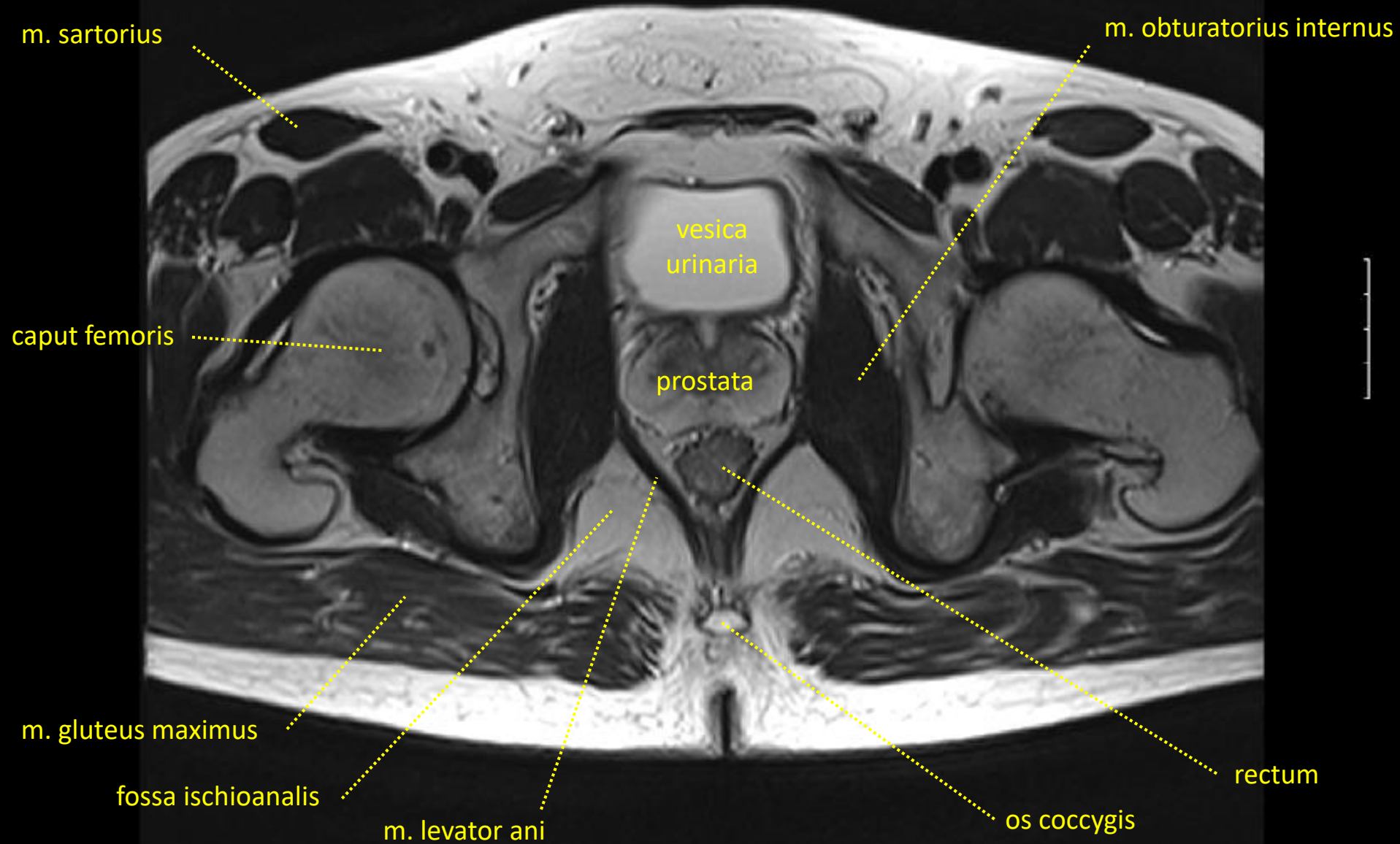
Ultrazvukové vyšetření močového měchýře

Ultrasound examination of the urinary bladder



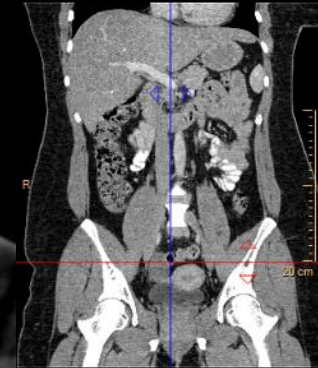
MR břicha / MRI of the abdomen

transverzální řez / transverse section



CT pánve / CT of the pelvis

transverzální řez / transverse section



m. rectus abdominis



R

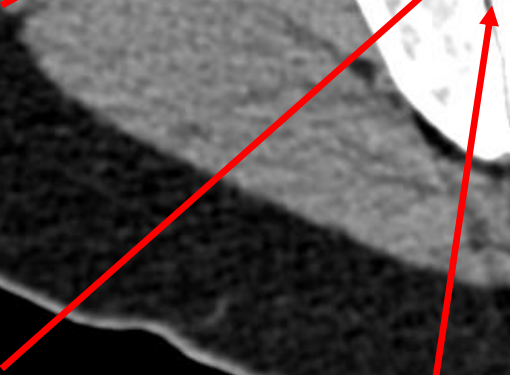
m. iliacus



m. psoas major



ovarium dx.



articulatio sacroiliaca




P


rectum



ovarium sin.



a. iliaca externa



v. iliaca externa



10 cm

R

F

L


P



CT pánve / CT of the pelvis

transverzální řez / transverse section

lig. teres uteri

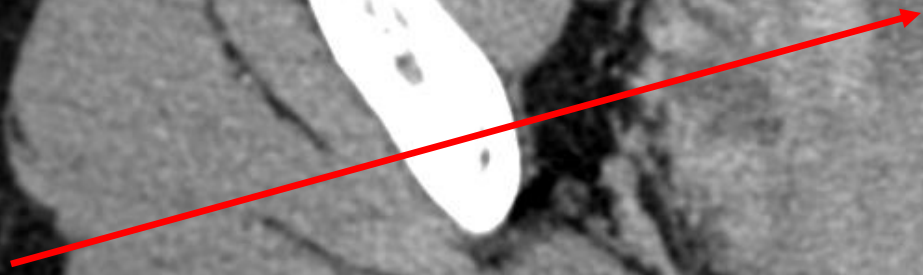


m. iliopsoas




R

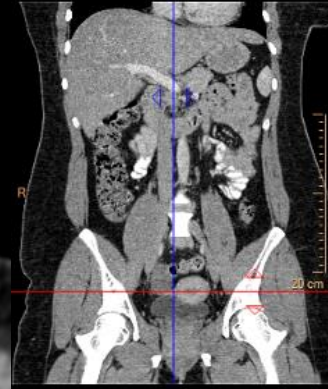uterus



rectum



10 cm



R

A

P

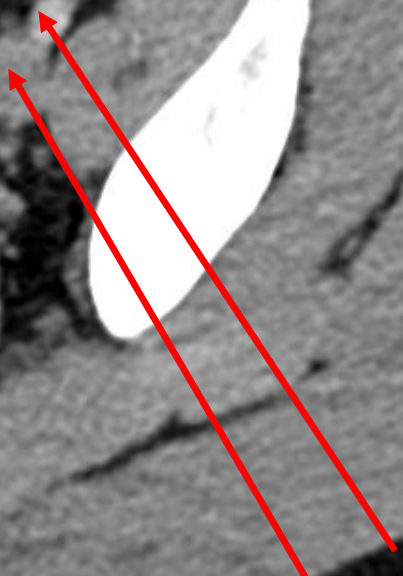
F

L

excavatio rectouterina

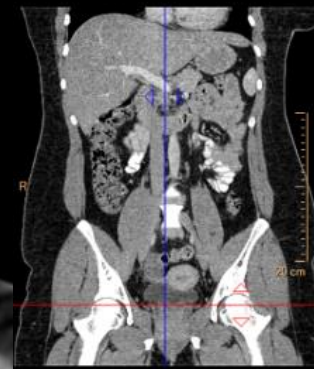


a. iliaca externa
v. iliaca externa




CT pánve / CT of the pelvis

transverzální řez / transverse section



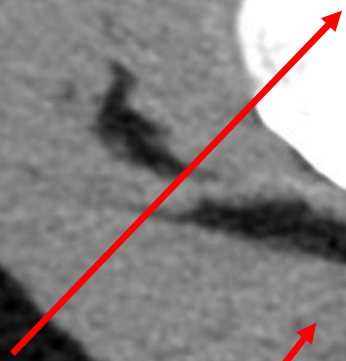
m. rectus abdominis



vesica urinaria

R

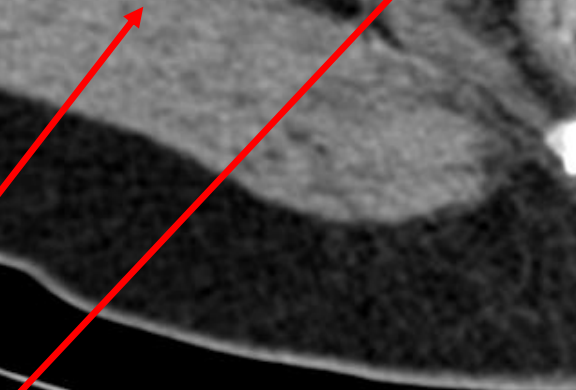
caput femoris



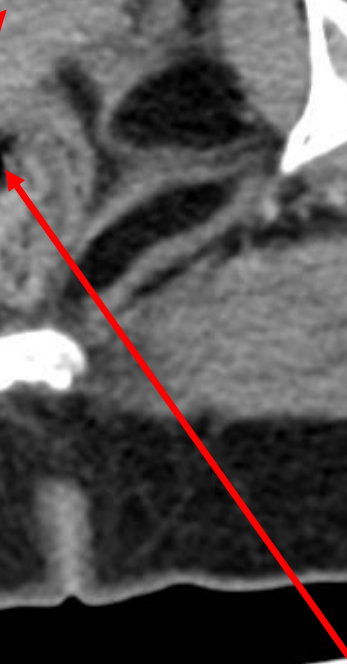
m. gluteus maximus



vagina



rectum



10 cm

