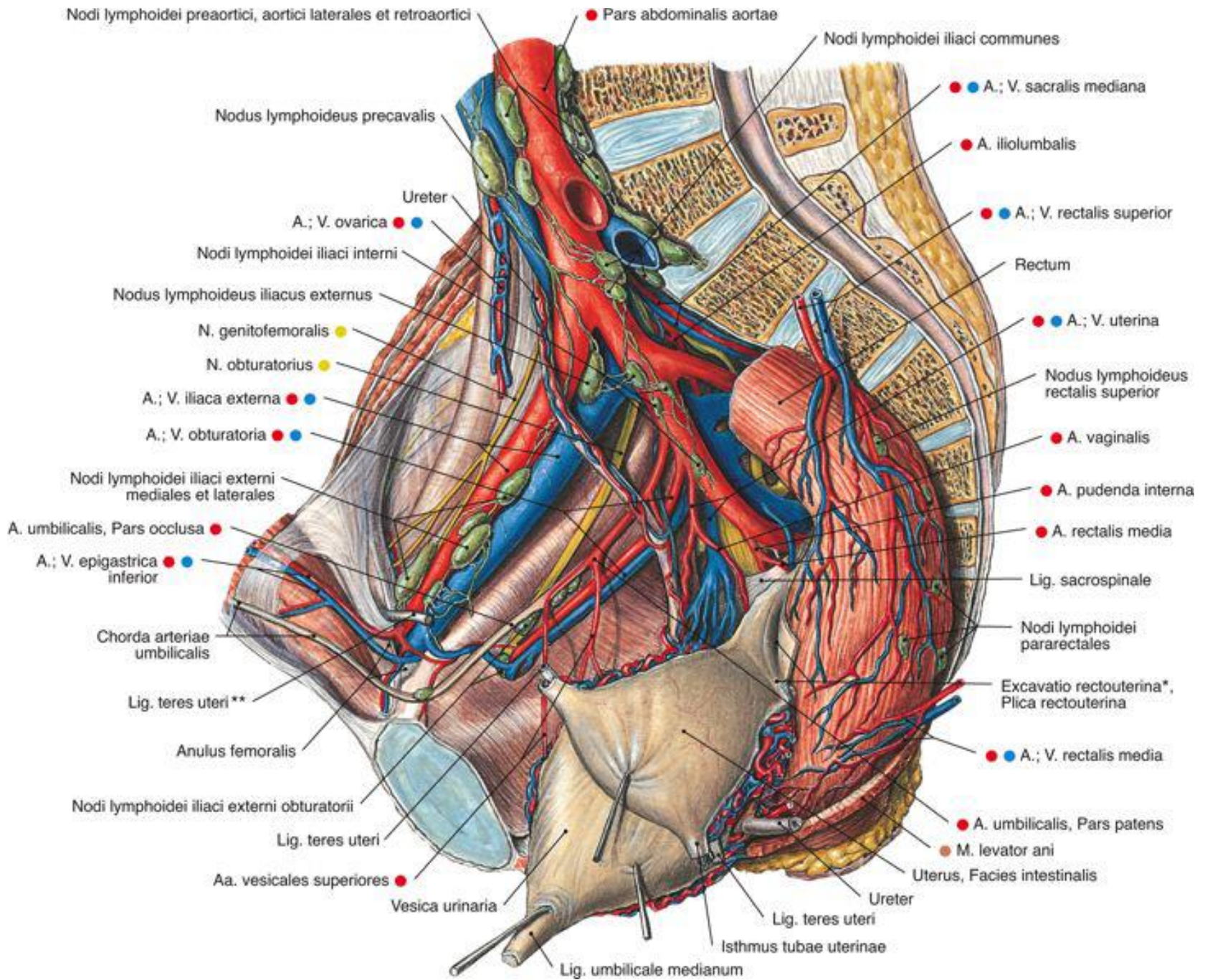
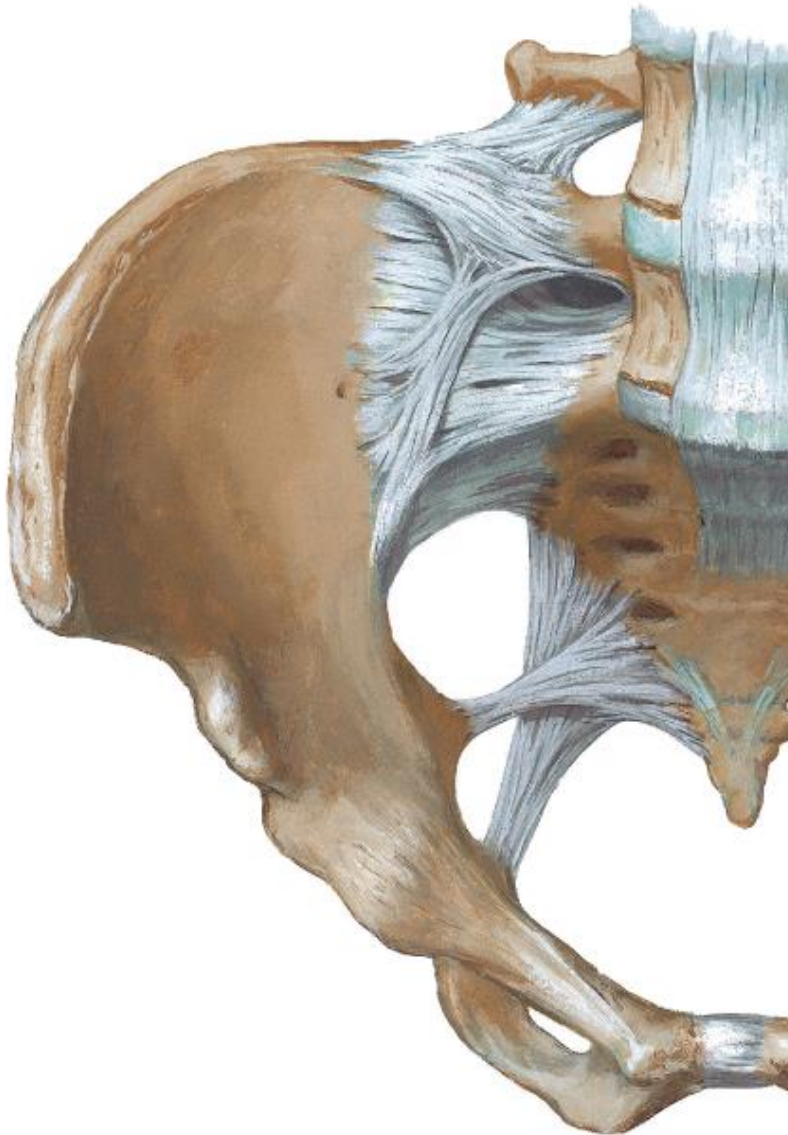


Topography of pelvis

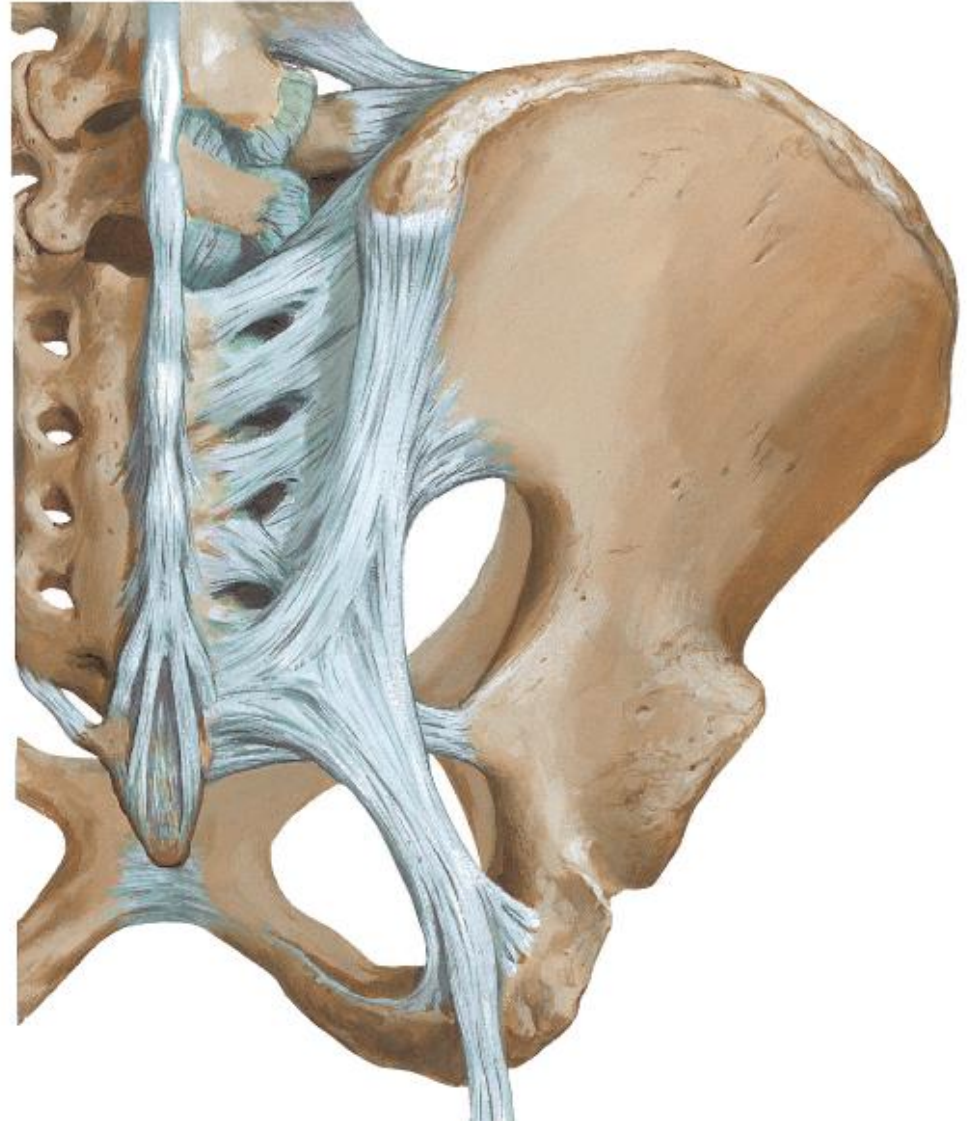


Ligaments

lig. sacroiliacum anterius



lig. sacroiliacum posterius



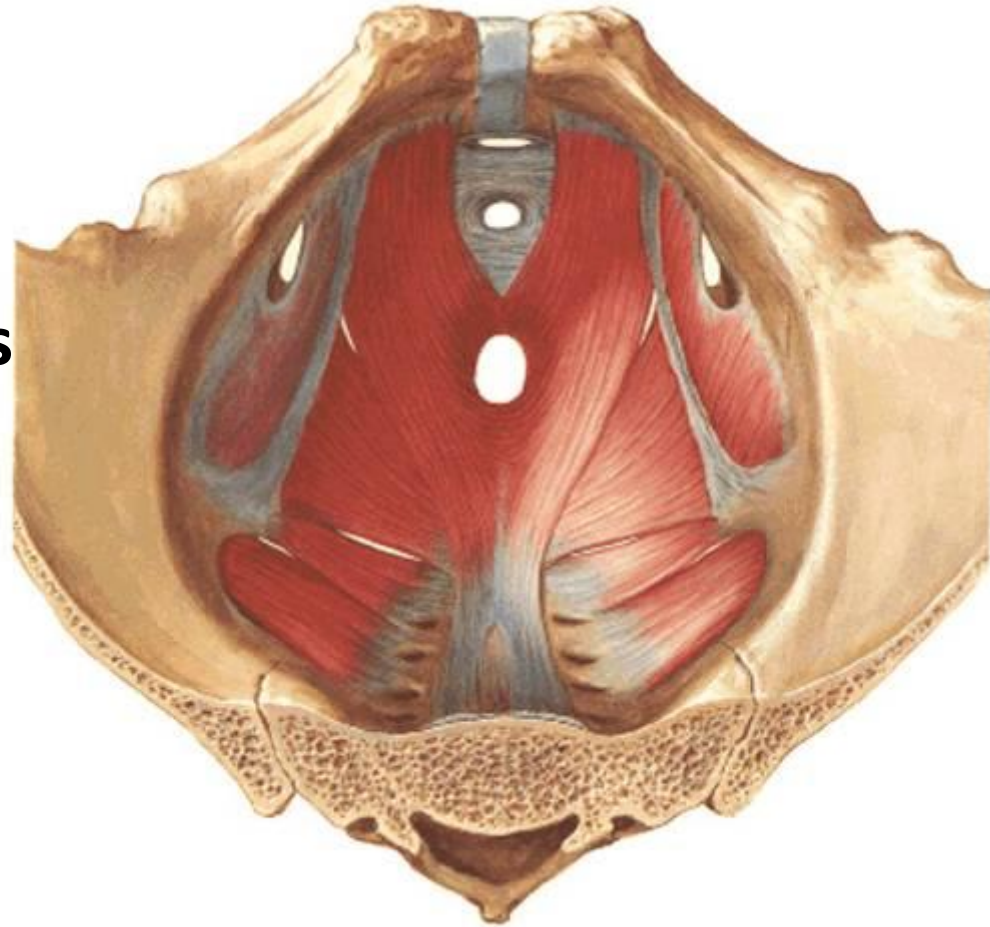
Muscles of pelvic floor

- **m. levator ani**
- **m. ischiooccocygeus**
- **m. sphincter ani externus**

innervation:

n. pudendus (ventrolateral part)

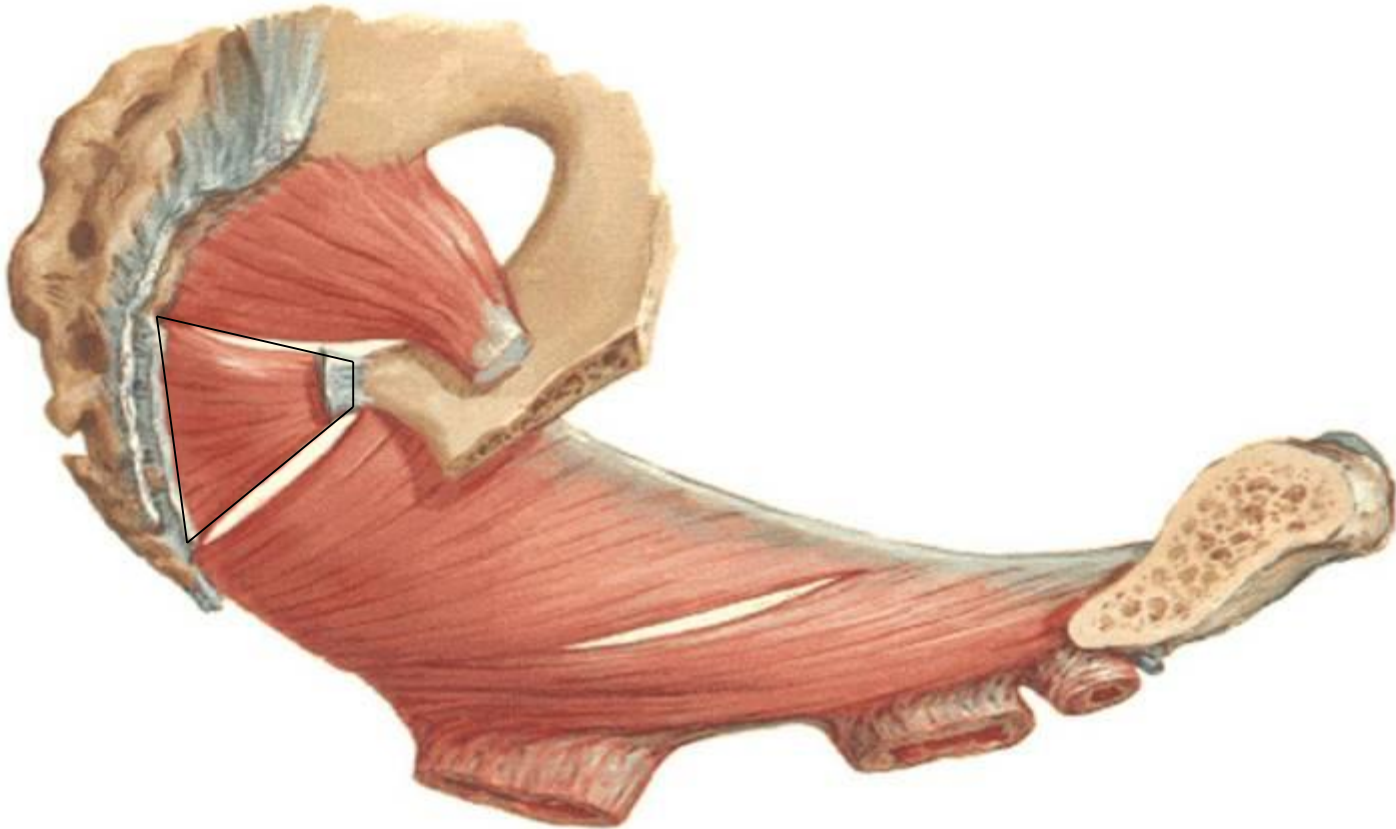r. anterior n. sacralis S4



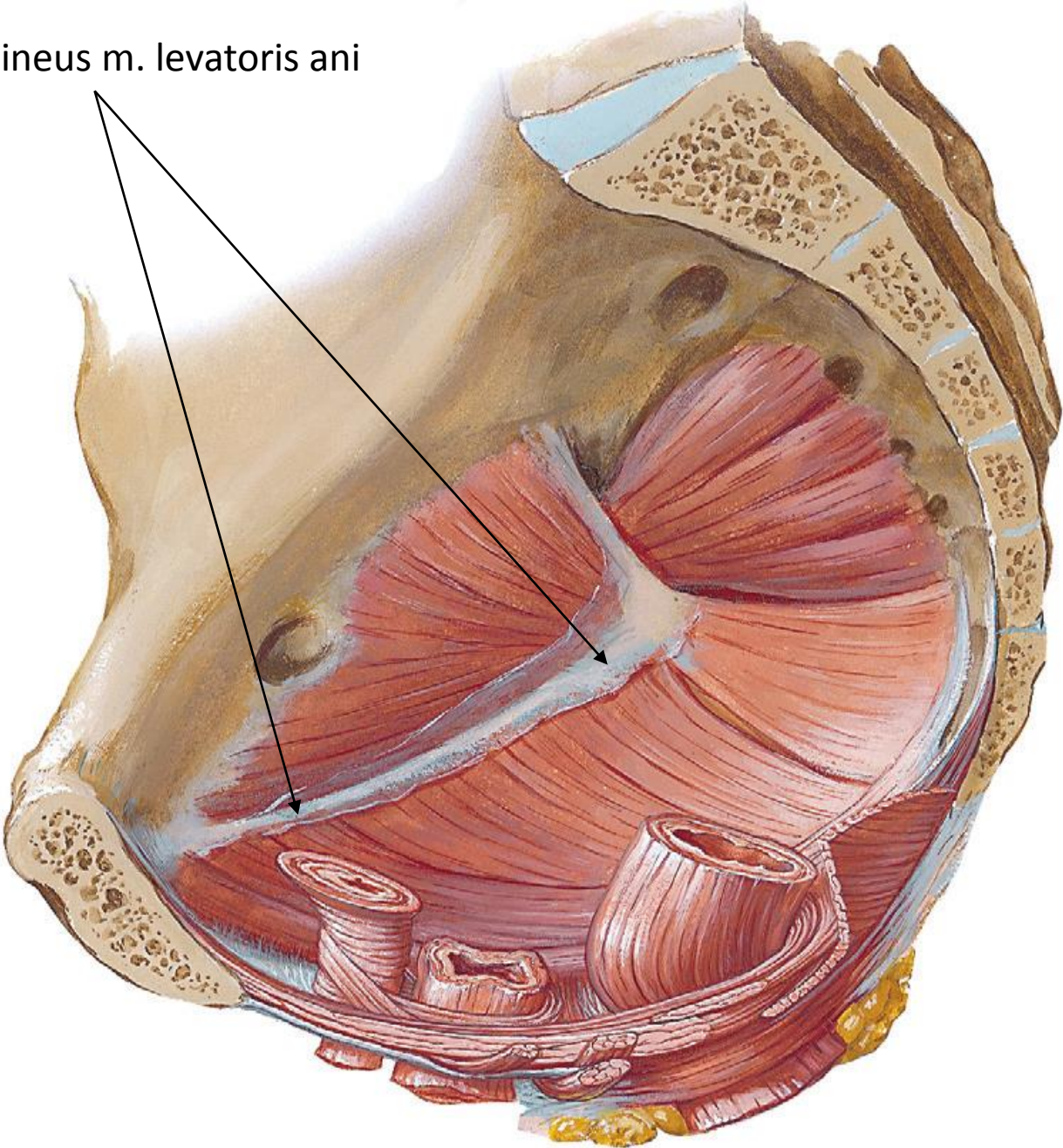
Muscles of pelvic floor

M. ischiococcygeus (coccygeus)

- parallel and internal to lig. sacrospinale



arcus tendineus m. levatoris ani



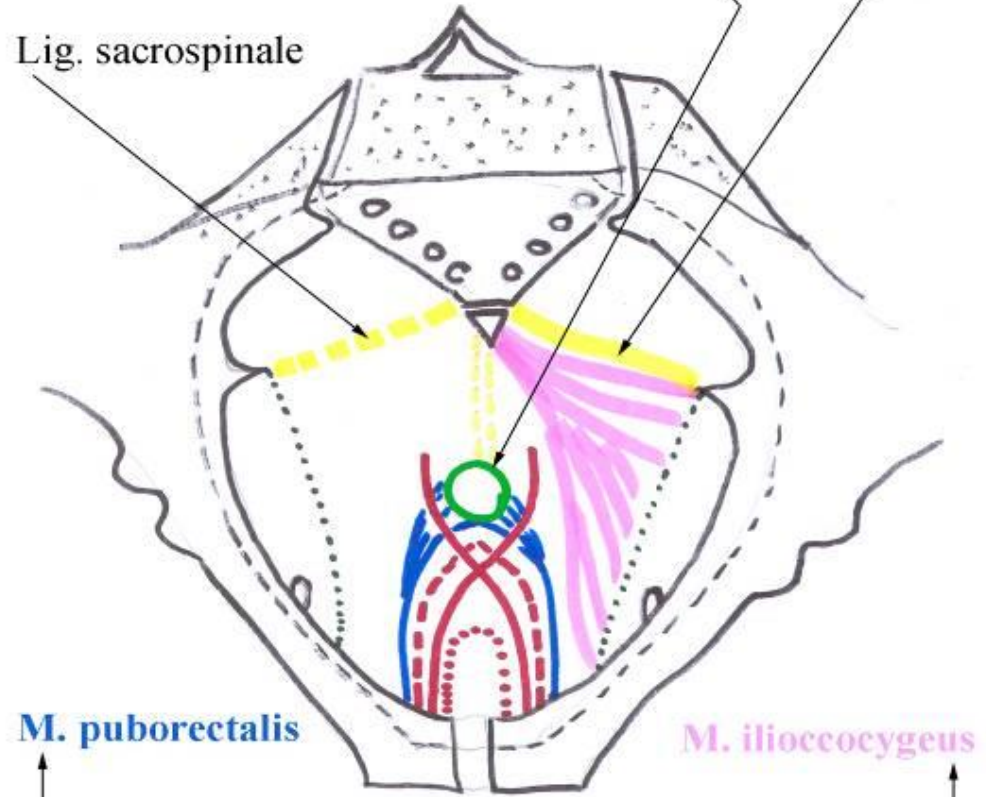
Muscles of pelvic floor

M. levator ani

M. ISCHIOCOCCYGEUS

M. SPHINCTER ANI EXTERNUS

Lig. sacrospinale



M. puborectalis

M. iliococcygeus

M. pubococcygeus

--- m. puboperinealis

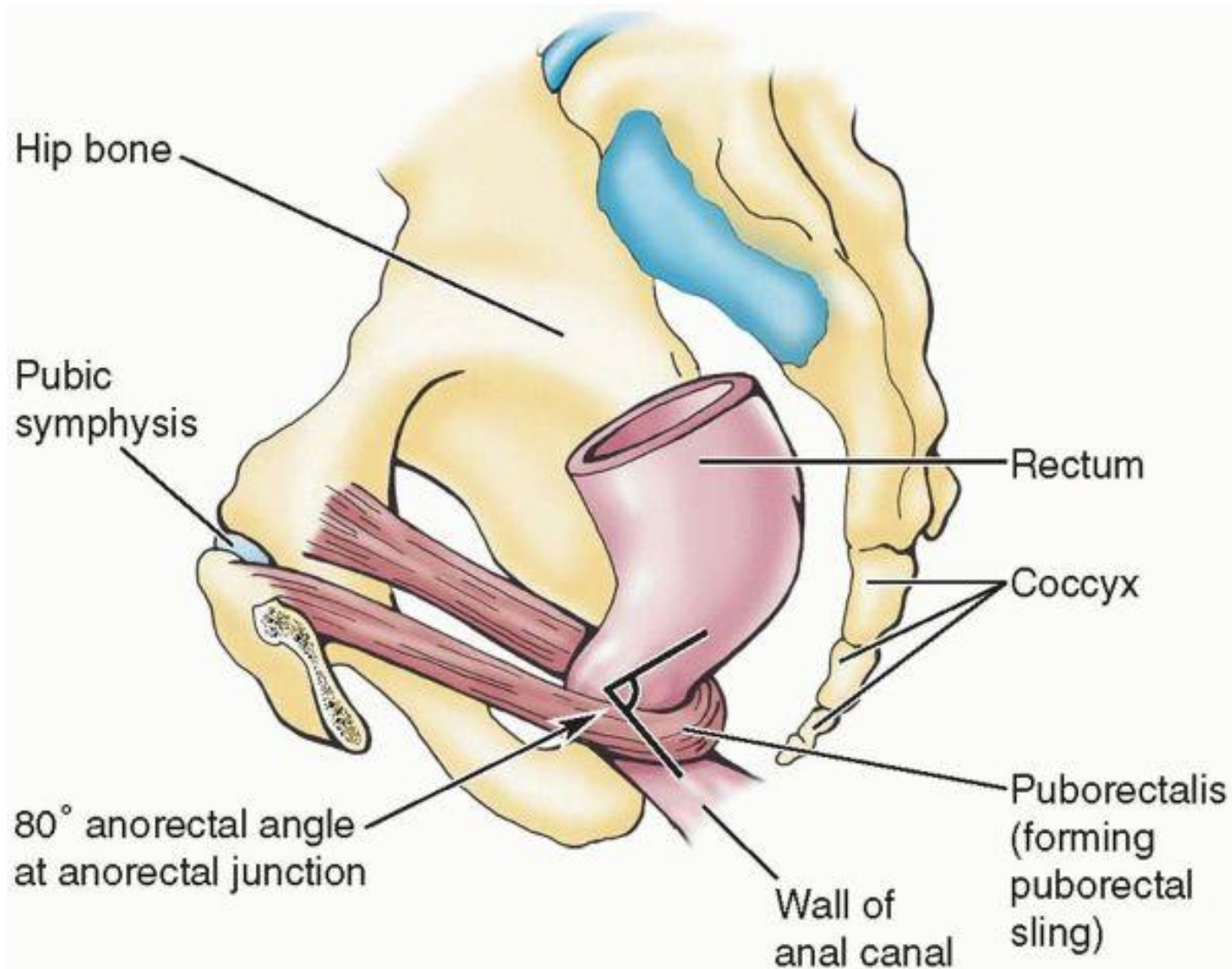
— m. puboanalis

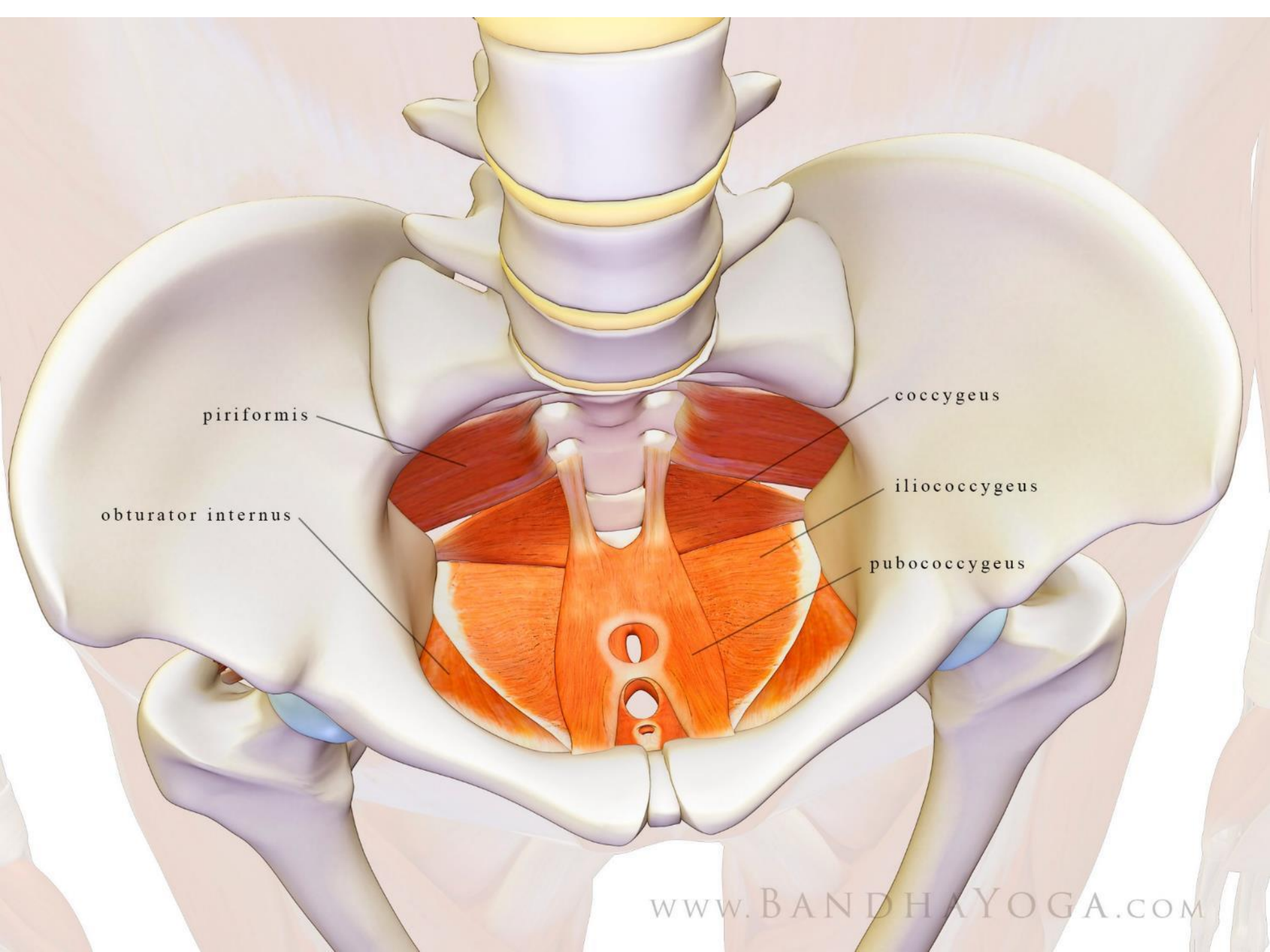
..... m. puboprostaticus / pubovaginalis

M. LEVATOR ANI

- m. pubococcygeus
 - m. puboperinealis
 - m. puboprostaticus (=m. levator prostatae)
 - in males
 - m. pubovaginalis
 - in females
 - m. puboanalis
- m. puborectalis – caudally to m. pubococcygeus
- m. iliococcygeus – originates from arcus tendineus m. levatoris ani

M. puborectalis





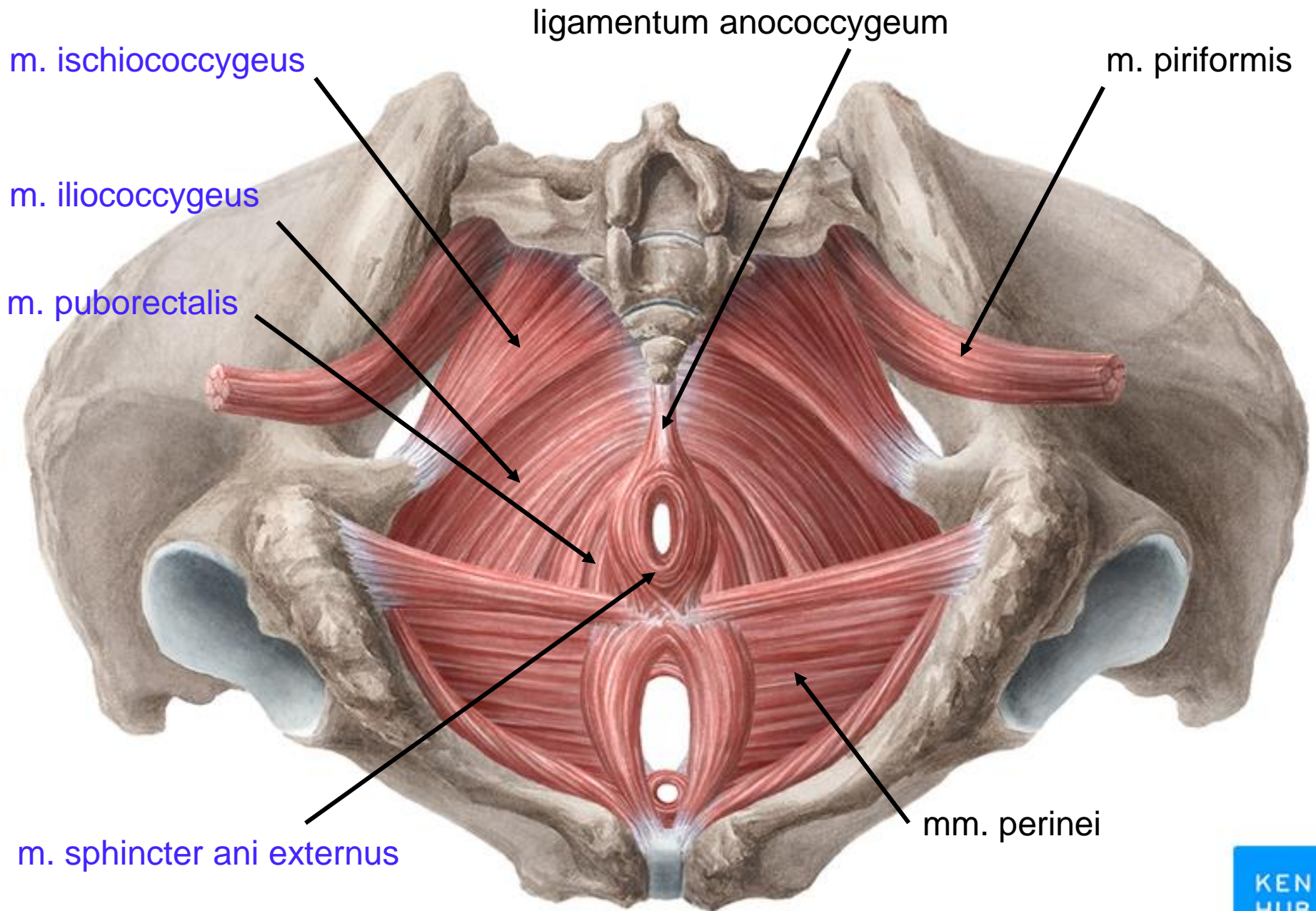
piriformis

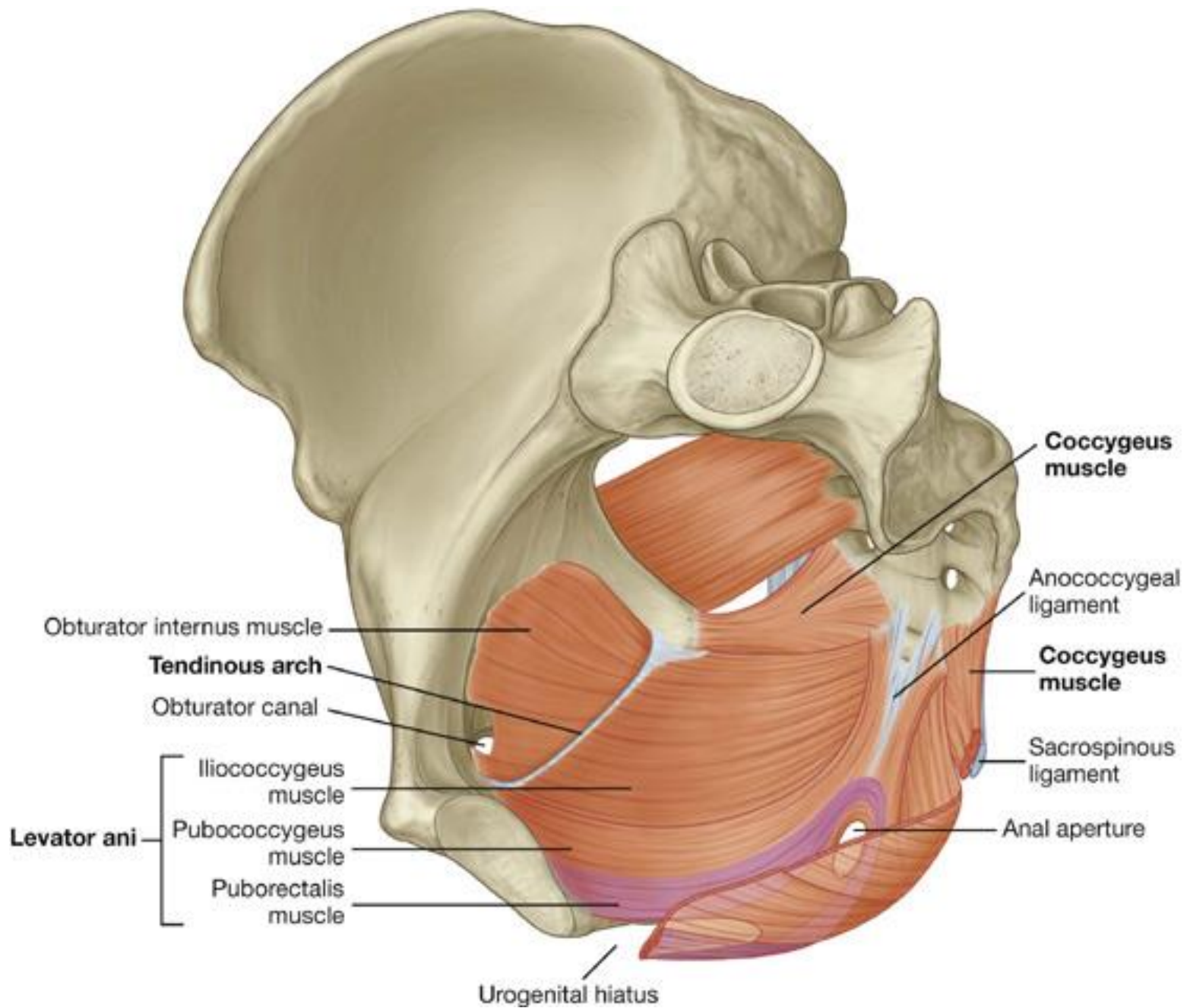
obturator internus

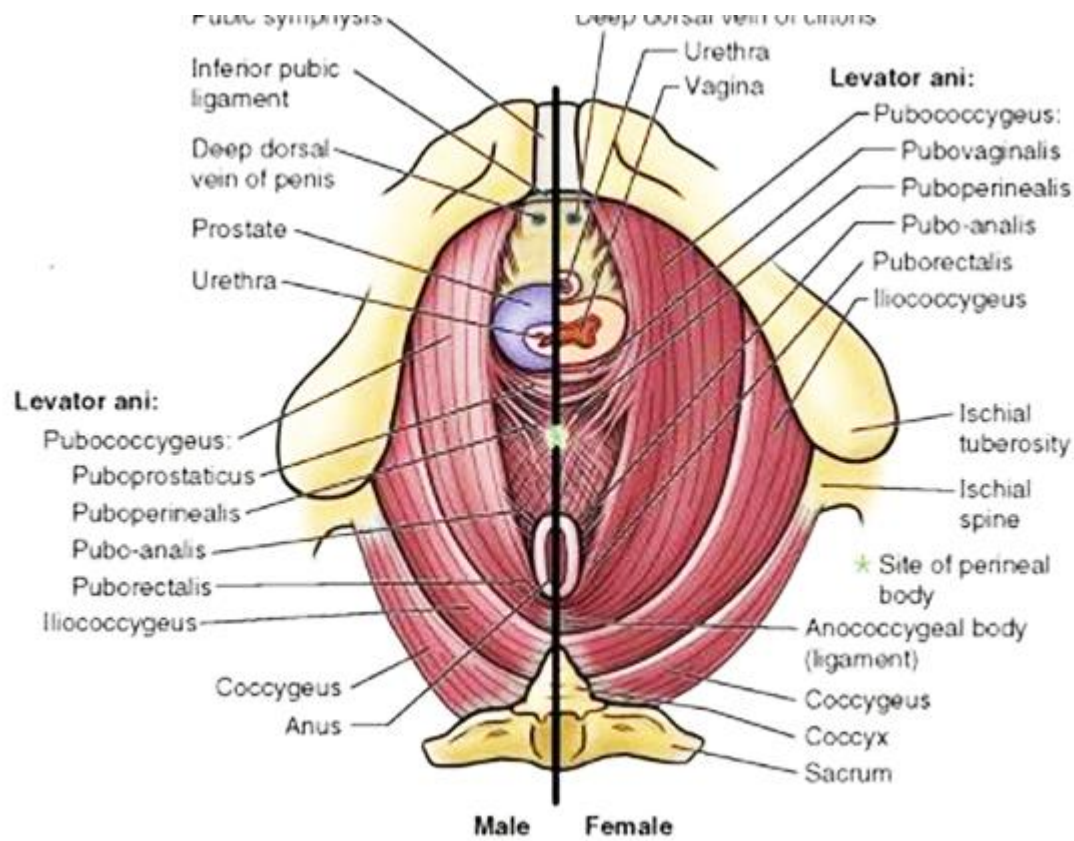
coccygeus

iliococcygeus

pubococcygeus







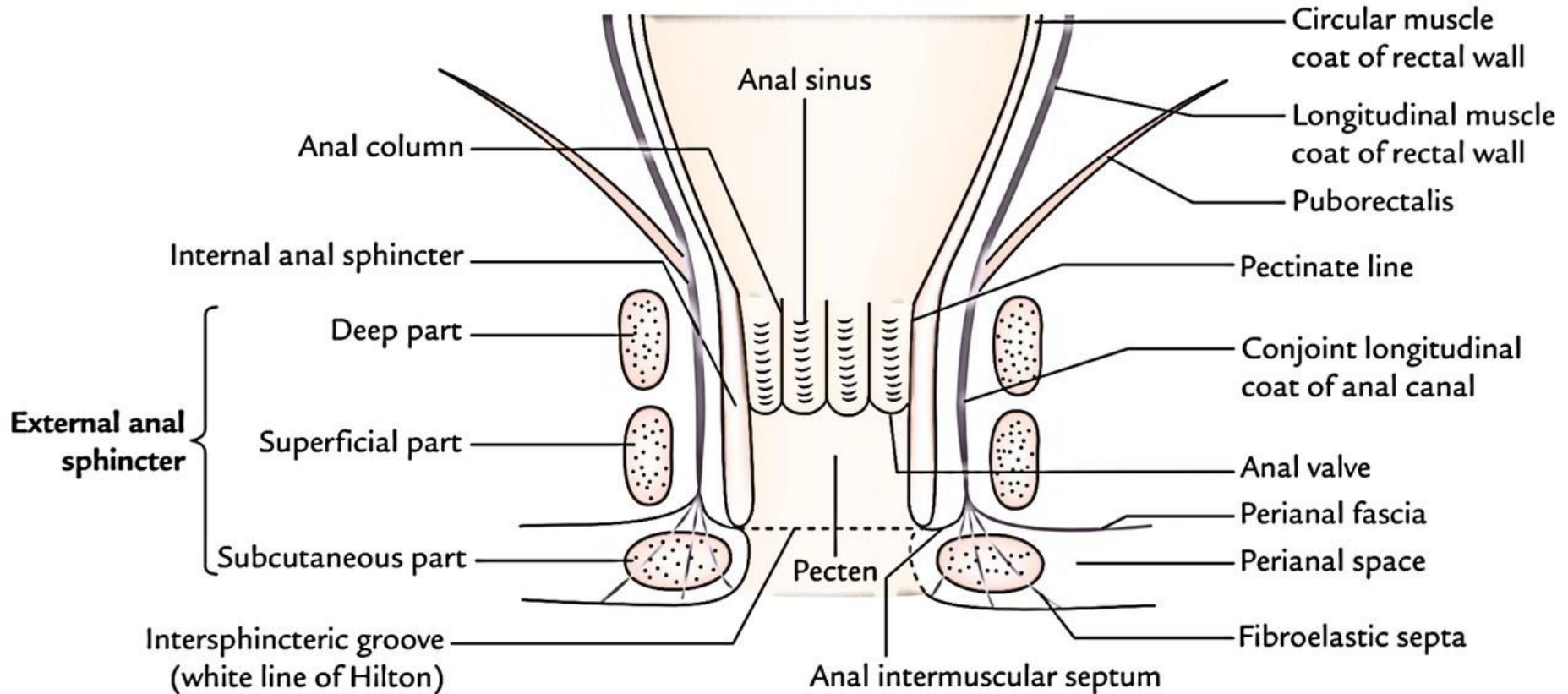
male – m. pubococcygeus:

- m. puboprostaticus
- m. puboperinealis
- m. puboanalis
- m. puborectalis

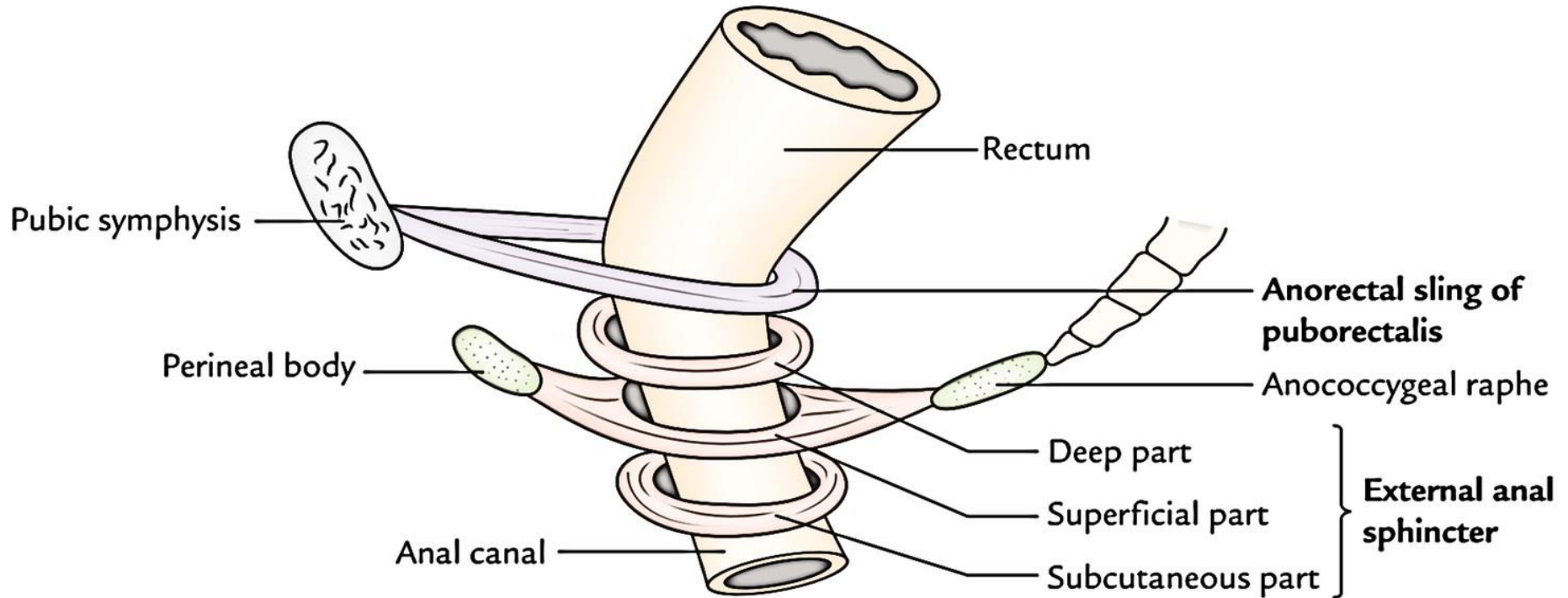
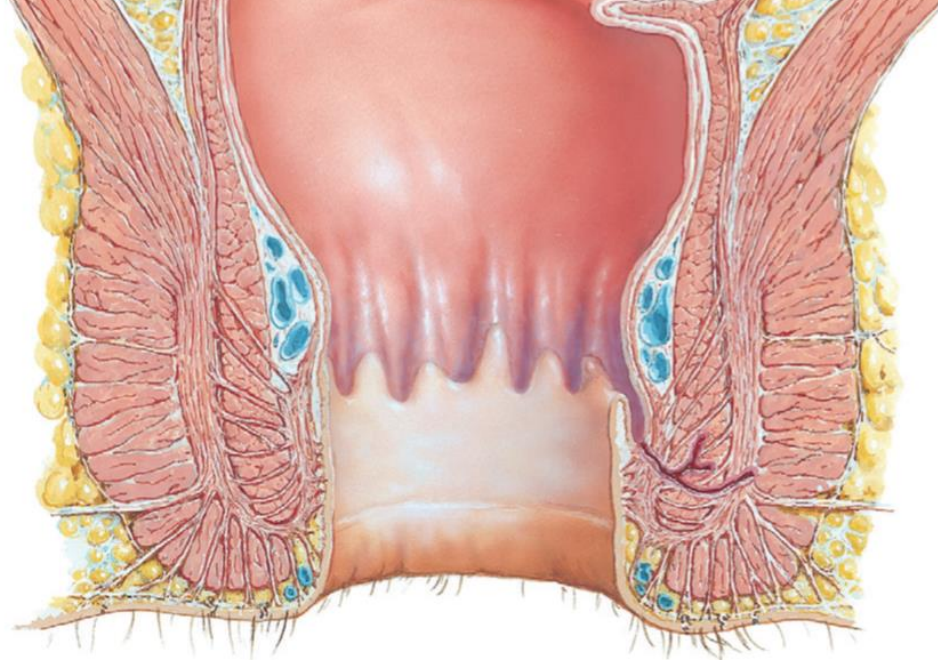
female – m. pubococcygeus:

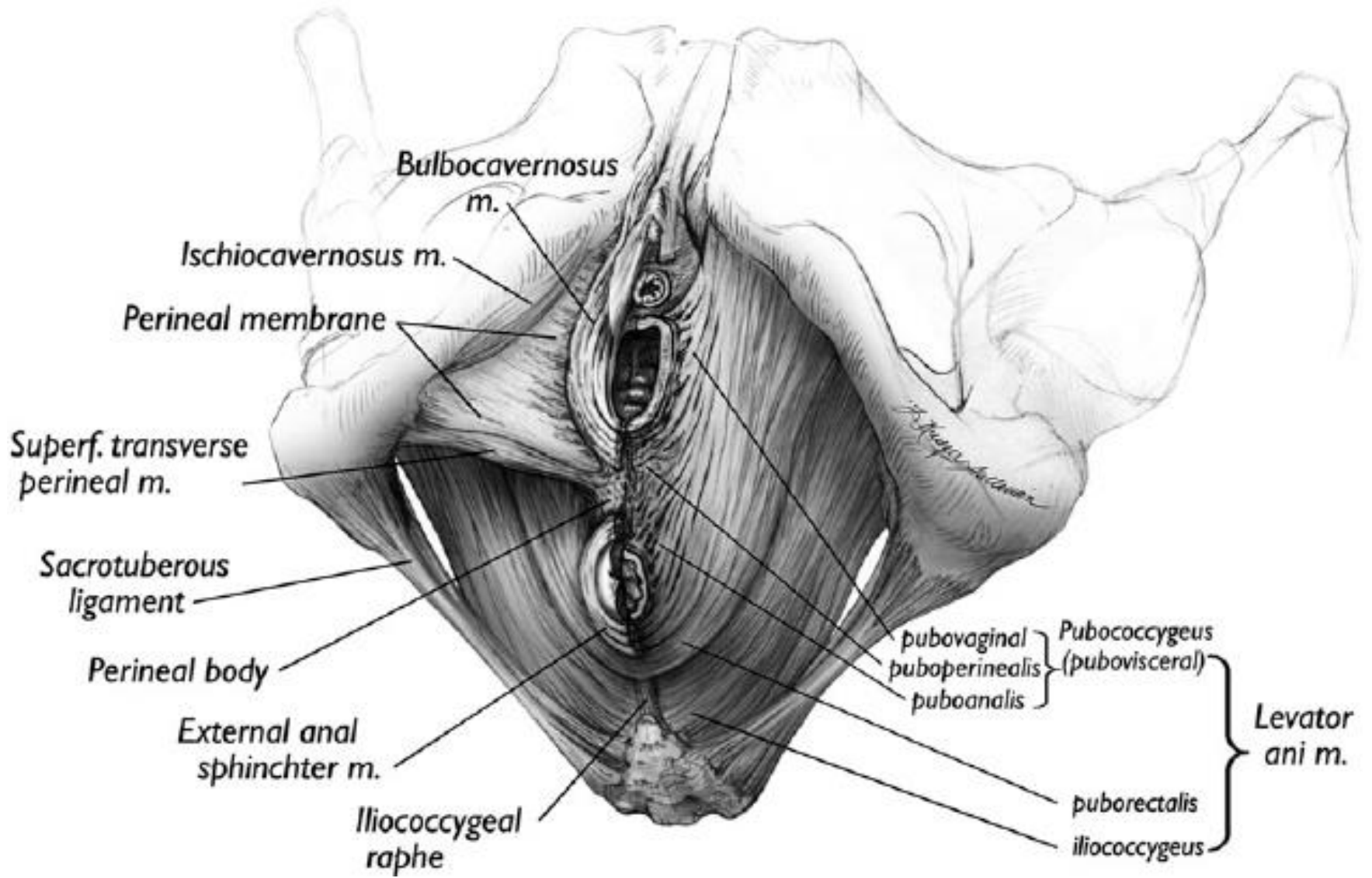
- m. pubovaginalis
- m. puboperinealis
- m. puboanalis
- m. puborectalis

M. sphincter ani externus et internus



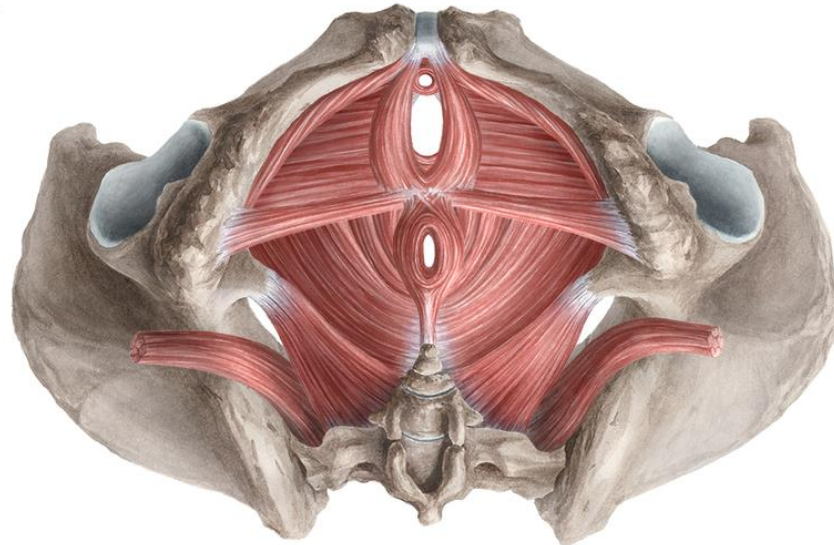
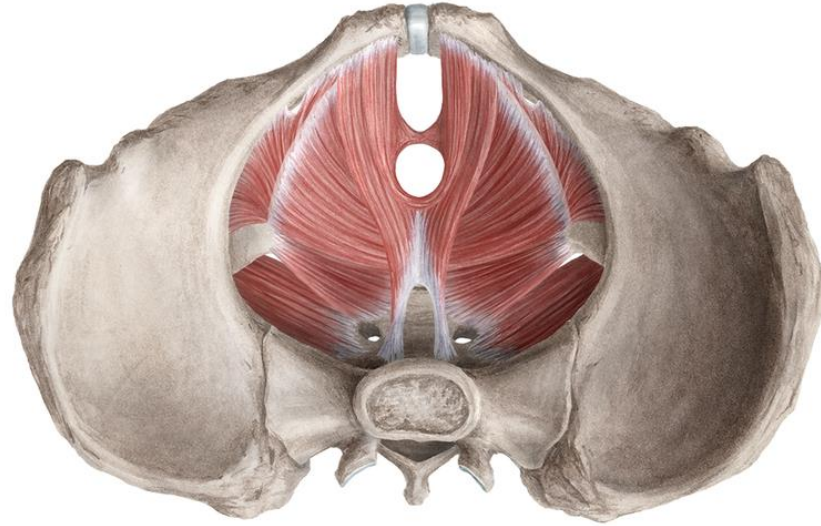
M. sphincter ani externus et internus





Diaphragma pelvis

Diaphragma urogenitale



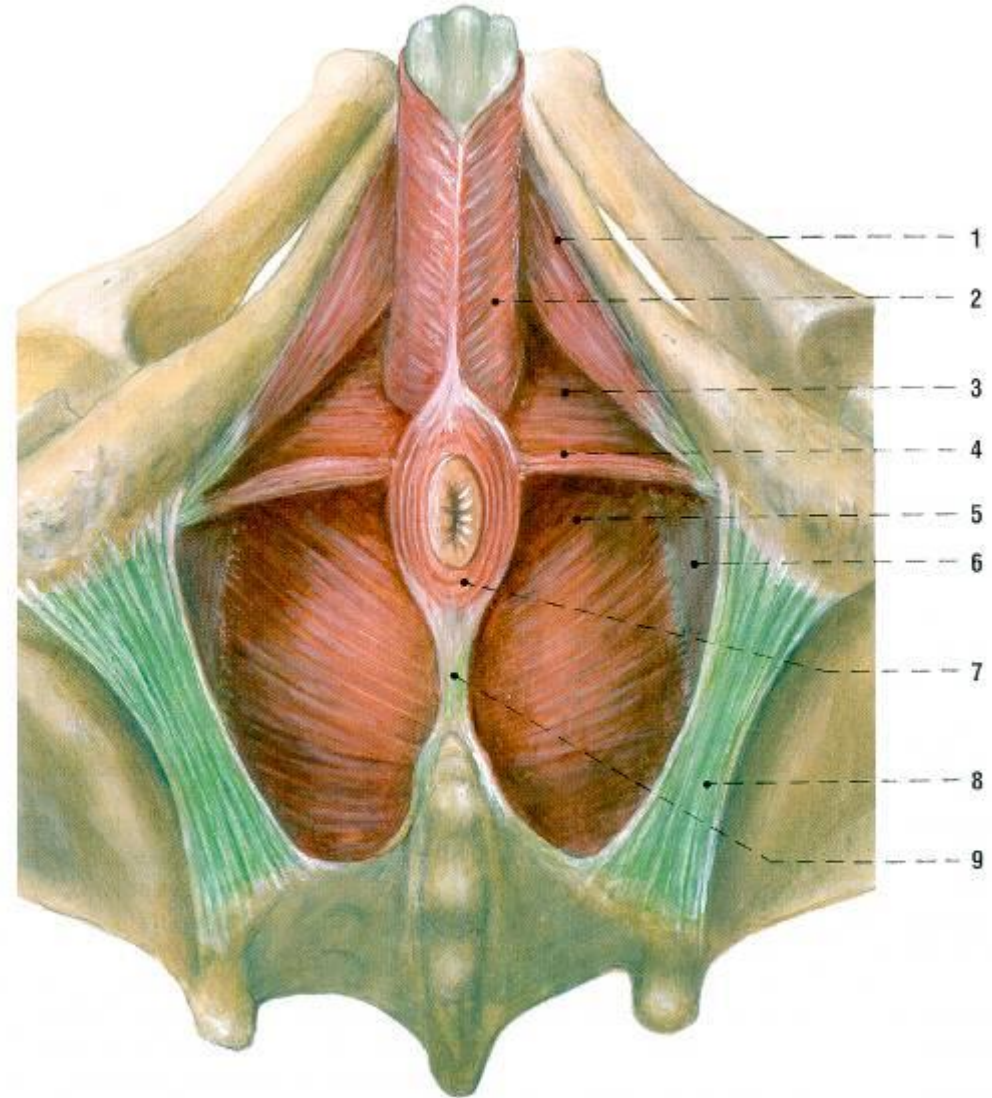
Diaphragma urogenitale

- **not a term listed in** Terminologia Anatomica 1998
- illustrative
- **perineal muscles = *musculi perinei*** in TA 1998
- 4 muscles in a level = „floor“
- + 3 ♀ / 1 ♂ other muscles around urethra
- corpus perineale is its center
- innervation: S4
 - nn. perineales n. pudendi
 - rr. anteriores nn. sacralium
 - nn. splanchnici pelvici

Svaly dna pánevního a mčopohlavního muže žabí perspektiva



- m. transversus perinei profundus
- m. transversus perinei superficialis
- m. bulbospongiosus
- m. ischiocavernosus
- m. sphincter urethrae externus



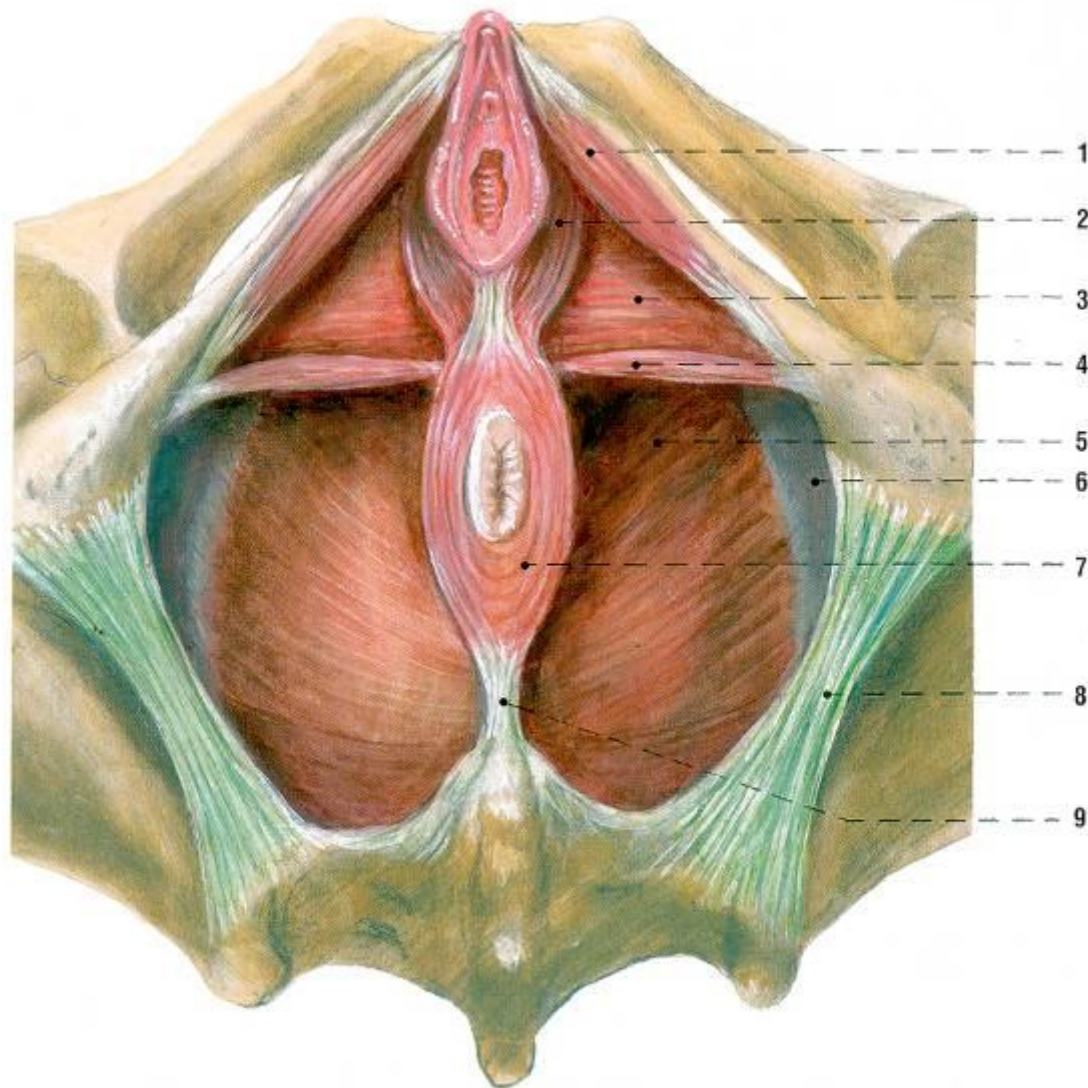
1 m. ischiocavernosus
2 m. bulbospongiosus
3 diaphragma urogenitale
4 m. transversus perinei superficialis

5 m. levator ani
6 m. obturatorius internus a jeho fascie
7 m. sphincter ani externus
8 lig. sacrotuberale
9 lig. anocecygeum

Svaly dna pánevního a močopohlavního ženy žabí perspektiva



- m. bulbospongiosus
- m. ischiocavernosus
- m. transversus perinei superficialis



1 m. ischiocavernosus
2 m. bulbospongiosus
3 diaphragma urogenitale
4 m. transversus perinei superficialis

5 m. levator ani
6 m. obturatorius internus a jeho fascie
7 m. sphincter ani externus
8 lig. sacrotuberale
9 lig. anococcygeum

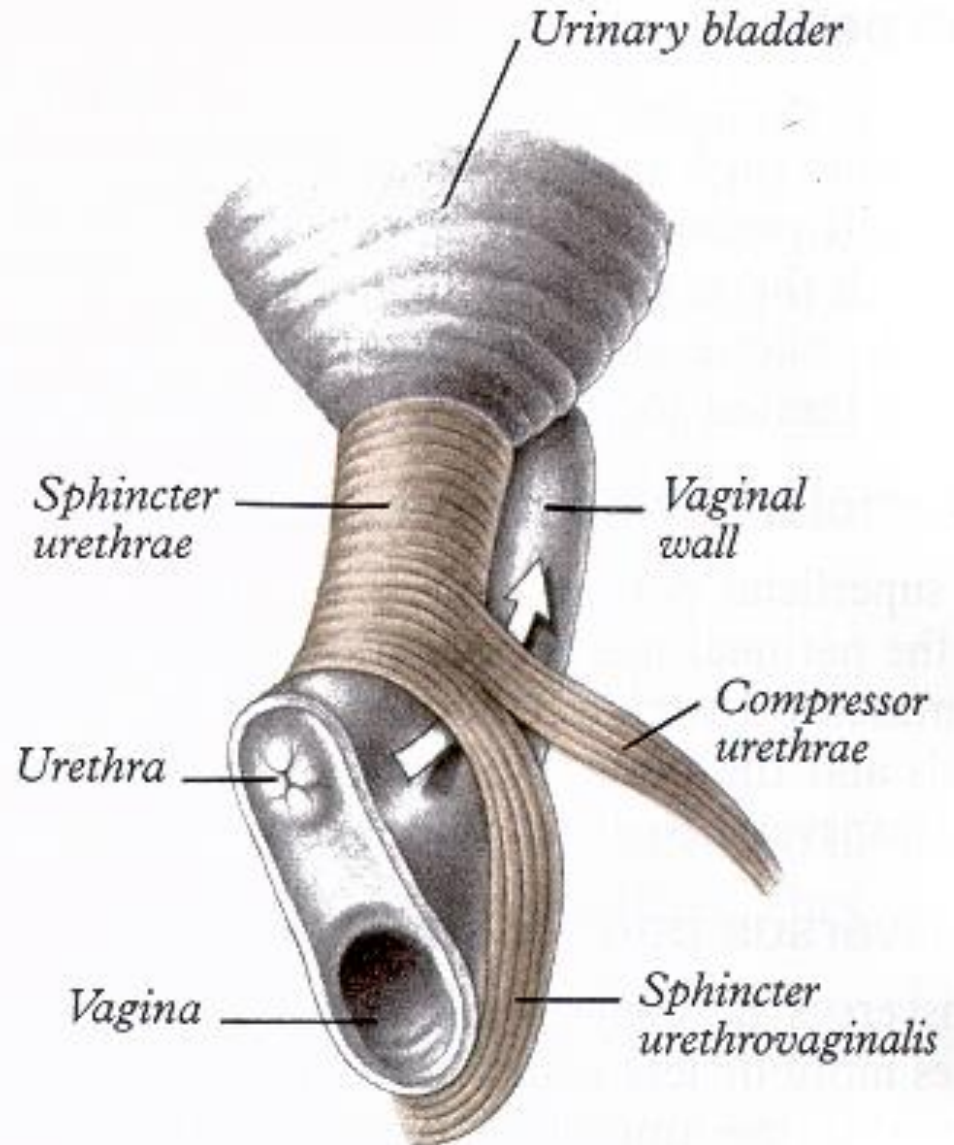
Svaly močopovavního dna ženy



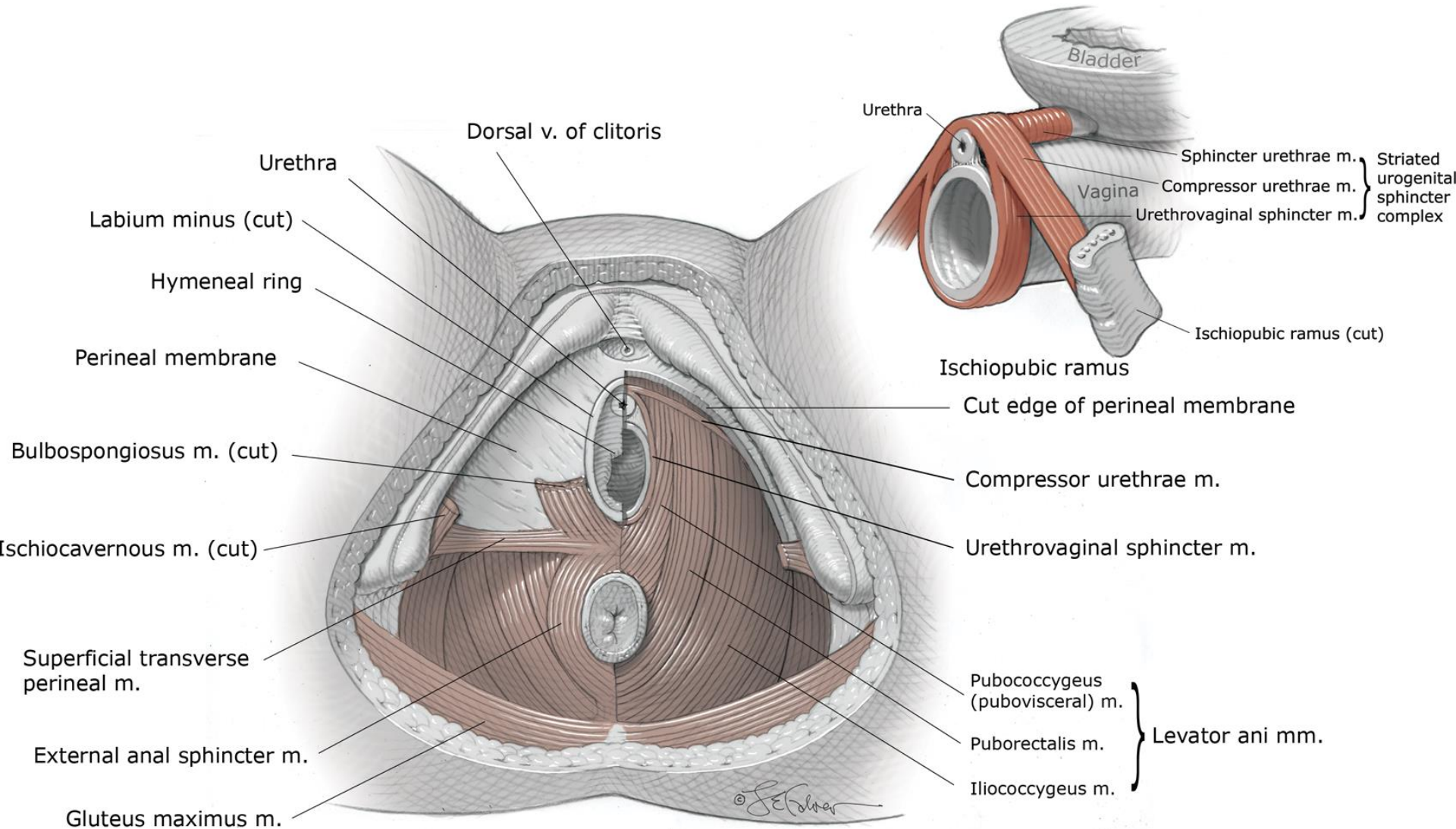
- m. sphincter urethrae



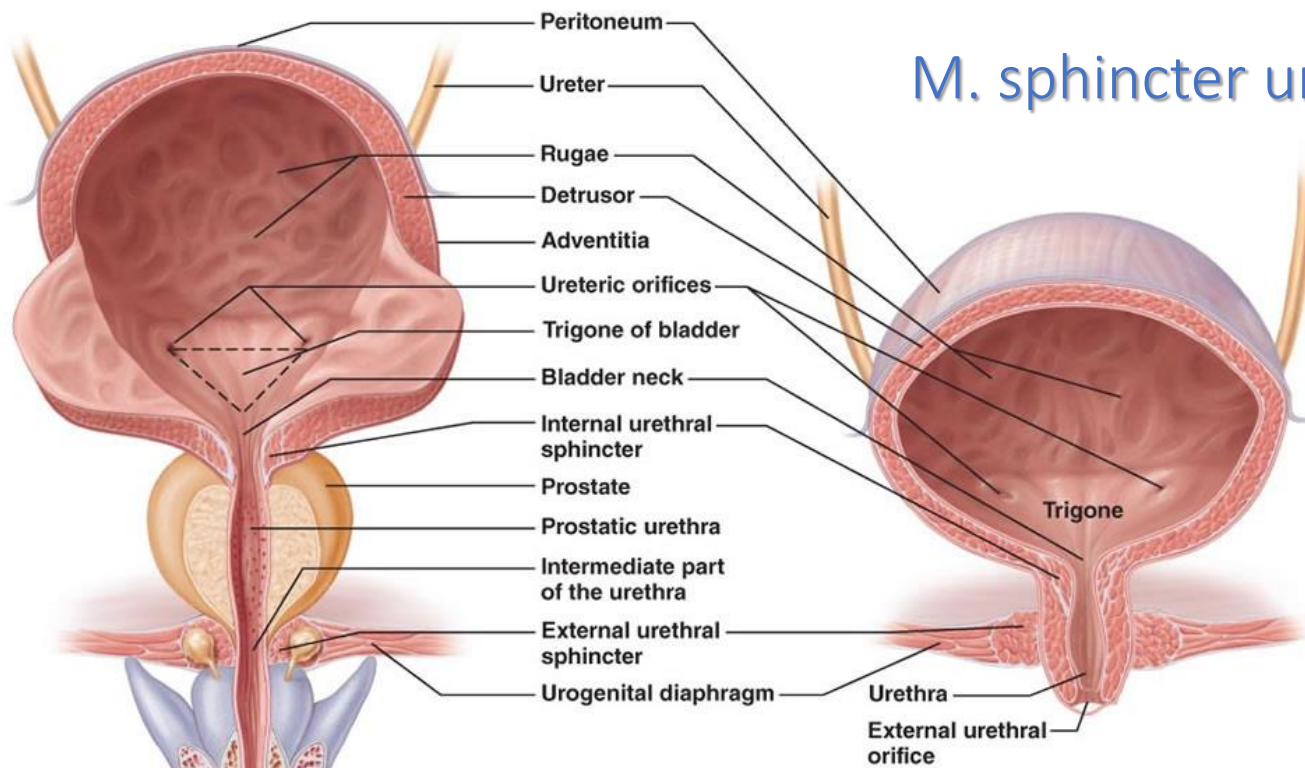
- m. sphincter urethrae
- m. compressor urethrae
- m. sphincter urethrovaginalis



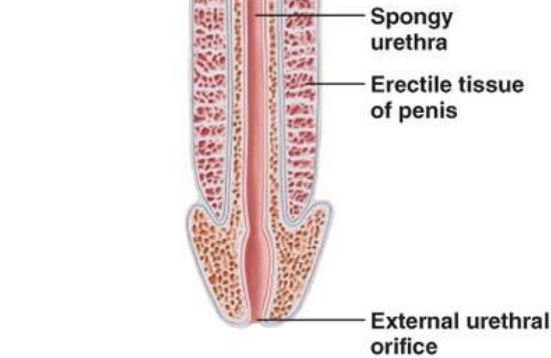
3 sphincters of female urethra



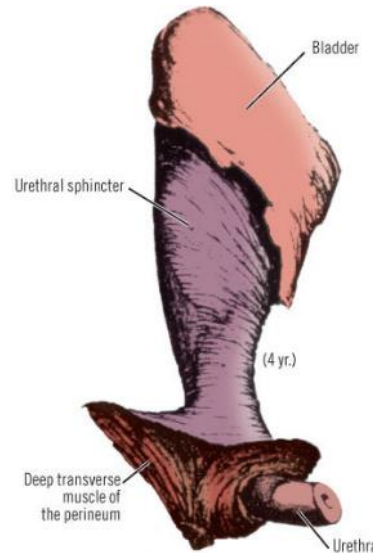
M. sphincter urethrae (externus)



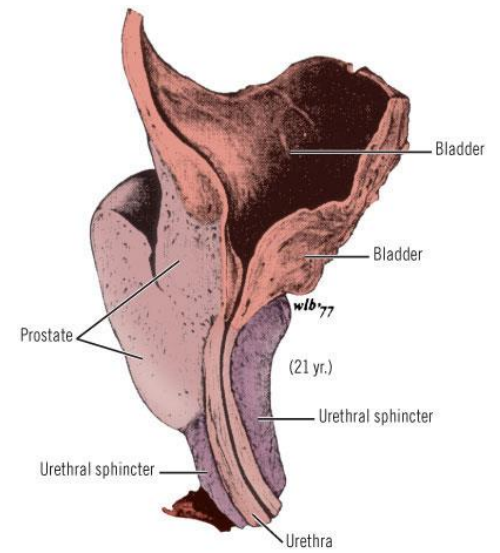
(b) Female.



(a) Male. The long male urethra has three regions: prostatic, intermediate, and spongy.

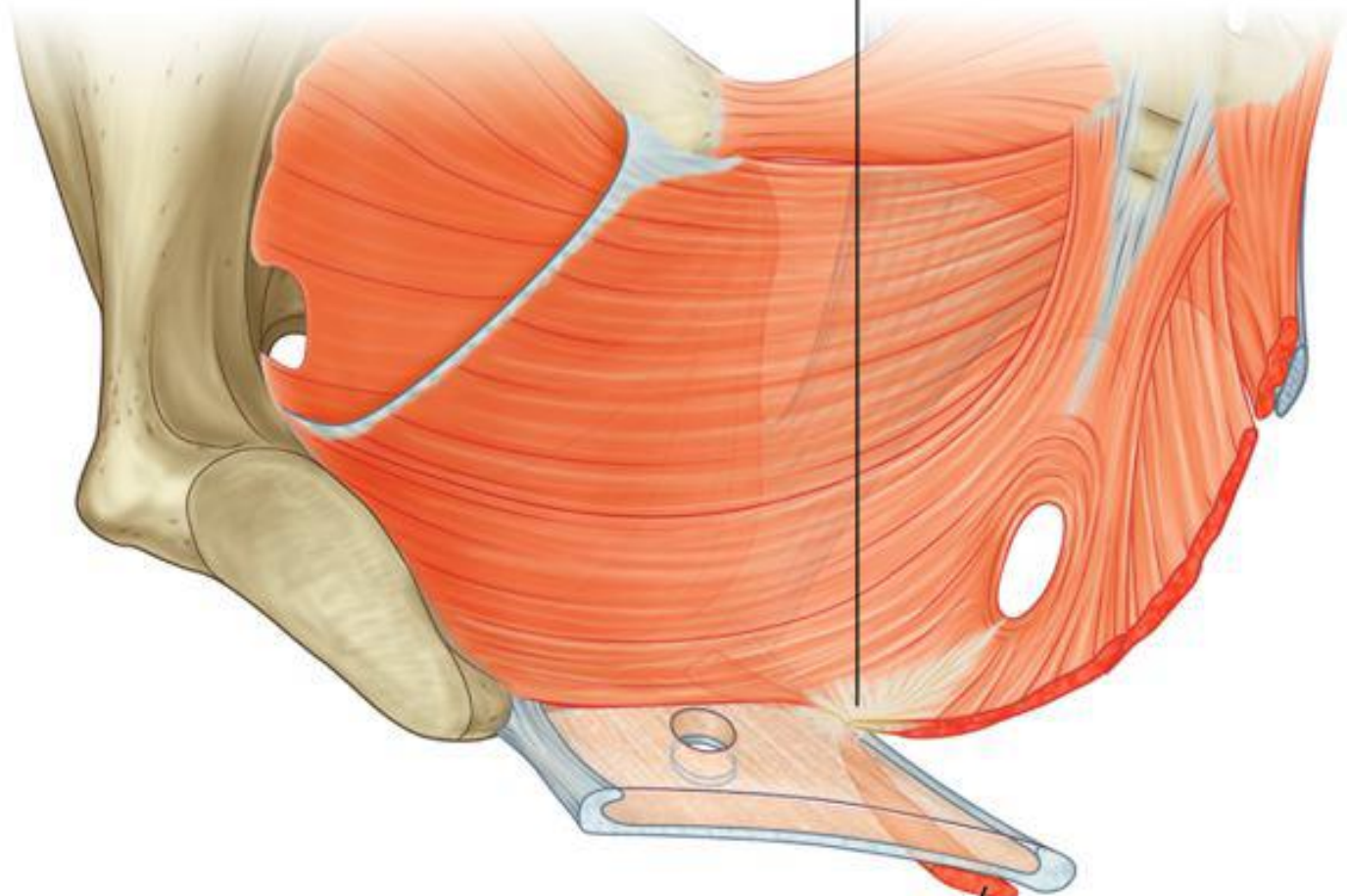


Copyright ©2006 by The McGraw-Hill Companies, Inc. All rights reserved.

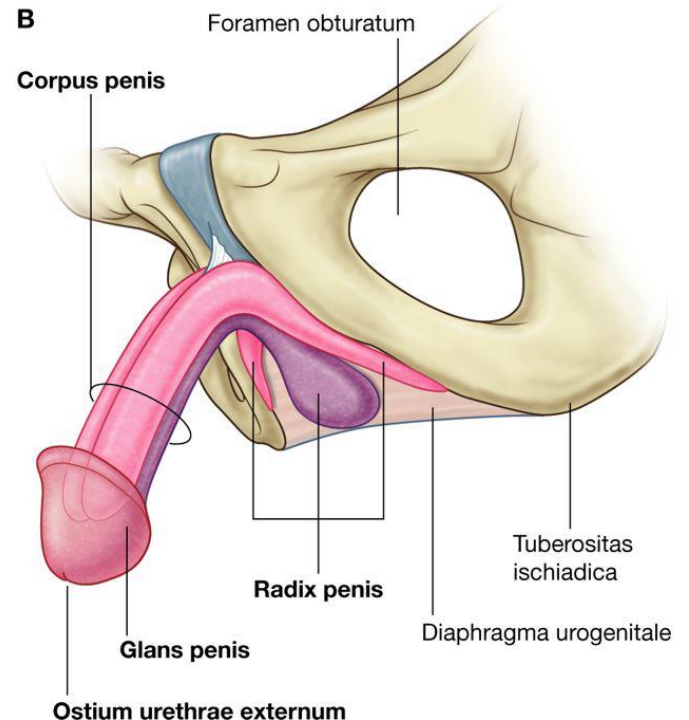
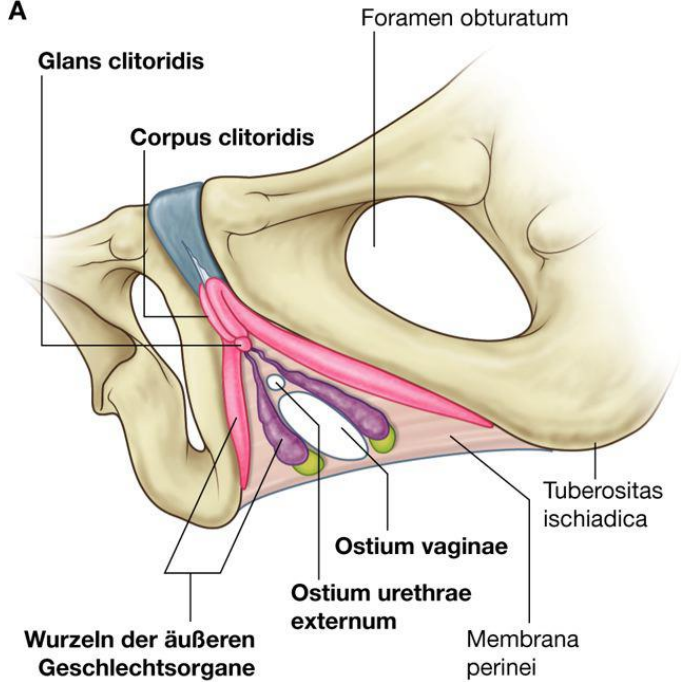
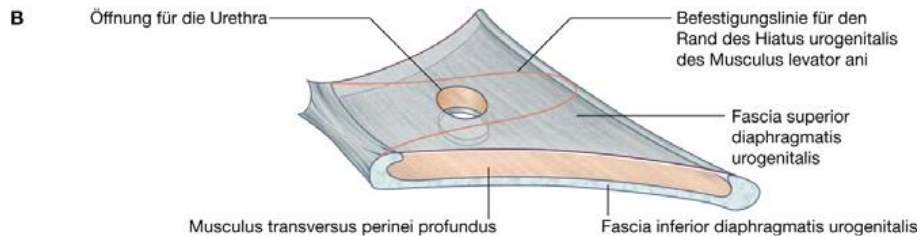
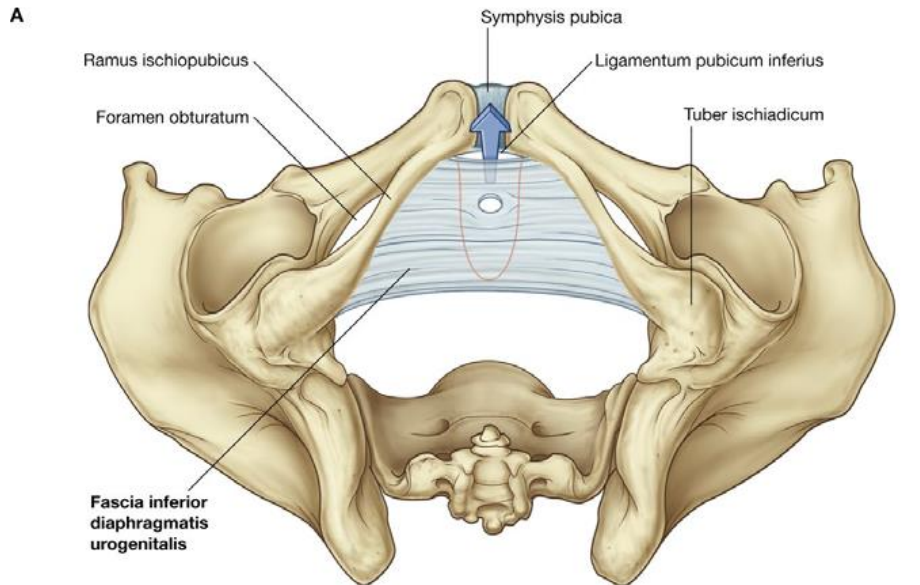


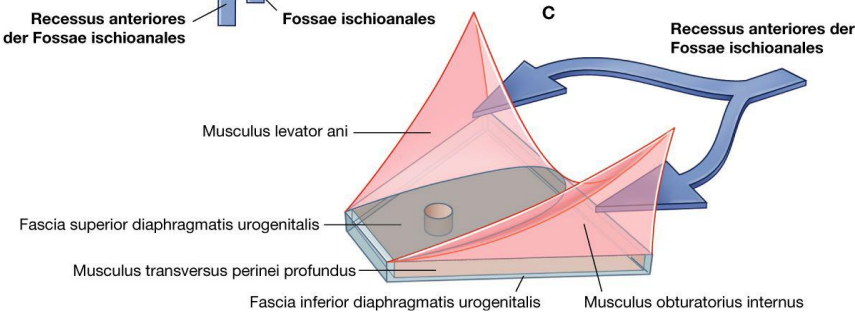
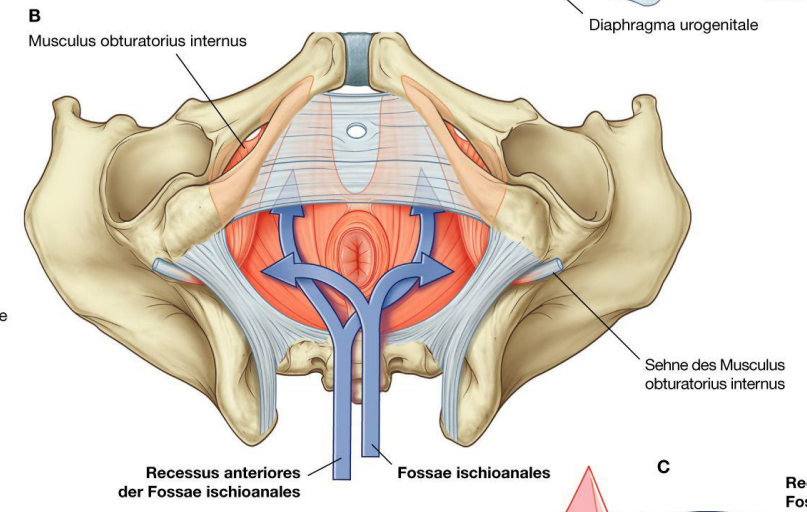
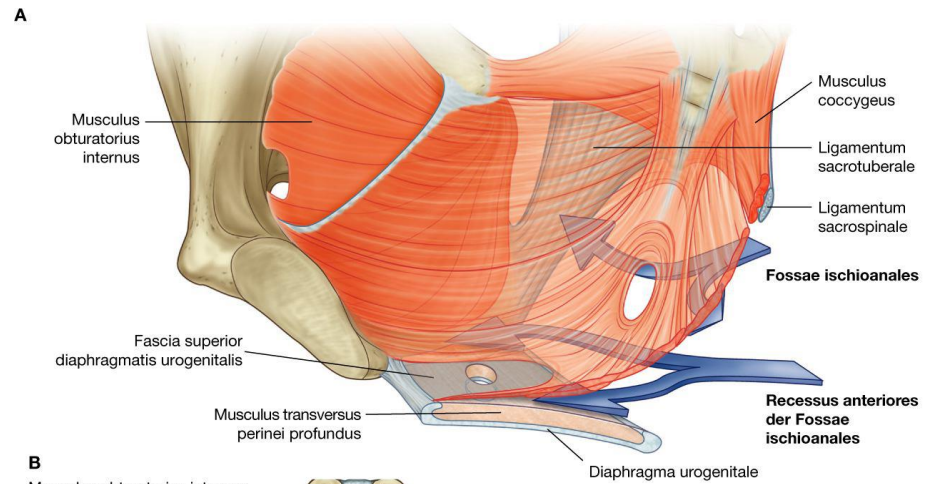
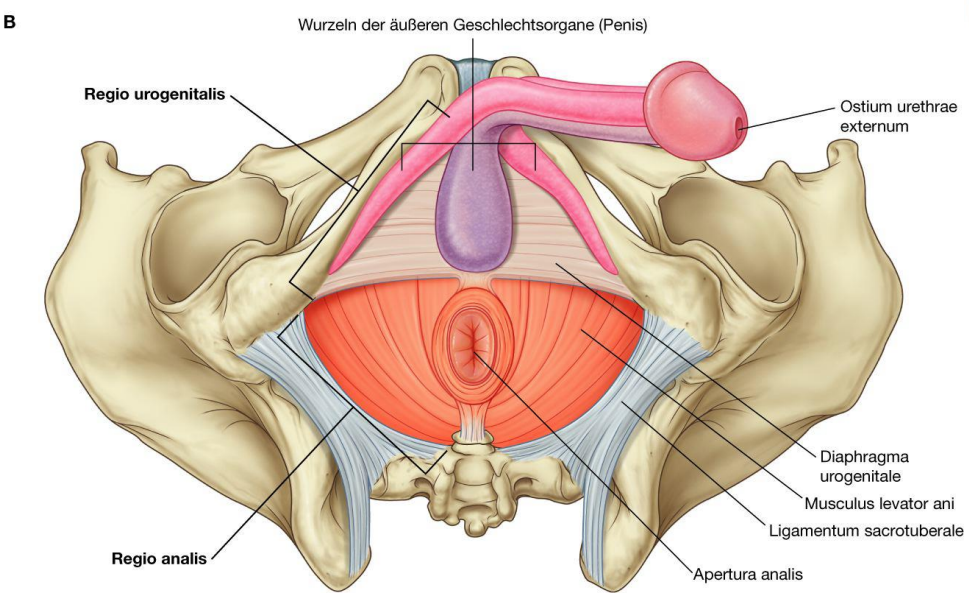
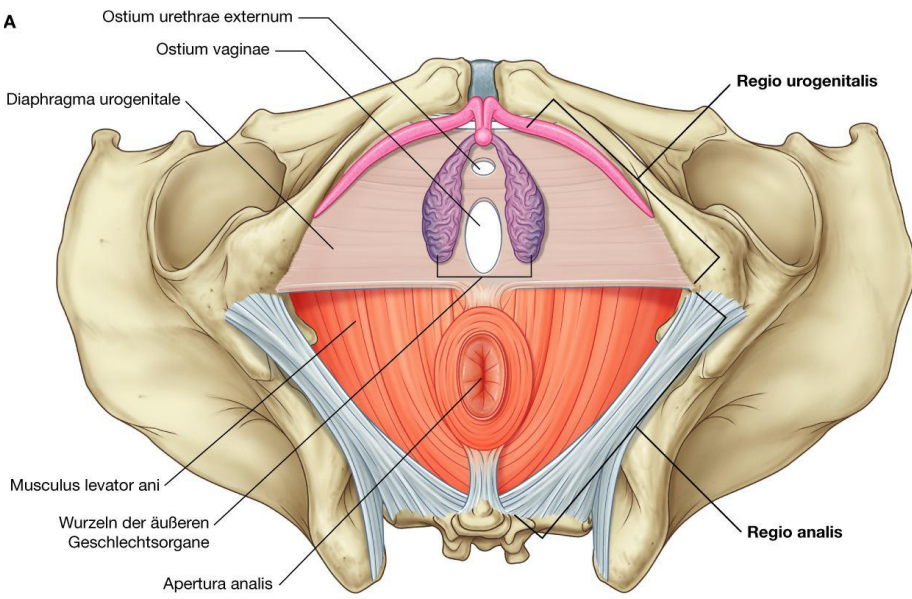
Copyright ©2006 by The McGraw-Hill Companies, Inc. All rights reserved.

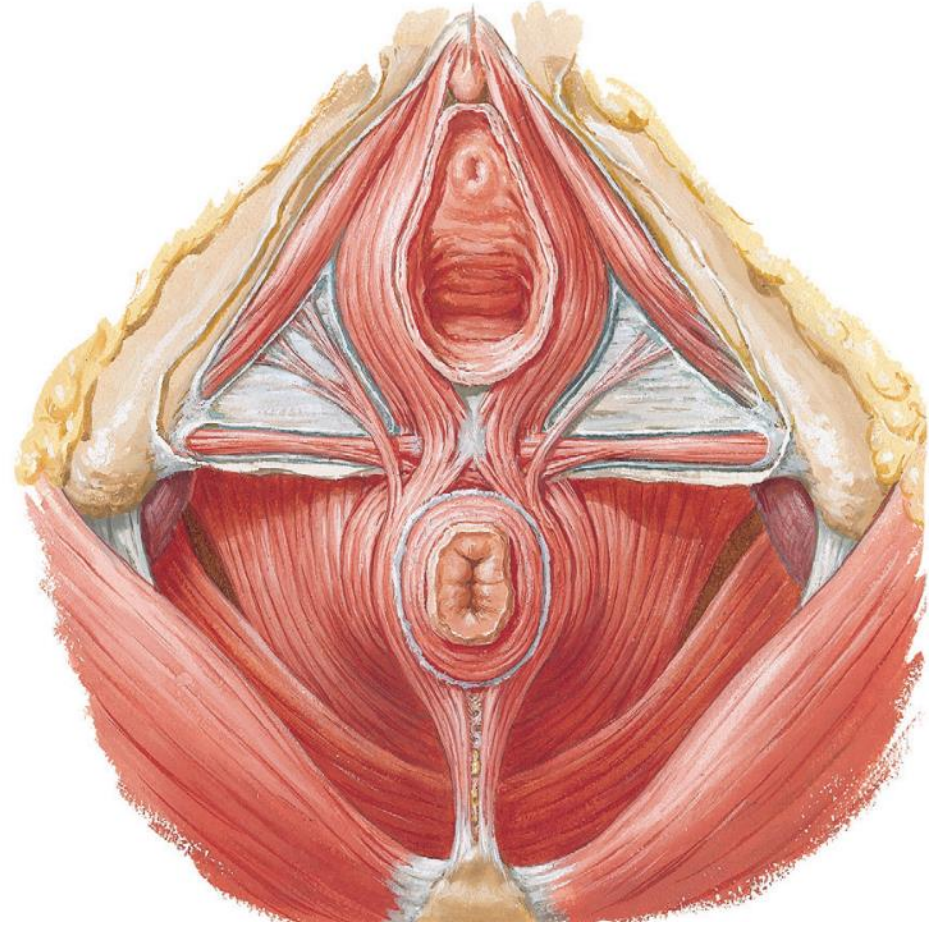
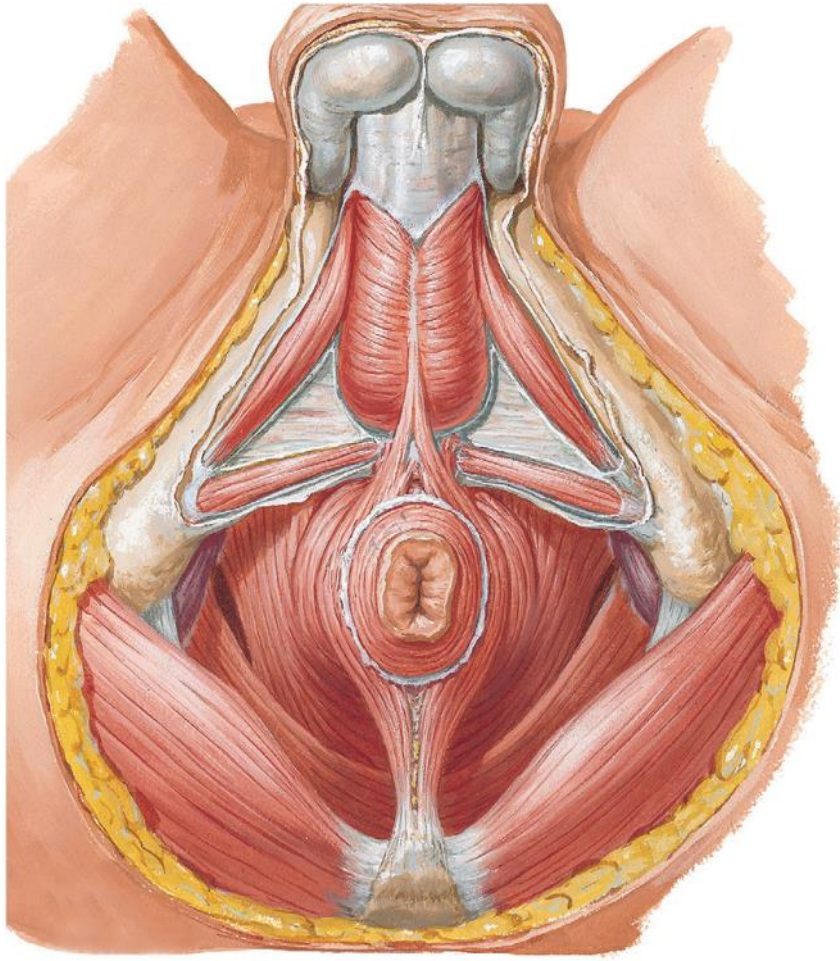
Centrum perinei



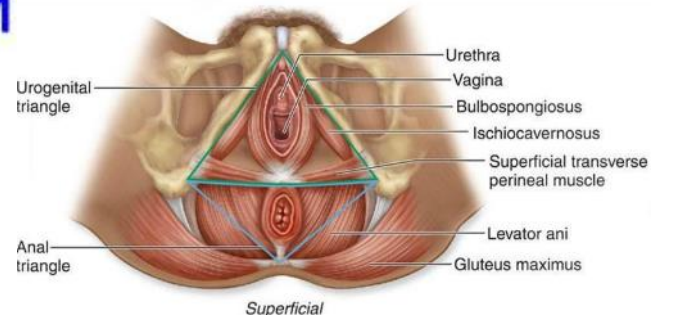
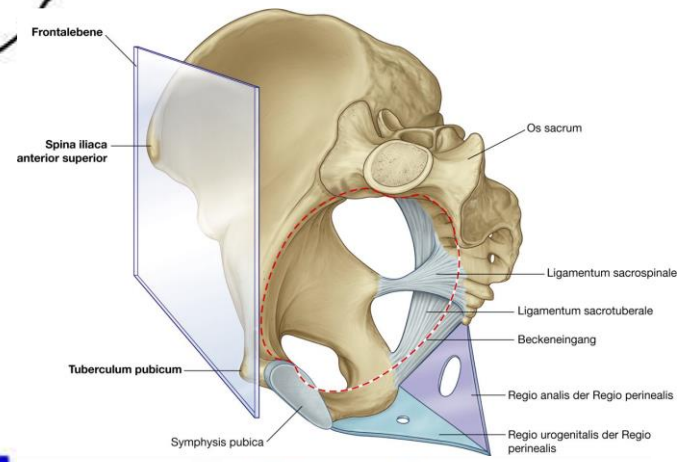
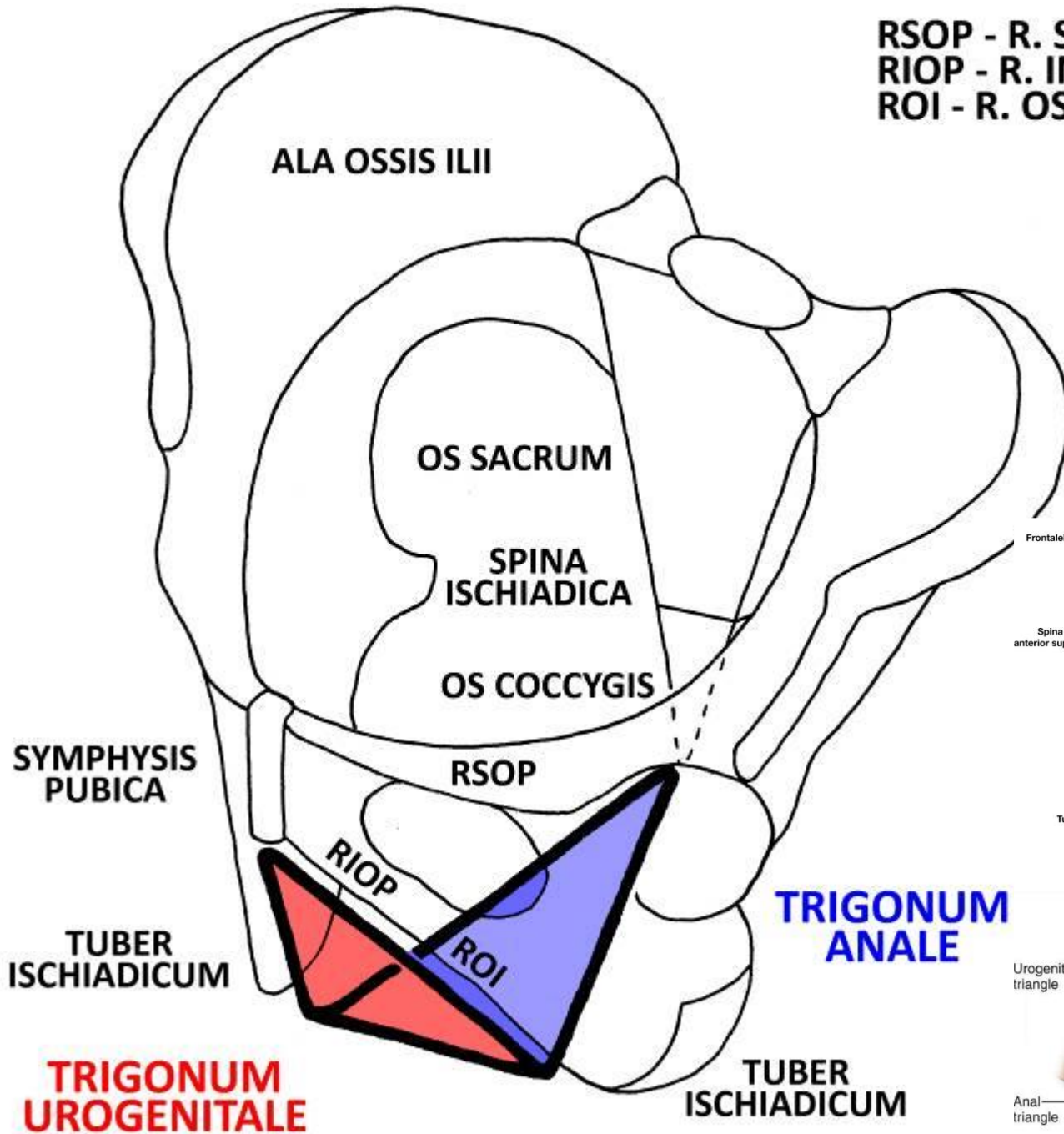
Musculus transversus perinei superficialis



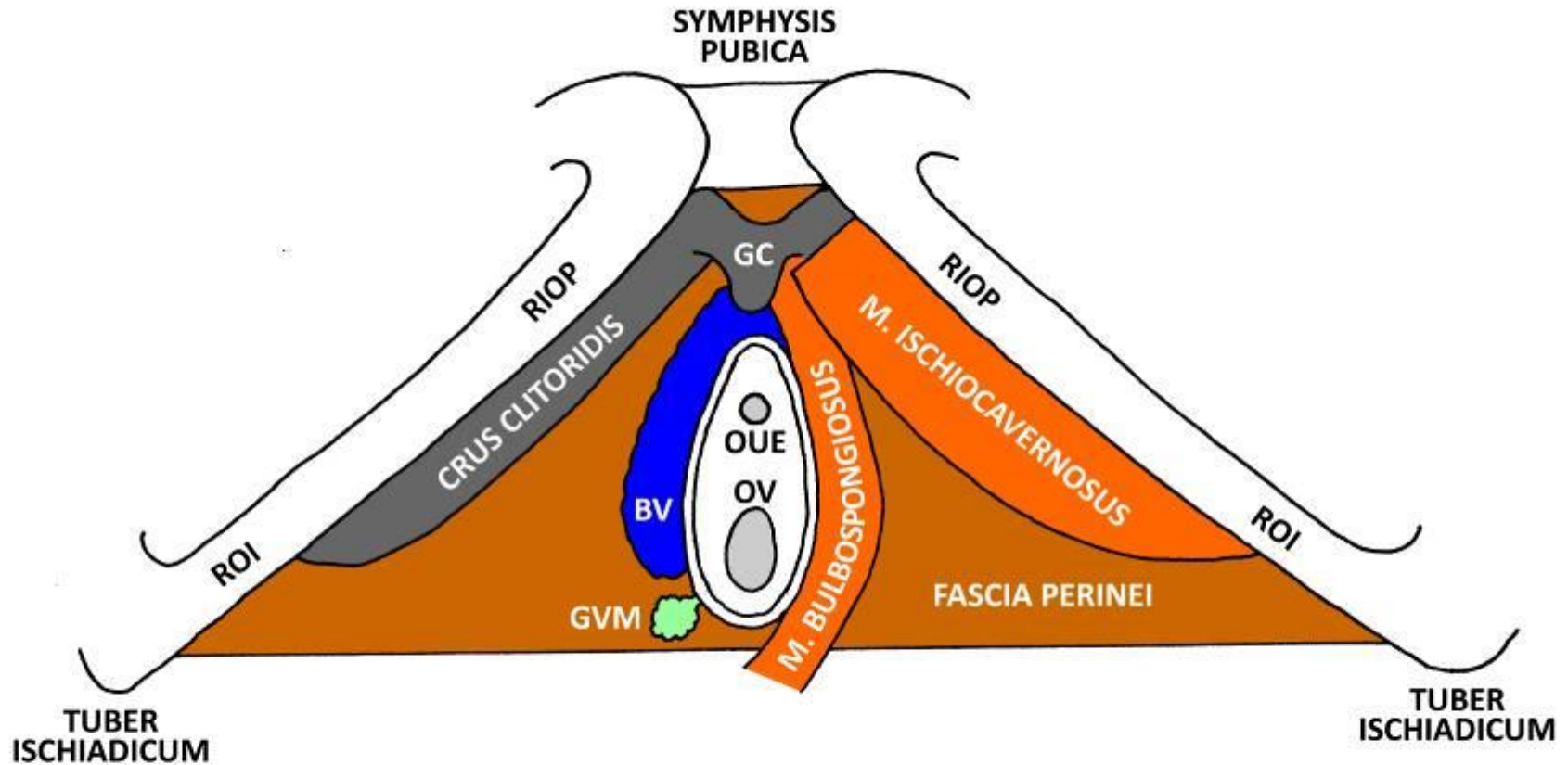




RSOP - R. SUPERIOR OSSIS PUBIS
 RIOP - R. INFERIOR OSSIS PUBIS
 ROI - R. OSSIS ISCHII

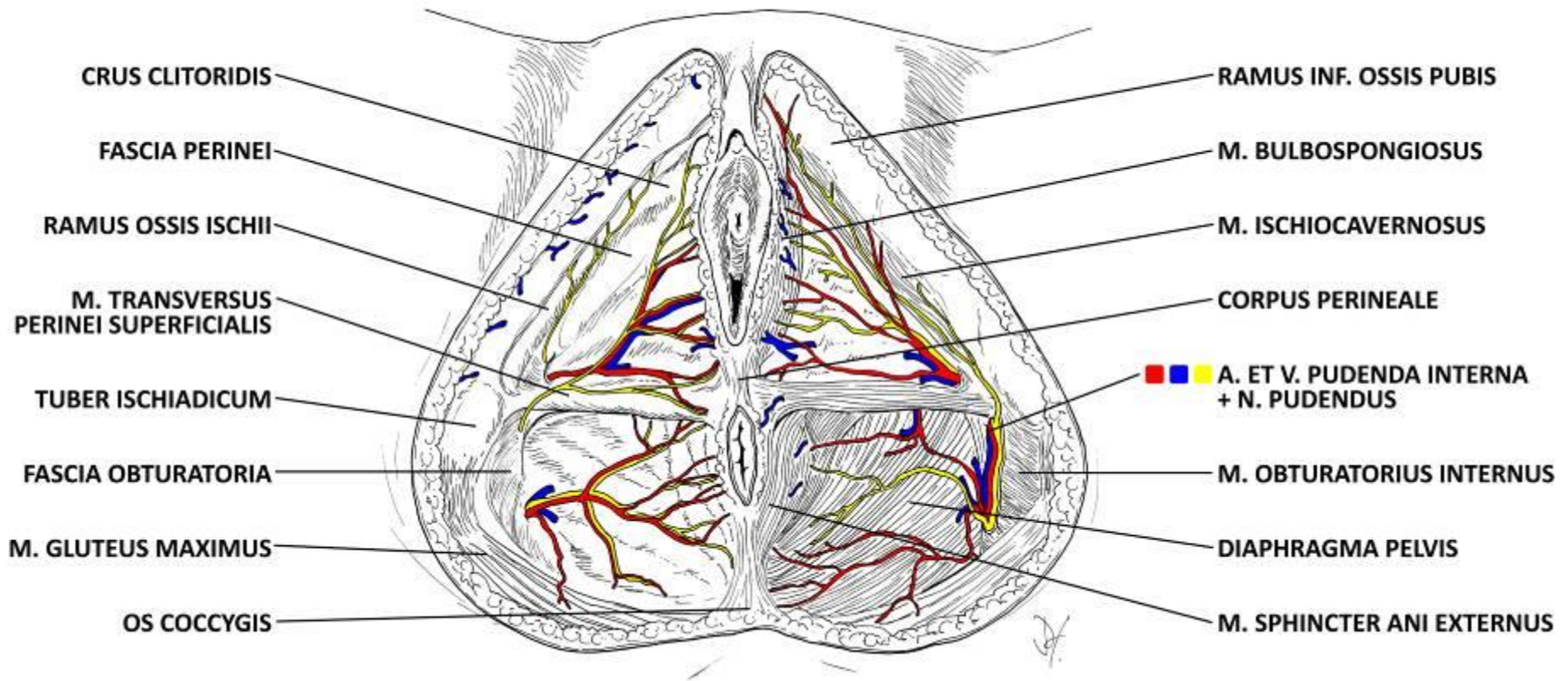


Trigonum urogenitale ♀



RIOP - R. INF. OSSIS PUBIS
ROI - R. OSSIS ISCHII
GC - GLANS CLITORIDIS
BV - BULBUS VESTIBULI
OUE - OSTIUM URETHRAE EXTERNUM
OV - ORIFICIUM VAGINAE
GVM - GLANDULA VESTIBULARIS MAJOR

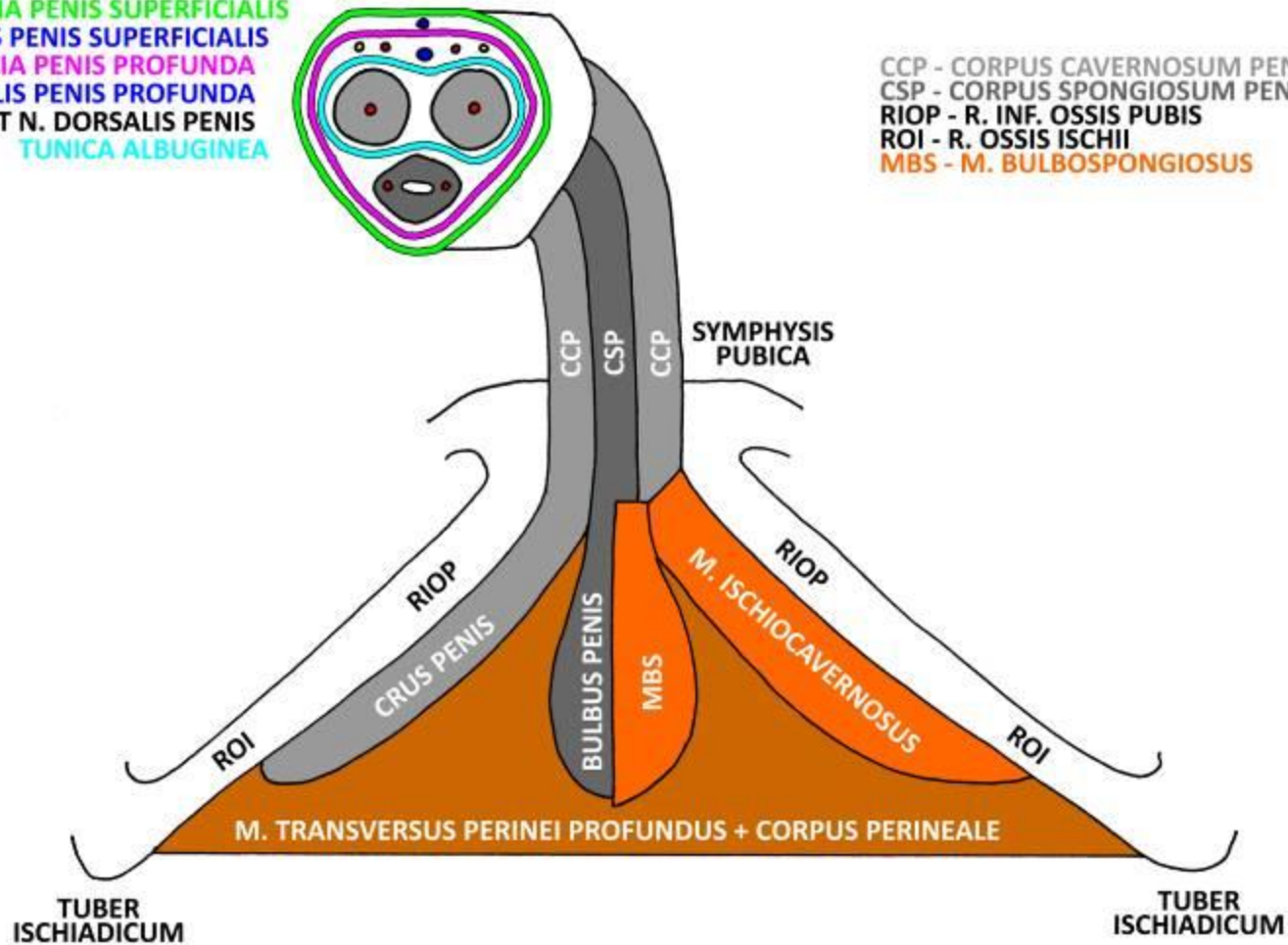
Regio perinealis ♀



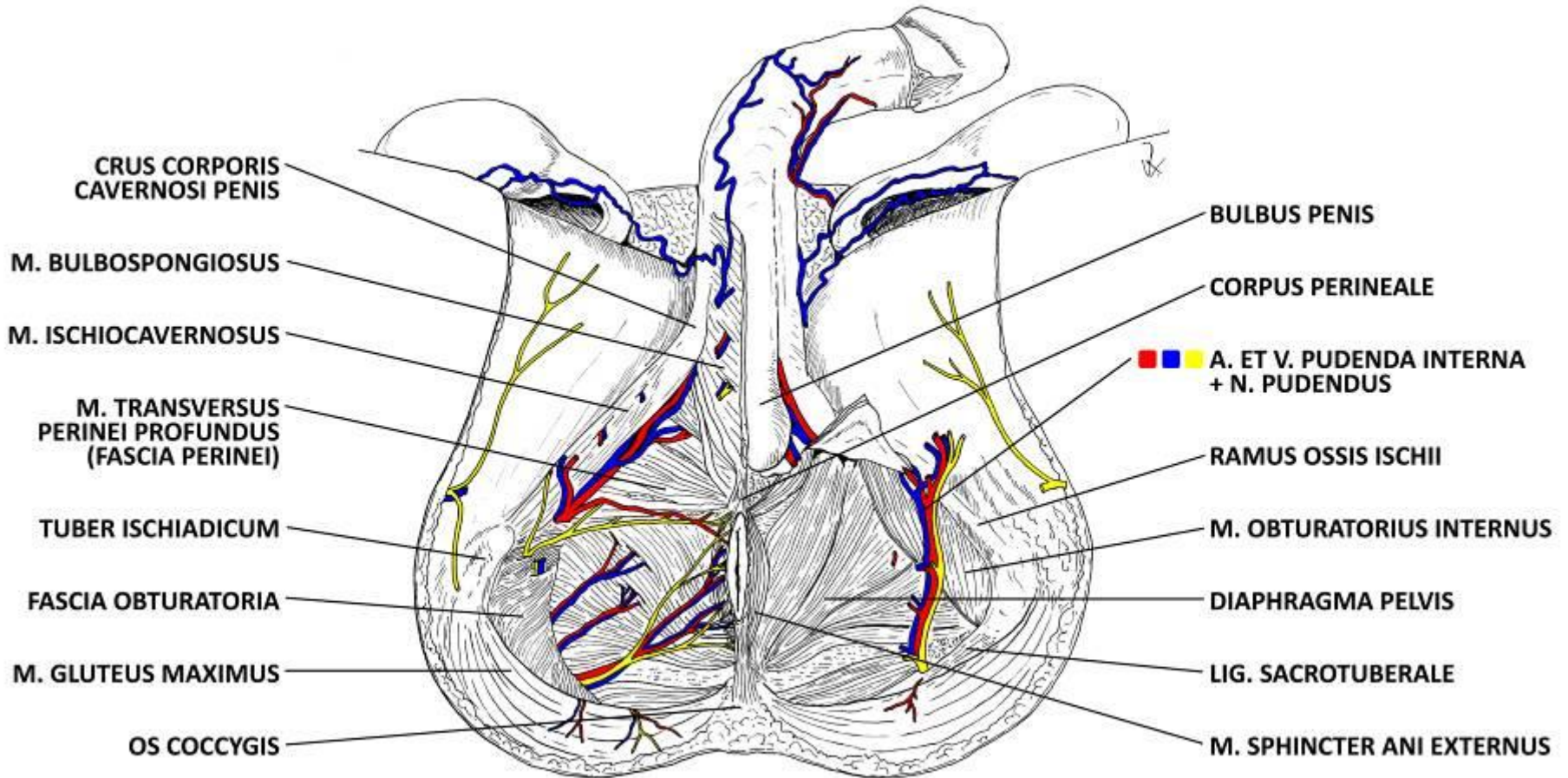
Trigonum urogenitale ♂

FASCIA PENIS SUPERFICIALIS
V. DORSALIS PENIS SUPERFICIALIS
FASCIA PENIS PROFUNDA
V. DORSALIS PENIS PROFUNDA
+ A. ET N. DORSALIS PENIS
TUNICA ALBUGINEA

CCP - CORPUS CAVERNOSUM PENIS + A. PROFUNDA PENIS
CSP - CORPUS SPONGIOSUM PENIS + AA. URETHRALES
RIOP - R. INF. OSSIS PUBIS
ROI - R. OSSIS ISCHII
MBS - M. BULBOSPONGIOSUS



Regio perinealis ♂



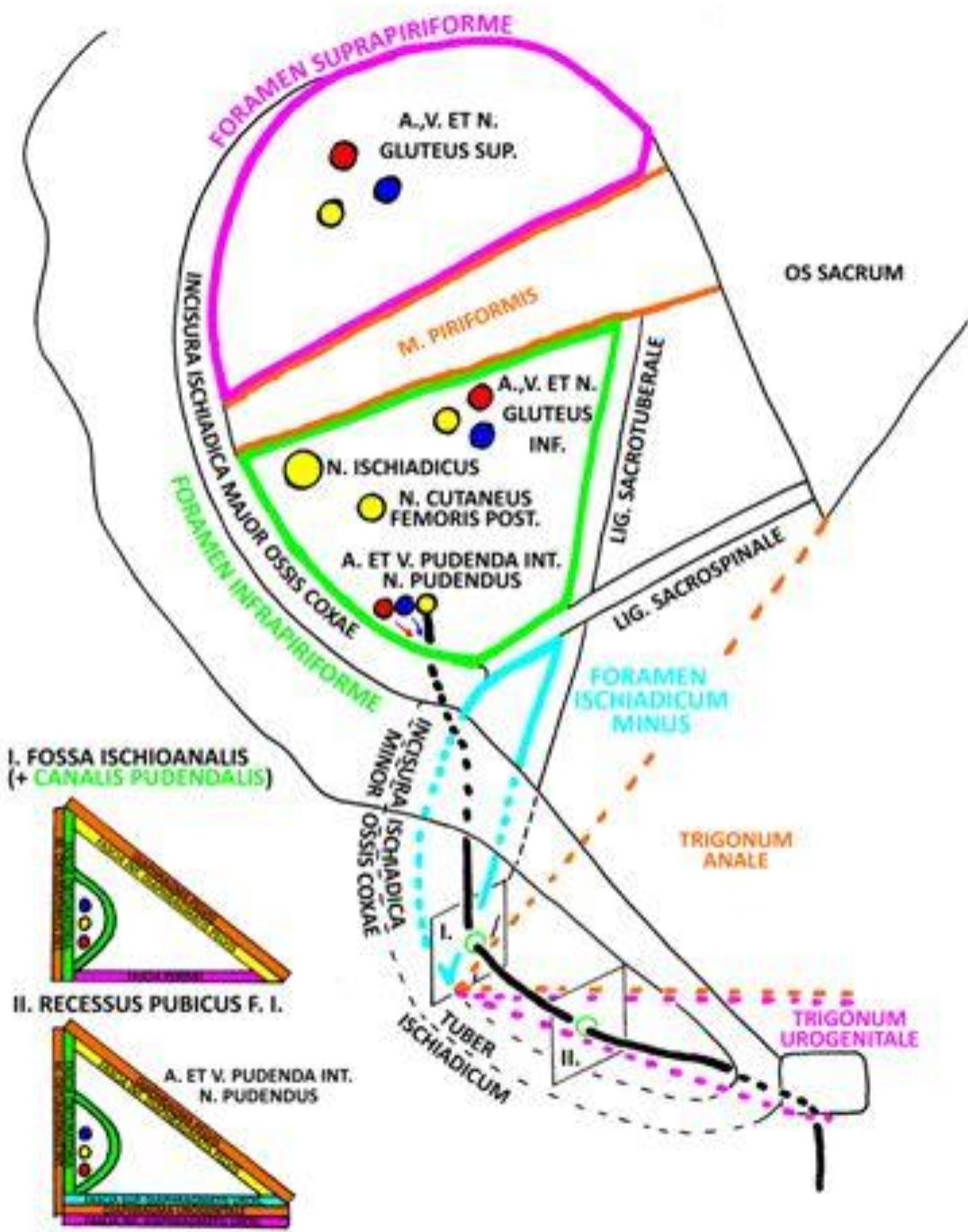
Fossa ischioanal

BOUNDARIES:

- **MEDIOCRANIALY + CRANIALY:** m. sphincter ani externus, fascia diaphragmatis pelvis inferior
- **LATERALLY:** tuber ischiadicum, fascia obturatoria
- **DORSALLY:** dolní okraj m. gluteus maximus, lig. sacrotuberale
- **CAUDALLY:** fascia perinei superficialis

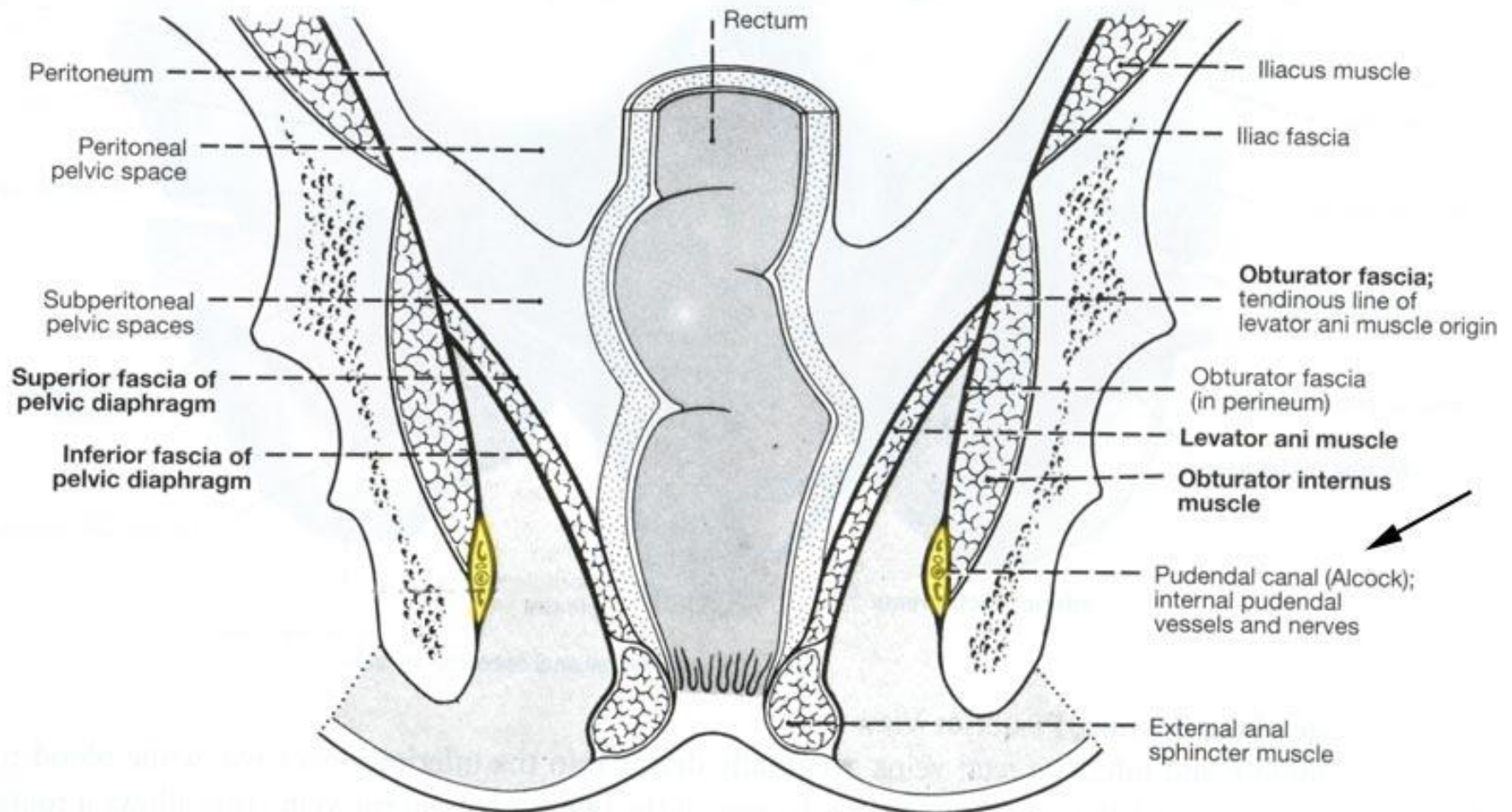
CONTENTS:

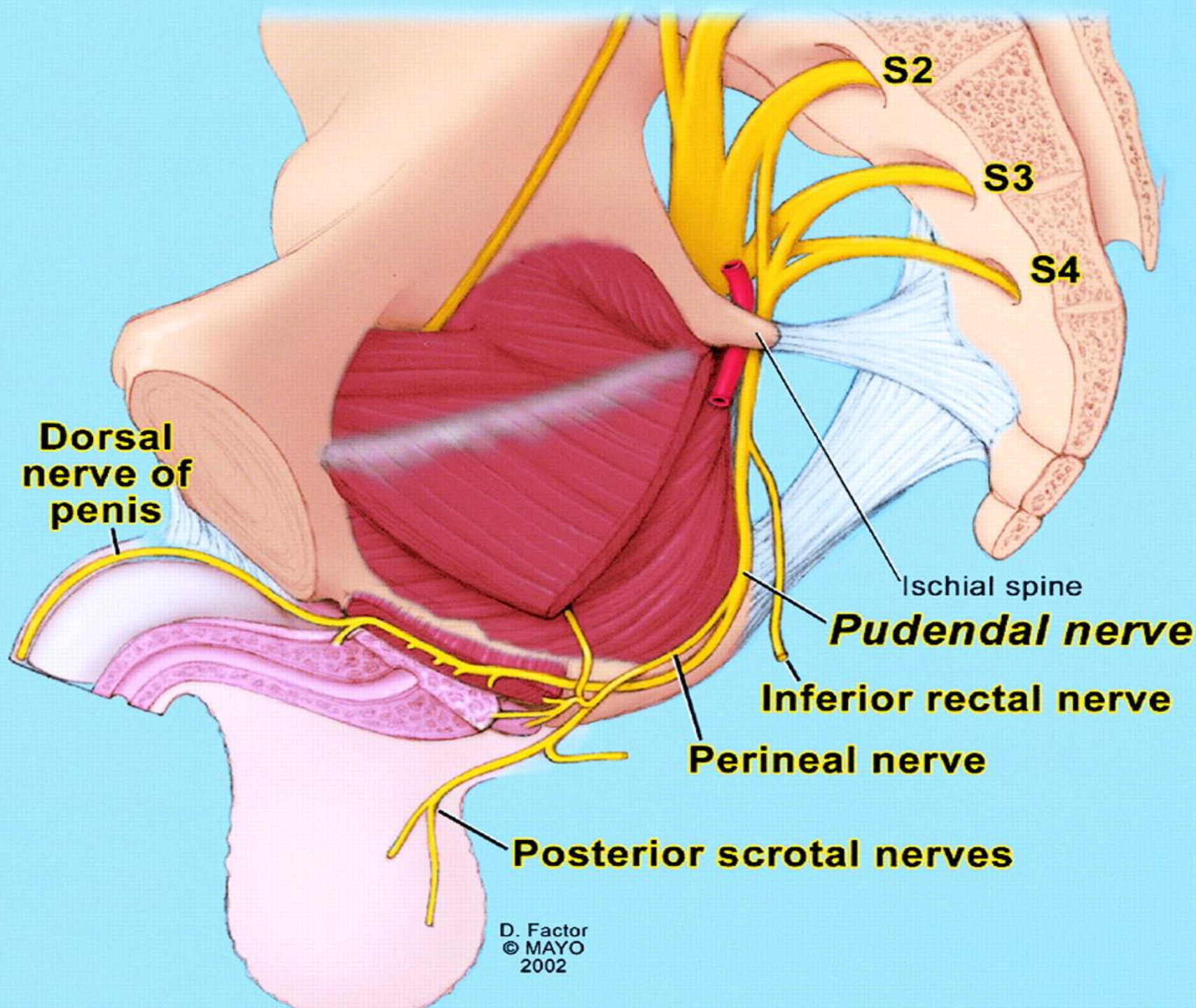
- canalis pudendalis (*Alcocki*)
- corpus adiposum fossae ischioanal
- paired recessus pubicus reaches ventrally above the trigonum urogenitale as far as the symphysis pubica

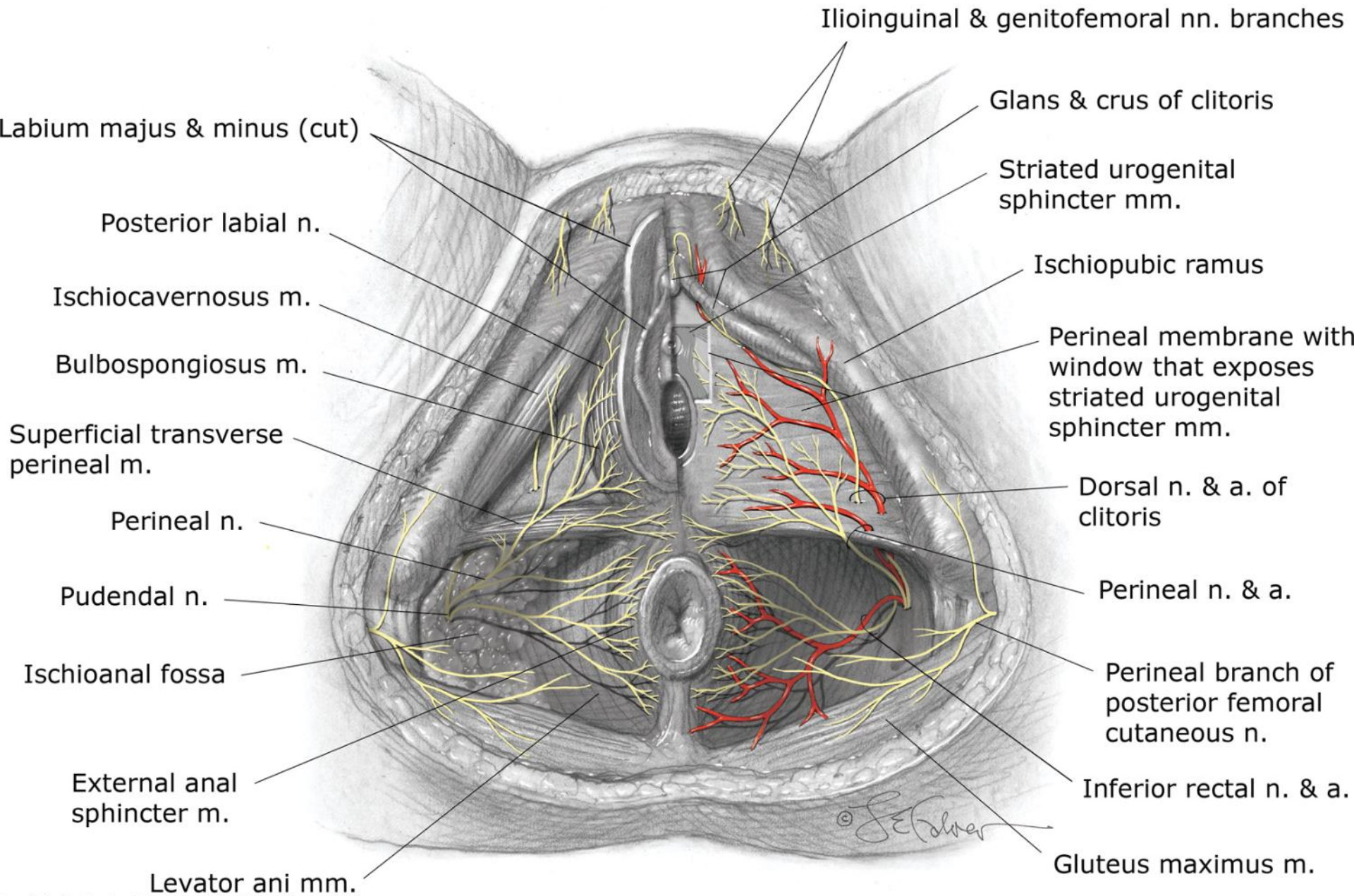


Canalis pudendalis Alcocki

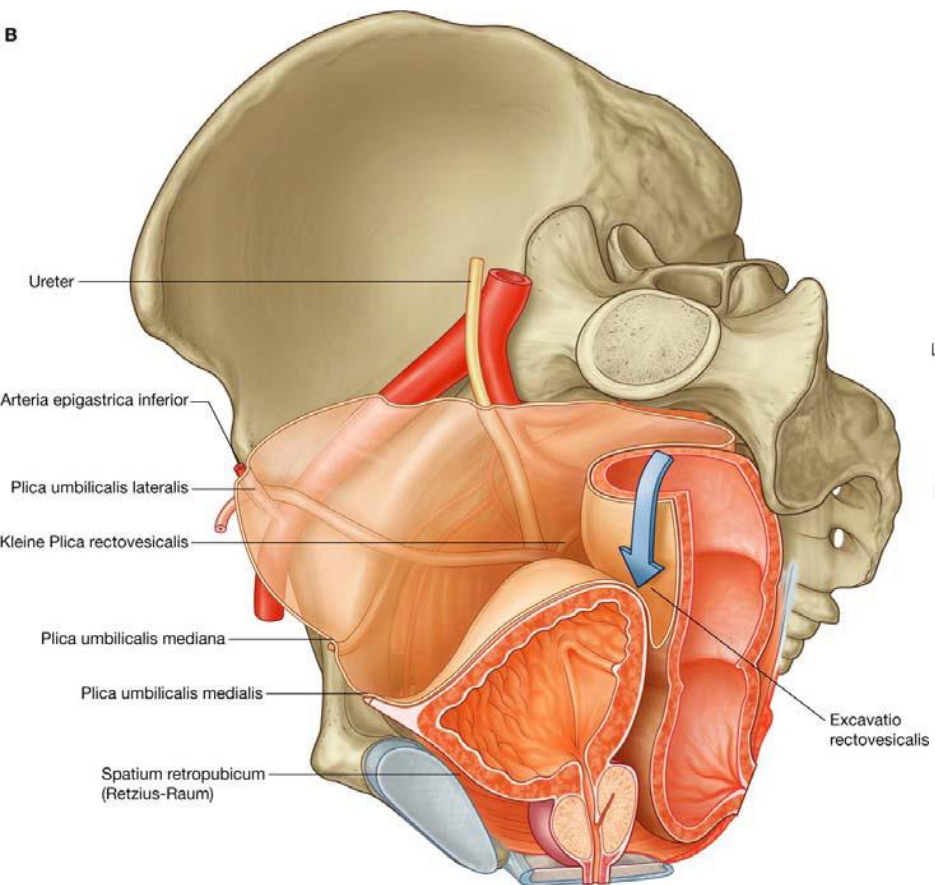
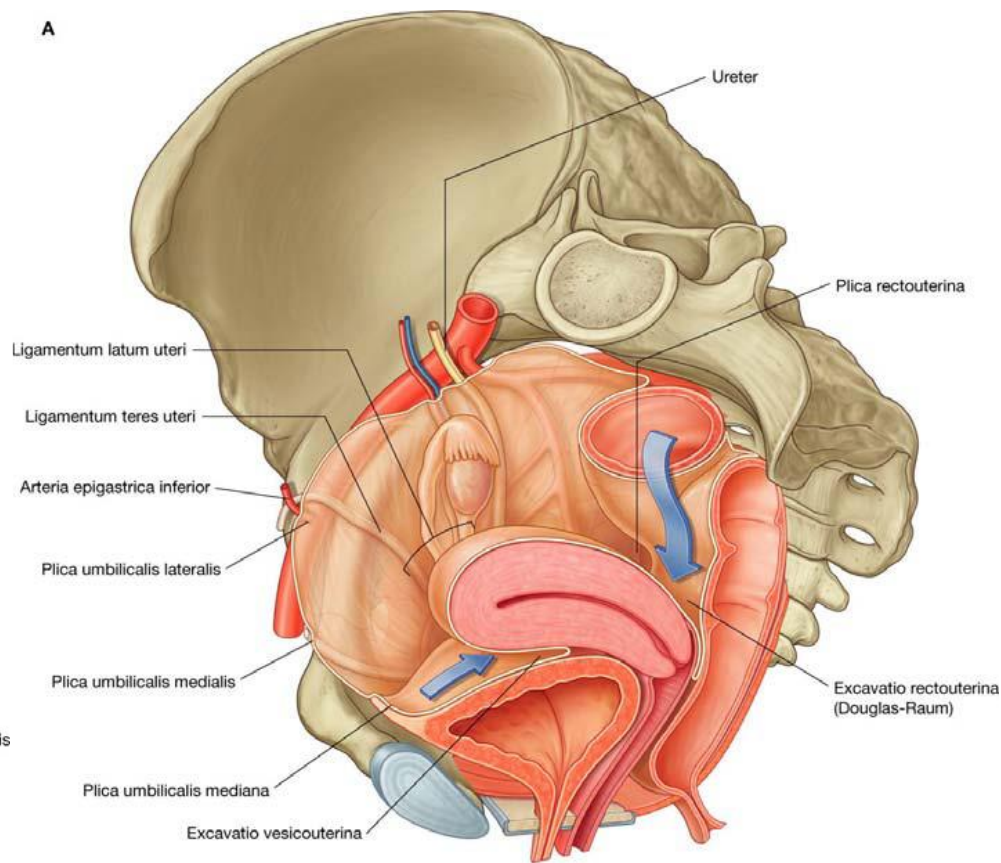
Pelvis and Perineum Frontal Section

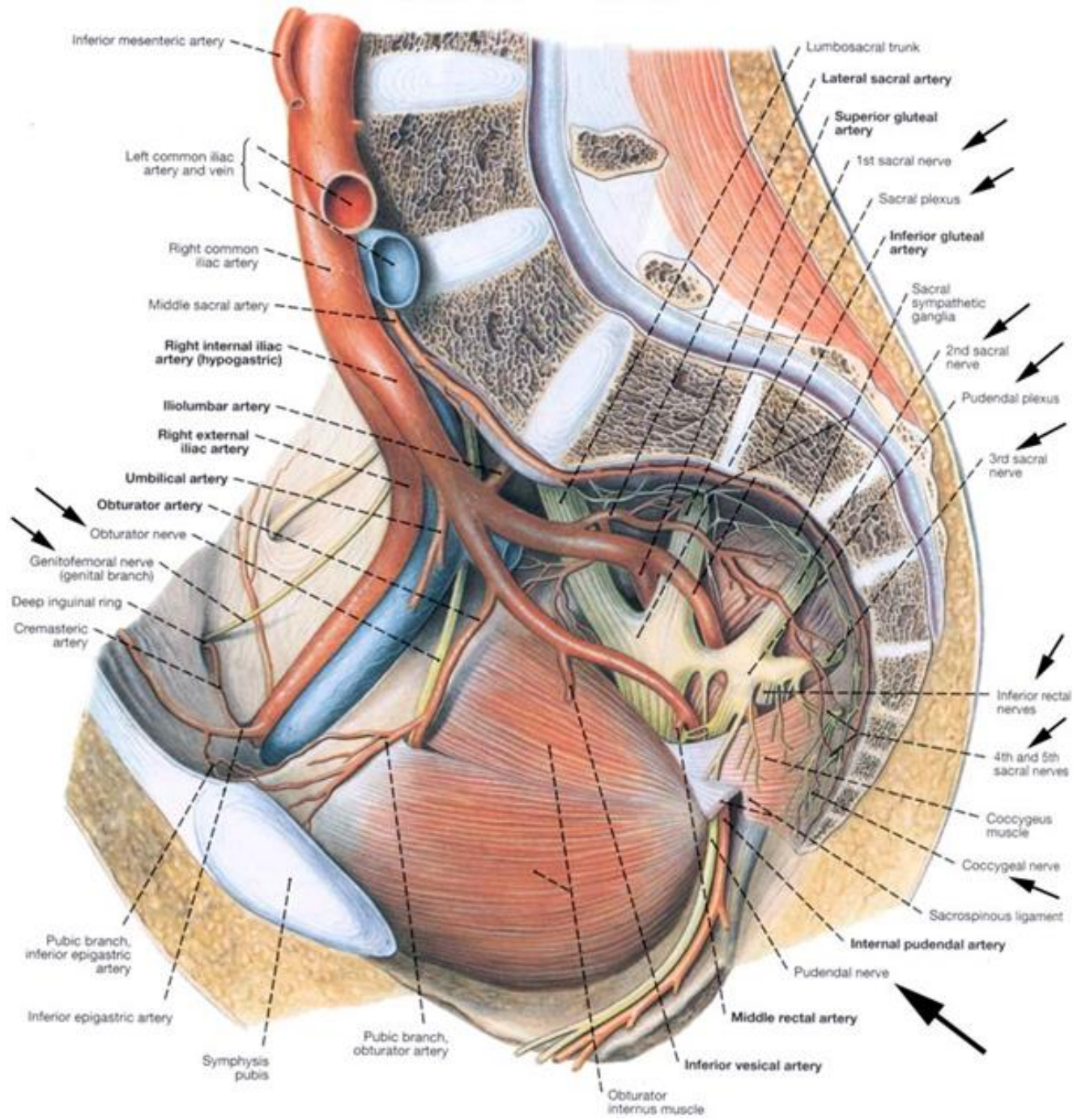






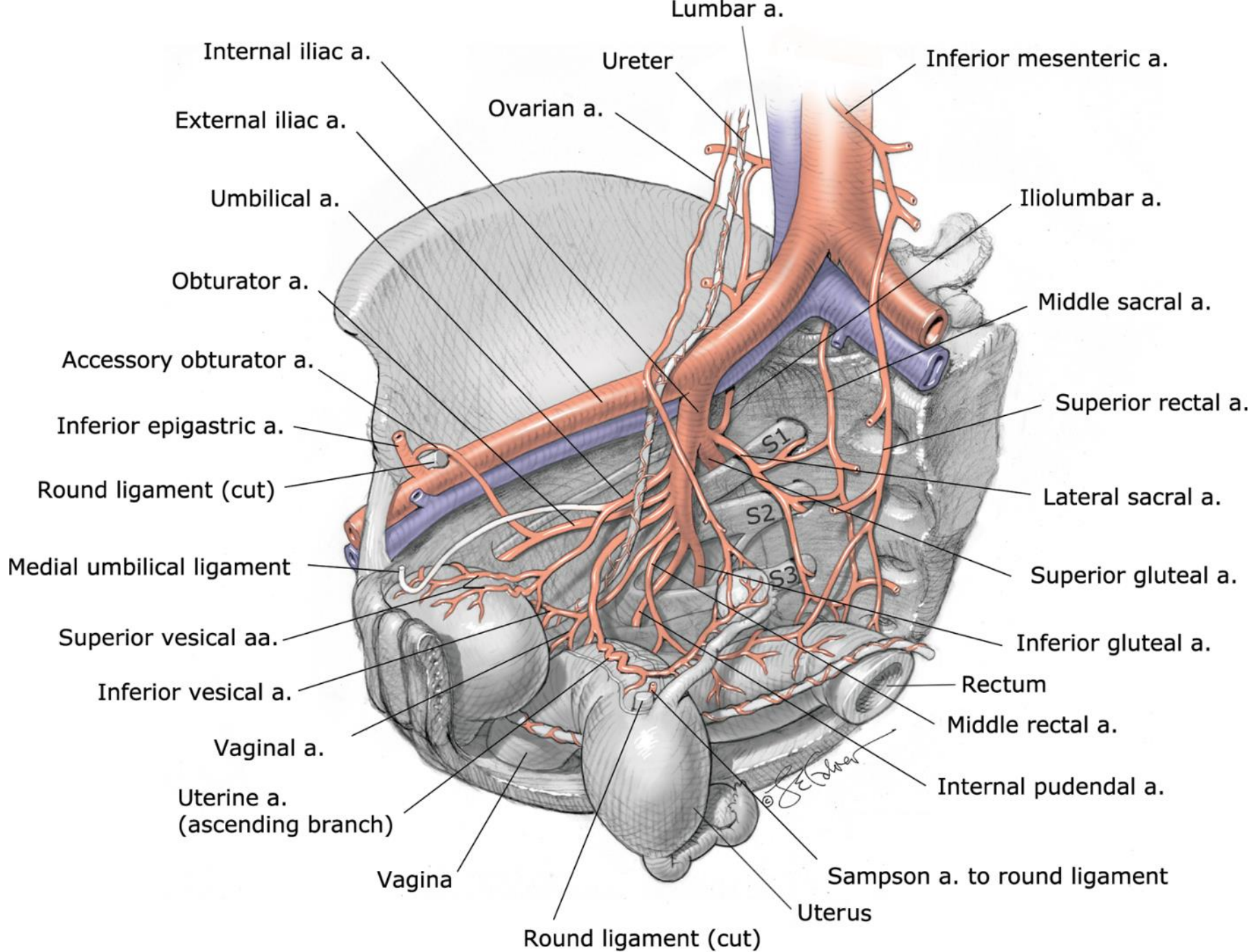
Source: F. Gary Cunningham, Kenneth J. Leveno, Steven L. Bloom, Catherine Y. Spong, Jodi S. Dashe, Barbara L. Hoffman, Brian M. Casey, Jeanne S. Sheffield: *Williams Obstetrics*, 25th Edition: www.obgyn.mhmedical.com Copyright © McGraw-Hill Education. All rights reserved.

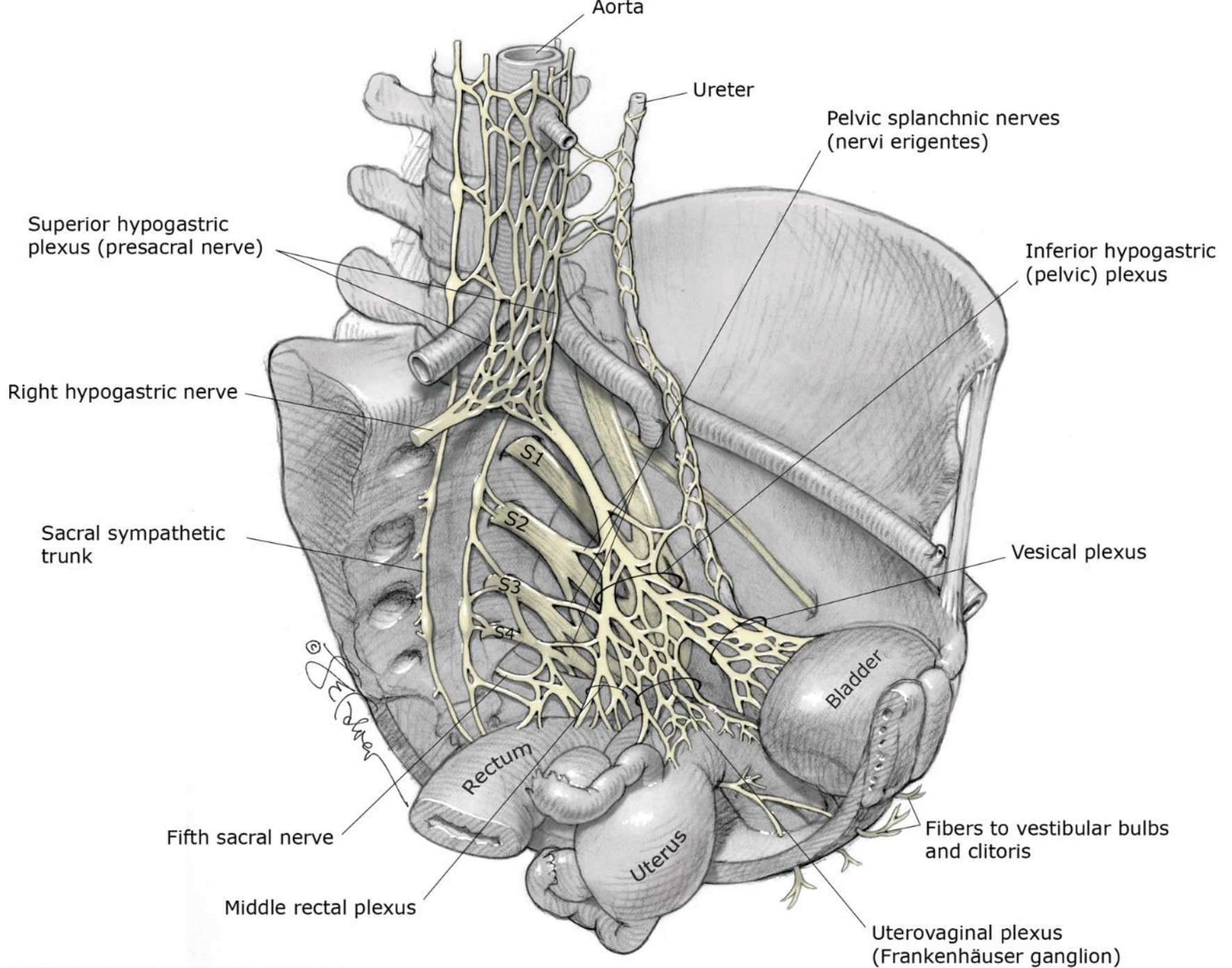
B**A**



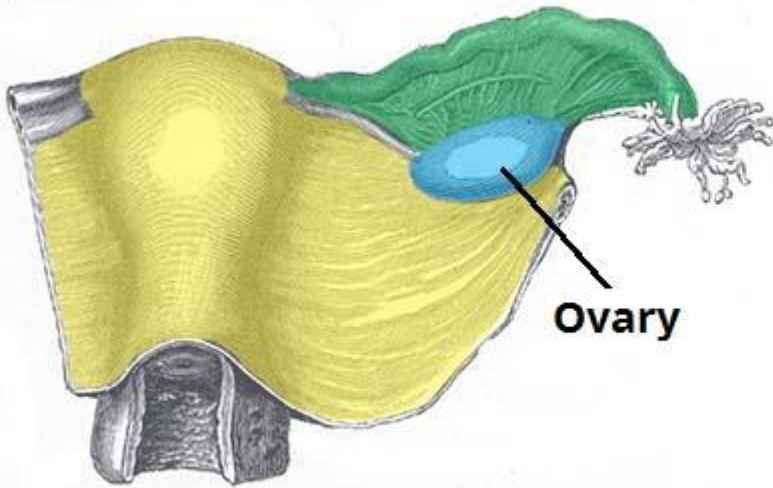
Inferior mesenteric artery
 Left common iliac artery and vein
 Right common iliac artery
 Middle sacral artery
 Right internal iliac artery (hypogastric)
 Iliolumbar artery
 Right external iliac artery
 Umbilical artery
 Obturator artery
 Obturator nerve
 Genitofemoral nerve (genital branch)
 Deep inguinal ring
 Cremasteric artery
 Pubic branch, inferior epigastric artery
 Inferior epigastric artery
 Symphysis pubis
 Pubic branch, obturator artery
 Obturator internus muscle

Lumbosacral trunk
 Lateral sacral artery
 Superior gluteal artery
 1st sacral nerve
 Sacral plexus
 Inferior gluteal artery
 Sacral sympathetic ganglia
 2nd sacral nerve
 Pudendal plexus
 3rd sacral nerve
 Inferior rectal nerves
 4th and 5th sacral nerves
 Coccygeus muscle
 Coccygeal nerve
 Sacrospinous ligament
 Internal pudendal artery
 Pudendal nerve
 Middle rectal artery
 Inferior vesical artery

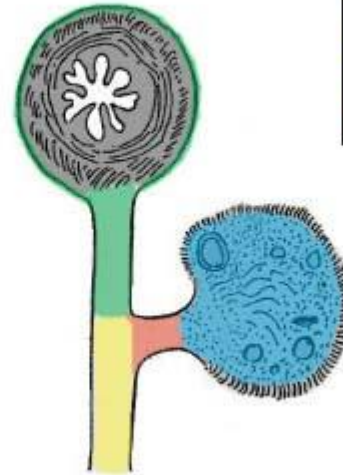




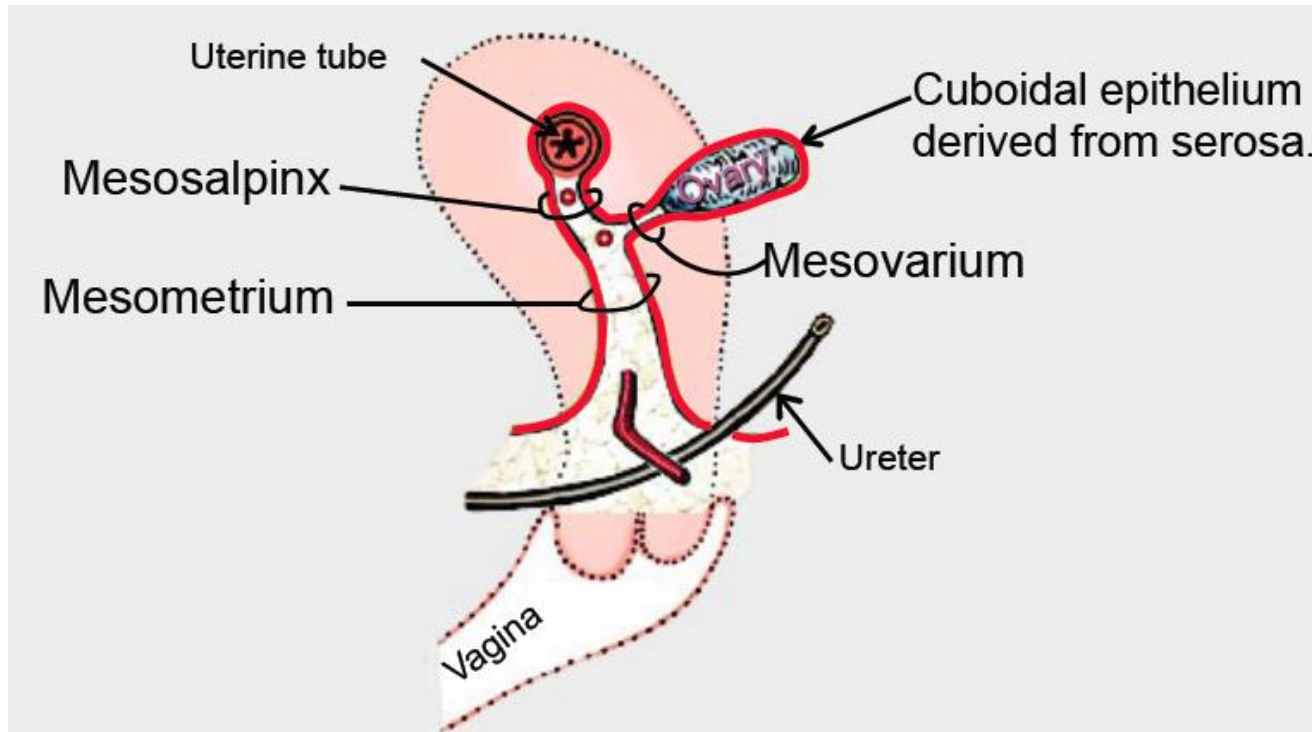
Coronal Plane:

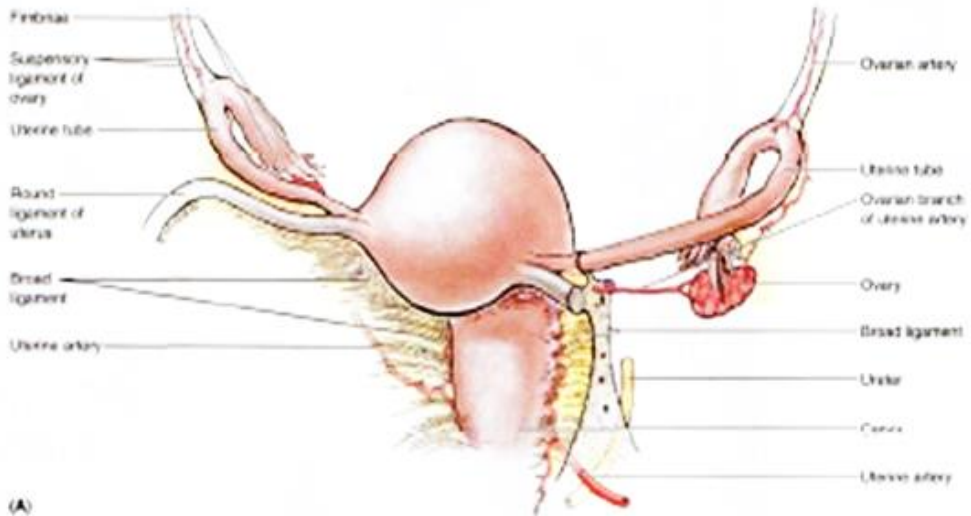
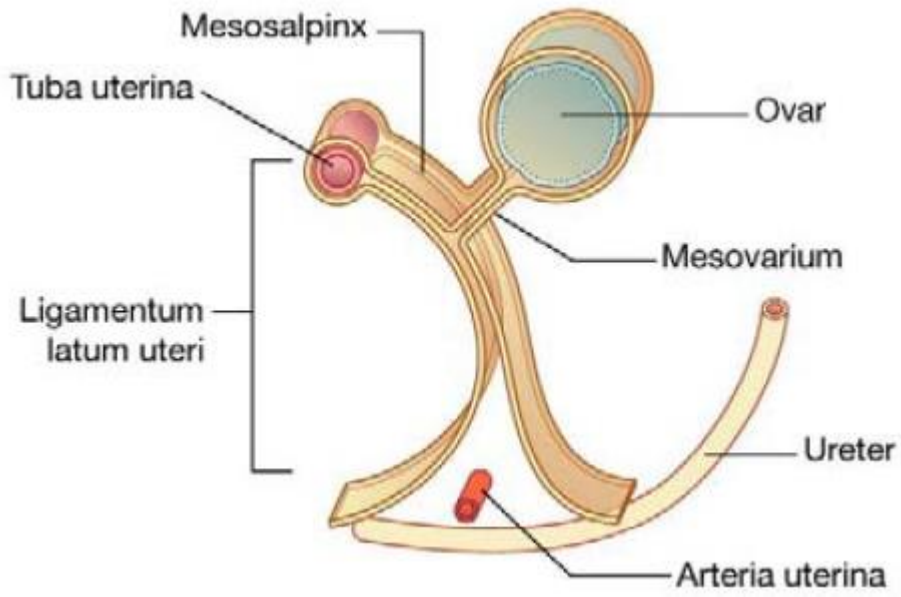


Sagittal Plane:

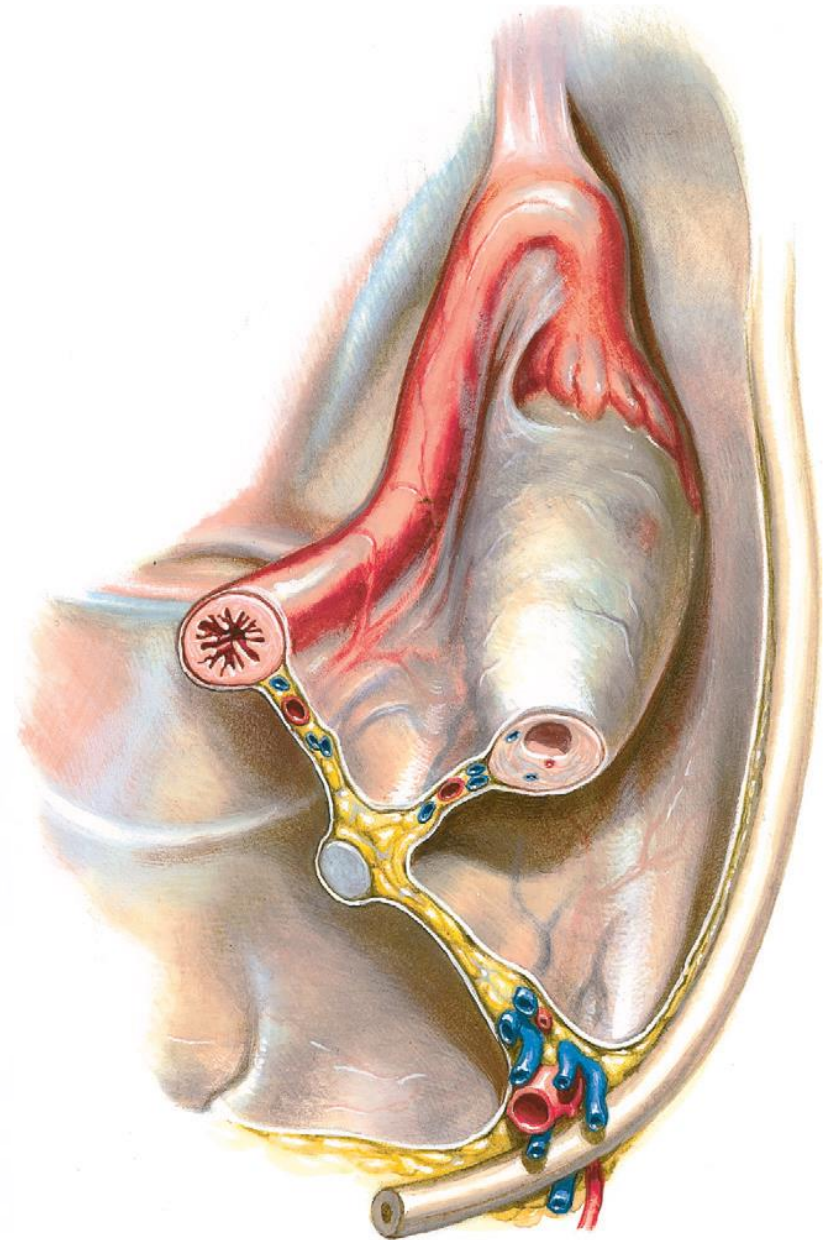


	Mesometrium
	Mesosalphinx
	Mesovarium



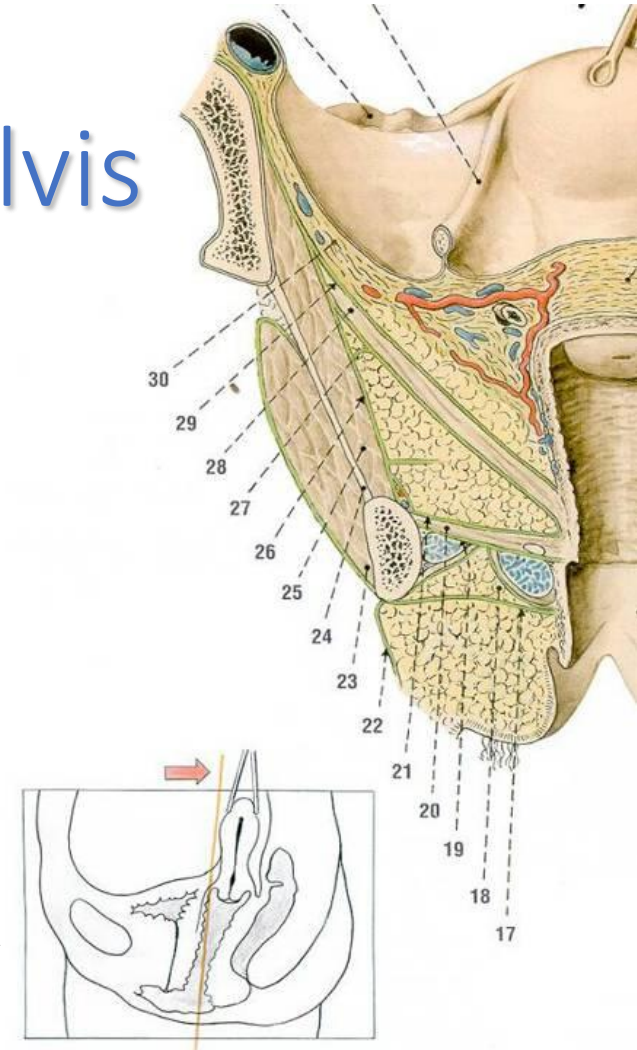


(A)

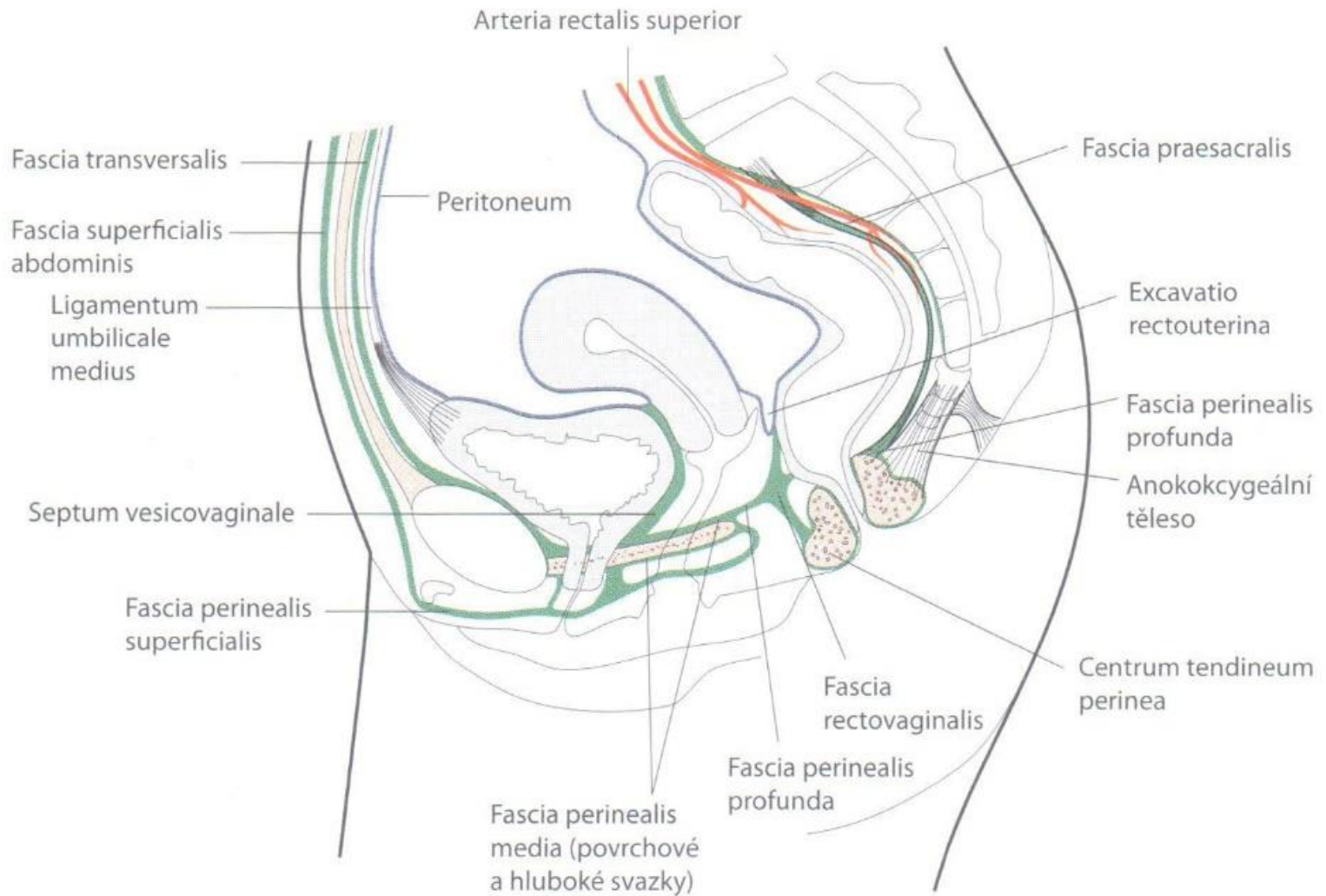


Fasciae of female lesser pelvis

- ***stratum membranosum tela subcutaneae***
 - „fascia perinei superficialis Collesi“
- ***fascia perinei***
 - *fascia investiens perinei superficialis*
 - „fascia perinei profunda Gallaudeti, fascia diaphragmatis urogenitalis inferior“
- ***membrana perinei***
 - „diaphragma urogenitale, fascia diaphragmatis urogenitalis superior“
- ***fascia diaphragmatis pelvis inferior***

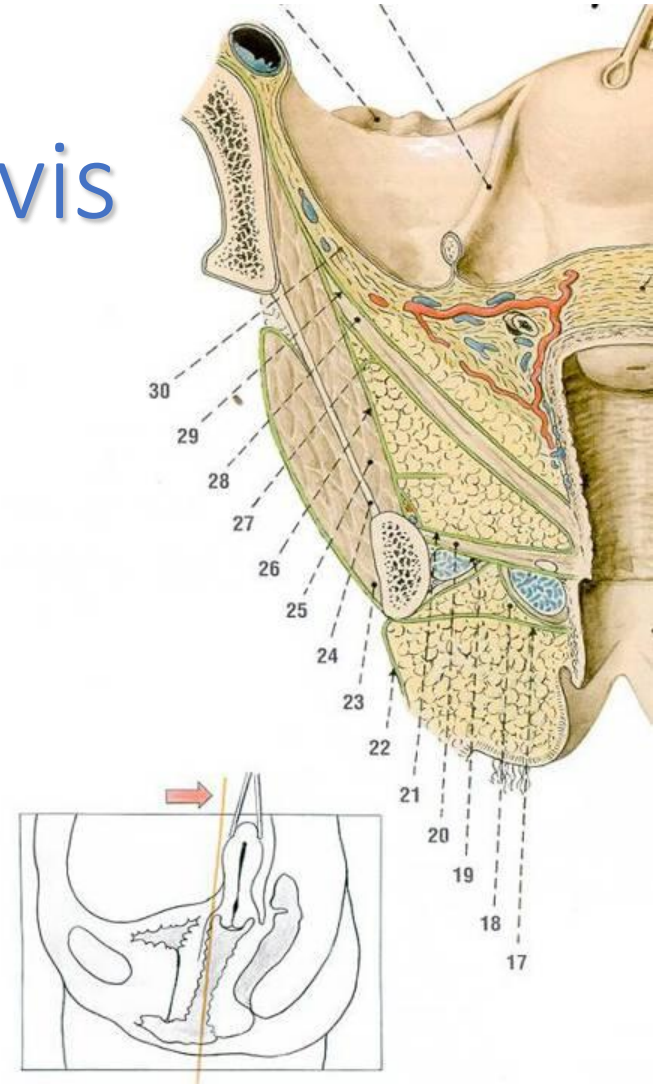


Fasciae of perineum



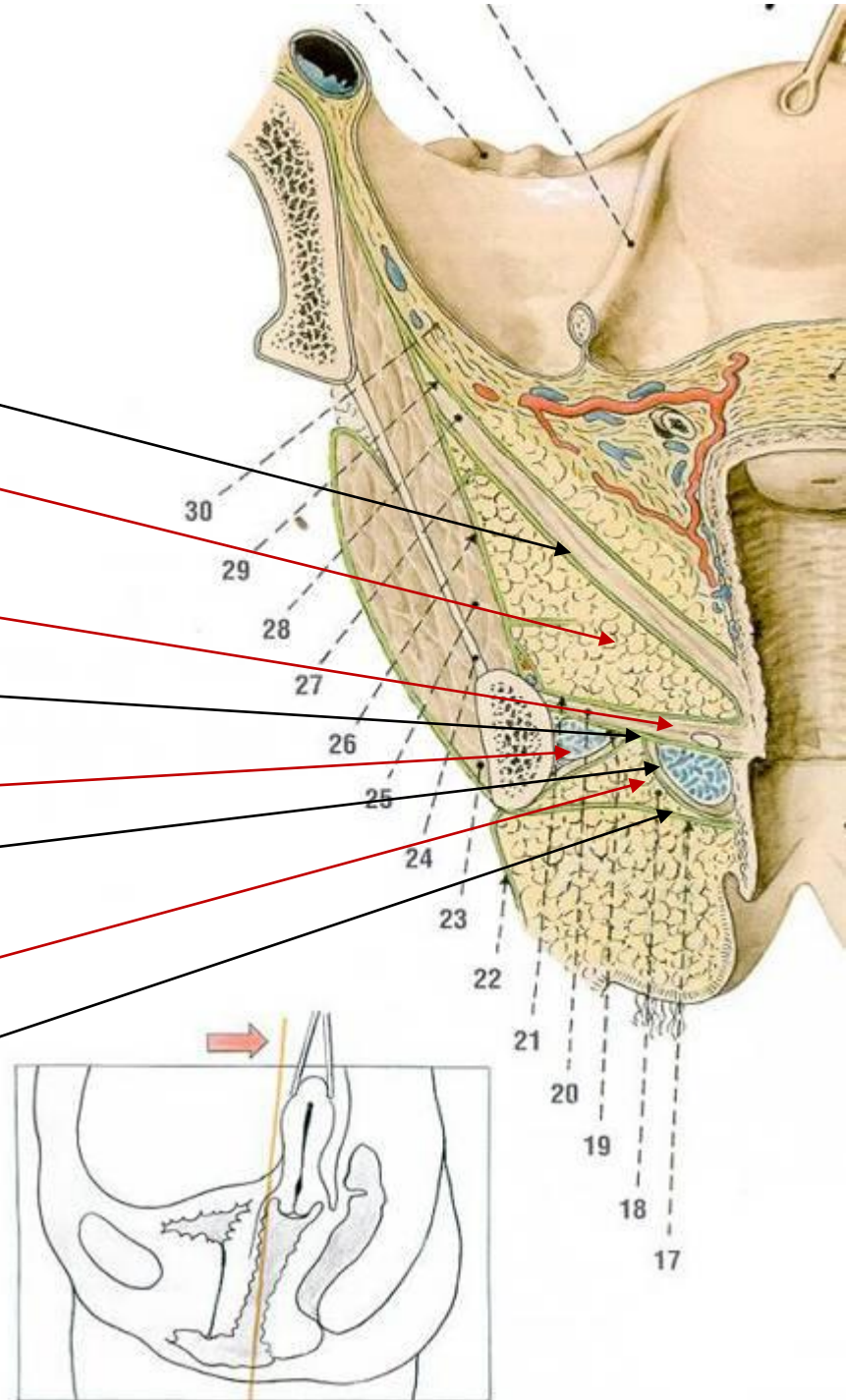
Space of female lesser pelvis

- saccus subcutaneus perinei
 - adipose tissue of hypodermis
- compartimentum / spatium superficiale perinei
 - crura clitoridis + mm. ischiocavernosus, bulbi vestibuli + mm. bulbospongiosus, mm. transversus perinei superficiales
- saccus profundus / spatium profundum perinei
 - membrana perinei, 3 sphincters of urethra
- recessus pubicus fossae ischioanalis

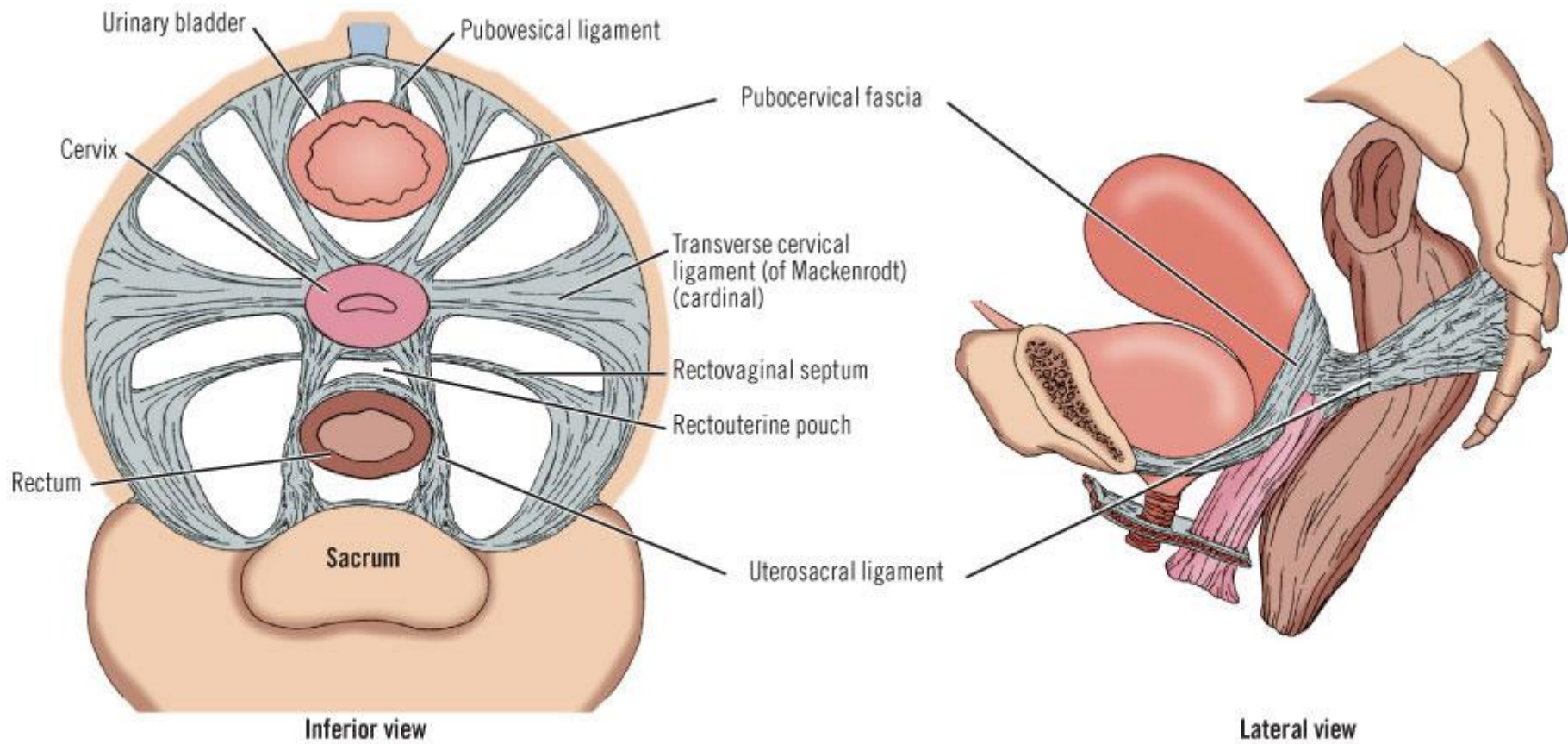


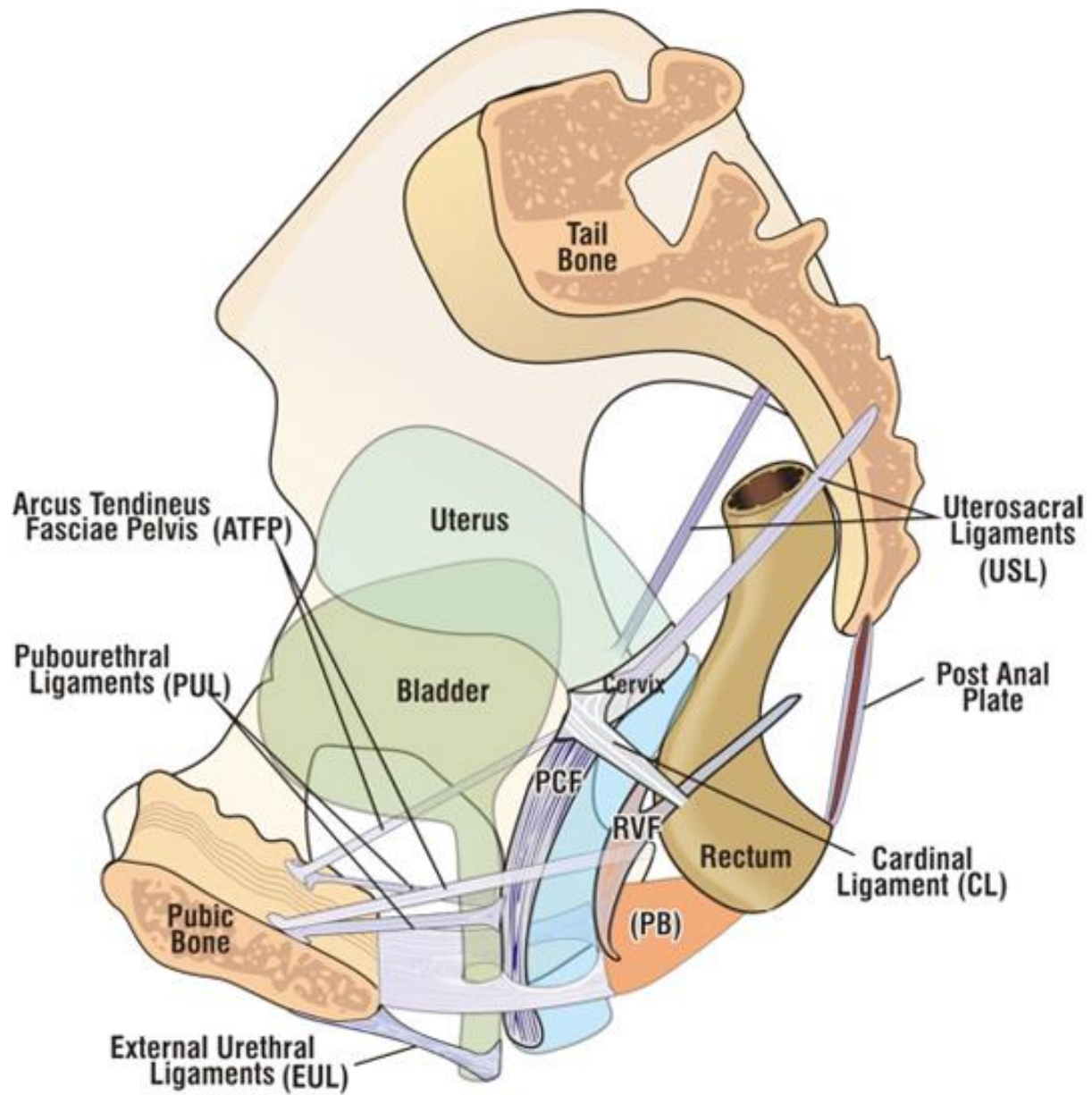
Fasciae and spaces of female lesser pelvis

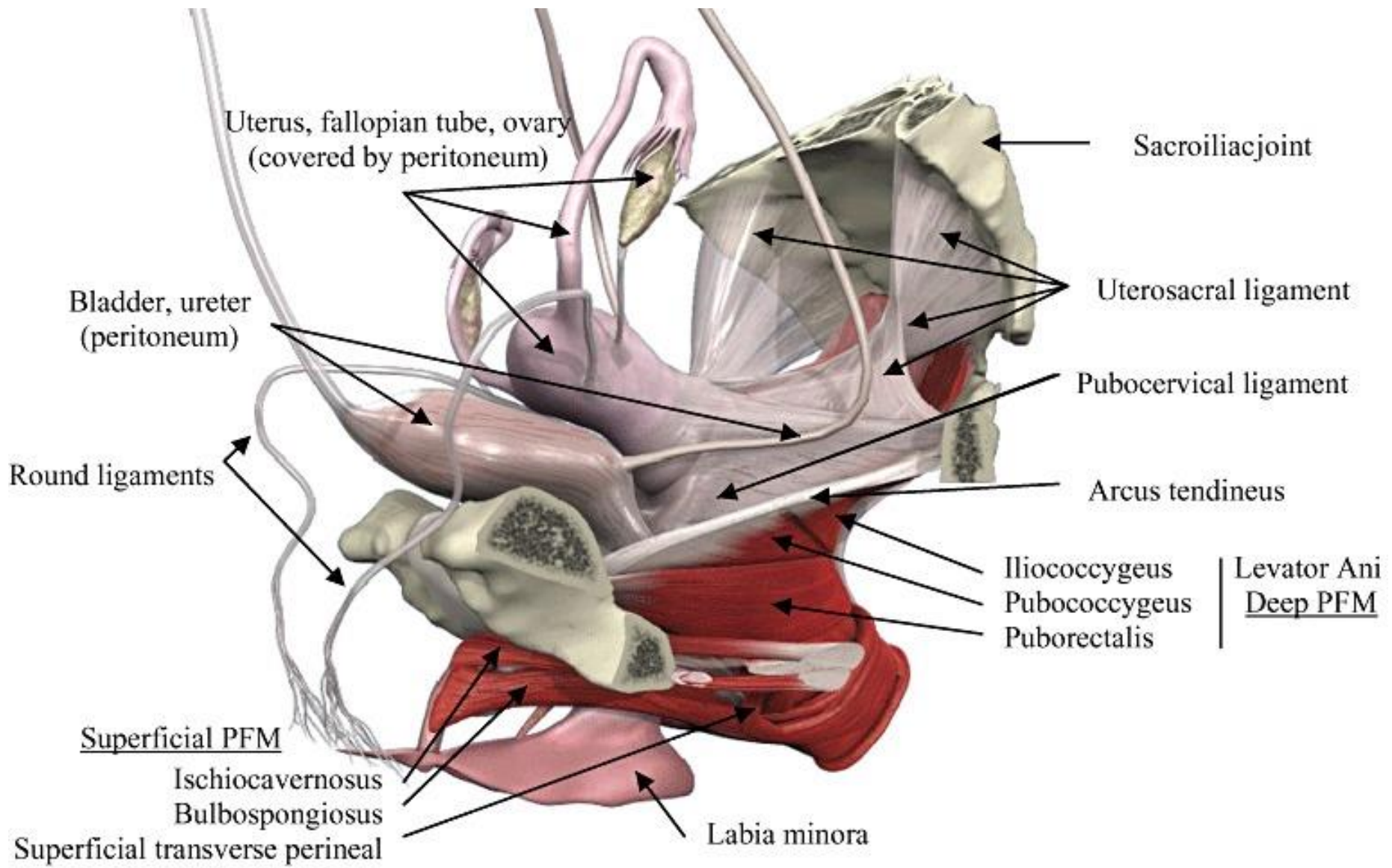
- fascia diaphragmatis pelvis inferior
- recessus pubicus fossae ischioanalis
- saccus profundus perinei
- membrana perinei
- compartimentum superficiale perinei
- fascia perinei
- saccus subcutaneus perinei
- stratum membranosum telae subcutaneae



Fibrous bands

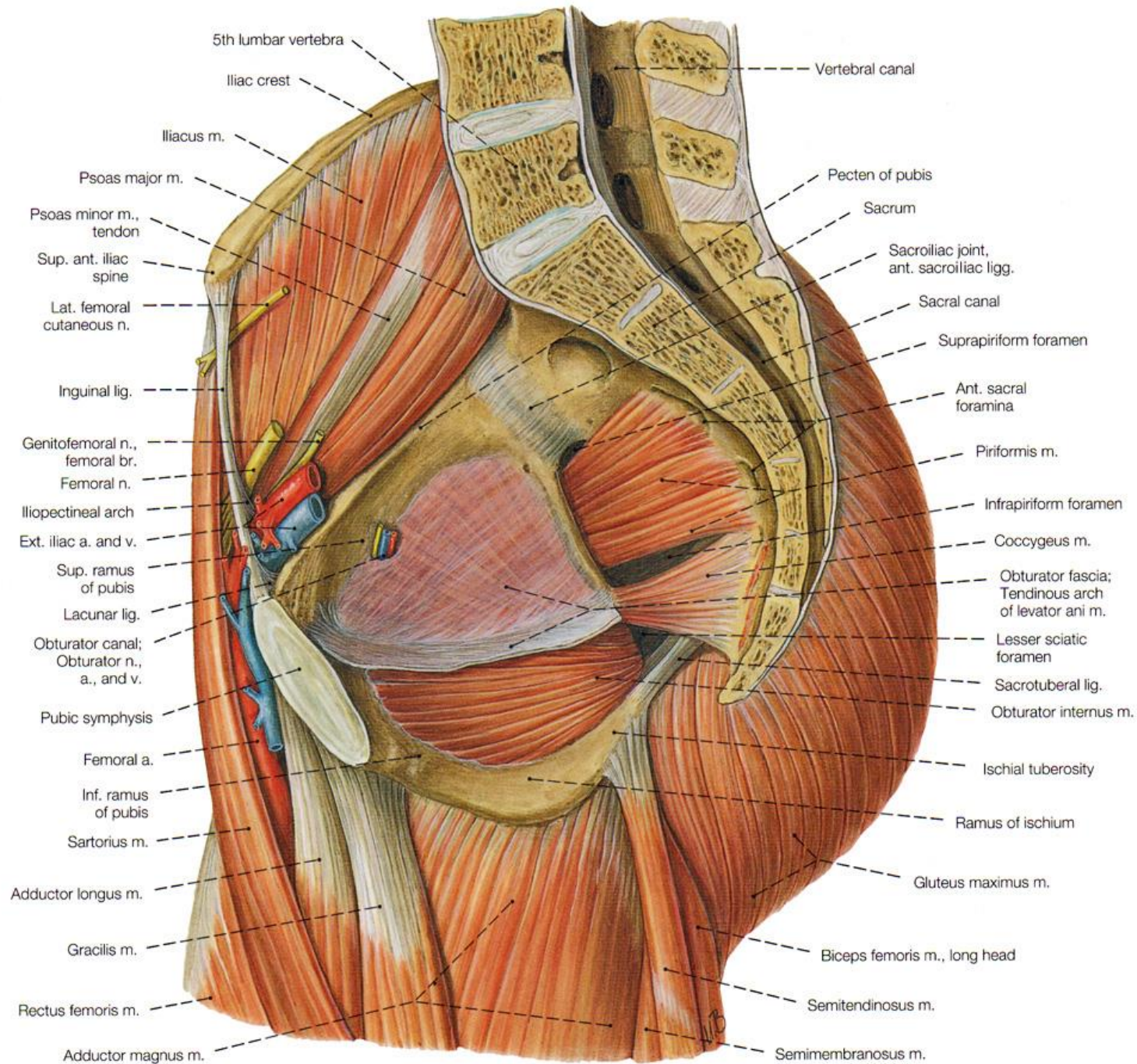


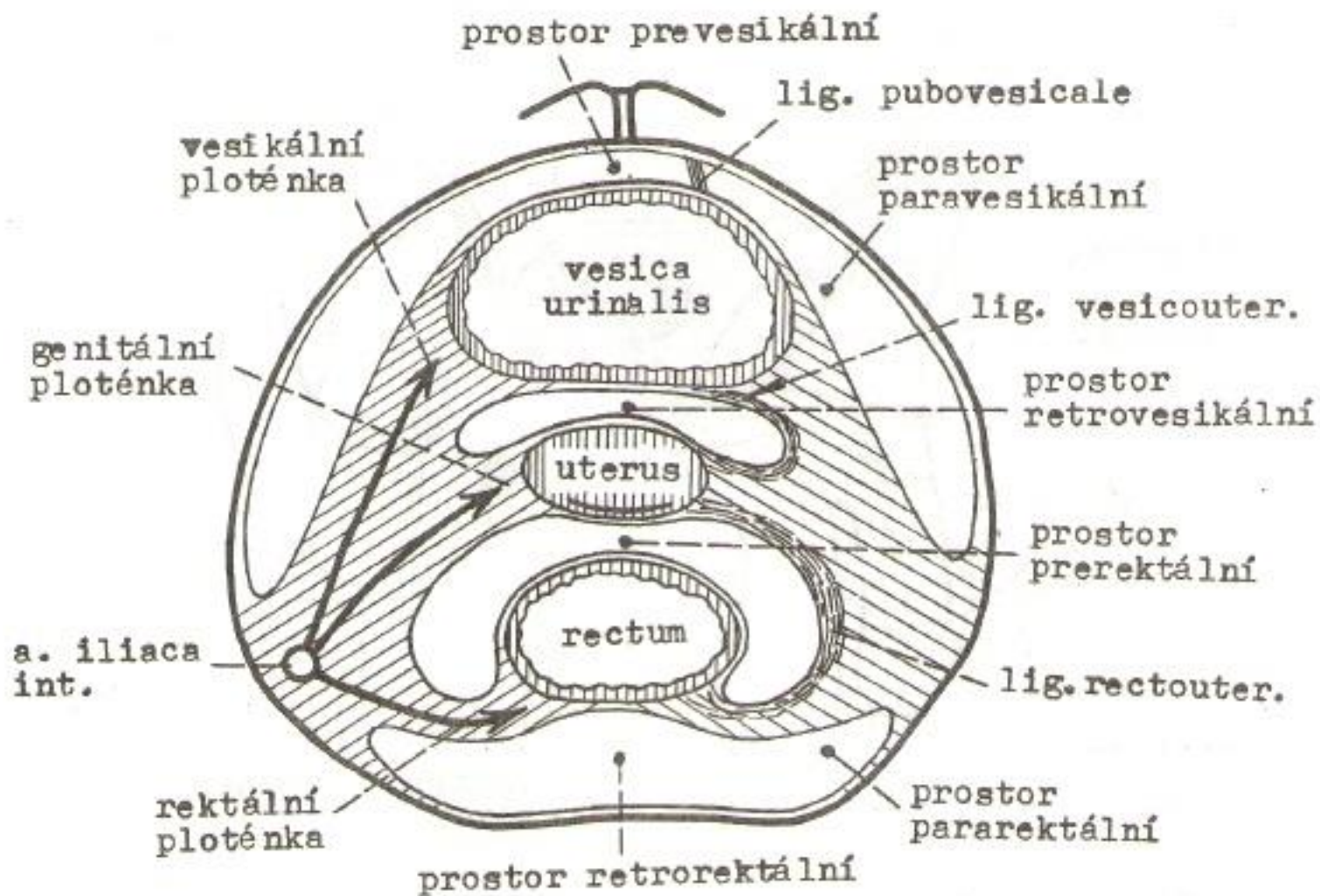




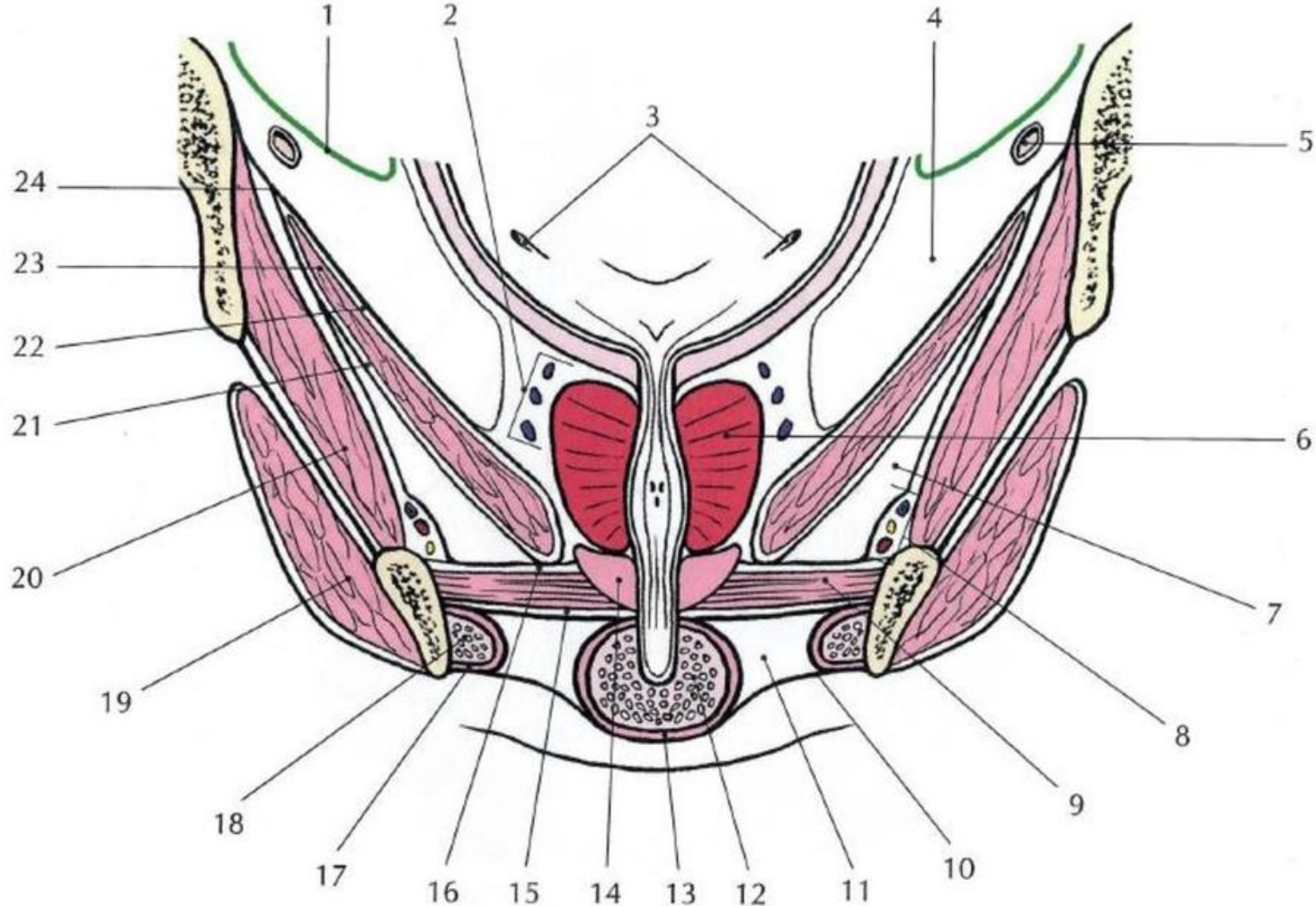
Fasciae of pelvic cavity

- fascia pelvis parietalis (fascia endopelvica)
 - fascia obturatoria
 - fascia diaphragmatis pelvis superior
 - Innominate over os sacrum (FPP)
- fascia pelvis visceralis
 - arcus tendineus fasciae pelvis
 - lamina vesicalis (anterior pillar) = continues as fascia vesicoumbilicalis
 - lamina genitalis (middle pillar) = fascia rectoprostatica/rectovesicalis
 - lamina rectalis (posterior pillar) = fascia perirectalis





Obr.66. Členění infraperitoneálního prostoru pánve.
 Schema. (Zjednodušeno podle Pernkopfa).

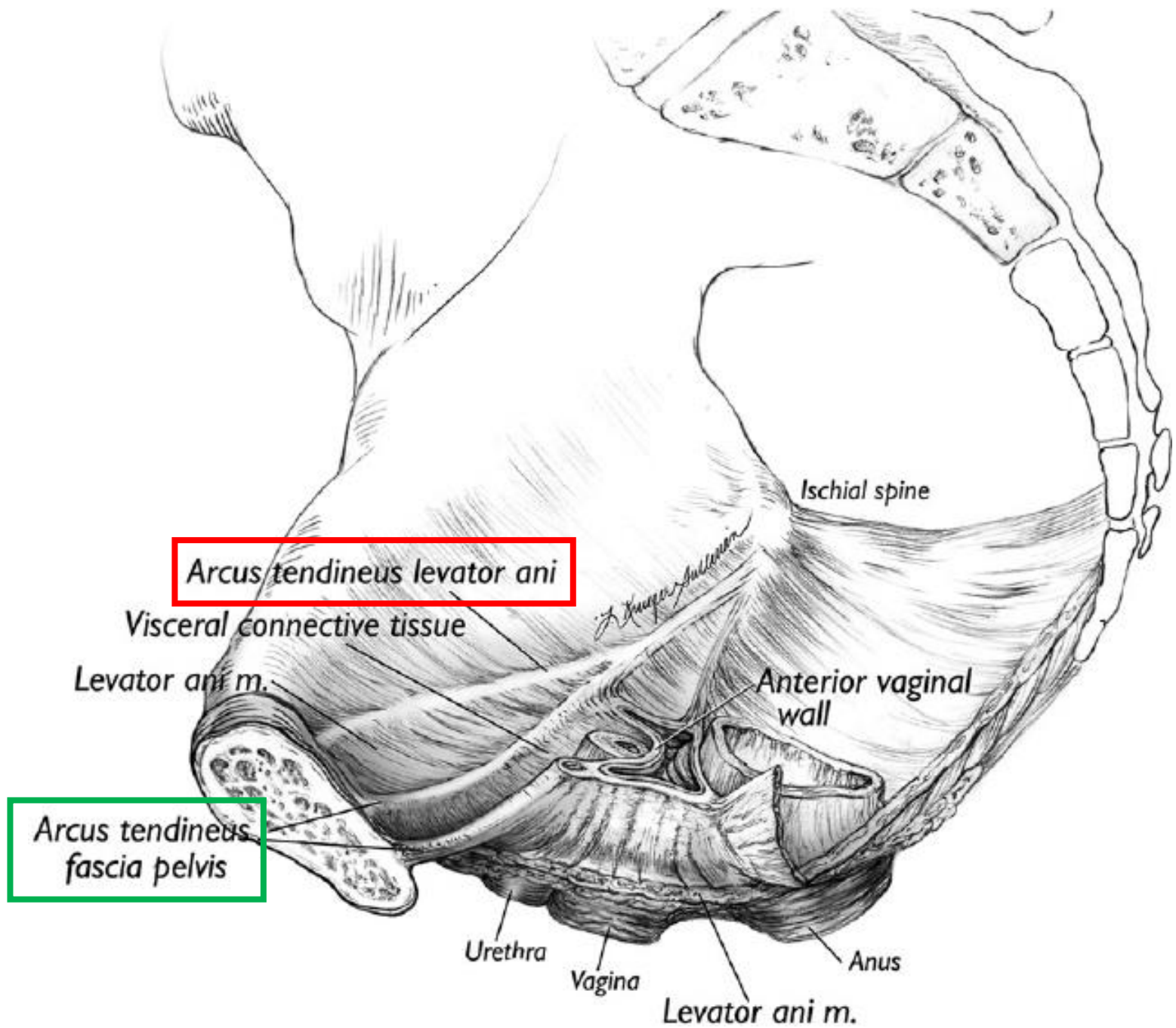


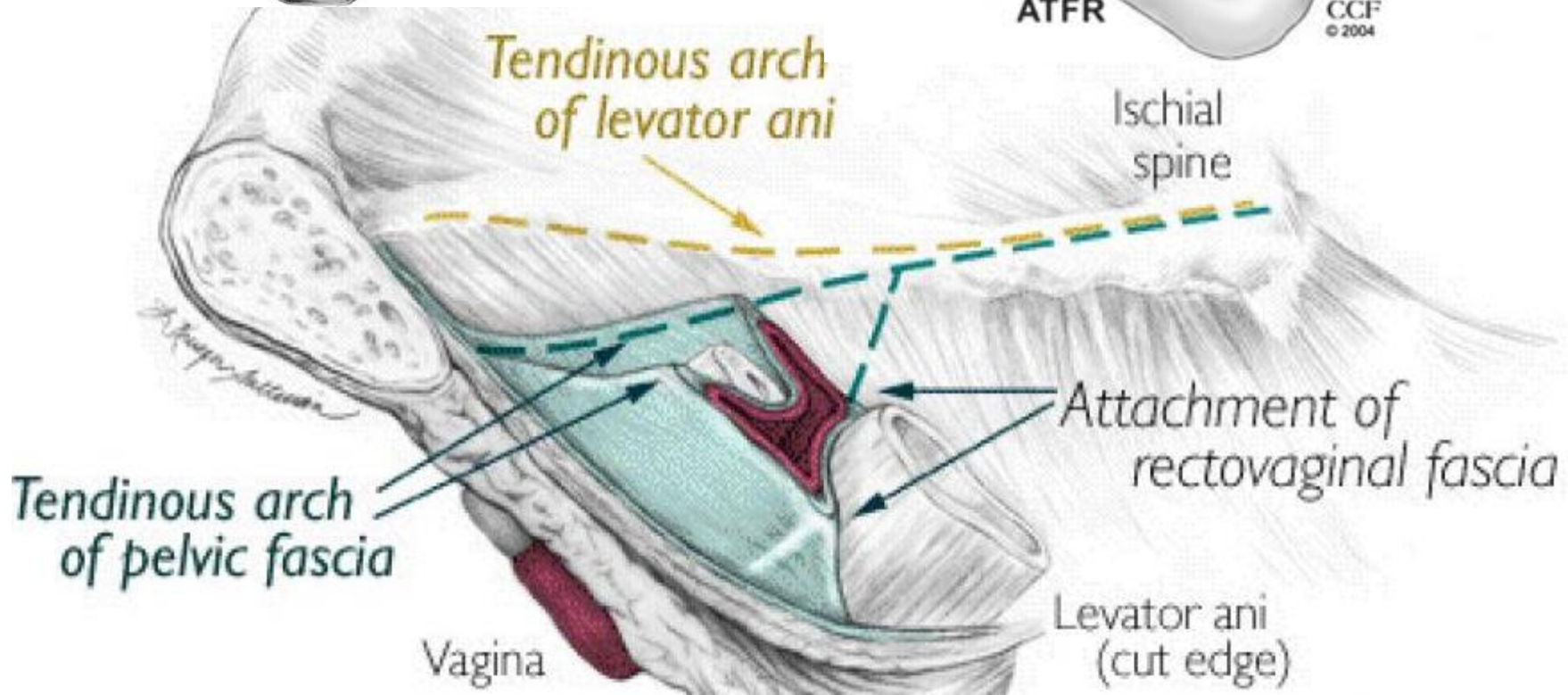
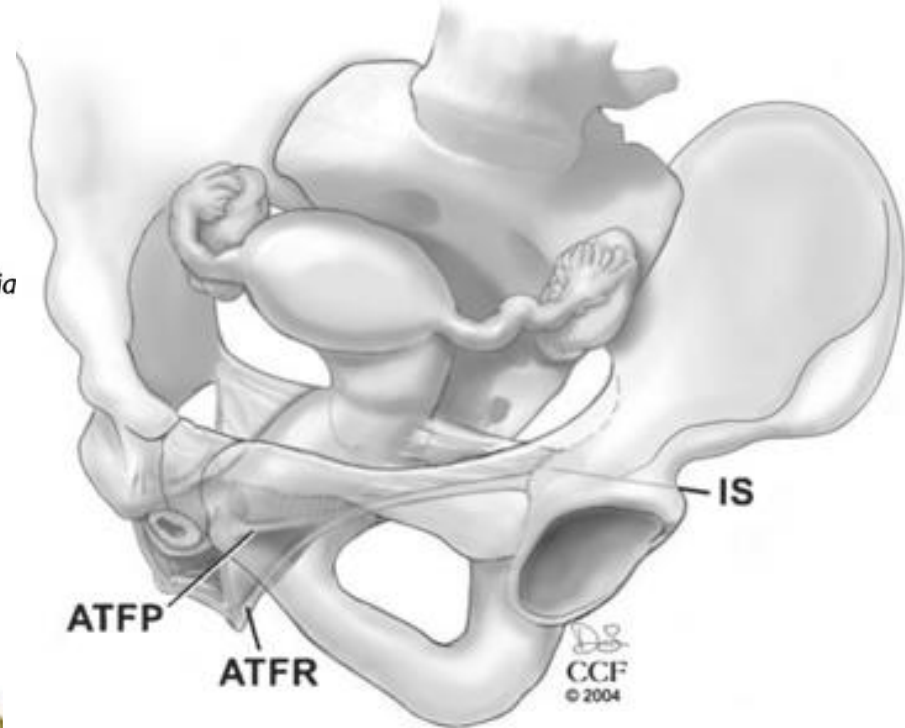
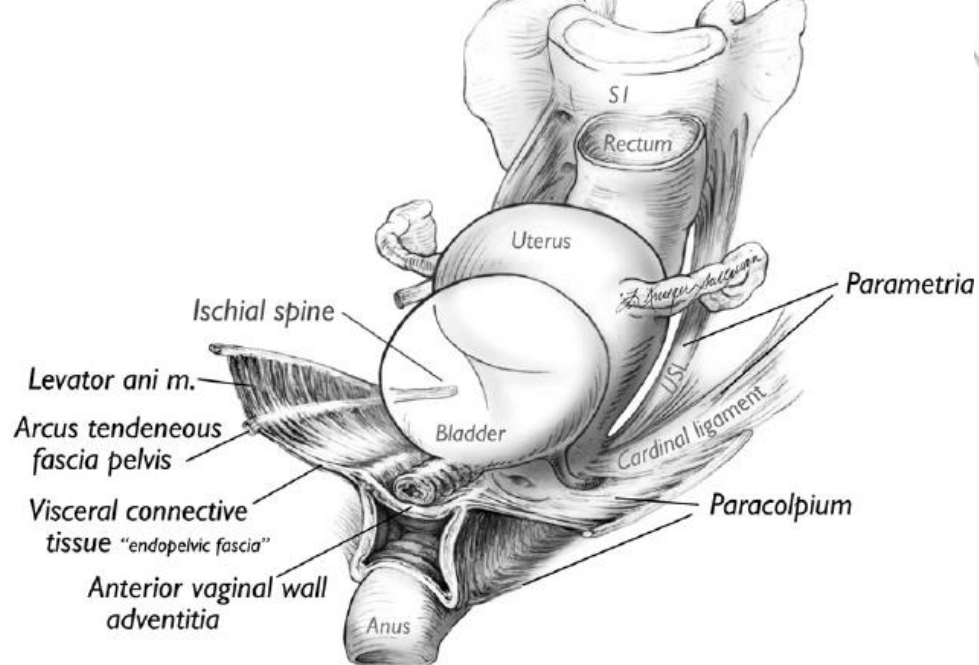
Obr. 14.11. Prostory a fascie malé pánve (frontální řez mužskou pánví)

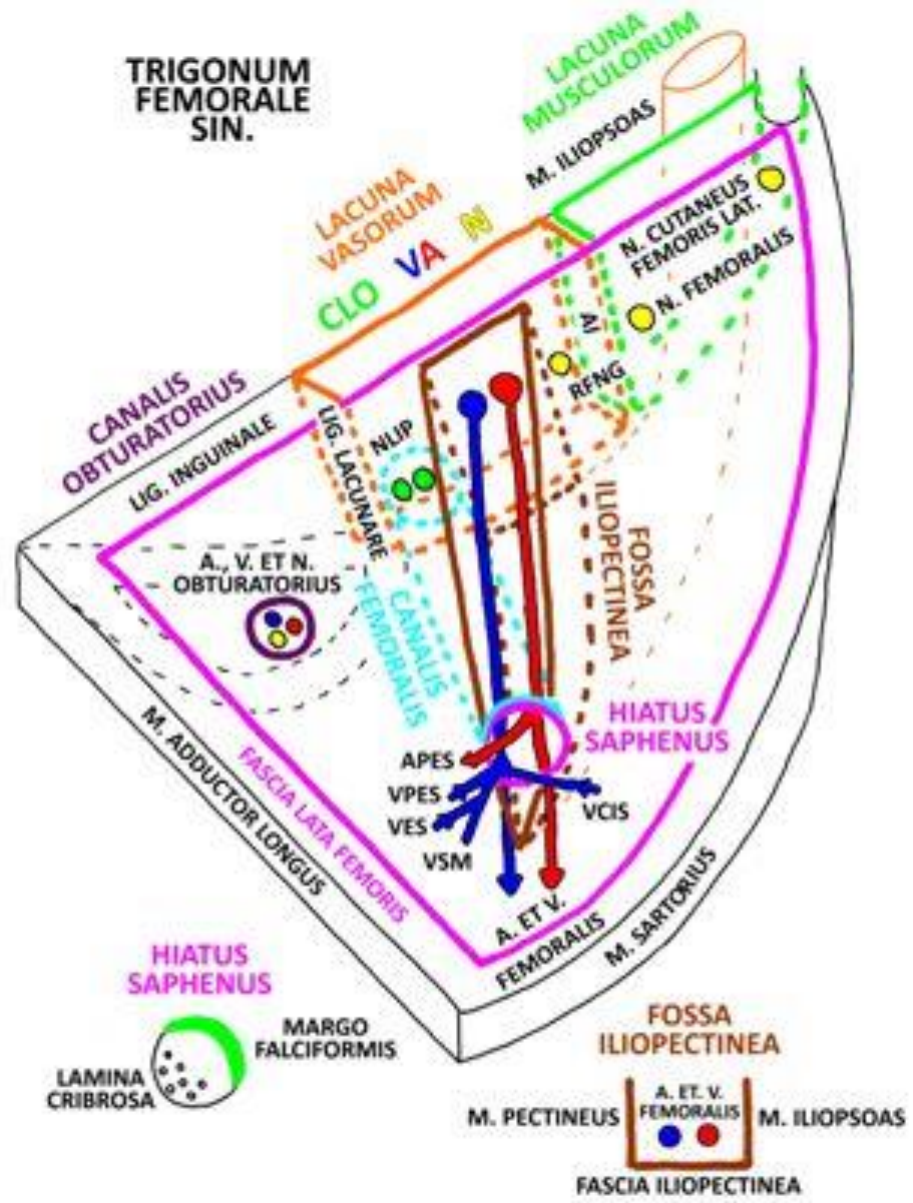
- 1 – peritoneum
- 2 – plexus venosus prostaticus
- 3 – ostium uretherum int.
- 4 – paracystium
- 5 – ductus deferens
- 6 – prostata
- 7 – fossa ischiorectalis
- 8 – vasa pudenda int. a n. pudendus
v Alcockově kanále

- 9 – diaphragma urogenitale
- 10 – fascia perinei superficialis
- 11 – spatium perinei superficiale
- 12 – bulbus penis
- 13 – m. bulbospongiosus
- 14 – m. sphincter urethrae ext.
- 15 – fascia diaphragmatis urogenitalis
inferior
- 16 – fascia diaphragmatis urogenitalis
superior

- 17 – m. ischiocavernosus
- 18 – crus penis
- 19 – m. obturatorius ext.
- 20 – m. obturatorius int.
- 21 – fascia diaphragmatis pelvis
inferior
- 22 – fascia diaphragmatis pelvis
superior
- 23 – m. levator ani
- 24 – arcus tendineus m. levatoris ani





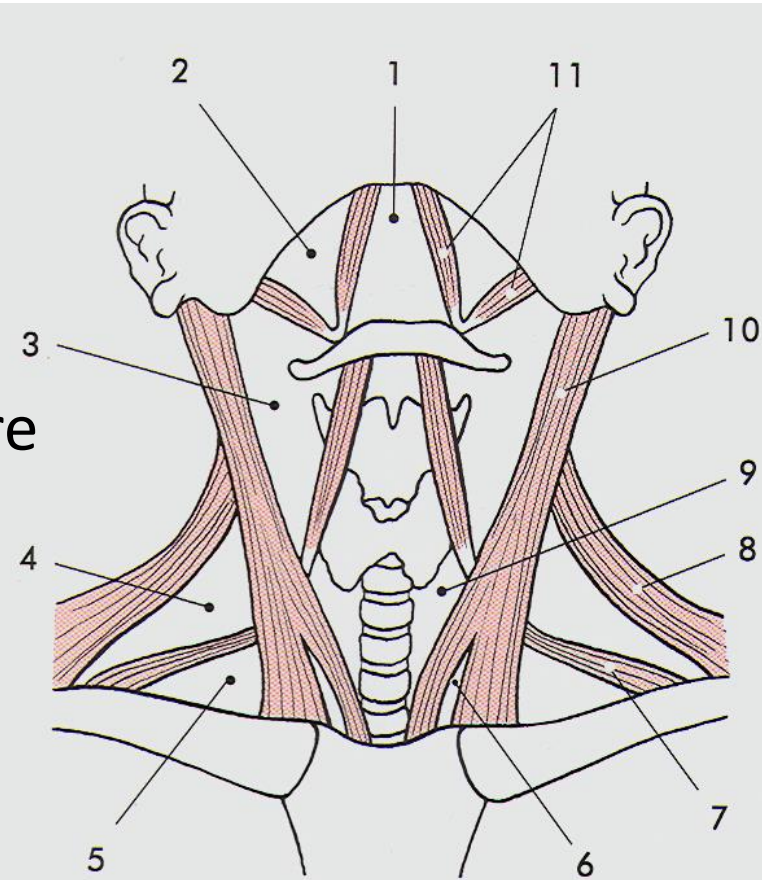


- NLIP = NODI LYMPHOIDEI INGUINALES PROFUNDI
- AI = ARCUS ILIOPECTINEUS
- RFNG = R. FEMORALIS N. GENITOFEMORALIS
- APES = A. PUDENDA EXTERNA SUPERFICIALIS
- VPES = V. PUDENDA EXTERNA SUPERFICIALIS
- VES = V. EPIGASTRICA SUPERFICIALIS
- VSM = V. SAPHENA MAGNA
- VCIS = V. CIRCUMFLEXA ILIUM SUPERFICIALIS

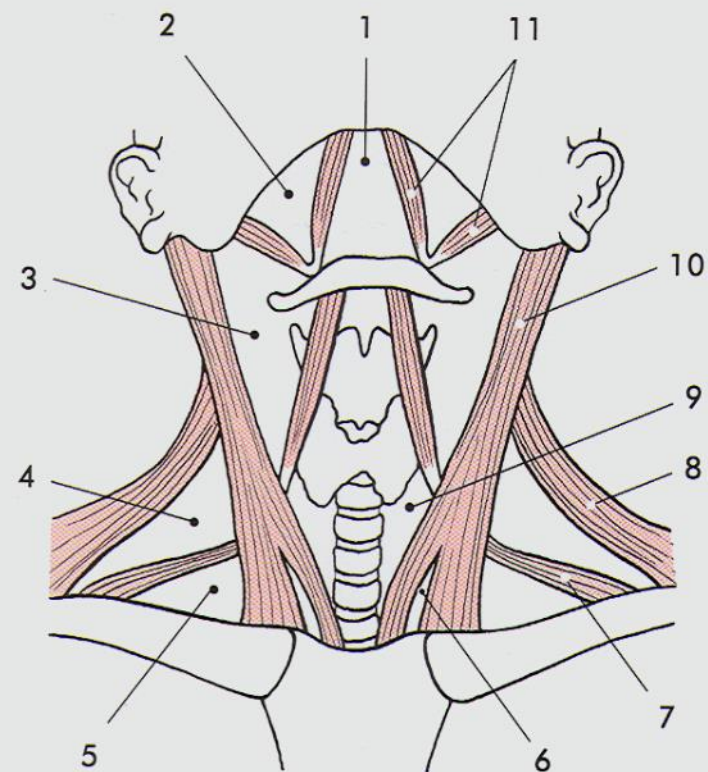
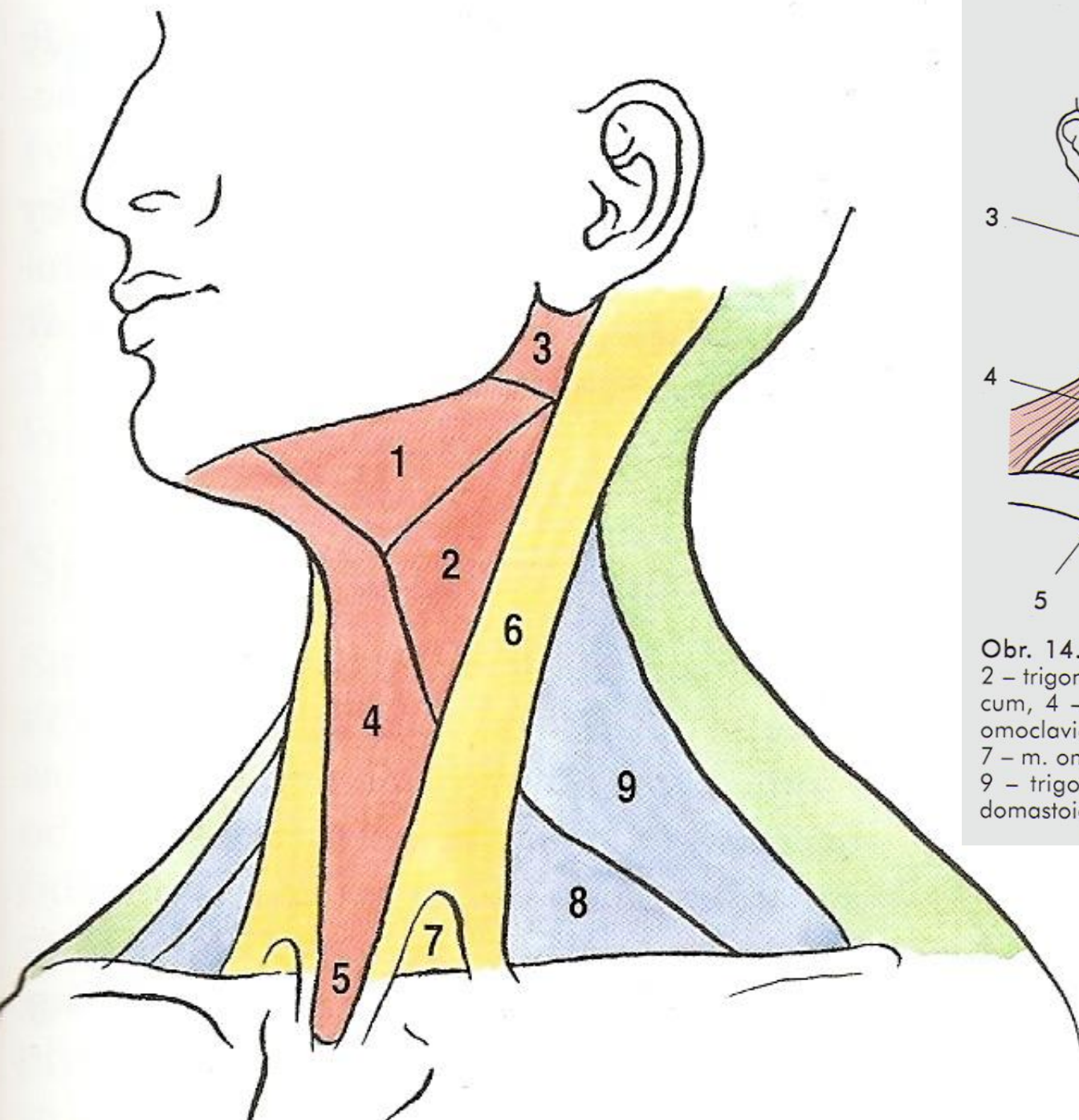
Topography of neck

Triangles of neck

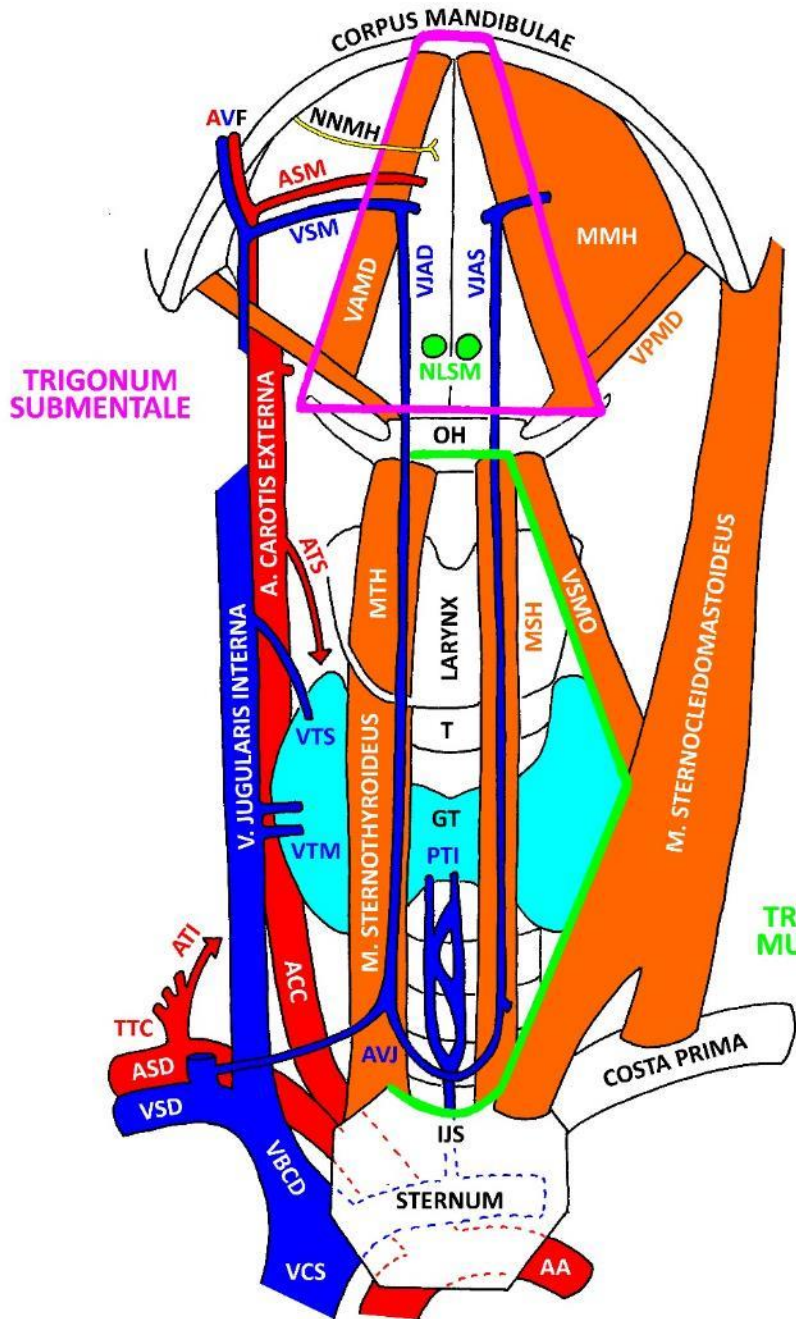
- **regio colli anterior**
 - trigonum submandibulare
 - trigonum submentale
 - trigonum caroticum (*Malgaignei*)
 - trigonum omotracheale = musculare
- **regio colli lateralis**
 - trigonum omoclaviculare
 - trigonum omotrpezium
 - fossa supraclavicularis minor
 - fissura scalenorum
 - trigonum scalenovertebrale



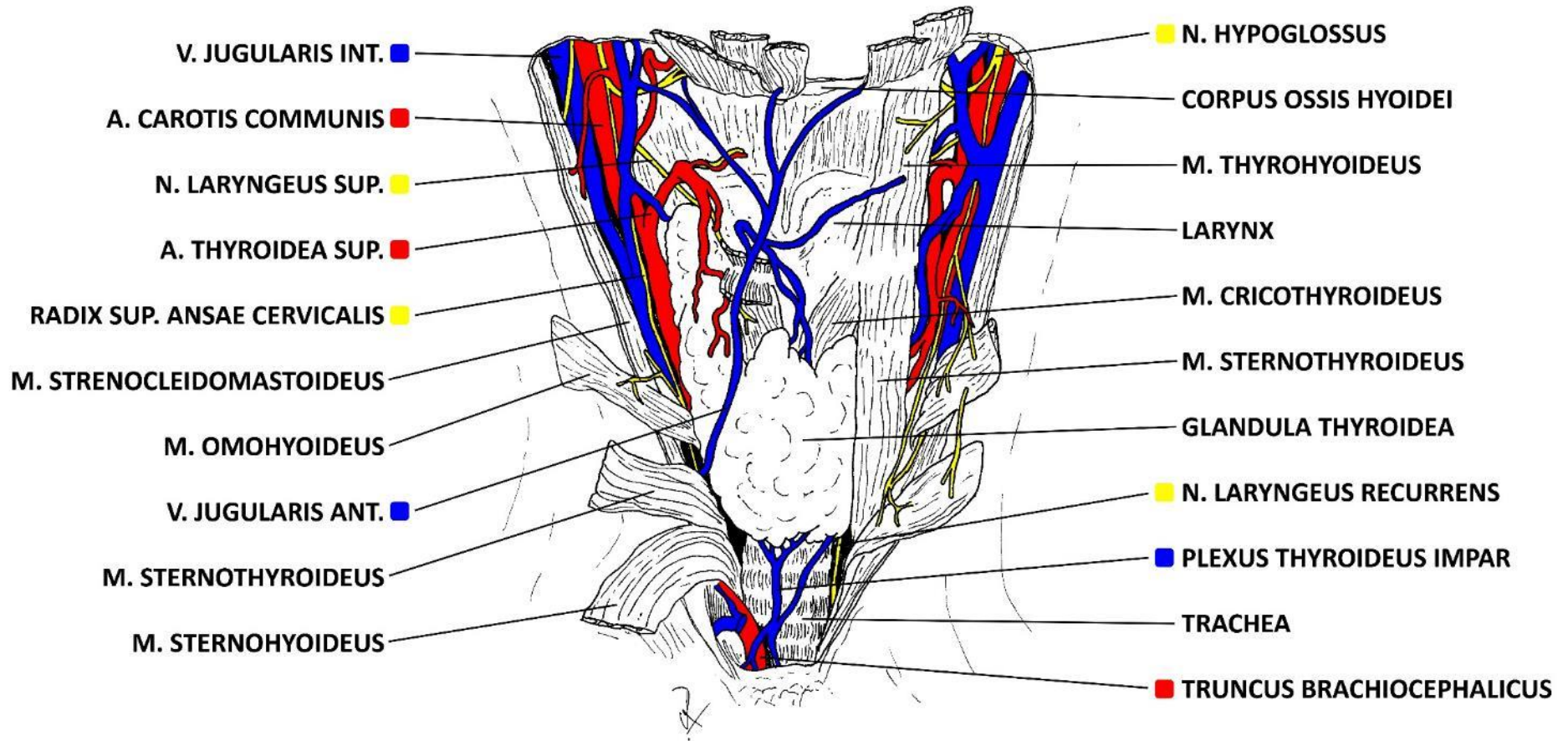
Obr. 14.1. Krajiny krční. 1 – regio submentalis, 2 – trigonum submandibulare, 3 – trigonum caroticum, 4 – trigonum omotrpezium, 5 – trigonum omoclaviculare, 6 – fossa supraclavicularis minor, 7 – m. omohyoideus, dolní bříško, 8 – m. trapezius, 9 – trigonum omotracheale, 10 – m. sternocleidomastoideus, 11 – m. digastricus

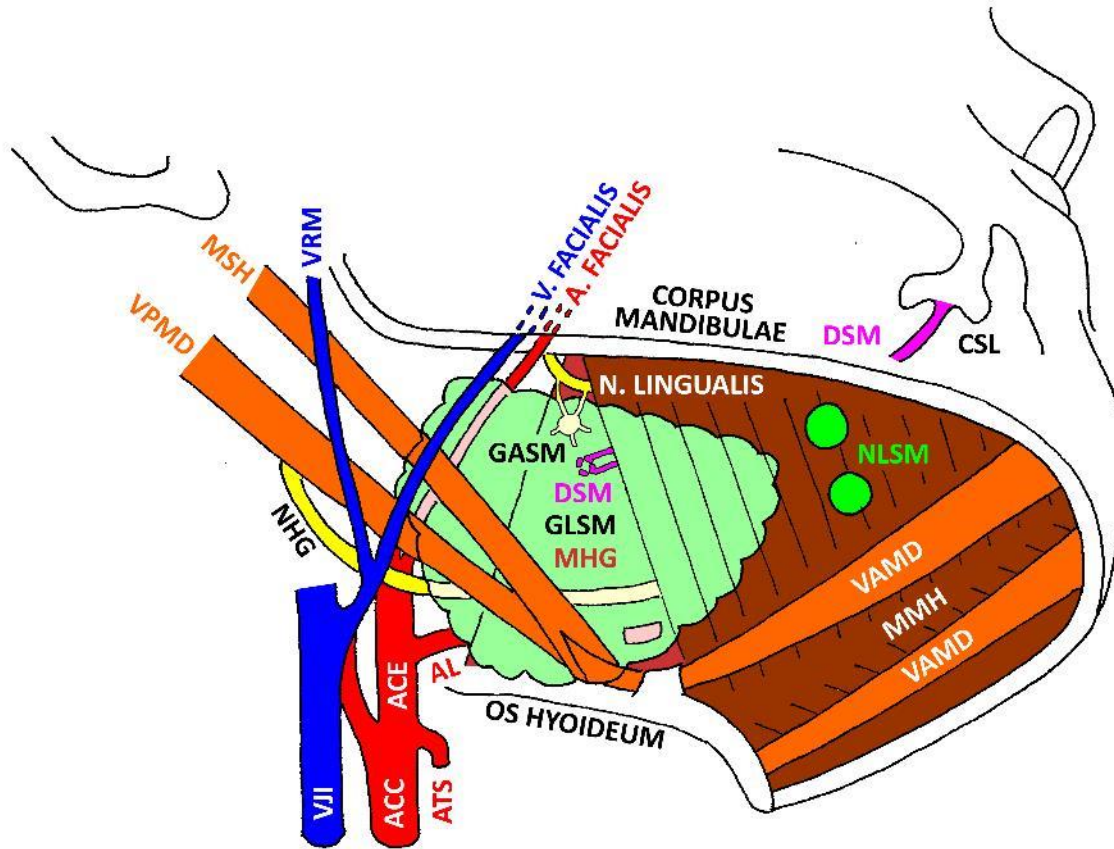


Obr. 14.1. Krajiny krční. 1 – regio submentalis, 2 – trigonum submandibulare, 3 – trigonum caroticum, 4 – trigonum omotracheum, 5 – trigonum omoclaviculare, 6 – fossa supraclavicularis minor, 7 – m. omohyoideus, dolní bříško, 8 – m. trapezius, 9 – trigonum omotracheale, 10 – m. sternocleidomastoideus, 11 – m. digastricus

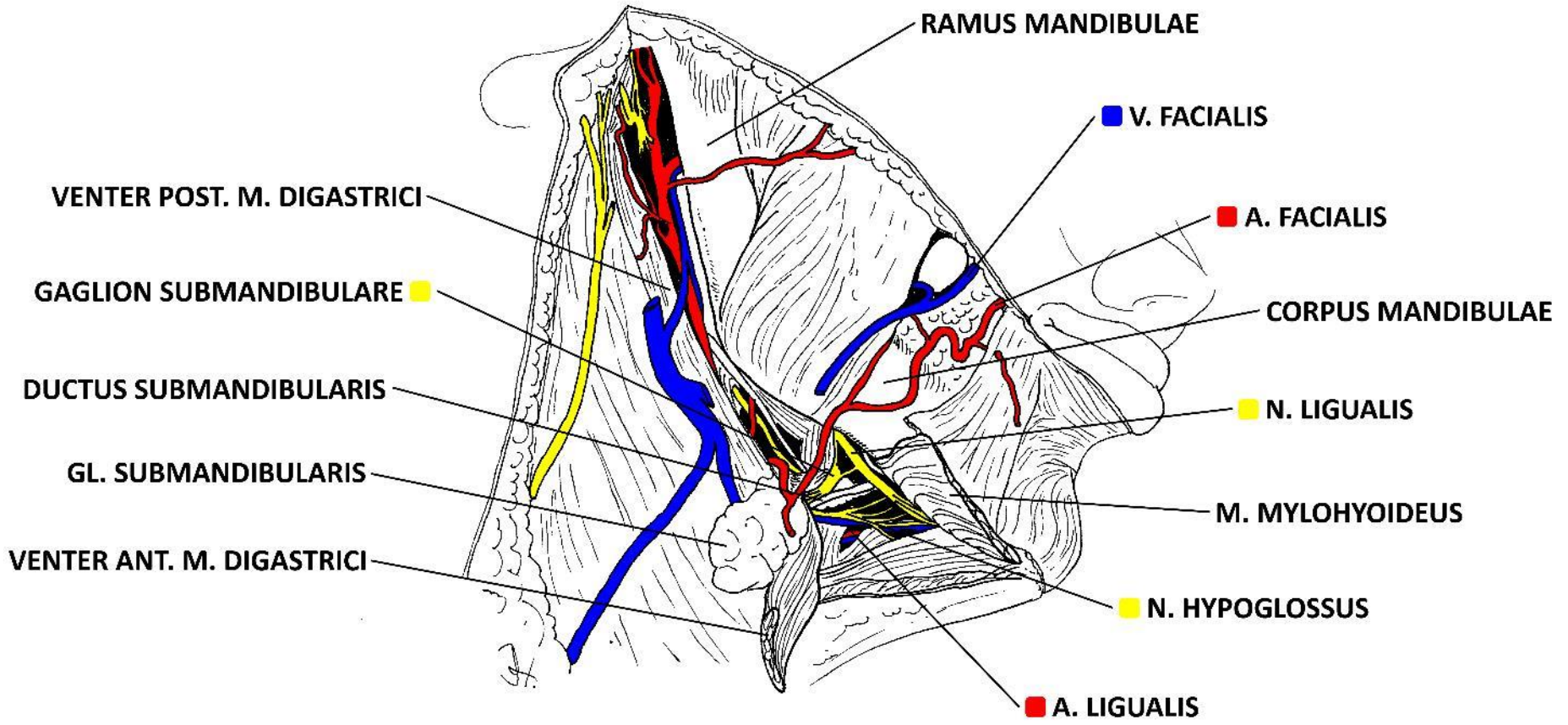


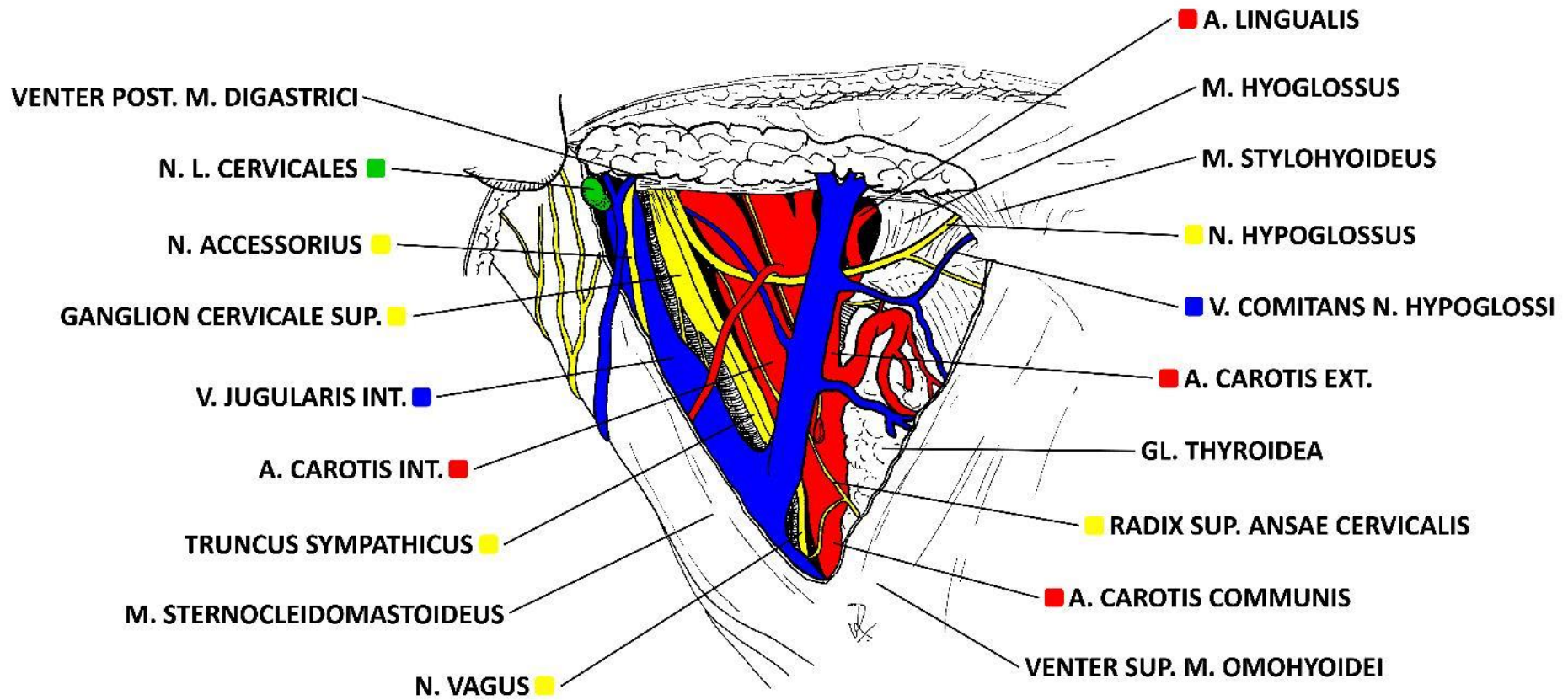
- AVF - A. ET V. FACIALIS
- NNMH - NN. MYLOHYOIDEI
- ASM - A. SUBMENTALIS
- VSM - V. SUBMENTALIS
- VAMD - VENTER ANT. M. DIGASTRICI
- VJAD - V. JUGULARIS ANT. DX.
- VJAS - V. JUGULARIS ANT. SIN.
- NLSM - N. L. SUBMENTALES
- MMH - M. MYLOHYOIDEUS
- VPMD - VENTER POST. M. DIGASTRICI
- OH - OS HYOIDEUM
- ATS - A. THYROIDEA SUP.
- MTH - M. THYROHYOIDEUS
- MSH - M. STERNOHYOIDEUS
- VSMO - VENTER SUP. M. OMOHYOIDEI
- T - TRACHEA
- VTS - V. THYROIDEA SUP.
- VTM - V. THYROIDEA MEDIA
- GT - GLANDULA THYROIDEA
- PTI - PLEXUS THYROIDEUS IMPAR
- ACC - A. CAROTIS COMMUNIS
- AVJ - ARCUS VENOSUS JUGULI
- IJS - INCISURA JUGULARIS STERNI
- ATI - A. THYROIDEA INF.
- TTC - TRUNCUS THYROCERVICALIS
- ASD - A. SUBCLAVIA DX.
- VSD - V. SUBCLAVIA DX.
- VBCD - V. BRACHIOCEPHALICA DX.
- VCS - V. CAVA SUP.
- AA - ARCUS AORTAE

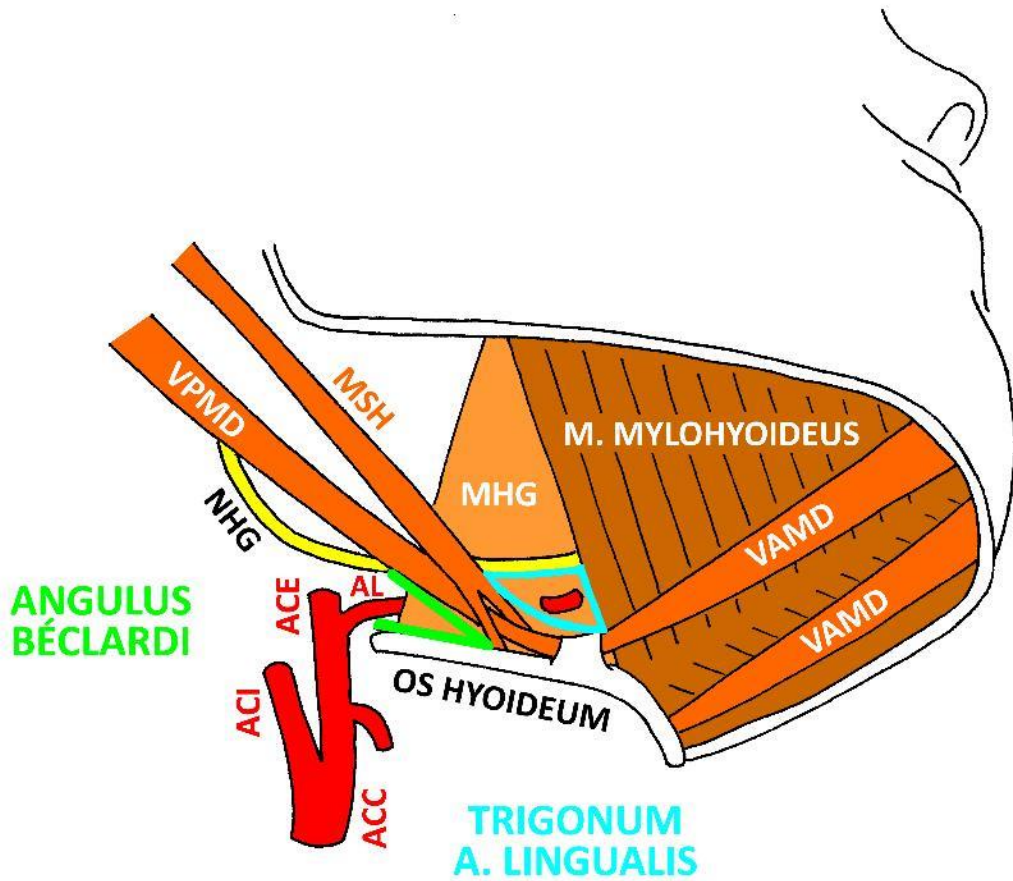




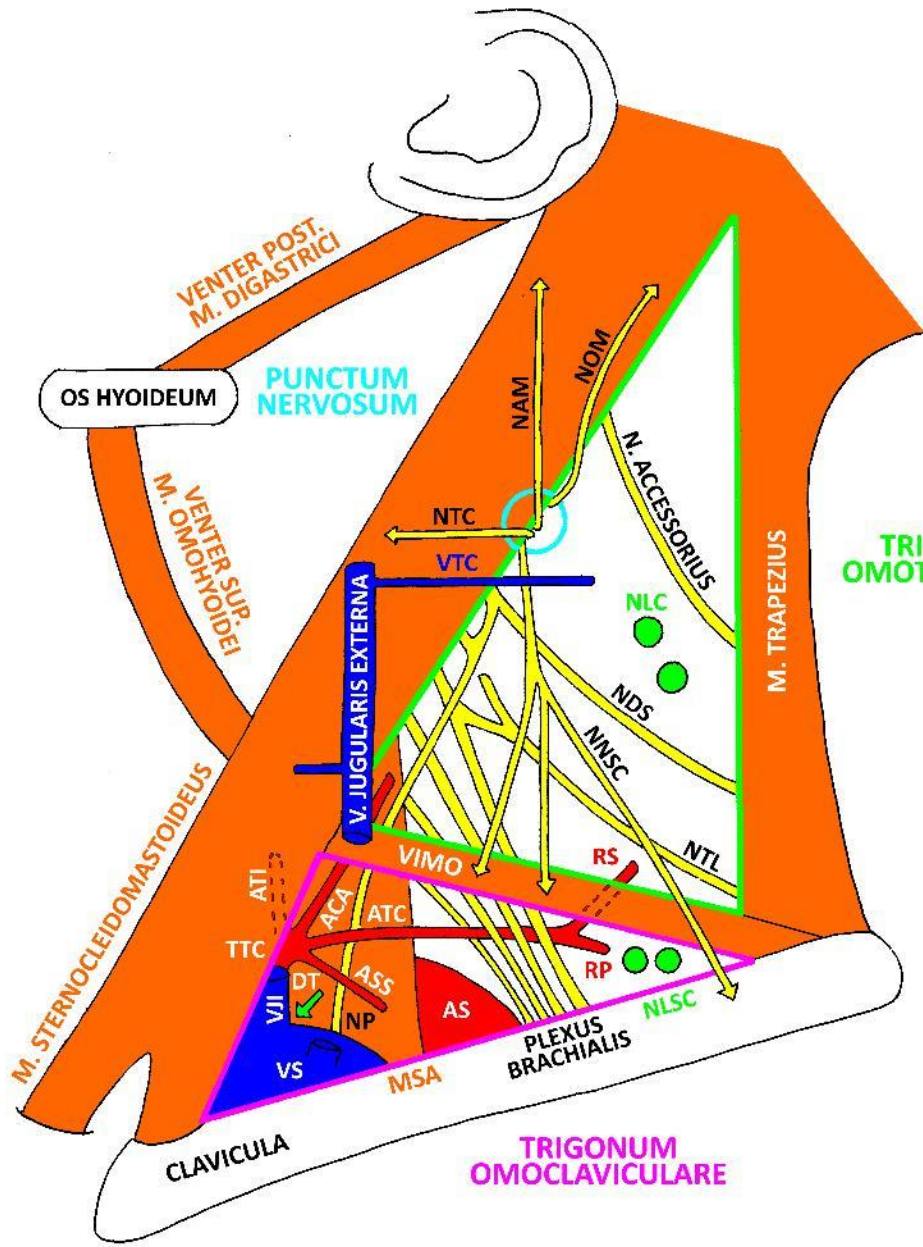
- VRM - V. RETROMANDIBULARIS**
- MSH - M. STYLOHYOIDEUS**
- VPMD - VENTER POST. M. DIGASTRICI**
- NHG - N. HYPOGLOSSUS**
- GASM - GANGLION SUBMANDIBULARE**
- DSM - DUCTUS SUBMANDIBULARIS**
- GLSM - GLANDULA SUBMANDIBULARIS**
- MHG - M. HYOGLOSSUS**
- AL - A. LIGUALIS**
- ACE - A. CAROTIS EXTERNA**
- VJI - V. JUGULARIS INTERNA**
- ACC - A. CAROTIS COMMUNIS**
- ATS - A. THYROIDEA SUP.**
- CSL - CARUNCULA SUBLINGUALIS**
- NLSM - N. L. SUBMANDIBULARES**
- VAMD - VENTER ANT. M. DIGASTRICI**
- MMH - M. MYLOHYOIDEUS**







VPMD - VENTER POST. M. DIGASTRICI
 NHG - N. HYPOGLOSSUS
 MSH - M. STYLOHYOIDEUS
 MHG - M. HYOGLOSSUS
 ACE - A. CAROTIS EXTERNA
 AL - A. LINGUALIS
 ACI - A. CAROTIS INTERNA
 ACC - A. CAROTIS COMMUNIS
 VAMD - VENTER ANT. M. DIGASTRICI

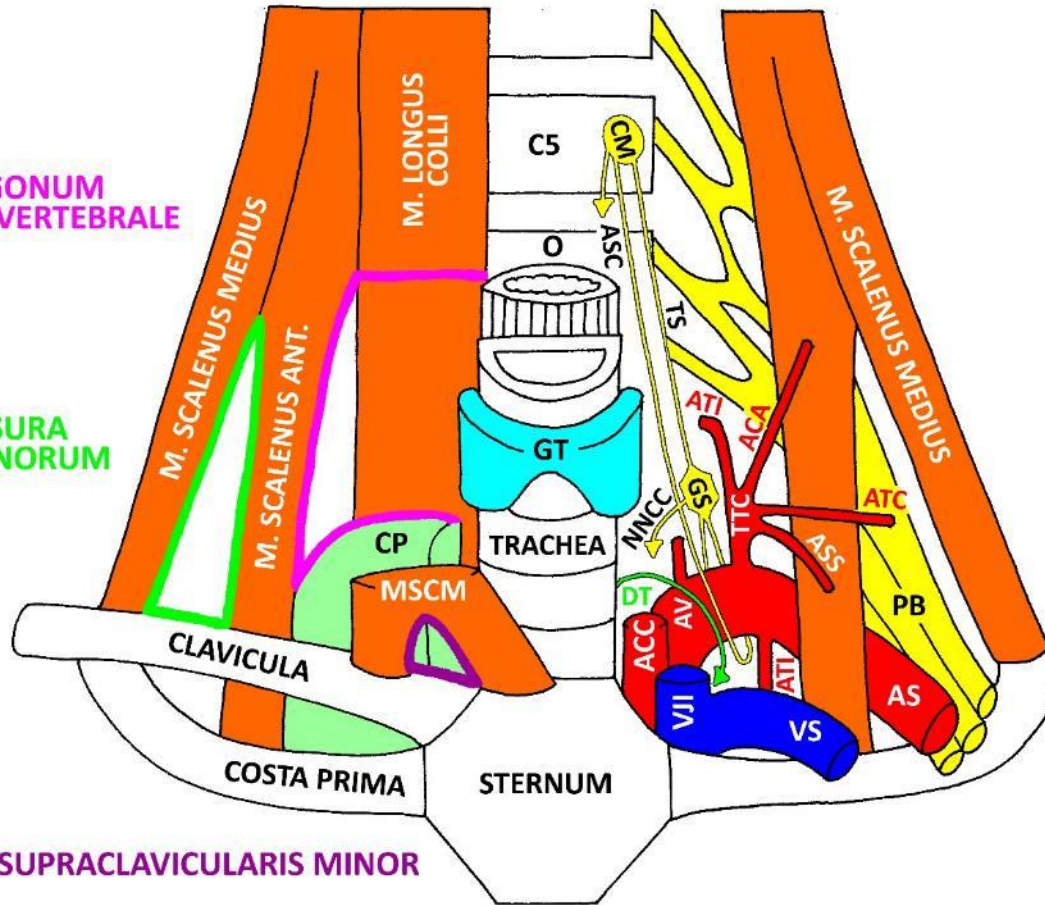


- NOM - N. OCCIPITALIS MINOR
- NAM - N. AURICULARIS MAGNUS
- NTC - N. TRANSVERSUS CERVICIS
- VTC - V. TRANSVERSA CERVICIS
- NLC - N. L. CERVICALES
- NDS - N. DORSALIS SCAPULAE
- NNSC - NN. SUPRACLAVICULARES
- NTL - N. THORACICUS LONGUS
- VIMO - VENTER INF. M. OMOHYOIDEI
- RS - R. SUPERFICIALIS (A. TRANSVERSAE CERVICIS)
- TTC - TRUNCUS THYROCERVICALIS
- ATI - A. THYROIDEA INF.
- ACA - A. CERVICALIS ASCENDENS
- ATC - A. TRANSVERSA CERVICIS
- RP - R. PROFUNDUS (A. TRANSVERSAE CERVICIS)
- ASS - A. SUPRASCAPULARIS
- VJI - V. JUGULARIS INTERNA
- DT - DUCTUS THORACICUS
- VS - V. SUBCLAVIA
- NP - N. PHRENICUS
- AS - A. SUBCLAVIA
- MSA - M. SCALENUS ANT.
- NLSC - N. L. SUPRACLAVICULARES

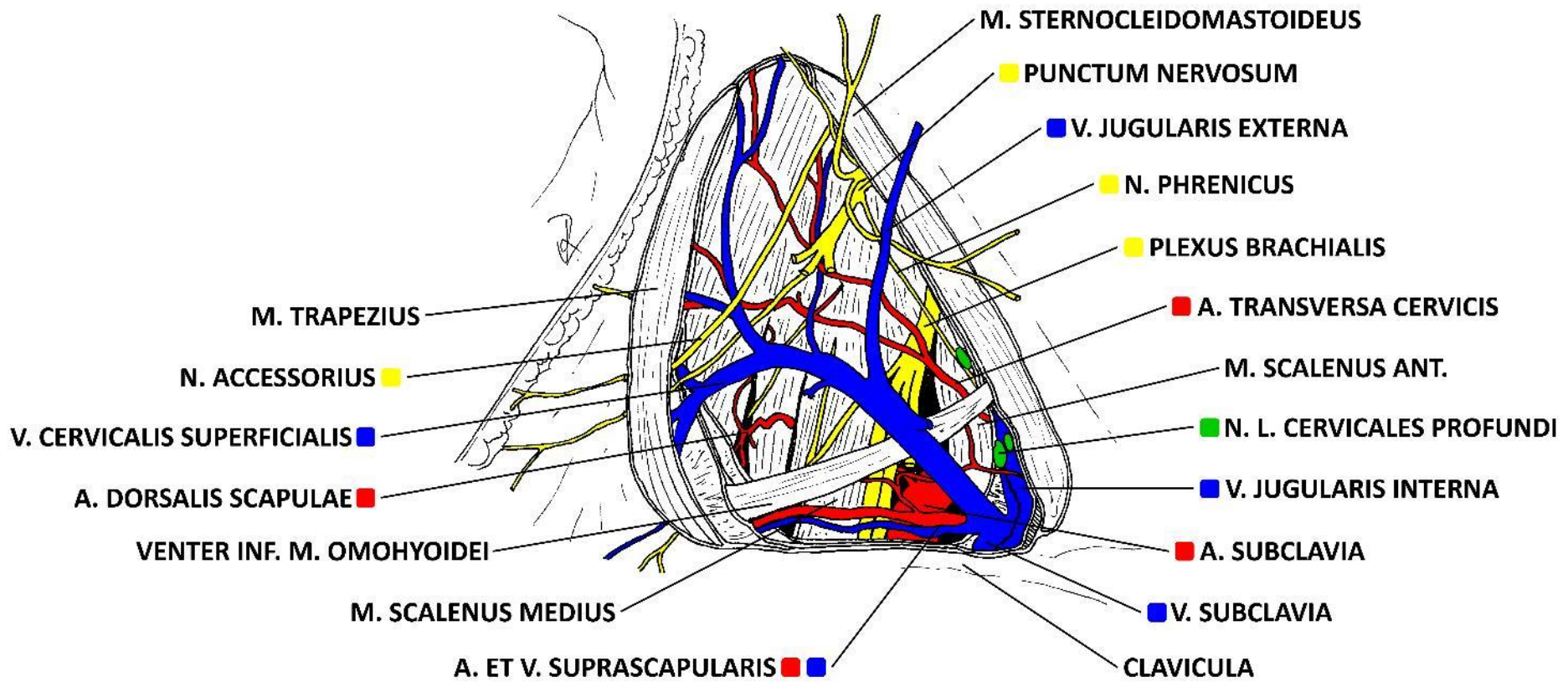
**TRIGONUM
SCALENOVERTEBRALE**

**FISSURA
SCALENORUM**

FOSSA SUPRACLAVICULARIS MINOR



- CM - GANGLION CERVICALE MEDIUM
- O - OESOPHAGUS
- ASC - ANSA SUBCLAVIA
- TS - TRUNCUS SYMPATHICUS
- GT - GLANDULA THYROIDEA
- NNCC - NN. CARDIACI CERVICALES
- GS - GANGLION STELLATUM
- TTC - TRUNCUS THYROCERVICALIS
- ATI - A. THYROIDEA INF.
- ACA - A. CERVICALIS ASCENDENS
- ATS - A. TRANSVERSA CERVICIS
- ASS - A. SUPRASCAPULARIS
- CP - CUPULA PLEURAE
- MSCM - M. STERNOCLEIDOMASTOIDEUS
- DT - DUCTUS THORACICUS
- ACC - A. CAROTIS COMMUNIS
- VJI - V. JUGULARIS INTERNA
- AV - A. VERTEBRALIS
- ATI - A. THORACICA INTERNA
- VS - V. SUBCLAVIA
- AS - A. SUBCLAVIA
- PB - PLEXUS BRACHIALIS

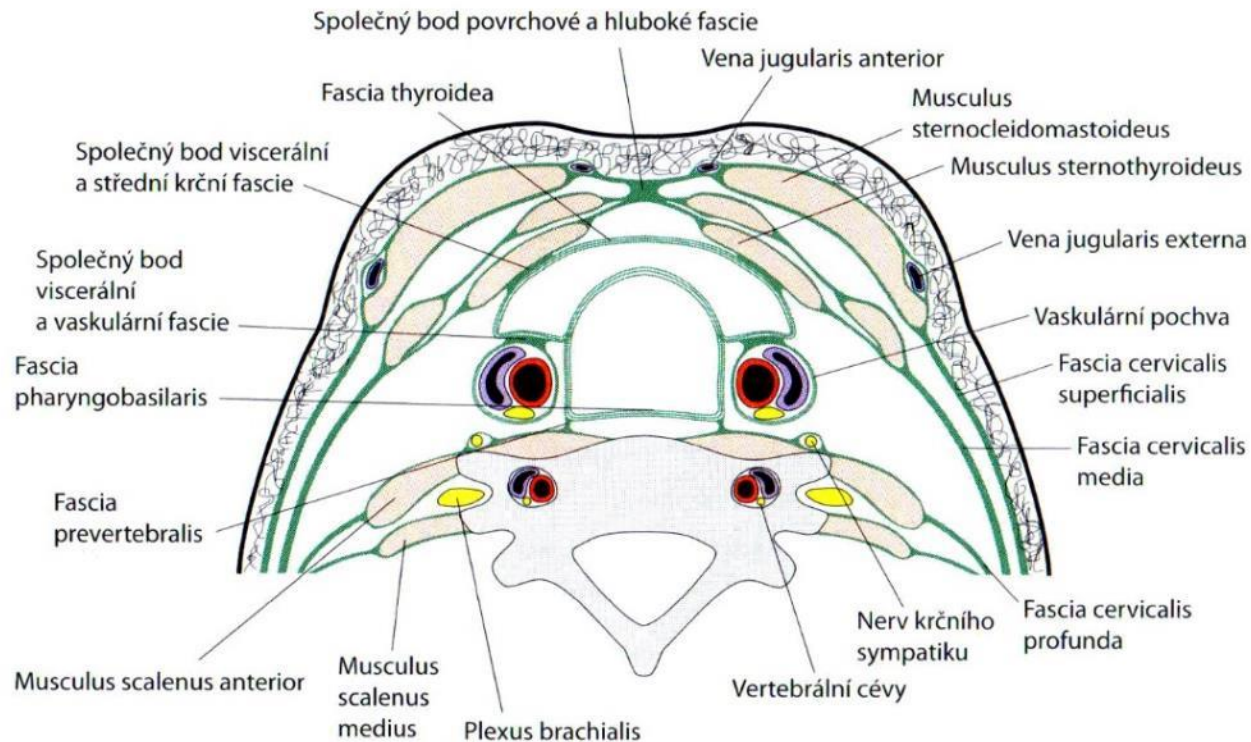


Superficial fascia of neck

- contains m. platysma
- fuses with the deep one in linea alba cervicis and lig. nuchae
- on face it fuses with SMAS and with m. risorius
 - thin, vascular
 - ventrally and dorsally continues into facial muscles, cranially into galea aponeurotica, caudally to SMAS
 - contains vasa temporalia superficialia and n. auriculotemporalis
- SMAS
 - envelops majority of facial muscles
 - „central tendon of fascial muscles“
 - fibro-elastic (600 μm)
 - get thinner from center to periphery
 - in regio parotideomasseterica adheres to the deep fascia (due to missing deep adipose layer)
- superficial adipose layer is thin

Deep fascia of neck

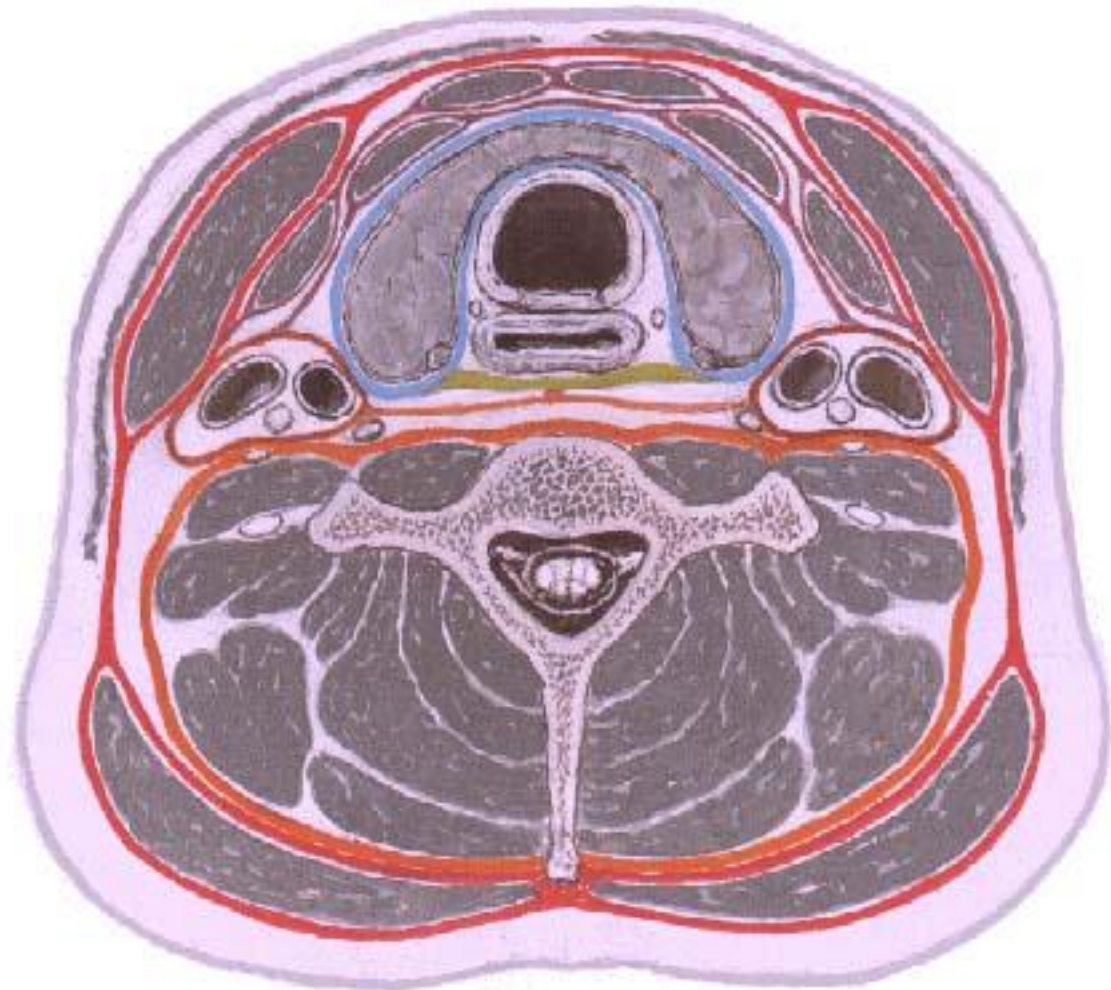
- 3-layered, envelops cervical muscles
- especially m. trapezius is firmly envelopped



Fascia cervicalis – 3 laminae

old concept

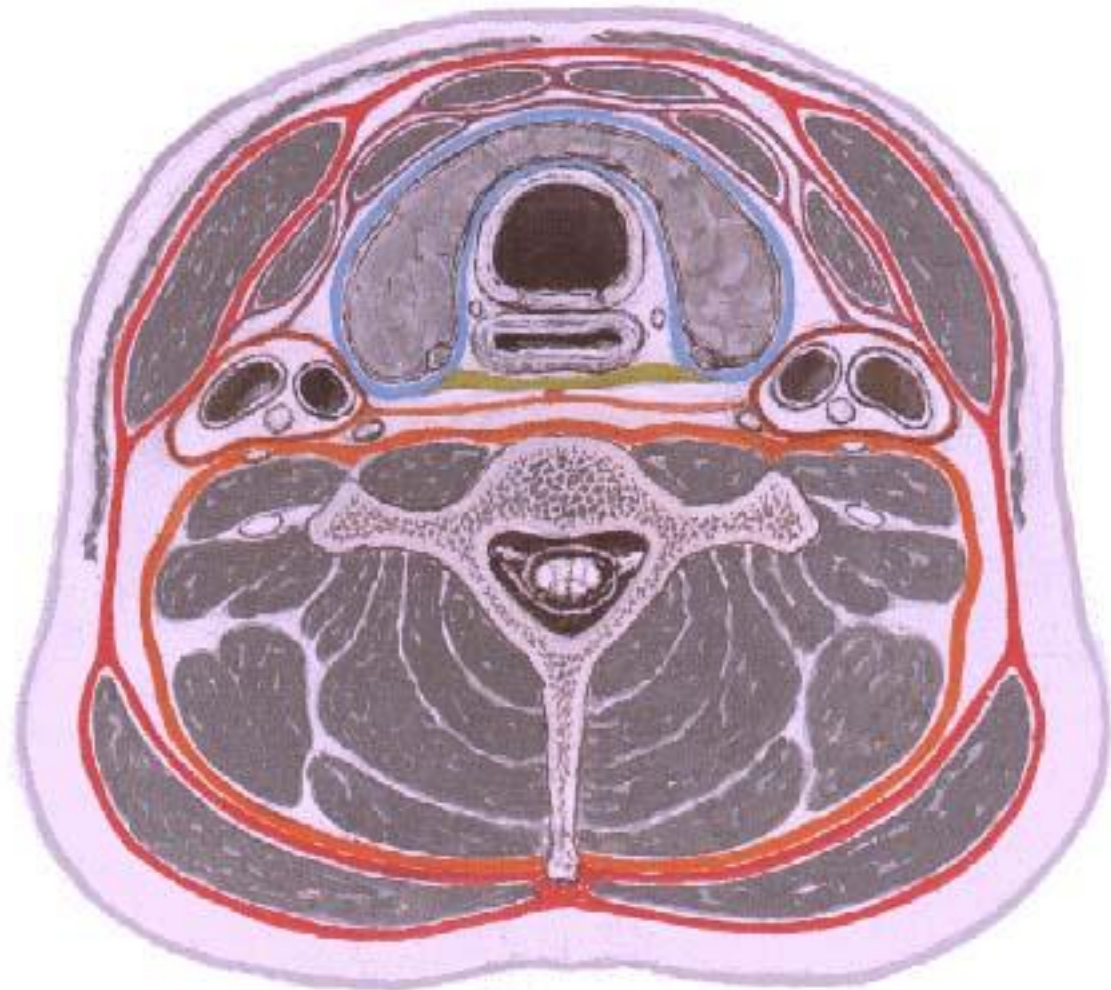
- lamina superficialis
- lamina pretrachealis
 - vagina carotica
- lamina prevertebralis



Fascia cervicalis – 3 laminae

new concept

- lamina superficialis
- lamina media
 - vagina carotica
 - fascia intercarotica
- lamina pretrachealis
- lamina buccopharyngea
- lamina prevertebralis

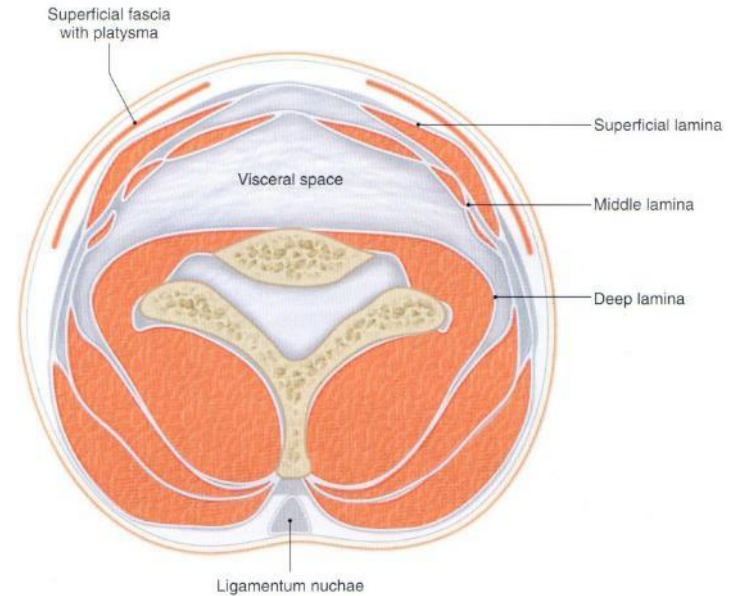


Spaces in neck

- spatium previscerale
- spatium paraviscerale
- spatium retroviscerale

continues:

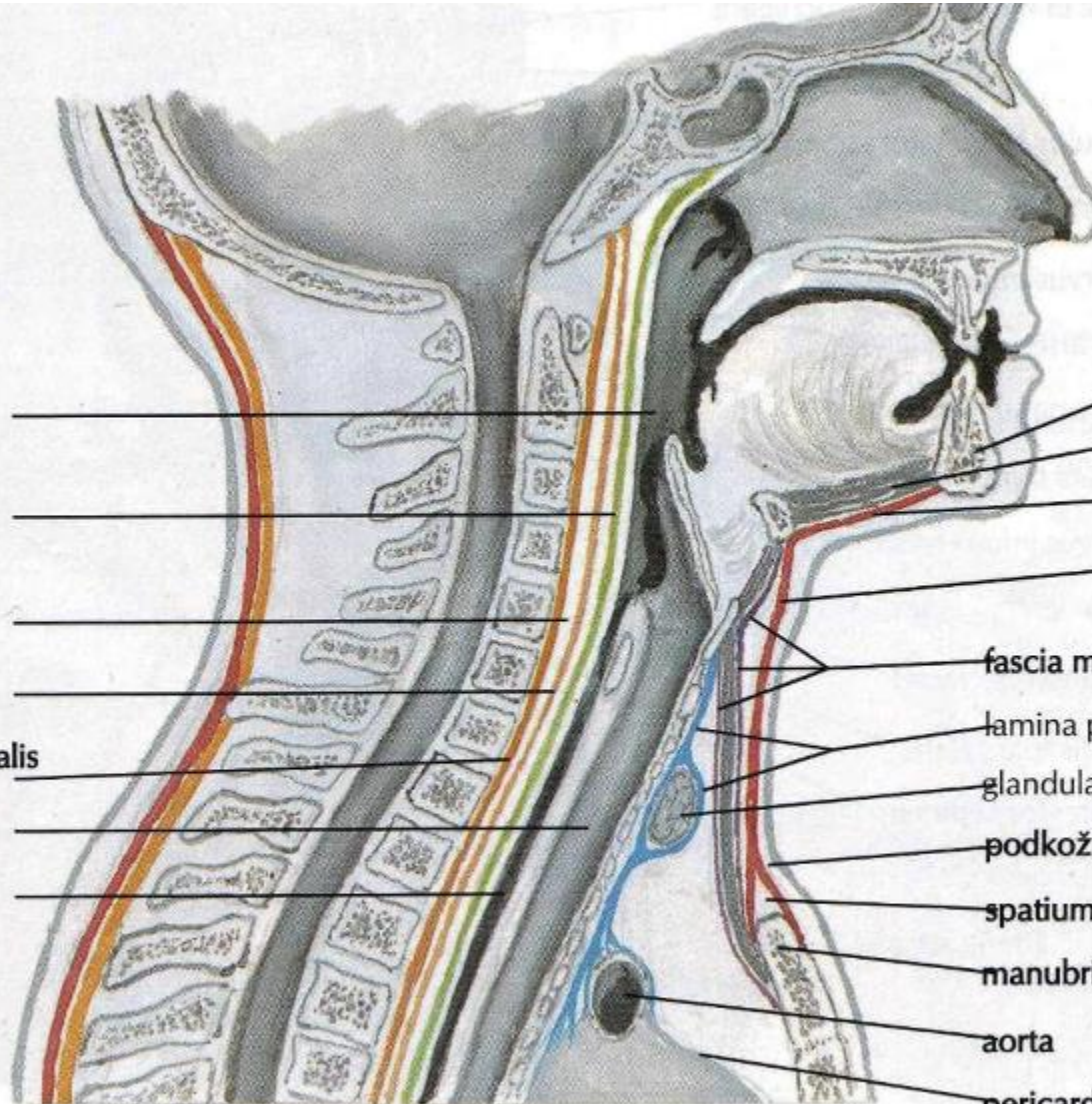
- cranially: spatium parapharyngeum
spatium retropharyngeum
- caudally: spatium suprasternale
mediastinum superius



Spaces in neck

sagitální řez

pharynx
fascia
buccopharyngea
retrofaryngeální
prostor
fascia alaris
lamina prevertebralis
fasciae cervicalis
trachea
oesophagus



mandibula
musculus geniohyoideus
fascia musculi geniohyoidei
lamina superficialis fasciae cervicalis
fascia musculi infrahyoidei
lamina pretrachealis fasciae cervicalis
glandula thyroidea
podkožní vazivo
spatium suprasternale
manubrium sterni
aorta
pericardium

Septum styloideum („Riolan's bouquet“)

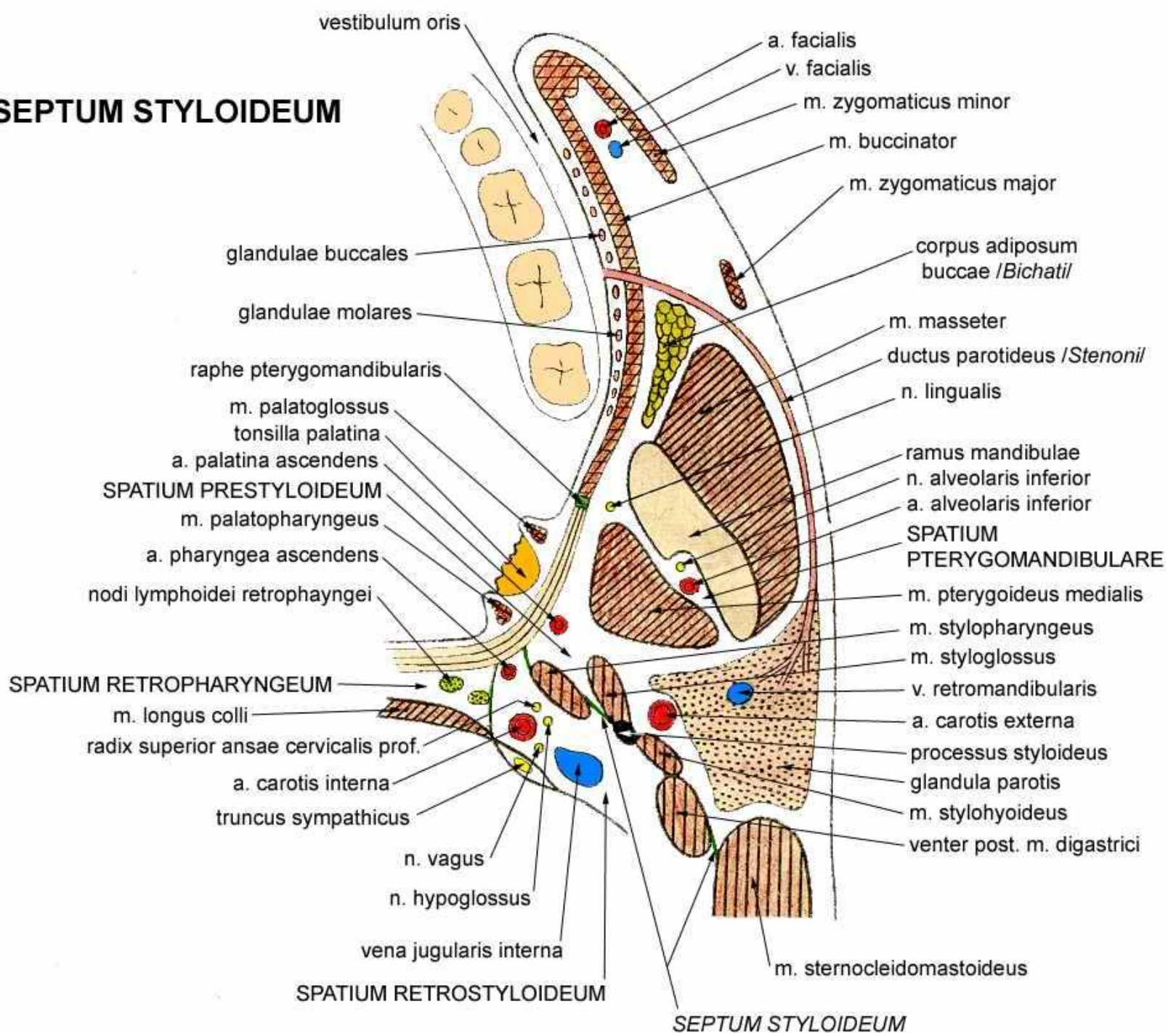
muscular septum envelopped with fascia

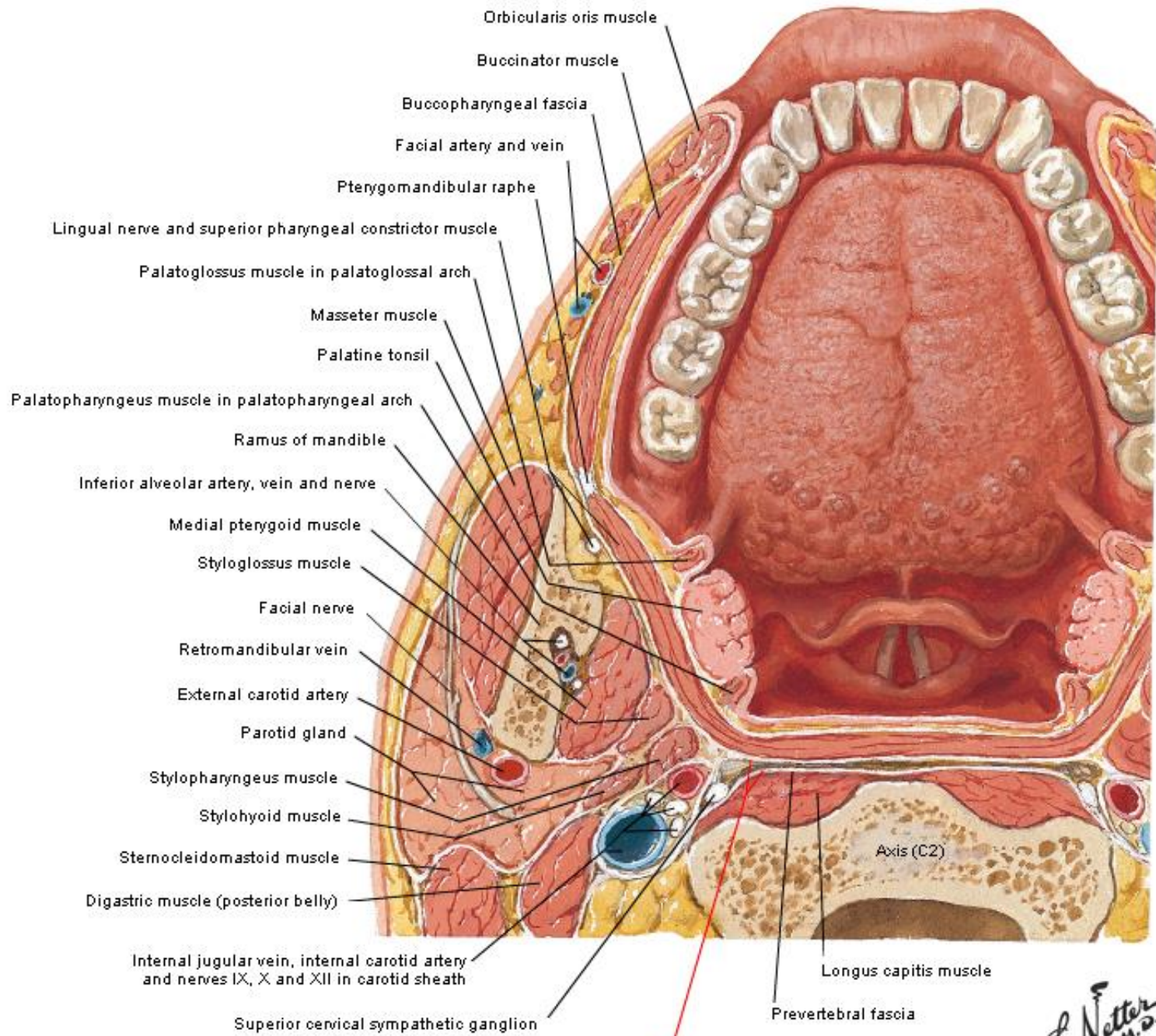
divides the cranial part of spatium parapharyngeum
into spatium pre- + retrostyloideum

terminates approximately at the line connecting
processus styloideus and cornu majus ossis hyoidei

- m. stylopharyngeus
- m. styloglossus
- m. stylohyoideus + lig. stylohyoideum
- venter posterior m. digastrici
- m. sternocleidomastoideus

SEPTUM STYLOIDEUM





Buccopharyngeal fascia and retropharyngeal space