

Visual system 2 and accessory visual structures

Organum visuale et structurae oculi accessoriae

David Kachlík

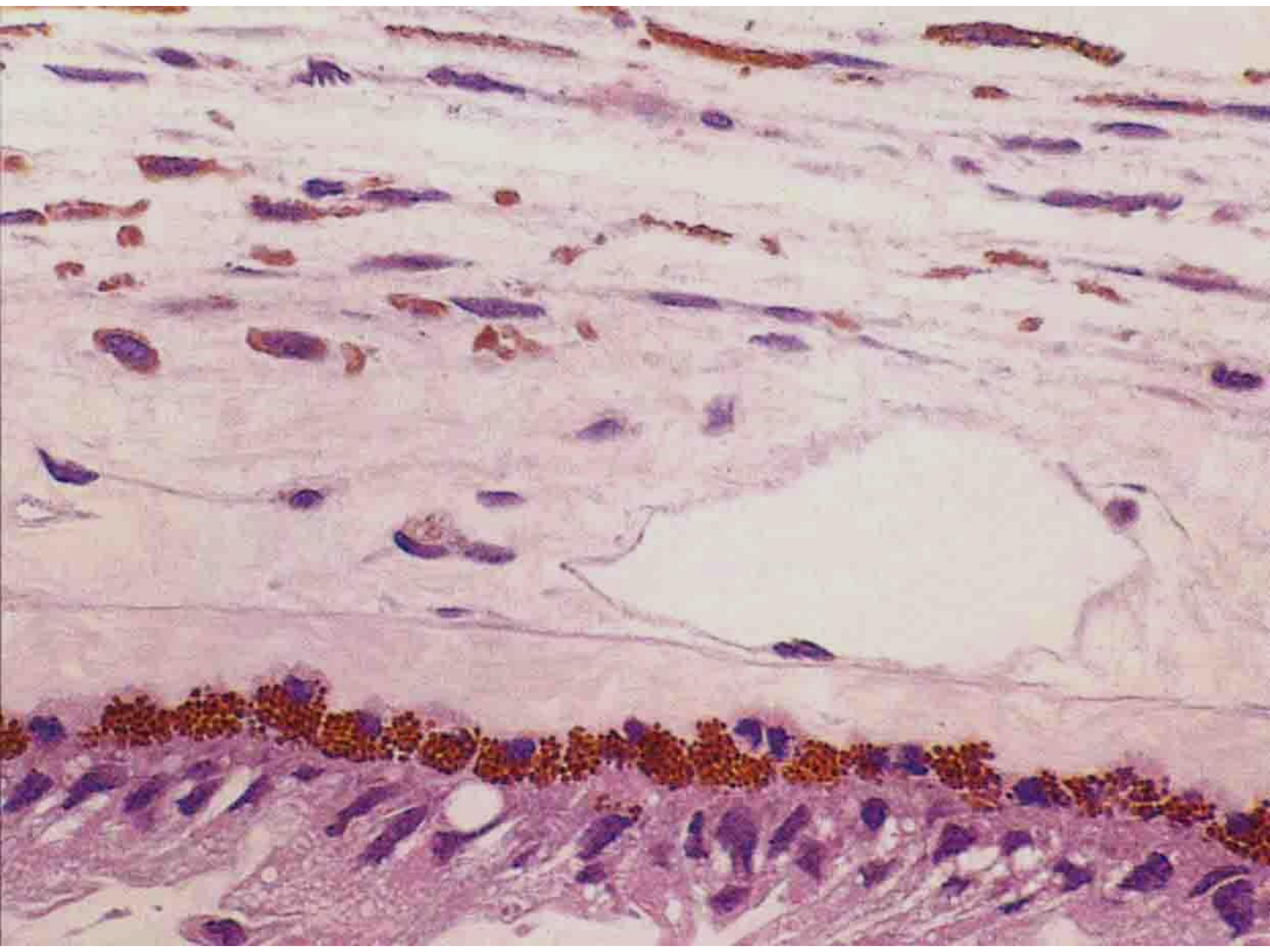
Tunica interna (nervosa)

Retina

- pars caeca
 - pars iridica
 - pars ciliaris
- ora serrata
- pars optica – 10 layers
 - pigmented part
 - sensory part

Retina – pigmented part

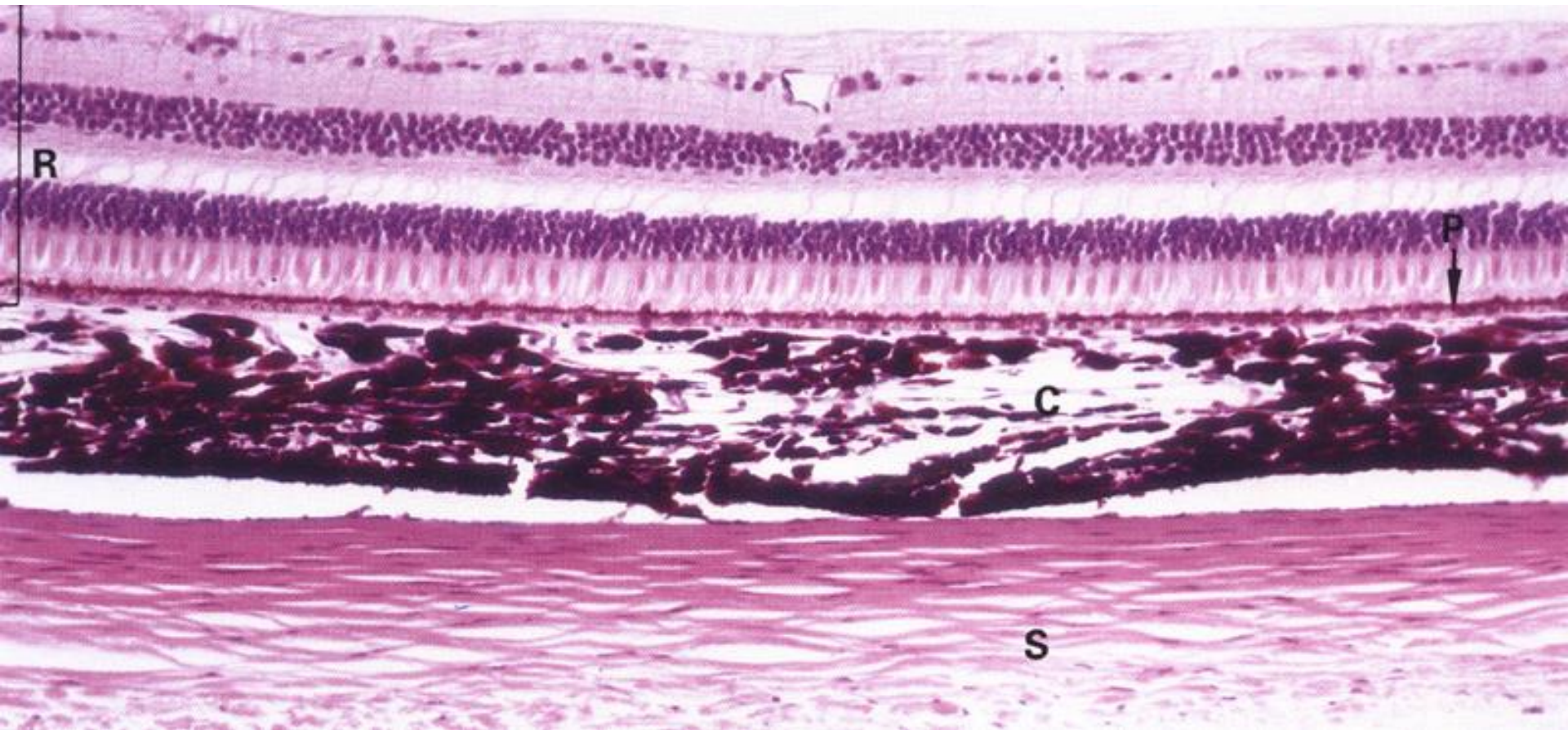
- *stratum pigmentosum*
- simple cuboid epithelium on basal lamina = Bruch's membrane
- cells (*pigmentocytus*) connected by tight junctions
- apical parts contain melanin granules
- microvilli separate the outer segments of rods and cones
- interphotoreceptor matrix (IRBP)
- *nutrition of rods and cones, photopigment resynthesis, degradation of membranous discs, barrier „blood-retina“*



Retina – sensory part

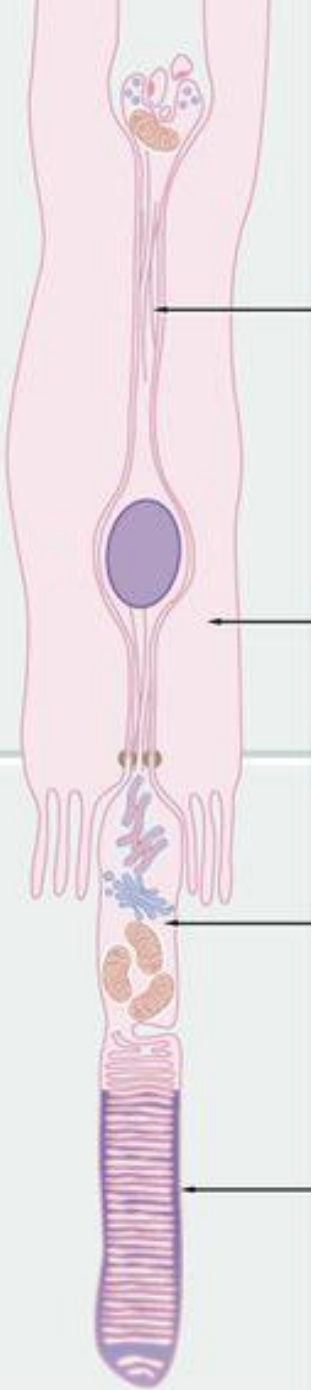
- light-sensitive neurons (transducers)
 - rods and cones
- transmission neurons (integrators)
 - bipolar and ganglionic cells
- association neurons
 - horizontal and amacrine cells
- supporting cells (glia)
 - radial glial cells (Müller's cells)

Section of eyeball layers



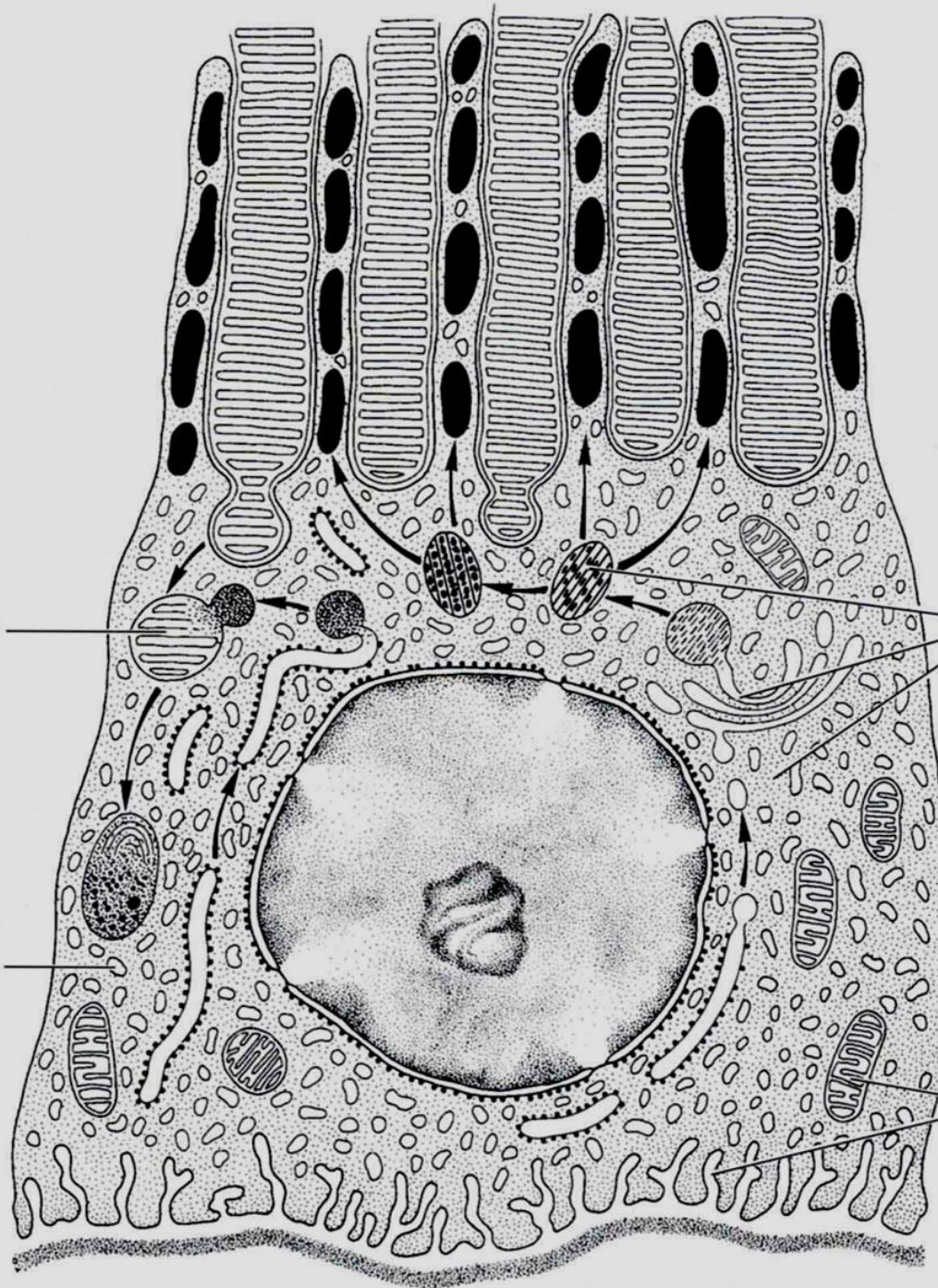
Rods = *Neura bacillifera*

- rod = *bacillum retinae*
- spherula – synaptic terminal
- axonal process
- nucleus ***black-abd-white vision***
- inner segment
 - GA, ER, MIT; synthesis of ATP and rhodopsin
 - myoideum (glycogen) + ellipsoideum (mitochondria)
- connecting cilium (*cilium connectens*) – modified cilium
- outer segment (*segmentum externum*)
 - membranous discs with photopigment
 - migrate externally and are released



Digestion, by lysosomal enzymes, of photo-receptor fragments phagocytized by pigment epithelial cells.

Vitamin A transport and esterification in SER.

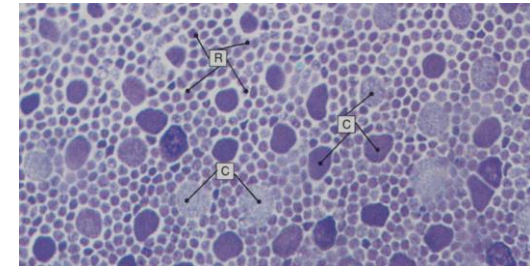
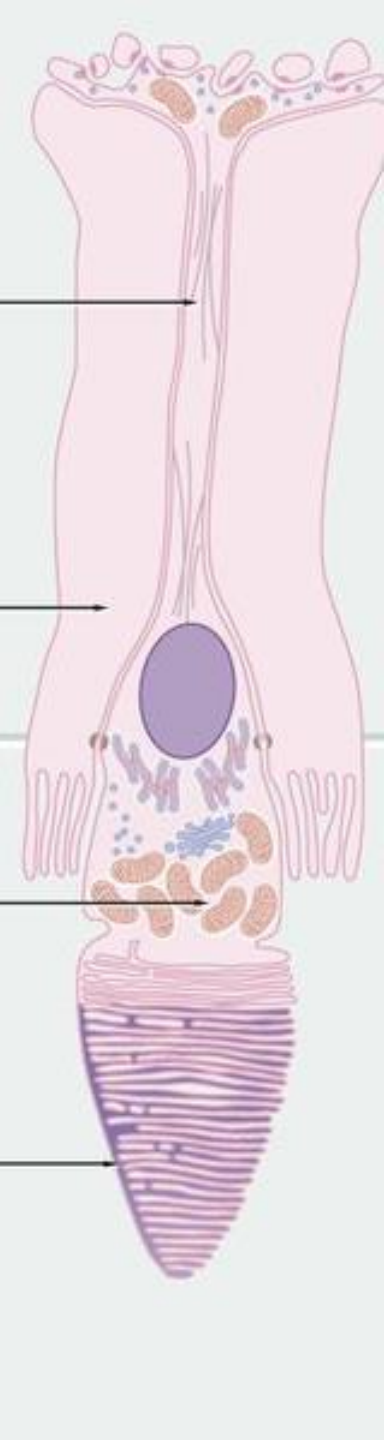


Synthesis of melanin by RER, Golgi apparatus and melanosomes. Melanin absorbs light after it has sensitized the receptor.

Ion transport by mitochondria and membrane invaginations.

Cones = Neuron coniferum

- cone = *conus retinae*
- synaptic pedicle (*pes terminalis*)
- photopigment is iodopsin
- outer segment
 - membranous discs with photopigment
 - communicate with surroundings
- *color vision* – 3 types of cones – according to wave-length
 - „blue“ – 420 nm – type S
 - „green“ – 535 nm – type M
 - „red“ – 565 nm – type L



Retina – Transmission neurons

- **Bipolar** neurons (*Neuron bipolare*)
 - rod bipolar neurons (*n.b. bacillotropicum*)
 - cone bipolar neurons (*n.b. conotopicum*)
 - midget (*n.b.c. nanum*) – macula lutea (no convergence = 1 : 1 : 1)
 - diffuse (*n.b.c. diffusum*) – convergence of signal
 - contact with retinal ganglion cells
- **Retinal ganglion** cells (*N. ganglionare multipolare*)
 - diffuse (*n.g.m. umbelliforme*) – connect more bipolar neurons
 - midget (*n.g.m. nanum*) – connect with midget bipolar neurons
 - their axons form the nervus opticus

Retina – Association neurons

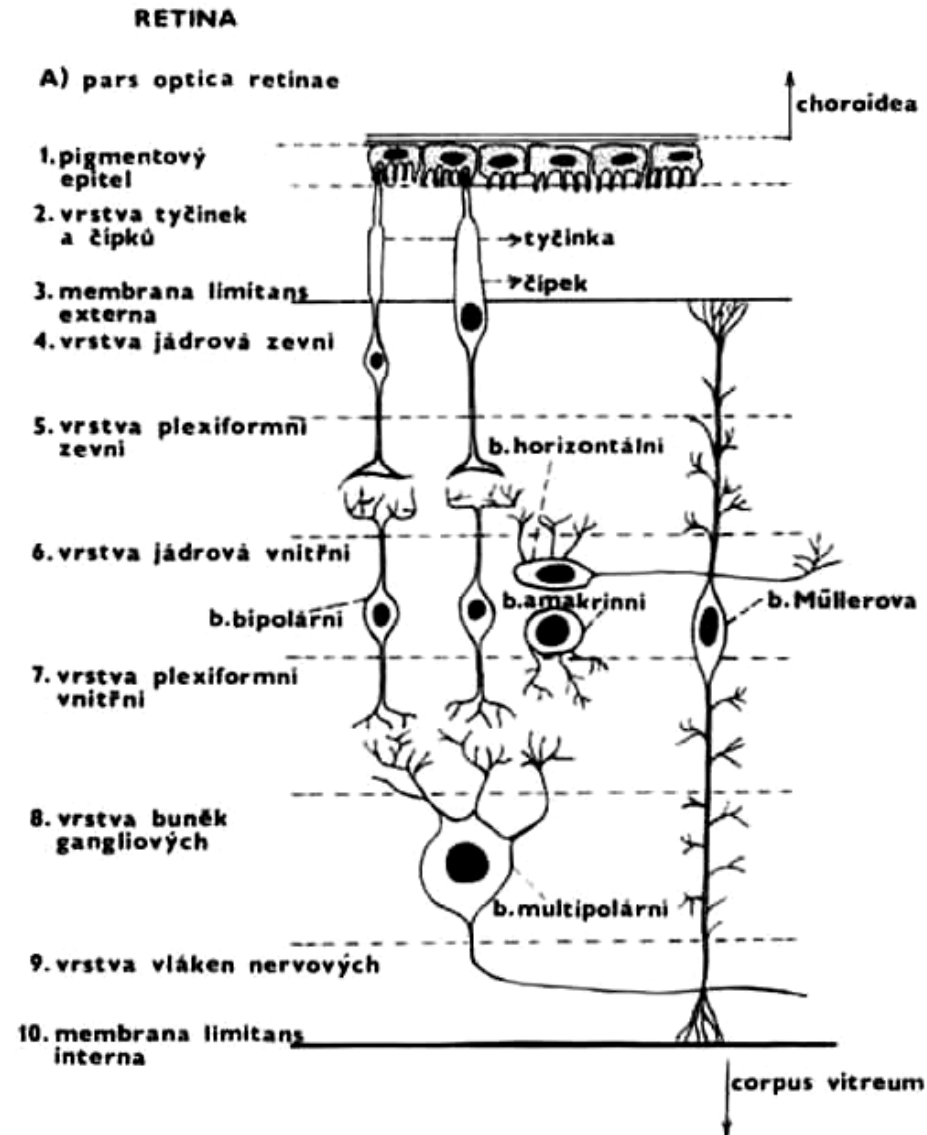
signal modification and synchronization

- **Horizontal** neurons (*N. horizontale*)
 - connections with axons of rods and cones and with dendrites of bipolar neurons
 - integrate rods and cones of adjacent areas
 - suppress signals from less lit areas
- **amacrine** cells (*N. amacrinum*)
 - no axon!
 - connections with axons of bipolar cells and with dendrites of retina ganglion cells
 - remove noise

Retina – Supporting cells

- **Radial glial (Müller's) cells (*gliocytus radialis*)**

- makroglia
- extend through whole thickness of retina
- processus radiales
- their own BL = stratum limitans internum
- zonulae adherentes with rods and cones = stratum limitans externum



Tunica sensoria (interna)

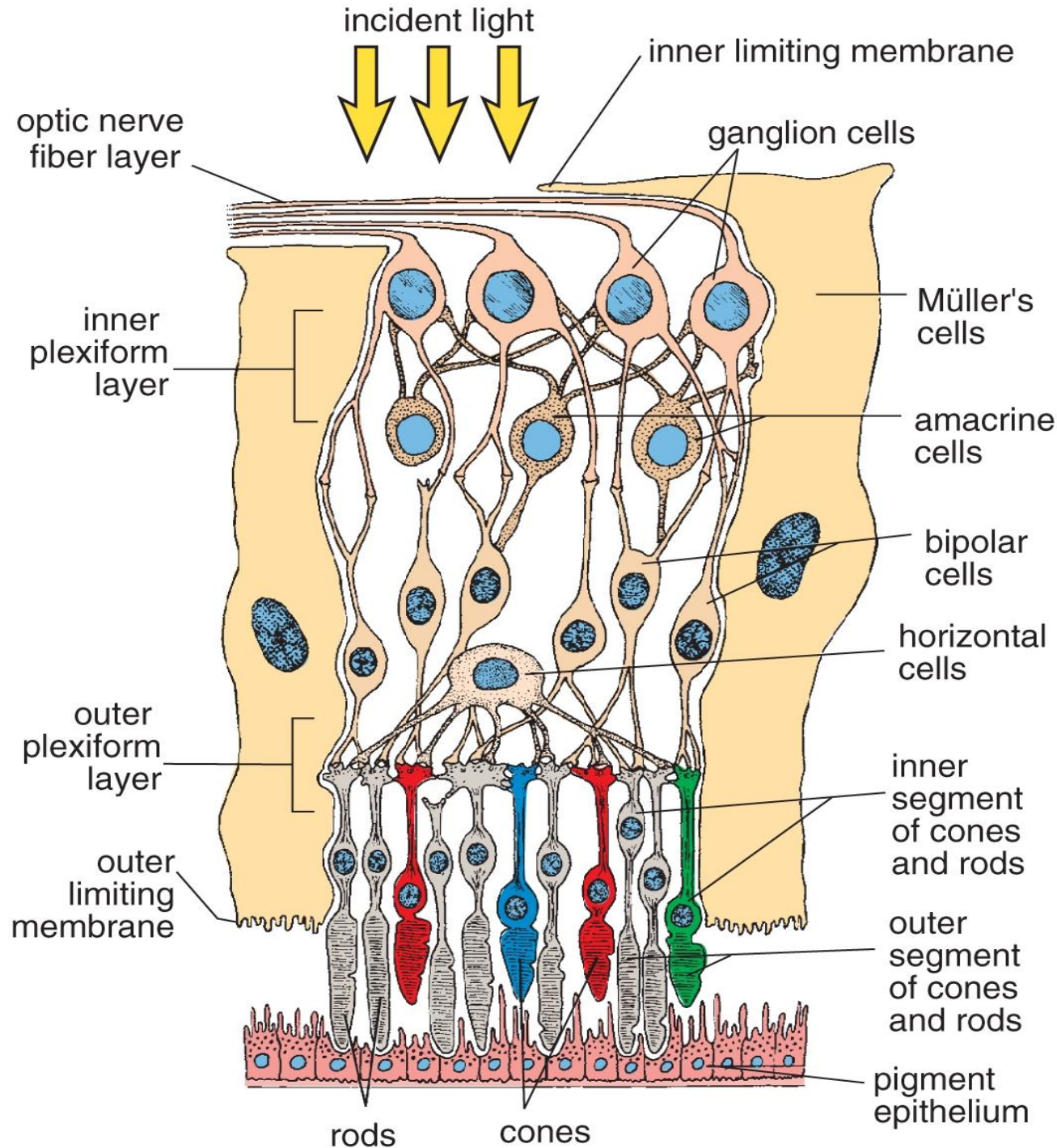
Layer of sensory part

- 10 layer

!!! 😊 do not worry 😊 !!!

- retinal OCT shows 14 layers

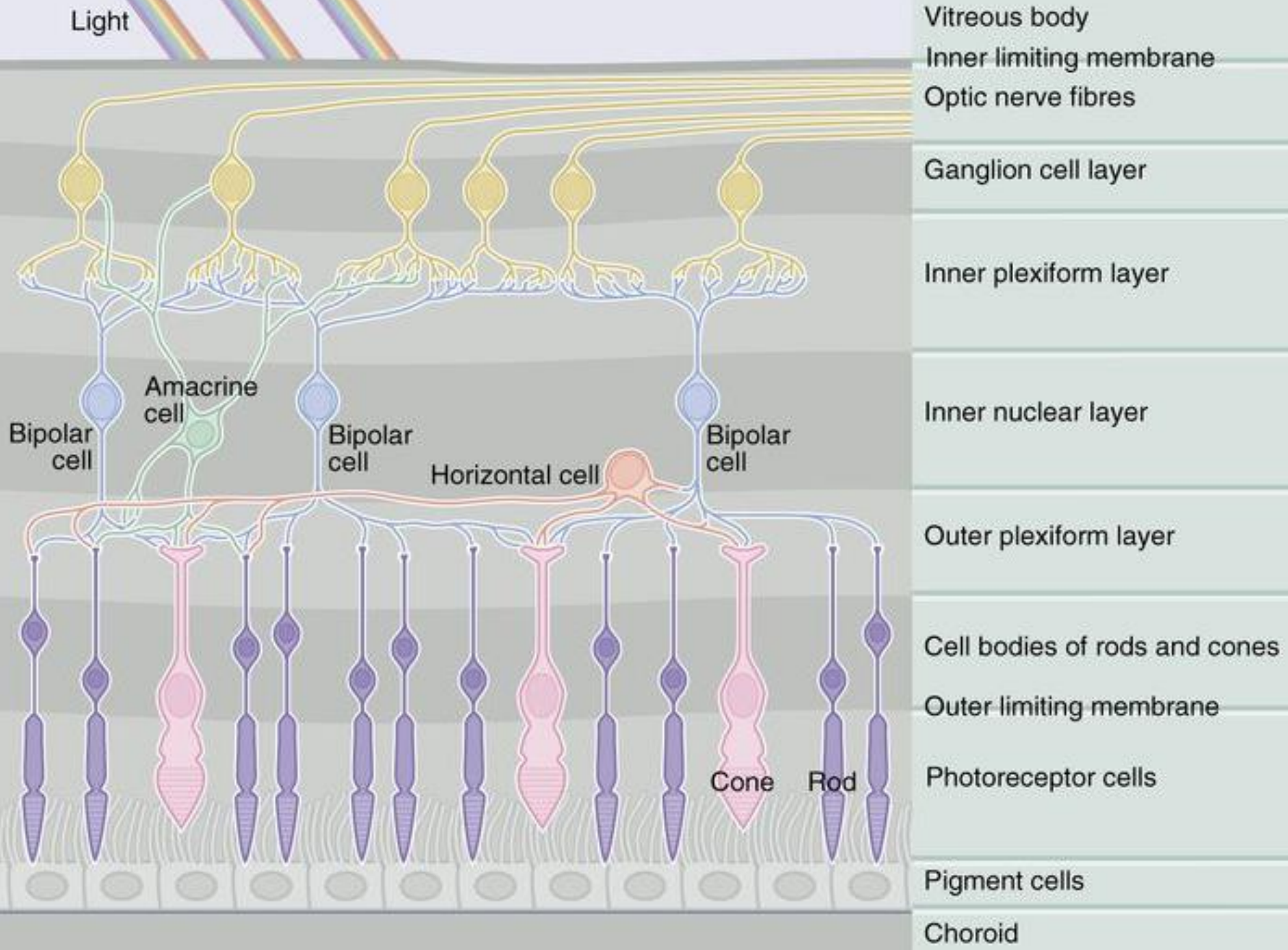
- *whole eyeball OCT shows 18 layers*



Tunica sensoria (interna)

Layers of sensory part of retina

- stratum pigmentosum (1.)
- stratum nervosum (2.-10.)
 - stratum segmentorum externorum et internorum(2.)
 - stratum limitans externum (3.)
 - stratum nucleare externum (4.)
 - stratum plexiforme externum (5.)
 - stratum nucleare internum (6.)
 - stratum plexiforme internum (7.)
 - stratum ganglionicum (8.)
 - stratum neurofibrarum (9.)
 - stratum limitans internum (10.)



Light

Vitreous body
 Inner limiting membrane
 Optic nerve fibres

Ganglion cell layer

Inner plexiform layer

Inner nuclear layer

Bipolar cell
 Amacrine cell
 Horizontal cell
 Bipolar cell

Outer plexiform layer

Cell bodies of rods and cones

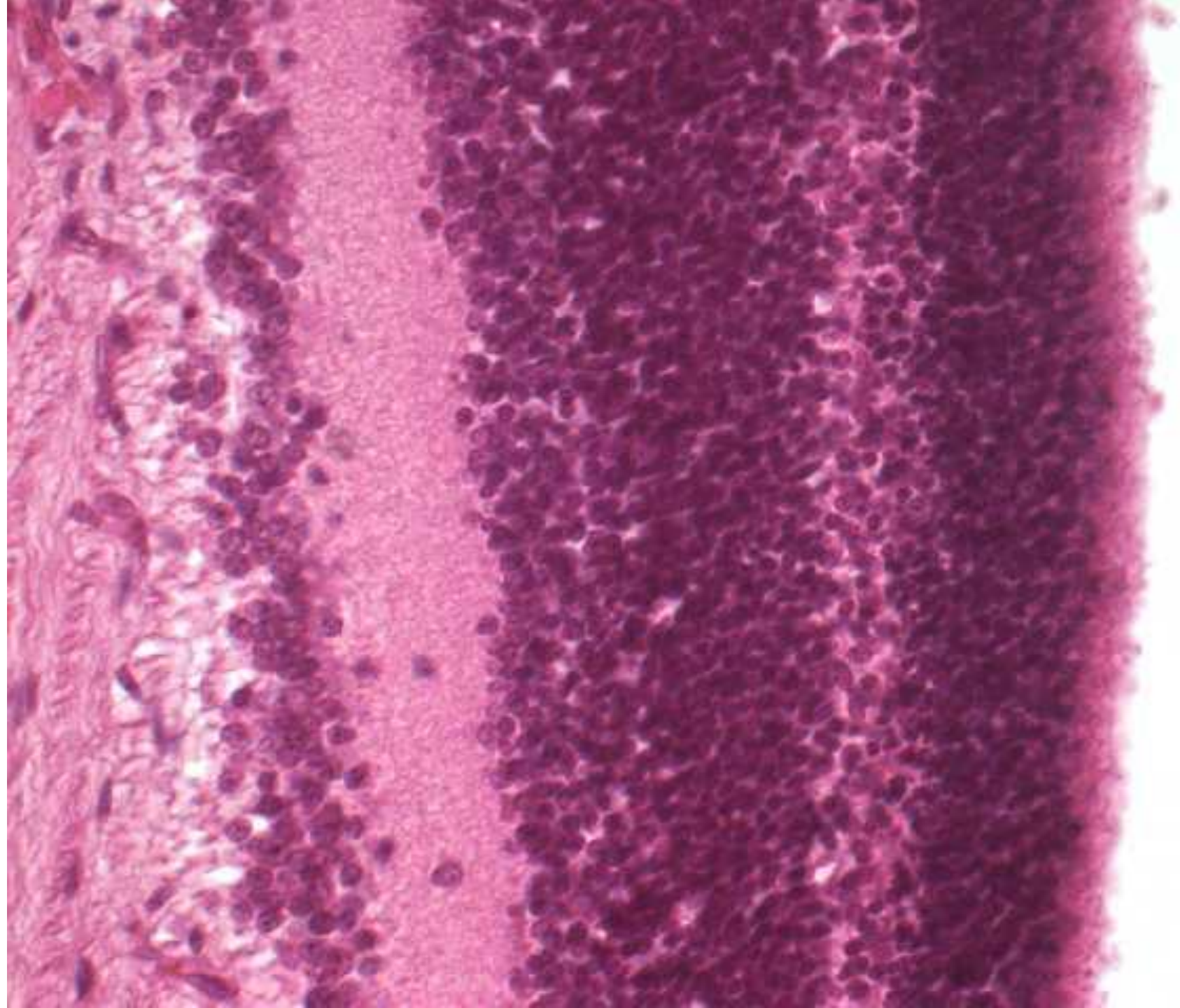
Outer limiting membrane

Photoreceptor cells

Cone Rod

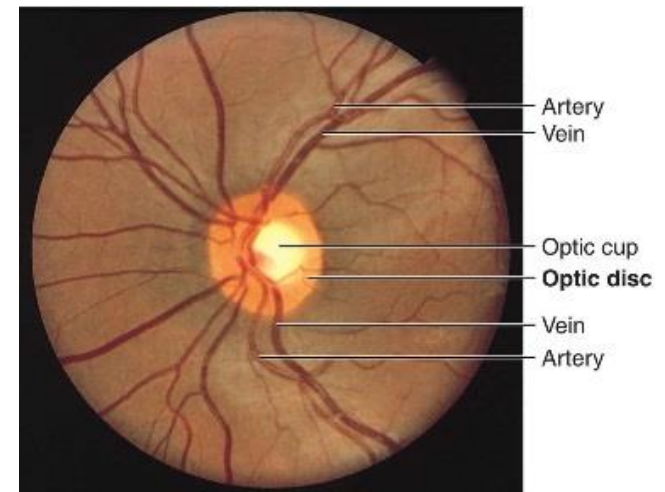
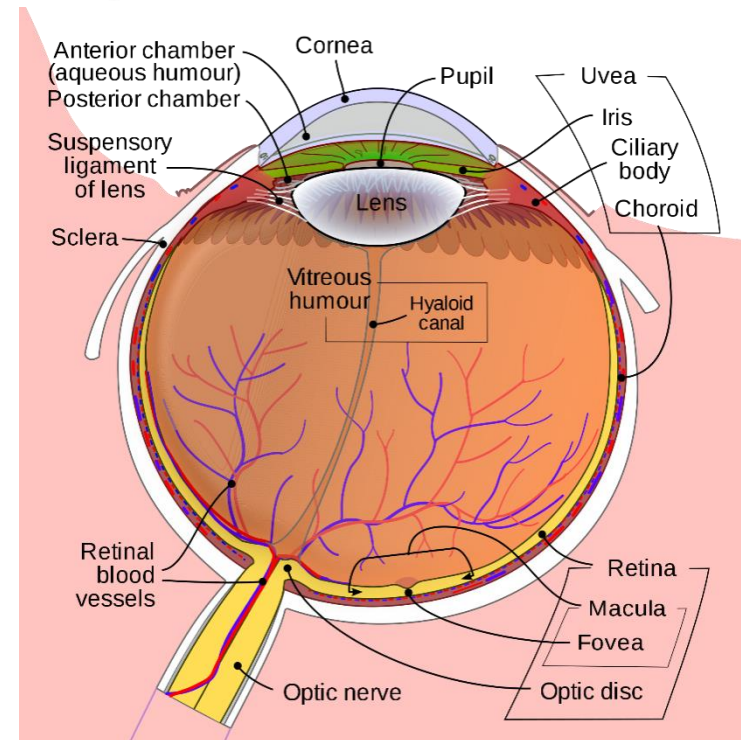
Pigment cells

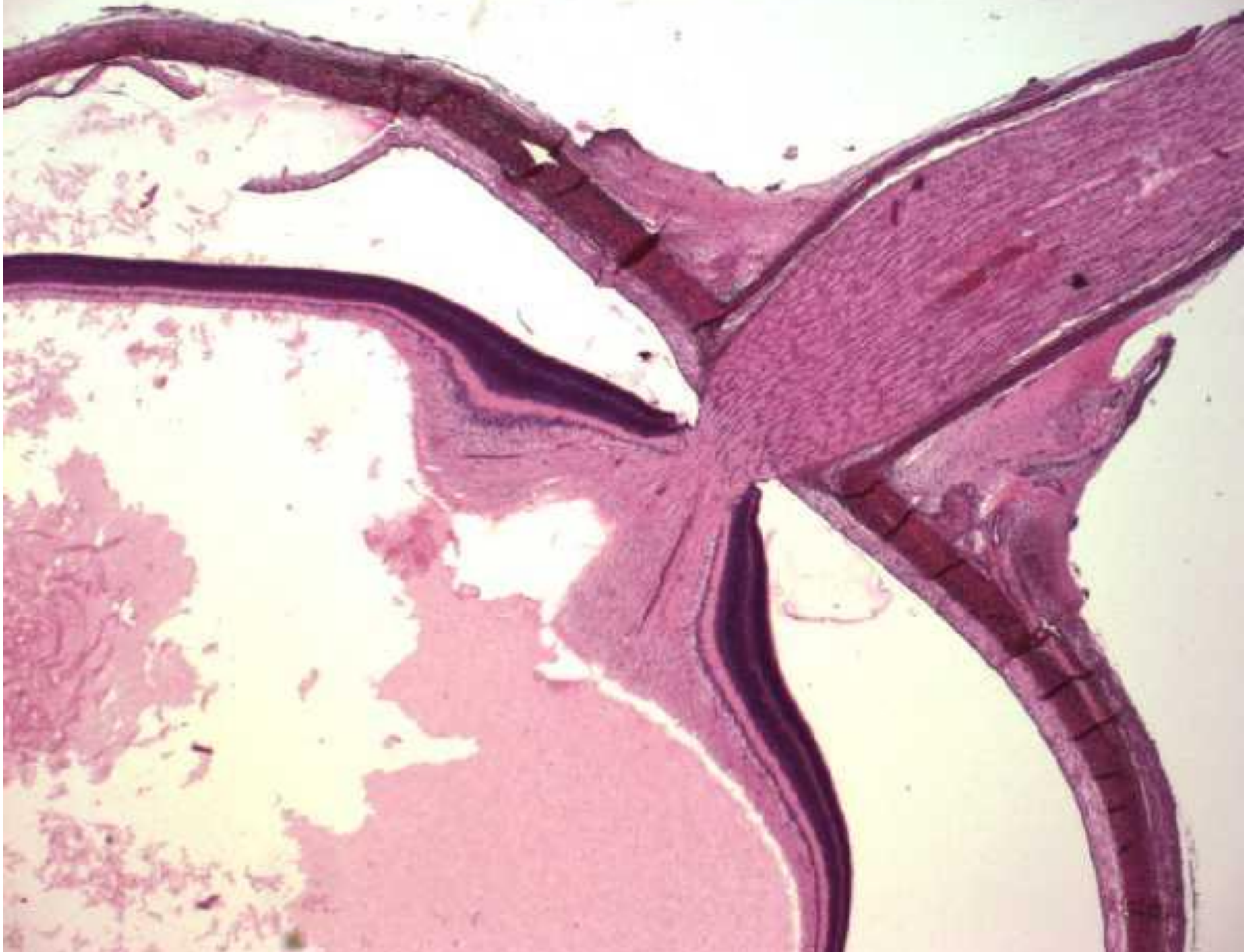
Choroid

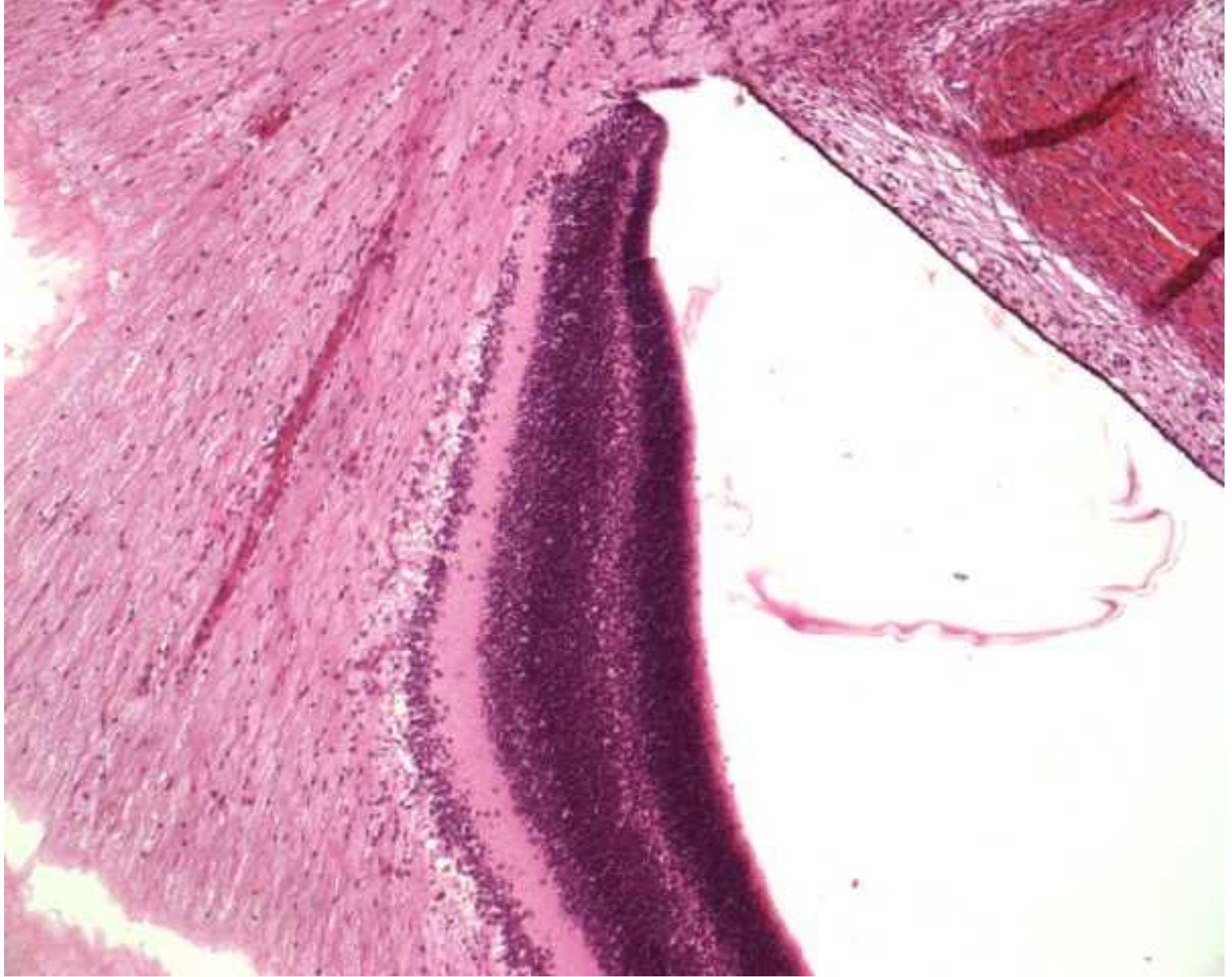


Retina – sensory part

- **discus n. optici**
= **optic disc**; „blind spot“; „papilla“
 - no light-sensitive cells
 - excavatio disci
 - exit of n. opticus fibers
 - entrance of vasa centralia retinae



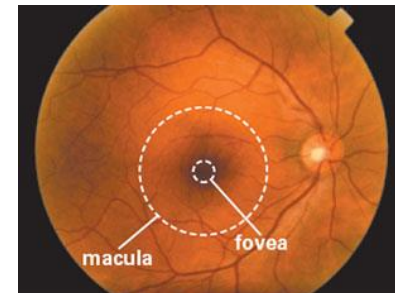
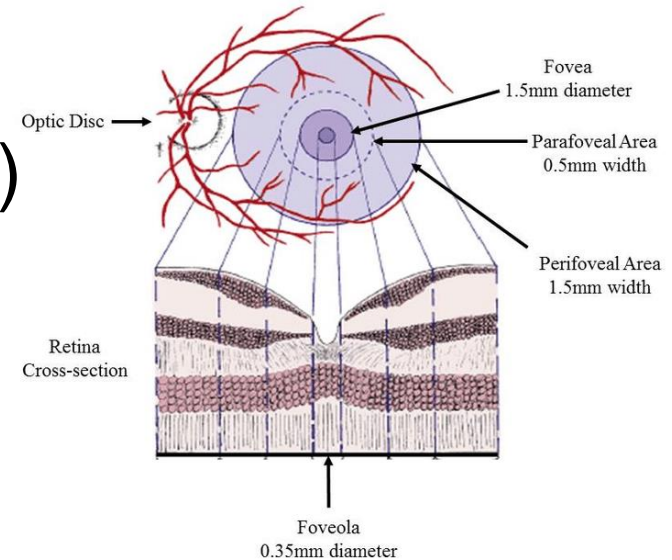
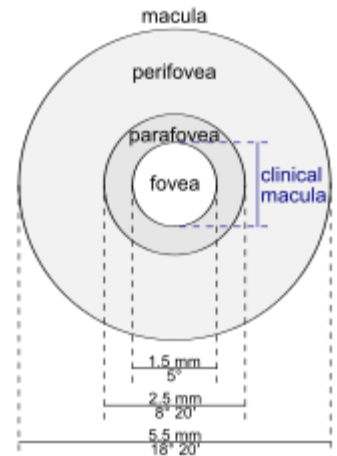


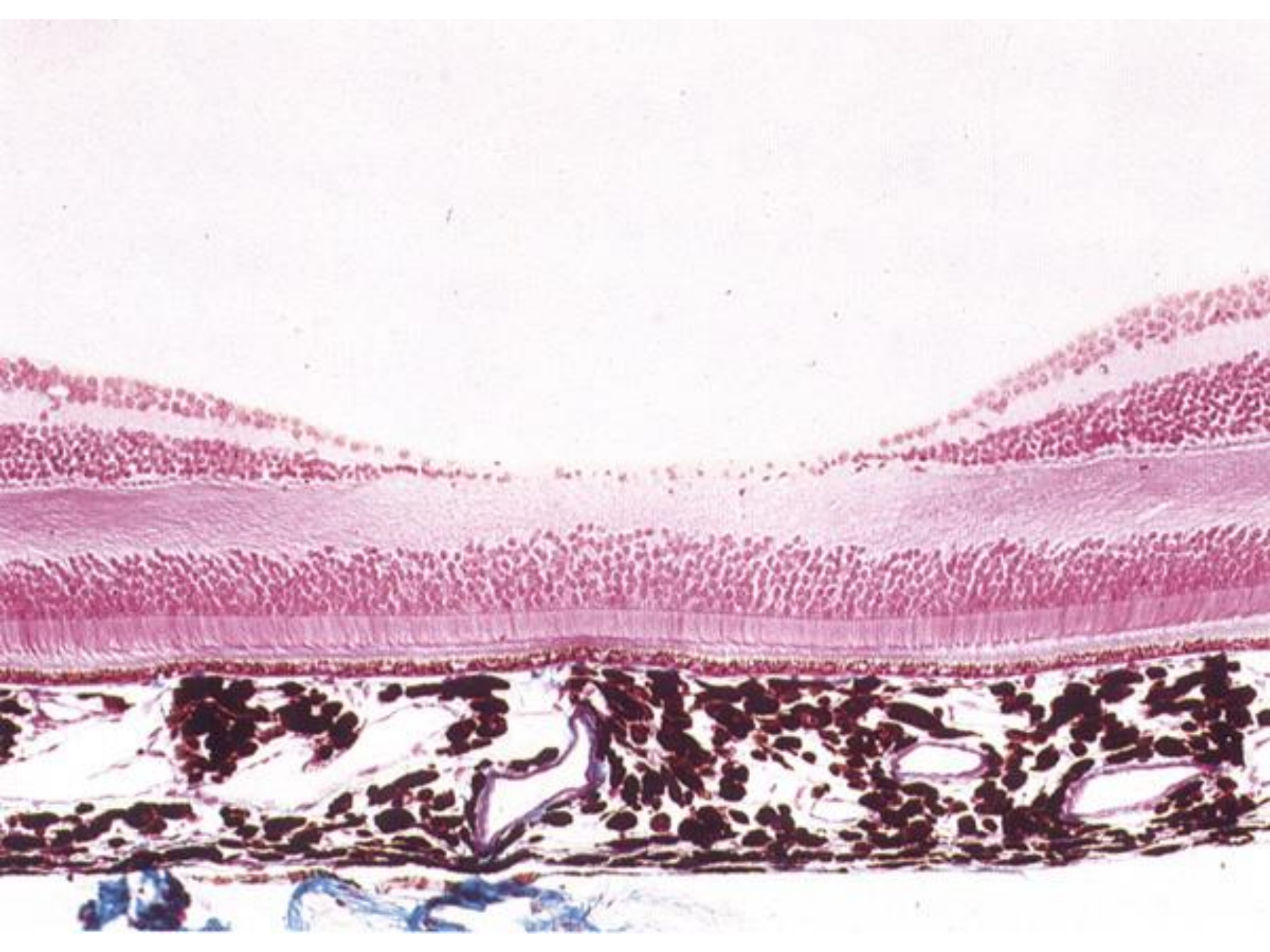


Retina – sensory part

macula lutea (= „yellow spot“)

- more than 1 layer of retinal ganglion cells
- other layer deflected laterally
- most acute vision – 5.5 mm wide
- yellow pigment (lutein, zexanthin)
- fovea centralis (1,5 mm)
 - no rods
- foveola
 - neither rods nor retinal ganglion cells
- umbo
 - only cones and Müller's cells

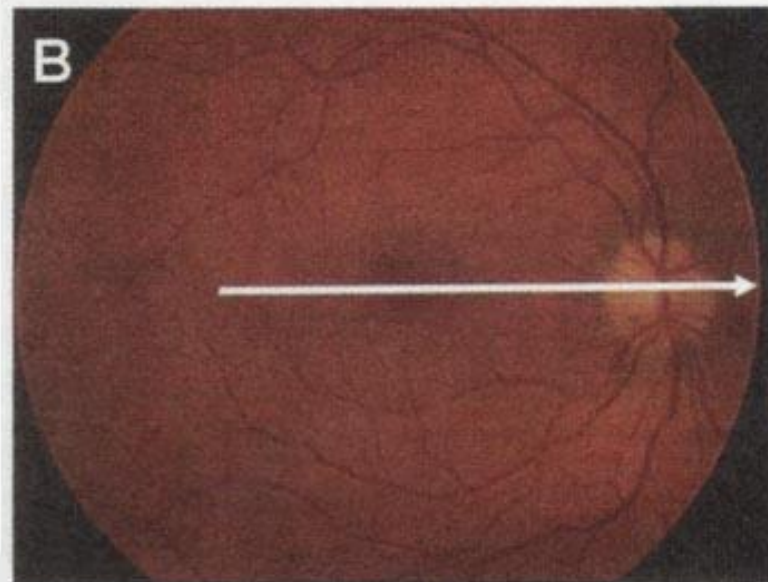
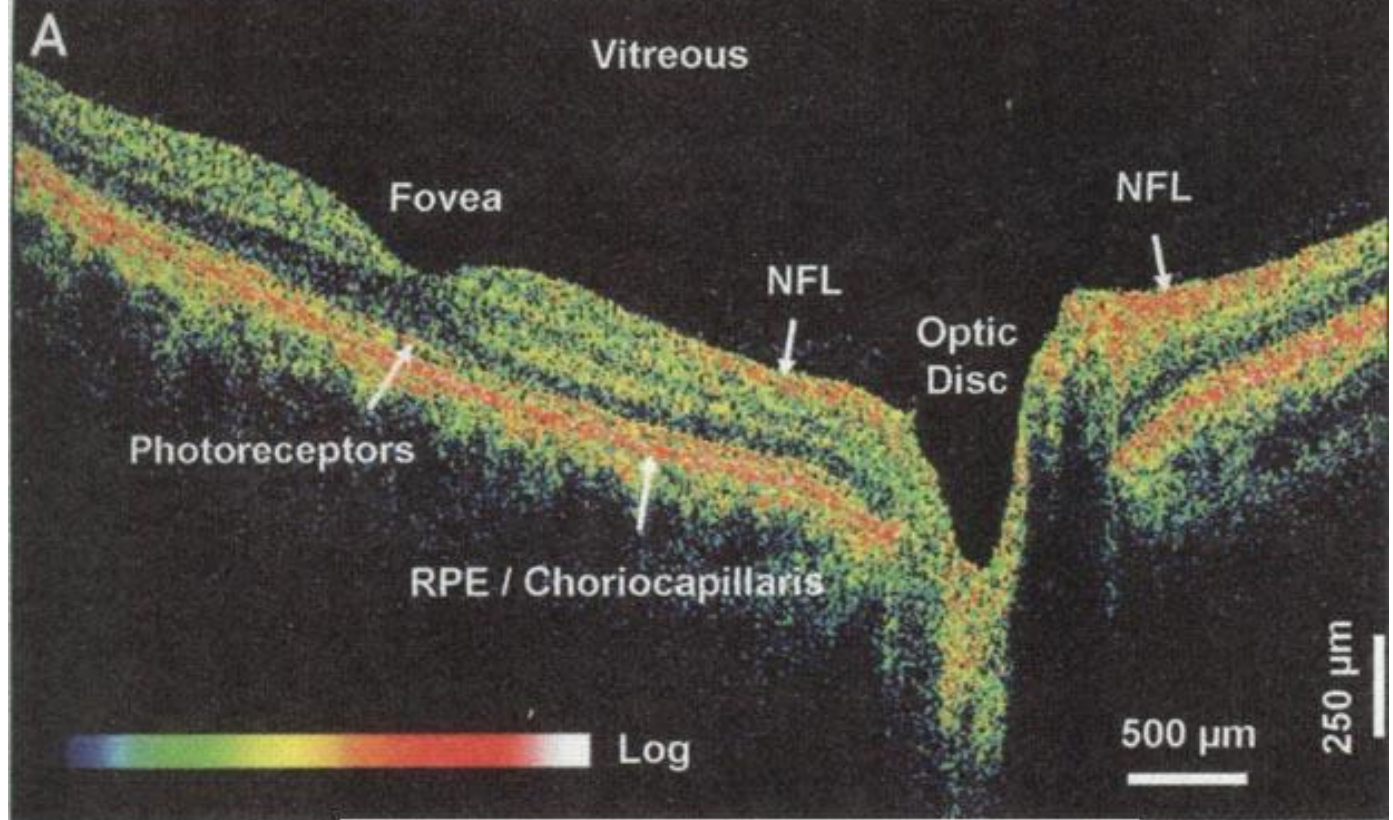




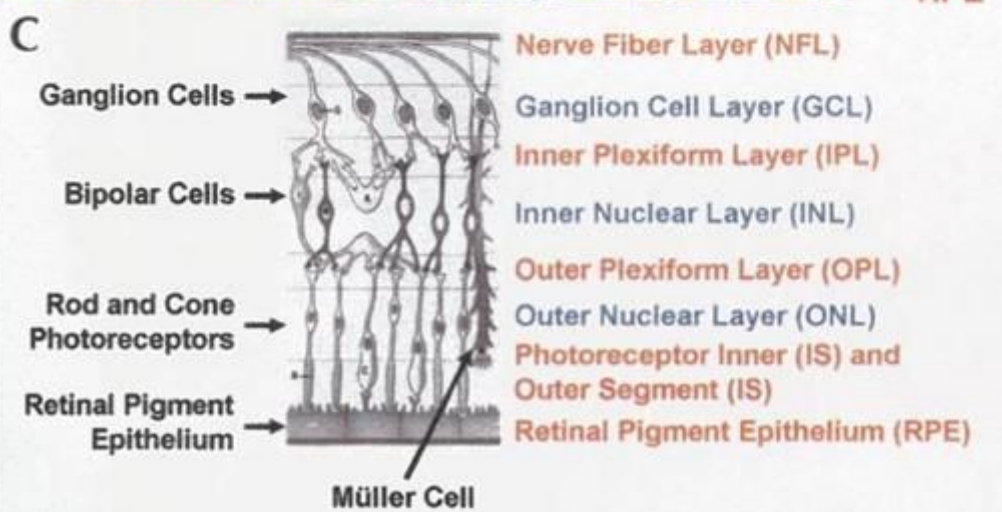
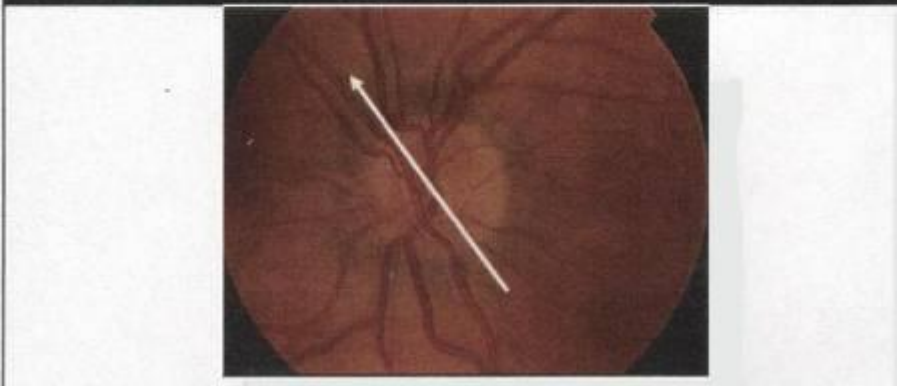
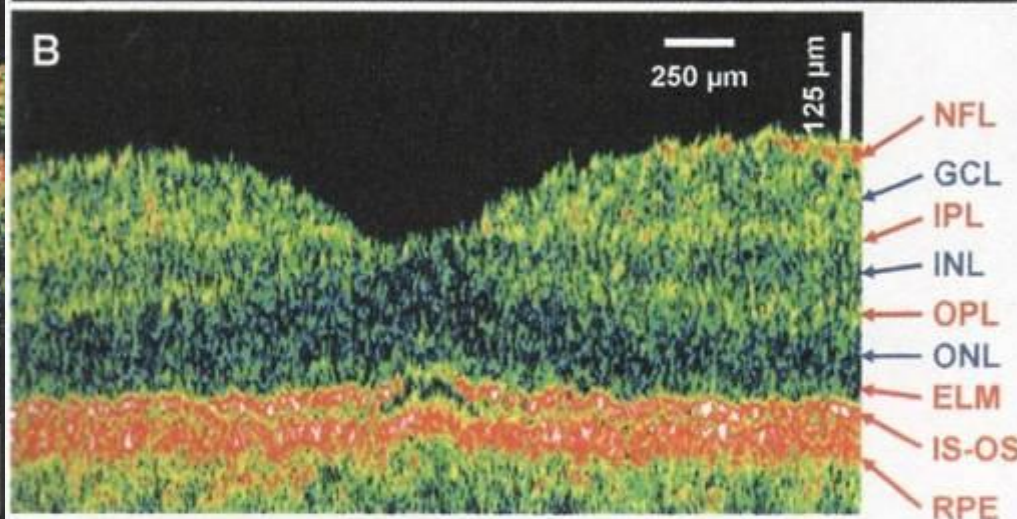
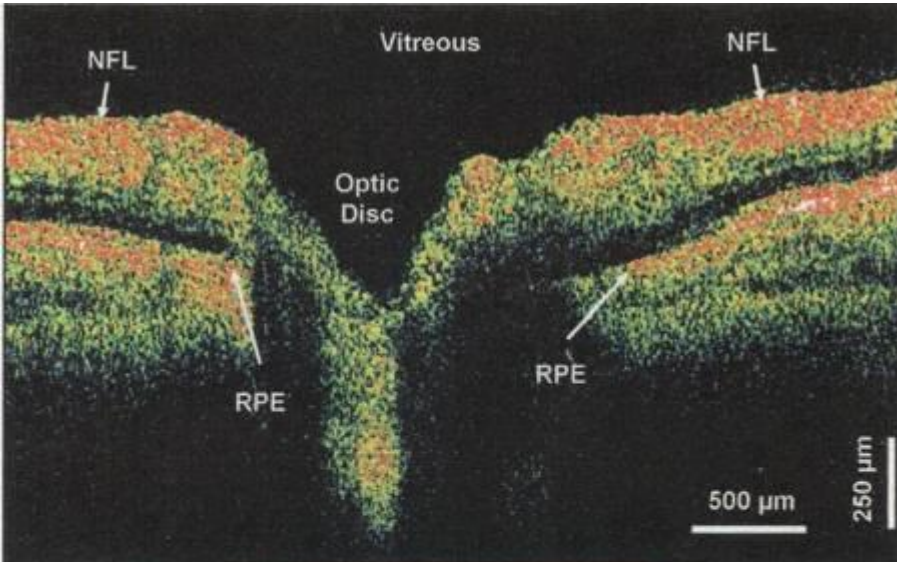
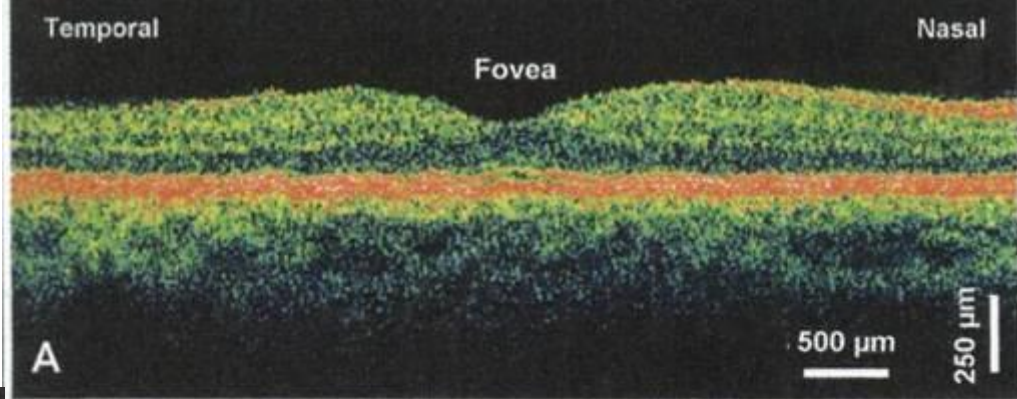
OCT

Optic
coherent
tomograph

*measurement
of light
reflection*

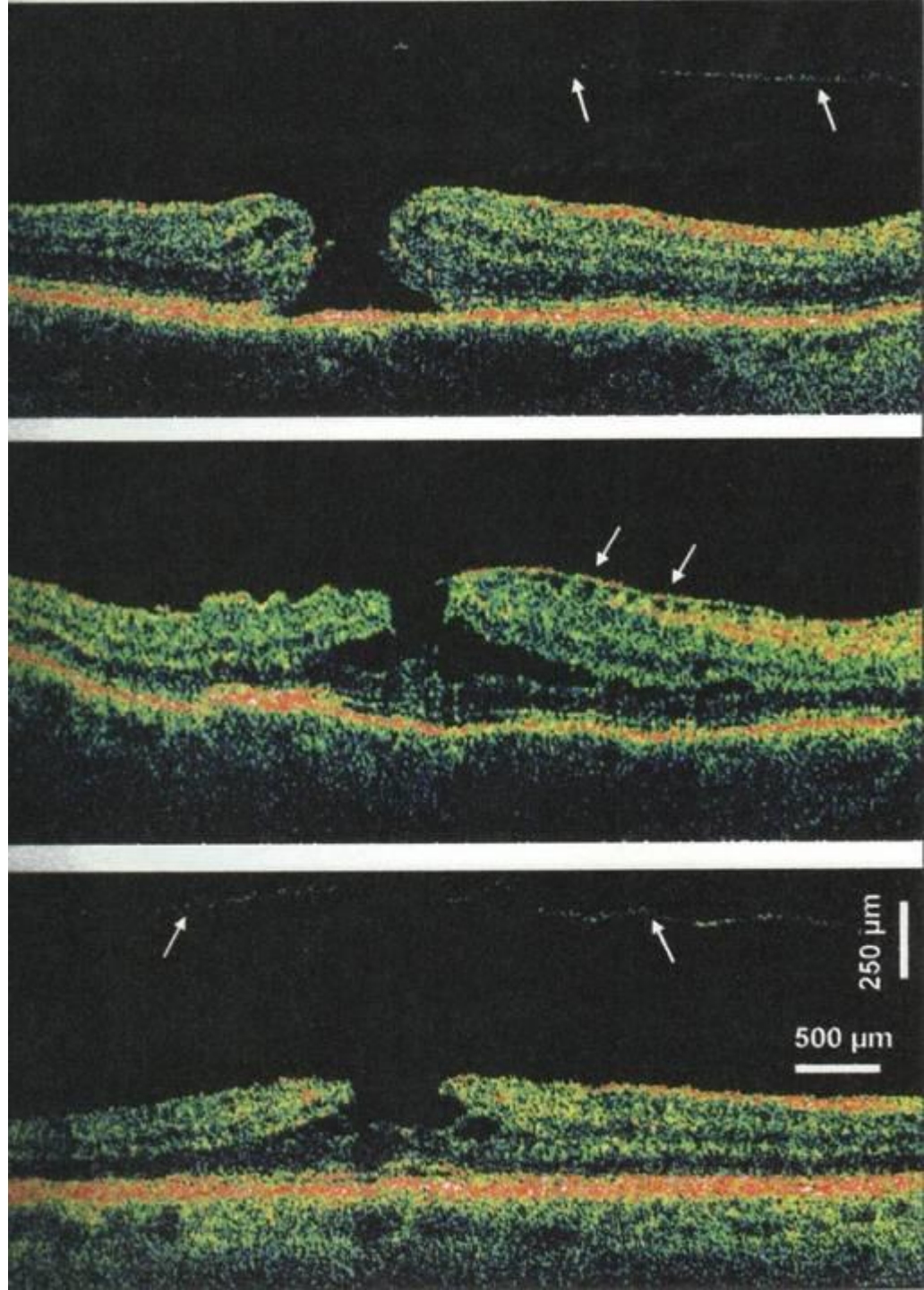


OCT



OCT

Retinal detachment (amotio retinae)

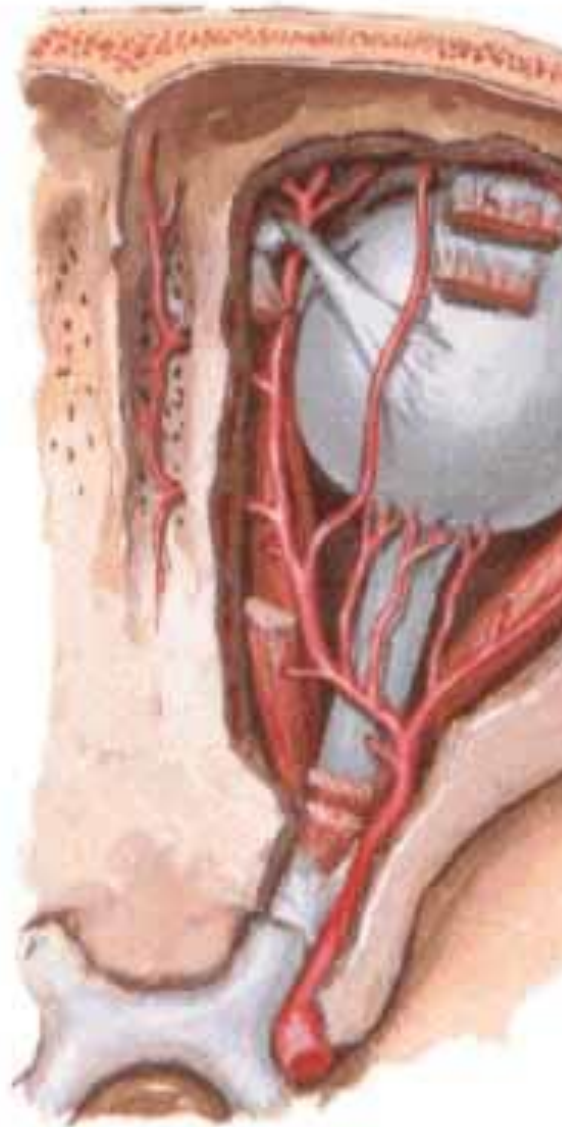

Arterial supply of the eye

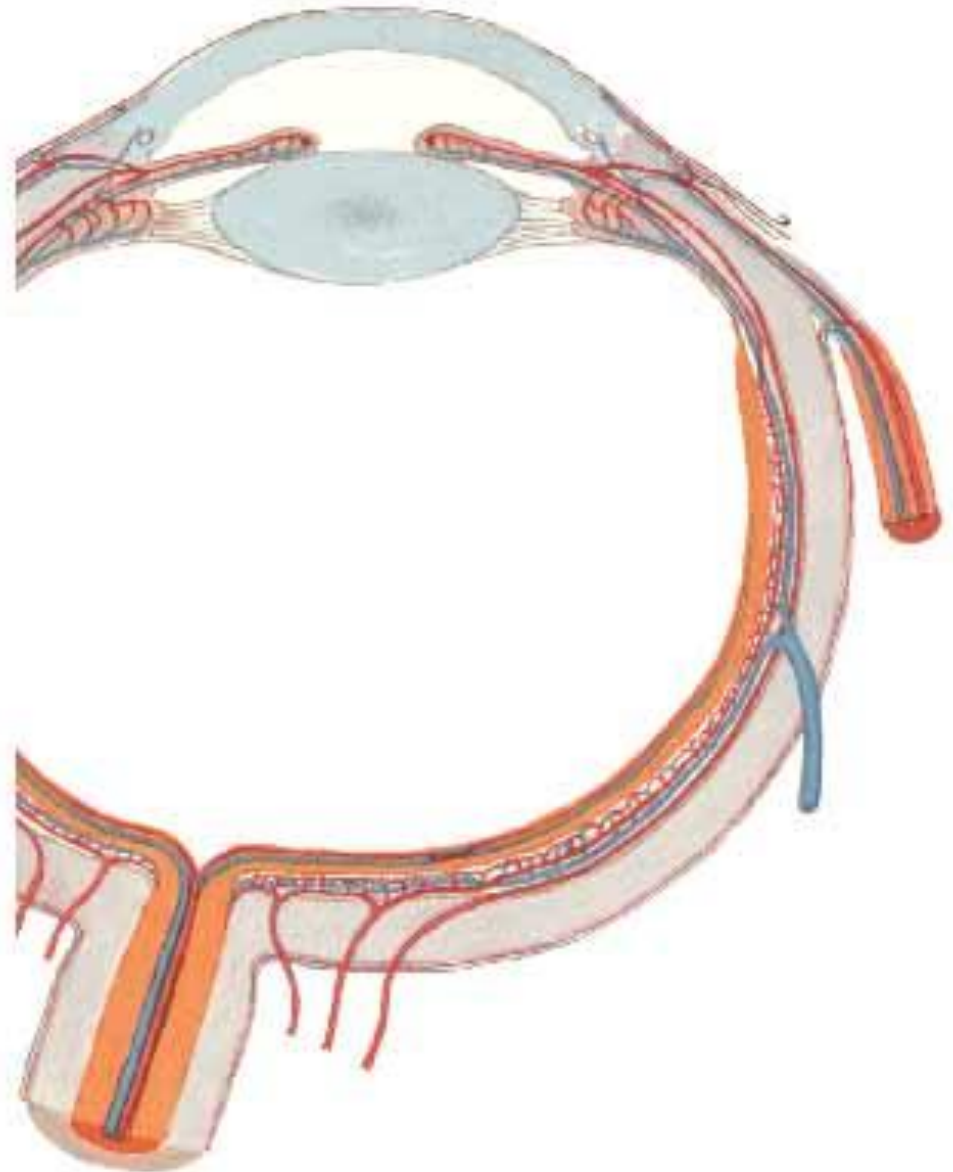a. carotis interna → a. ophthalmica →

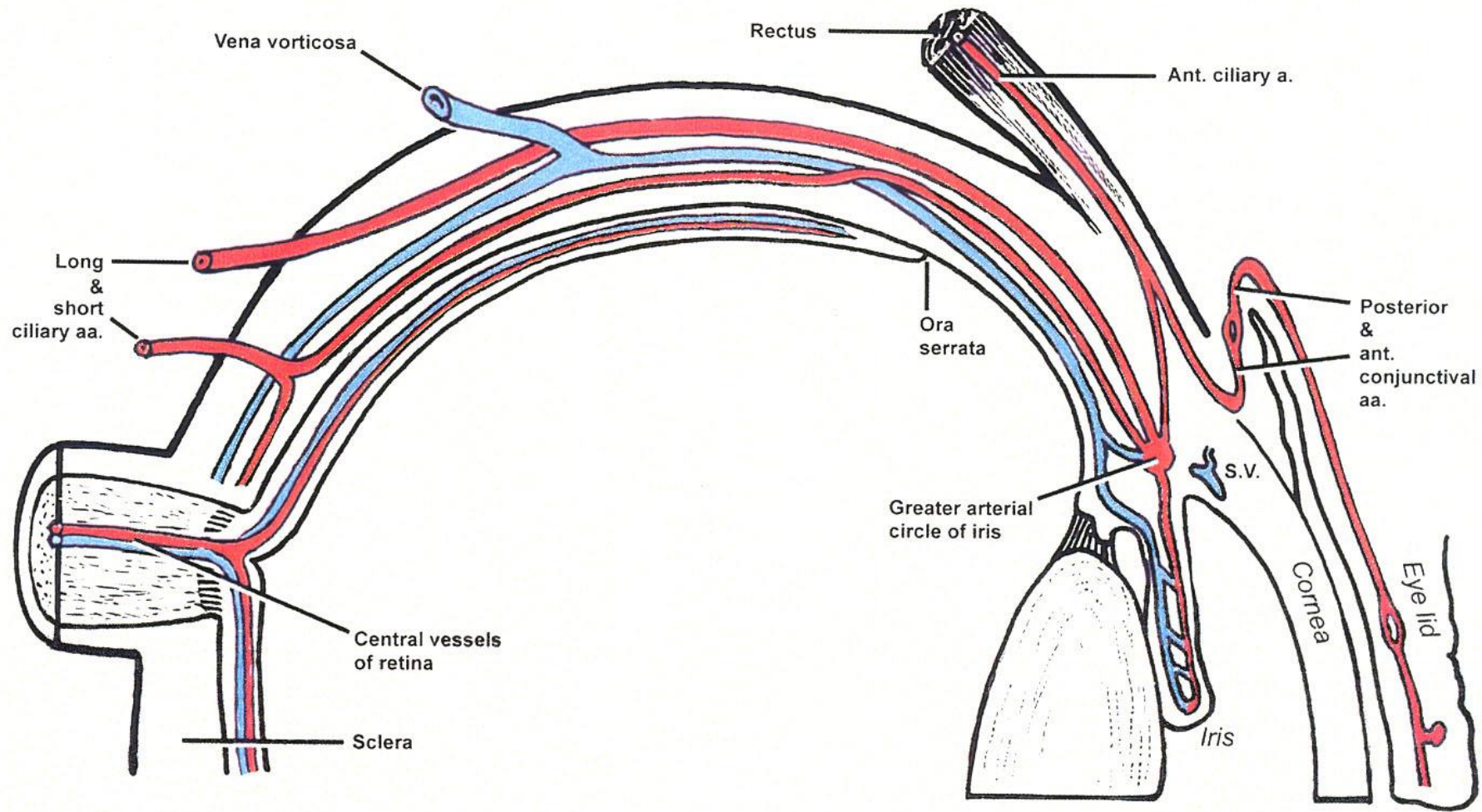
- **aa. ciliares posteriores breves** → *choroidea*
- **aa. ciliares posteriores longae (2→4)** → *corpus ciliare + iris*
- aa. musculares → **aa. ciliares ant., aa. episclerales, aa. conjunctivales lat.**
- **a. centralis retinae** → *retina*
- a. lacrimalis → aa. palpebrales lat.
- aa. palpebrales med. → **aa. conjunctivales med.**

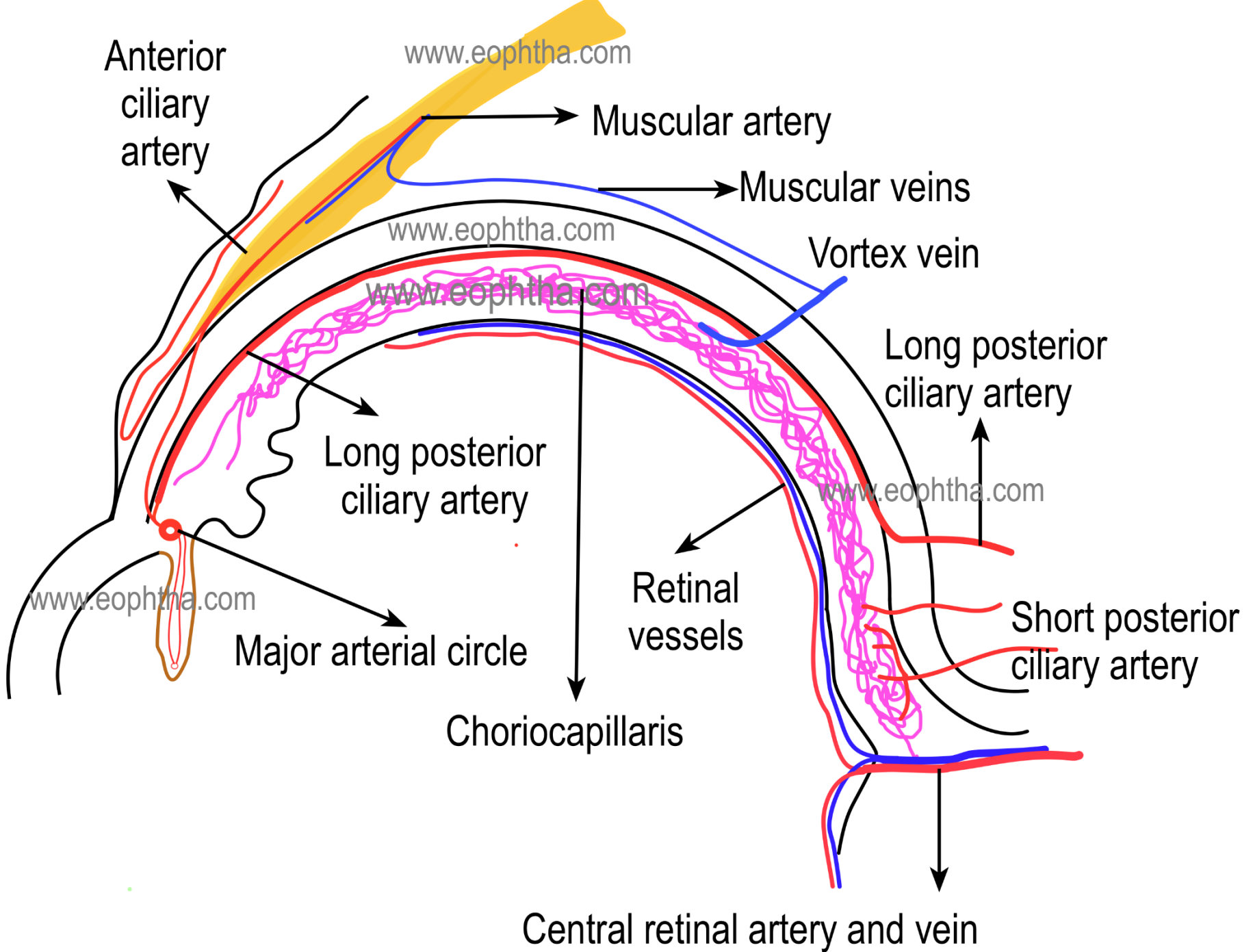
**Arteries and Veins of Orbit
Superior View**



**Intrinsic Arteries and Veins of Eye
Horizontal Section**







Vasa sanguinea retinae

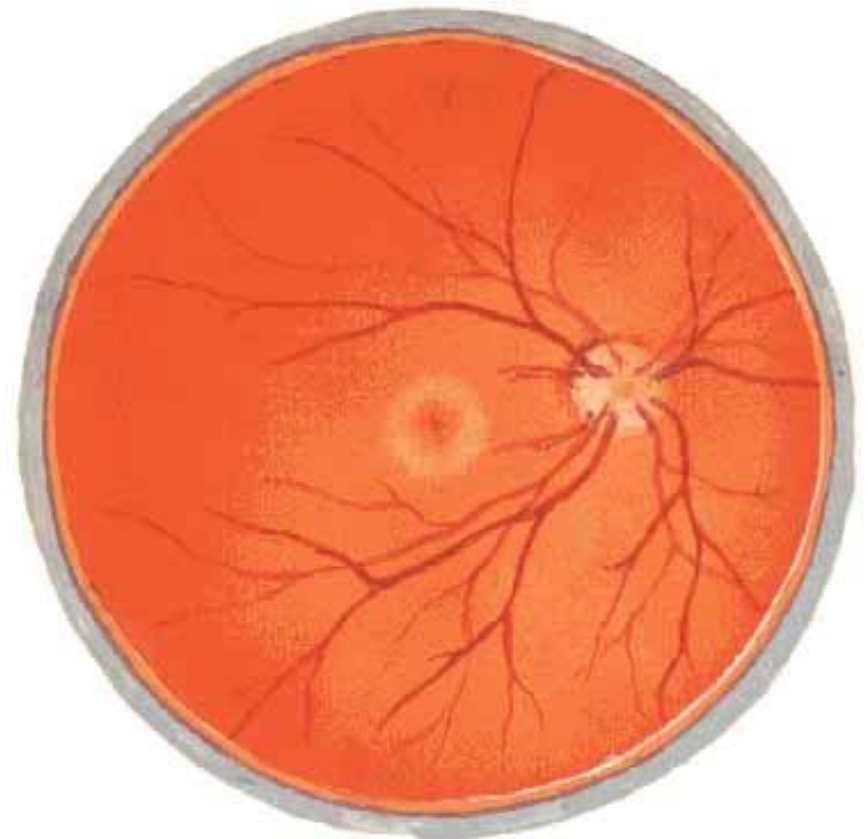
– fundus of the eye (*fundus oculi*)

a. centralis retinae →
arterioles

- a. temporalis sup.+ inf.
- a. nasalis sup.+ inf.
- a. macularis sup.+ inf.
(+ media)

veins correspond to
arteries, they often
cross

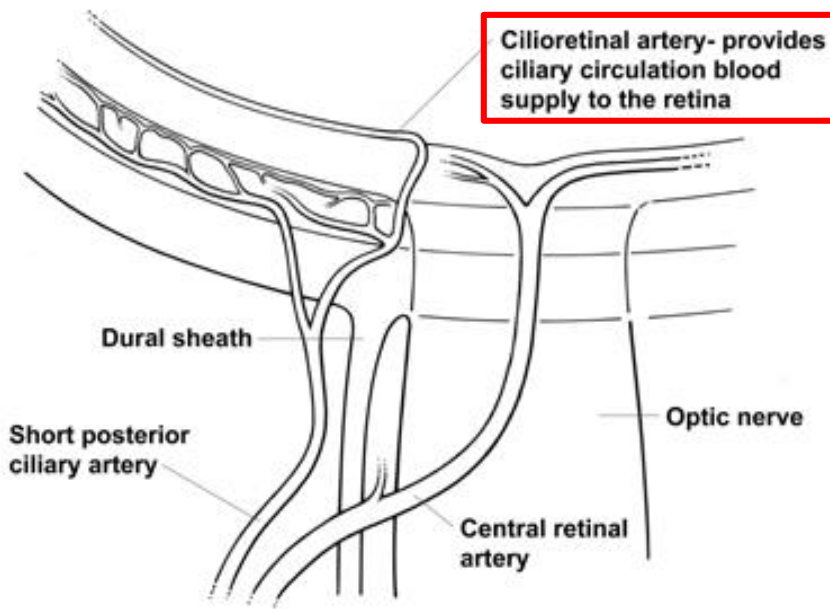
Intrinsic Arteries and Veins of Eye
Ophthalmoscopic View



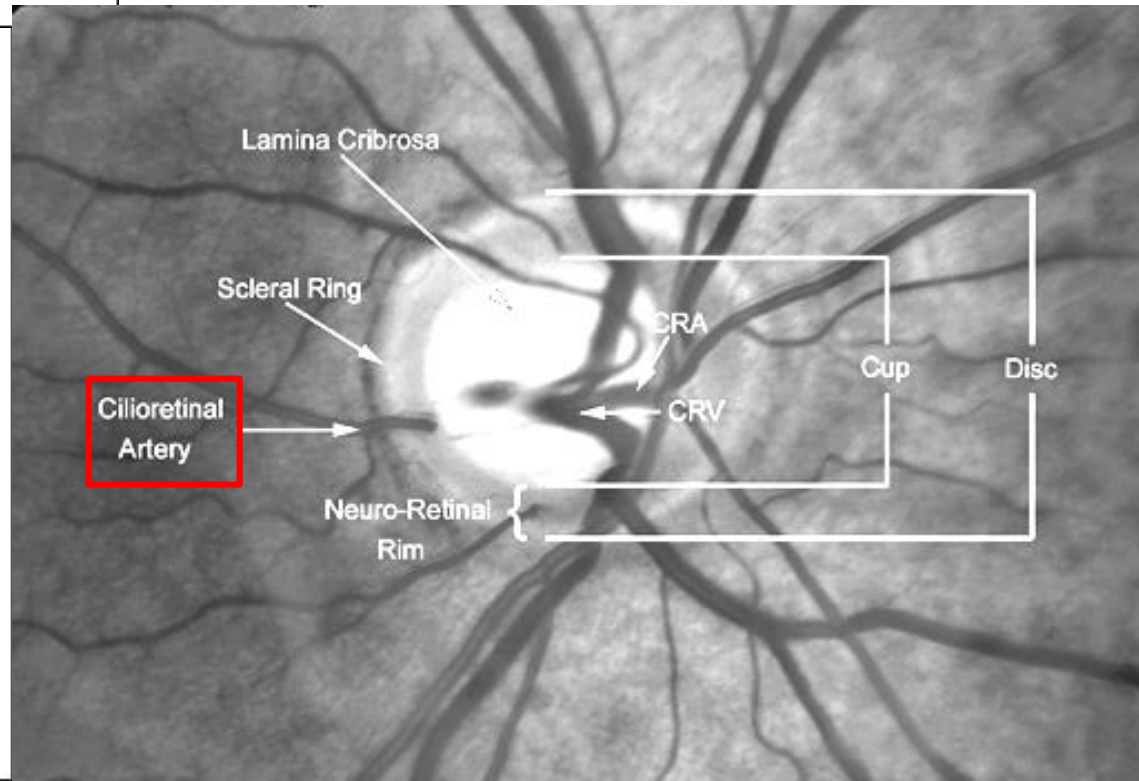
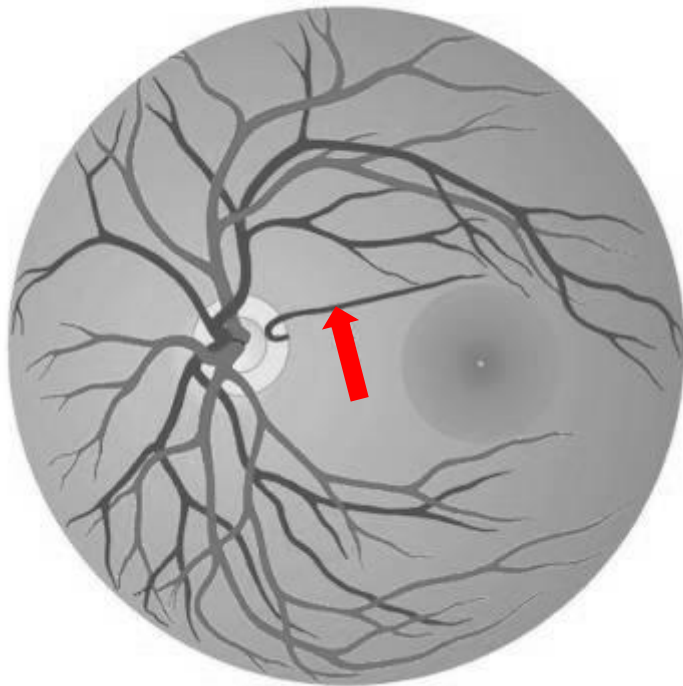
Right retinal vessels

Arteria cilioretinalis

- present in **10-33%** of eyes
- branches from *a. ciliaris posterior brevis*
- exits the discus n.II separately from a. centralis retinae
- additional supply to macula lutea from choroidal circulation
- provide a small amount of blood supply to the retina when a. centralis retinae is occluded
- 90% located temporally x 10% nasally
- *closure of a. cilioretinalis → central scotoma*
- ***closure of a. centralis retinae → non-affected macula lutea and spared central vision***



A. cilioretinalis



Venous drainage of the

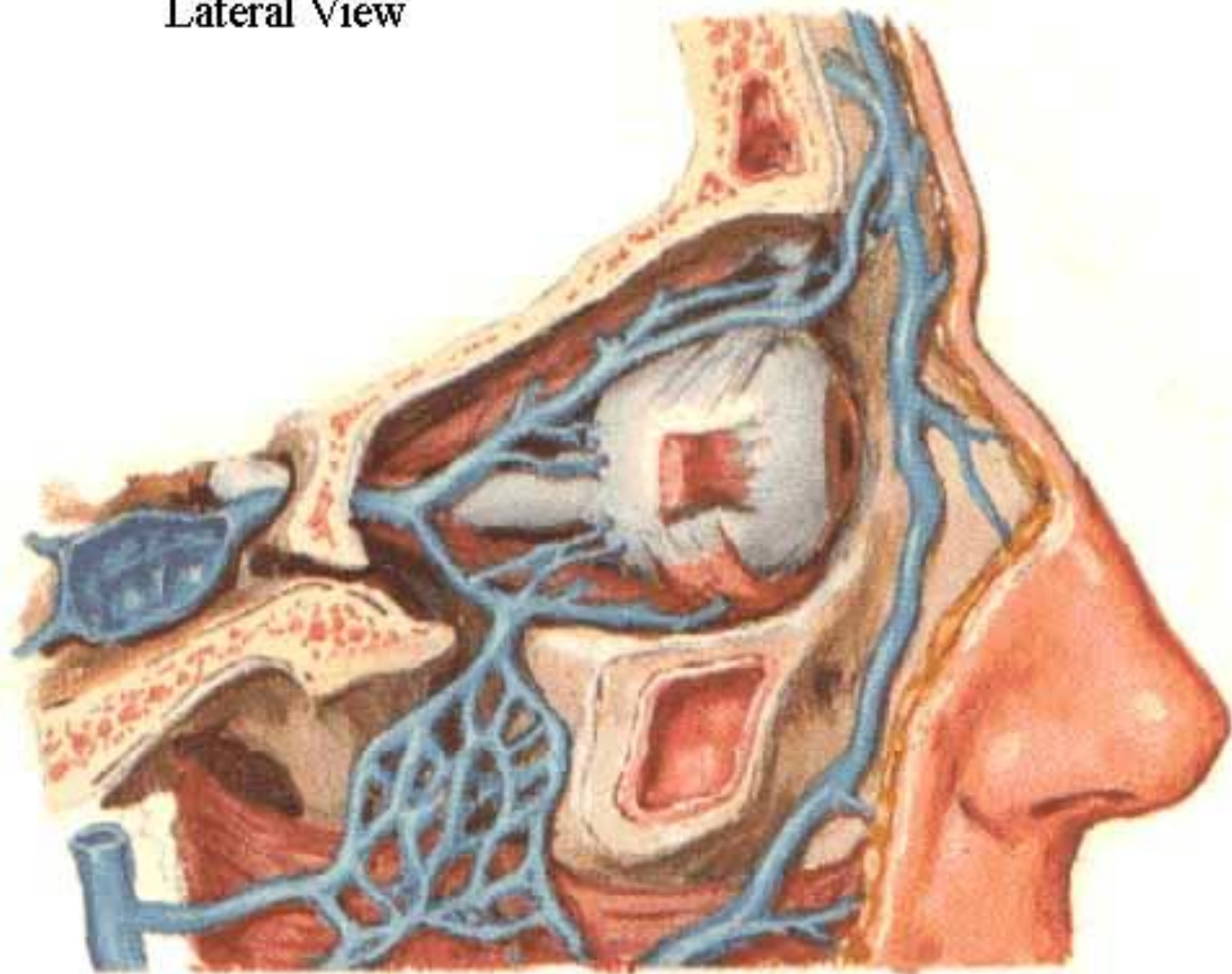
– 3 directions

- vv. episclerales
- vv. ciliares ant. ← vv. sclerales ← sinus venosus sclerae *Schlemmi*
- vv. vorticosae (4 in eyeball quadrants)
- v. centralis retinae
- v. ophthalmica sup. → sinus cavernosus
- v. ophthalmica inf. → plexus pterygoideus
- v. angularis → v. facialis → v. jugularis int.

! danger of infection spreading!

Veins of Orbit

Lateral View

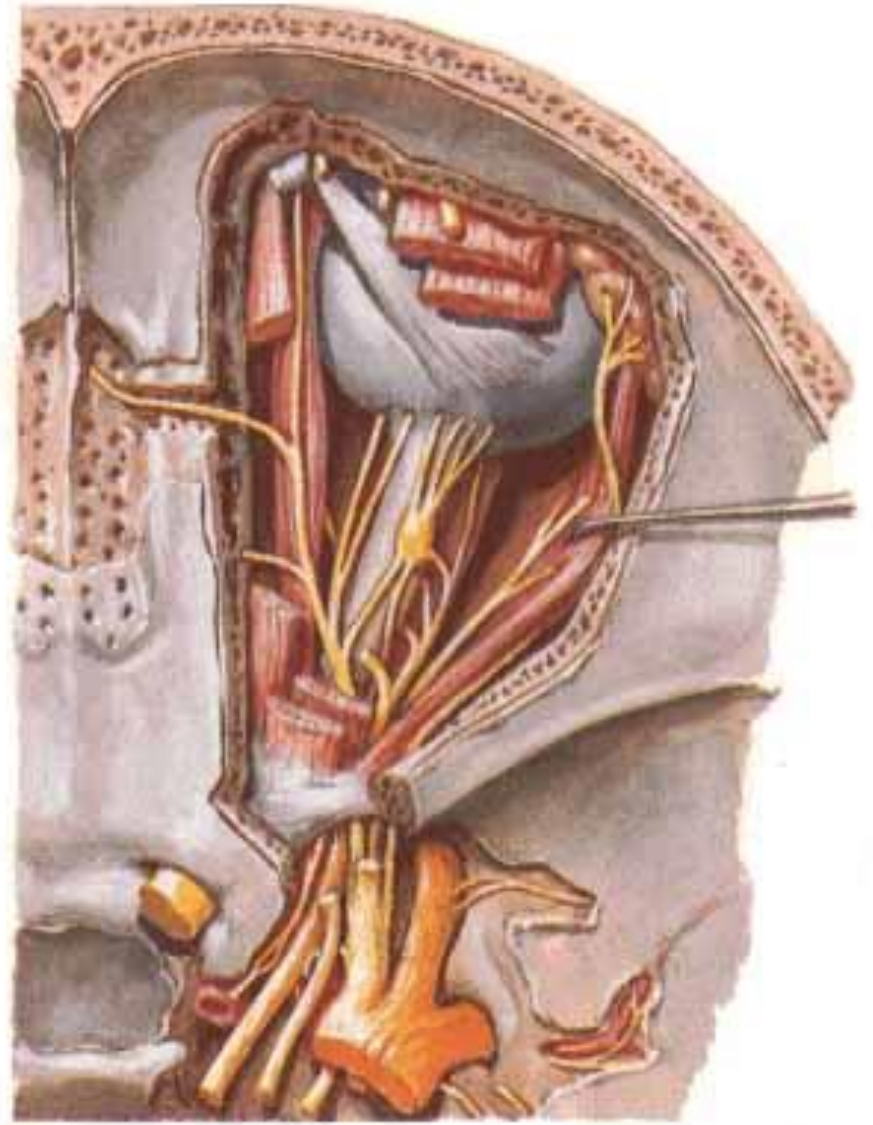
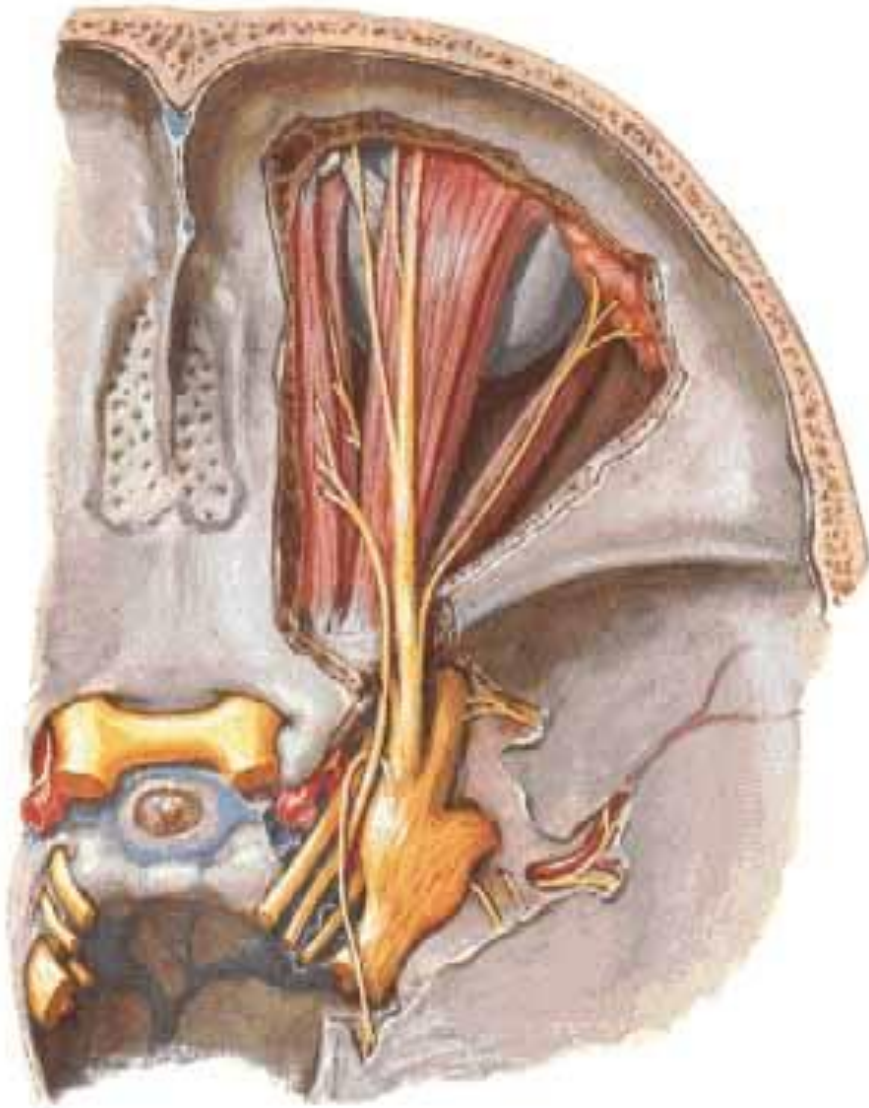


Nerve supply of the eye

- **n. opticus** – *special sensory*
 - pars intraocularis, canalis, intracranialis
 - vagina interna, externa
- **n. ophthalmicus** → nn. ciliares longi – *somatosensory*
- **n. lacrimalis, n. frontalis, n. nasociliaris** – somatosensory for surrounding structures
- ganglion ciliare → **nn. ciliares breves** – *autonomic (visceromotor)*
 - (sympathetic is not synapsed, parasympathetic yes)
- **n.III., n. IV., n.VI** – *somatomotor*

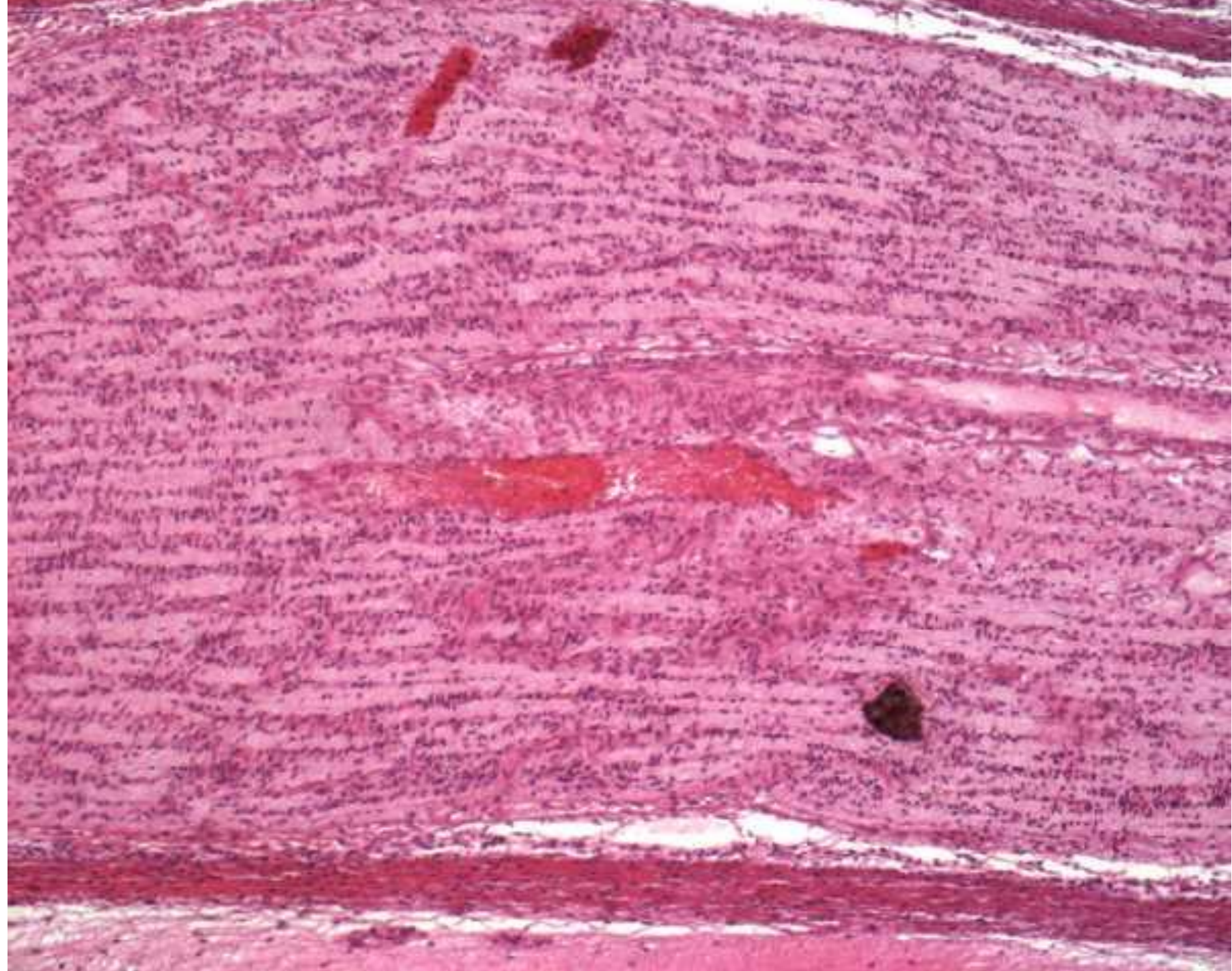
Nerves of Orbit

Superior View



Nervus opticus

- čistě senzorický
- výchlipka diencefala (thalamus opticus)
- axony odděleny endoneuriem
- na povrchu jsou analogy mozkových obalů
 - vagina externa = pachymeninx
 - vagina interna = leptomeninx
- nervem probíhá a. et v. centralis retinae



Projection → Ascending → Special sensory

VISUAL PATHWAY

4-neurons, partially decussated pathway

1.N: rods and cones of retina

2.N: bipolar neurons of retina

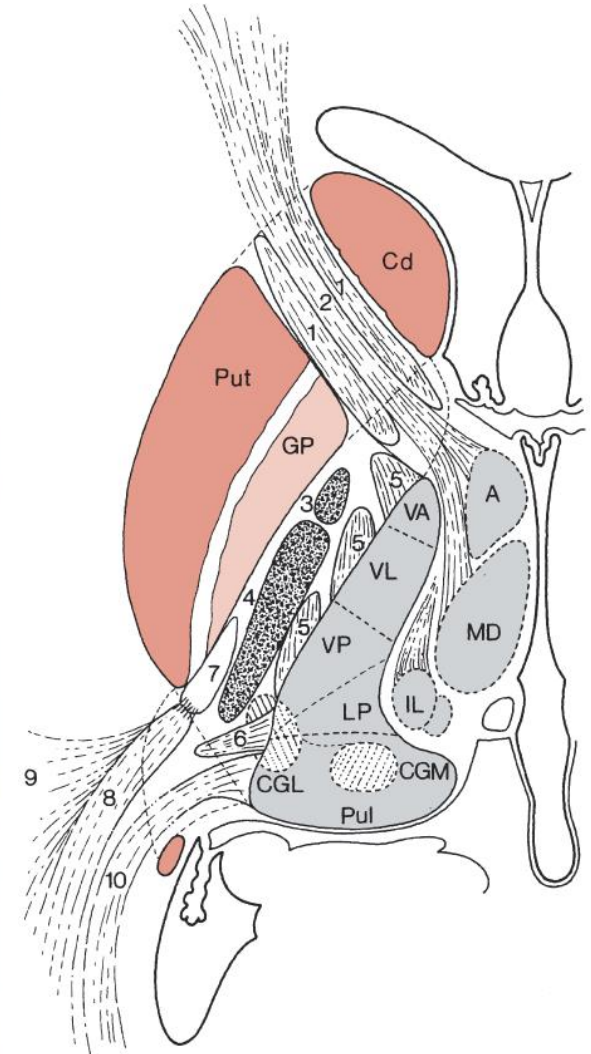
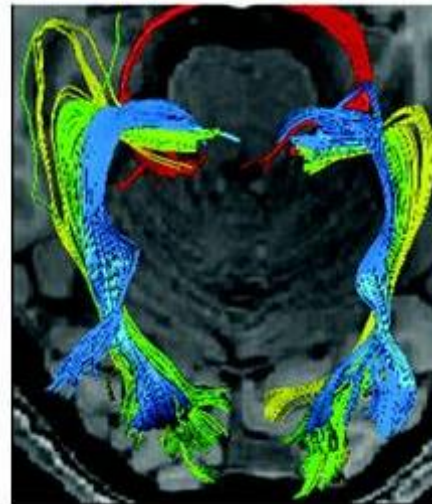
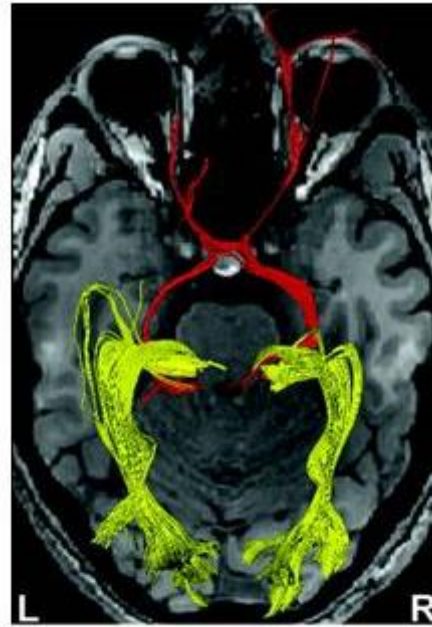
3.N: retinal ganglion cells → n. II → chiasma opticum
→ corpus geniculatum laterale

4.N: cells v nucleus corporis geniculati lateralis →
fibrae geniculocalcarinae (= radiatio optica
Gratioleti) → lobus occipitalis, area 17 (around
sulcus calcarinus)

- lower (Flechsig-**Meyer**-Archimbaum's) loop – lower half of retina (upper 1/2 of visual field)
- middle bundle
- upper (**Baum**'s) loop – upper half of retina (lower 1/2 of visual field)

Radiatio optica *Gratiolet*

- **fasciculus anterior**
= lower (Flechsig-**Meyer-Archimbault's**) loop
 - loops forms an arch around cornus inferior ventriculi lateralis within lobus temporalis
 - lower half of retina (upper 1/2 of visual field)
- **fasciculus centralis**
- **fasciculus posterior**
= upper (**Baum's**) loop
 - loop directly through lobus parietalis
 - upper half of retina (lower 1/2 of visual field)



VISUAL PATHWAY

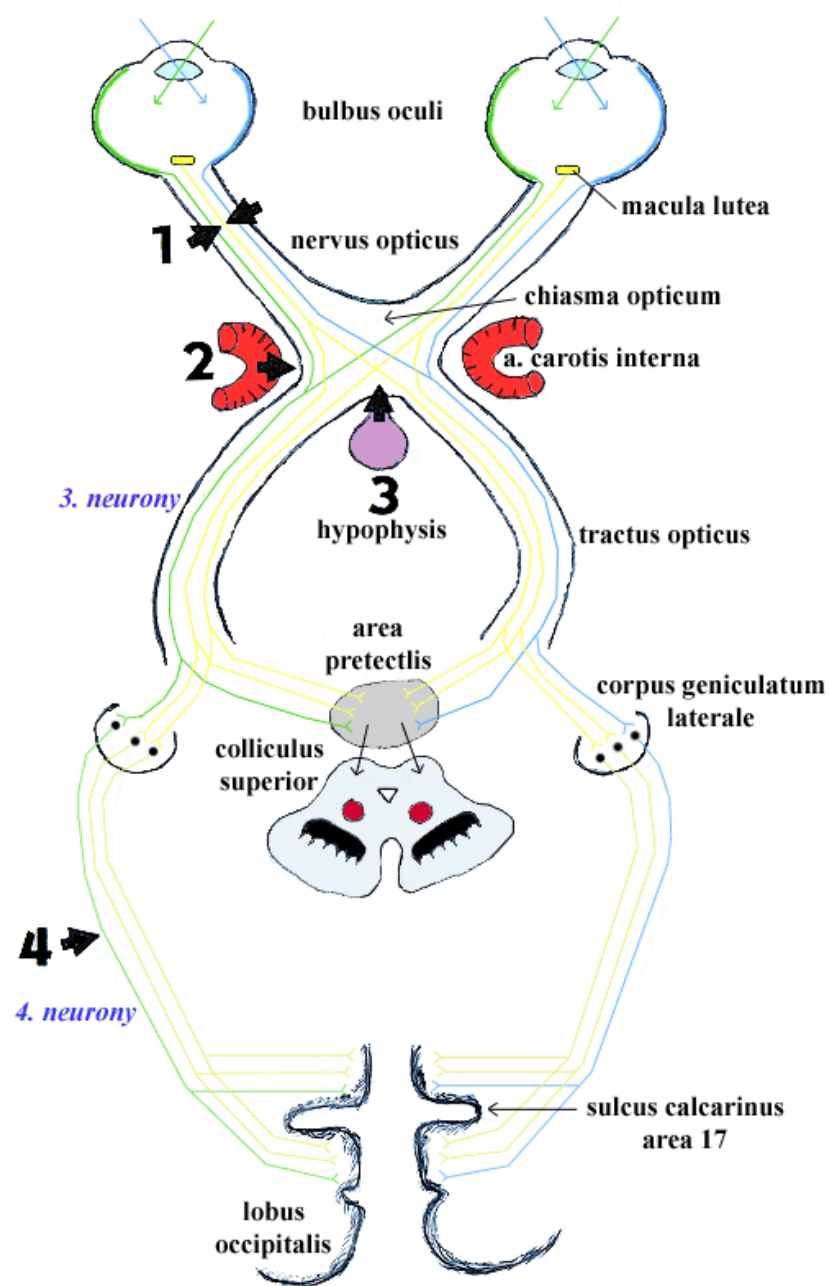
3-order-neuron collaterals

- radix optica hypothalamica to **nucleus suprachiasmaticus** (and paraventricularis) – transmits visual signals to the highest autonomic centers (seeing meal → salivation)
- radix medialis (optica mesencephalica) to **area pretectalis** to ncll. pretectales (4.N) – pathway of pupillary reflex
 - for **miosis**: → 5.N: nucleus accessorius n. III (pars preganglionica) *Edinger-Westphal* → parasympathetic fiber with n. III → 6.N: ganglion ciliare → nn. ciliares breves → m. ciliaris et m. sphincter pupillae (accomodation + miosis)

VISUAL PATHWAY

3-order-neuron collaterals

- for **mydriasis**: → 5.N: reticular formation → tractus reticulospinalis → 6.N: centrum ciliospinale *Budge* (C8-T1) → r.com.albus → ggl. stellatum (not synapsed) → truncus sympathicus → 7.N: ganglion cervicale superius → n. et plexus caroticus internus → plexus ophthalmicus → ggl. ciliare (not synapsed) → nn. ciliares breves → m. dilatator pupillae (mydriasis)
- for **convergence**: 4.N: nucleus interstitialis *Cajali* → fasciculus longitudinalis medialis (both decussated and non-decussated) → 5.N nuclei of all oculomotor nerves
- **tectal visual circuit** → tractus tectospinalis
 - management of coordinated movements of eyes, head and neck towards to the visual impulses and for coordination with total body movements



- 1 - amaurosis (= slepota) levého oka
- 2 - hemianopsia nasalis (porucha jen na levém oku)
- 3 - hemianopsia heteronyma bitemporalis
- 4 - hemianopsia homonyma dextra

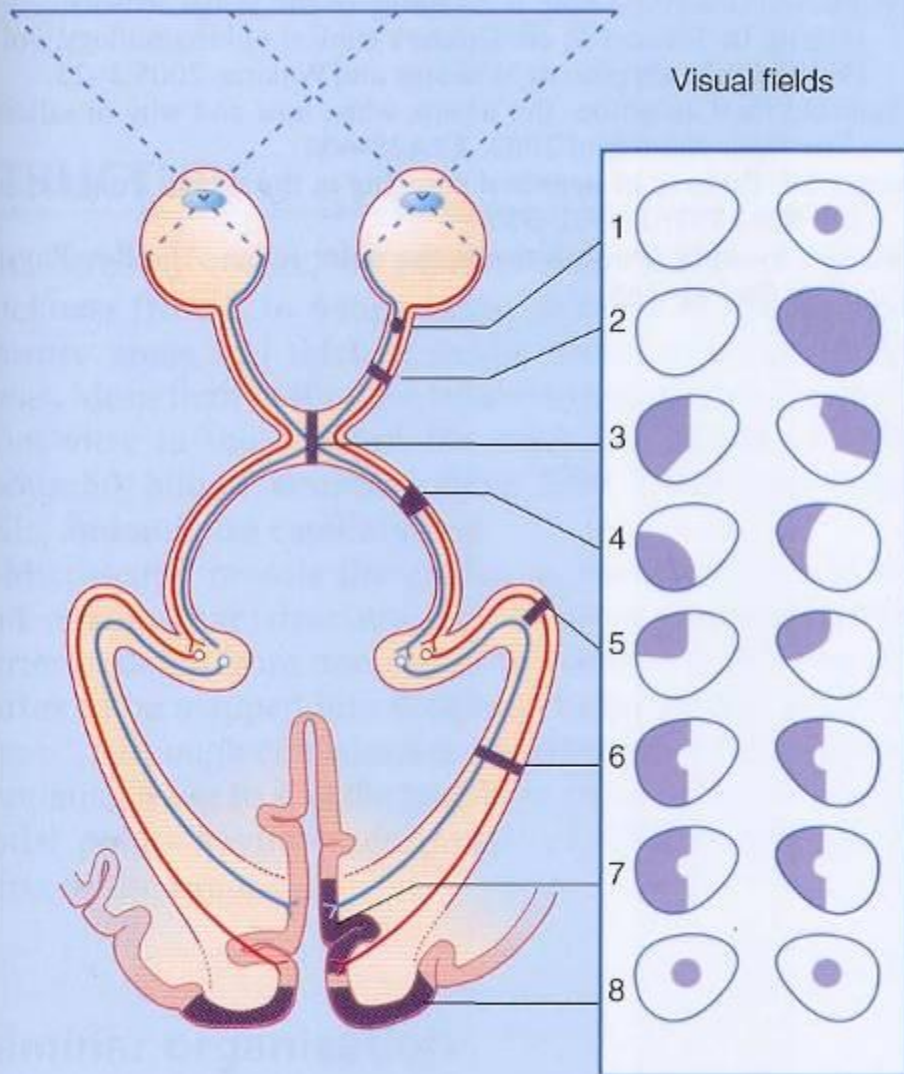
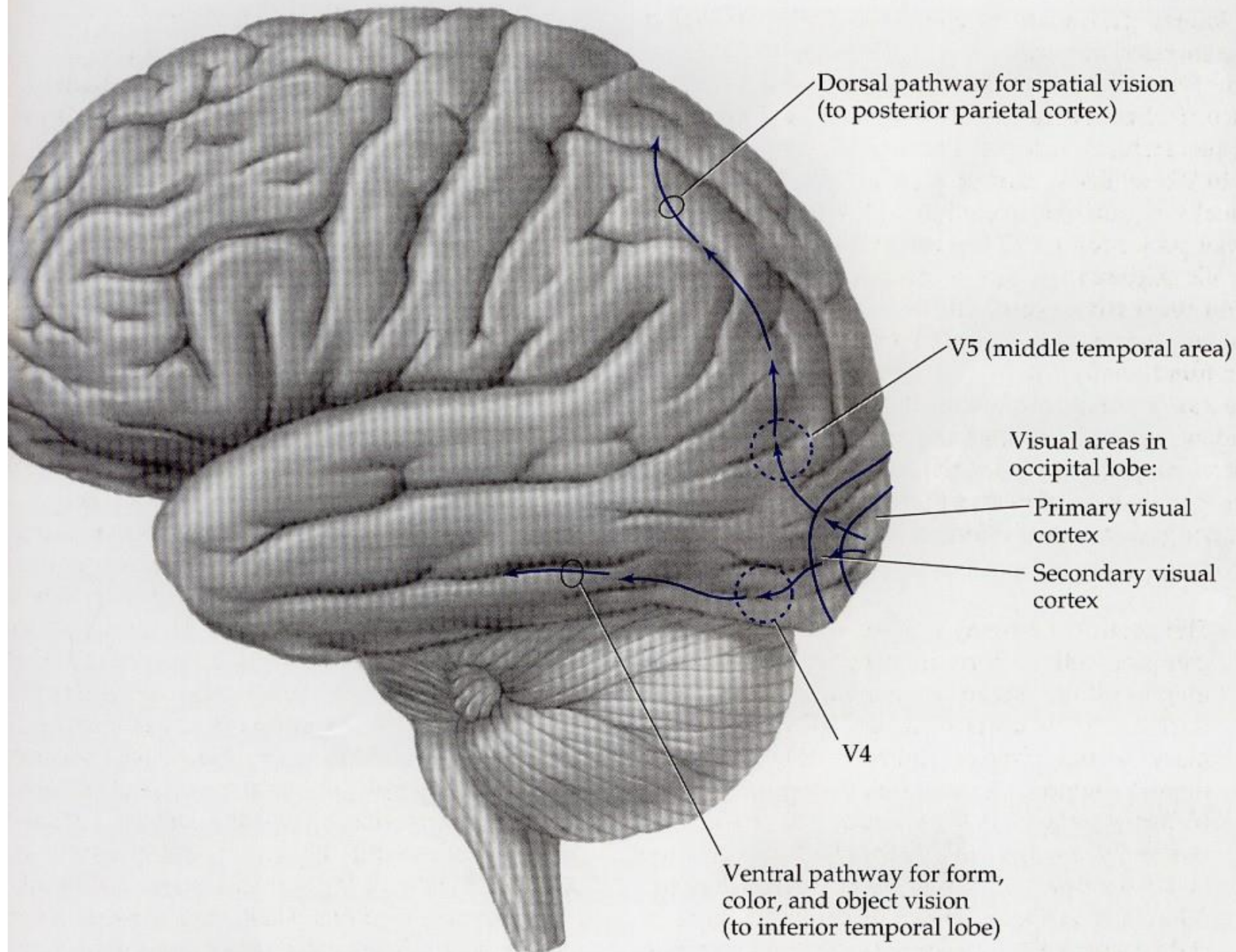


Table CP 28.1.1 Classification of dyphasia.

Number	Lesion	Field defect
1	Partial optic nerve	Ipsilateral*scotoma ^a
2	Complete optic nerve	Blindness in that eye
3	Optic chiasm	Bitemporal hemianopia
4	Optic tract	Homonymous ^b hemianopia
5	Meyer's loop	Homonymous upper quadrantanopia
6	Optic radiation	Homonymous hemianopia
7	Visual cortex	Homonymous hemianopia
8	Bilateral macular cortex	Bilateral central scotomas



Structurae oculi accessoriae

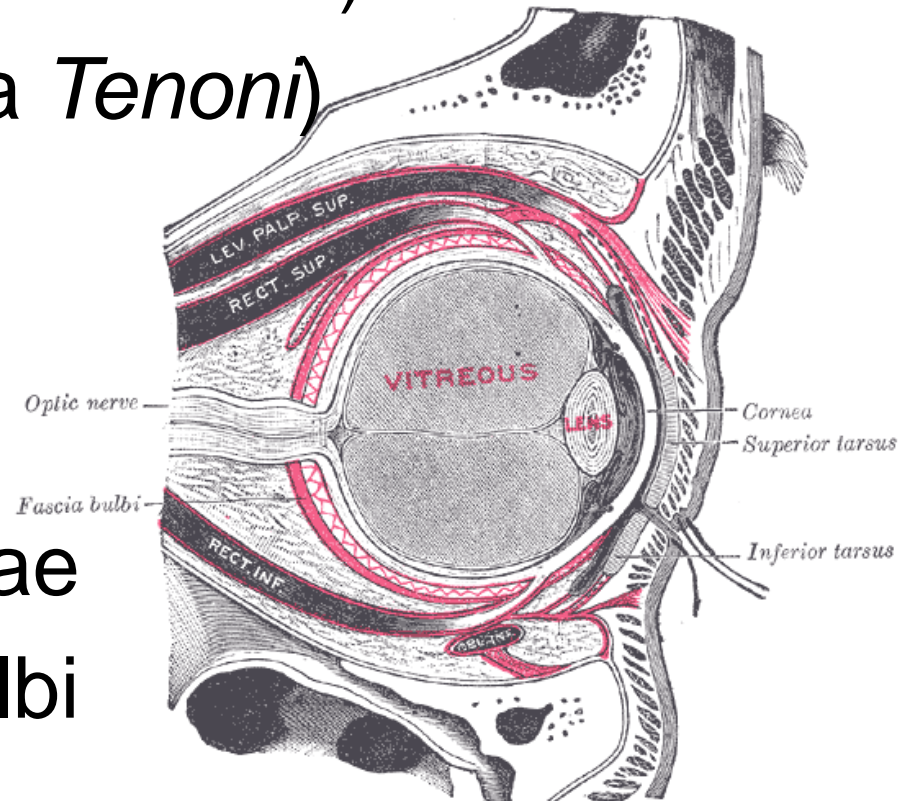
Accessory visual organs

- ligamentous apparatus = *apparatus ligamentosus*
- eyelids = *palpebrae*
- conjunctiva = *tunica conjunctiva*
- lacrimal apparatus = *apparatus lacrimalis*
- muscular apparatus (extraocular muscles) = *apparatus muscularis (mm. externi bulbi oculi)*
- *supercilium*

Ligamentous apparatus

Apparatus ligamentosus

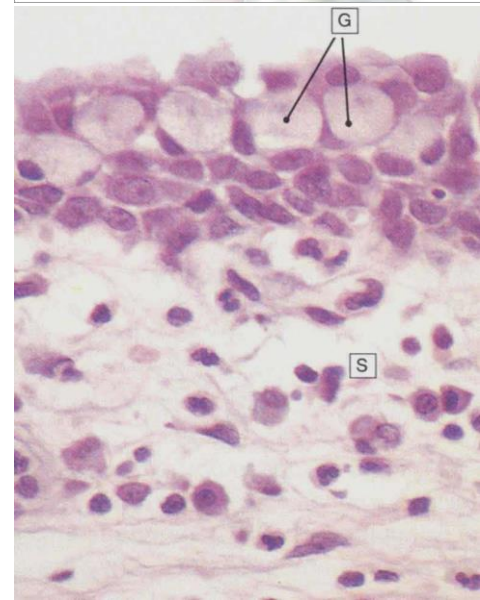
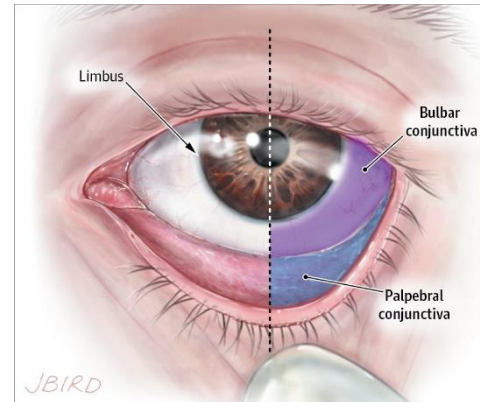
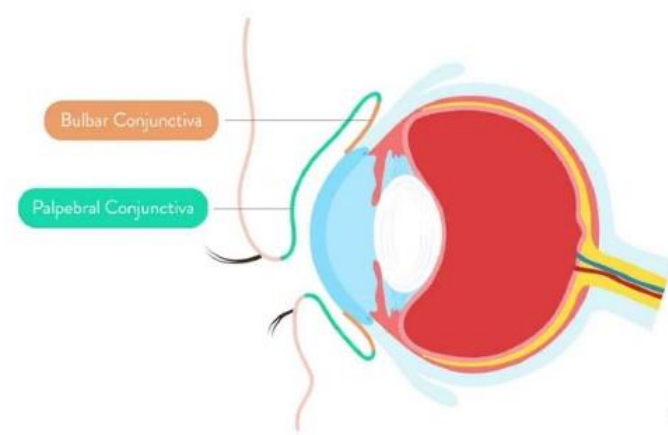
- periorbita
 - membrana orbitalis (+ m. orbitalis)
- vagina bulbi (= capsula *Tenoni*)
 - lig. suspensorium bulbi
- septum orbitale
- spatium episclerale
- corpus adiposum orbitae
- fasciae musculares bulbi



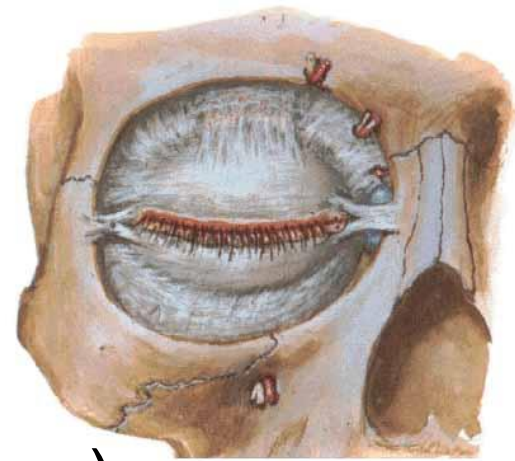
Conjunctiva

Tunica conjunctiva

- t.c.bulbi et palpebrarum
- fornix superior + inferior
- continuation of epithelium anterius cornea, continues to facies posterior palpebrae and covers the anterior surface of the eyeball
- stratified (2-5) low cuboid to columnar epithelium
- goblet cells + lymphocytes + melanocytes
- CALT = lymphoid nodule
- lacrimal film (*irroratio lacrimarum*)
- glanduale conjunctivales *Wolfringi* (2-5 superiorly)
- glandulae lacrimales accessoriae *Krausei* (5-40 superiorly, 1-10 inferiorly)
- caruncula lacrimalis

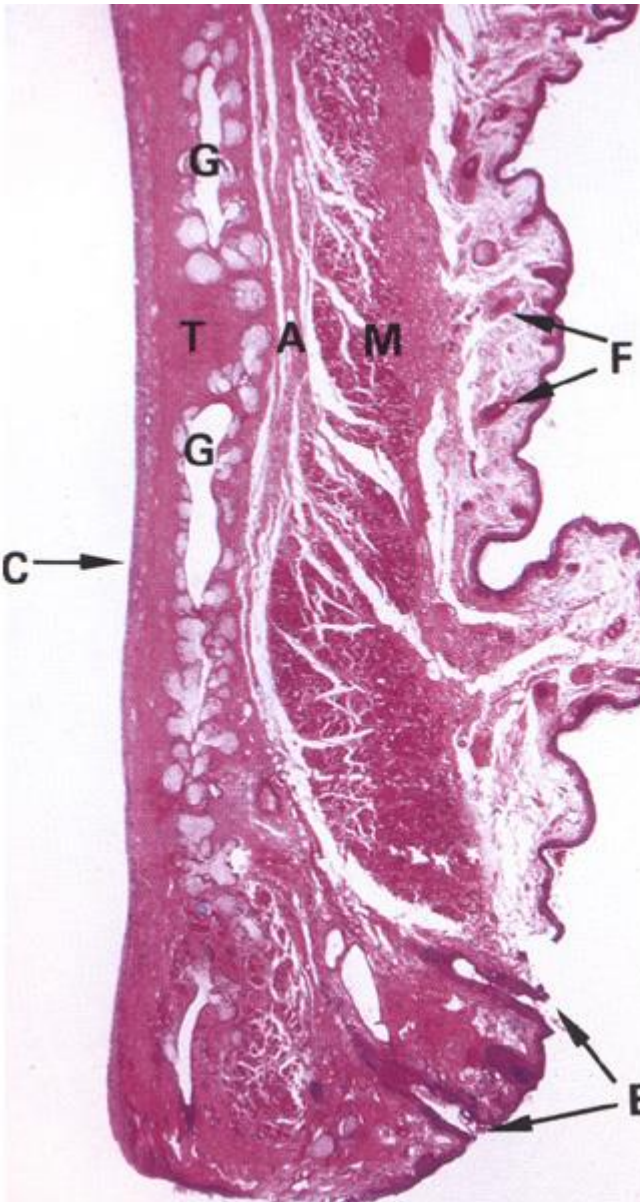


Eyelids = *Palpebrae*

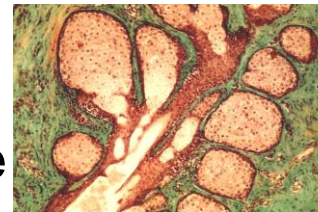
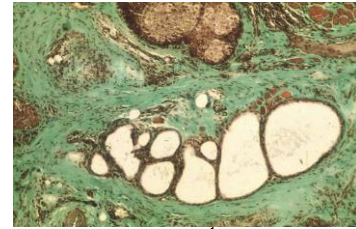
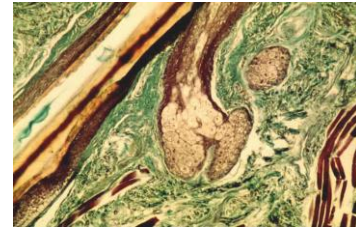


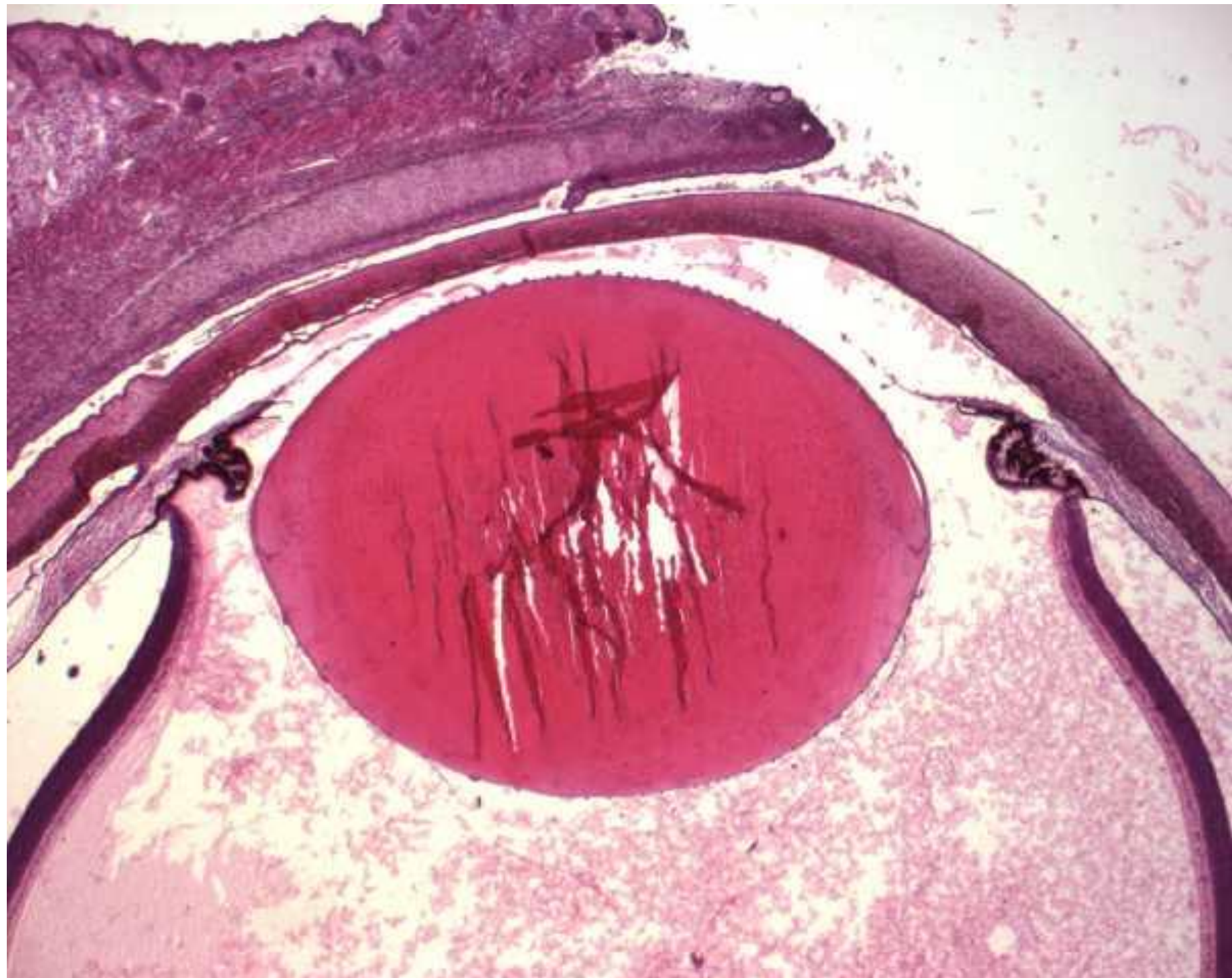
- palpebra superior + inferior
- tarsus superior (10 mm) + inferior (5 mm)
- lig. palpebrale med. (2 bands) + lat.
- rima palpebrarum, commissura palp. med.+lat.
- facies ant.+post., limbus ant.+ post.
- angulus oculi med.+ lat.
- m. tarsalis sup.(Mülleri) + inf. – *smooth muscles*
- pars palpebralis m. orbicularis oculi – n. VII
- m. levator palpebrae superioris – n. III
- eyelashes = cilia

Eyelids = *Palpebrae*



- outer cutaneous part
 - stratified squamous keratinizing epithelium
 - no adipose tissue
 - gll. sebaceae *Zeissi*
 - sebaceous glands – *hordeolum*
 - eyelashes (cilia) + gll. ciliares *Molli*
 - apocrine glands
- m. orbicularis oculi (p. palpebralis)
- tarsus
 - fibroelastic plate
 - gll. tarsales *Meibomi* (20-30)
 - sebaceous glands – *chalazion*
- inner conjunctival part
 - epithelial transition – groove

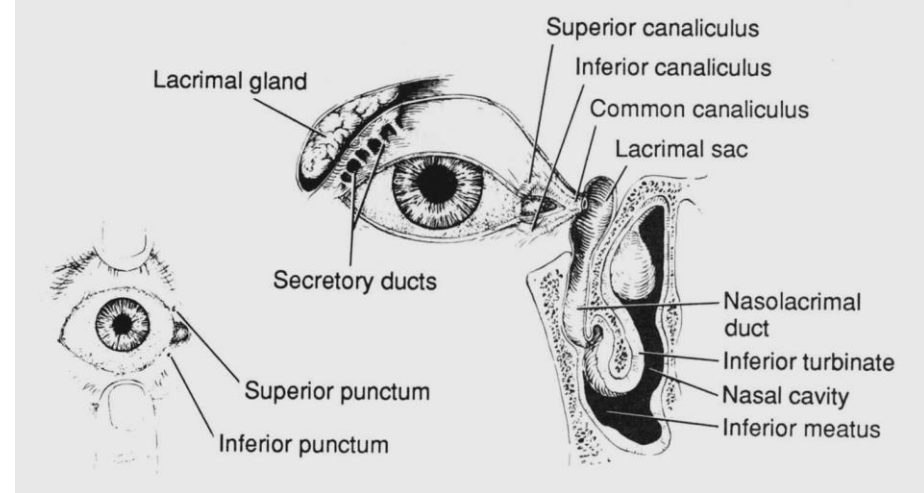




Lacrimal apparatus

Apparatus lacrimalis

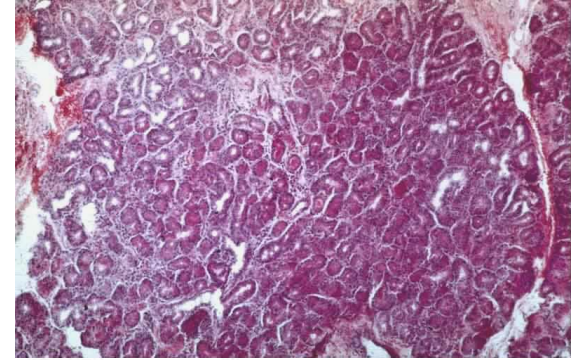
- glandula lacrimalis
 - pars orbitalis + palpebralis
 - 12–15 individual ductus excretorii
- glandulae lacrimales accessoriae *Krausei*
- rivus lacrimalis
- lacus, papilla, caruncula lacrimalis
- punctum, canaliculus lacrimalis sup.+inf. → communis
- saccus lacrimalis → ductus nasolacrimalis (features plica lacrimalis *Hasneri*) → meatus nasi inf.
- more little fine folds within excretory lacrimal excretory system



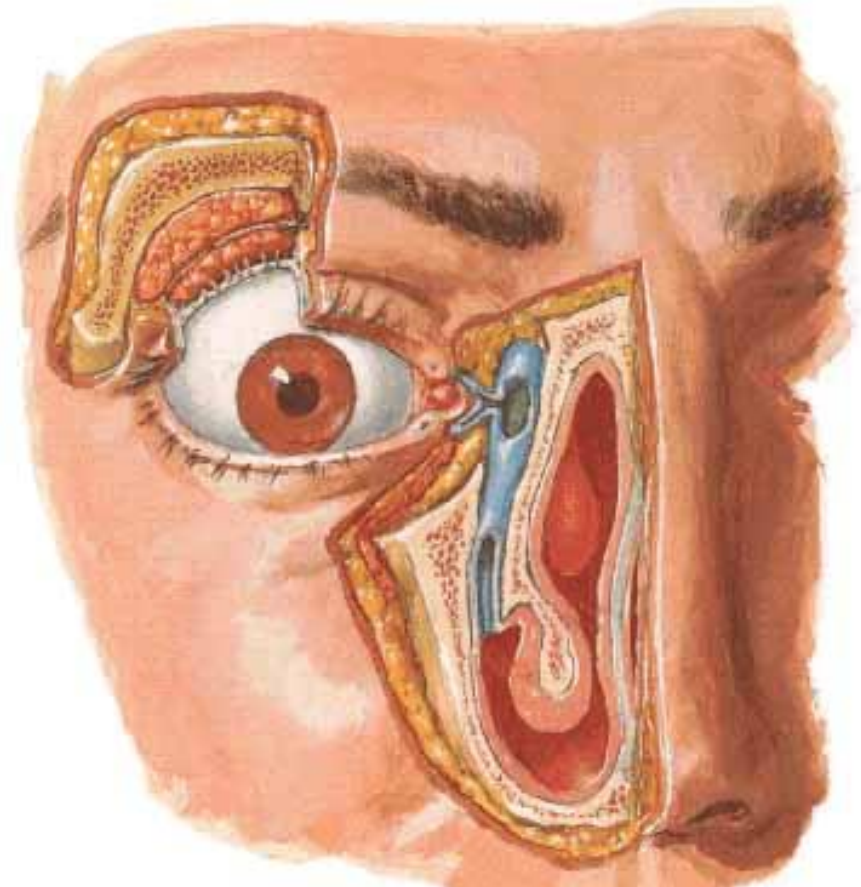
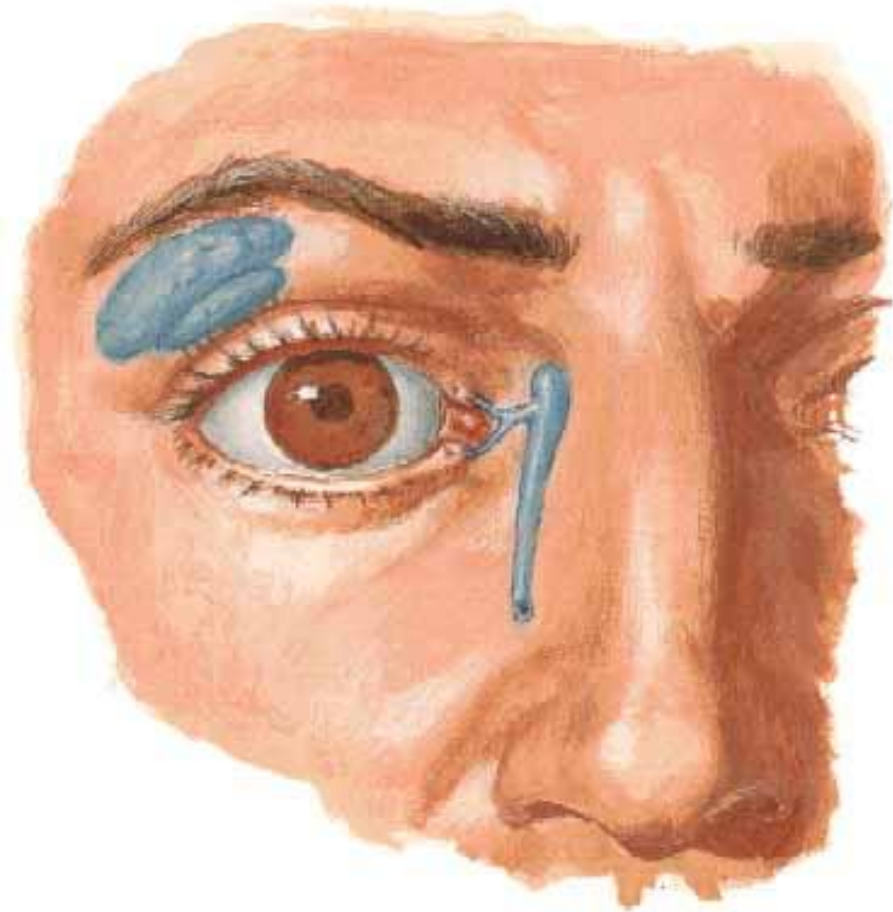Glandula lacrimalis

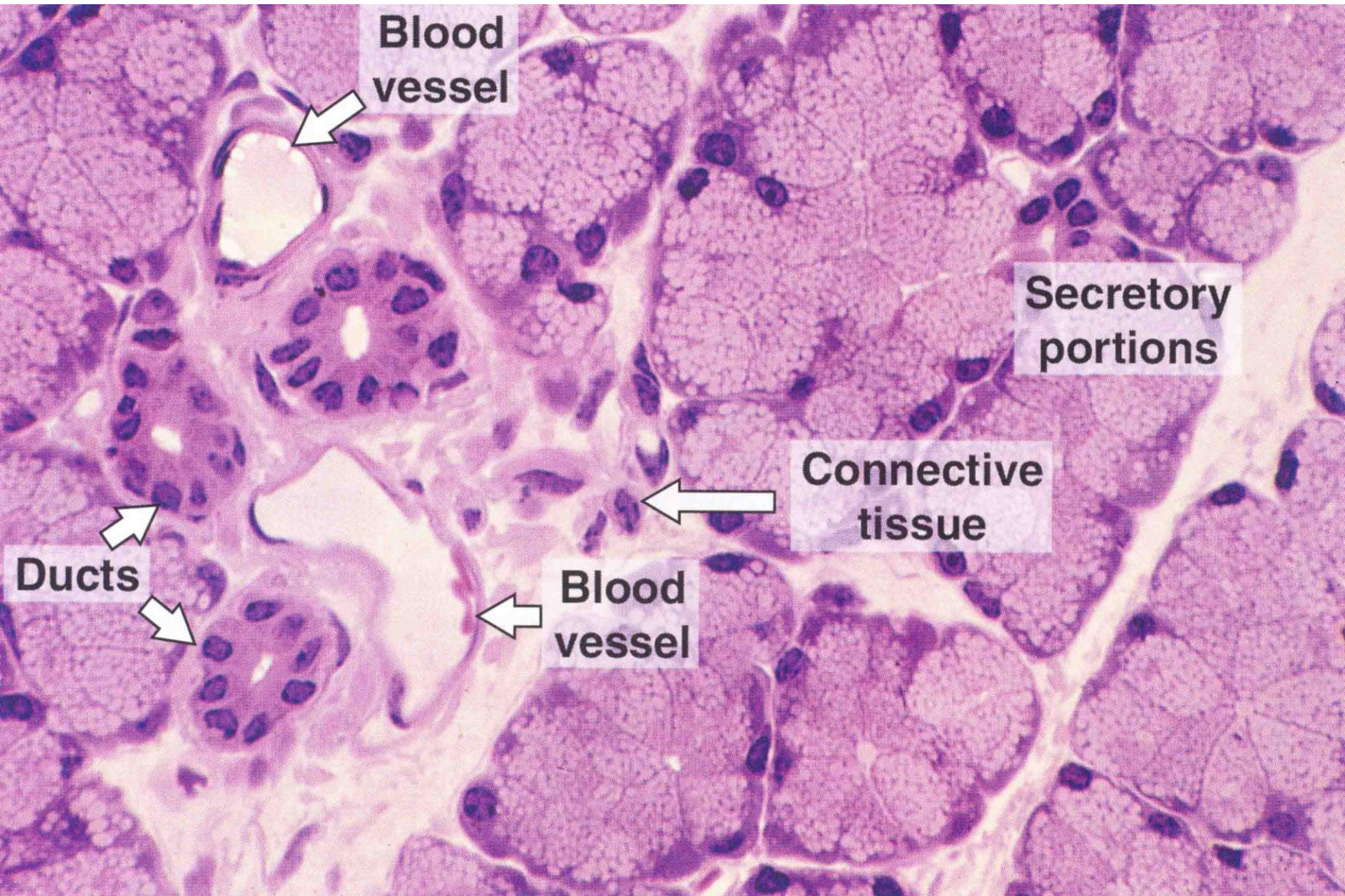
- tuboacinar serous glands with myoepithelial cells

Lacrimal Apparatus in Situ



**Lacrimal Apparatus
Dissection**





Blood vessel

Secretory portions

Connective tissue

Ducts

Blood vessel

Muscular apparatus

Apparatus muscularis

Mm. externi bulbi oculi – striated

- n. III (5 muscles), n. IV+VI (1 muscle)
- mm. **recti** bulbi: sup., inf., med., **lat. (VI.)**
- mm. **obliqui** bulbi: inf., **sup.(IV.)**
 - /fovea trochlearis, spina trochlearis, trochlea, vagina m.o.b.s./
- m. levator palpebrae sup. (pars spf.+prof.)

Smooth muscles:

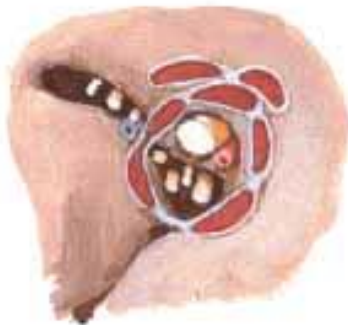
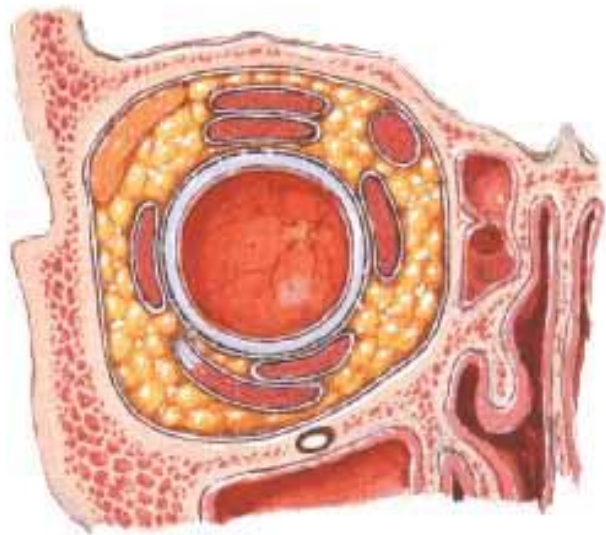
- m. orbitalis *Mülleri*
- m. tarsalis sup. *Mülleri* + inf.

Muscular apparatus

Apparatus muscularis

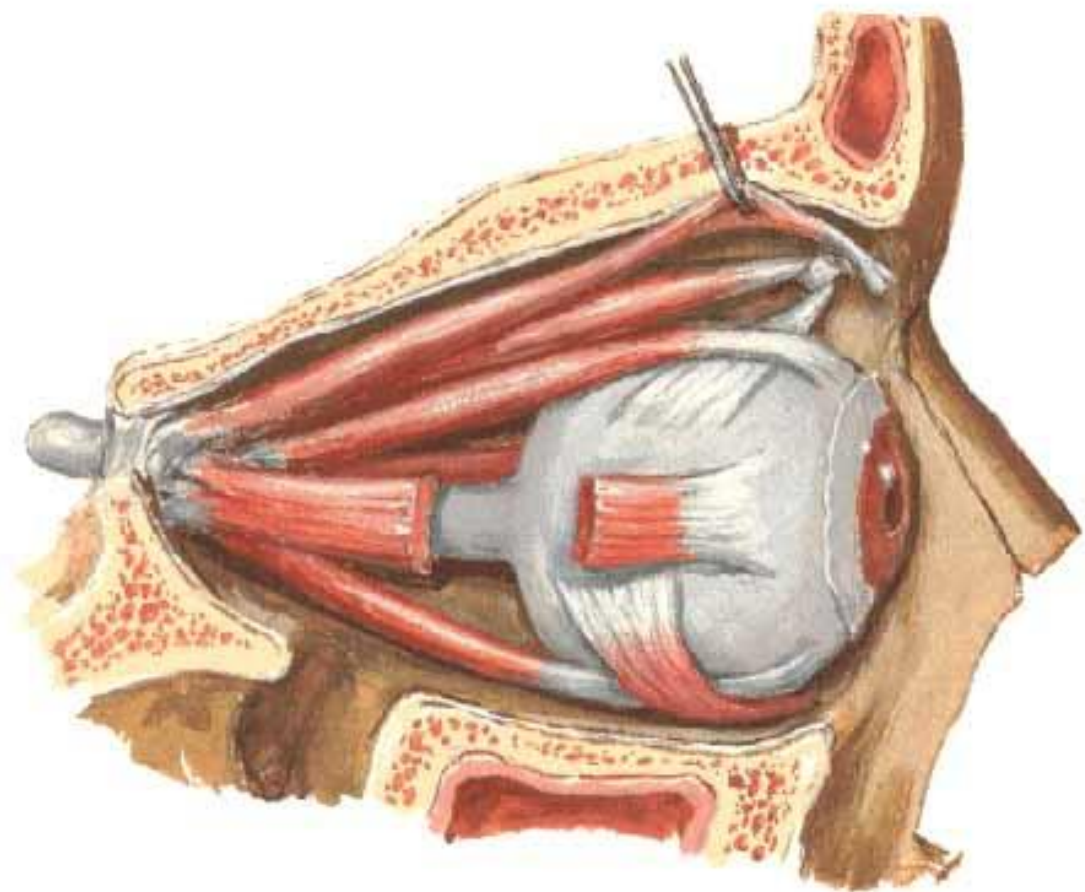
Fascia of Orbit and Eyeball

Frontal Section and Entering Structures



Extrinsic Eye Muscles

Right Lateral View



Movements of the eyeball I.

movements around axis = *ductions*

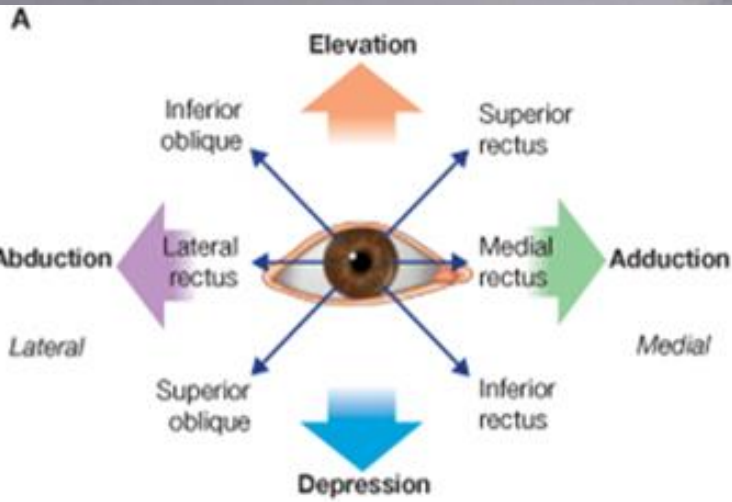
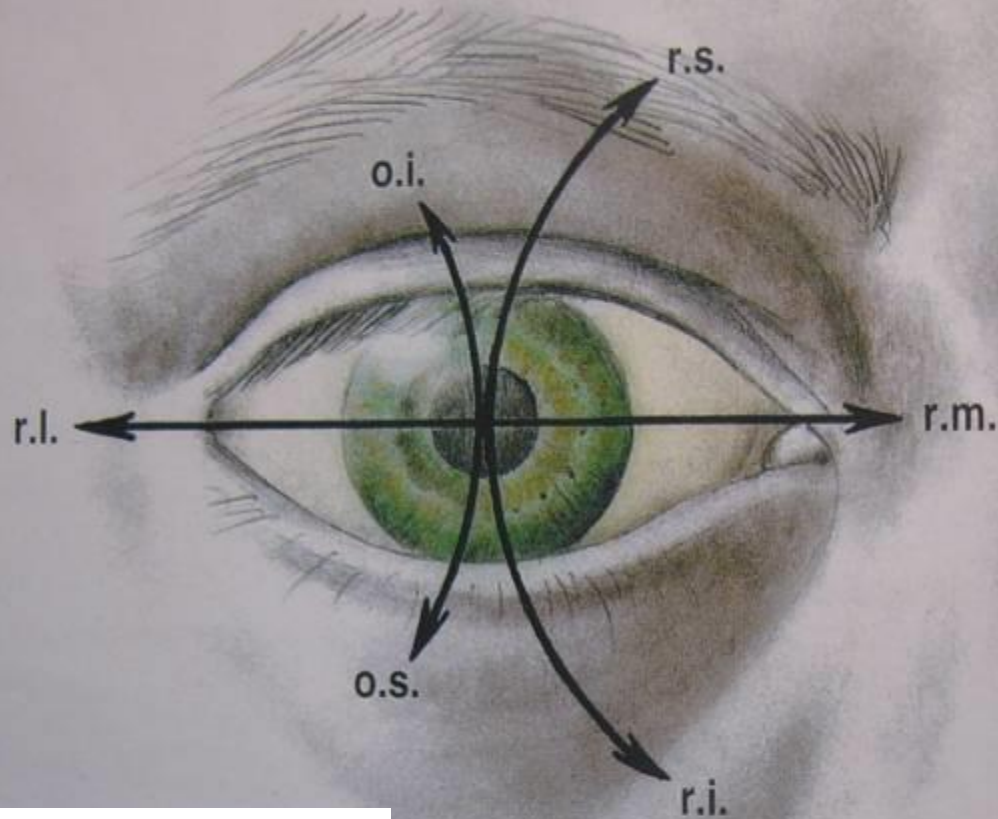
- around vertical axis:
 - **adduction** (internal)
 - **abduction** (external)
- around horizontal axis:
 - **elevation** (sursumduction; supraduction): up
 - **depression** (deorsumduction; infraduction): down
- around sagittal (antero-posterior) axis:
 - **intorsion** (incykloduction): tilted internally
 - **extorsion** (excykloduction): tilted externally

Movements of the eye-ball II.

paired movements (both eyes working together)

- simultaneous movement of both eyes in the same direction = **version (conjugate movements)**
 - **dextro**version (to the right) + **levo**version (to the left)
 - supraversion (sursumversion) + infra/deorsumversion (up + down)
 - dextro/levoelevation + dextro/levodepression (up/down and to side)
 - dextro/levocykloverversion (rotation to the right/left)
- simultaneous movement of both eyes in opposite directions = **vergence (disconjugate movements)**, convergence = both eyes moving nasally or inward , divergence = both eyes moving temporally or outward
- *strabismus; heterotropia; squint* = one eye constantly is turned inward (“crossed-eye”), outward (“wall-eye”), upward, or downward.

Movements of the eyeball



Strabismus concomitans

- esotropia (s. convergens)



- exotropia (s. divergens)



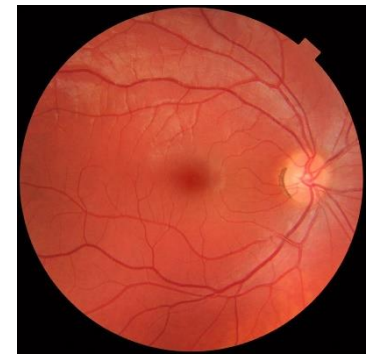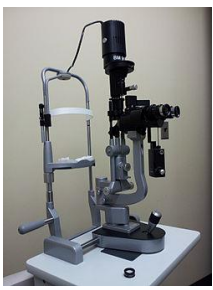- hypertropia (s. sursumvergens)



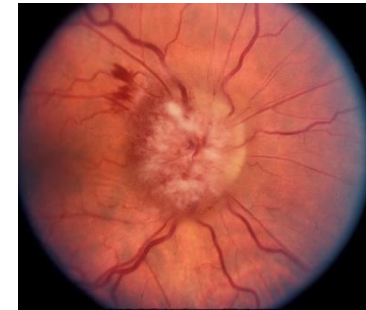- hypotropia (s. deosumvergens)



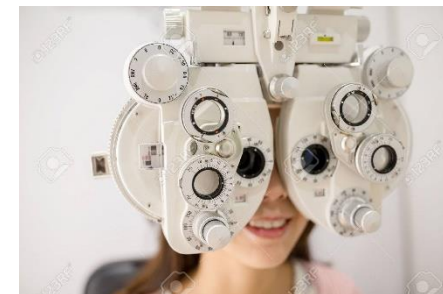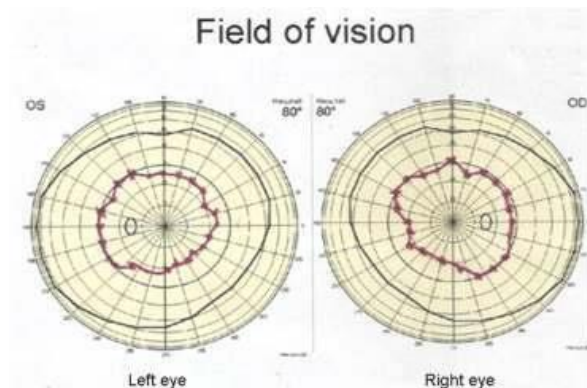
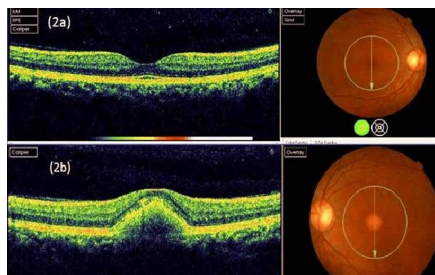

Examination



- slit lamp examination
- ophthalmoscopy (fundoscopy)
 - swollen optic disc (papilledema) = raised intracranial pressure



- perimetry = examination of field vision
- optotypes, e.g. Snellen eye chart
- optometry
- OCT

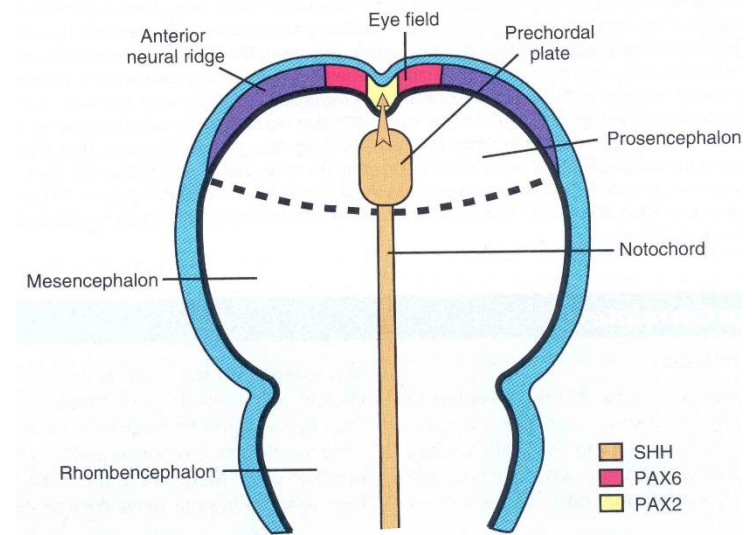


Symptoms and defects

- epiphora (excessive lacrimation)
- myopy – hypermetropy
- *hypermetry (cerebellar disorder!)*
- presbyopy
- hemeralopy
- amblyopy – *functional disorder (e.g. in squint)*
- daltonism

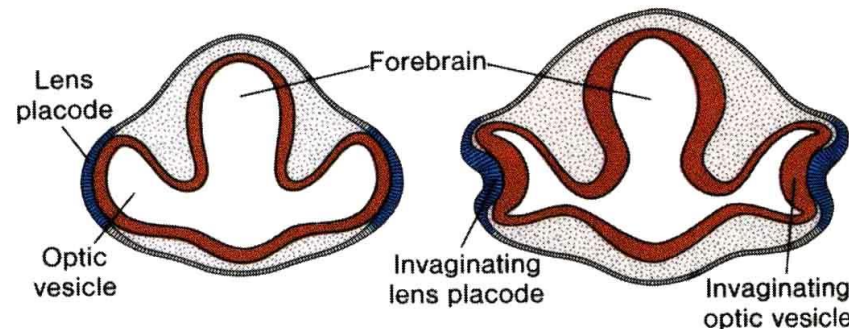
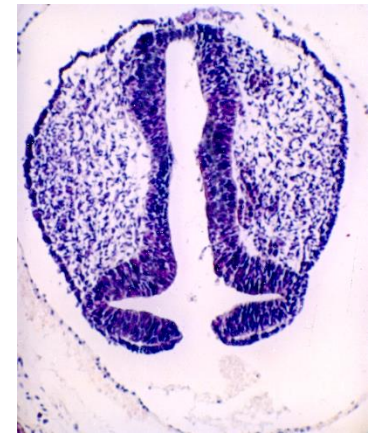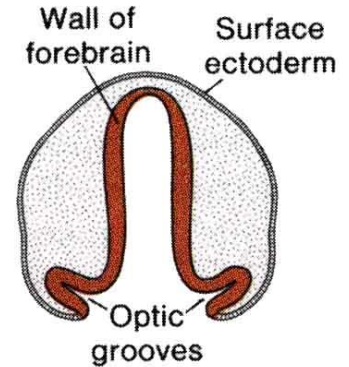
Development of visual system

- neuroectoderm of the forebrain
- superficial ectoderm of head
- mesoderm in between
- cells from neural crest

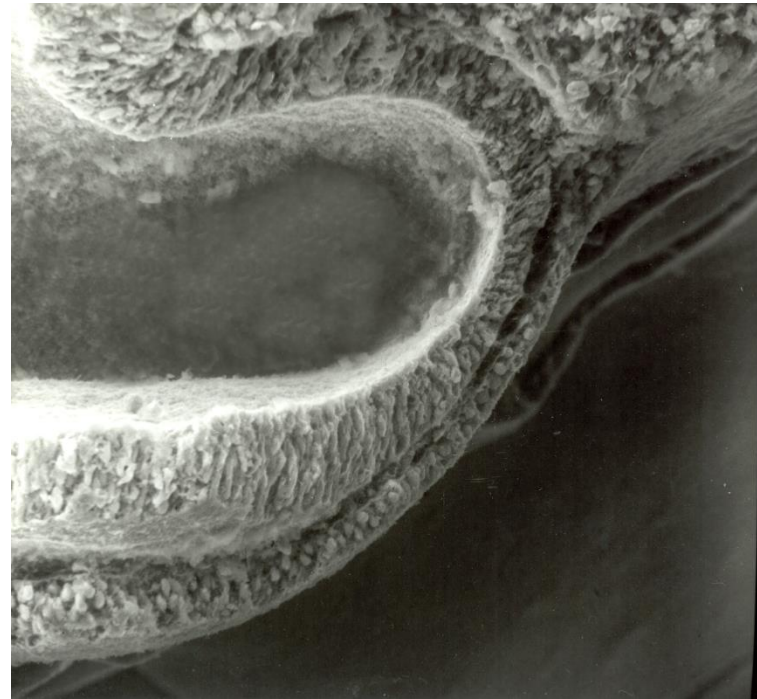
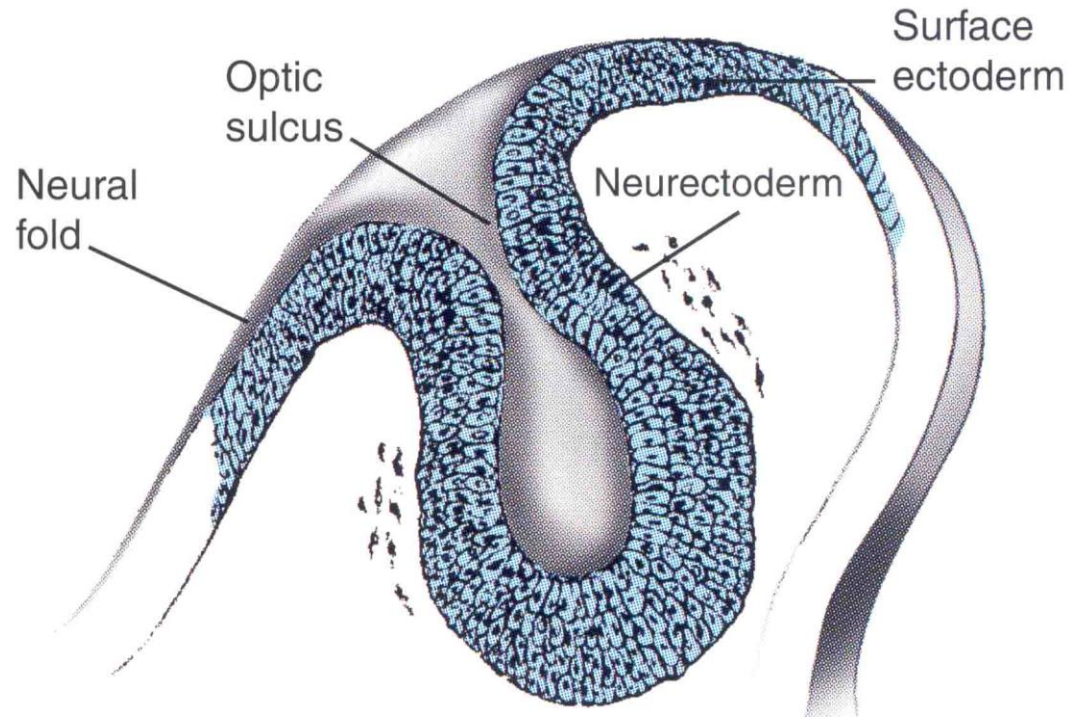
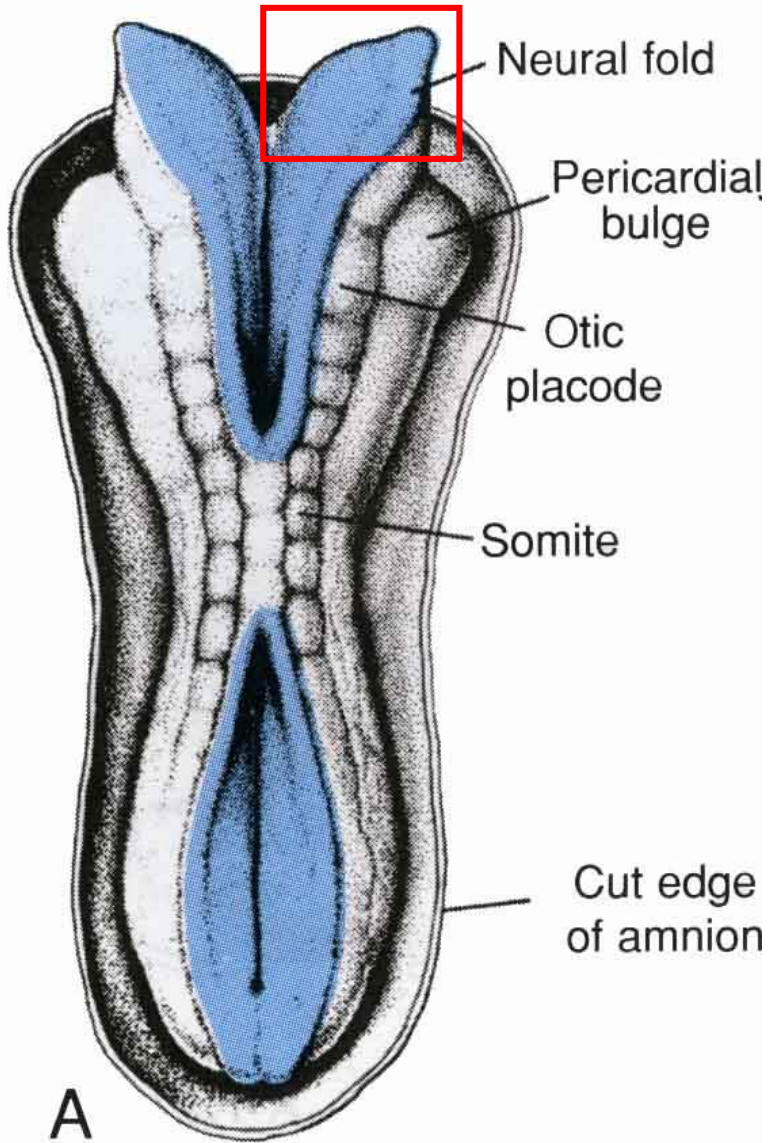


Development of visual system

- primordia from beginning of 4th week (22nd day)
- formation of optic **grooves** in the region of forebrain
- grooves deepen in optic **vesicles**
- formation of optic **peduncle**
- induction of ectoderm = thickening
- formation of **lens (optic) placode**



Day 22



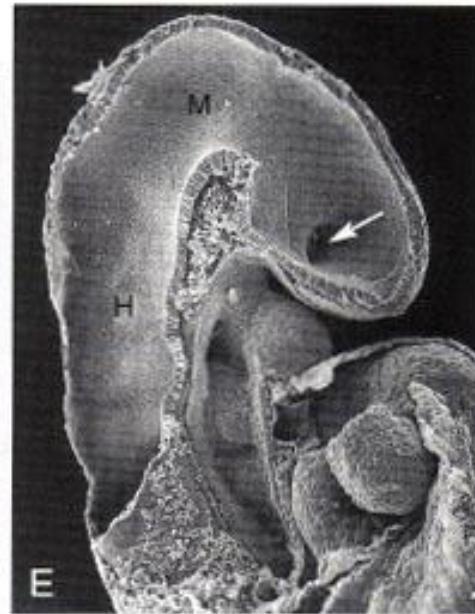
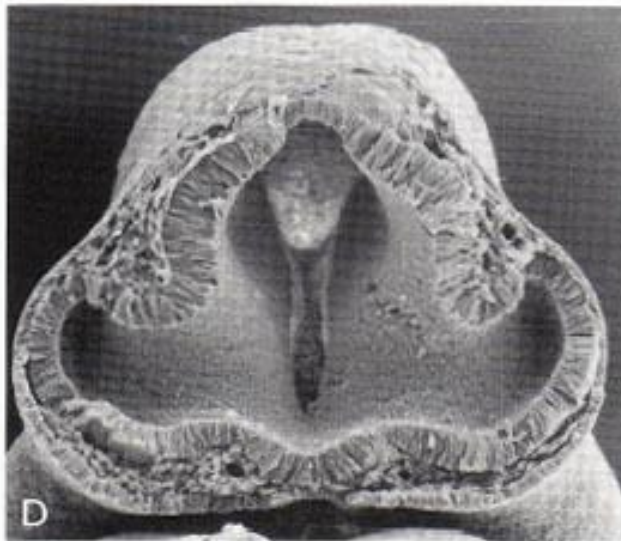
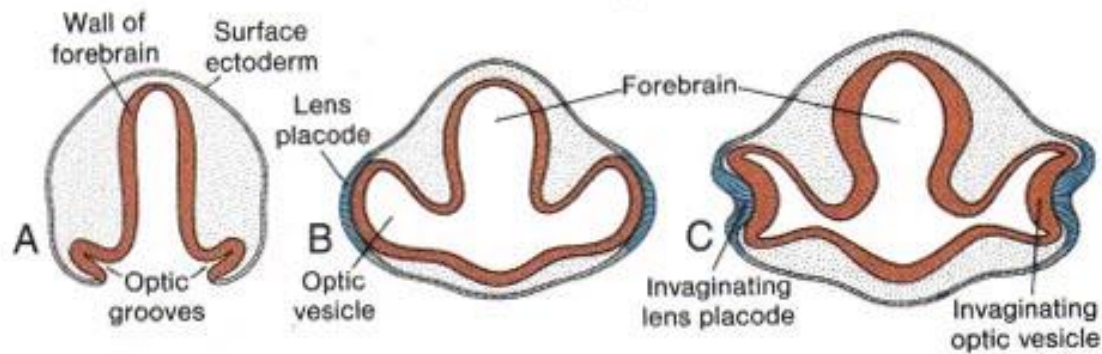
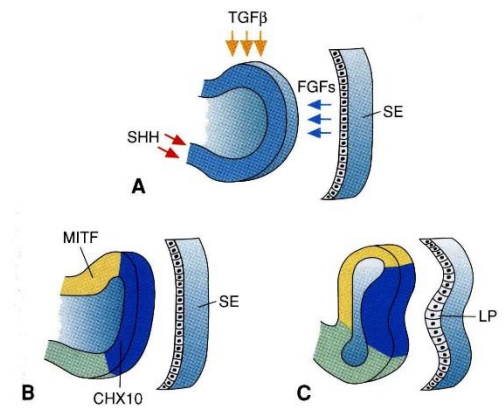


Figure 17.1. A. Transverse section through the forebrain of a 22-day embryo (approximately 14 somites), showing the optic grooves. B. Transverse section through the forebrain of a 4-week embryo showing the optic vesicles in contact with the surface ectoderm. Note the slight thickening of the ectoderm (lens placode). C. Transverse section through the forebrain of a 5-mm embryo showing invagination of the optic vesicle and the lens placode. D. Scanning electron micrograph showing a frontal view of a mouse embryo at a stage similar to that shown in B. E. Scanning electron micrograph of a mouse embryo during formation of the optic vesicle. The embryo has been cut sagittally to reveal the inside of the brain vesicles and outpocketing of the optic vesicle (arrow) from the forebrain. H, hindbrain; and M, midbrain.

Development of visual system

- invagination of lens (optic) placode
- formation of hollow lens vesicle without connection to the external surface
- optic vesicles invaginate = optic **cup**
- invagination of optic pedicle and cup + migration of vascular mesenchyme = formation of vitreous vessels

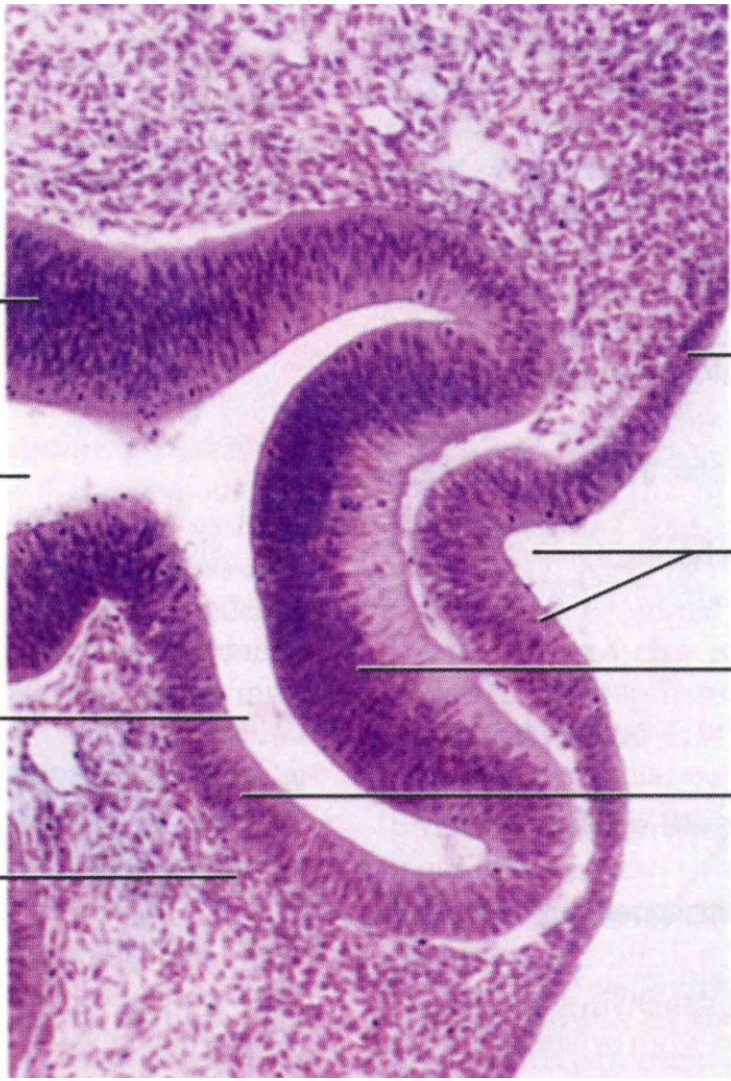

stěna optické stopky
(přecházející ve stěnu
předního mozku)

dutina optické stopky
(související s dutinou
předního mozku)

intraretinální prostor

mezenchym (primordium
cévnatky a skléry)



povrchový ektoderm

čočková jamka
(invaginovaná čočková
plakoda)

vnitřní vrstva očního po-
hárku (primordium op-
tické části sítnice)

zvní vrstva očního po-
hárku (základ pigmen-
tového epitelu sítnice)

Day 32

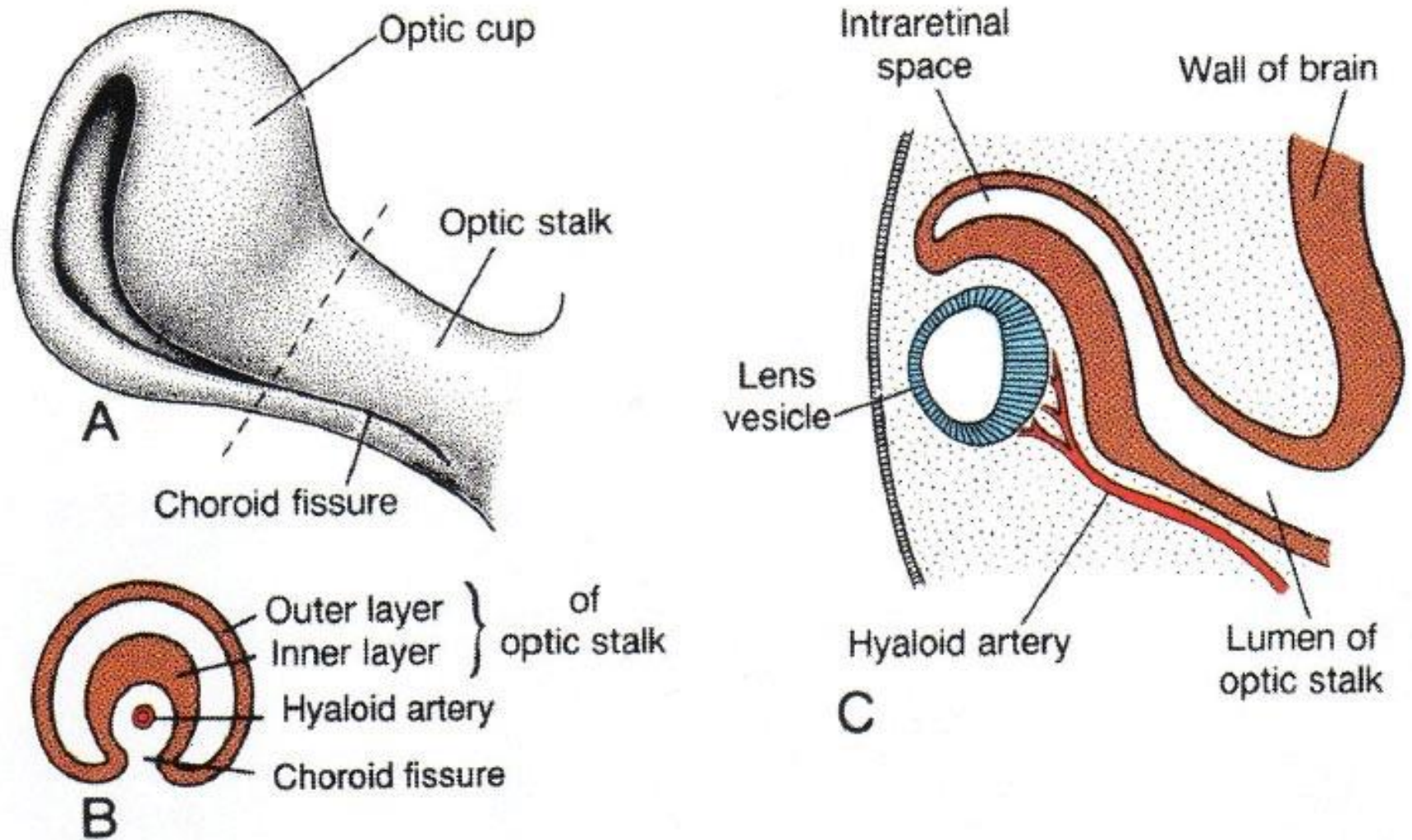
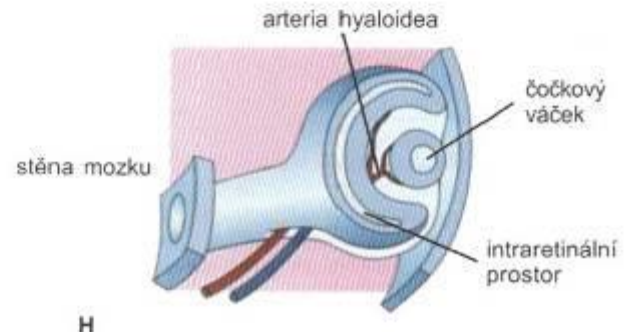
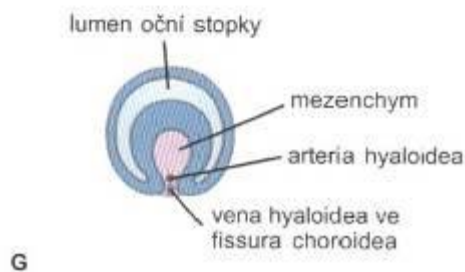
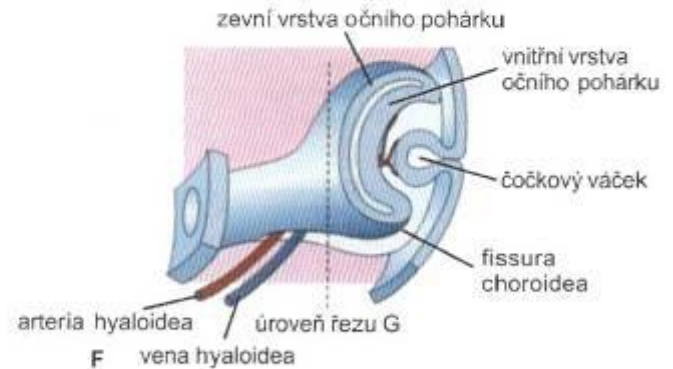
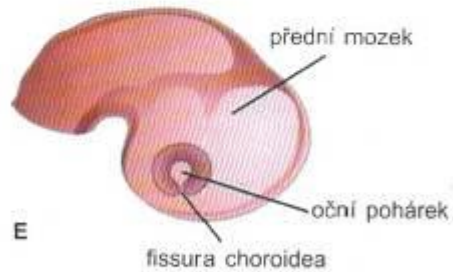
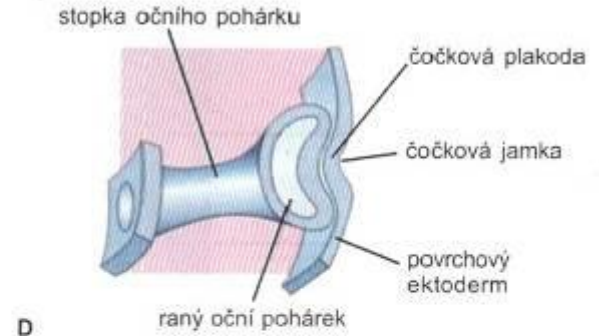
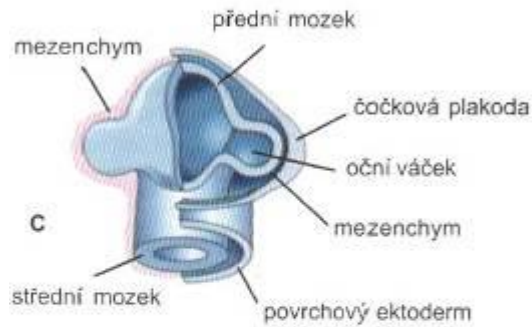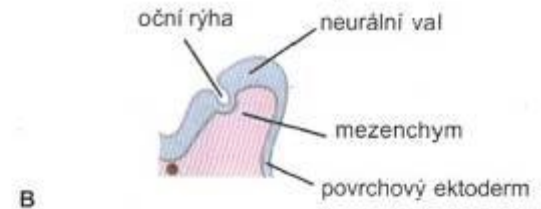
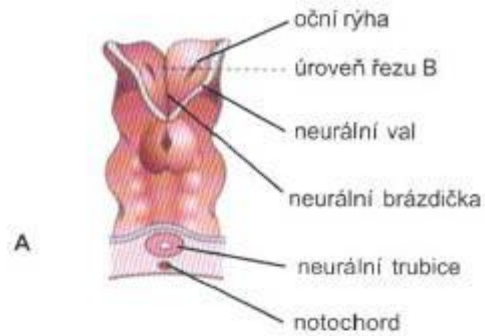


Figure 17.2. **A.** Ventrolateral view of the optic cup and optic stalk of a 6-week embryo. The choroid fissure on the undersurface of the optic stalk gradually tapers off. **B.** Transverse section through the optic stalk as indicated in **A**, showing the hyaloid artery in the choroid fissure. **C.** Section through the lens vesicle, the optic cup, and optic stalk at the plane of the choroid fissure.



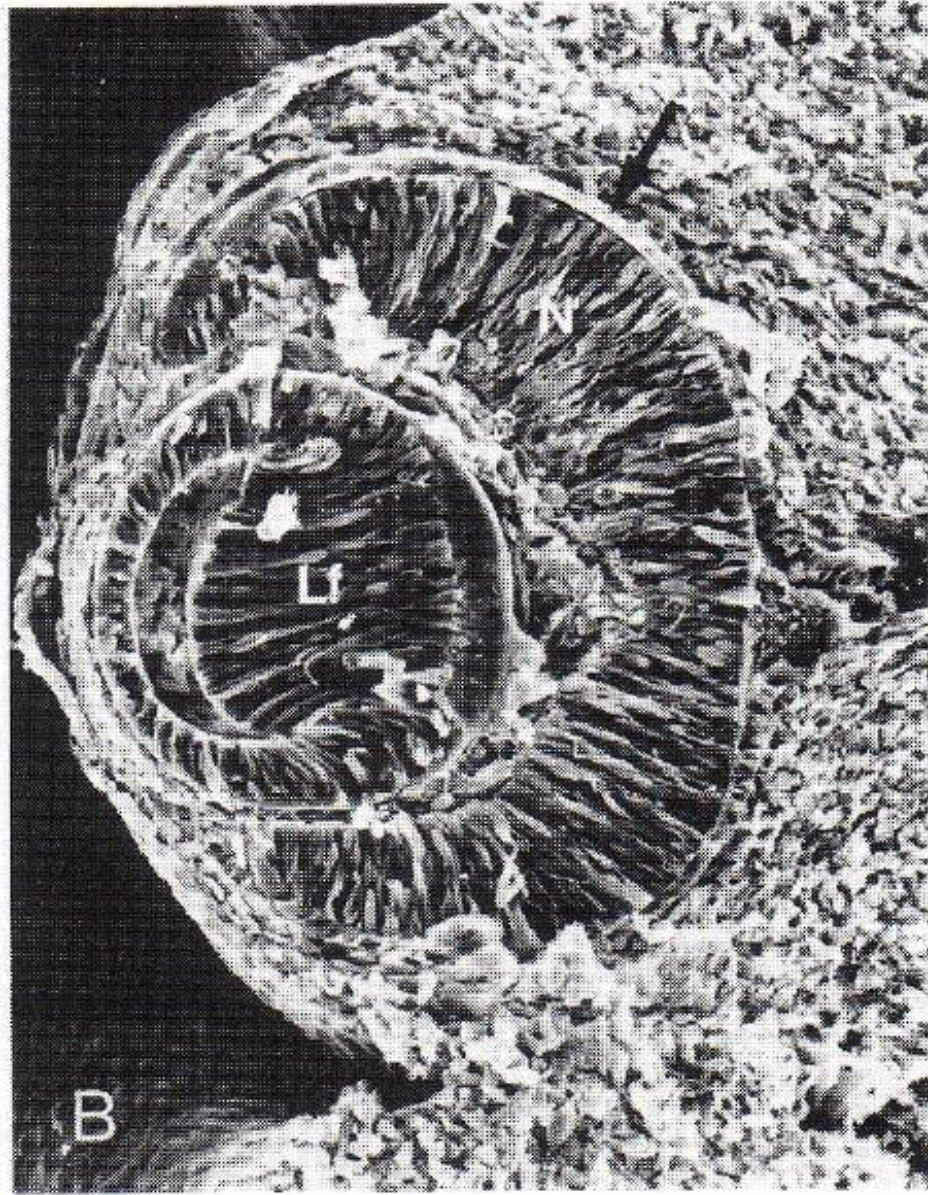
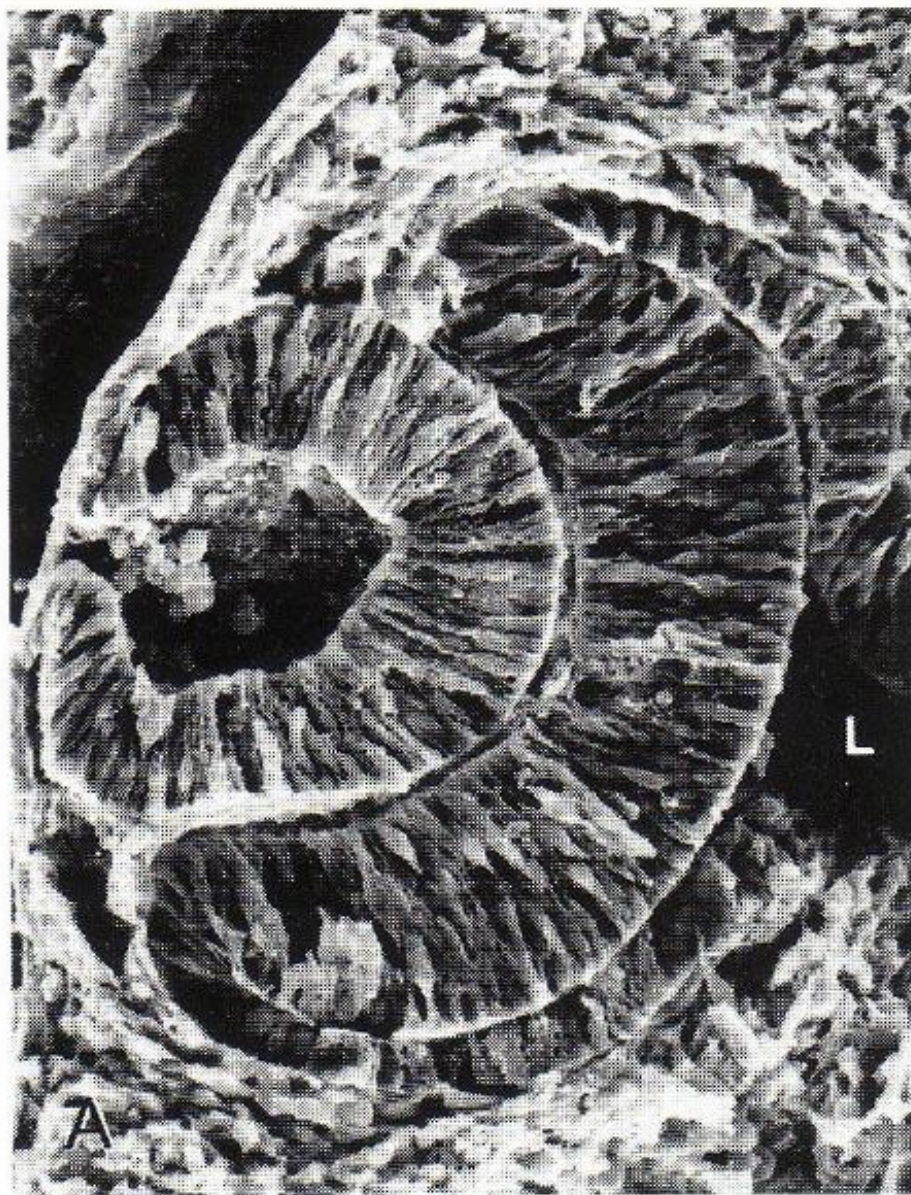
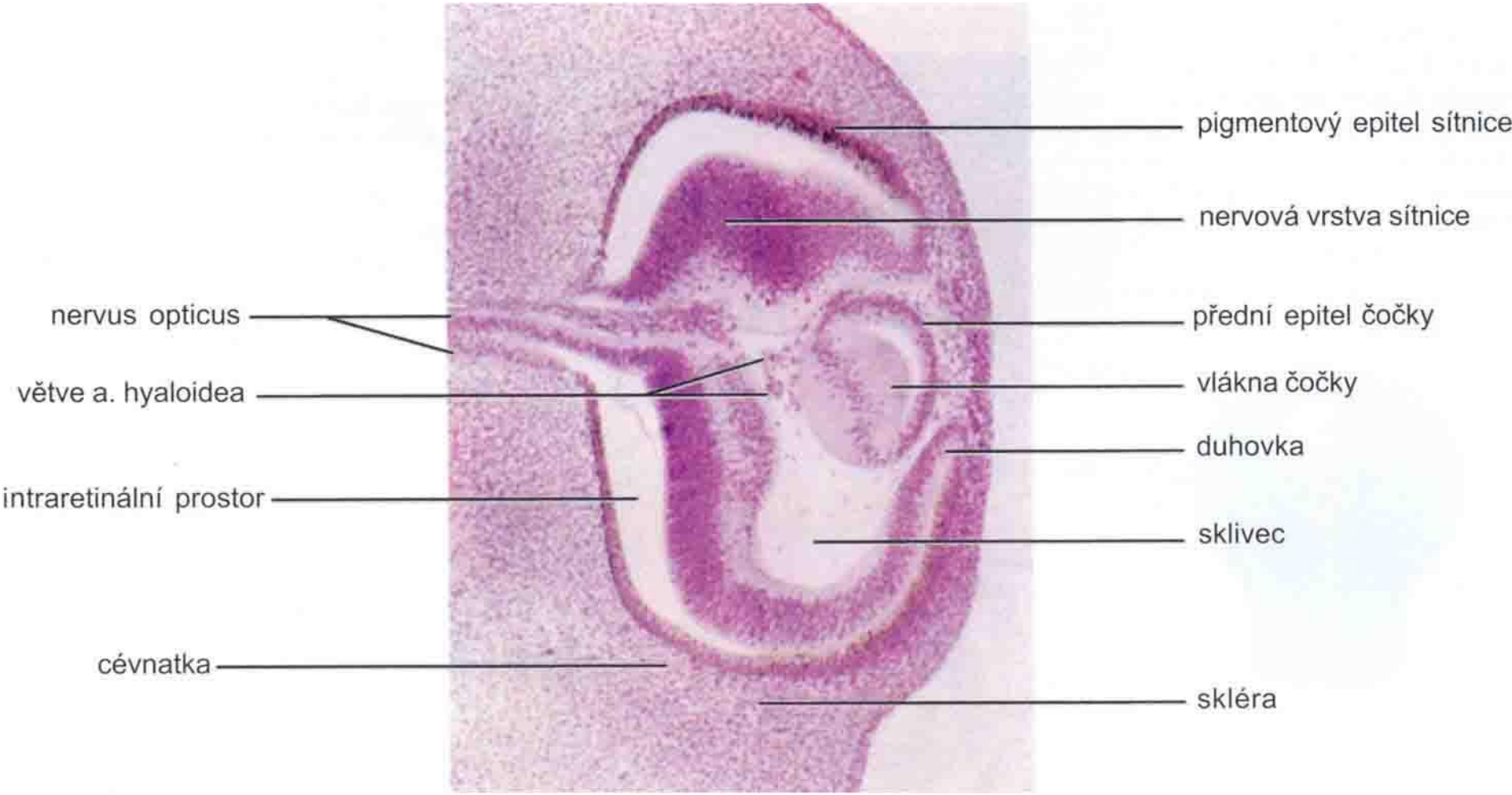


Figure 17.4. Scanning electron micrographs of sections through the eyes of mouse embryos at stages equivalent to (A) 6 weeks and (B) 7 weeks in the human. A. The

Development of retina

- origin from optic cup
- external layer – pigment epithelium
- internal layer – proliferates into pars nervosa
- intraretinal space – successively fades out
- inversion of retina



Day 44

Development of nervus opticus

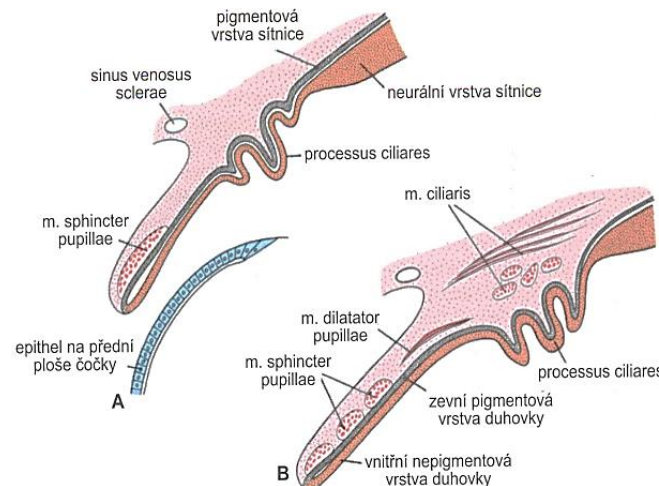
- fibres from ganglionic cells growth through the optic pedicle
- cavity of the optic pedicle fades out
- fissure (evagination) fades out

Development of visual system in motion

- <https://www.youtube.com/watch?v=ghHDFWlfpoQ>
- <https://www.youtube.com/watch?v=Xme8PA6xv-M>

Development of corpus ciliare

- protrusion of both layers of optic cup
- pigmented epithelium – from external layer
- non-pigmented epithelium – from internal layer
- ciliary canal – from optic cup cavity
- m. ciliaris and connective tissue – from mesenchyme

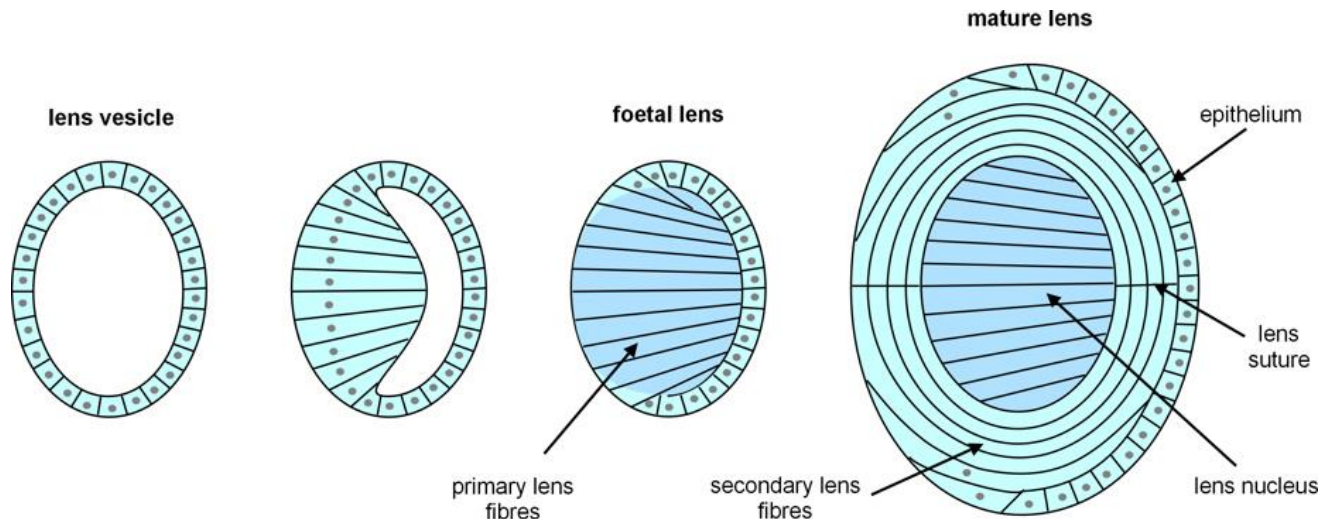


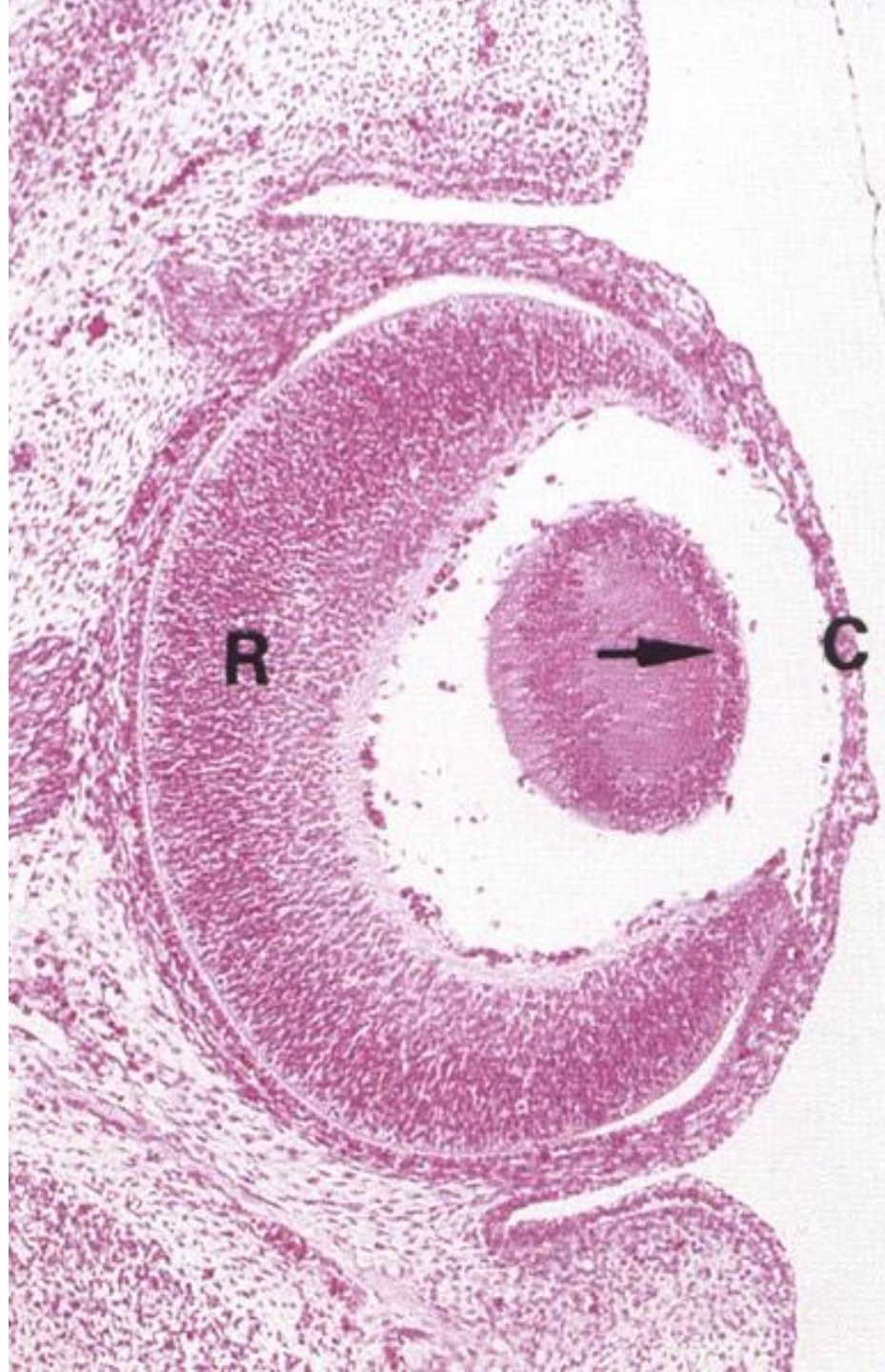
Development of iris

- margin of eye cup
- external layer → smooth muscles
- internal layer → pigmented epithelium

Development of lens

- from lens (optic) vesicle
 - anterior surface – no change = *epithelium anterius*
 - posterior surface – cells elongate as far as lumen disappears
 - formation of primary fibers
 - secondary fibers – derived from cells of *epithelium anterius*
 - capsula lentis – thickened BL of *epithelium anterius*
- a. hyaloidea – fades out
- pupillary membrane – covering lens – fades out



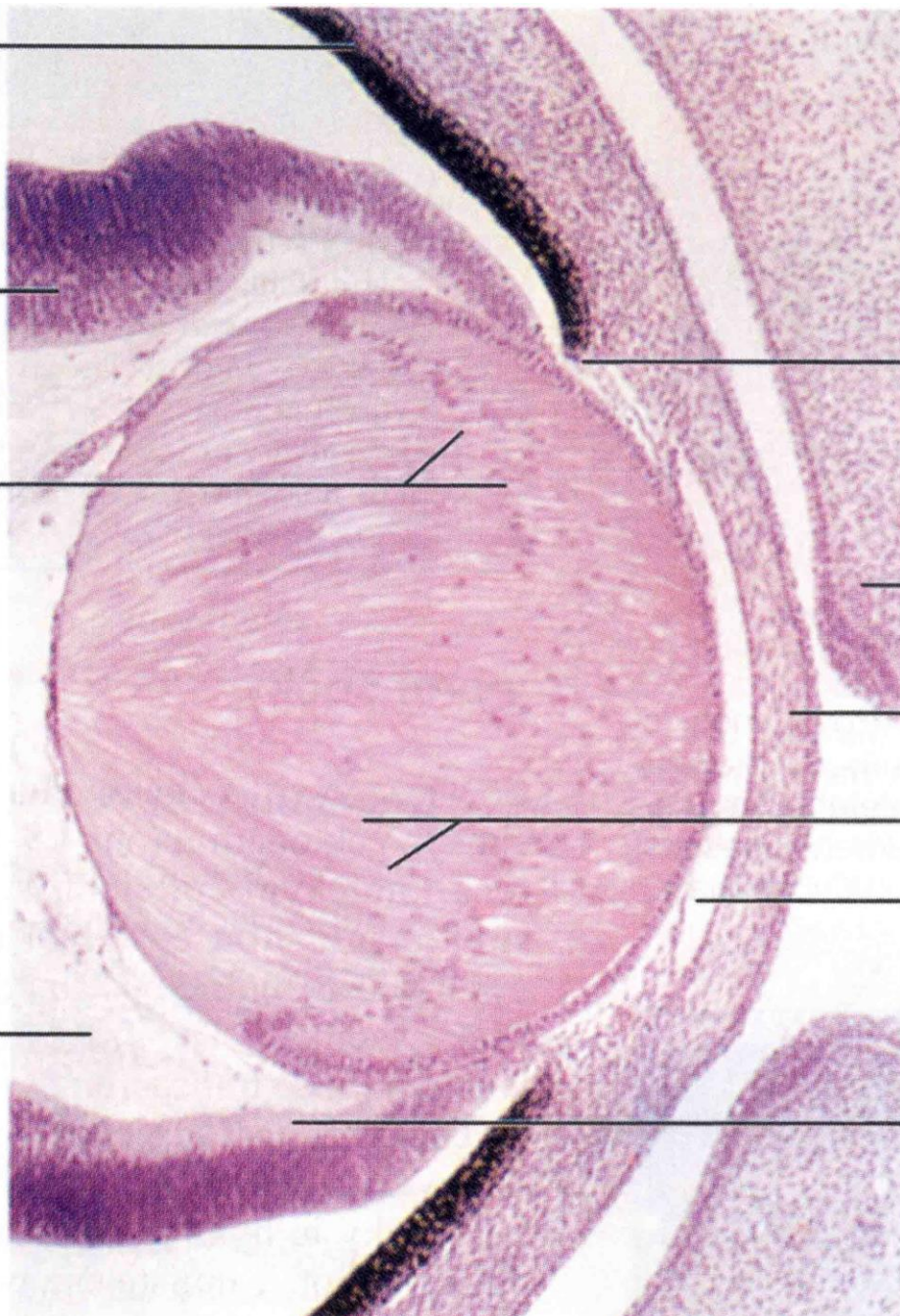

pigmentový
epitel sítnice

nervová
vrstva sítnice

jádra buněk
ekvatoriální
zóny čočky

sklivec



iris

oční víčko

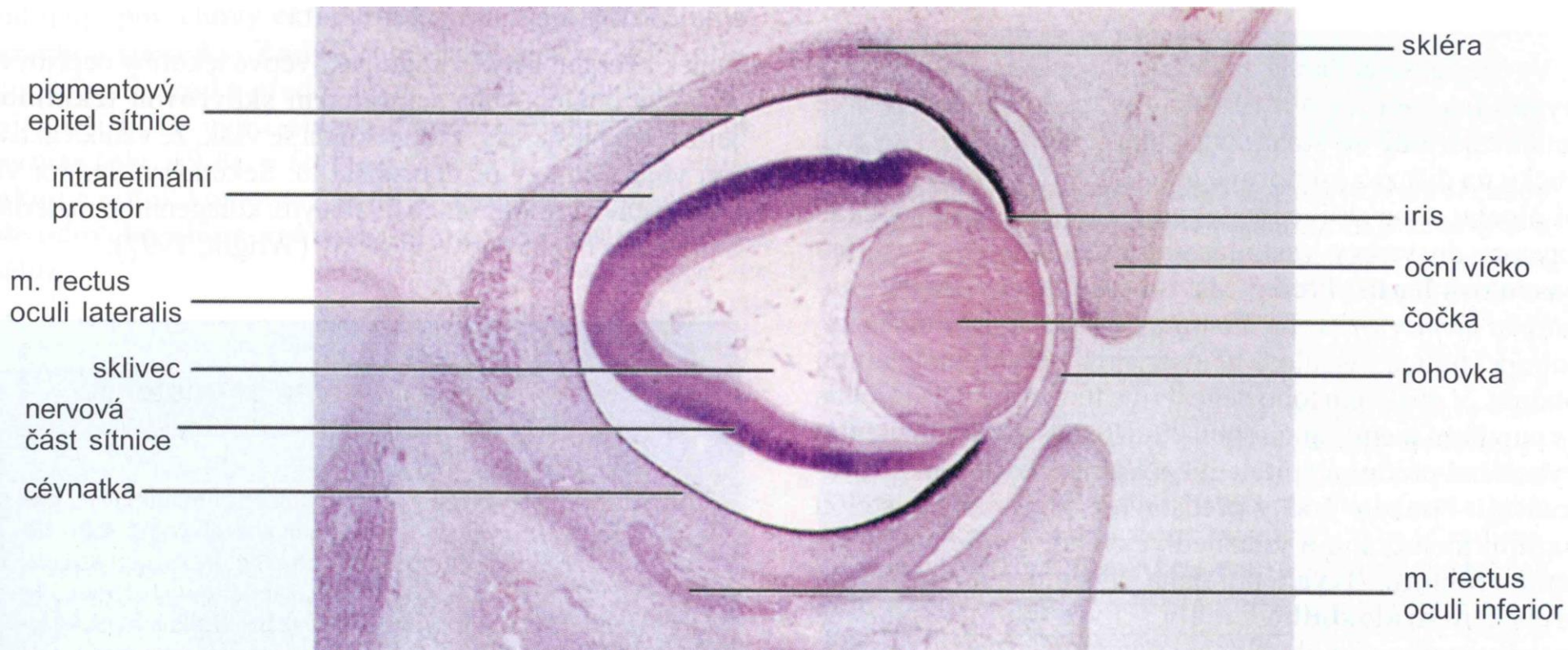rohovka

vlákna čočky

vyvíjející se přední ko-
mora

pars caeca retinae

Day 56



Day 56

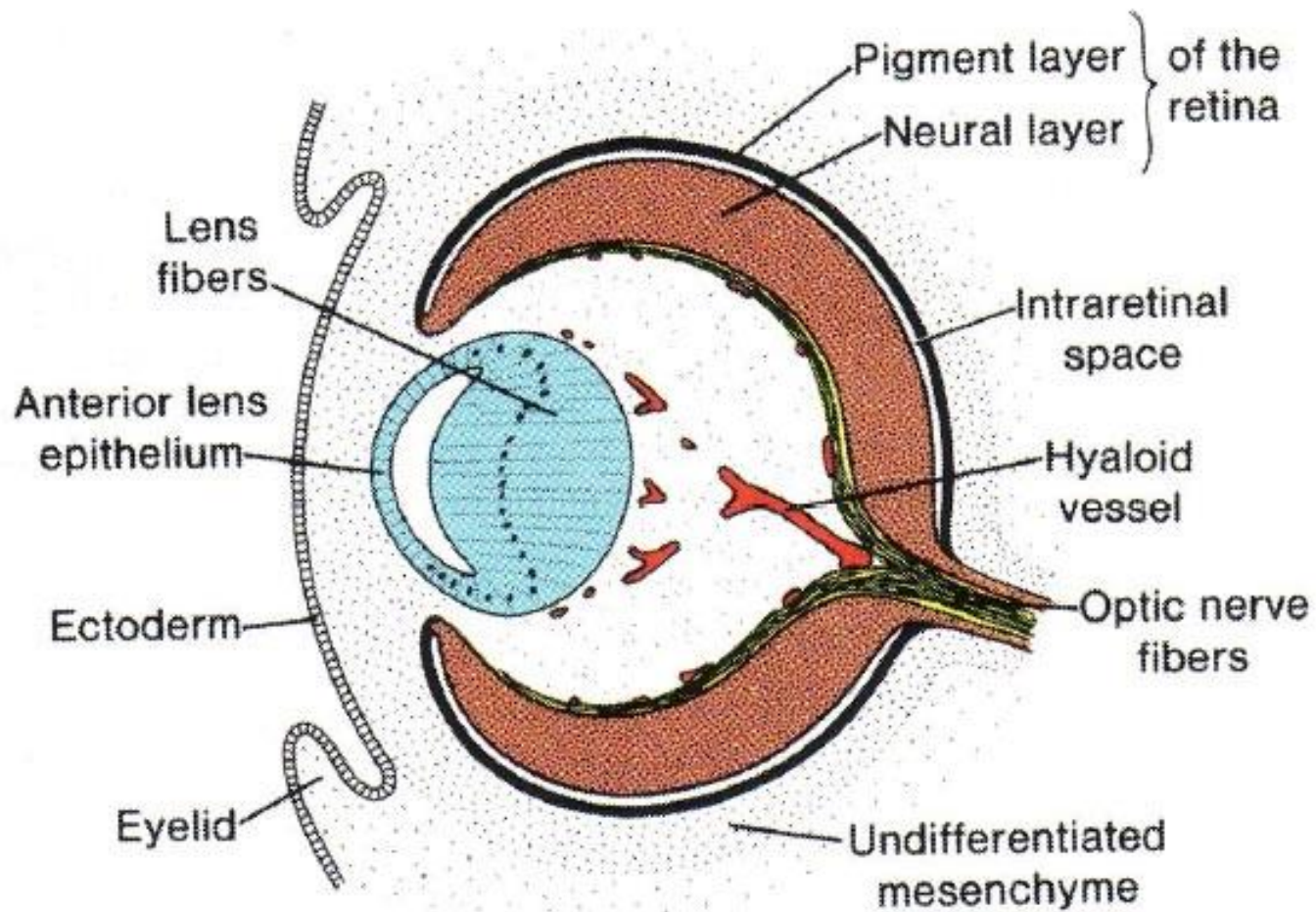


Figure 17.3. Section through the eye of a 7-week embryo. The eye primordium is completely embedded in mesenchyme. Fibers of the neural retina converge toward the optic nerve.

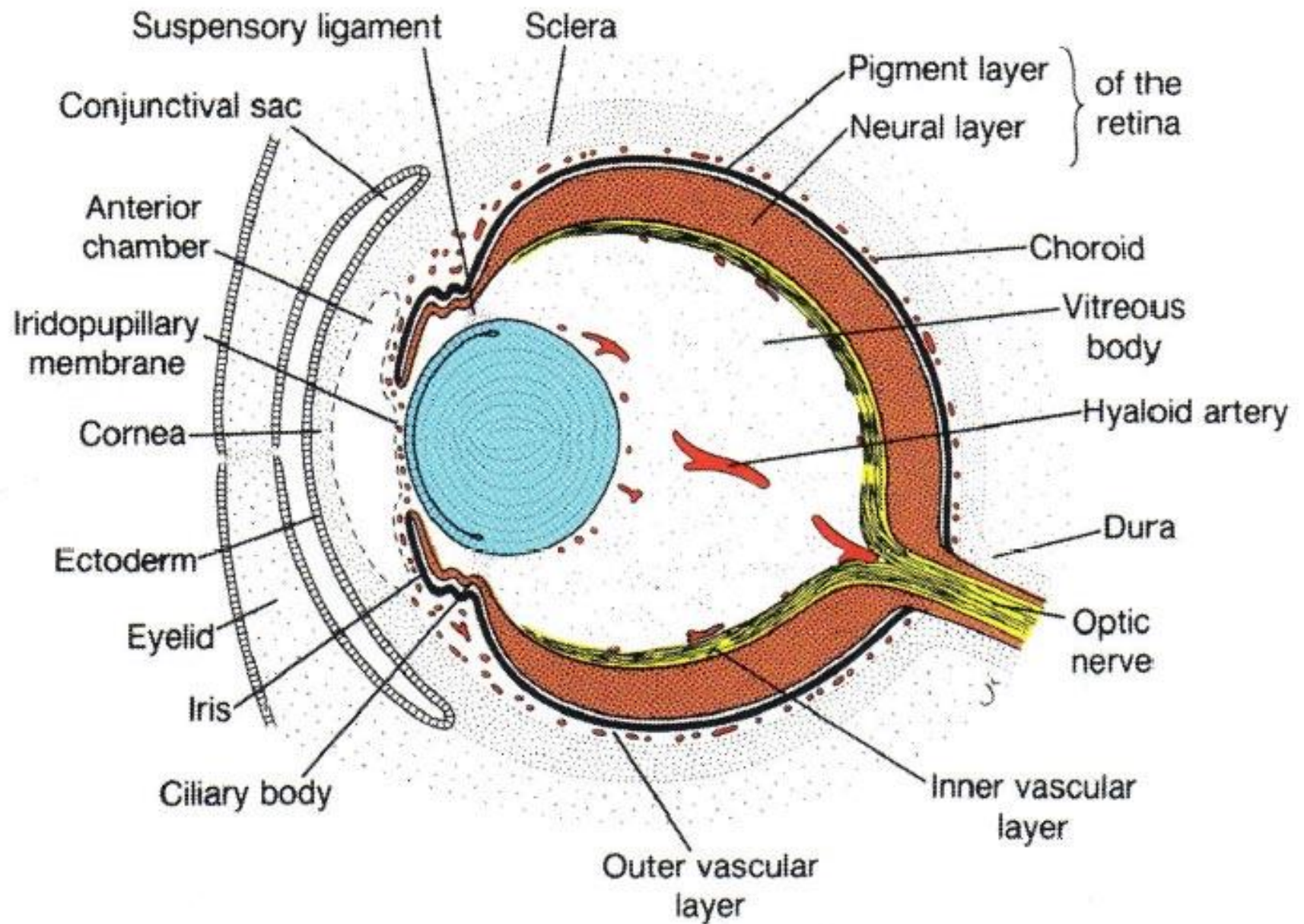


Figure 17.7. Section through the eye of a 15-week fetus showing the anterior chamber, iridopupillary membrane, inner and outer vascular layers, choroid, and sclera.

Development of camerae bulbi

- camera anterior
 - fissure between primordial lens and cornea
- camera posterior
 - fissure in optic cup on sides of lens vesicle

Development of cornea, choroidea and sclera

- cornea
 - superficial ectoderm
 - mesenchyme
 - cells of neural crest
- choroidea and sclera
 - surrounding mesenchyme

Development of palpebrae

- 6th week: cutaneous folds across cornea
- 10th week: both folds fuse
- 28th week: folds separate again
- inbetween: conjunctiva adheres internally

- muscles: 2nd pharyngeal arch
- tarsus and glands from mesenchyme

Development of lacrimal glands

- evaginations of superficial ectoderm
- non-functional until 6th week postnatally
 - newborn does not water in eyes

Developmental defects

- **congenital reinal detachment**
- **coloboma retinae** (usually bilateral – impaired closure of fissura optica)
- cyclopia (1 eye), synophthalmia (fused eyes)
- microphthalmia – due to infection
- anophthalmia
- **coloboma iridis** (6th week – impaired closure of fissura optica)
- aniridia, afakia
- **membrana pupillaris persistens**
- a. hyaloidea persistens
- **congenital glaucoma**
- **congenital cataract** (in galactosemia)
- congenital ptosis, coloboma palpebrale
- cryptophthalmia (absent eyelids – eyes covered with skin)

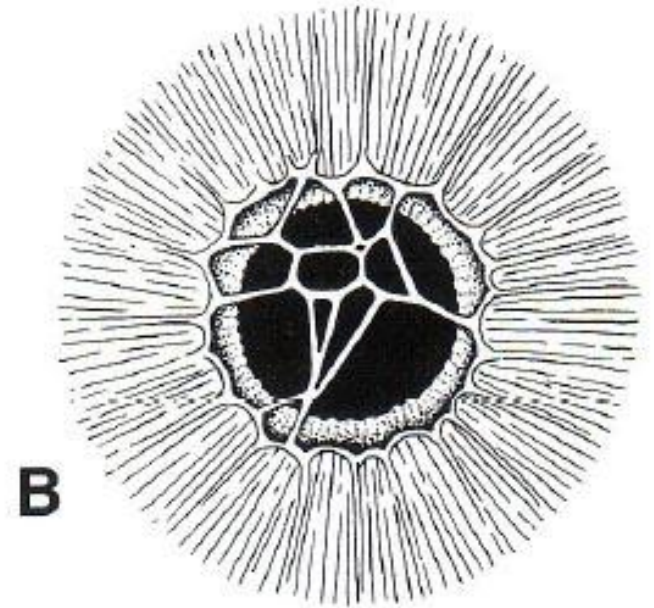
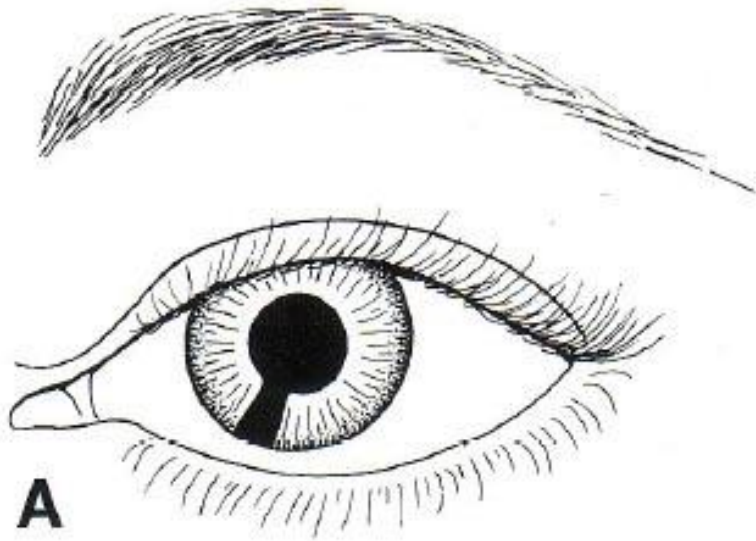


Figure 17.9. A. Coloboma iris. B. Persistence of the iridopupillary membrane.

END



DEVELOPMENT of the EYE I from CNS

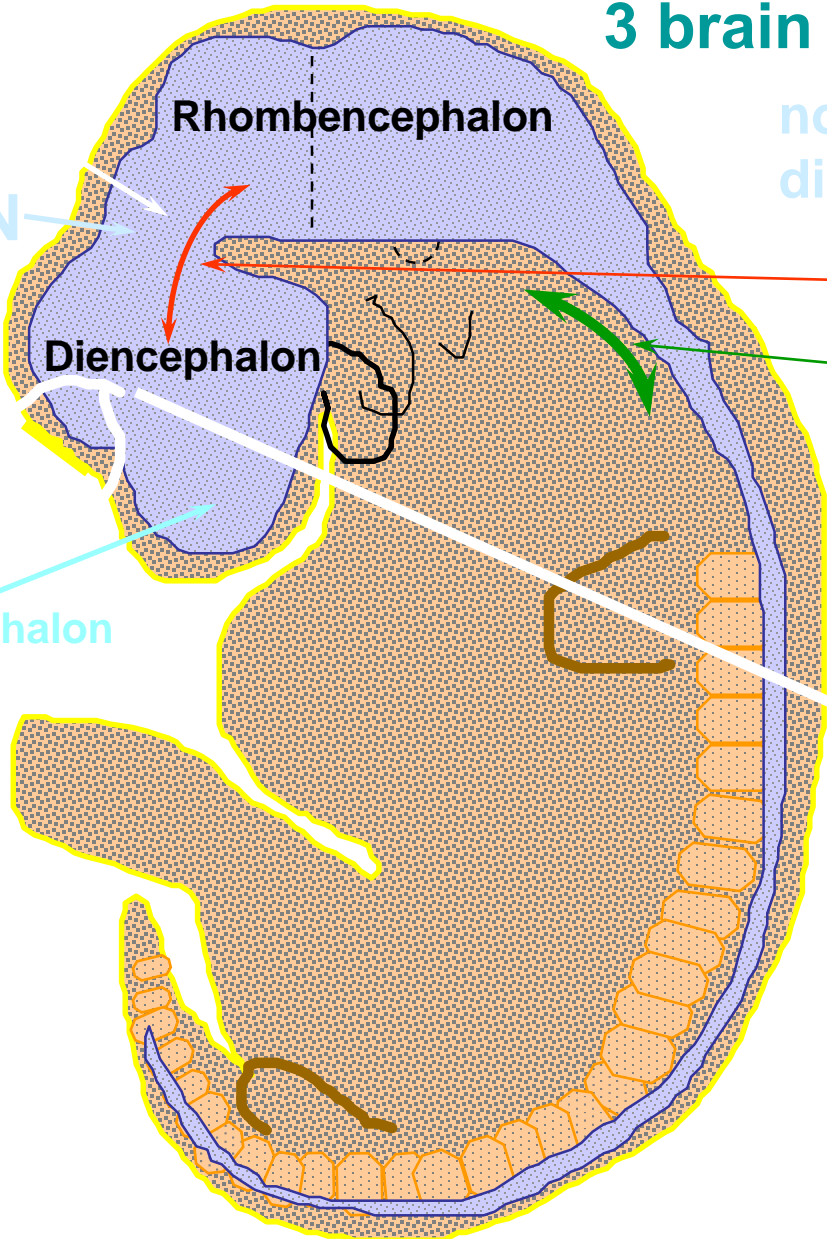
35 days pc

3 brain 'vesicles' are subdividing

now four, then Rhombencephalon divides into Met- & Mel-encephalons

BRAIN

Telencephalon



Cephalic flexure/bend

Cervical flexure

start the folding

Surface ECTODERM

MESENCHYME

Neural ECTODERM

ECTODERM,
FOREBRAIN
MESENCHYME

EYE PARTS' EMBRYONIC SOURCES

**Surface
ECTODERM**

MESENCHYME

**Neural
ECTODERM**

LENS

UVEA

SCLERA

RETINA

**CORNEAL
EPITHELIUM**

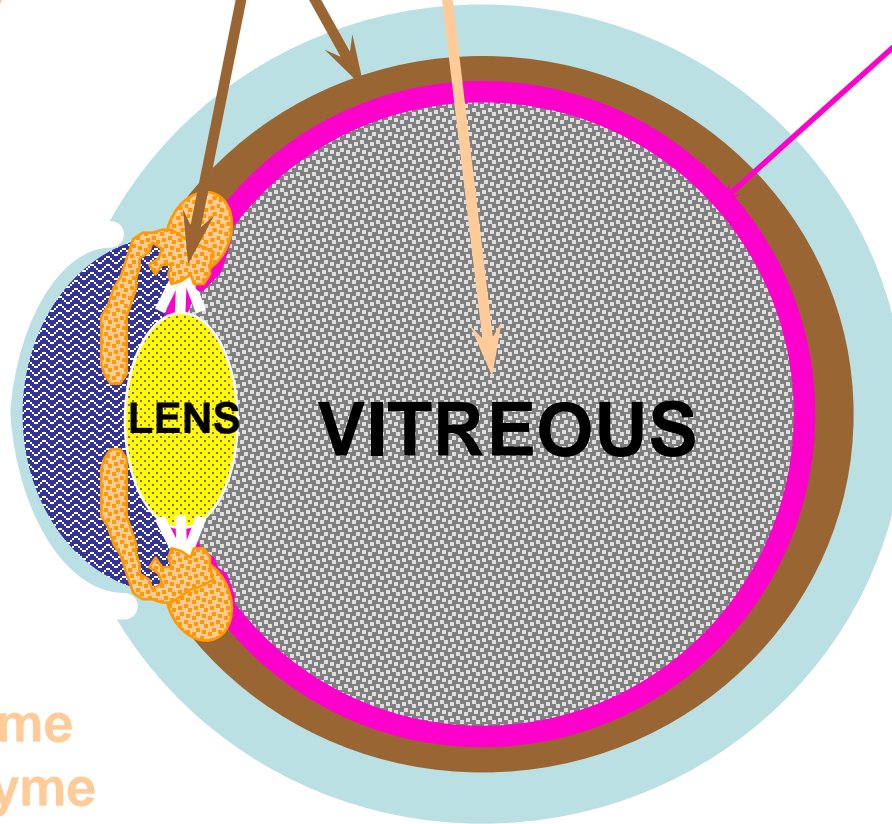
**CORNEAL
STROMA**

LENS

VITREOUS


Connective tissue & muscle (& vessels) come from cranial mesenchyme

Two ectoderms drive events and shaping



ANTERIOR EYE PARTS' EMBRYONIC SOURCES

Surface
ECTODERM

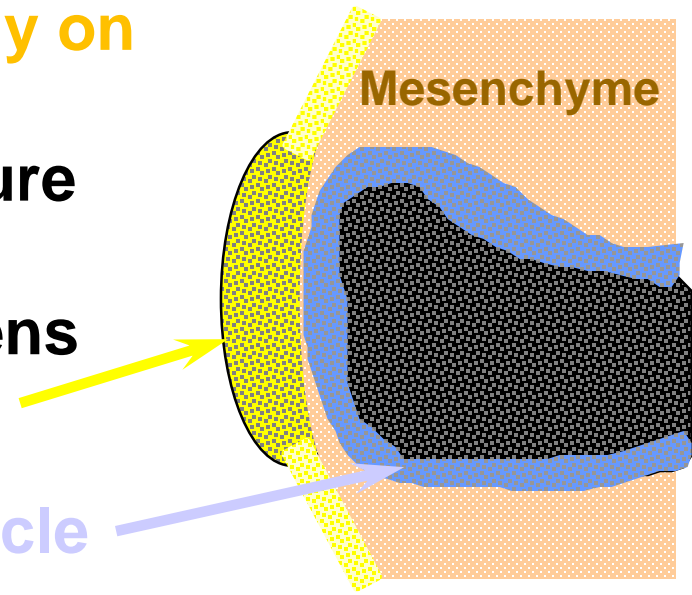


In much the same way as an endocrine gland is produced: by a downgrowth of cells that then break off the surface connection

Here the downgrowth makes the *lens vesicle*, conferring a roundish shape from early on

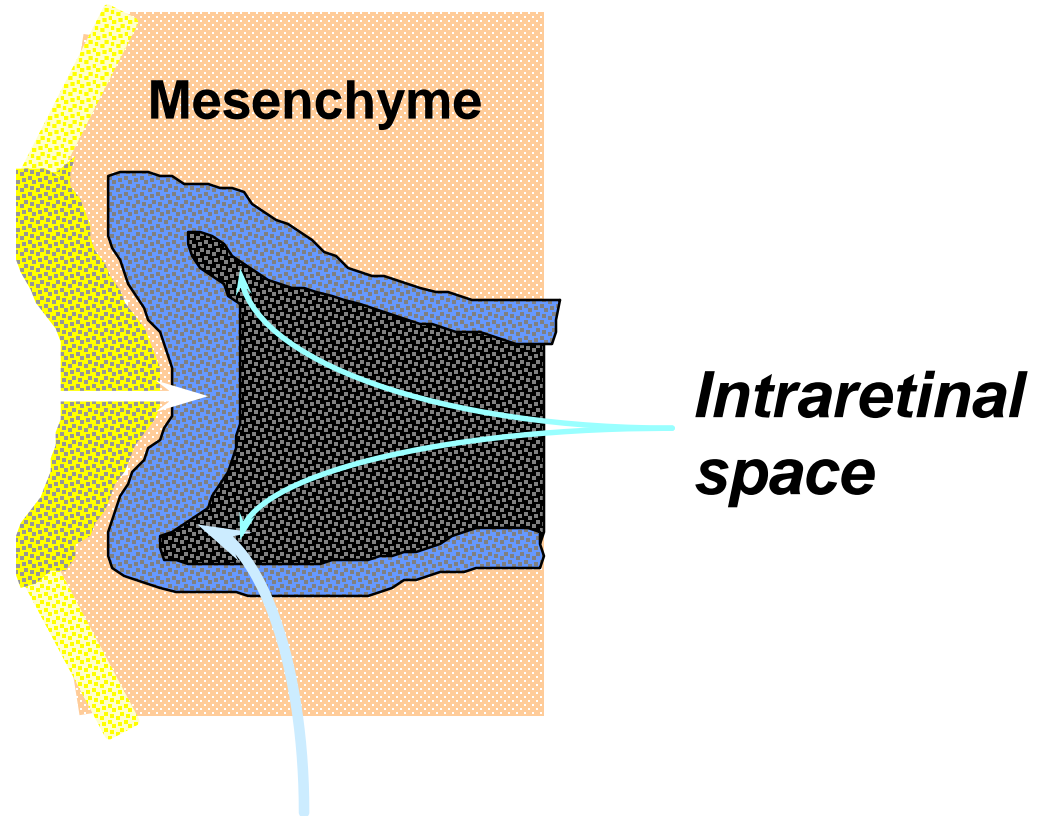
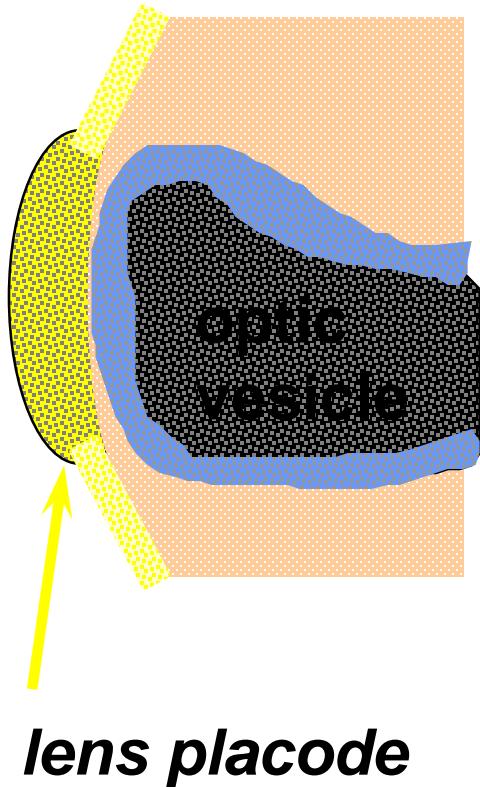
To have enough cells for the future cornea and for the lens vesicle, the surface ectoderm first thickens to form a *lens placode*

brain-derived optic vesicle



LENS & OPTIC CUP DEVELOPMENT I

While still growing, both placode and end of the optic vesicle invaginate

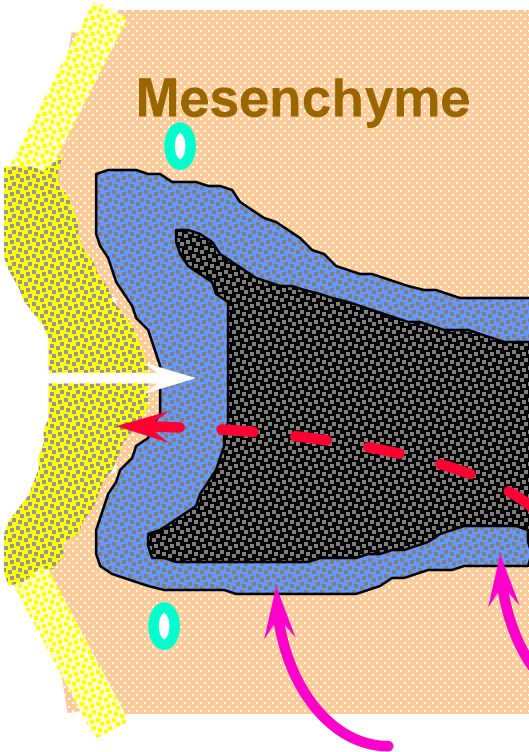


Double wall of *optic cup* is starting to form


Optic vesicle precedes the lens vesicle and is a distinct structure

OPTIC CUP DEVELOPMENT II: Choroid fissure

Blood vessels have to be introduced early into the soon to be enclosed round eye

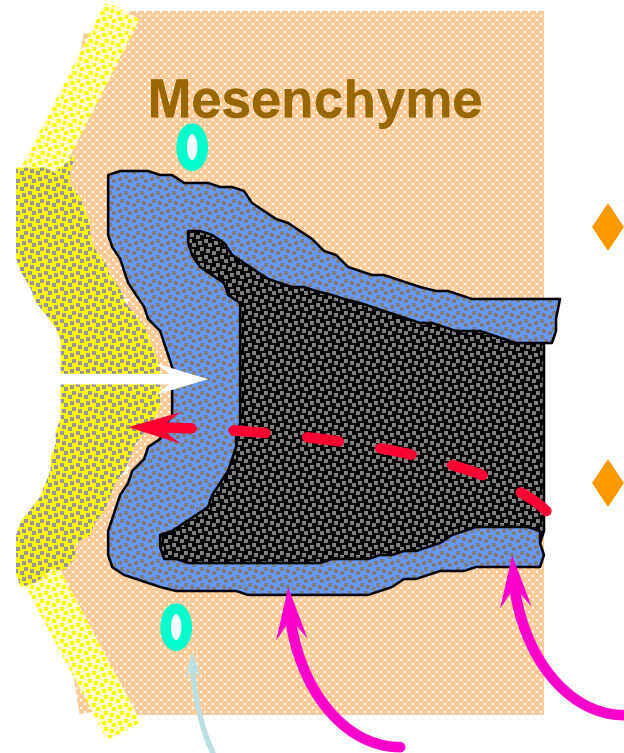


◆ an invagination along the cup & stalk's inferior surface occurs, to create the *choroid fissure*




◆ in which runs the *hyaloid artery*

OPTIC CUP DEVELOPMENT II: Coloboma



Blood vessels have to be introduced early into the soon to be enclosed round eye

an invagination along the cup & stalk's inferior surface occurs, to create the *choroid fissure*



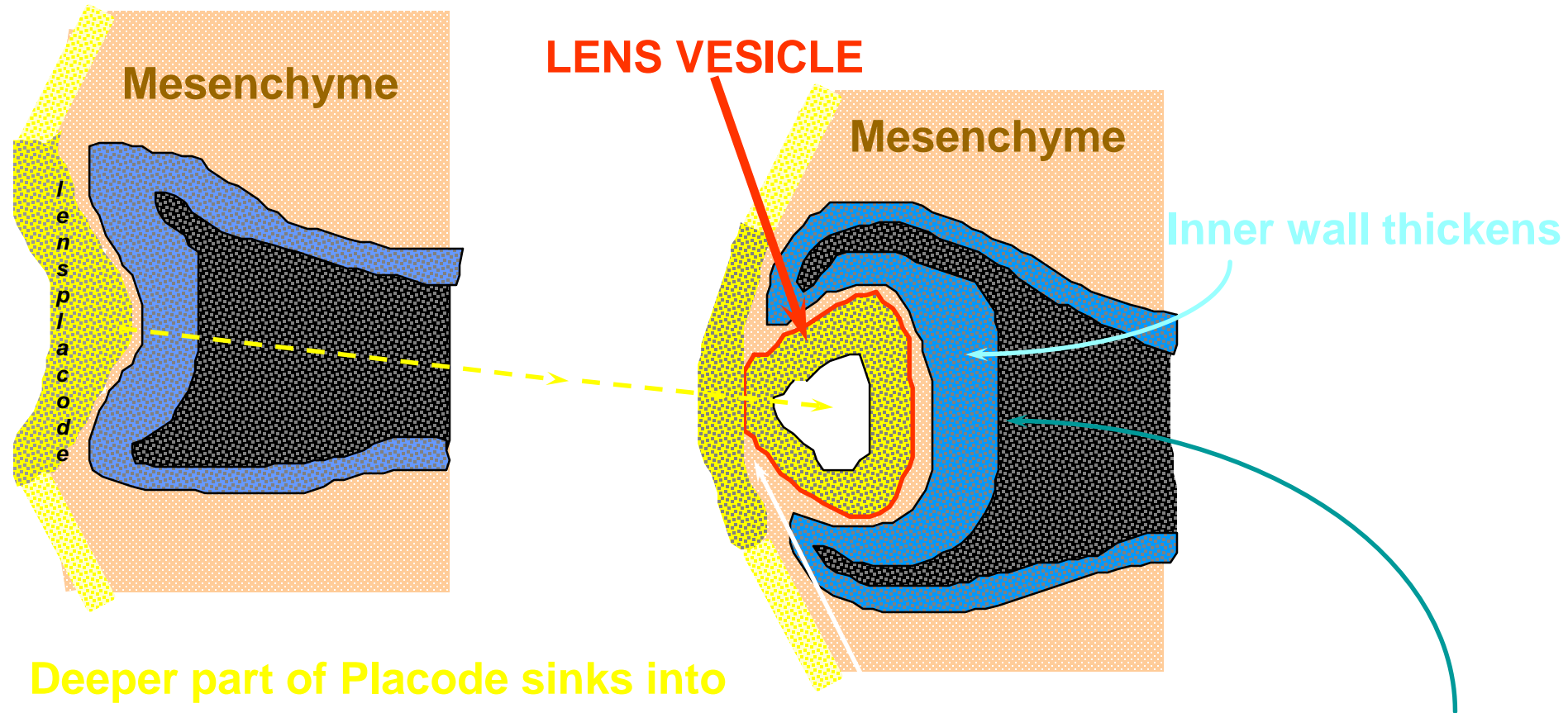
in which runs the *hyaloid artery*

Also, an *annular vessel* runs around the outside of the optic cup

Imagine a penis in which the urethra near & into the glans is still open on its underside - the condition of *hypospadias* - (but now contains an artery)

Defects in the eye from failure of the choroid fissure to close are *colobomas*

OPTIC DEVELOPMENT III: Lens vesicle

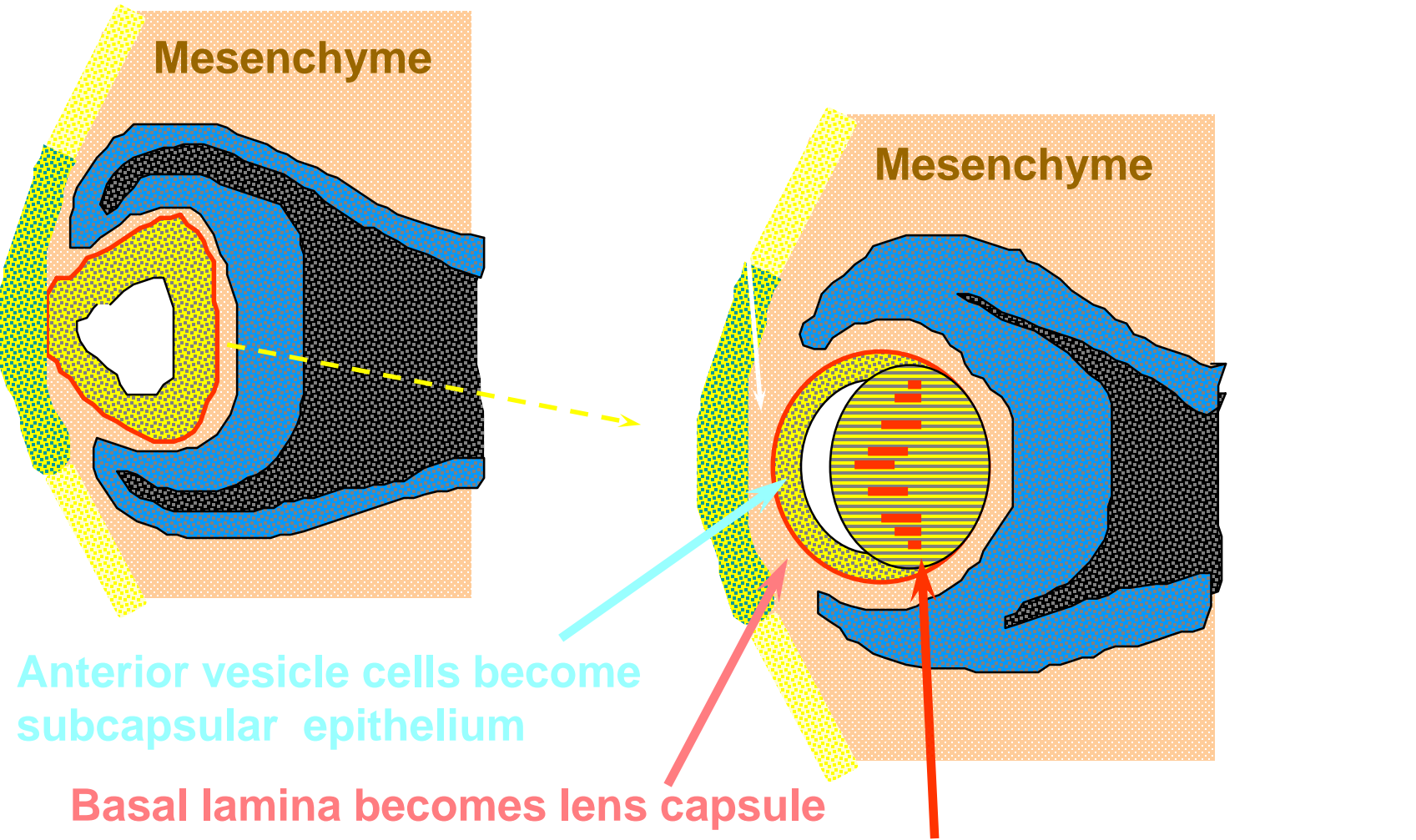


Deeper part of Placode sinks into mesenchyme & makes a vesicle

Optic cup becomes deeper

so that surface ectoderm can become corneal epithelium & intervening mesenchyme can form the corneal stroma

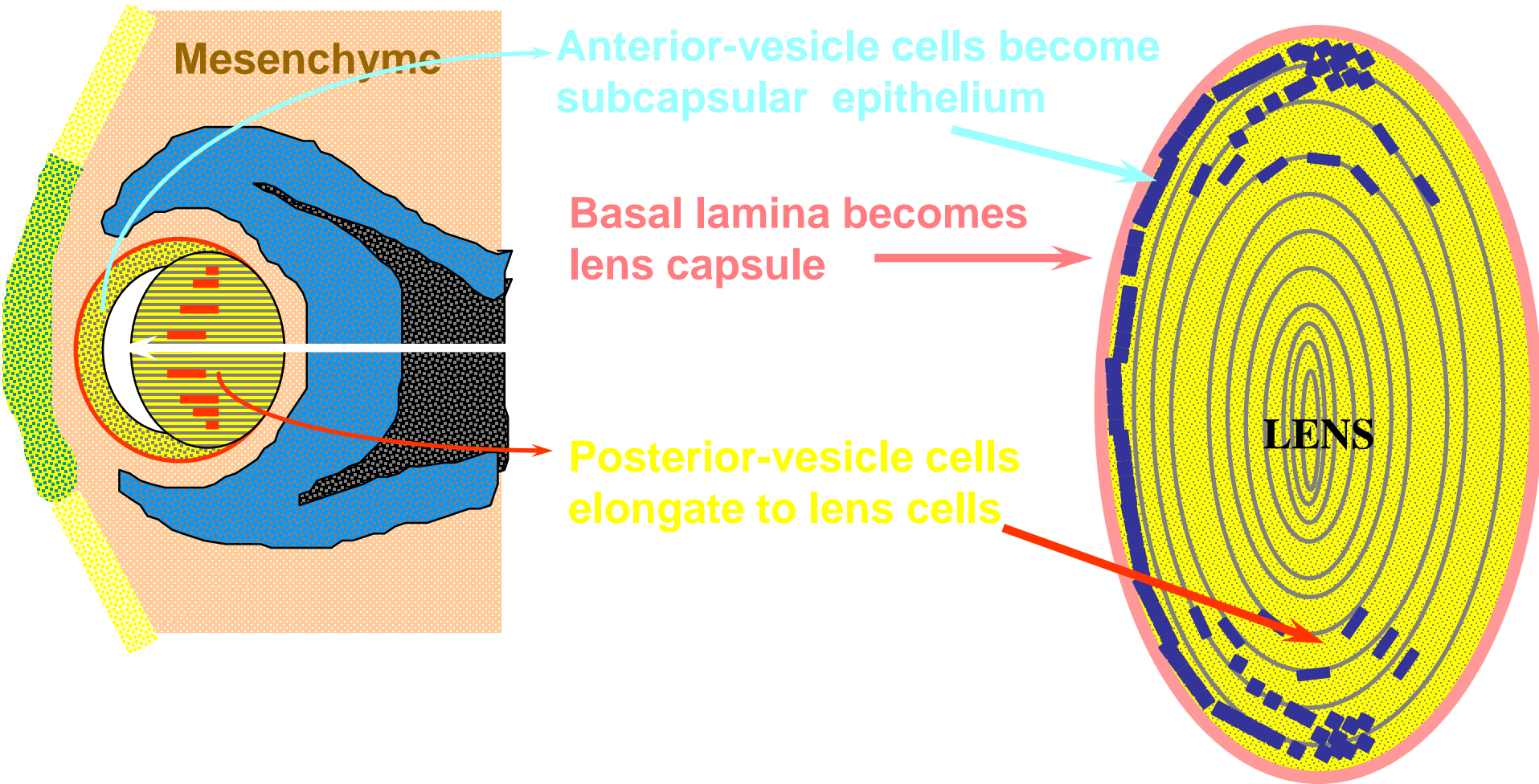
OPTIC DEVELOPMENT IV: Lens differentiation



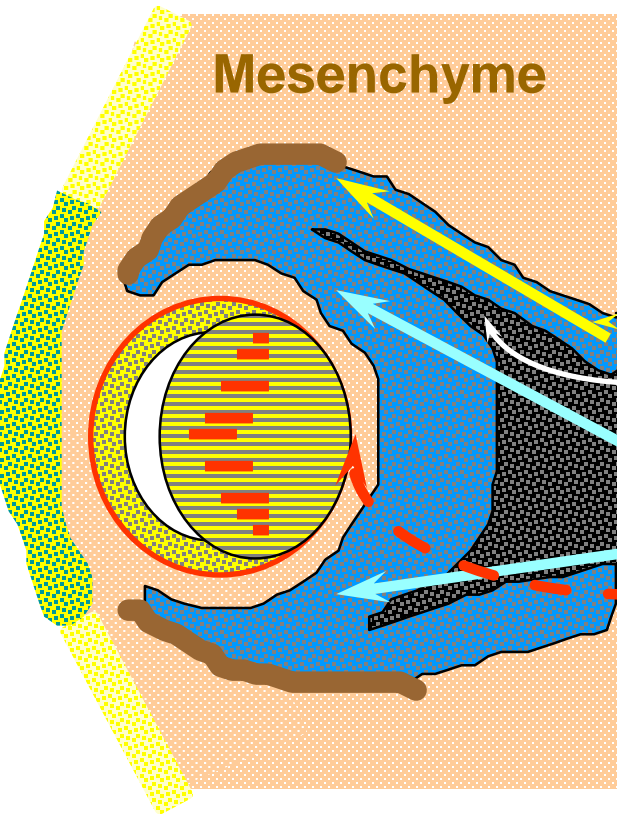
Posterior vesicle cells become elongated lens cells

Posterior vesicle cells form the nucleus of the lens. Subsequent lens cells derive from the subcapsular epithelium

OPTIC DEVELOPMENT IV: Lens differentiation



OPTIC DEVELOPMENT V: Retina differentiation I



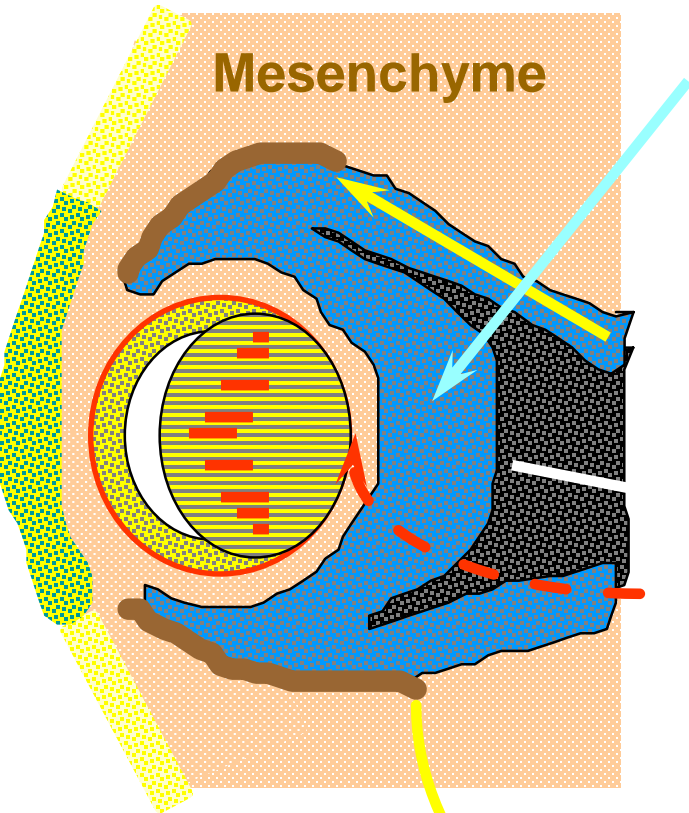
Outer layer of cup stays thin and becomes pigment cell layer

Inner layer of cup thickens and becomes Neural layer

Hyaloid artery reaches inside cup

After a while, the lens and vitreous no longer need it, and it atrophies. Only the neural retina continues to depend on it, but under another name - *central artery of the retina*

OPTIC DEVELOPMENT VI: Retina differentiation II



Inner layer of cup thickens and becomes Neural layer

Outer layer of cup stays thin and becomes pigment cell layer

