

# Targeted fascicular biopsy of the sciatic nerve and its major branches: rationale and operative technique



Stepan Capek, M.D.<sup>1,2</sup>,  
Kimberly K. Amrami, M.D.<sup>3</sup>,  
P. James B. Dyck, M.D.<sup>4</sup>,  
Robert J. Spinner, M.D.<sup>5</sup>



## Object

Nerve biopsy is typically performed in distal, sensory non-critical nerves with no imaging to target more involved regions; the yield of these procedures rarely achieves more than 50%. We believe that in selected cases where preoperative evaluation points towards a more localized (usually a more proximal) process, targeted biopsy would be likely to capture the disease. Herein we report our experience with the sciatic nerve and provide a description of the operative technique (Fig. 1).

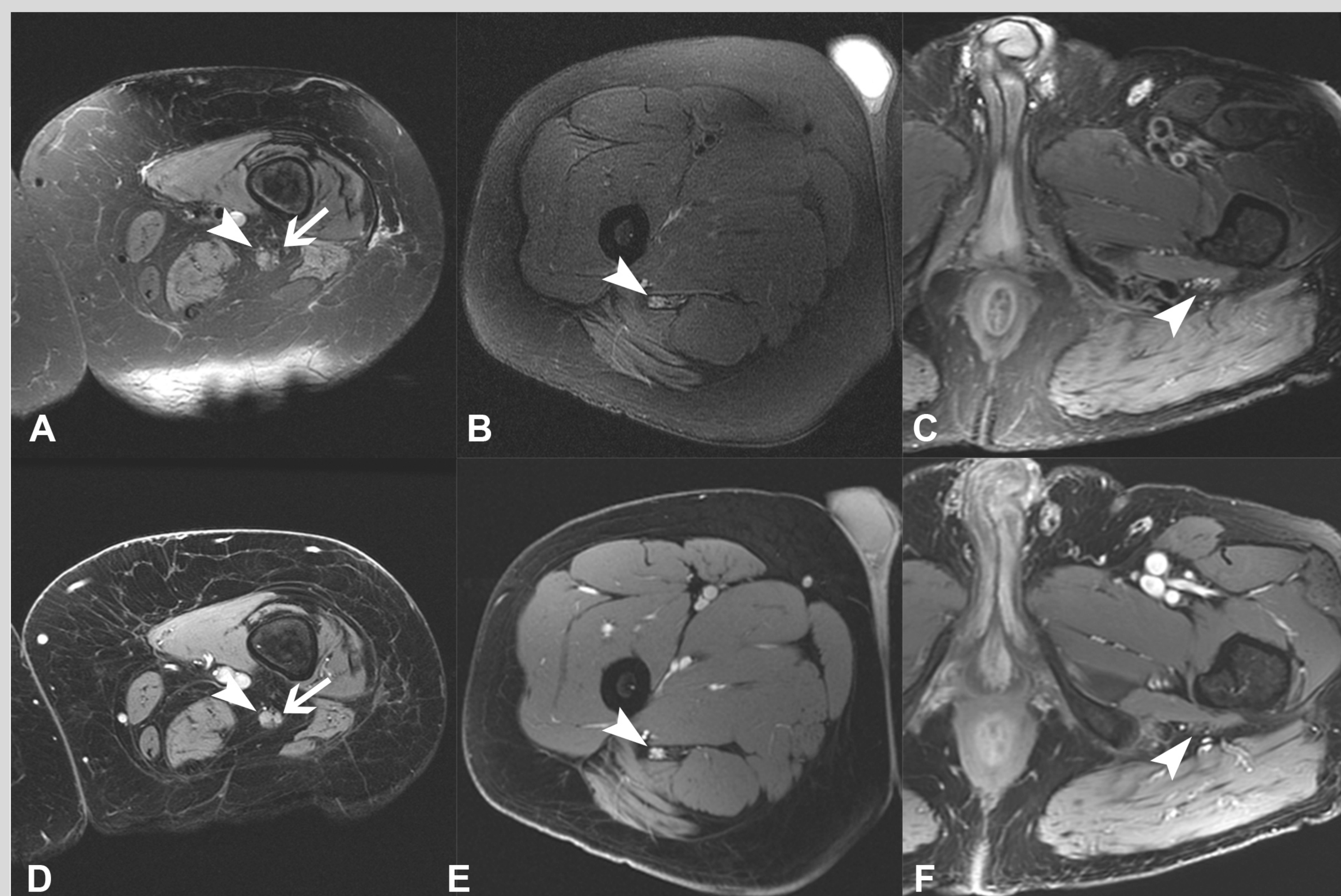


Fig. 2: MRIT2 andT1 post-contrast axial images of the sciatic nerve demonstrating an imaging pattern characteristic for neurolymphomatosis (A, D), perineurioma (B, E) and chronic inflammatory polyneuropathy (C, F).

## Results

One hundred-twelve cases of sciatic nerve biopsy were performed (Fig. 3). Mean age was 46.4 years. Seventy seven (68.8%) patients presented with single lower extremity symptoms, 16 (14.3%) with bilateral and 19 (17%) with generalized symptoms. All patients had electrodiagnostic studies, which were abnormal in 110 (98.2%) cases. MRI was available in all patients and was read as pathological in 111 (99.1%) (Fig. 2). The overall diagnostic yield of the biopsy was 84.8% (n=95). The pathological diagnoses included inflammatory demyelination, perineurioma, non-specific inflammatory changes, neurolymphomatosis, amyloidosis, prostate cancer, injury neuroma, neuromuscular choristoma, sarcoidosis, vasculitis, hemangiomas, arteriovenous malformation, fibrolipomatous hamartoma (lipomatosis of nerve) and cervical adenocarcinoma (Fig. 3). In the series were 11 (9.9%) temporary and 5 (4.5%) permanent complications: 3 patients (2.7%) reported permanent numbness in the peroneal division distribution and 2 patients (1.8%) diagnosed with neuromuscular choristoma developed desmoid tumor at the biopsy site three and eight years later.

## Methods

We reviewed all cases of sciatic nerve biopsy performed between 2000 and 2014. Demographic data, clinical presentation and the presence of percussion tenderness for each patient were recorded. Reviewed studies included electrodiagnostic tests and imaging modalities. All details of the procedure, final pathology and its treatment implications were recorded. Complication rate was carefully assessed for temporary as well as permanent complications.

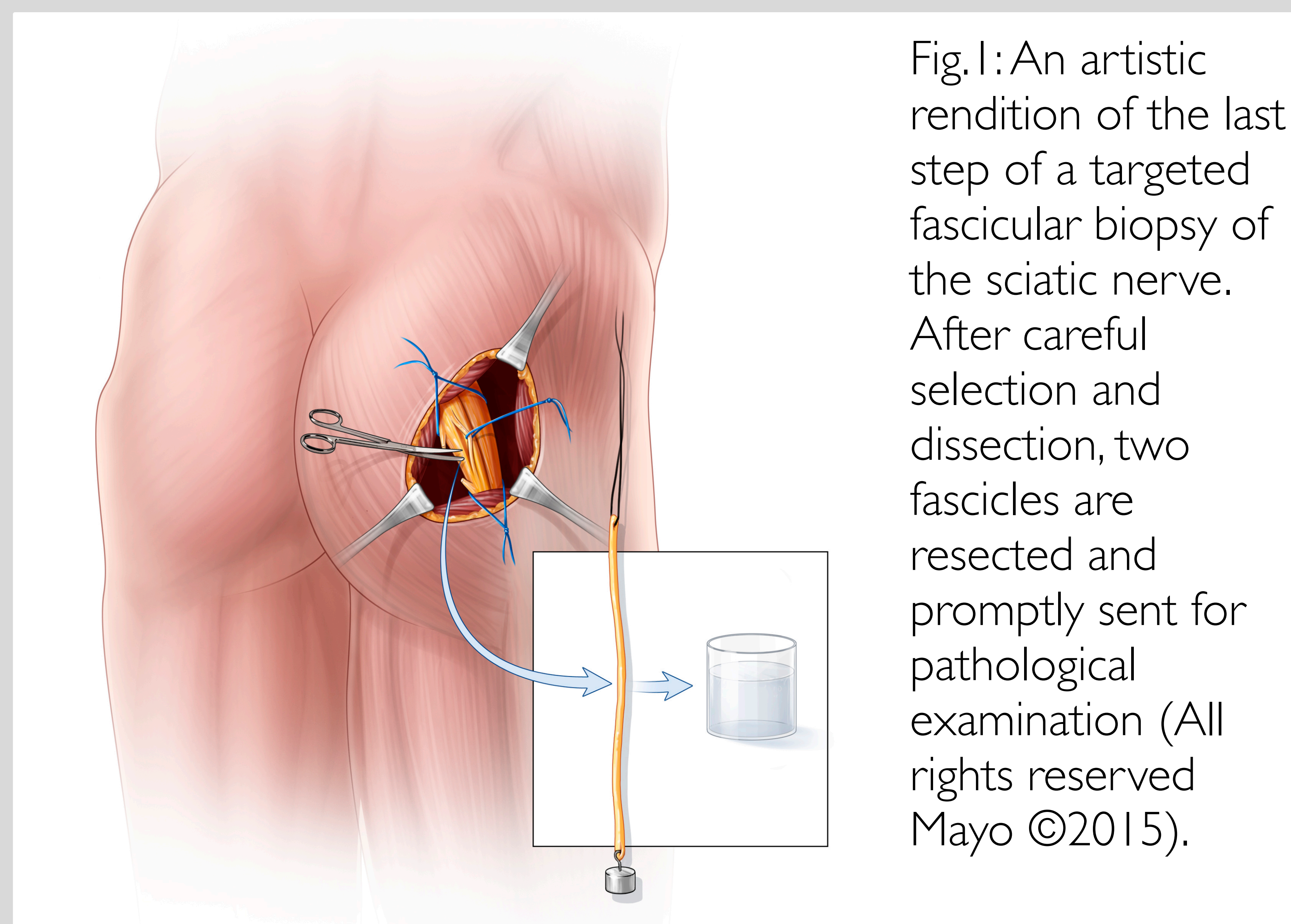


Fig. 1: An artistic rendition of the last step of a targeted fascicular biopsy of the sciatic nerve. After careful selection and dissection, two fascicles are resected and promptly sent for pathological examination (All rights reserved Mayo ©2015).

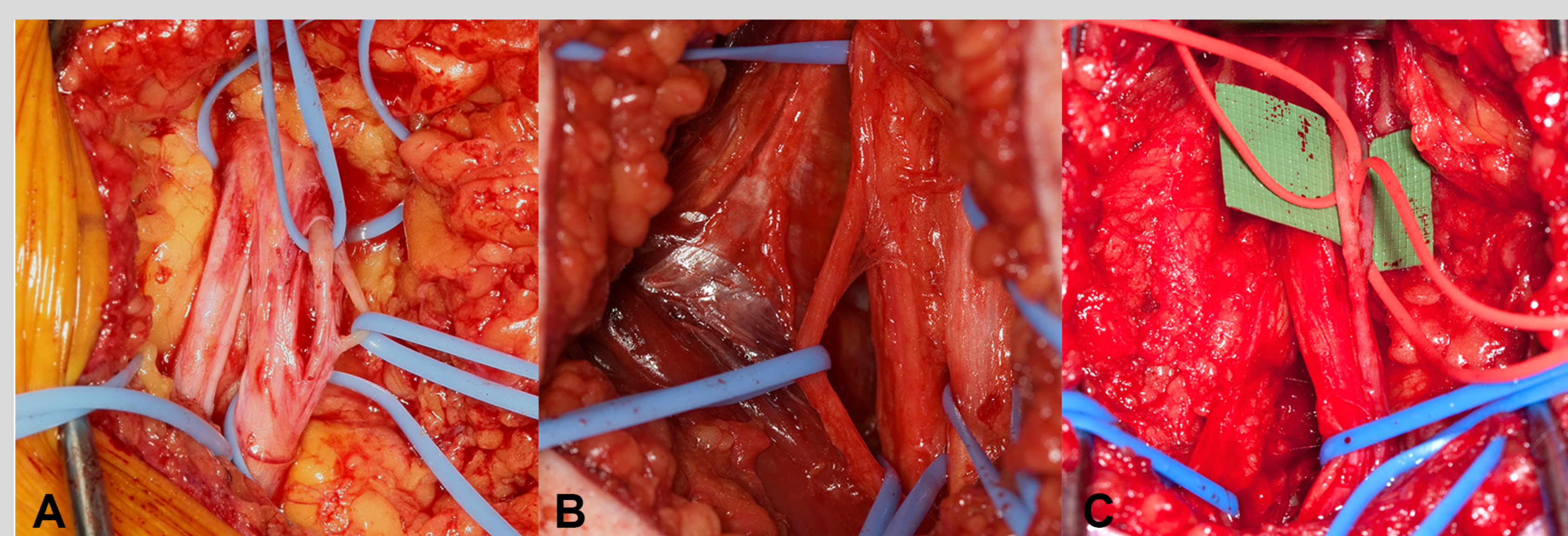


Fig. 3: Intraoperative photographs show irregularly appearing (A, B, C) and discolored (C) fascicles mobilized from the left sciatic nerves in patients with neurolymphomatosis (A), perineurioma (B) and chronic inflammatory demyelinating polyneuropathy (C). These images were taken from the same patients as MR imaging in Fig. 2.

## Conclusions

Targeted fascicular biopsy of the sciatic nerve is safe and efficient diagnostic procedure. Diagnoses were very diverse including entities considered very rare. Even in the more prevalent diagnoses, the biopsy technique allowed for a more targeted approach with a higher diagnostic yield and justification for more aggressive treatment.

Affiliations: 1) 2nd Faculty of Medicine, Charles University in Prague, CZ; 2) Department of Neurosurgery, University of Virginia, Charlottesville, VA, USA; 3) Department of Radiology, Mayo Clinic, Rochester, MN, USA; 4) Department of Neurology, Mayo Clinic, Rochester, MN, USA; 5) Department of Neurosurgery, Mayo Clinic, Rochester, MN, USA