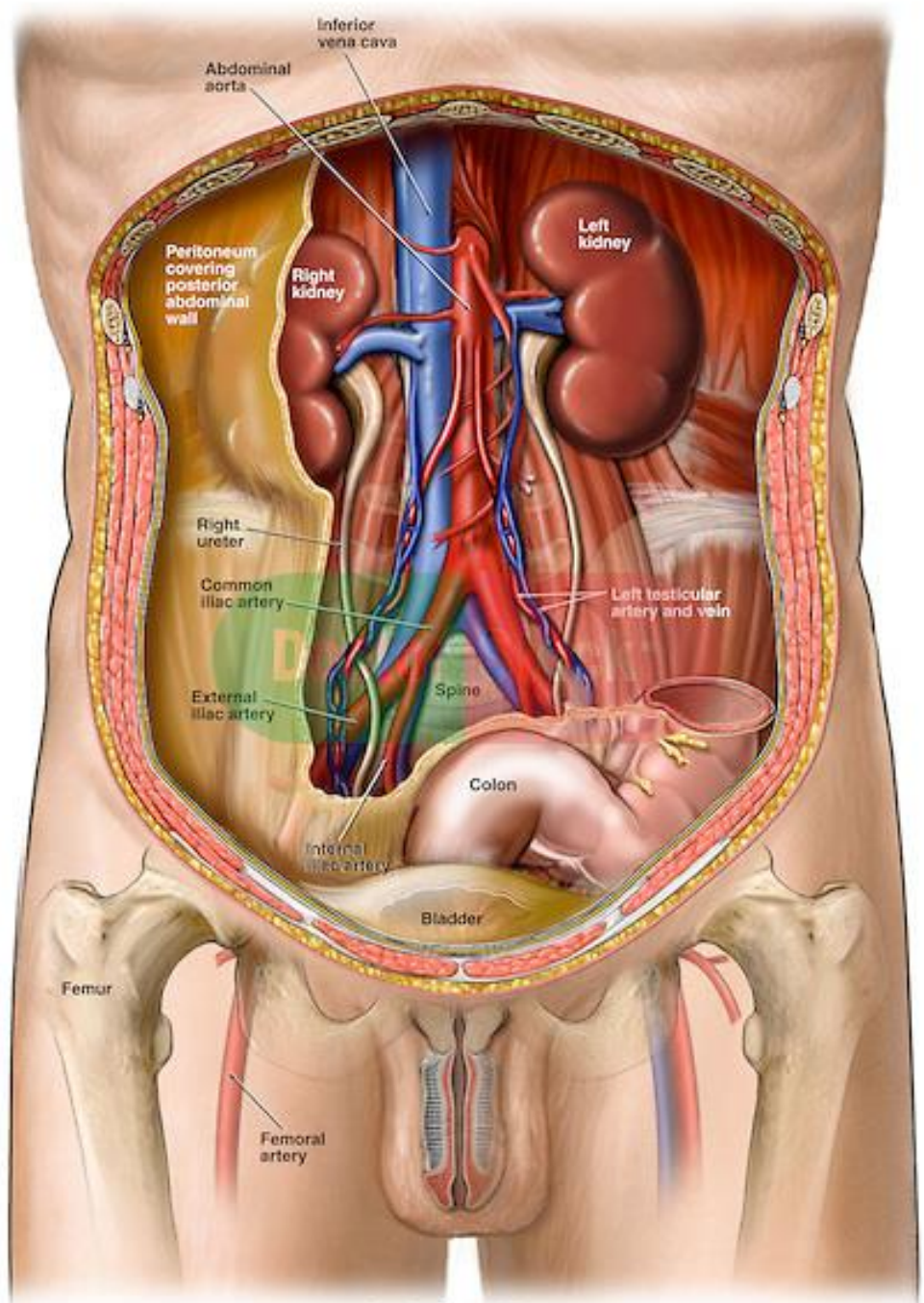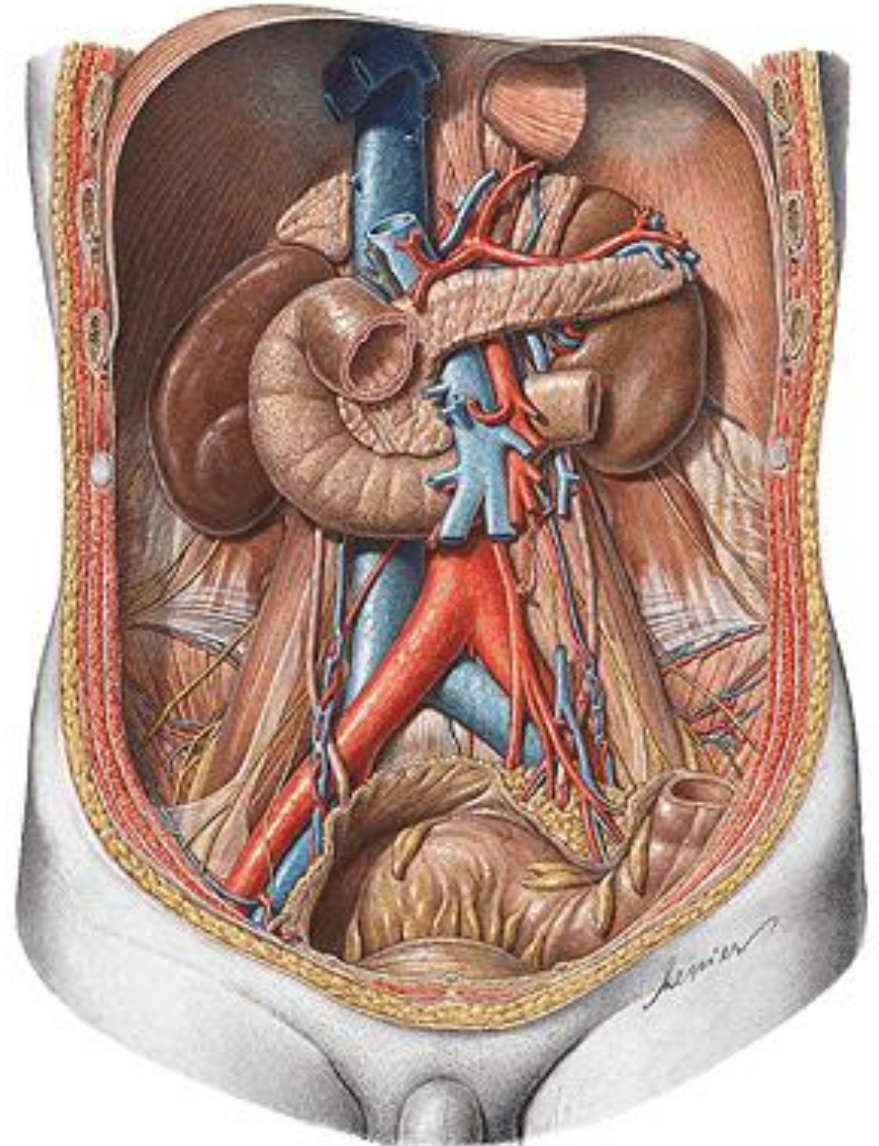
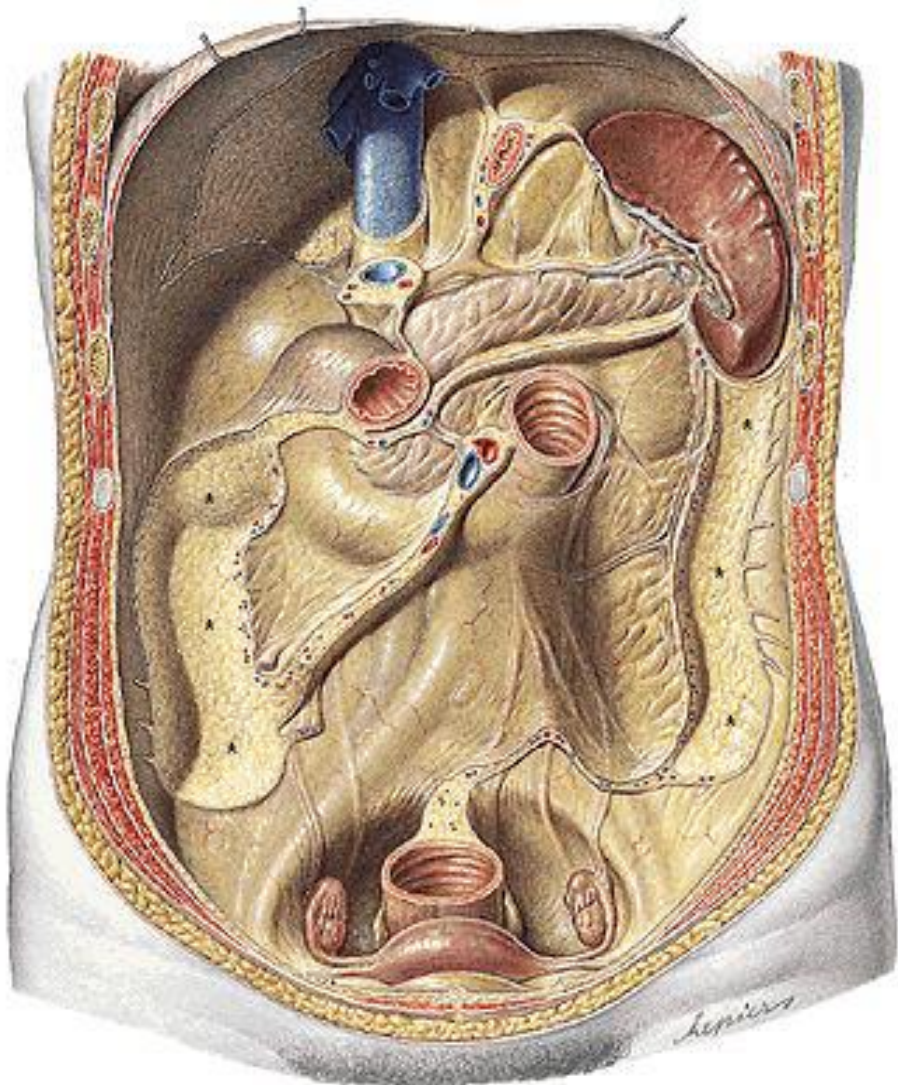


Anterior Cut-away View



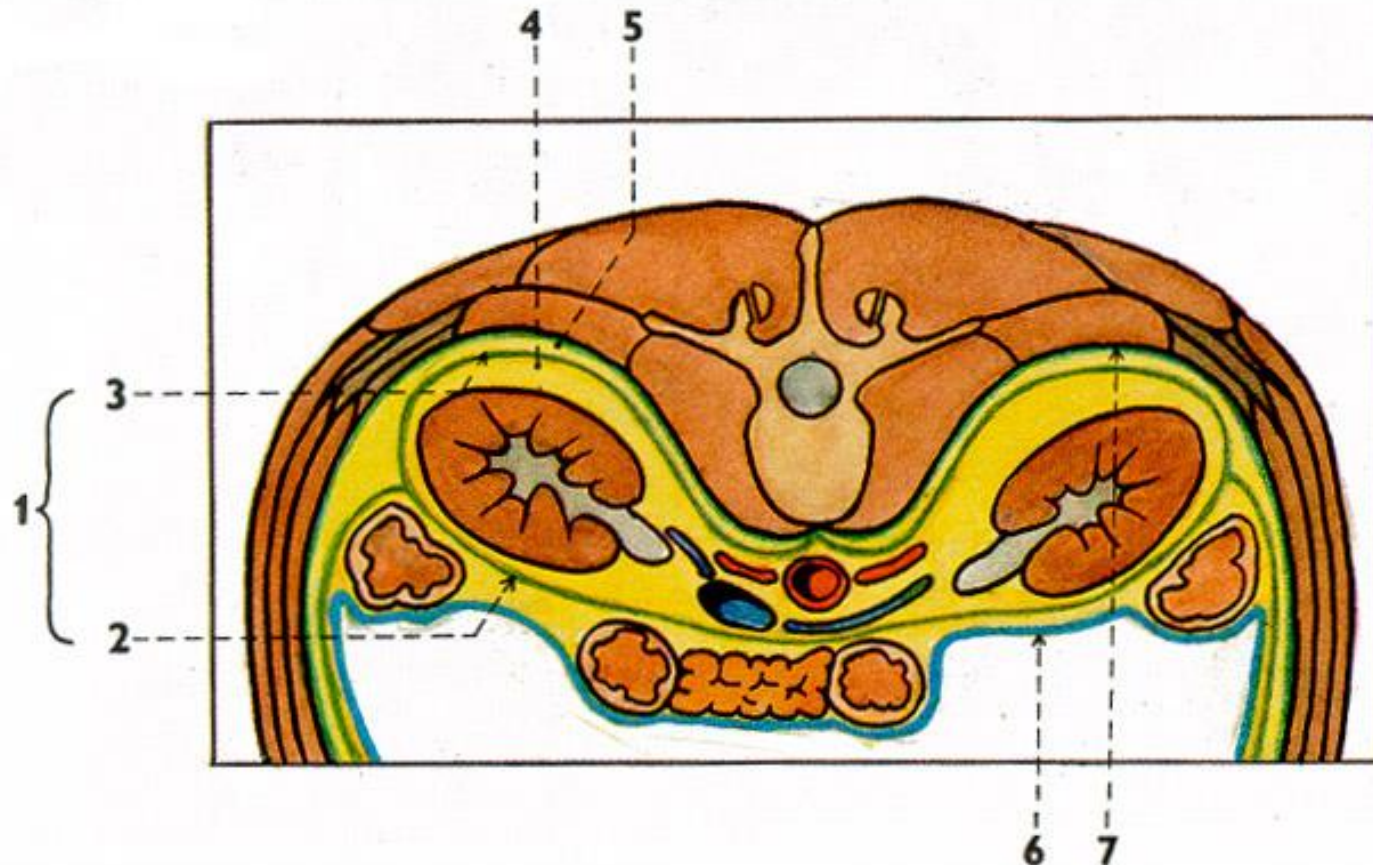
# Retroperitoneum





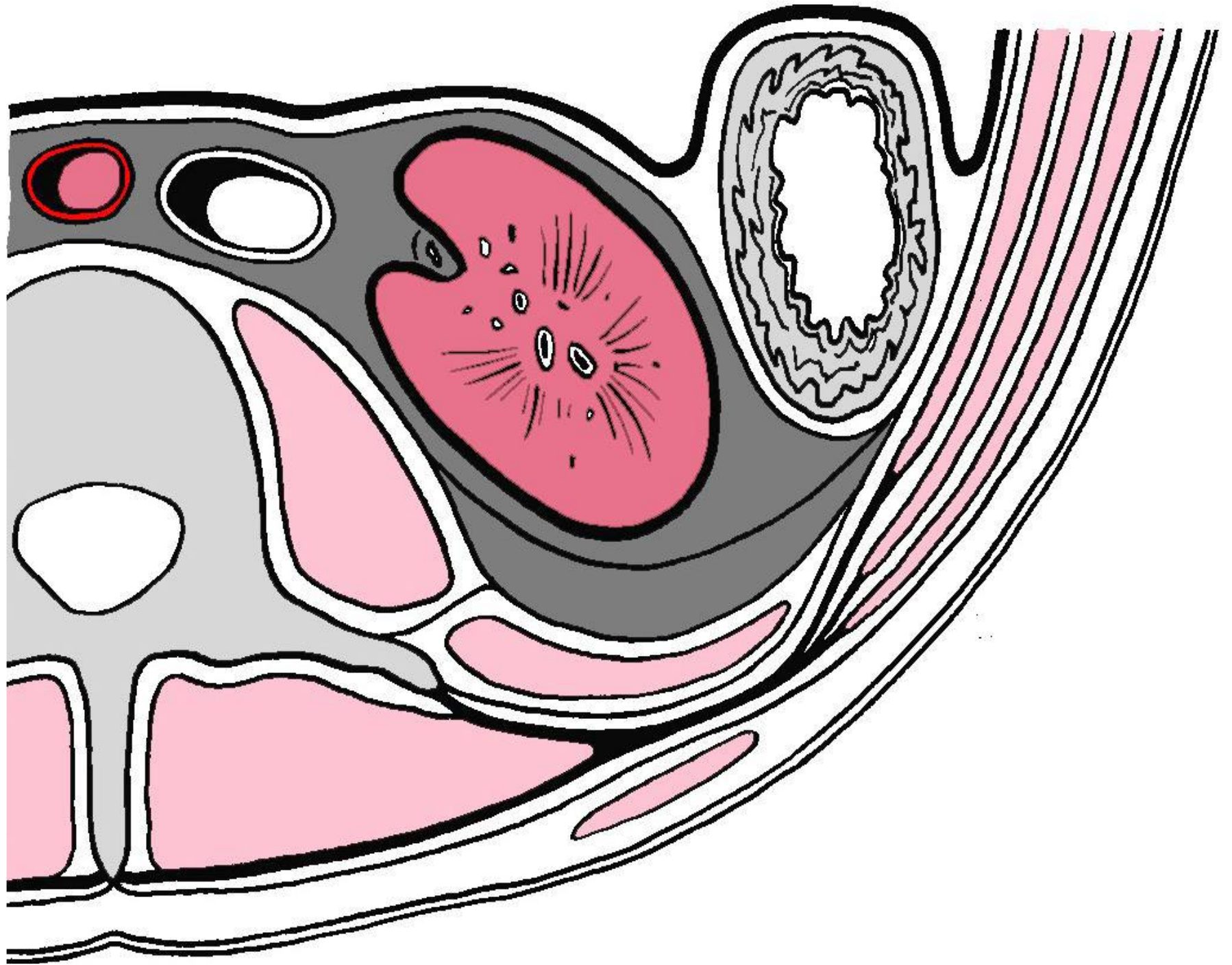
# Position, fixation and renal covers

## Transverse section at the level of L1



- 1 - fascia renalis *Gerotae*
- 2 - lamina prerenalis *Toldt*
- 3 - lamina retrorenalis *Zuckerkandeli*

- 4 - corpus adiposum perirenale
- 5 - corpus adiposum pararenale
- 6 - peritoneum
- 7 - fascia transversalis



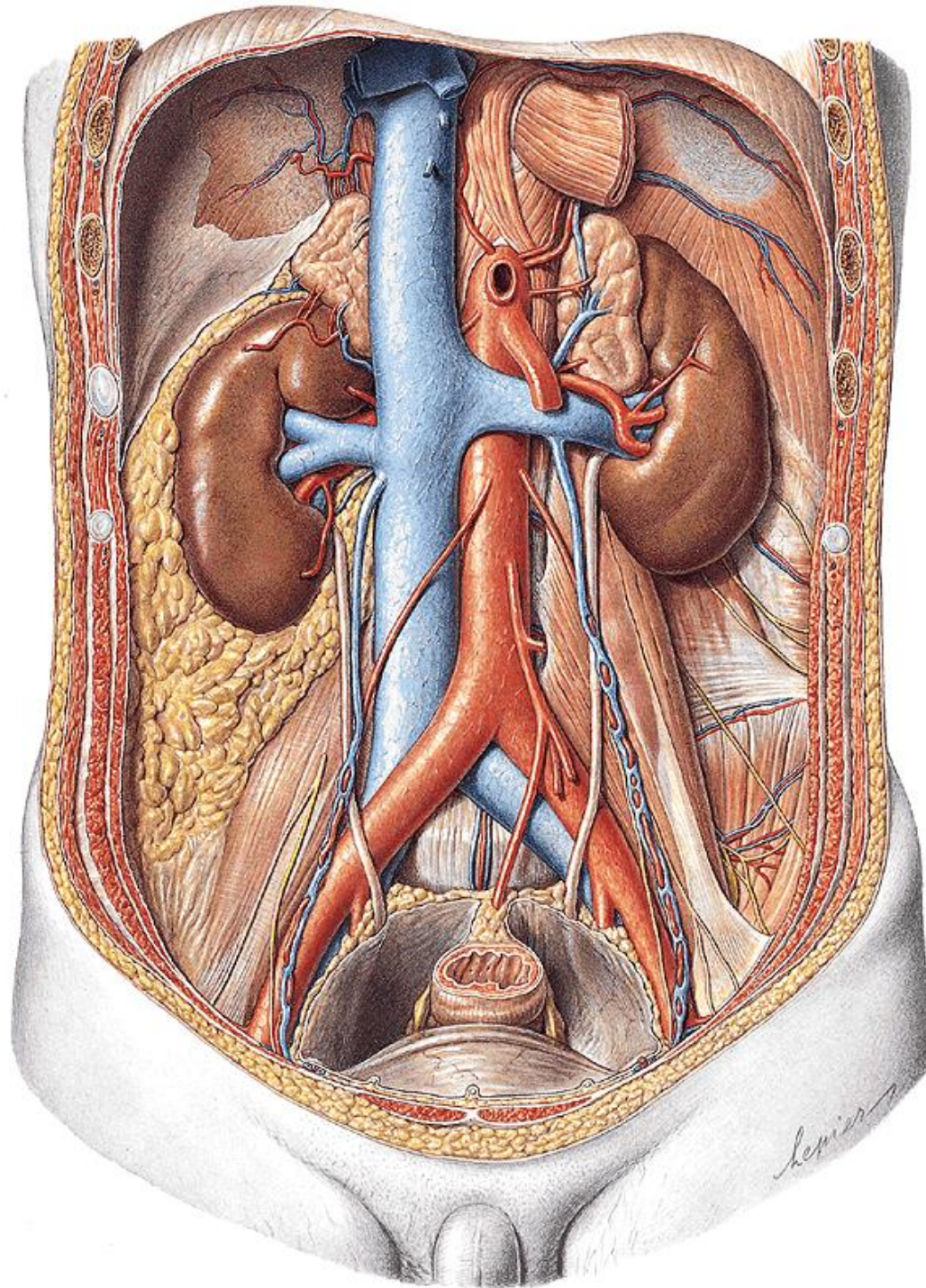


# Aorta abdominalis

origin: hiatus oesophageus  
diaphragmatis

end: bifurcatio aortae L4

- retroperitoneum, slightly left to vertebral column
- v. cava inferior + ductus thoracicus right to aorta abdominalis



# Aorta abdominalis

parietal branches: *paired*

- a. phrenica inf.
- aa. lumbales 1st - 4th
- rr. retroperitoneales (6-7)

visceral branches: *paired*

- a. suprarenalis media
- a. renalis
- a. renalis accessoria (30%)
- a. testicularis♂ / ovarica♀



# AORTA ABDOMINALIS

a. suprarenalis sup.

a. suprarenalis media

a. suprarenalis inf.

a. renalis

a. ovarica /  
testicularis

a. phrenica inf.

truncus coeliacus

a. mesenterica sup.

a. mesenterica inf.

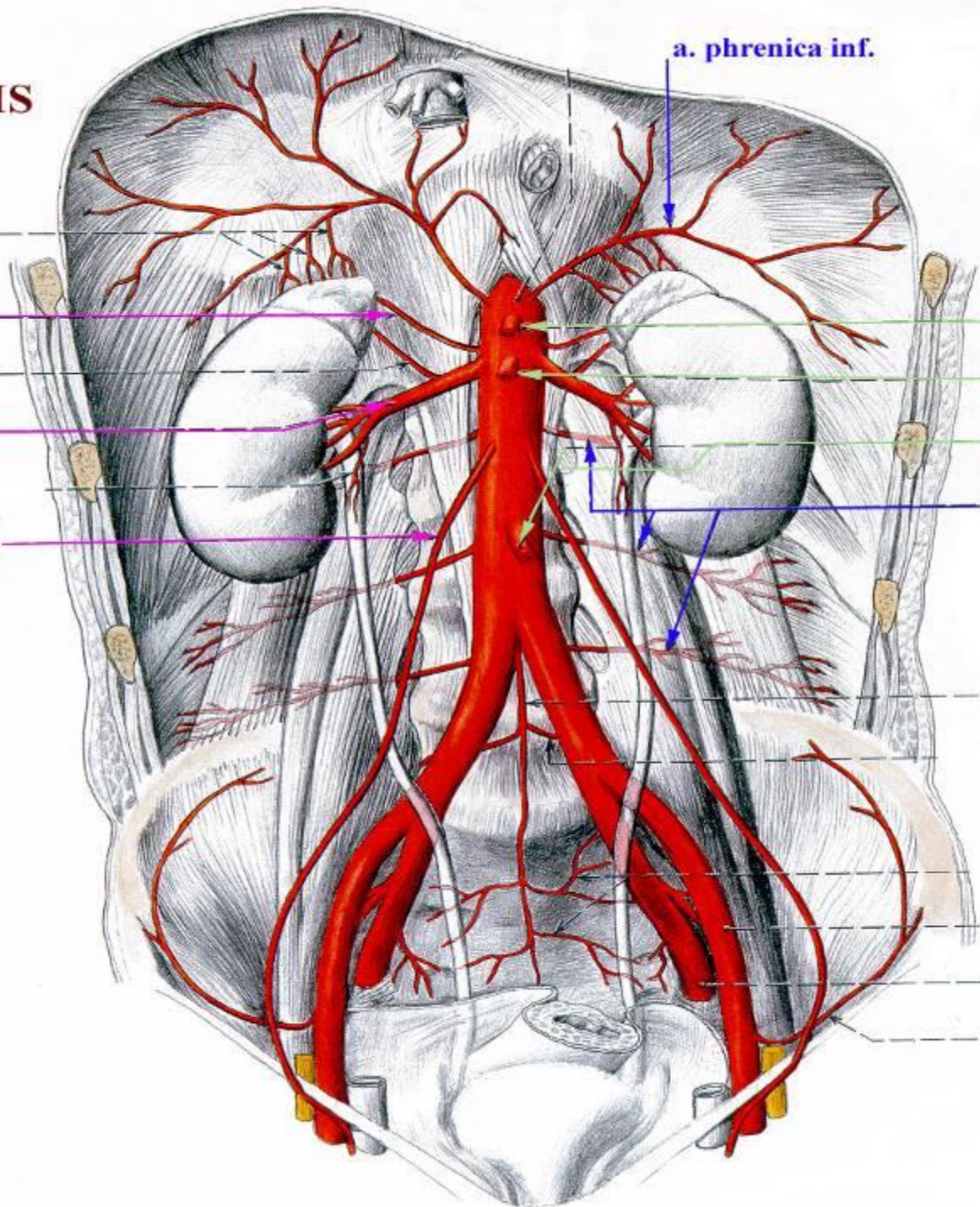
aa. lumbales

a. sacralis media

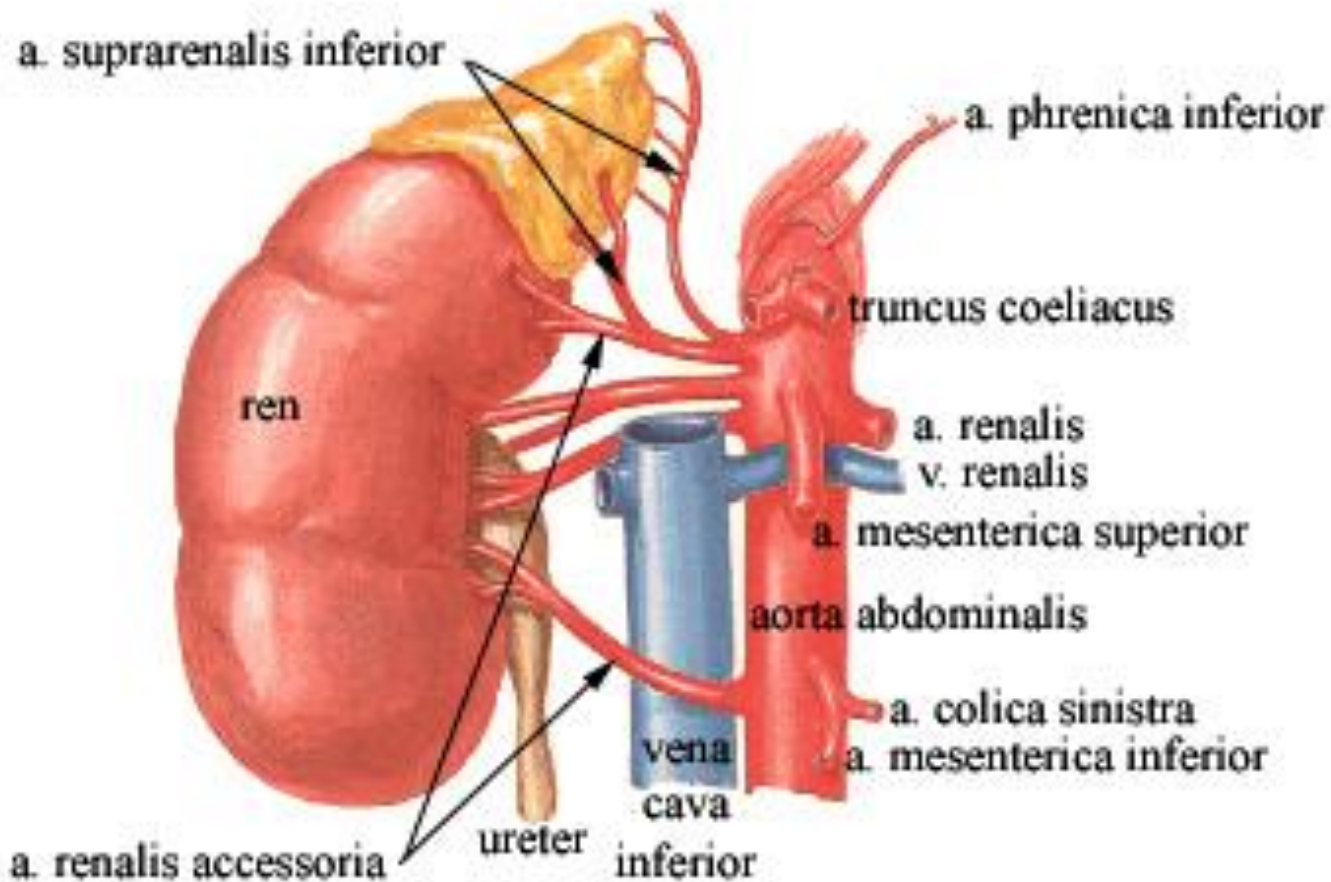
a. iliaca interna

a. iliaca externa

a. circumflexa  
ilium profunda



# ARTERIA RENALIS ACCESSORIA



- enters upper pole (less), hilum or inferior pole (more) of kidney
- incidence 30%



# Aorta abdominalis

terminal branches: *paired*

- a. iliaca communis

terminal branches : *unpaired*

- a. sacralis mediana

visceral branches : *unpaired*

- truncus coeliacus
- a. mesenterica superior
- a. mesenterica inferior

# Arteria iliaca communis

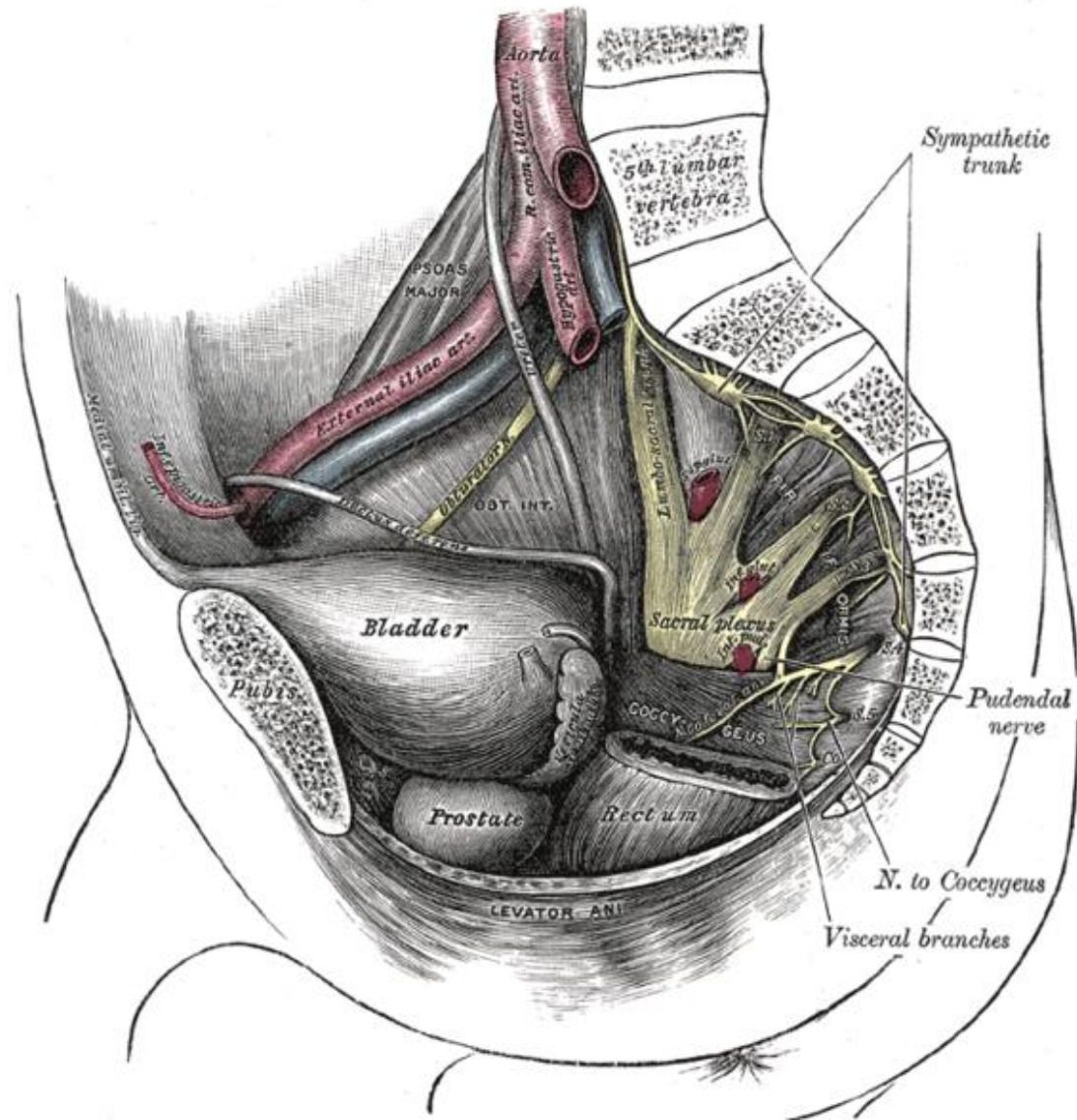
- 4 cm long
- 1 cm wide

origin: L4

- medial to m. psoas major
- dorsal to ureter

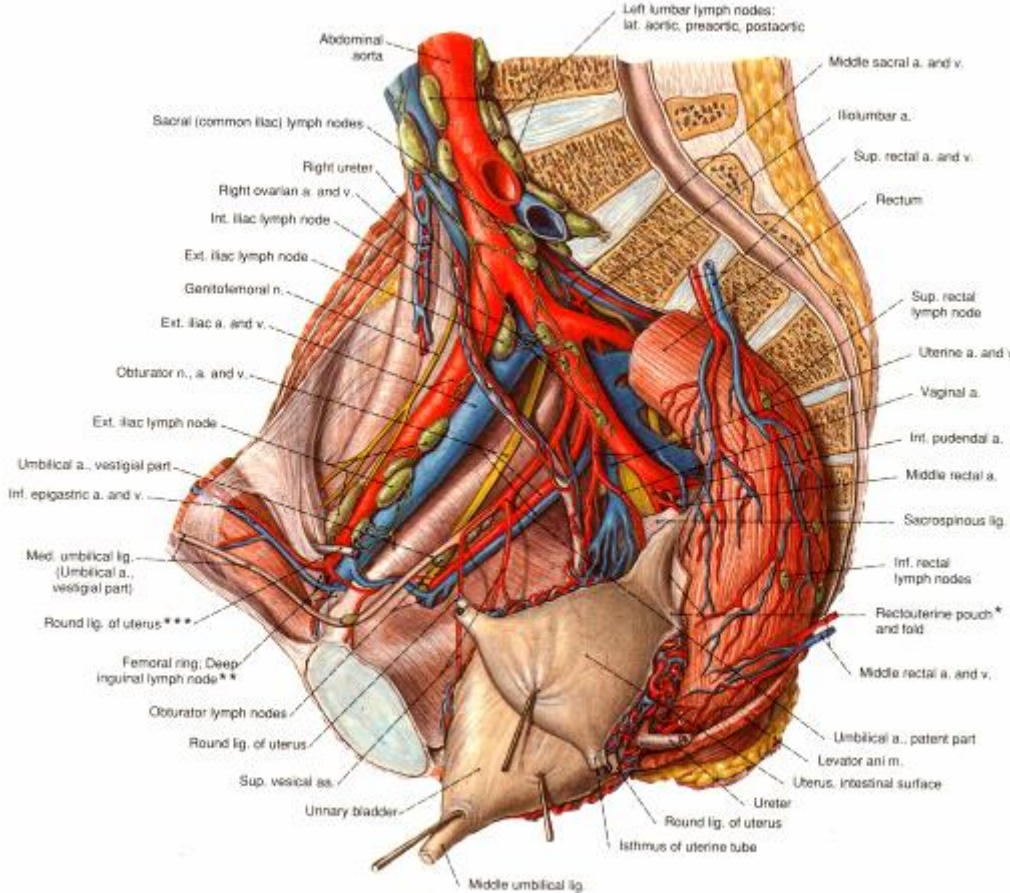
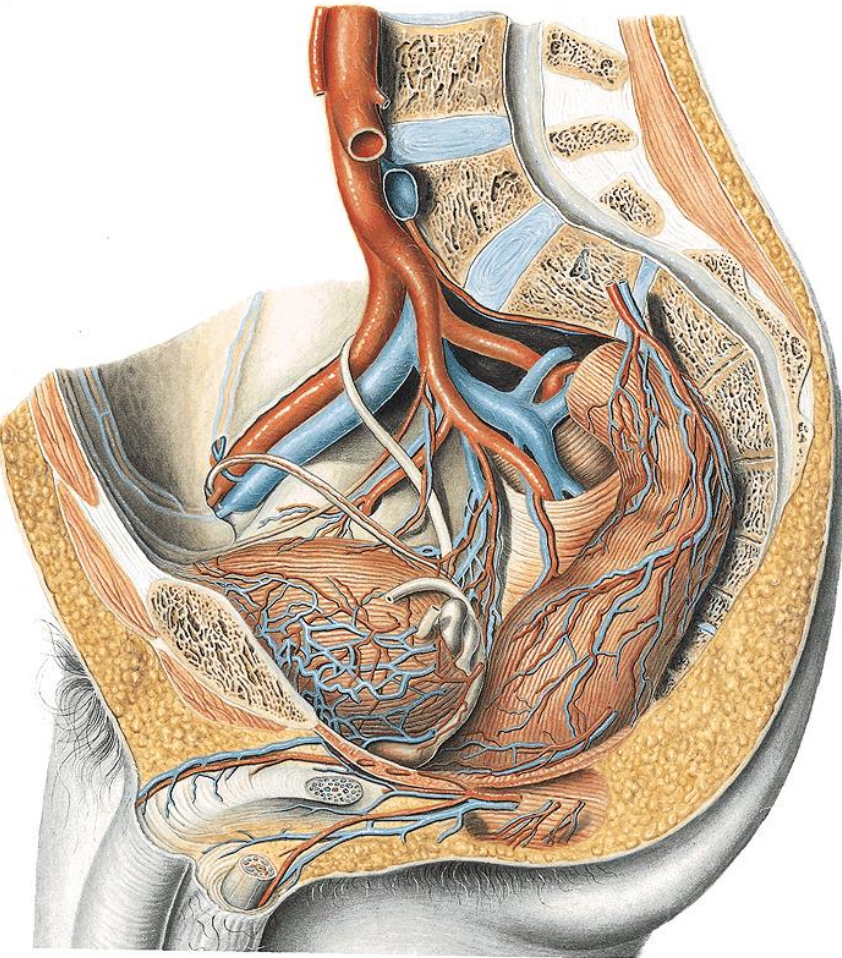
end: bifurcation ventral to articulatio sacroiliaca

- a. iliaca externa
- a. iliaca interna

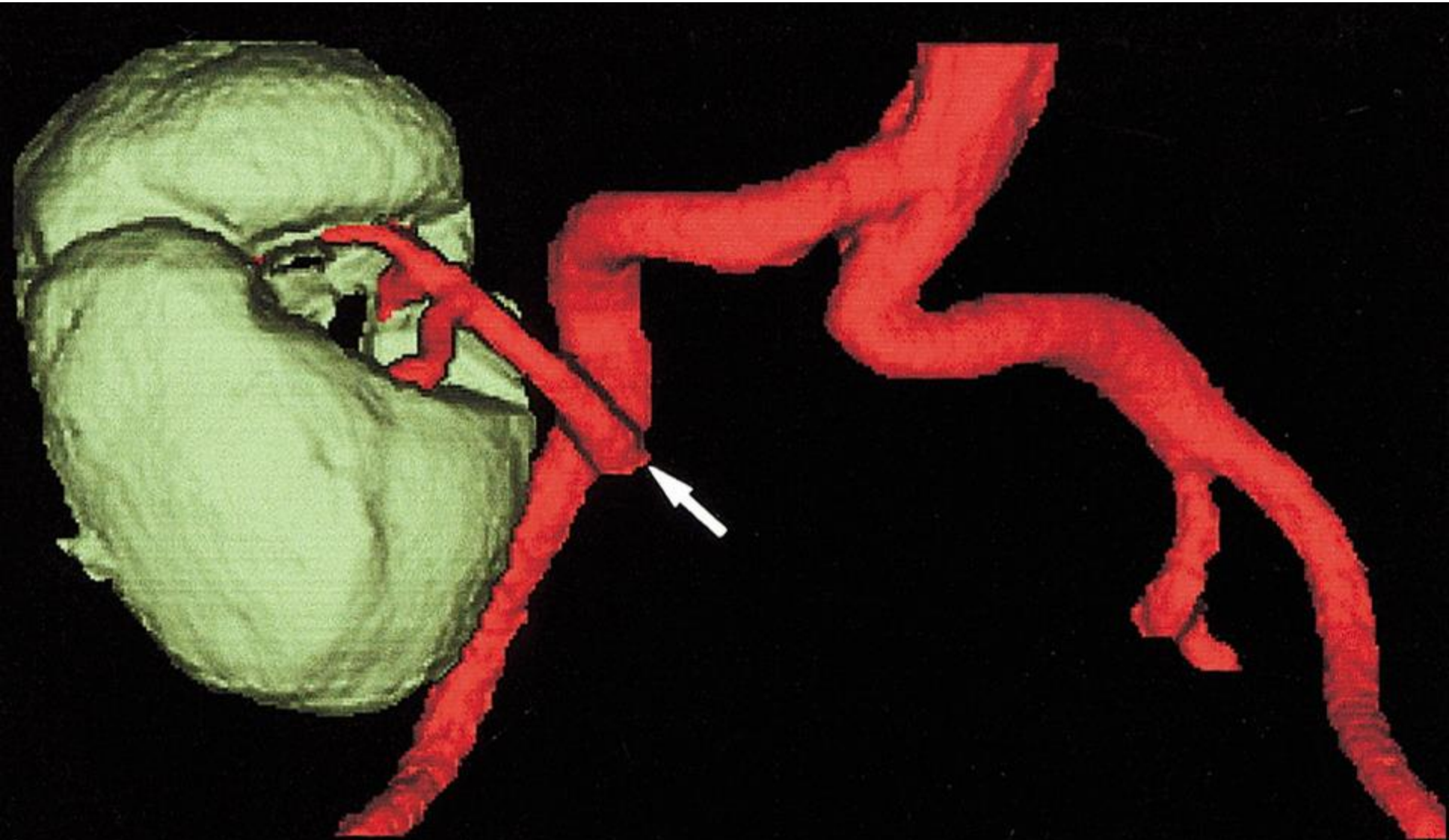




# Arteriae iliaca



# Transplanted kidney to AIC





# Arter

articul

ā

dorsal

ā

• ā

•

•

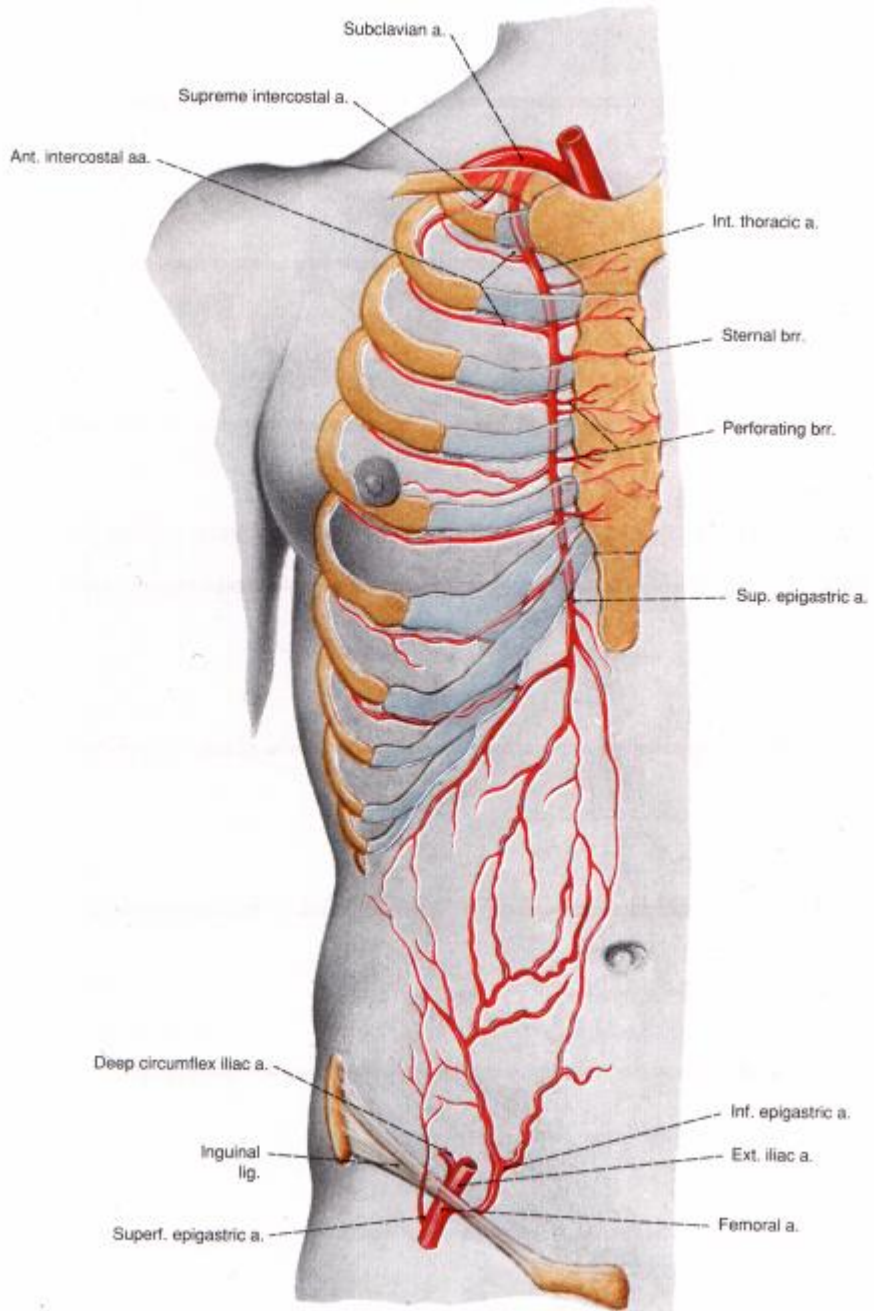
•

•

•

•

•

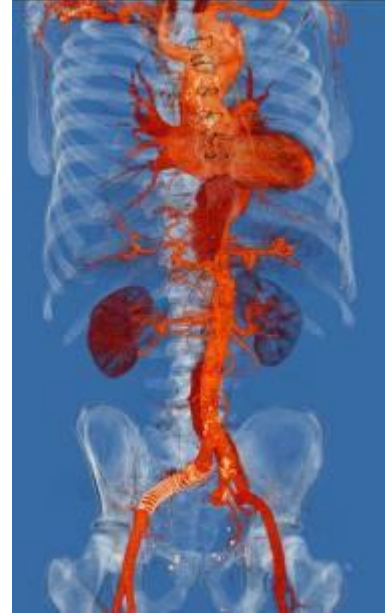
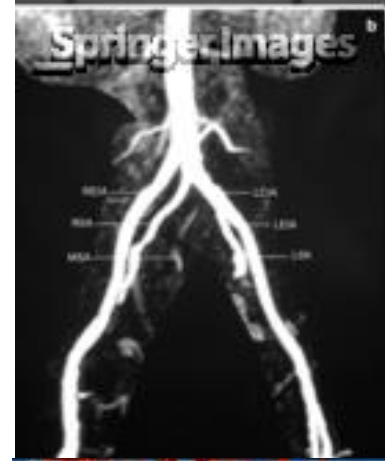
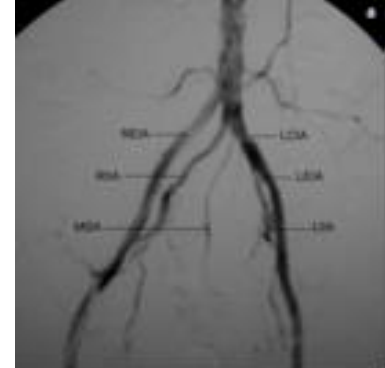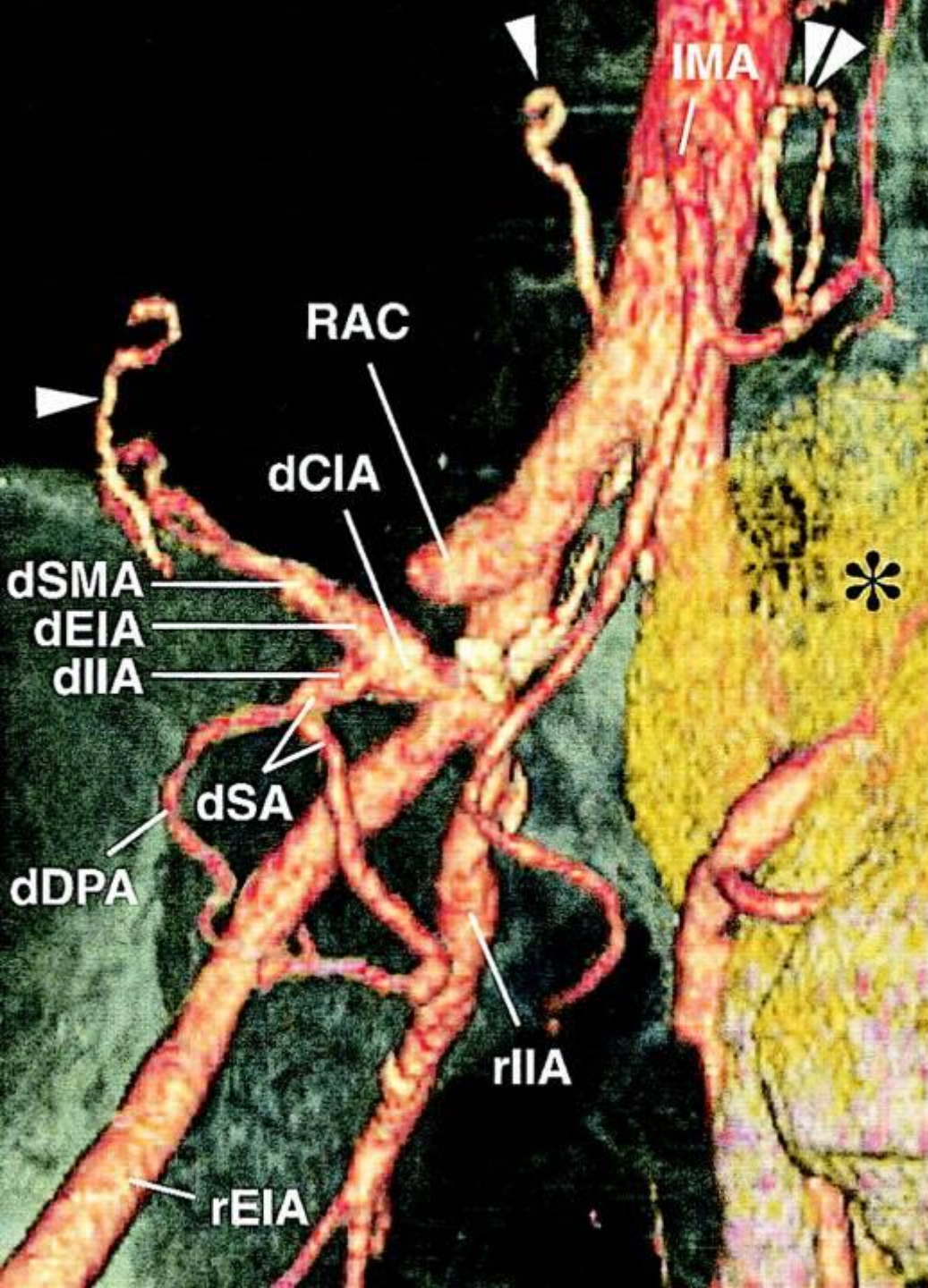
im (→

= corona

♀

S





## Two separate pancreas transplantations at different times

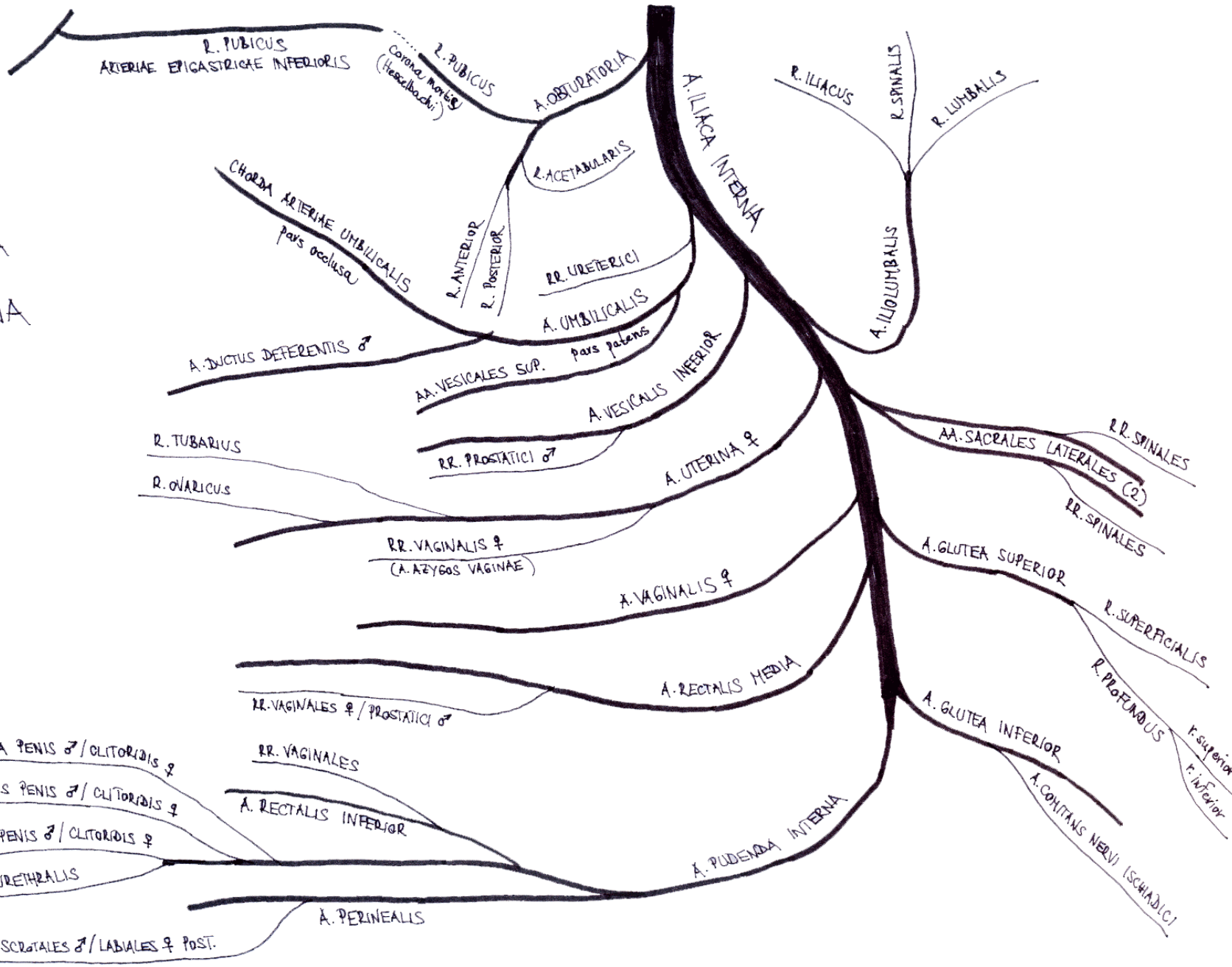
d = donor's, r = right, l = left

CIA = common iliac artery, CIVB = common iliac vein bifurcation, DPA = dorsal pancreatic artery, EIA = external iliac artery, IIA = internal iliac artery, IMA = inferior mesenteric artery, SA = splenic artery, SMA = superior mesenteric artery, asterisk = renal graft.

Three-dimensional volume-rendering image of contrast-enhanced MDCT during dominant arterial phase, obtained 5 days after sequential pancreas-after-kidney retransplantation after vascular failure and pancreatectomy of initial pancreatic graft, shows normal posttransplantation arterial anatomy, residual arterial conduit (RAC) after pancreatectomy of initial pancreatic graft, hyperdense staple line (*single arrowheads*) of donor's duodenum, and hyperdense circular staple line (*double arrowheads*) of duodenojejunostomy (intestinal wall structures and grafted pancreatic parenchyma are not seen because of applied electronic thresholds).

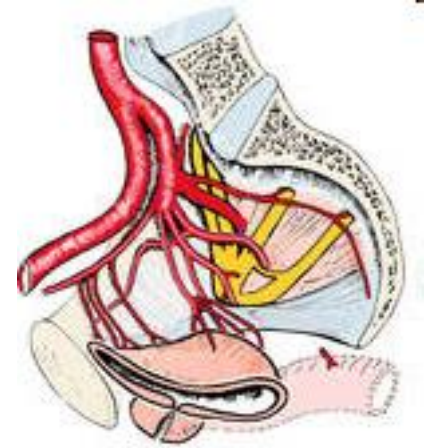


V  
 VEVE  
 ARTERIA  
 ILIACA  
 INTERNA



# Arteria iliaca interna

- lesser pelvis + buttocks
- obsolete term „a. hypogastrica“
- short (3-4 cm)
  - anterior division
    - 3 branches
  - posterior division
    - all organs of lesser pelvis
      - *ligation in postpartal haemorrhage*

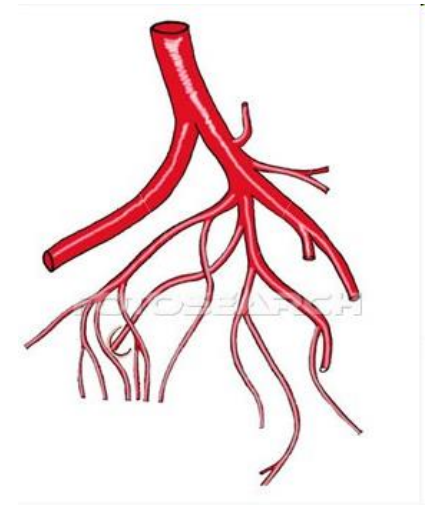




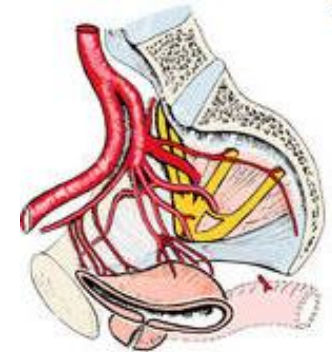
# Arteria iliaca interna - branches

## parietal branches: 5

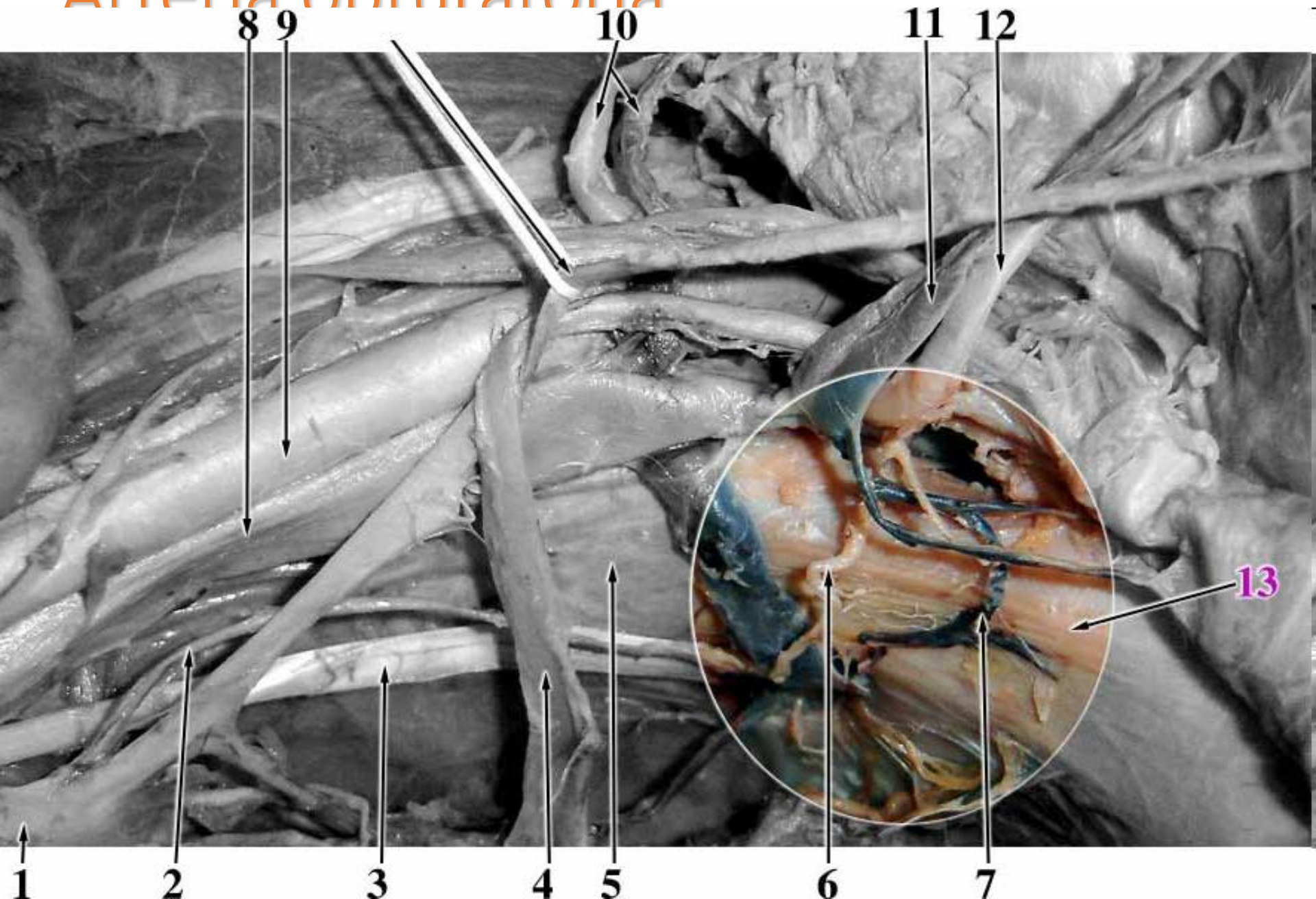
- a. iliolumbalis
  - r. iliacus, lumbalis, spinalis
- a. obturatoria
  - *canalis obturatorius*
- aa. sacrales laterales sup. + inf. (→2)
  - *foramina sacralia anteriora*
  - rr. spinales
- a. glutea superior
  - *foramen suprapiriforme*
  - r. superficialis + profundus
- a. glutea inferior
  - *foramen infrapiriforme*
  - a. comitans nervi ischiadici



gd304006 www.fotosearch.com



# Arteria obturatoria

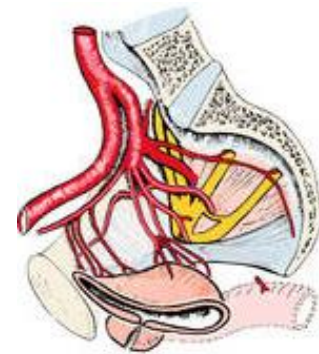
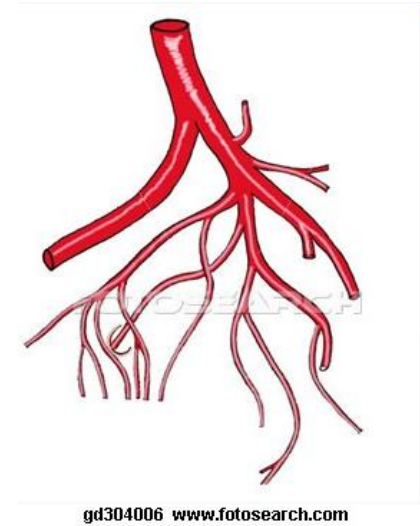




# Arteria iliaca interna - branches

## visceral branches: 6

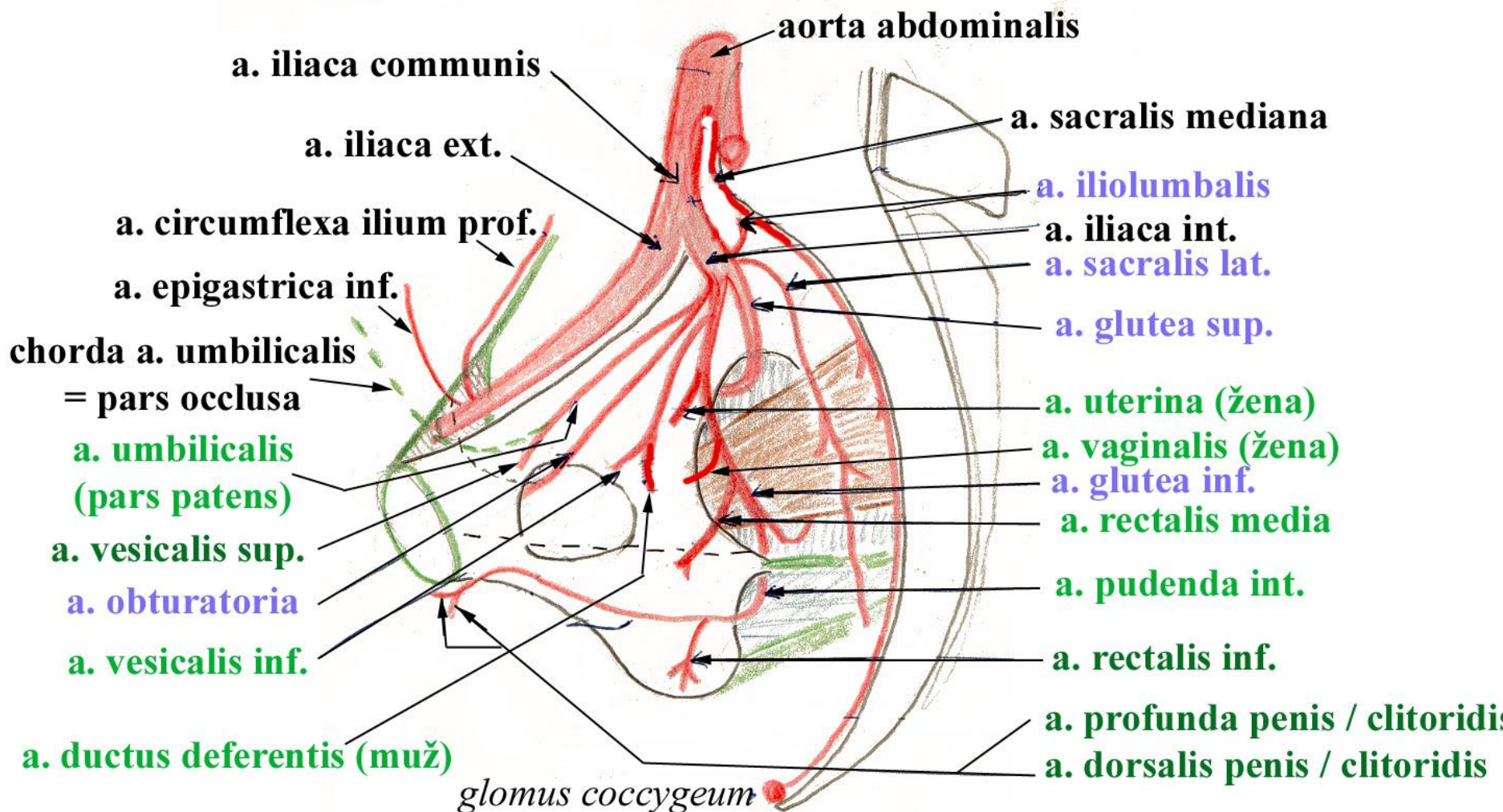
- a. umbilicalis
  - aa. vesicales superiores
  - a. ductus deferentis ♂
- a. vesicalis inferior
  - rr. prostatici ♂
- a. uterina ♀
  - r. ovaricus
  - r. tubarius
  - ventral to ureter
- a. rectalis media
  - rr. prostatici ♂ / rr. vaginales ♀
- a. vaginalis ♀
- a. pudenda interna



*parietální větve*

# TEPNY PÁNVE

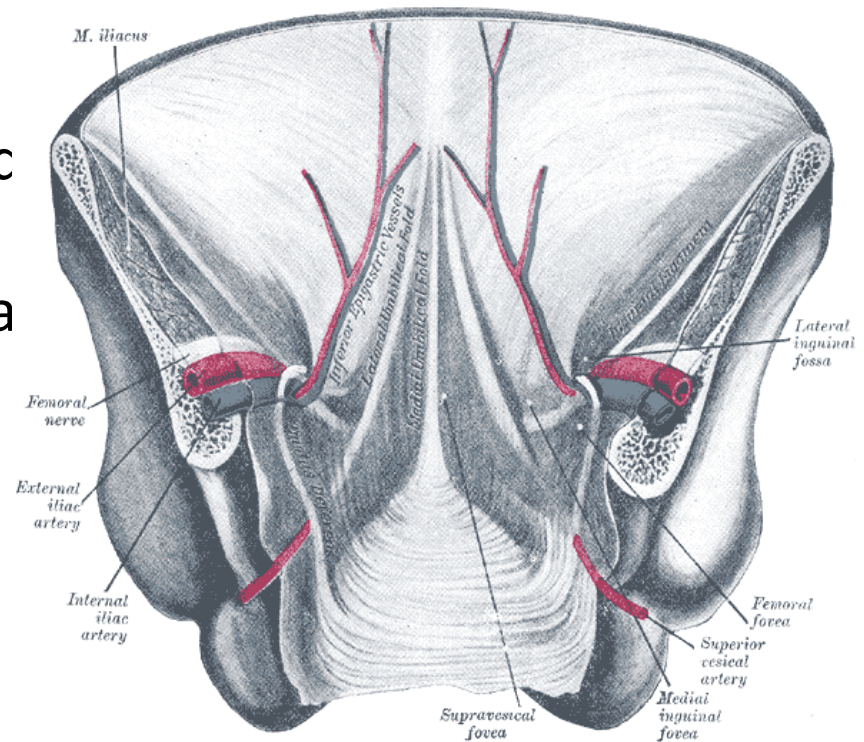
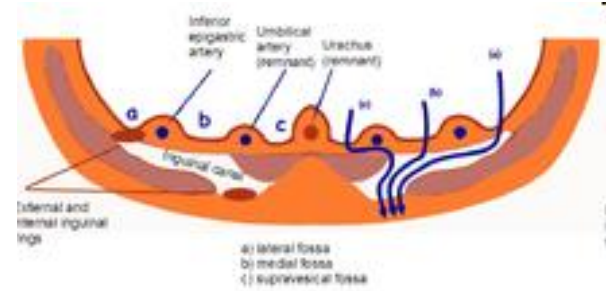
*viscerální větve*





# Arteria umbilicalis

- pars patens
  - aa. vesicales superiores
  - a. ductus deferentis ♂
- pars occlusa
  - fetal vessel with unoxygenated blood leading to placenta
  - lig. umbilicale mediale (chorda a. umbilicalis)
  - fascia vesicoumbilicalis





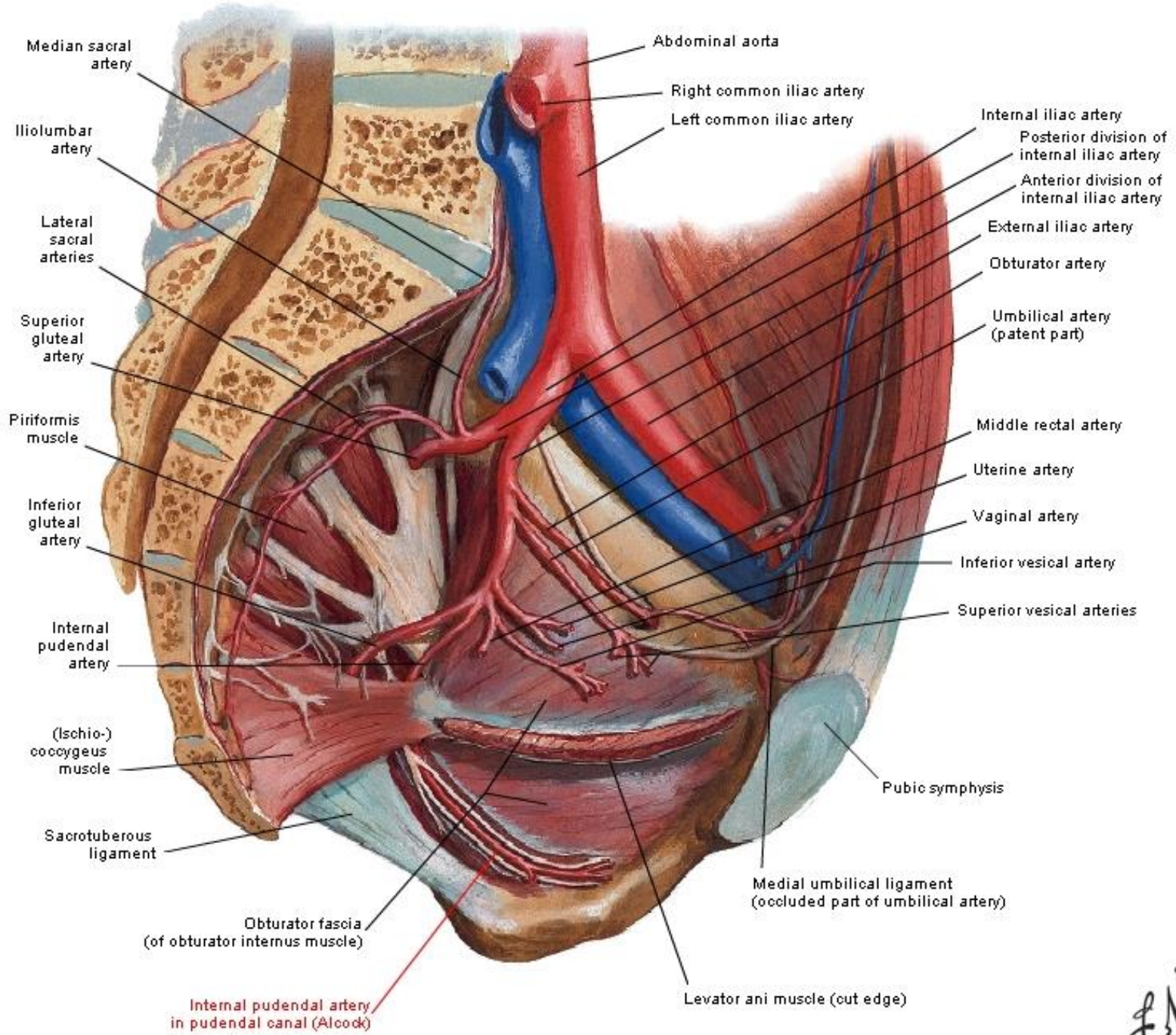


# Arteria pudenda interna

topography: foramen infrapiriforme → foramen ischiadicum minus → fossa ischioanalis (canalis pudendalis *Alcocki*)

branches:

- a. rectalis inferior
  - rr. vaginales ♀
- a. perinealis
- rr. scrotales ♂ / labiales ♀ anteriores
- a. urethralis
- a. bulbi penis ♂ / vestibuli ♀
- a. dorsalis penis ♂ / clitoridis ♀
- a. profunda penis ♂ / vestibuli ♀



Median sacral artery

Iliolumbar artery

Lateral sacral arteries

Superior gluteal artery

Piriformis muscle

Inferior gluteal artery

Internal pudendal artery

(Ischio-) coccygeus muscle

Sacrotuberous ligament

Obturator fascia (of obturator internus muscle)

Internal pudendal artery in pudendal canal (Alcock)

Abdominal aorta

Right common iliac artery

Left common iliac artery

Internal iliac artery

Posterior division of internal iliac artery

Anterior division of internal iliac artery

External iliac artery

Obturator artery

Umbilical artery (patent part)

Middle rectal artery

Uterine artery

Vaginal artery

Inferior vesical artery

Superior vesical arteries

Pubic symphysis

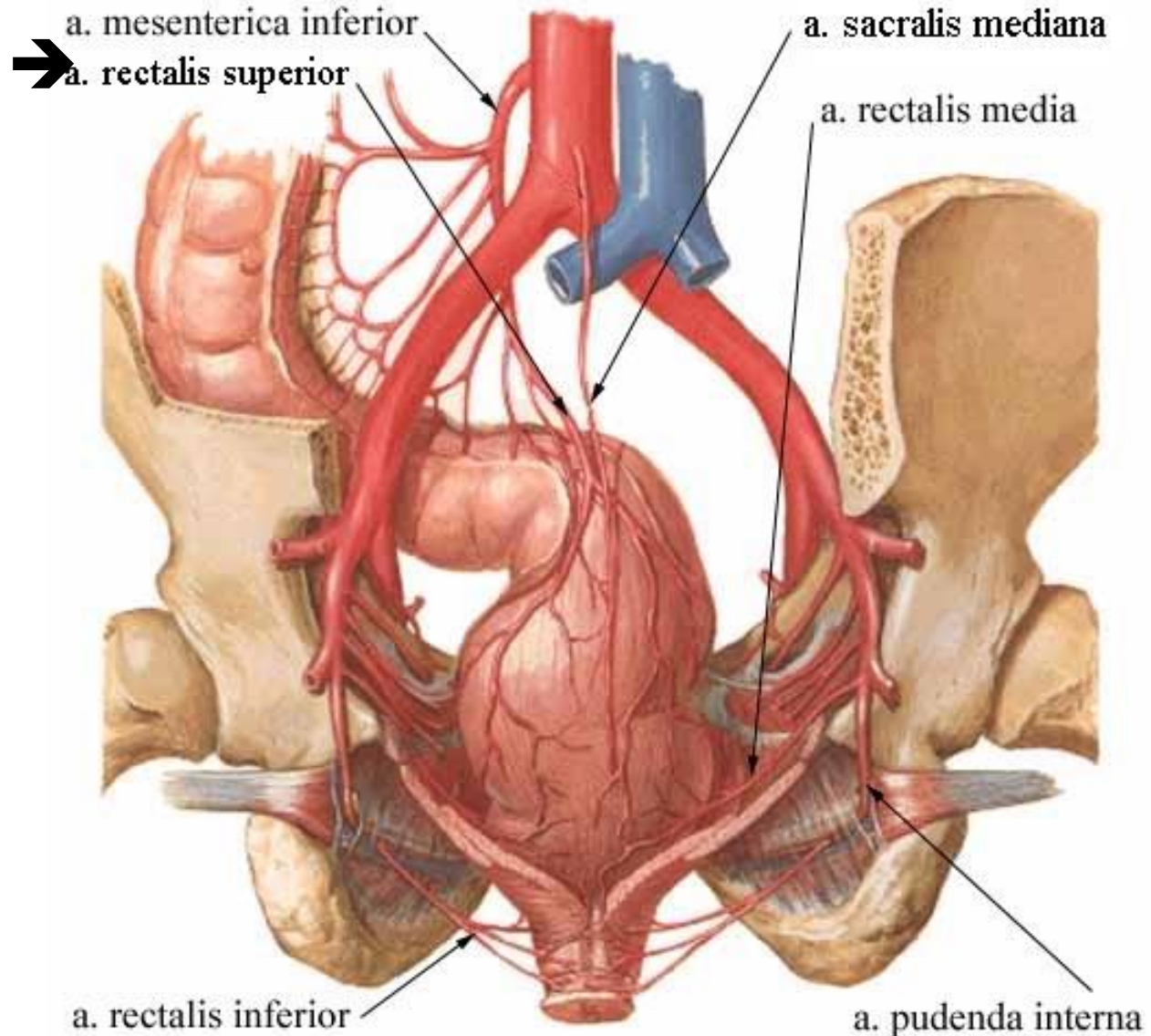
Medial umbilical ligament (occluded part of umbilical artery)

Levator ani muscle (out edge)



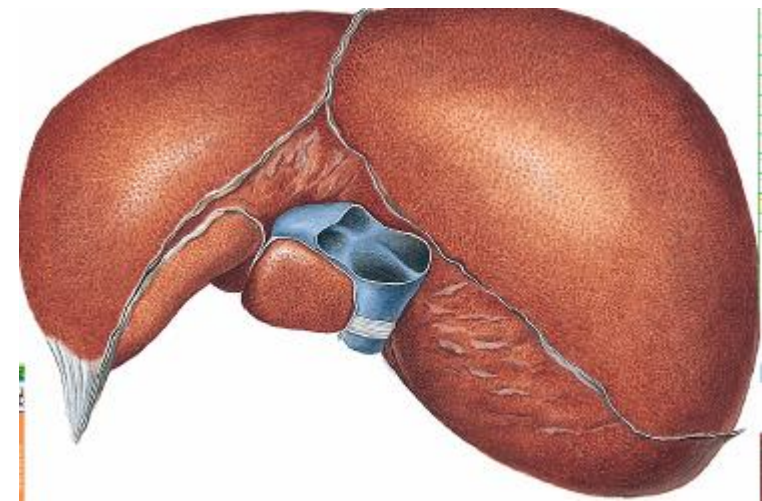
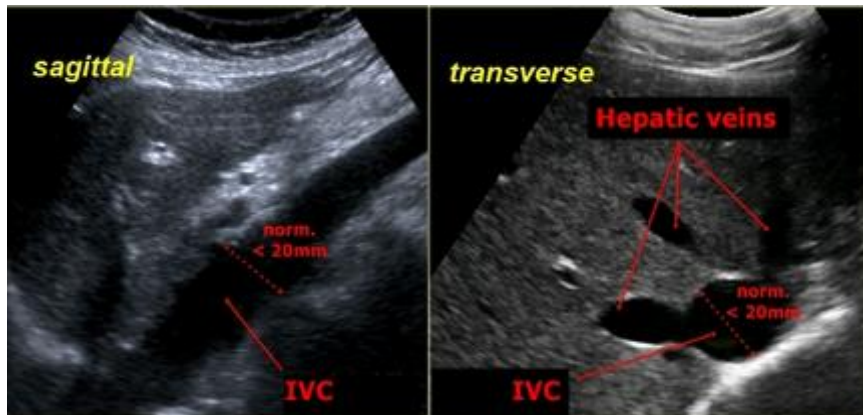
# Rectum

- a. mesenterica inf. → a. rectalis sup.
- a. iliaca int. → a. rectalis media
  - present in 50%, insignificant for rectum
- a. iliaca int. → a. pudenda int. → a. rectalis inf



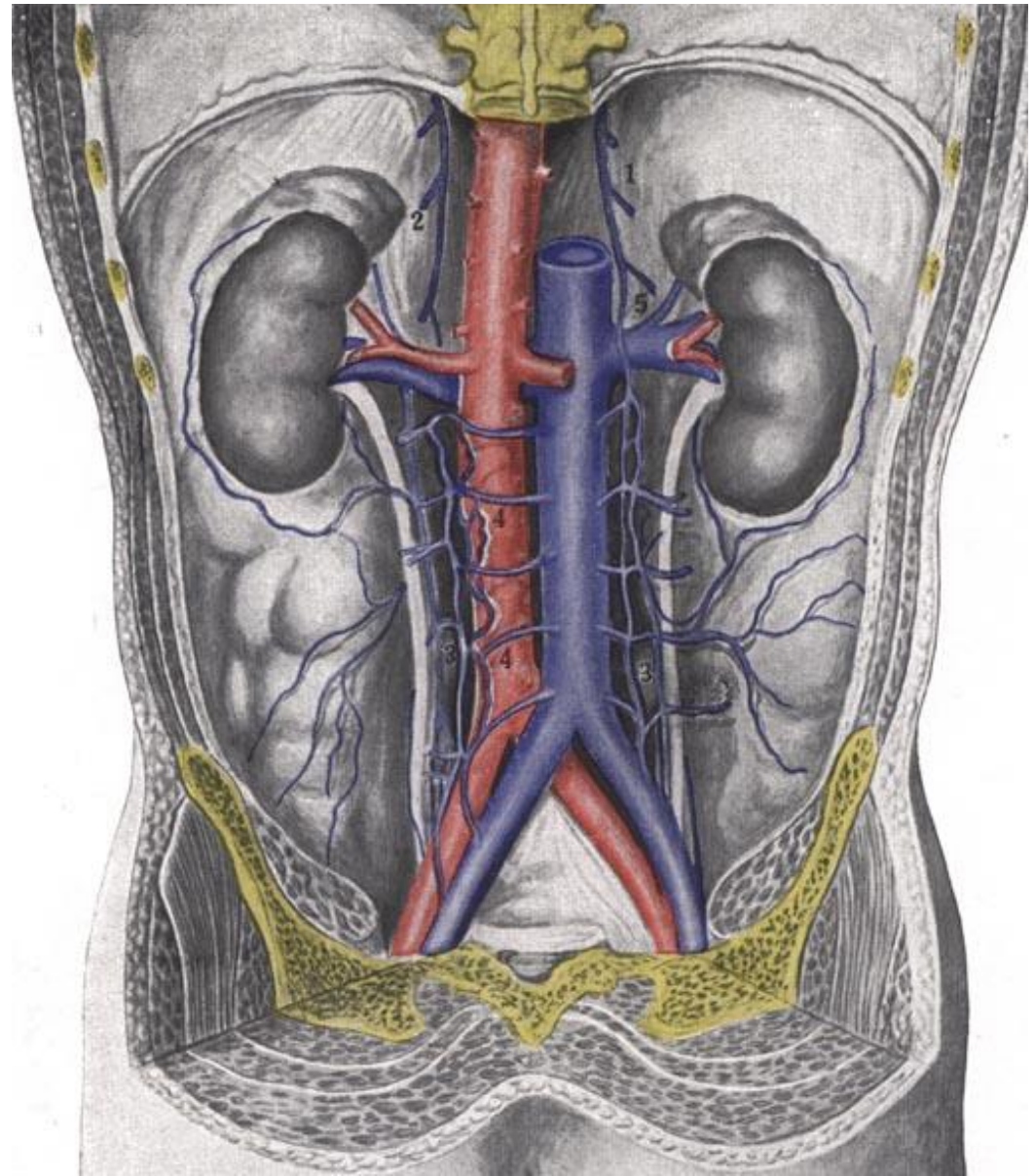
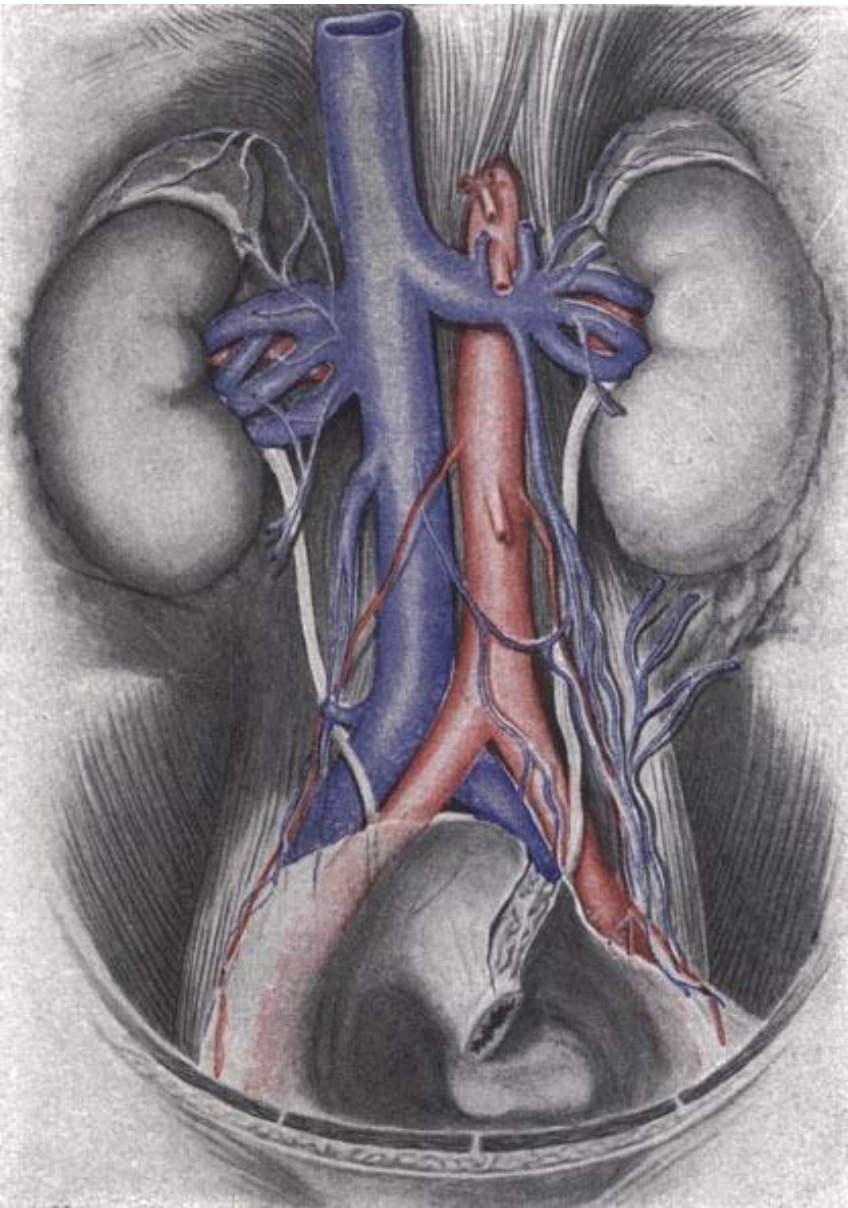
# Vena cava inferior

- origin: confluence of vv. iliaca communes (L4)
- right to aorta abdominalis, in retroperitoneum
- no valves, rarely doubled
- sulcus venae cavae hepatis
- foramen venae cavae diaphragmatis
- caliber: 2 cm at liver, 3.5 cm at heart
- end: atrium dextrum (T8)





# Vena cava inferior

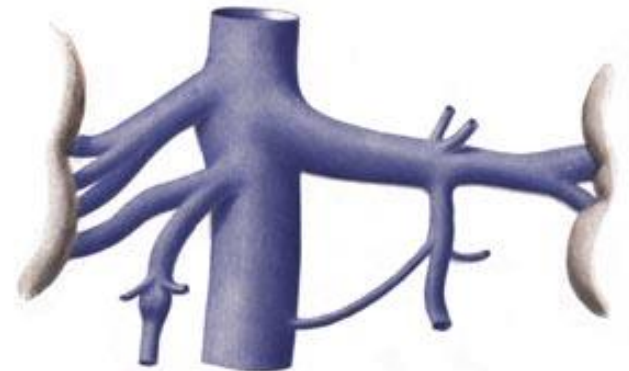
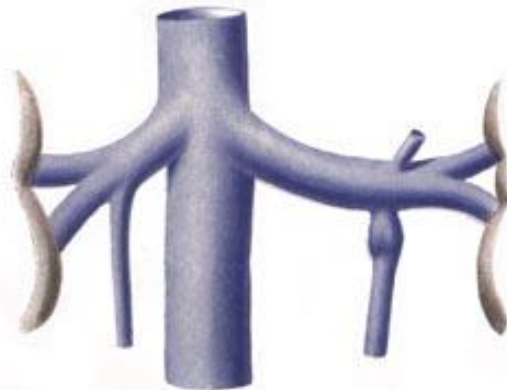
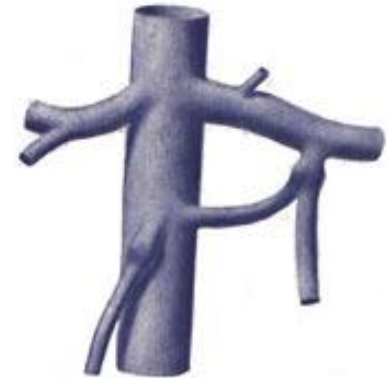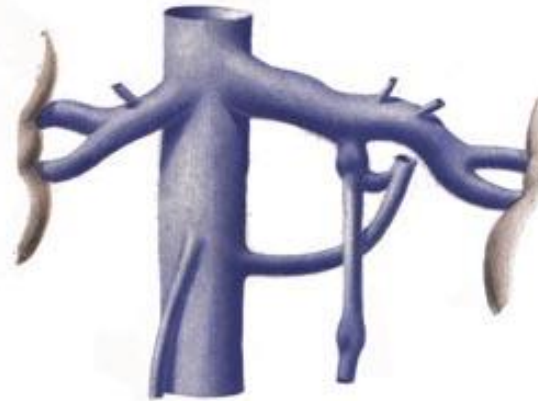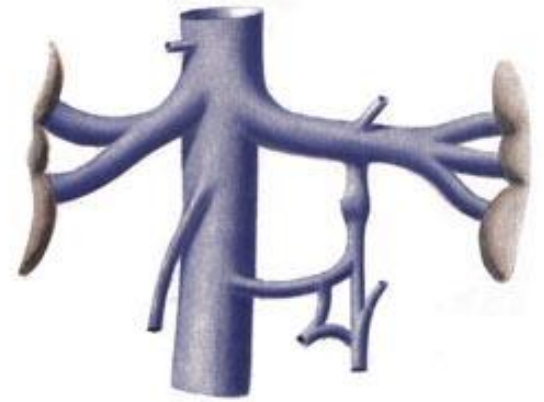
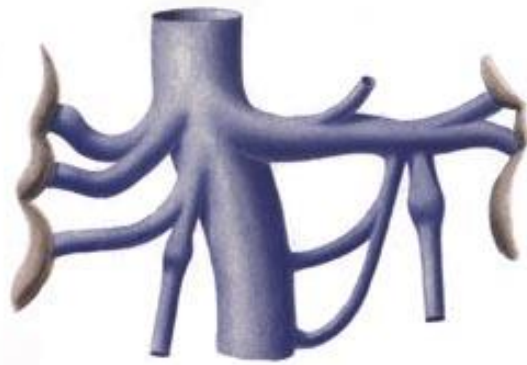


# Vena cava inferior - tributaries

- variation of VCI course, arrangement and tributaries
- parietal:
  - vv. iliacae communes, vv. lumbales I-IV (*interconnected with v. lumbalis ascendens*), vv. phrenicae inf., v. sacralis mediana
- visceral:
  - vv. renales
  - v. testicularis ♂ / ovarica dx. ♀ (begins as plexus pampiniformis)
  - v. suprarenalis dx.
  - vv. hepaticae dextra, intermedia, sinistra (ductus venosus *Aranzii*)

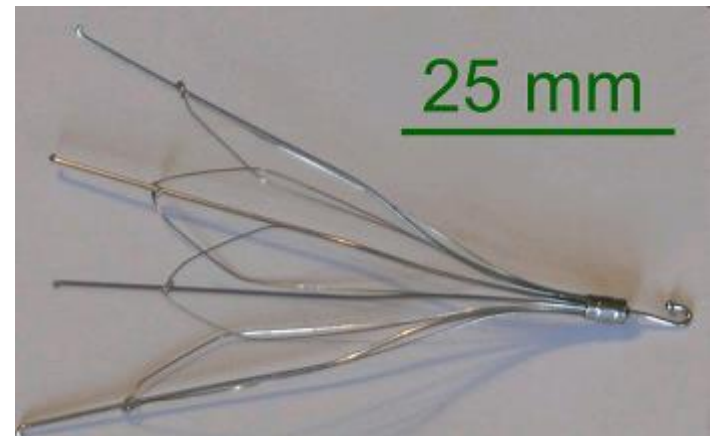
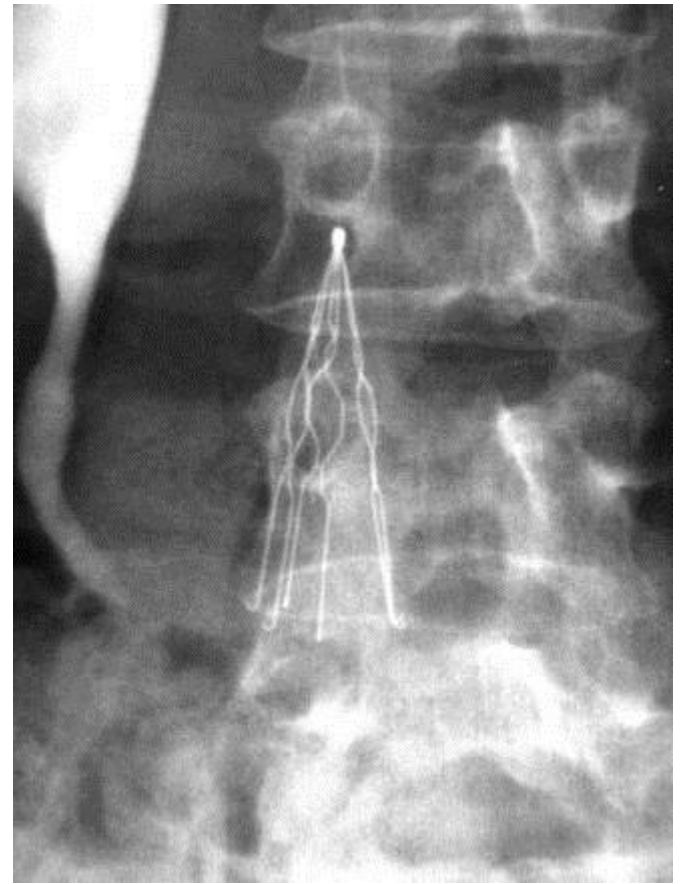


Variability of formation of VCI visceral tributaries




# VCI – clinical relevance

- compression
  - aortal aneurysm
  - pregnant uterus
  - abdominal tumours
- thrombosis
- prevention of fatal pulmonary embolism – Greenfield's filter
  - in venous thromboembolic disease + contraindication of anticoagulation treatment



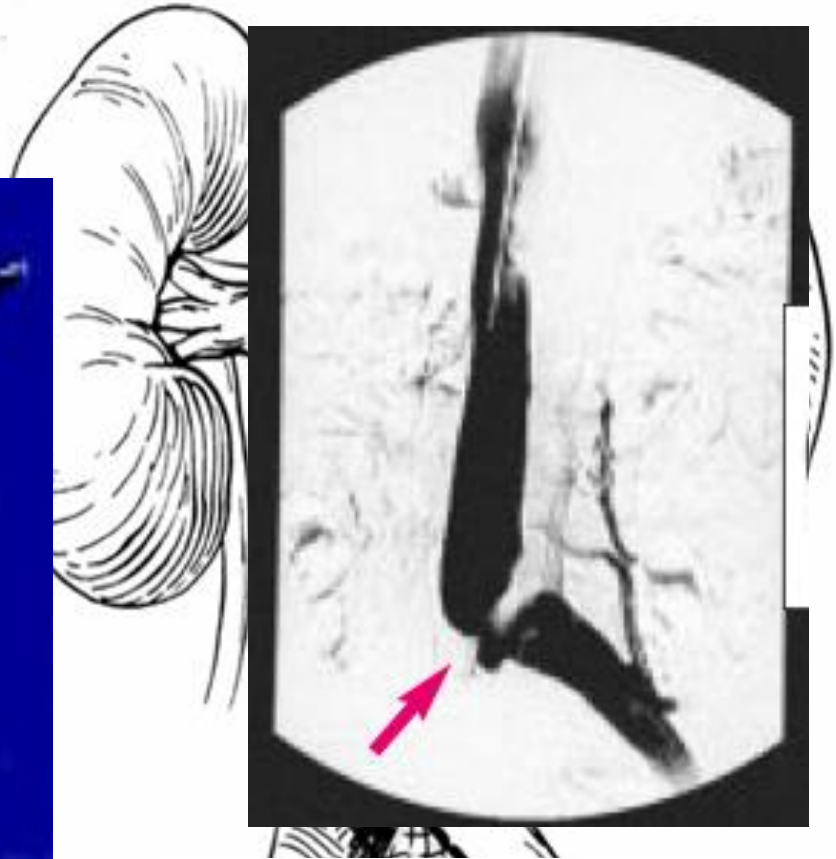

# Vena iliaca communis



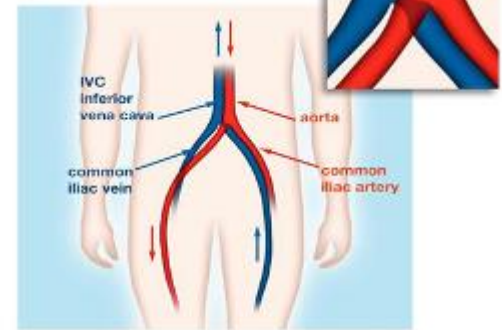
(AICdX.)

- thrombosis follows
- treatment: stent



## May-Thurner syndrome

Narrowed left iliac vein  
(by pressure from right iliac artery)

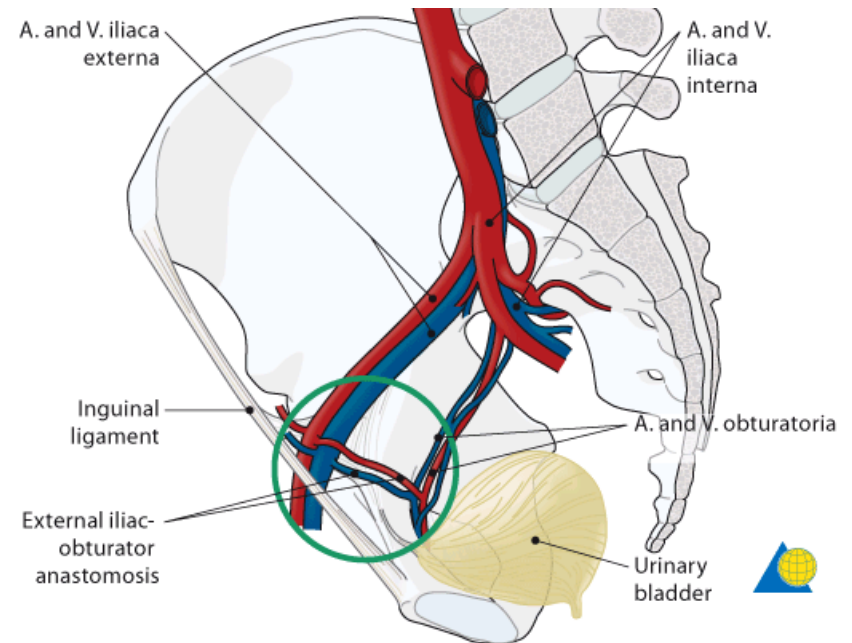
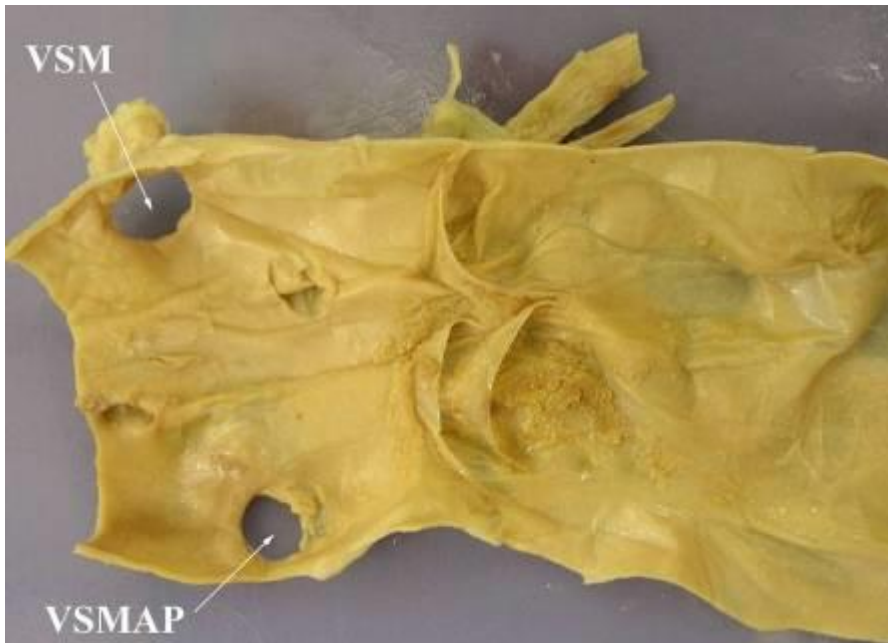

Graphic: Anatomic Art Partners, Washington, DC

© 2004/2005, LLC

# Vena iliaca externa

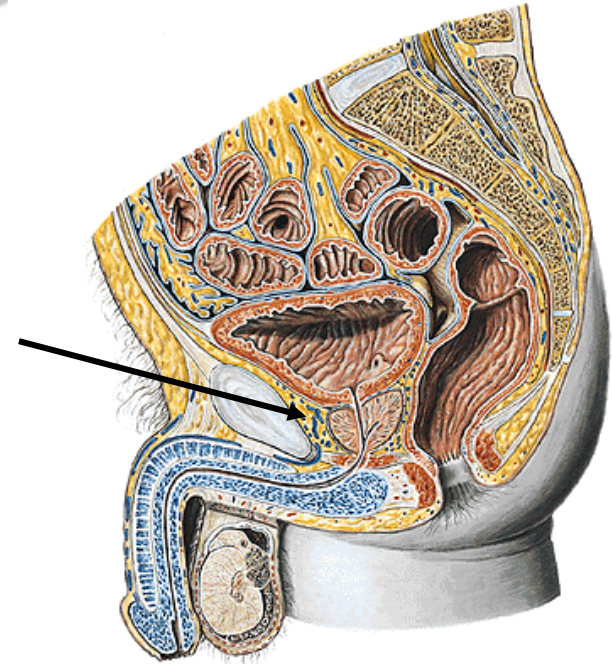
- branches correspond to arterial
- venous corona mortis present in 75%
- valves present in 20%
  - usually rudimentary





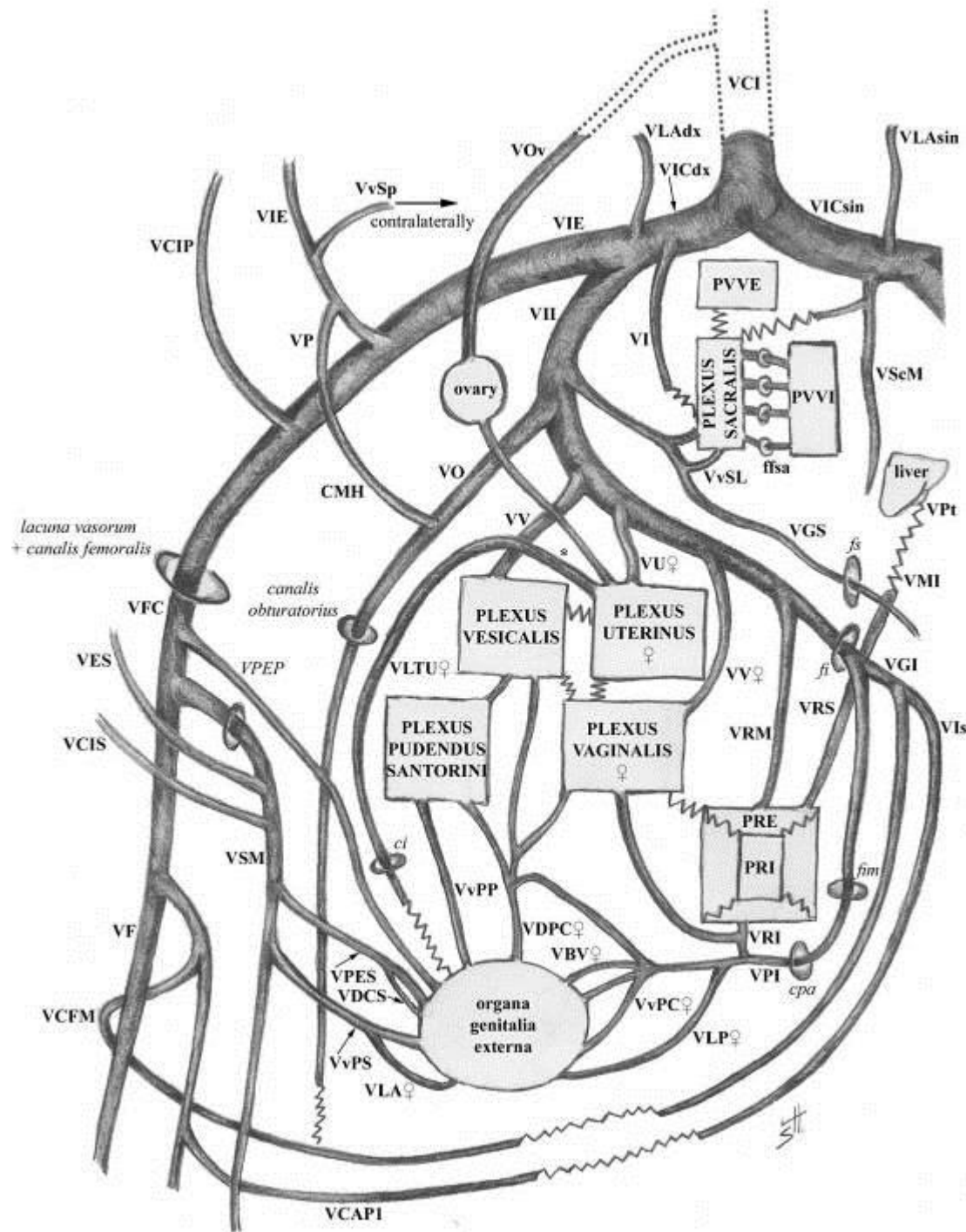
# Vena iliaca interna – pelvic veins

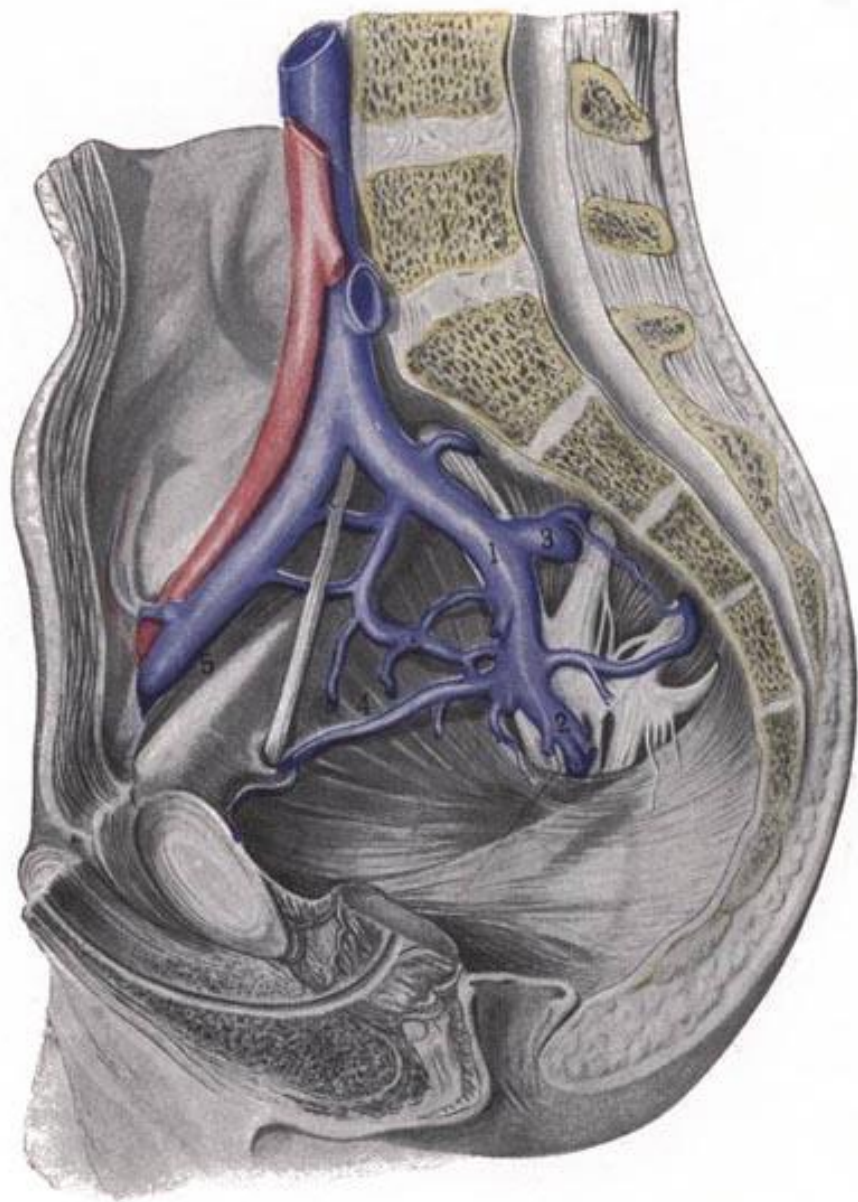
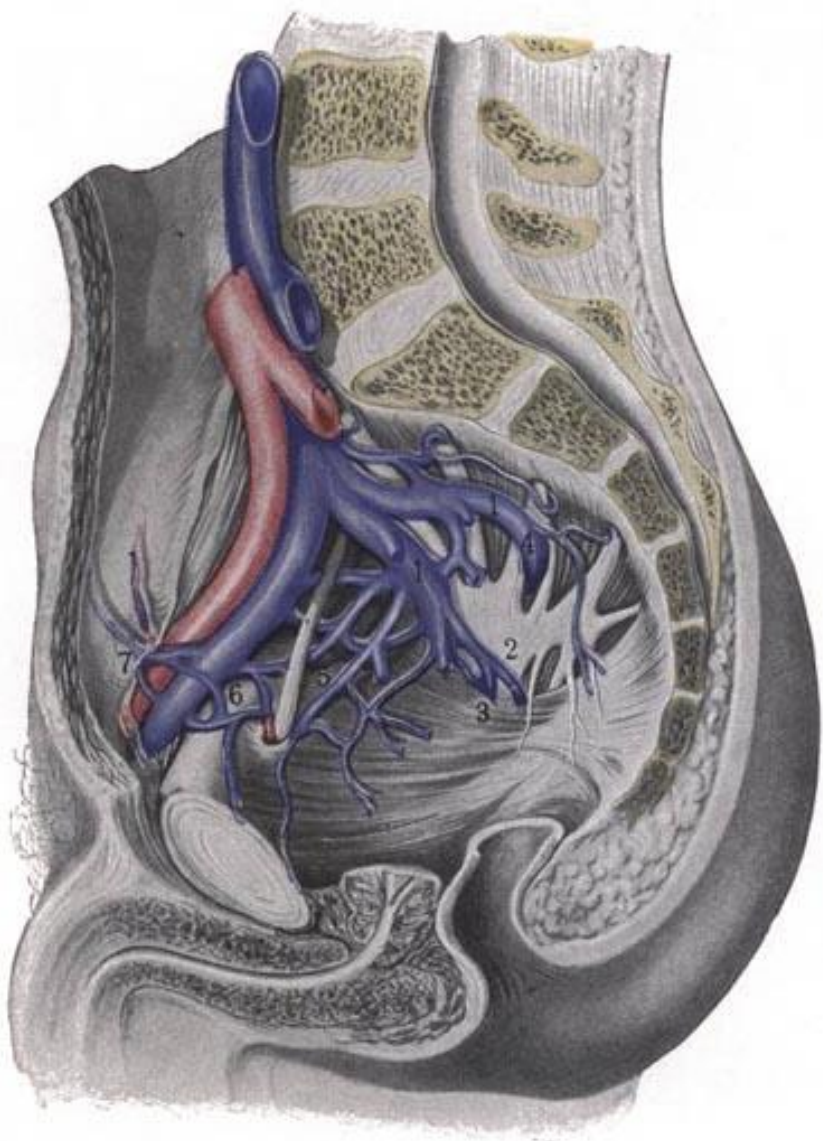
- *parietal*: correspond to arteries
- *visceral*: plexuses
  - plexus venosus pudendus (*Santorini*)
    - within spatium retropubicum (*Retzii*)
  - p.v. vesicalis + prostaticus
  - p.v. uterinus + vaginalis (uterovaginalis)
  - p.v. rectalis
    - p.v. rectalis externus (within tunica adventitia)
    - p.v. rectalis internus = p. haemorrhoidalis (within tunica submucosa)
  - p.v. sacralis (interconnected with vv. sacrales lat. + mediana)



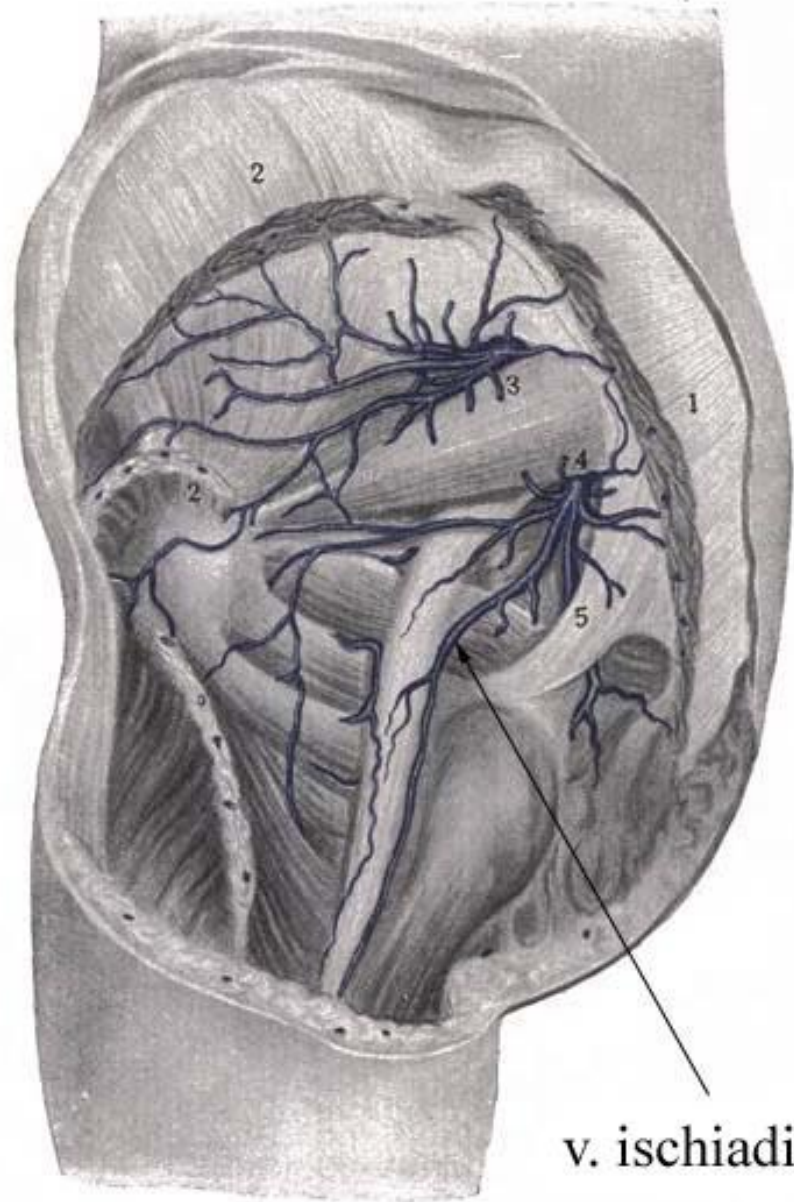
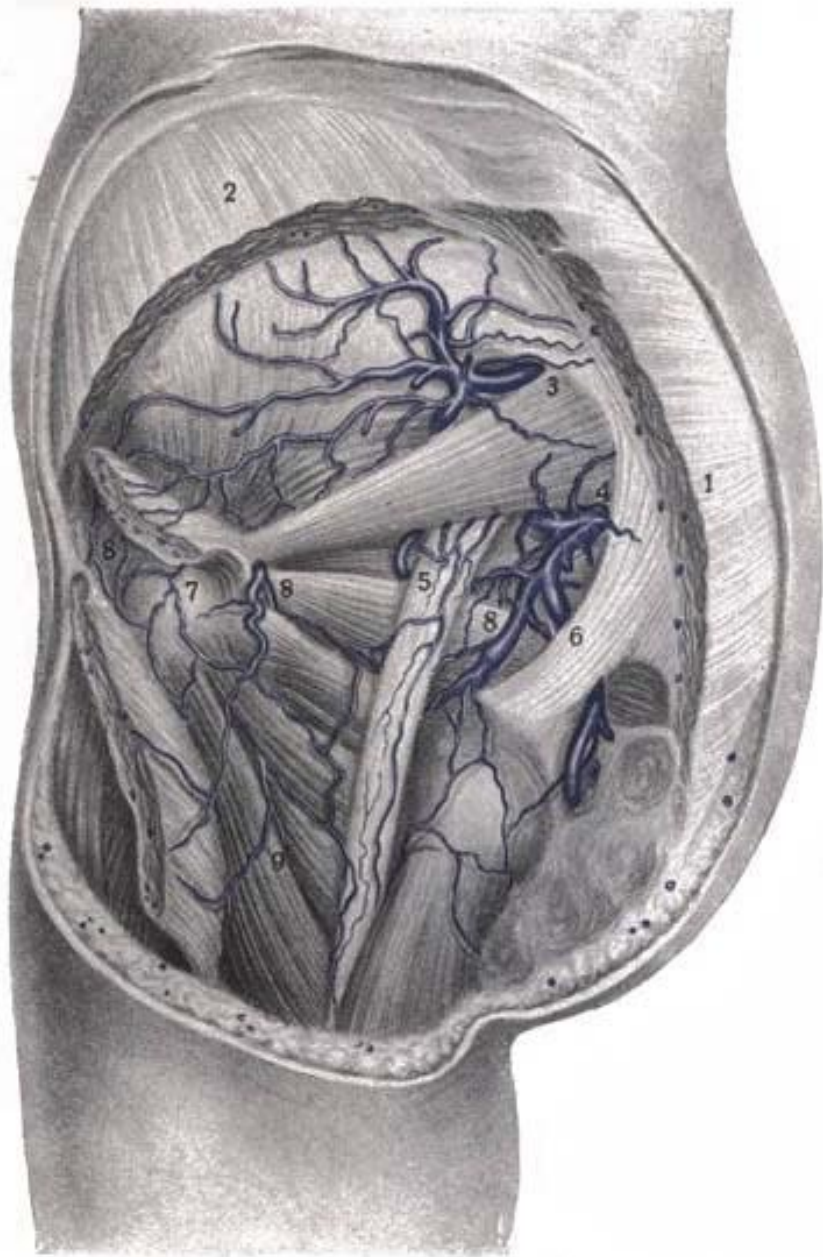# Veins of pelvis

- v. lig. teretis uteri ♀
- vv. lig. lati uteri ♀
- vv. suprapubicae
- v. ischiadica



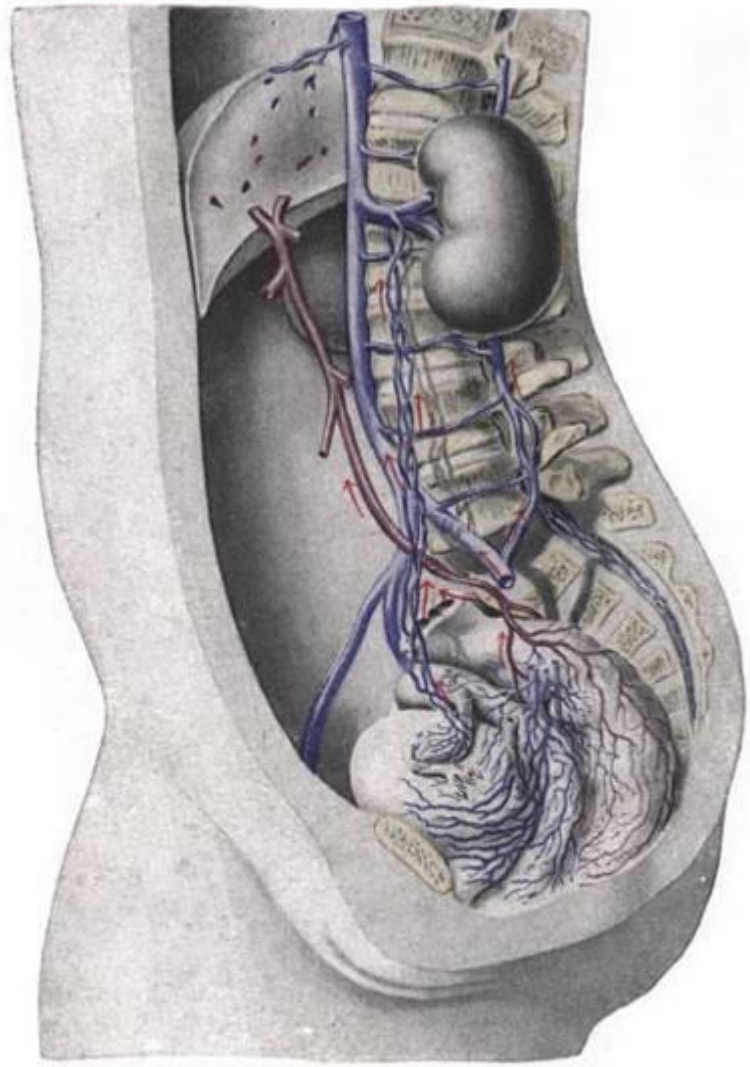
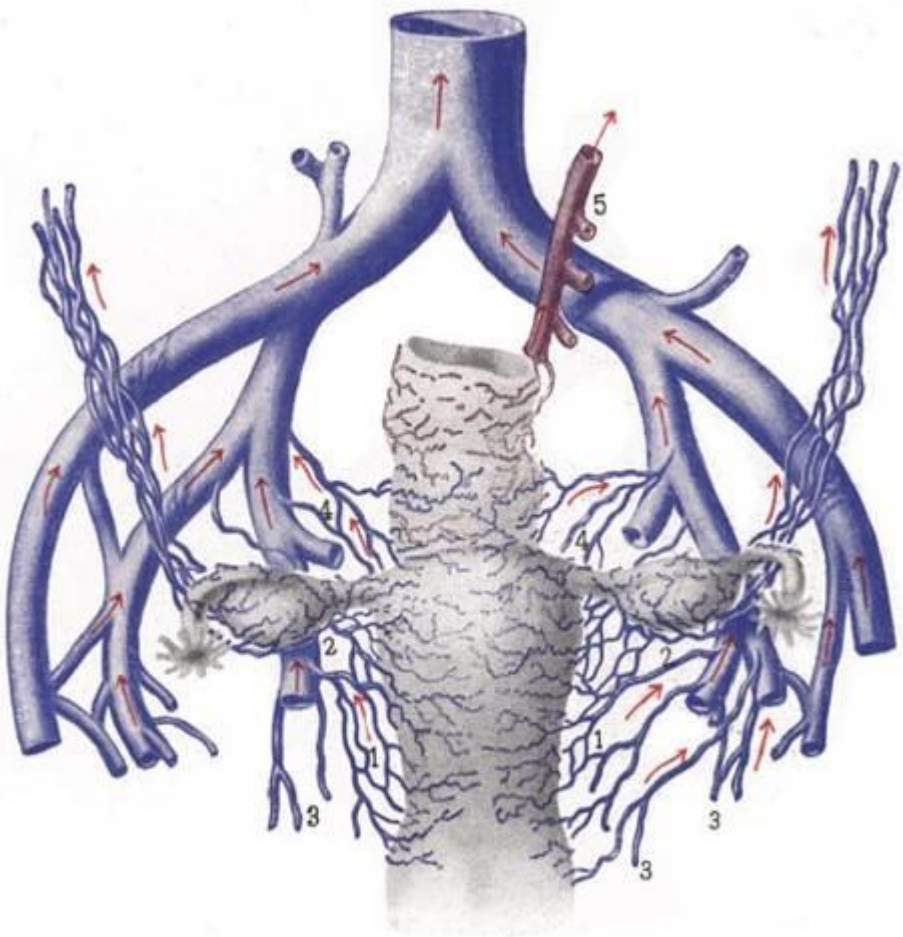






v. ischiadica

# Direction of venous outflow from pelvis



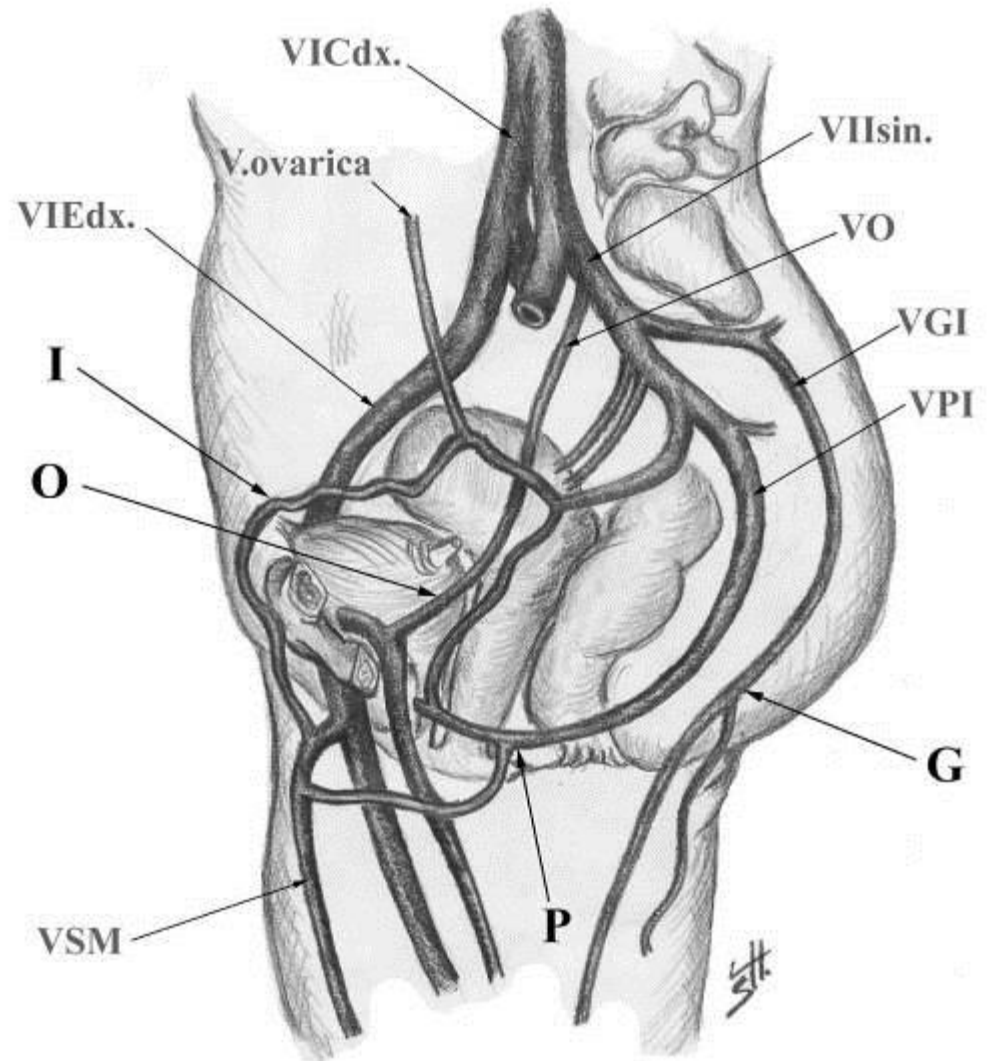
# Veins of pelvis – clinical relevance

- pelvis fractures → heavy bleeding
- slowed blood flow → thrombosis → embolism
- uptake of calcium in thrombi → phleboliths (visible in X-ray snaps)
- pelvic varices – connections with LL veins
- v.iliaca int. and its tributaries are not moveable → easy bleeding and difficult closure in surgery



# Site of connections between pelvic and LL veins

- canalis inguinalis
- canalis obturatorius
- foramen infrapiriforme
- perineum
- *change of flow direction in varices*



# Cavo-caval anastomoses

VCI

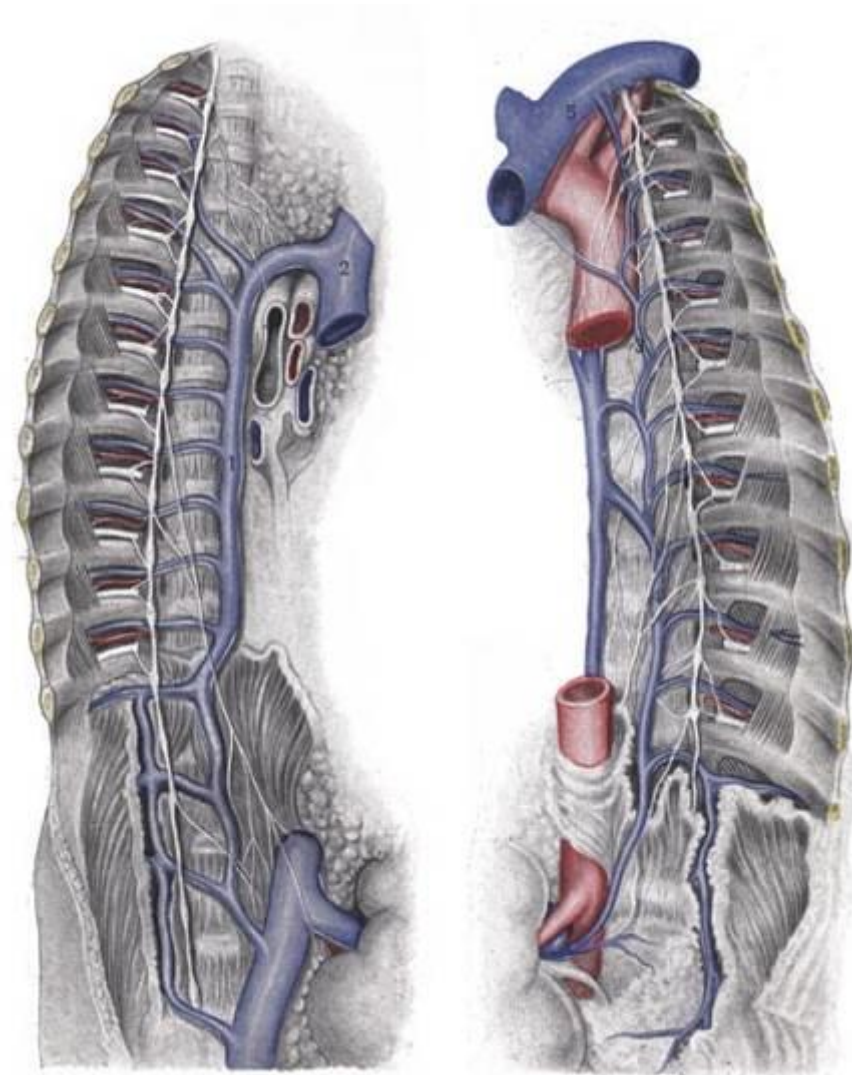
VCS

- vv. lumbales – v. azygos + hemiazygos
- v. epigastrica inf. – v. epigastrica sup.
- v. epigastrica spf. – vv. thoracoepigastricae
- plexus venosi vertebrales (*Batson's*)

# Vena azygos system

## v. azygos + hemiazygos

- accompany aorta thoracica
- no valves
- mediastinum posterius inferius → m. superius
- origin: v. lumbalis ascendens + v. subcostalis
- pass through diaphragm: via pars lumbalis or hiatus aorticus
- end: v. hemiazygos opens into do v. azygos at level of T7-9
- v. azygos opens into VCS
  - arcus v. azygos



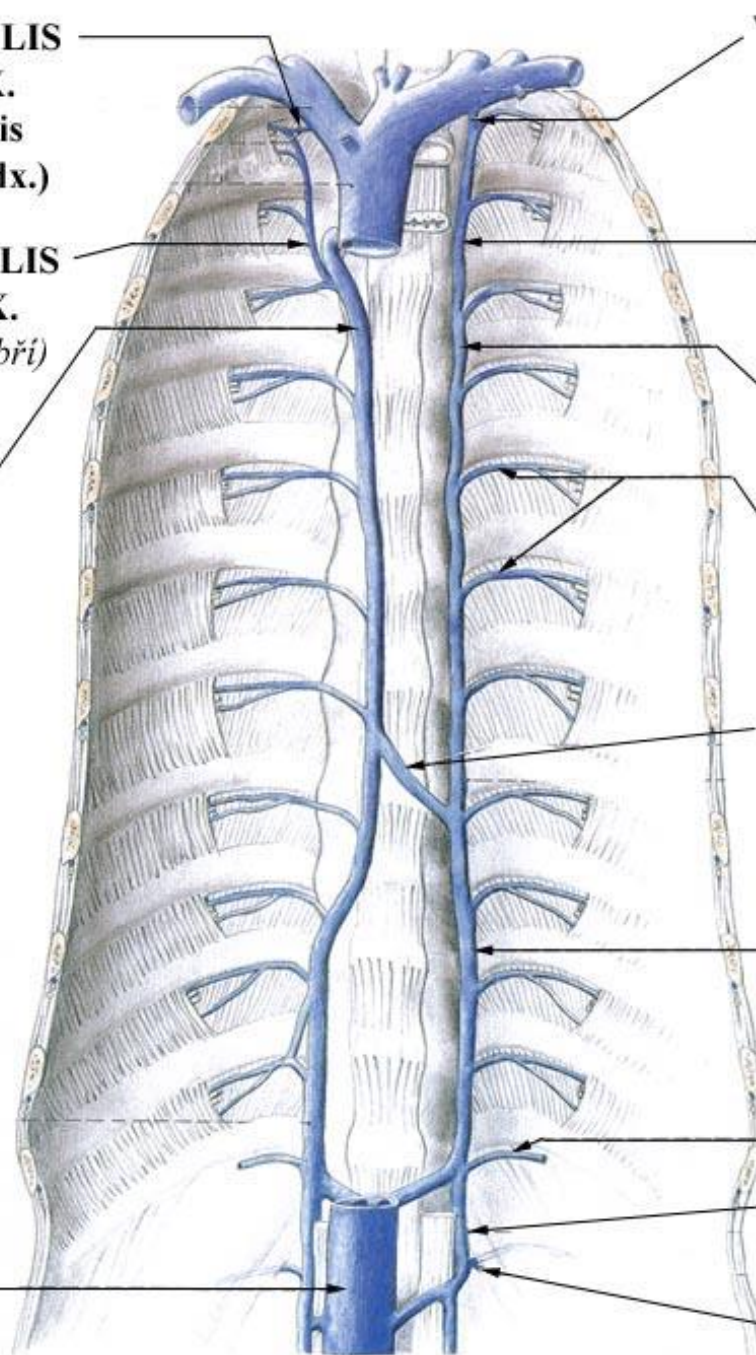


**V. INTERCOSTALIS  
SUPREMA DX.**  
(= v. intercostalis  
posterior prima dx.)

**V. INTERCOSTALIS  
SUPERIOR DX.**  
(pro 2. - 3. mezižebří)

**V. AZYGOS**

**VENA CAVA  
INFERIOR**



**V. INTERCOSTALIS  
SUPREMA SIN.**  
(= v. intercostalis  
posterior prima sin.)

**V. INTERCOSTALIS  
SUPERIOR SIN.**  
(pro 2. - 4. mezižebří)

**V. HEMIAZYGOS  
ACCESSORIA**

**VV. INTERCOSTALES  
POSTERIORES**

**V. HEMIAZYGOS**

**V. HEMIAZYGOS**

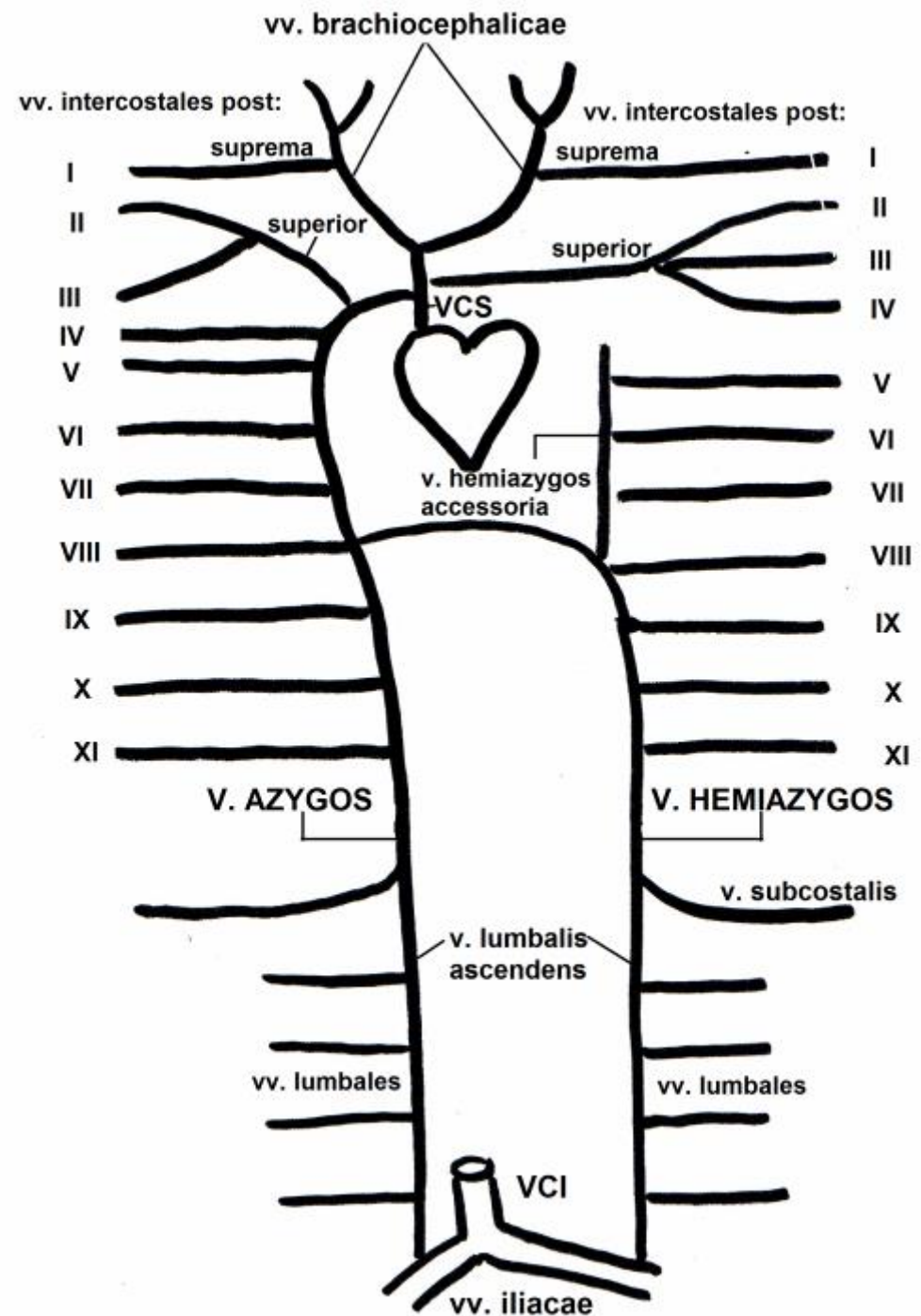
**V. SUBCOSTALIS**

**V. LUMBALIS  
ASCENDENS**

**V. LUMBALIS  
PRIMA**


# Tributaries of vena azygos system

- parietal:
  - vv. intercostales posteriores
  - v. intercostales sup. dx.
  - v. hemiazygos accessoria
  - vv. phrenicae sup.
- visceral:
  - vv. oesophageales, bronchiales, mediastinales

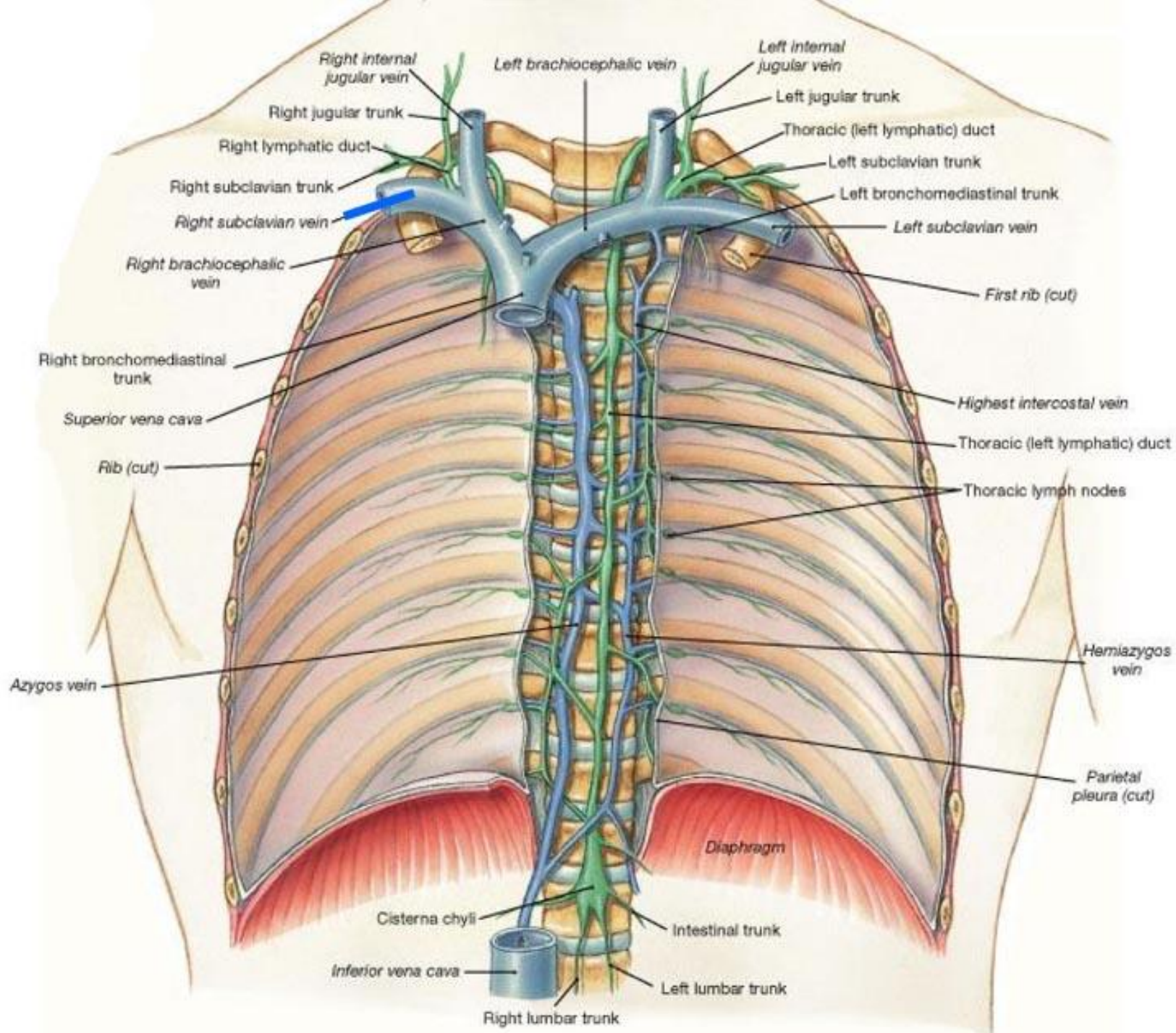


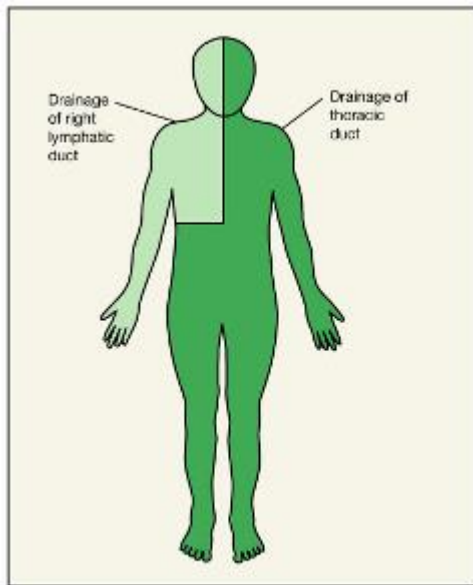
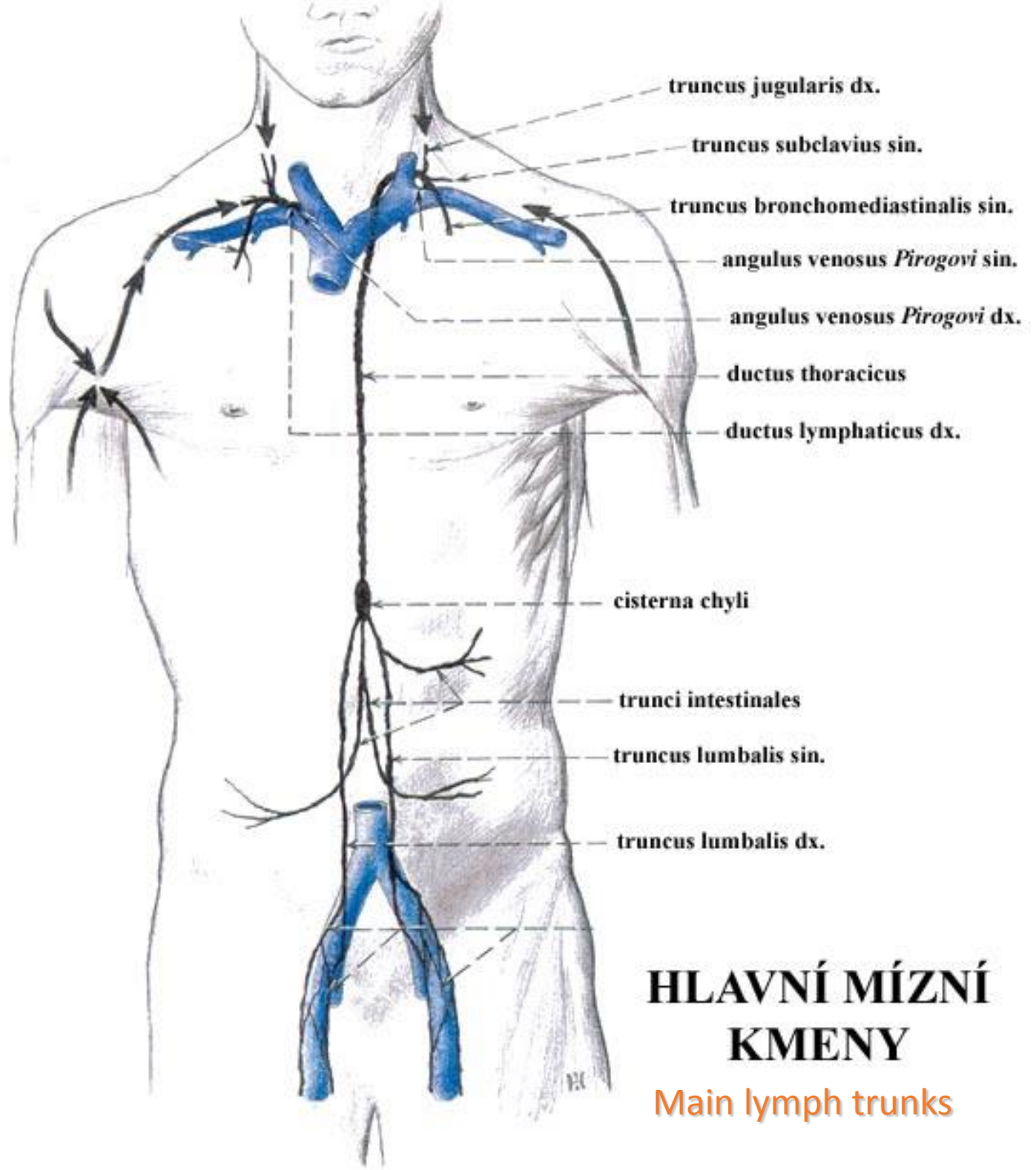
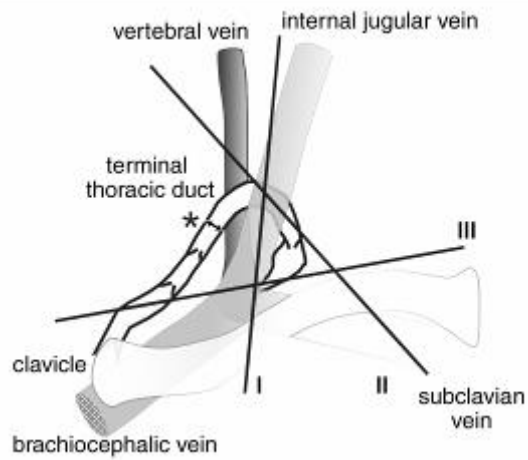
# Lymph vessels general arrangement

- lymph capillaries → lymph vessels
- limbs (collectors): superficial → deep vessels
- organs: plexuses (subcapsular + deep) → lymph trunks → lymph ducts
- lymph nodes put in vessels







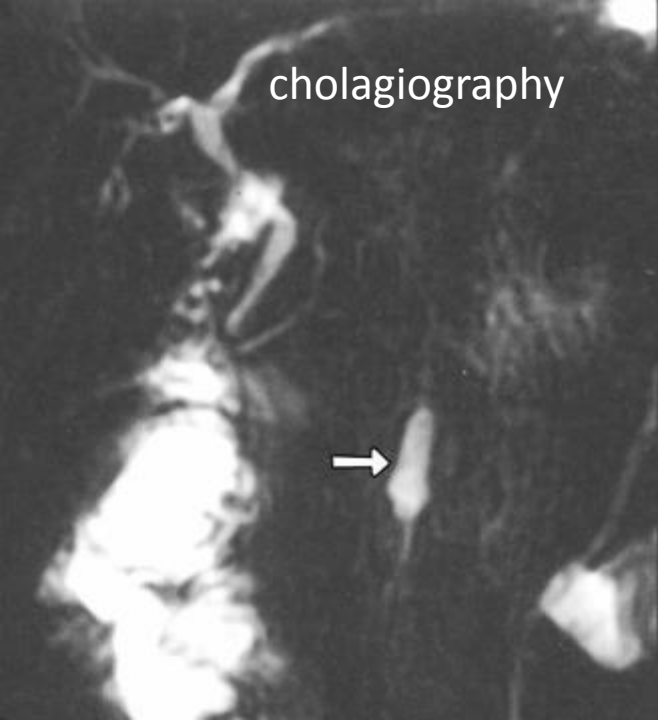


(a)

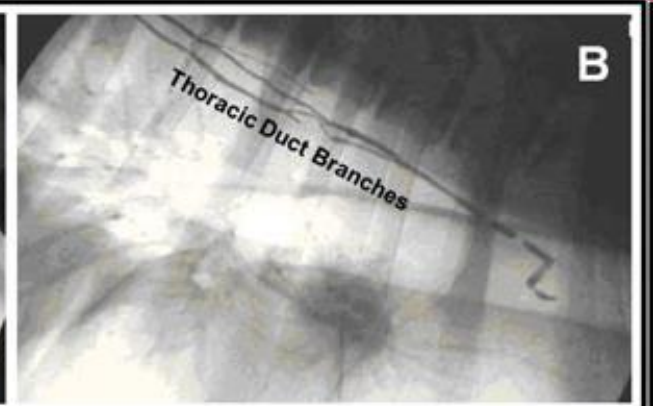
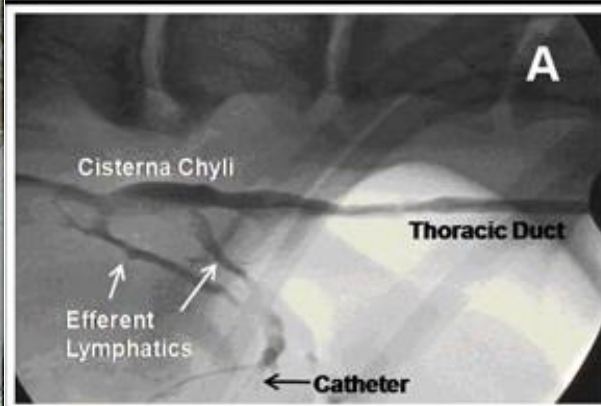
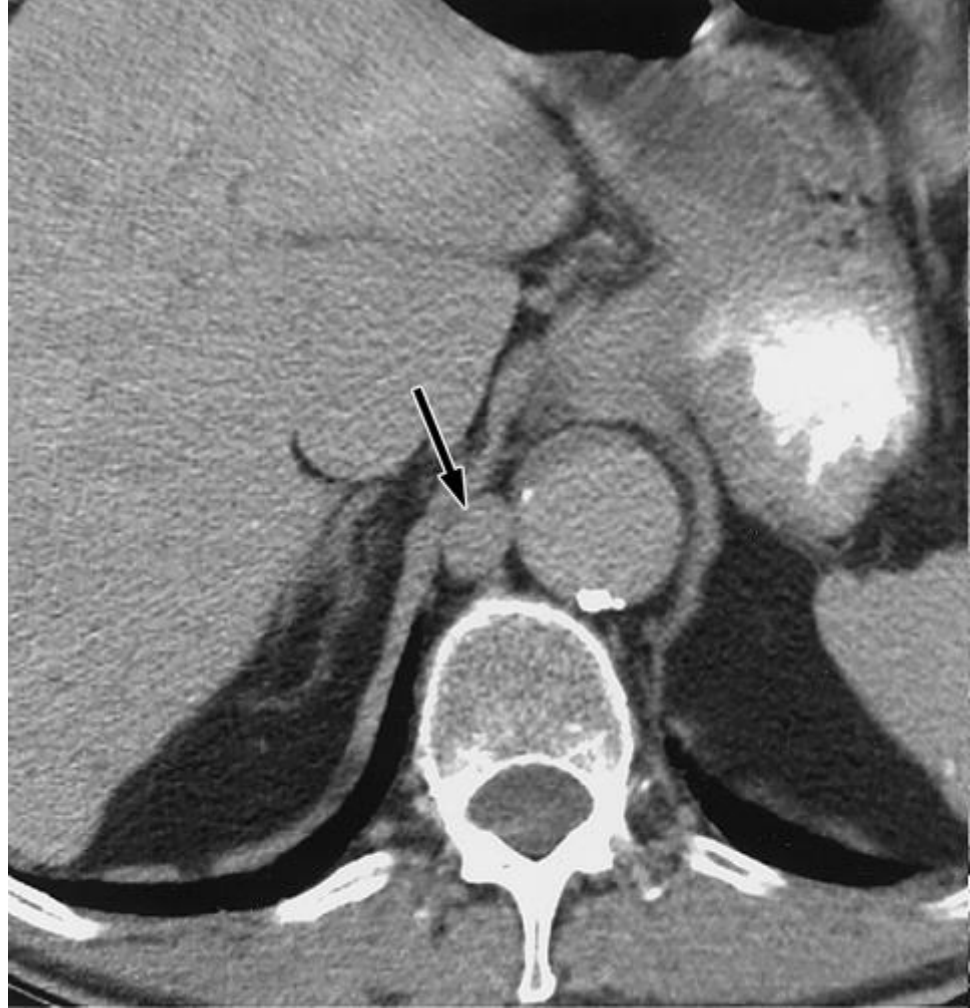# HLAVNÍ MÍZNÍ KMENY

Main lymph trunks



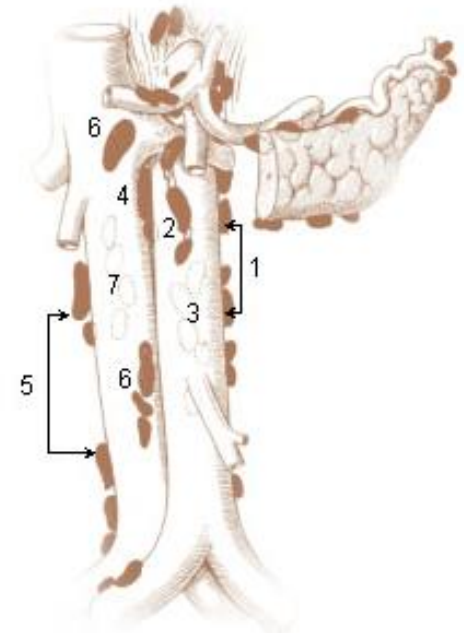
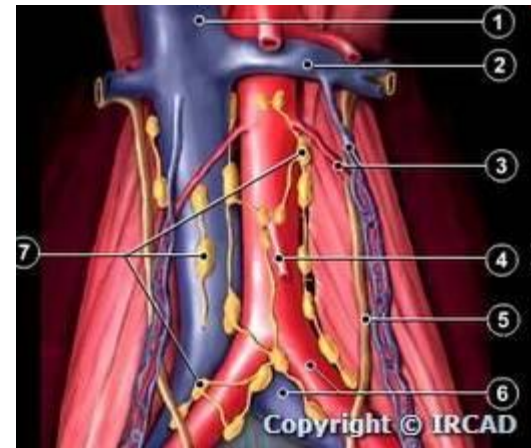
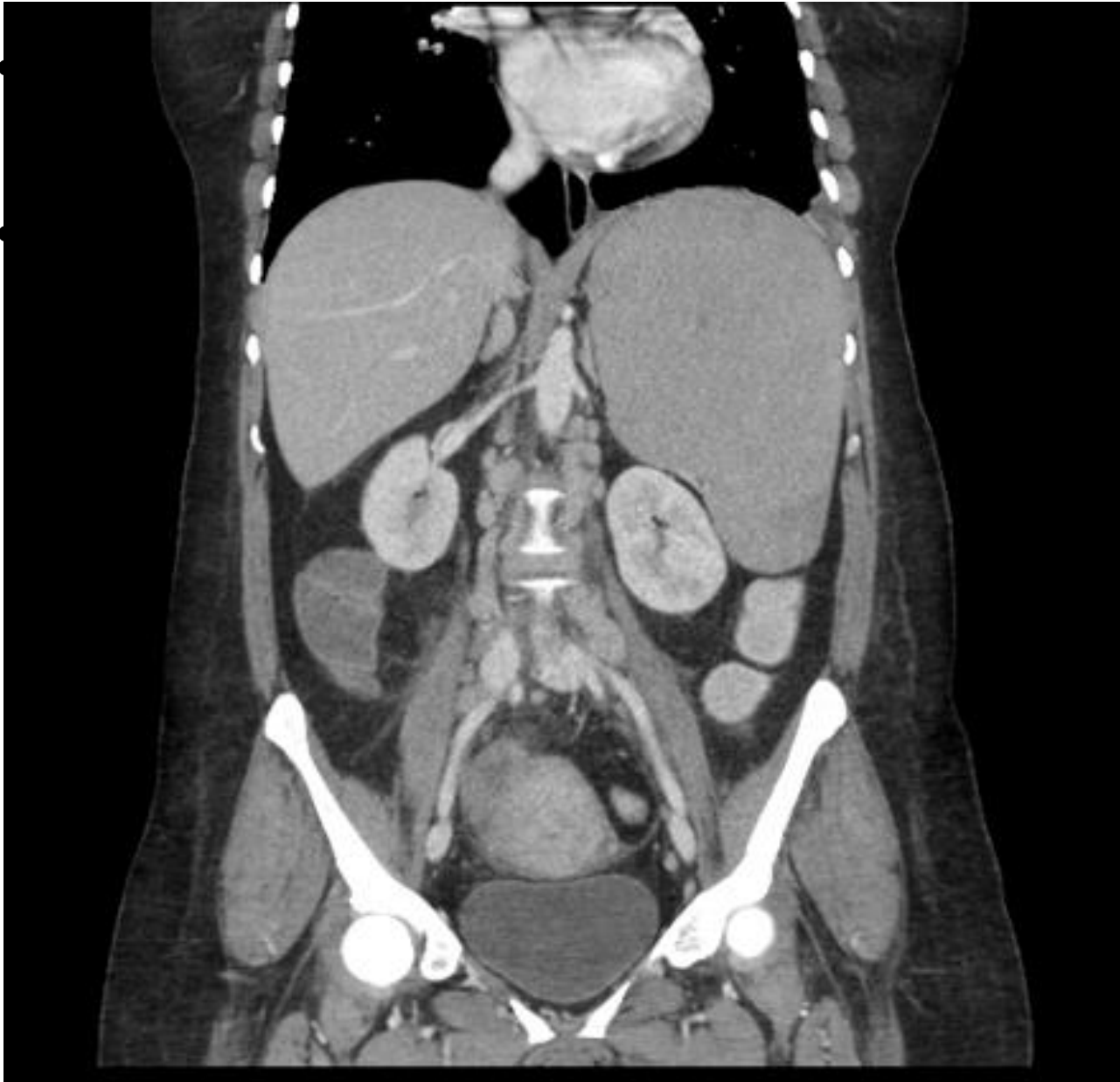


CISTERNA  
CHYLI

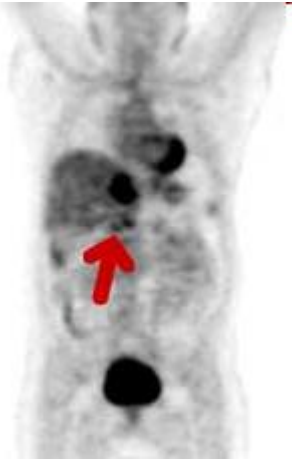
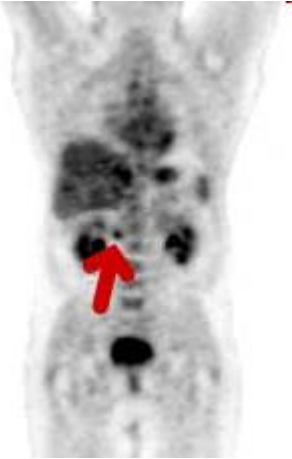


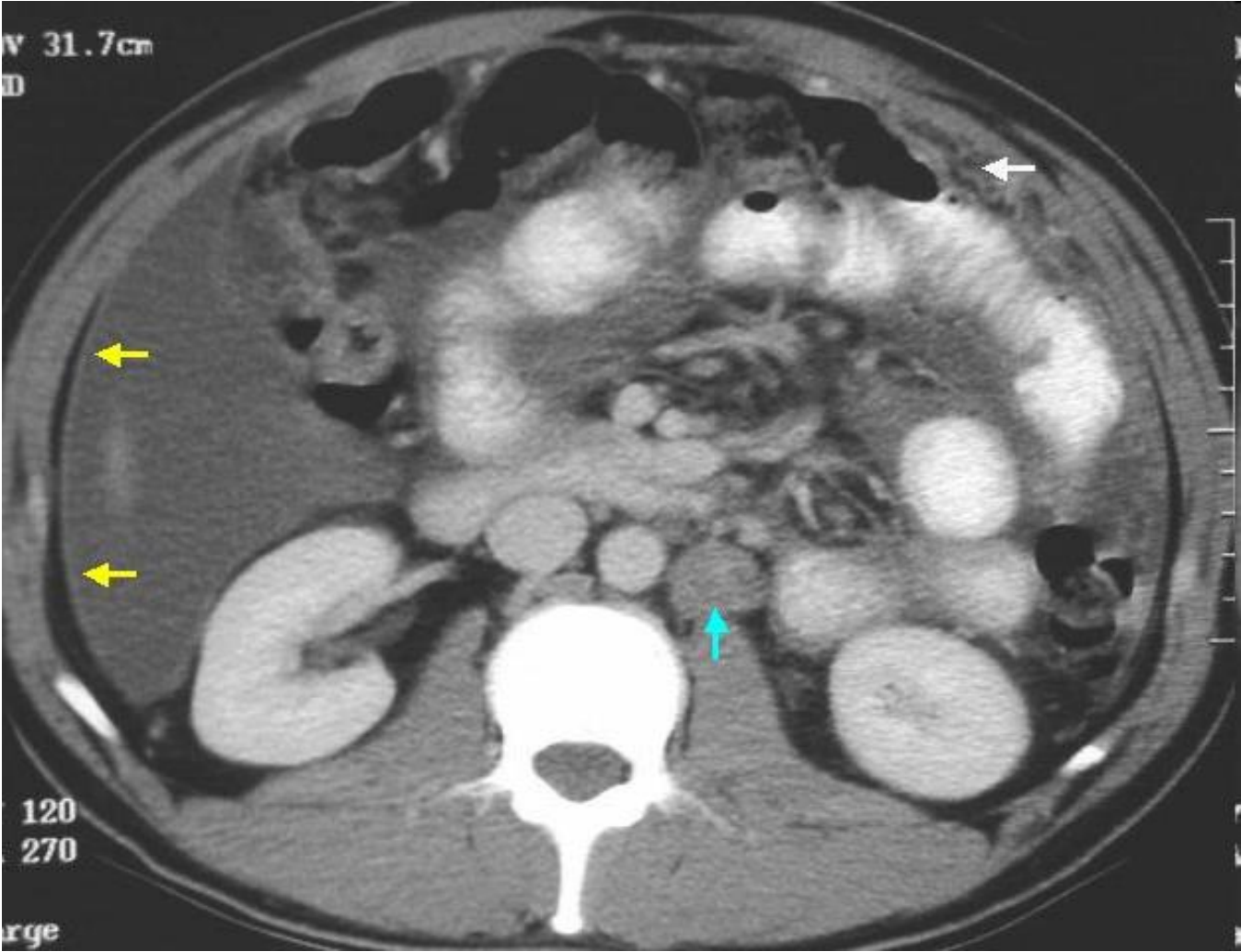
# Abdomen



# Colorectal metastasis



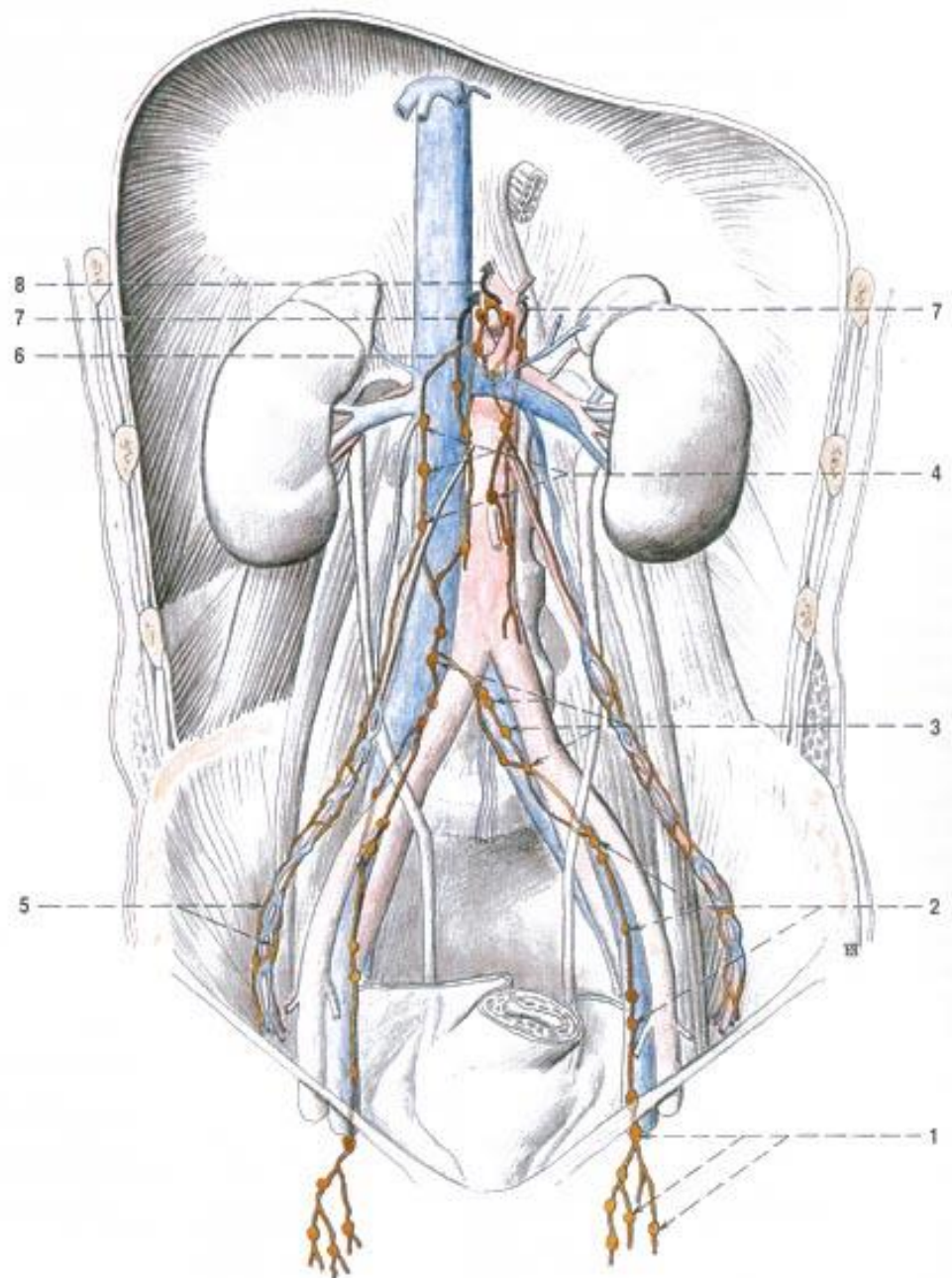
# Tuberculosis



# Testis ♂

# Ovary ♀

- n.l. lumbales
- *L2 – development*
- *scrotum → n.l. inguinales superficiales*
- *! no puncture !*



Obr. 138. NODI ILIACI EXTERNI ET NODI LUMBALES

- 1 nodi inguinales superficiales et profundi
- 2 nodi iliaci externi
- 3 nodi iliaci communes
- 4 nodi lumbales

- 5 mizni kolektory z varle / ovaria, jdoucí podél vasa testicularia / ovarica do nodi lumbales
- 6 nodi coeliaci
- 7 odtok mízy cestou truncus lumbalis do cisterna chyli
- 8 odtok mízy cestou truncus lumbalis do cisterna chyli



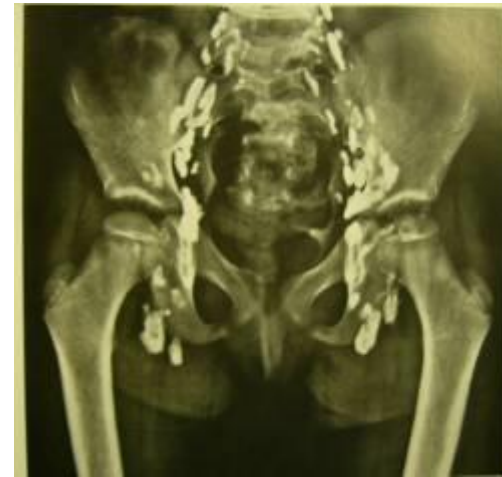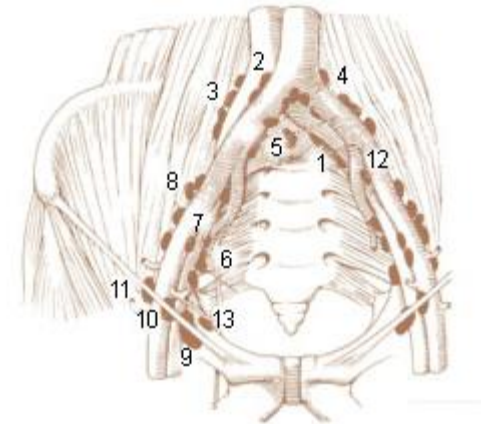
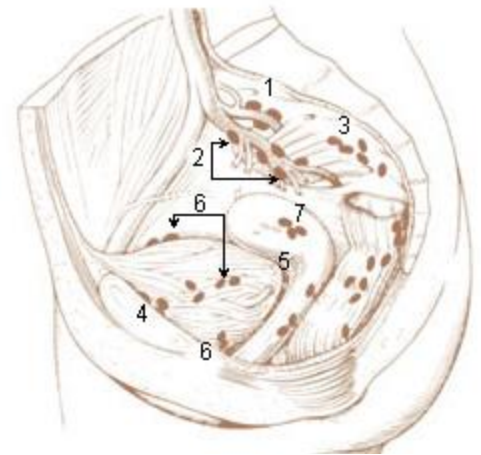
# Pelvis

- n.l. parietales

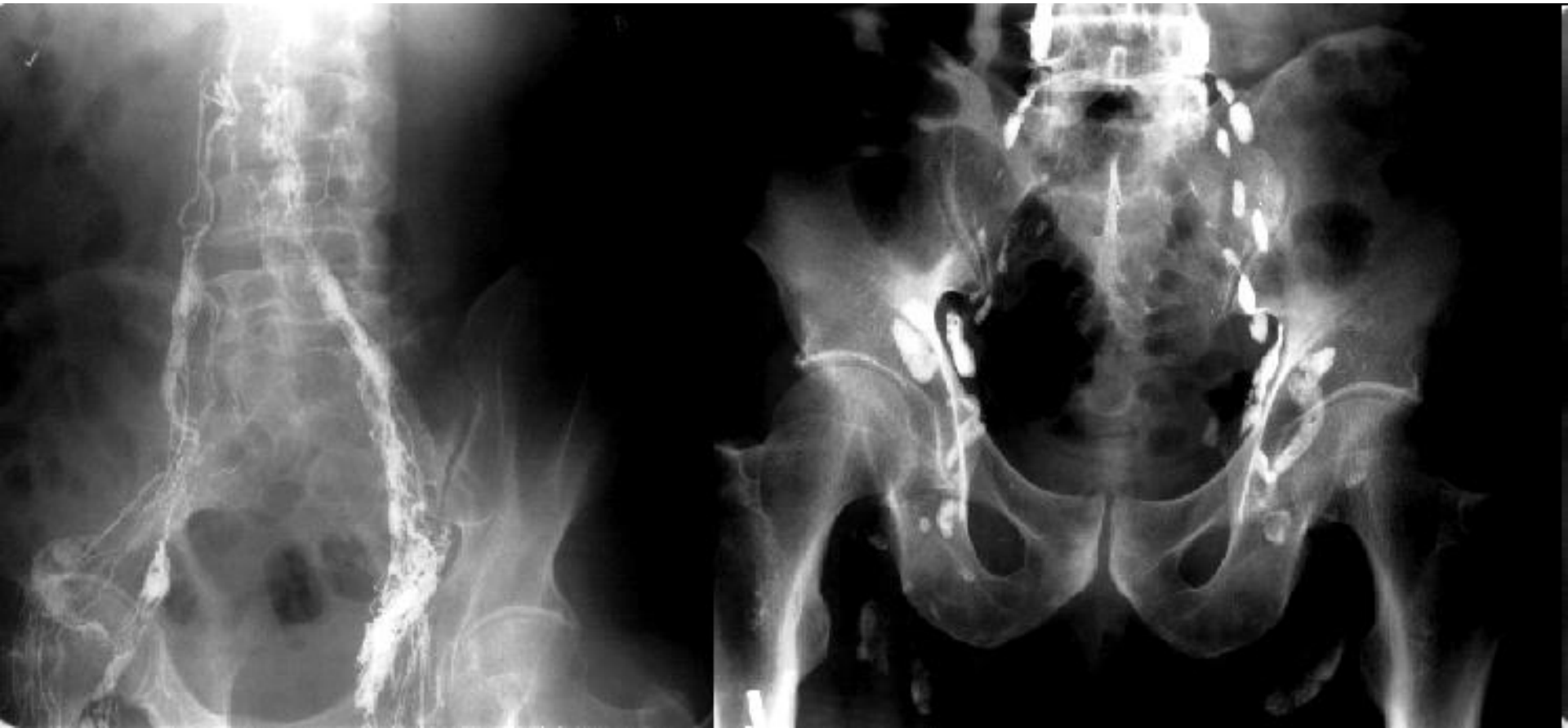- communes
- externi (obturatorii)
- interni
  - gluteales sup.+inf.
  - sacrales (rectum, prostata, cervix uteri, fornix vagi)

- n.l. viscerales

- paravesicales
- parauterini ♀, paravaginales ♀
- pararectales



# Abdomen and pelvis clinical relevance



# Uterus

## anatomical classification:

- n.l. lumbales ← fundus + corpus
- n.l. iliaci interni (iliaci externi, iliaci communes, obturatorii) ← corpus, isthmus + cervix
- n.l. sacrales ← isthmus, cervix
- n.l. inguinales superficiales ← margines + cornua (*exceptionally!*)

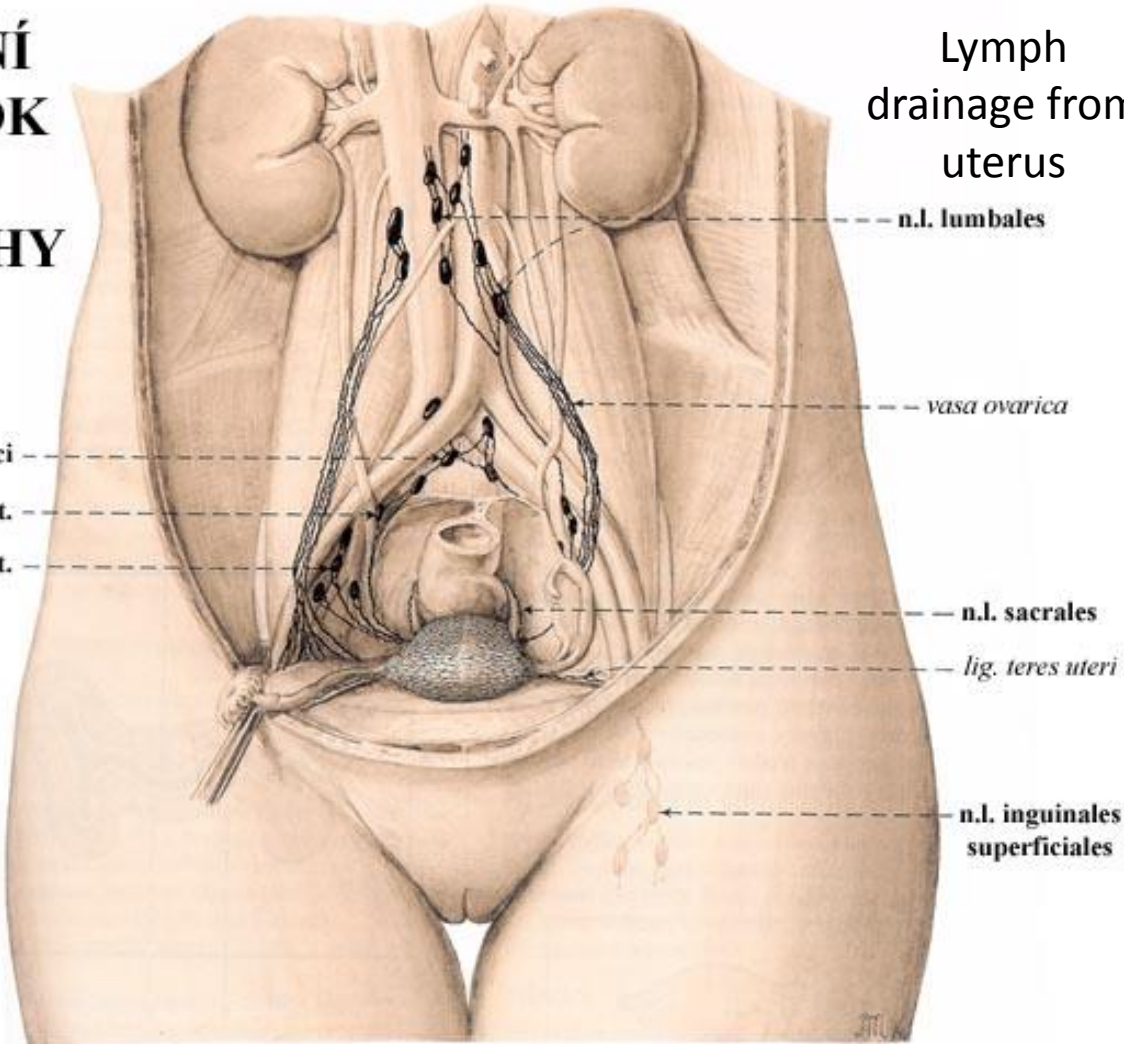
## clinical classification: according to corpus and cervix cancer

- corpus uteri → n.l. iliaci int.+ lumbales + (inguinales superficiales)
- cervix uteri → n.l. iliaci int.+ sacrales

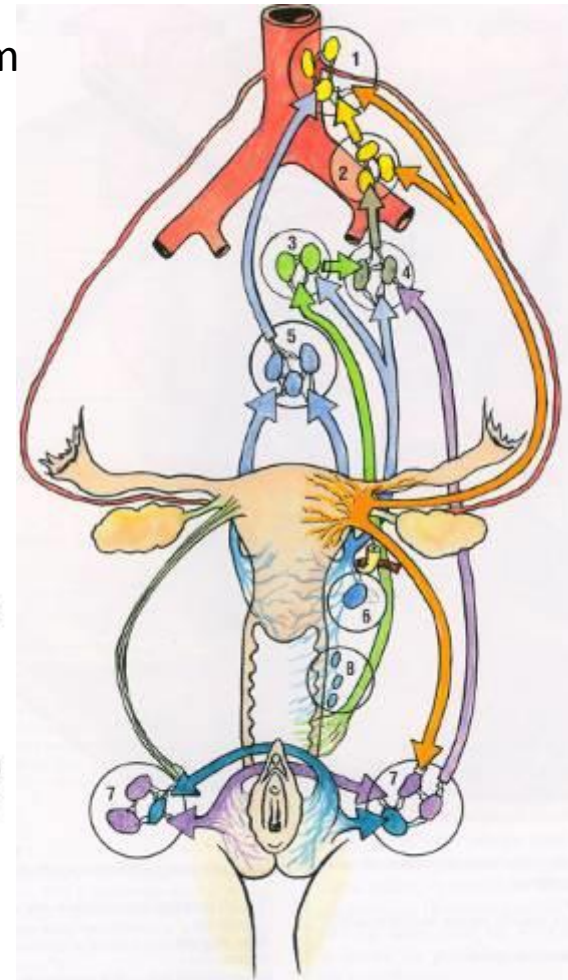


# Uterus

## MÍZNÍ ODTOK Z DĚLOHY

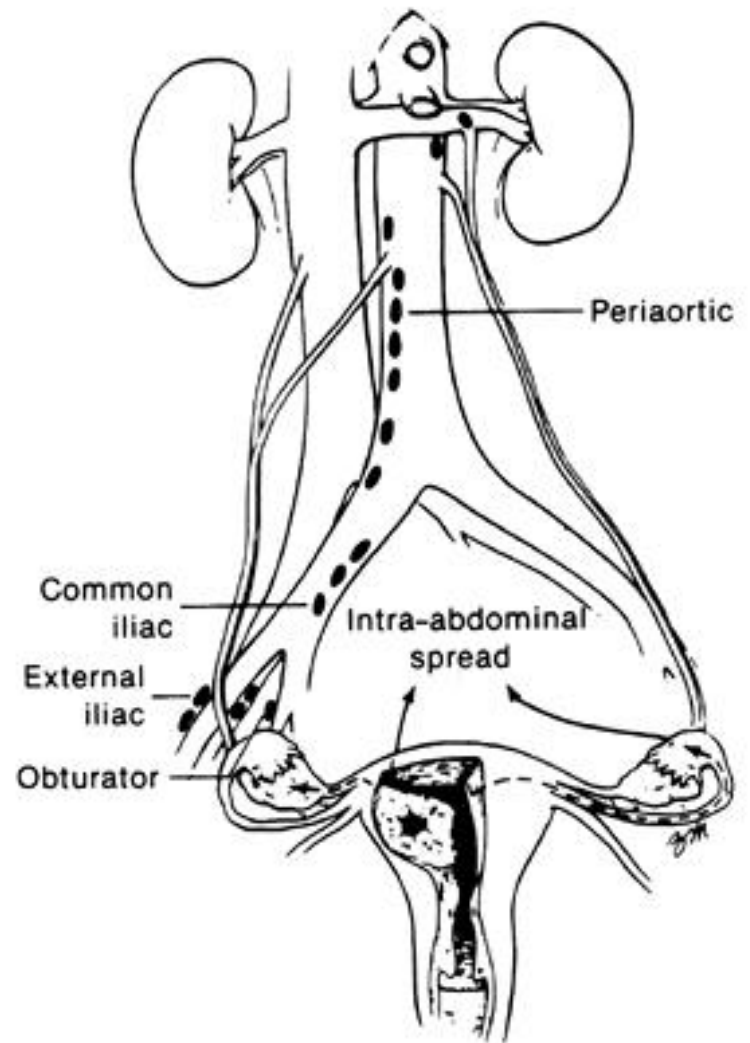
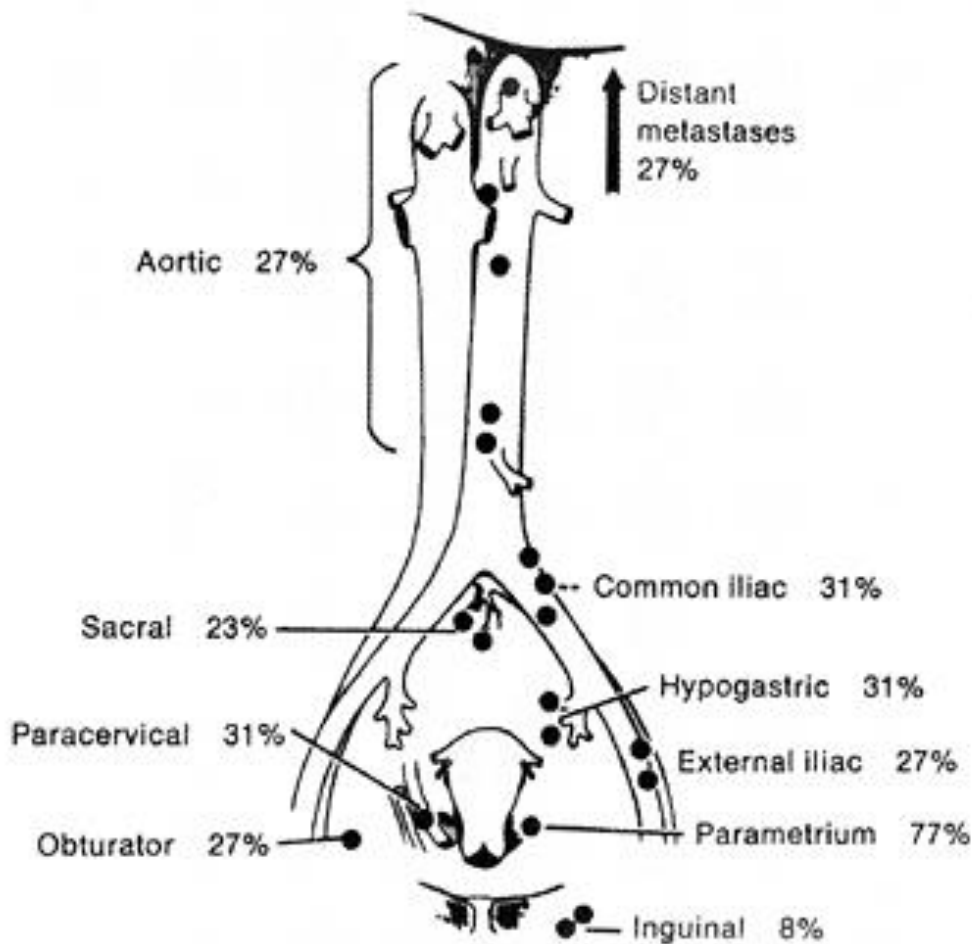


Lymph  
drainage from  
uterus



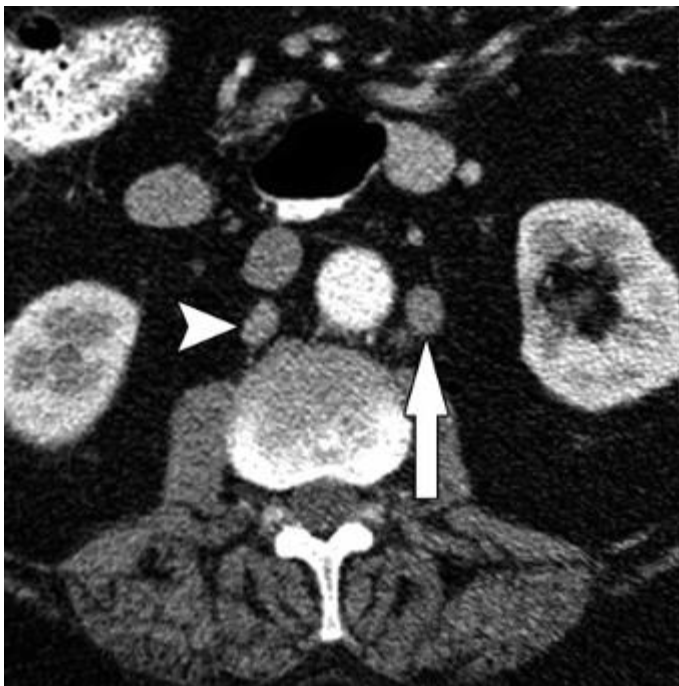# Cervix cancer

## – lymph nodes involvement

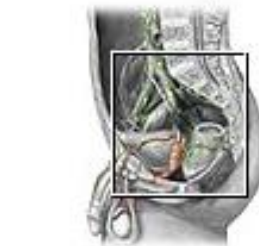

# Prostate

- n.l. iliaci int. + ext.
- n.l. sacrales



Lymph vessels and nodes of pelvis

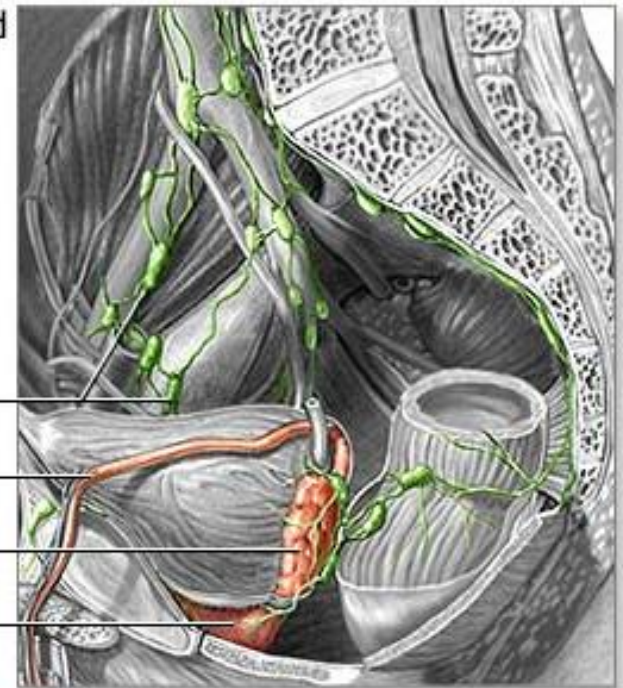


Lymph nodes

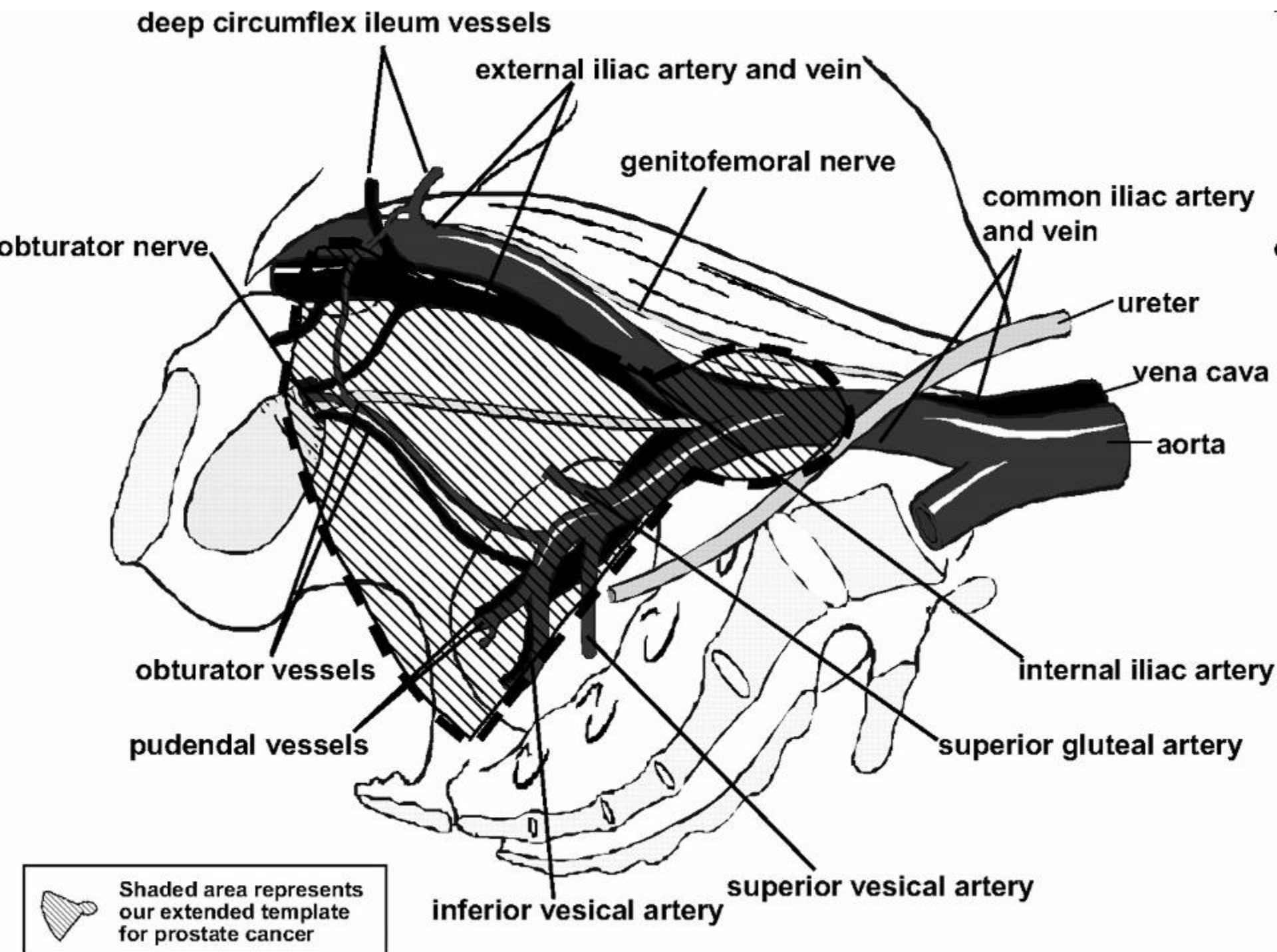
Vas deferens

Seminal vesicle

Prostate gland







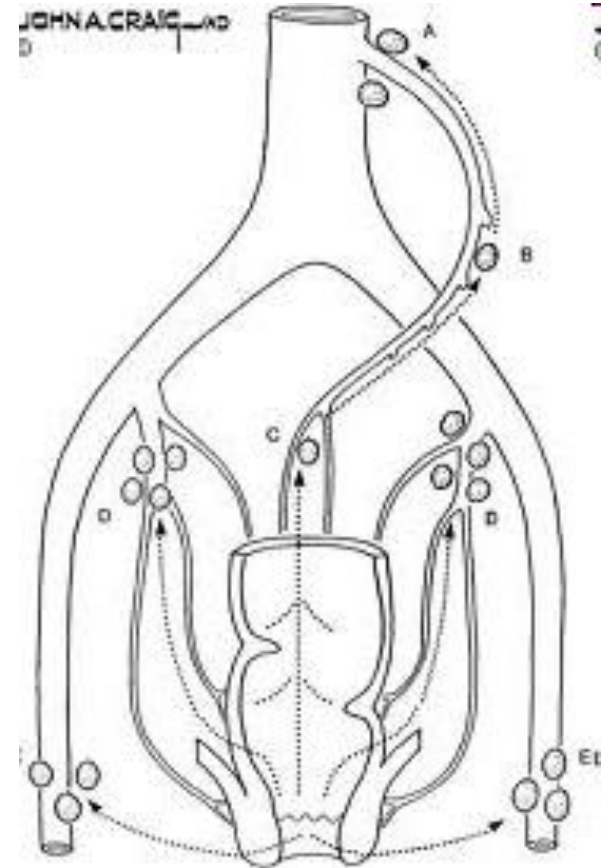
# Rectum + anal canal

- ampulla

- oral part: → n.l. rectales sup. → n.l. mesenterici inf.
- aboral part: → n.l. pararectales → n.l. iliaci interni
- *n.l. obturatorii, sacrales*

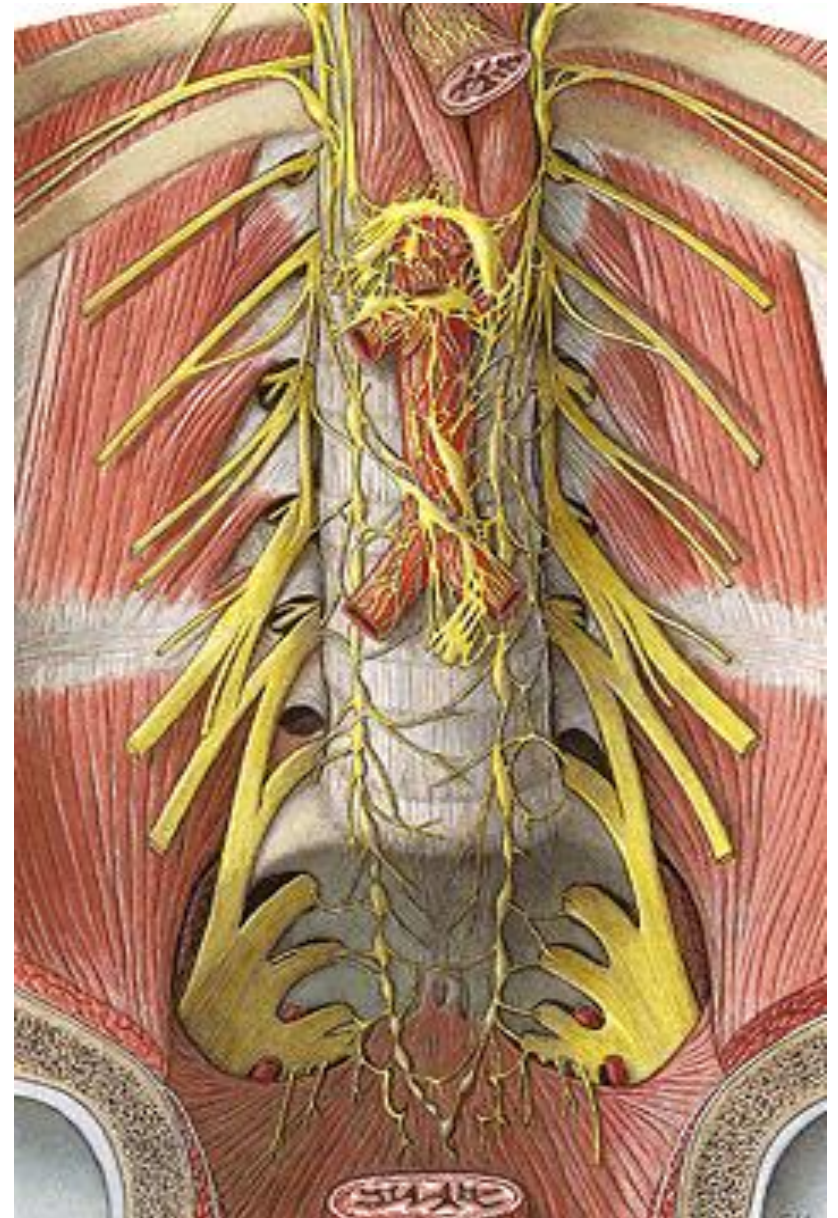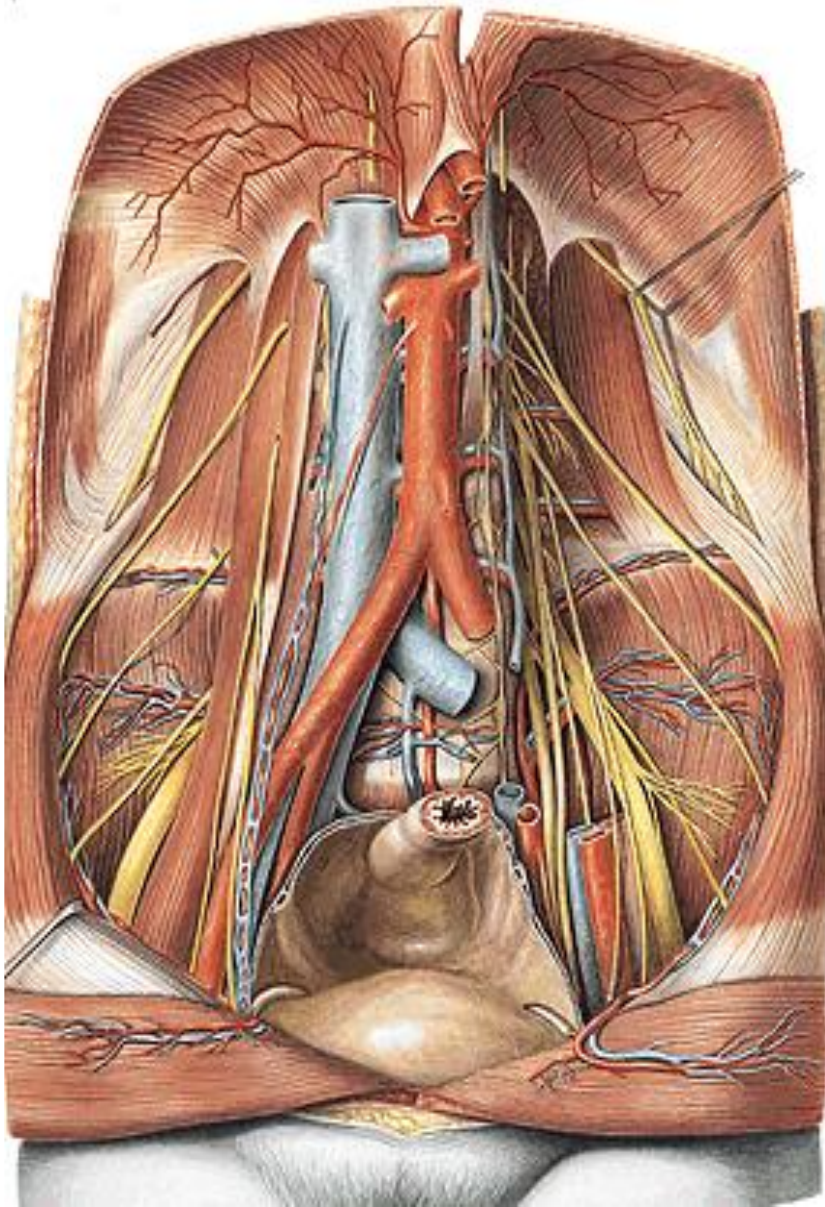
- canalis analis

→ n.l. pararectales + n.l. inguinales superficiales

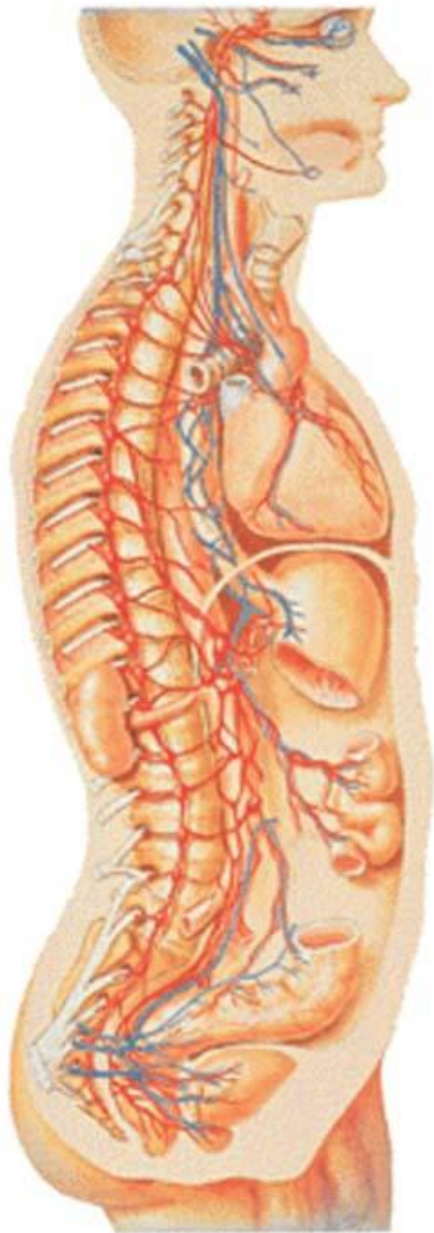




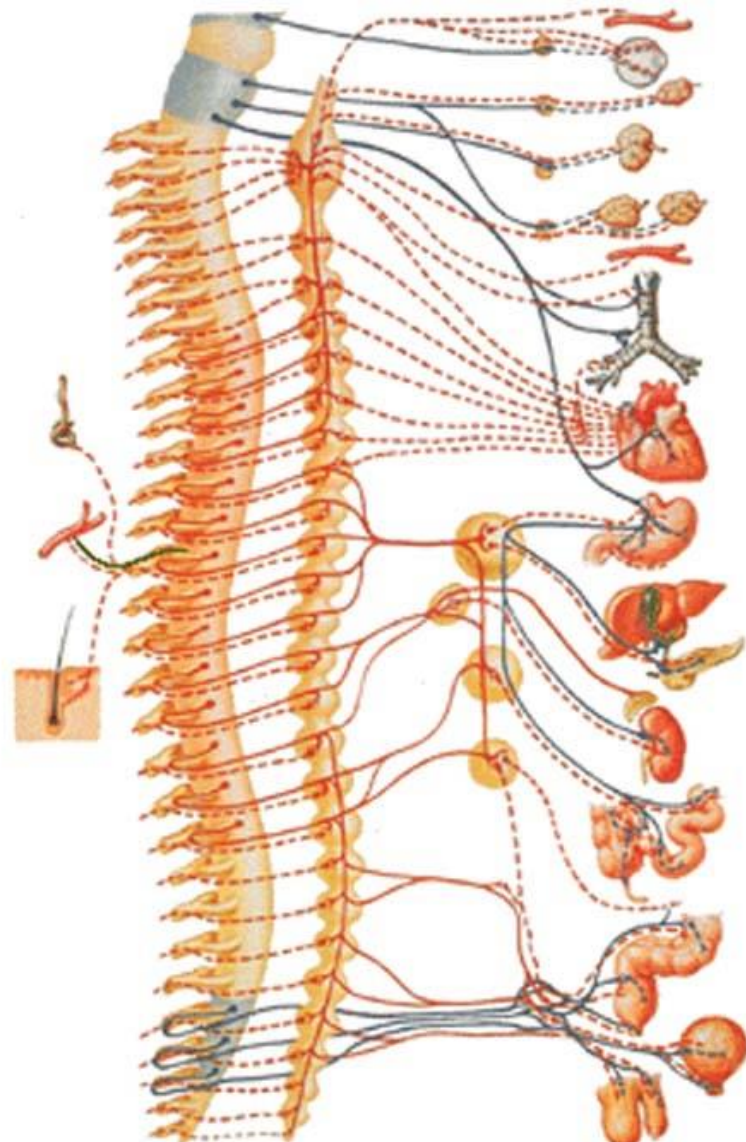
# Nerves of retroperitoneum





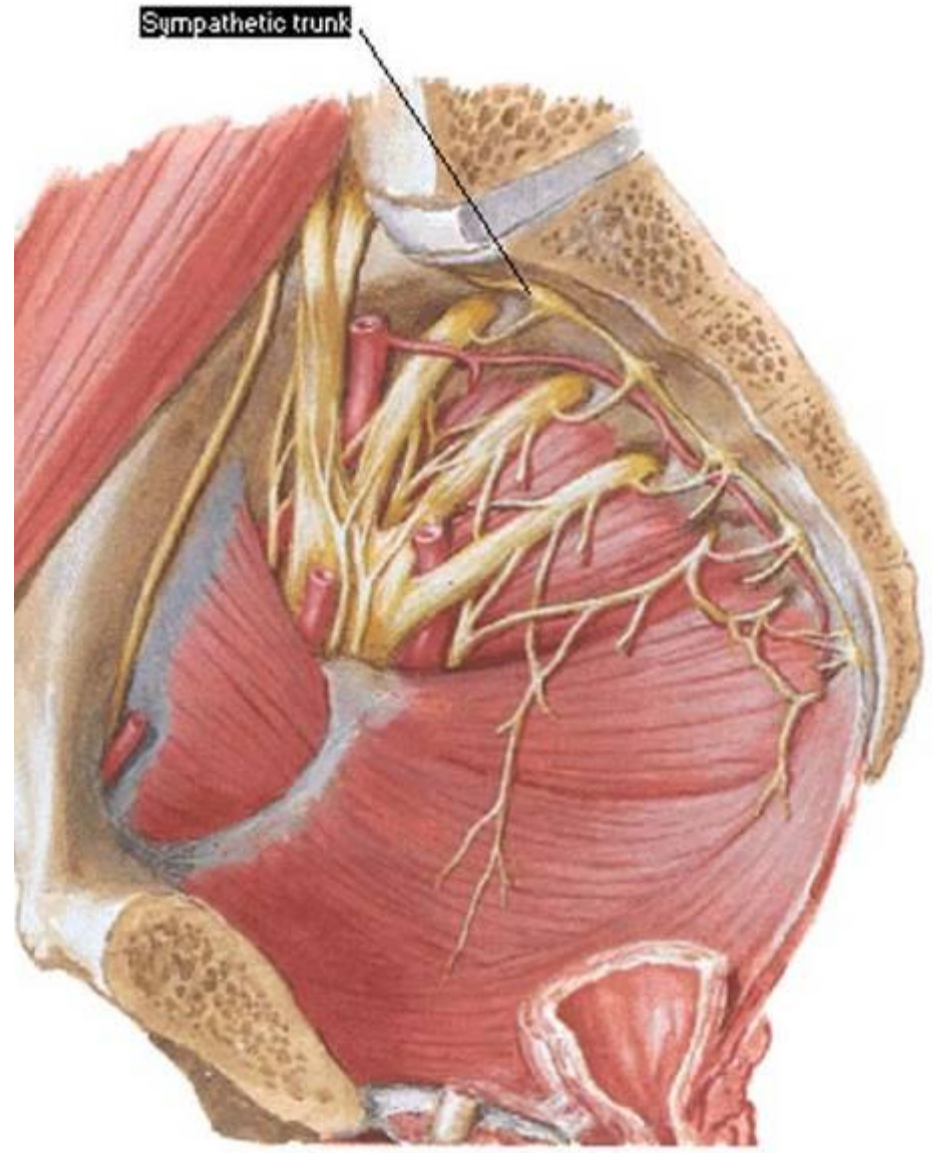
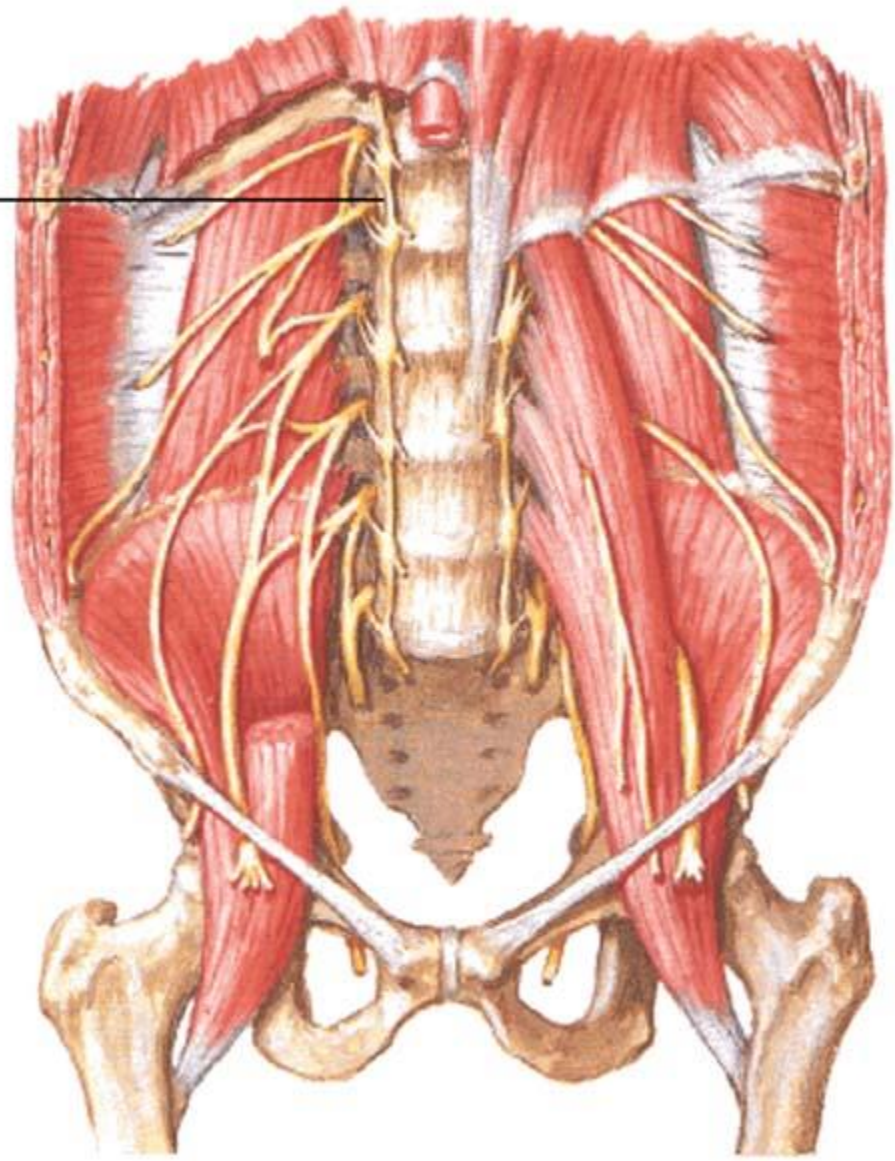


— Sympathetic fibers  
— Parasympathetic fibers



Sympathetic fibers    Presynaptic —  
                                  Postsynaptic - - -  
 Parasympathetic fibers    Presynaptic —  
                                  Postsynaptic - - -  
 Antidromic conduction —

# Sympathetic trunk





# Plexus aorticus abdominalis

**sympathetic fibers:** nn. splanchnici thoracici (major, minor, imus), lumbales 1-3

**parasympathetic fibers:** rr. coeliaci nn. vagorum

**mixed plexus** around aorta abdominalis + prevertebral ganglia

- paired **ggl. coelicum** + **ggl. aorticorenale**

- unpaired **ggl. mesentericum sup. + inf.**

→ along arteries → homonymous plexuses

- stomach → oral majority of rectum (**enteric system**), pancreas, liver

- spleen, suprarenal glands, kidneys, ureters, testes♂ / ovaries♀, uterine tubes (1/2) ♀

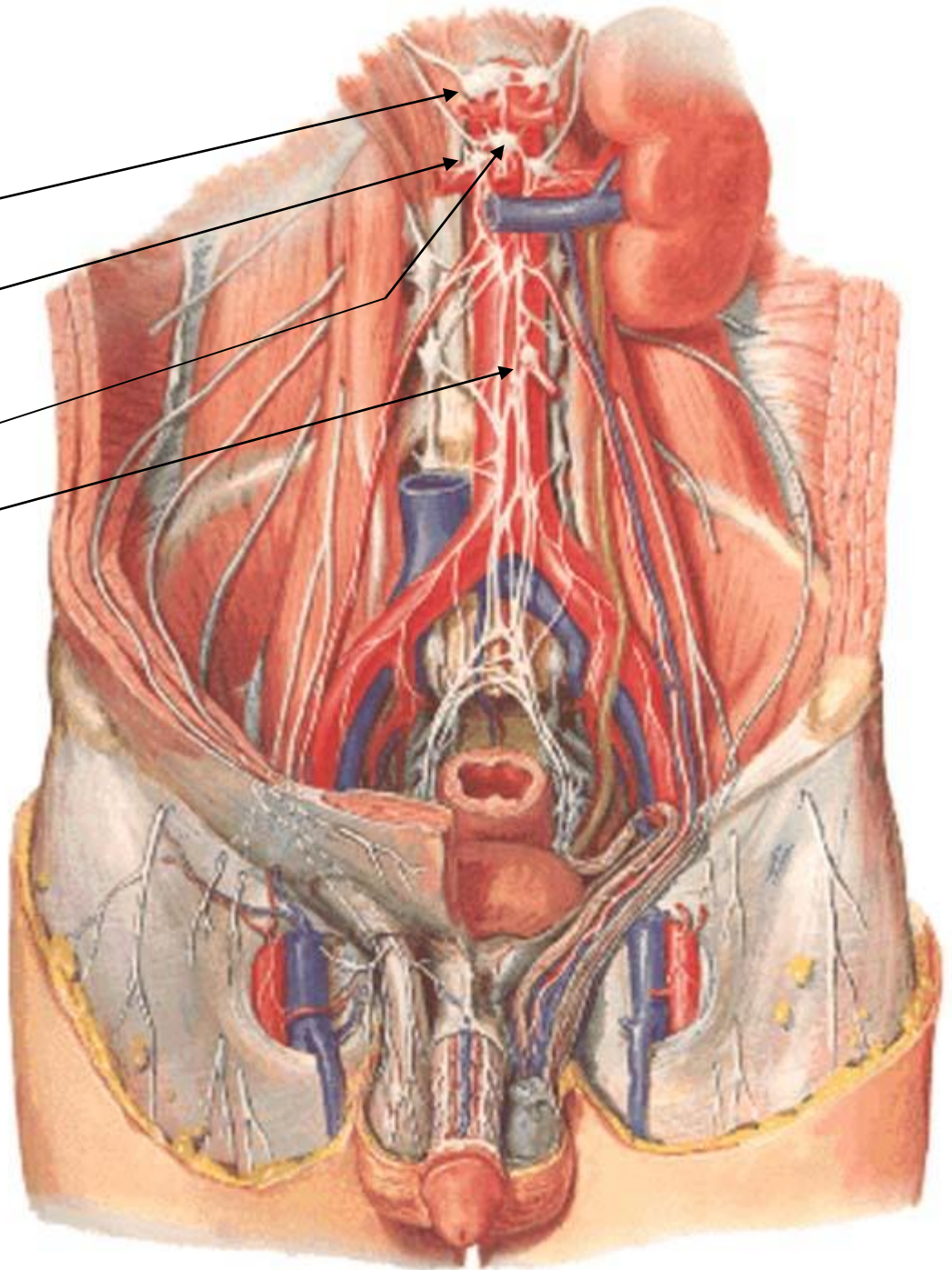


ggl. coelicum

ggl. aorticorenale

ggl. mesentericum sup.

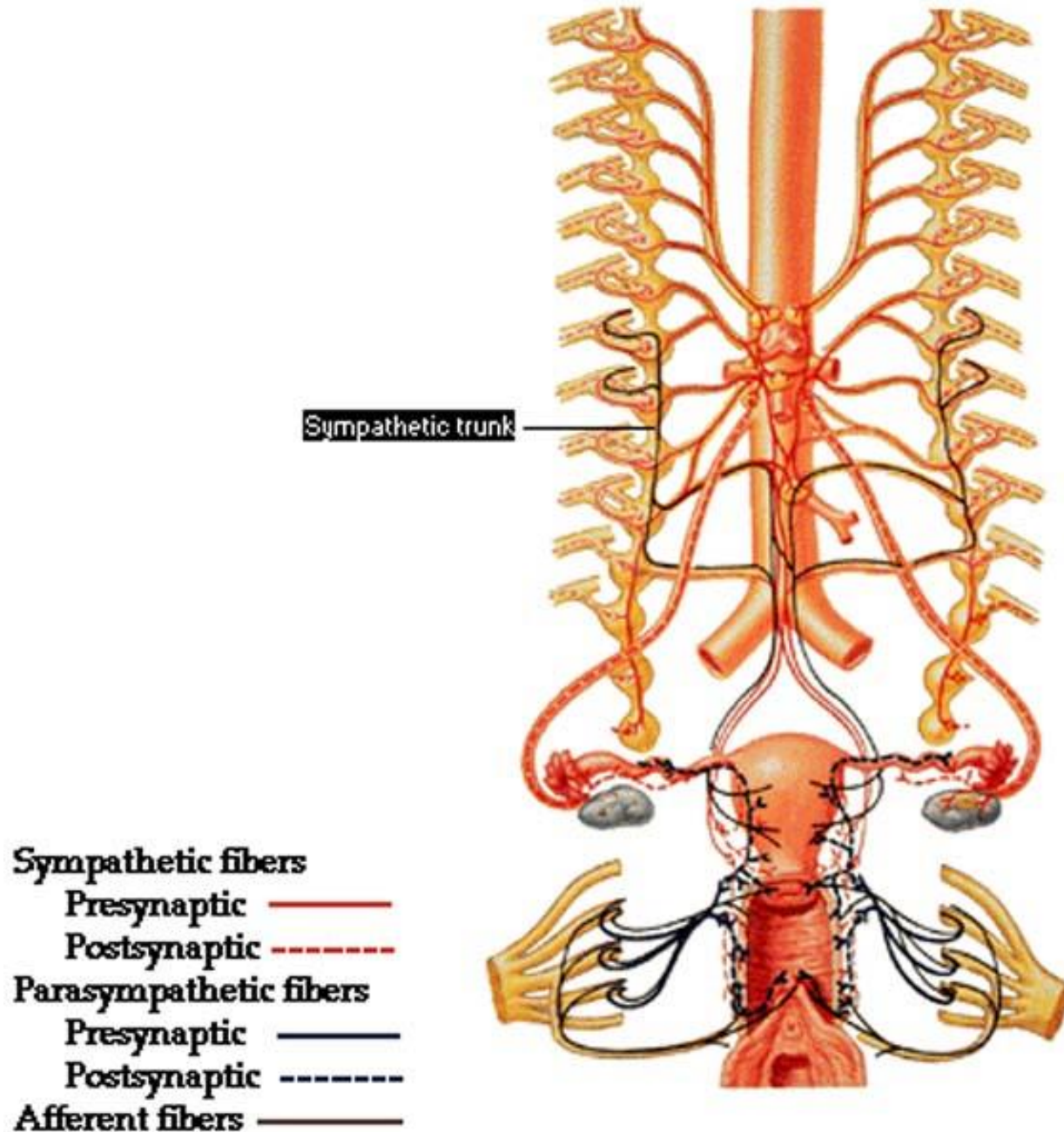
ggl. mesentericum inf.



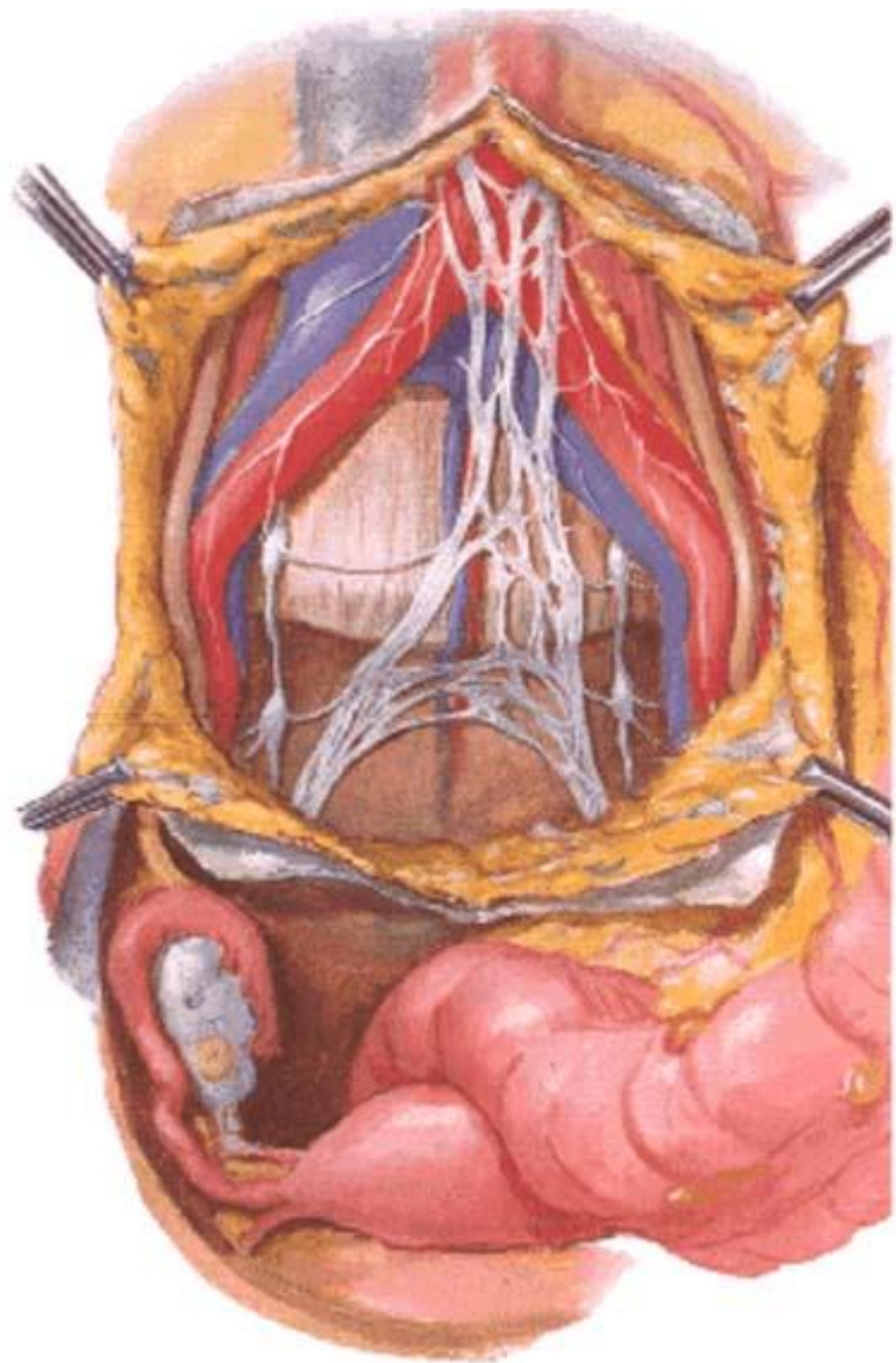
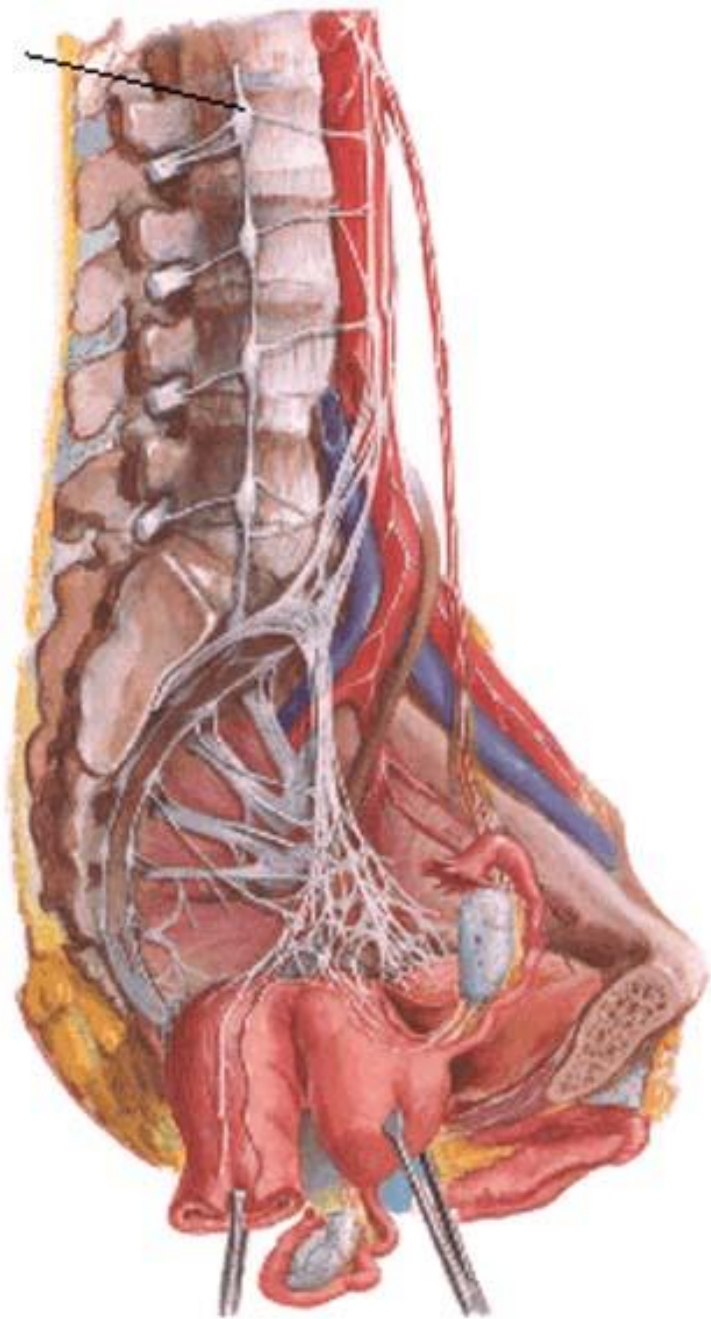
# Plexus aorticus abdominalis continuation

- **plexus hypogastricus superior** (pure sympathetic (from bifurcatio across promontorium))
  - n. hypogastricus dx. + sin. → **plexus hypogastricus inferior** s. pelvicus (mixed plexus) → pelvic organs except ovaries ♀, uterine tubes (1/2) ♀, fundus uteri ♀ and urinary bladder
- **plexus iliacus** dx. + sin. (pure sympathetic) → lower limb

# Innervation of Female Reproductive Organs







# Plexus hypogastricus inferior s. pelvicus

mixed plexus

AF-PS: nn. splanchnici pelvici S2-4 (*obsoletely nn. erigentes*)

AF-S: truncus sympathicus → plexus aorticus abdominalis → plexus hypogastricus superior → nn. hypogastrici

AF-S: truncus sympathicus → ganglia sacralia → nn. splanchnici sacrales

- pelvic organs except ovaries♀, uterine tubes (1/2)♀, fundus of uterus♀ and fundus of urinary bladder

EF (mixed): → plexus rectalis (aboral minority of rectum)

→ parasympathetic fibers ascend as orally as *Cannon-Böhm's point* = hindgut

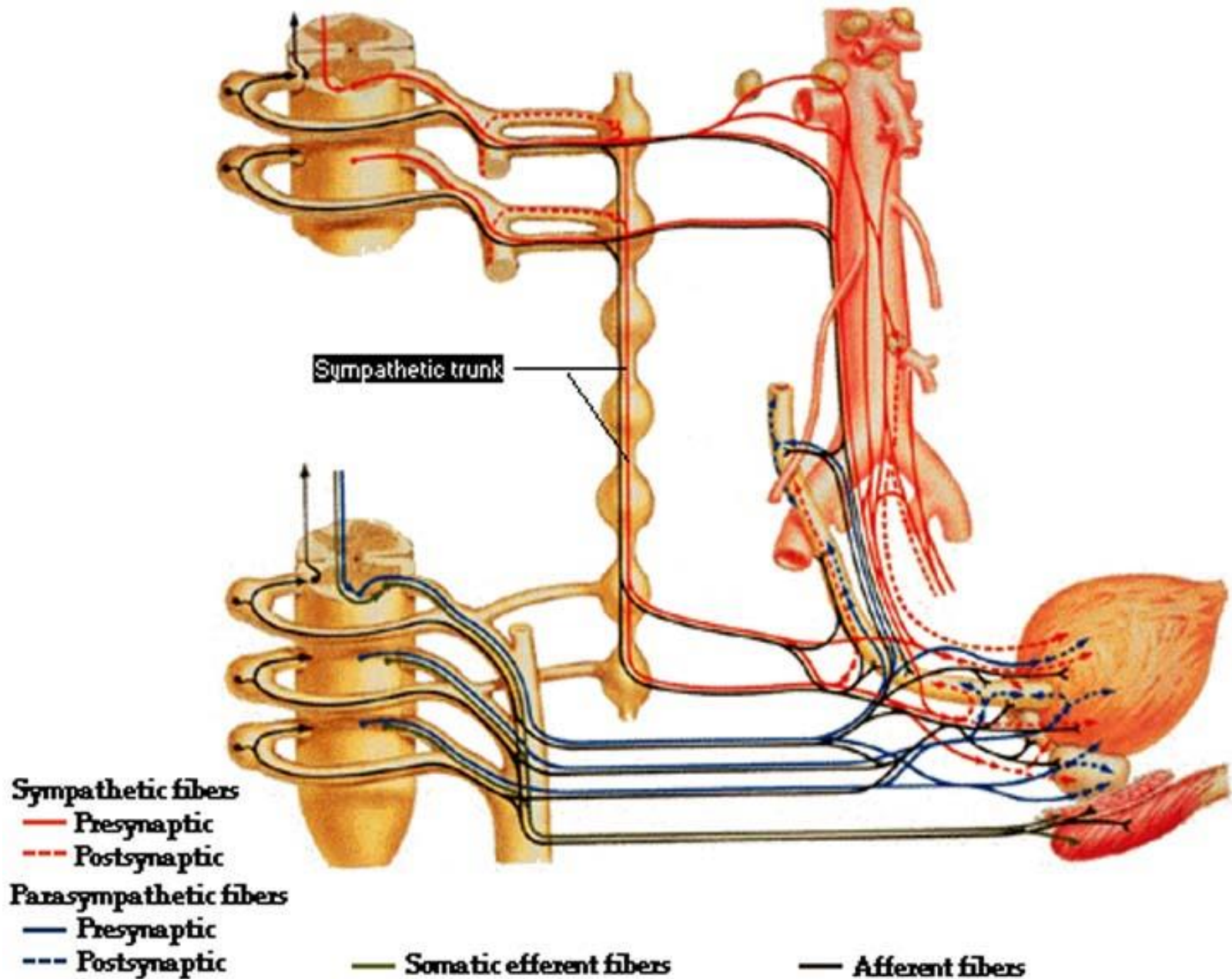
→ plexus prostaticus + deferentialis♂ / uterovaginalis♀

→ plexus vesicalis

- m. sphincter urethrae (nucleus n. pudendi *Onufi* in spinal cord segments S2-4)

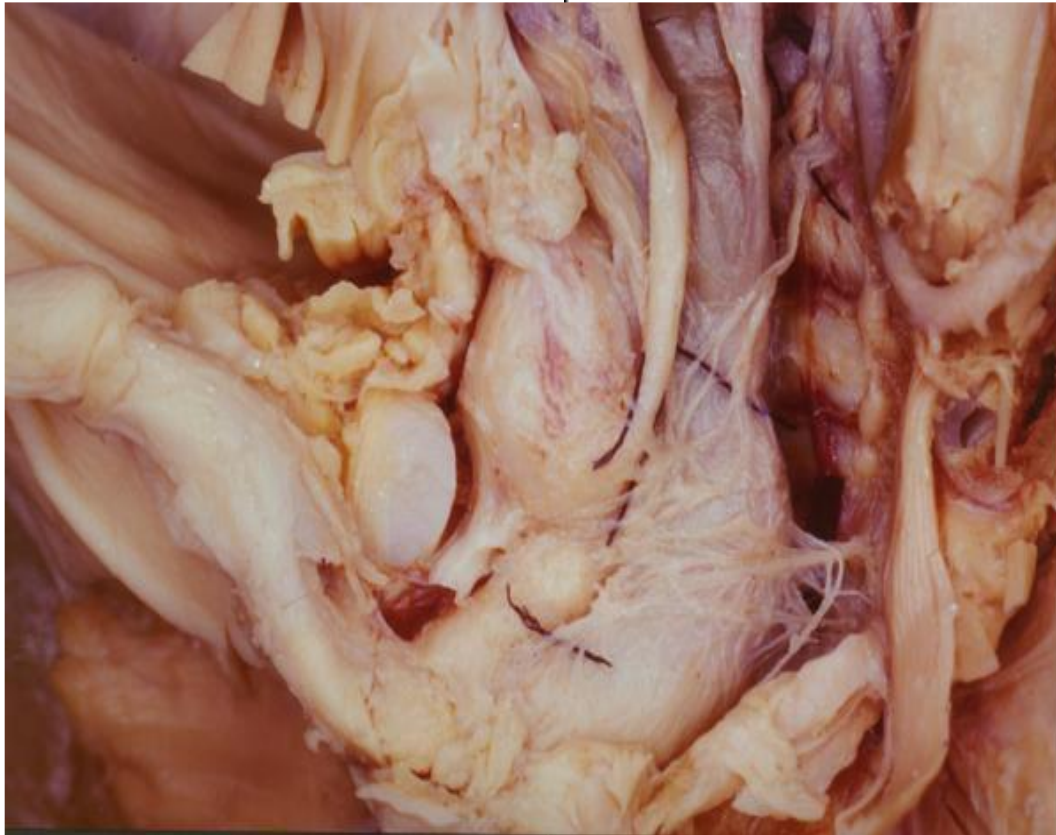→ n. cavernosus penis ♂ / clitoridis ♀ (erectile bodies)

# Innervation of Urinary Bladder

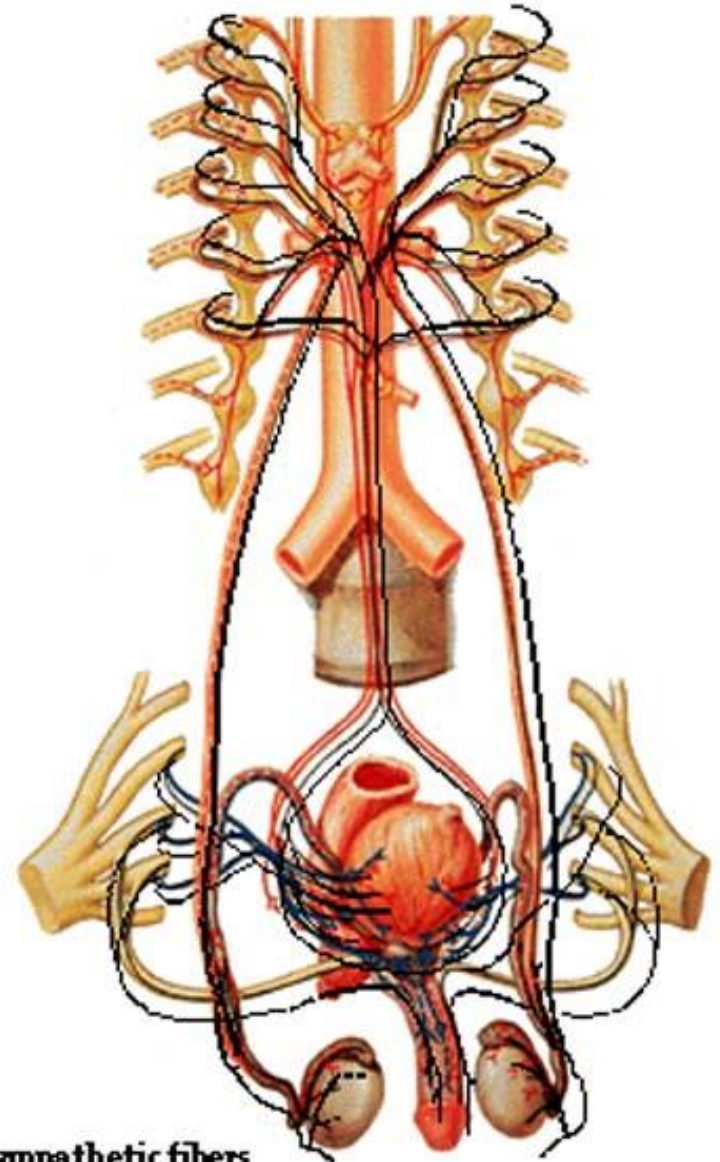




# Innervation of Male Reproductive Organs



Plexus hypogastricus inferior s. pelvicus



**Sympathetic fibers**  
— Presynaptic  
- - - Postsynaptic

**Parasympathetic fibers**  
— Presynaptic  
- - - Postsynaptic

— Afferent fibers