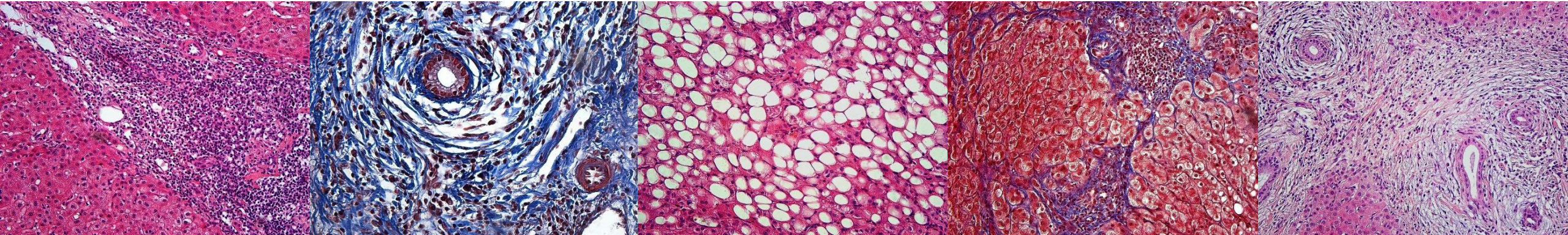


MAKROSKOPICKÁ A MIKROSKOPICKÁ STAVBA JATER



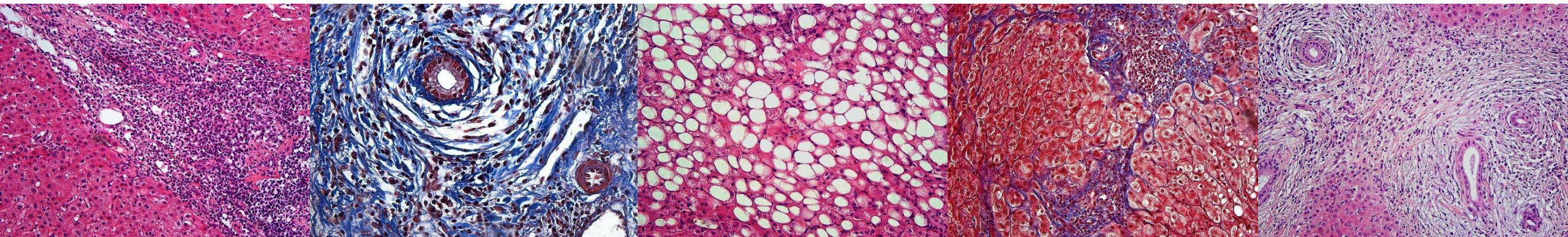
Přednáška v rámci předmětu AHE

12. 1. 2023

MUDr. Anna Malečková, Ph.D.

anna.maleckova@lfp.cuni.cz

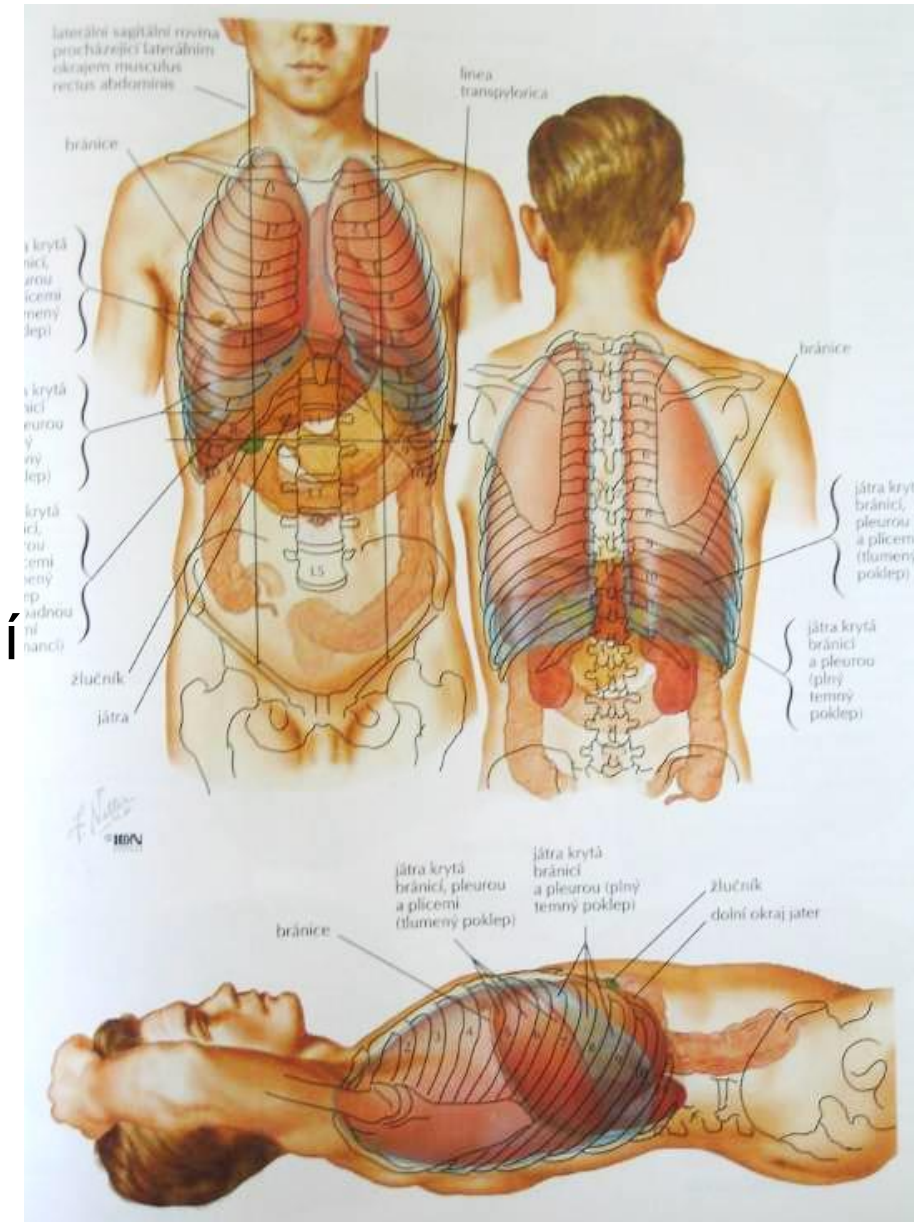
CO SE DNES DOZVÍME?



- Anatomická stavba jater
- Mikroskopická stavba jater
- Žlučové cesty
- Anatomická a mikroskopická stavba žlučníku

JÁTRA - ZÁKLADNÍ INFORMACE

- Největší žláza těla – 3 % tělesné hmotnosti
 - Dospělý muž 1500–1800 g
 - Dospělá žena 1200– 500 g
- Intraperitoneální orgán
 - Pravý a částečně levý horní kvadrant břišní dutiny pod brániční klenbou (regio hypochondriaca dextra)
- Spotřeba 12 % kyslíku z krve, ohřev krve

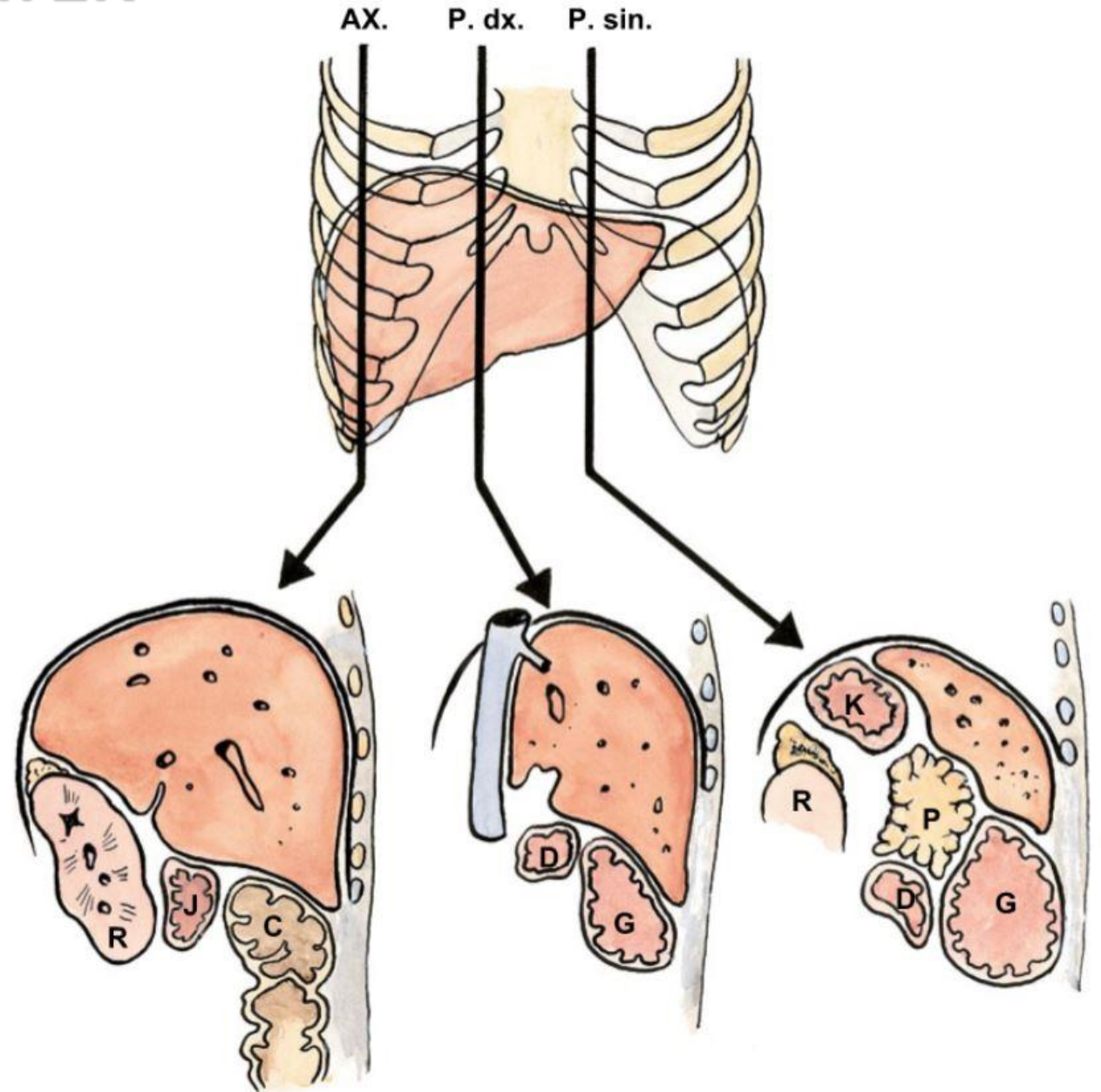


ANATOMICKÁ STAVBA JATER

Syntopie

- *Impressio gastrica*
- *Impressio renalis et suprarenalis*
- *Impressio duodenalis*
- *Impressio colica*
- *Impressio oesophagea*

- *Impressio cardiaca*



ANATOMICKÁ STAVBA JATER

Vnější členění jater

Plochy – vpředu dole rozděljuje *margo inferior*

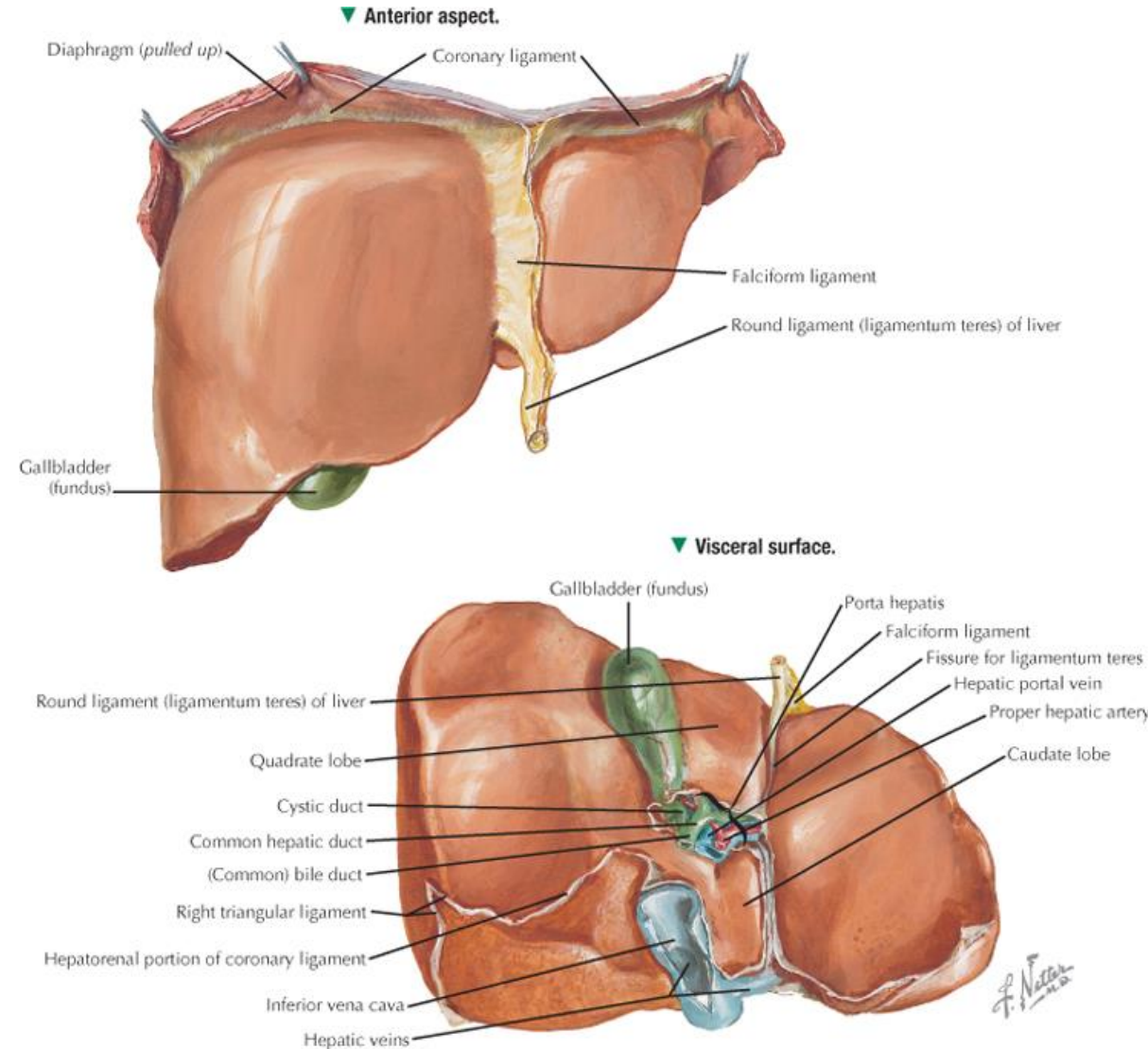
- ***Facies diaphragmatica***
 - area nuda
- ***Facies visceralis***
 - otisky orgánů

Rýhy

- ***Fissura sagitalis sin.***
- ***Fissura sagitalis dx.***
- ***Porta hepatis***

Laloky

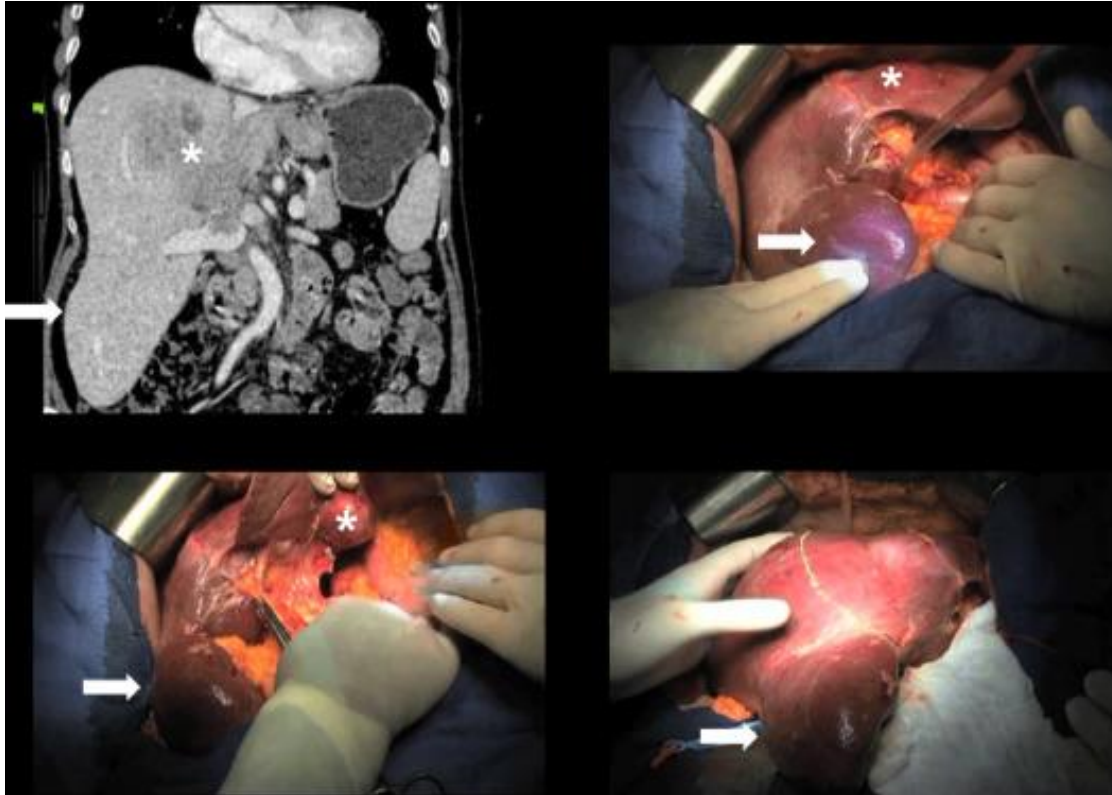
- ***Lobus dexter***
- ***Lobus sinister***
- ***Lobus quadratus***
- ***Lobus caudatus***



ANATOMICKÁ STAVBA JATER

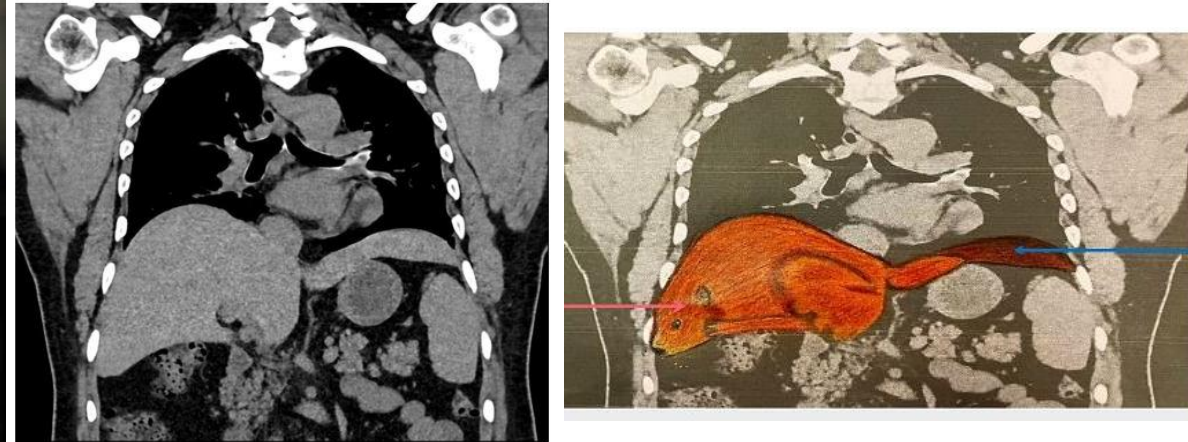Variace jaterních laloků

Riedlův lalok



Glenisson et al., 2014
<https://doi.org/10.1016/j.jviscsurg.2014.09.013>

Beaver tail liver = sliver liver

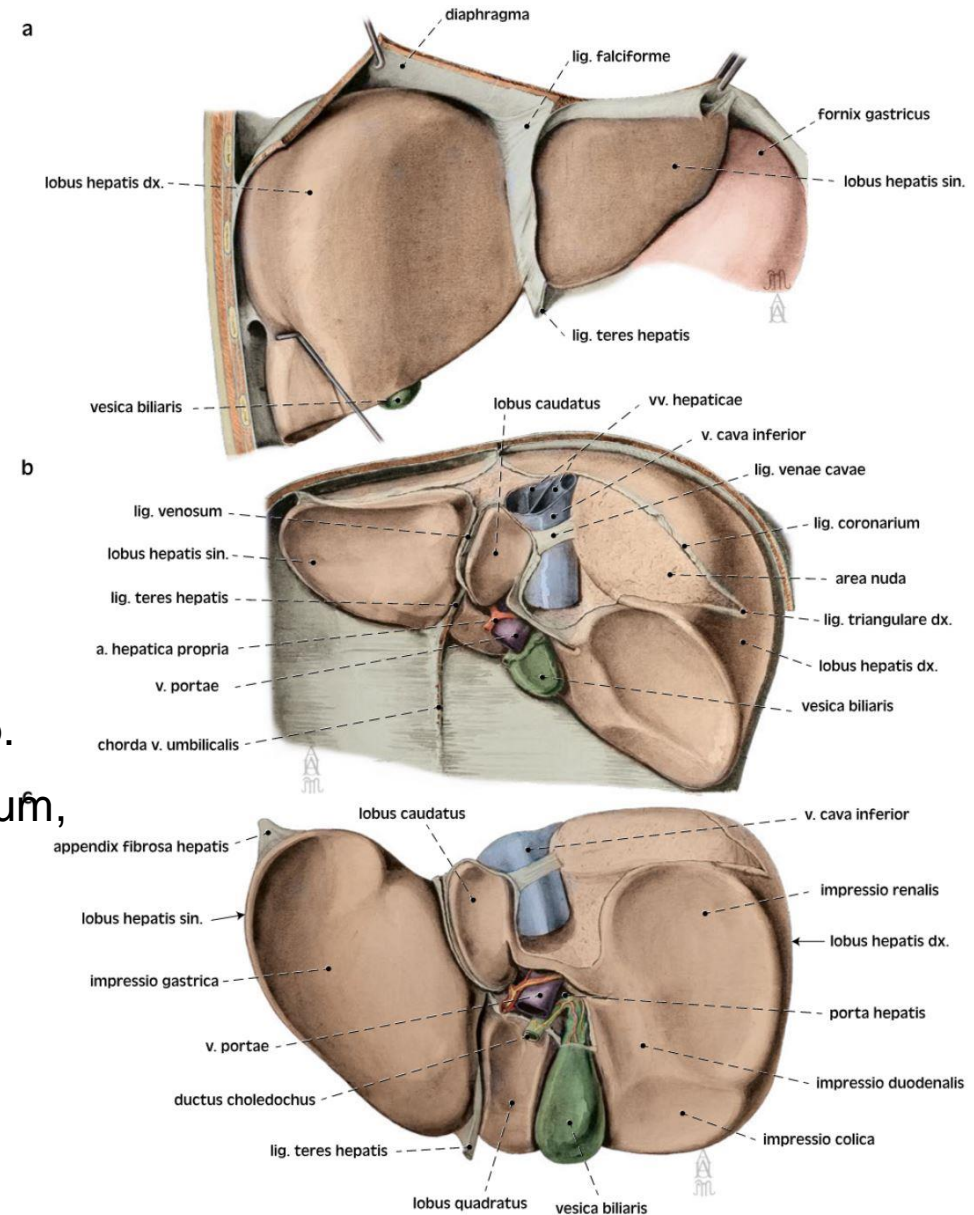


Khanduri et al., 2021
<https://doi.org/10.7759/cureus.16327>

ANATOMICKÁ STAVBA JATER

Vnější členění jater, závěsy jater

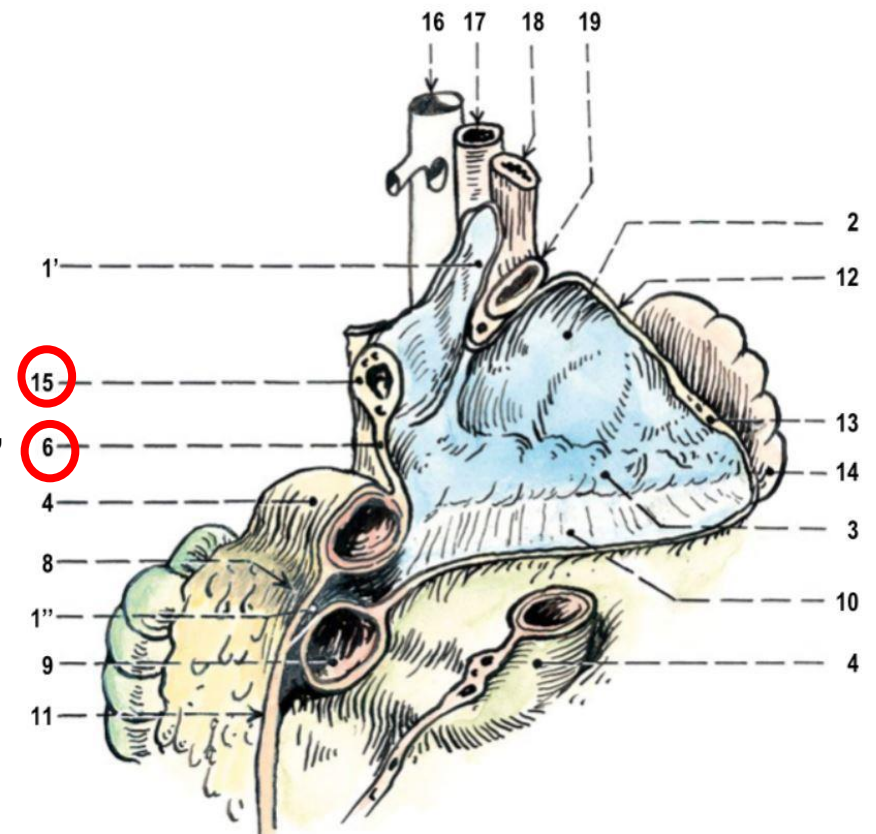
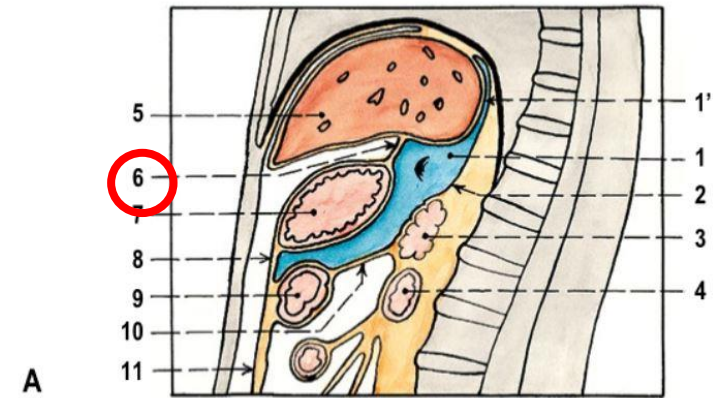
- **lig. falciforme hepatis**
- **lig. teres hepatis hepatis**
 - zbytek po vena umbilicalis
- **lig. coronarium dx.+ sin.**
 - jednoduchý závěs, lemuje area nuda
 - pokračuje jako lig. falciforme hepatis (dopředu)
 - lig. triangulare dx. -> lig. hepatorenale
 - lig. triangulare sin. -> appendix fibrosa hep.
- **omentum minus** – lig. hepatooesophageale, lig. hepatogastricum, lig. hepatoduodenale
- lig. venosum – zbytek po ductus venosus
- lig. venae cavae – mezi lobus caudatus a lobus dexter
- **Fixace:** závěs na v. cava inf., srůst s bránicí, břišní orgány, lig. teres hepatis



ANATOMICKÁ STAVBA JATER

Vnější členění jater, závěsy jater

- *lig. falciforme hepatis*
- *lig. teres hepatis hepatis*
 - zbytek po vena umbilicalis
- *lig. coronarium dx.+ sin.*
 - jednoduchý závěs, lemuje area nuda
 - pokračuje jako *lig. falciforme hepatis* (dopředu)
 - lig. triangulare dx. -> *lig. hepatorenale*
 - lig. triangulare sin. -> *appendix fibrosa hep.*
- **omentum minus** – *lig. hepatooesophageale*, *lig. hepatogastricum*,
lig. hepatoduodenale
- *lig. venosum* – zbytek po *ductus venosus*
- *lig. venae cavae* – *lobus caudatus* a *lobus dexter*
- **Fixace:** závěs na v. cava inf., srůst s bránicí, břišní orgány, *lig. teres hepatis*



ANATOMICKÁ STAVBA JATER

Jaterní segmenty

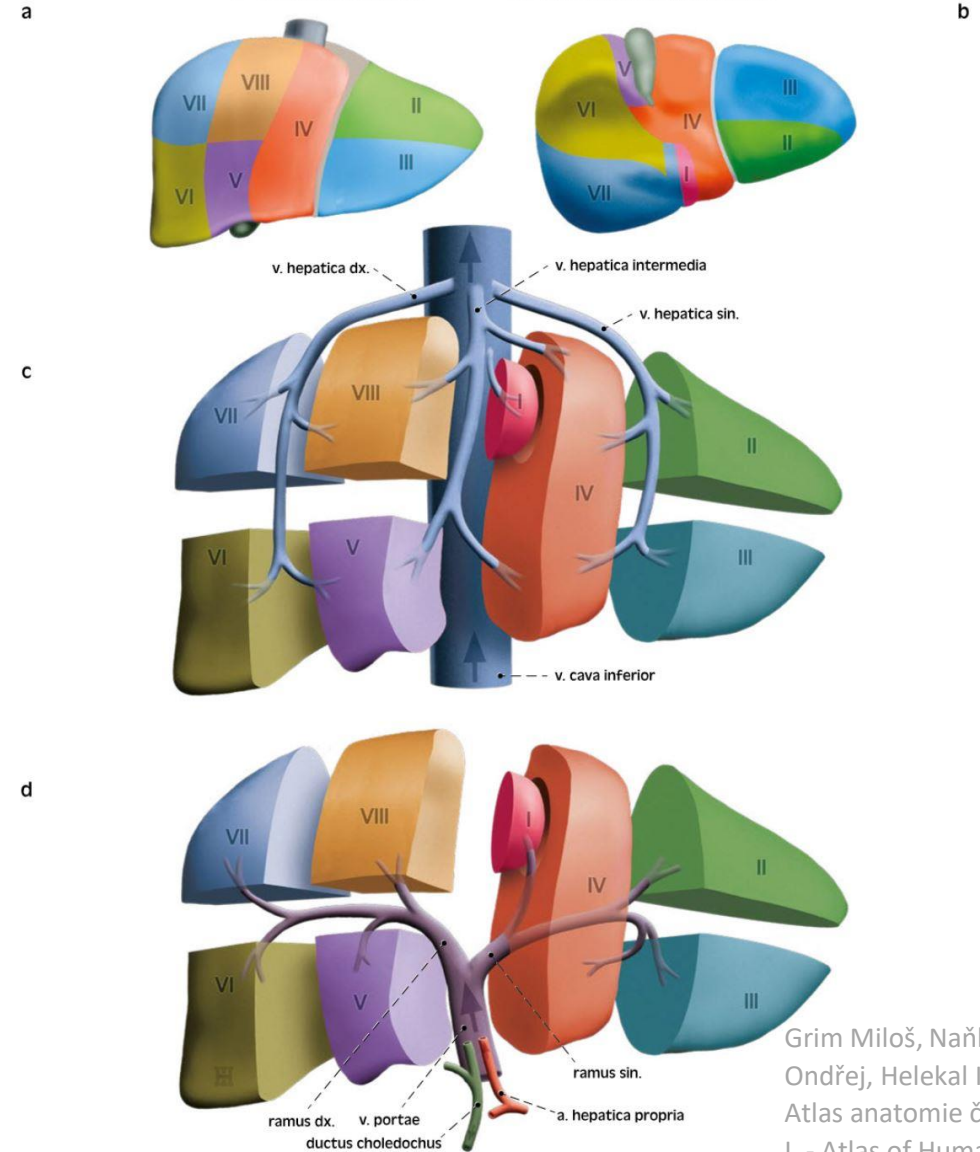
Pars hepatis sinistra

- *Divisio lateralis sinistra*
 - **II Segmentum posterius laterale sinistrum**
 - **III Segmentum anterius laterale sinistrum**
- *Divisio medialis sinistra*
 - **IV Segmentum mediale sinistrum**
 - **I Segmentum posterius** – variabilní zásobení Lobus caudatus

Pars hepatis dextra

- *Divisio medialis dextra*
 - **V Segmentum anterius mediale dextrum**
 - **VIII Segmentum posterius mediale dextrum**
- *Divisio lateralis dextra*
 - **VI Segmentum anterius laterale dextrum**
 - **VII Segmentum posterius laterale dextrum**

I – segmentum posterius
II – segmentum posterius laterale sin.
III – segmentum anterius laterale sin.
IV – segmentum mediale sin.
V – segmentum anterius mediale dx.
VI – segmentum anterius laterale dx.
VII – segmentum posterius laterale dx.
VIII – segmentum posterius mediale dx.



Segmentatio hepatis, segmenty jater

- a *pohled zřepedu*
b *pohled zdola*
c *poloha vv. hepaticae mezi jaterními segmenty*
d *větvení v. portae k jaterním segmentům*

Liver segments

- a *anterior view*
b *inferior view*
c *position of the hepatic veins between hepatic segments*
d *branching of the hepatic portal vein to the liver segments*

Grim Miloš, Naňka Ondřej, Helekal Ivan:
Atlas anatomie člověka
I. - Atlas of Human Anatomy I. ISBN: 978-80-247-4012-6, Grada

ANATOMICKÁ STAVBA JATER

Cévní zásobení

1,5 l krve/minutu = 25 % srdečního výdeje

Funkční oběh 70 – 80 %

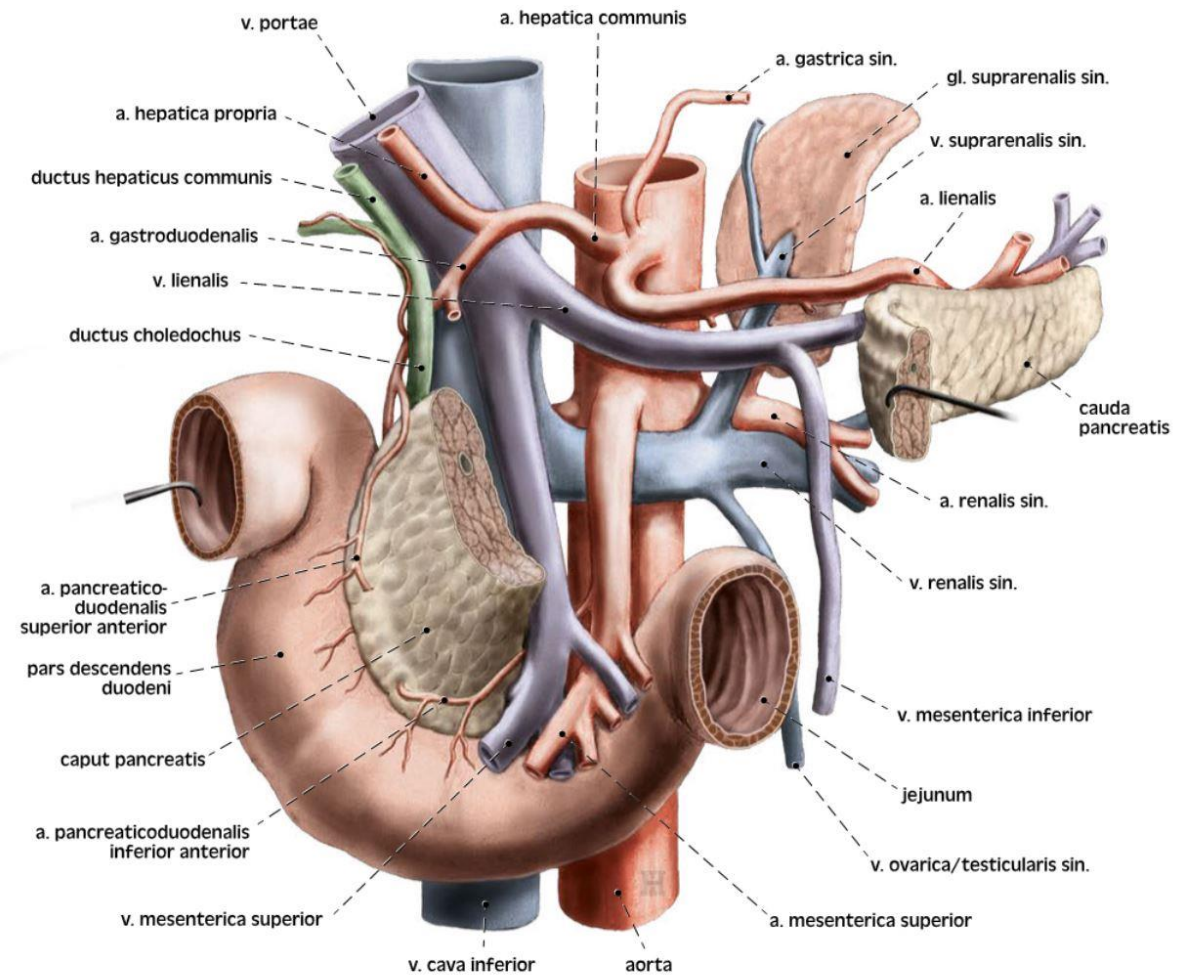
- **Vena portae**
 - soutok *vena mesenterica superior* a *vena splenica*
 - dorzálně

Nutritivní oběh 20 – 30 %

- **Arteria hepatica propria**
 - *truncus coeliacus* → *a. hepatica communis*
 - ventromediálně

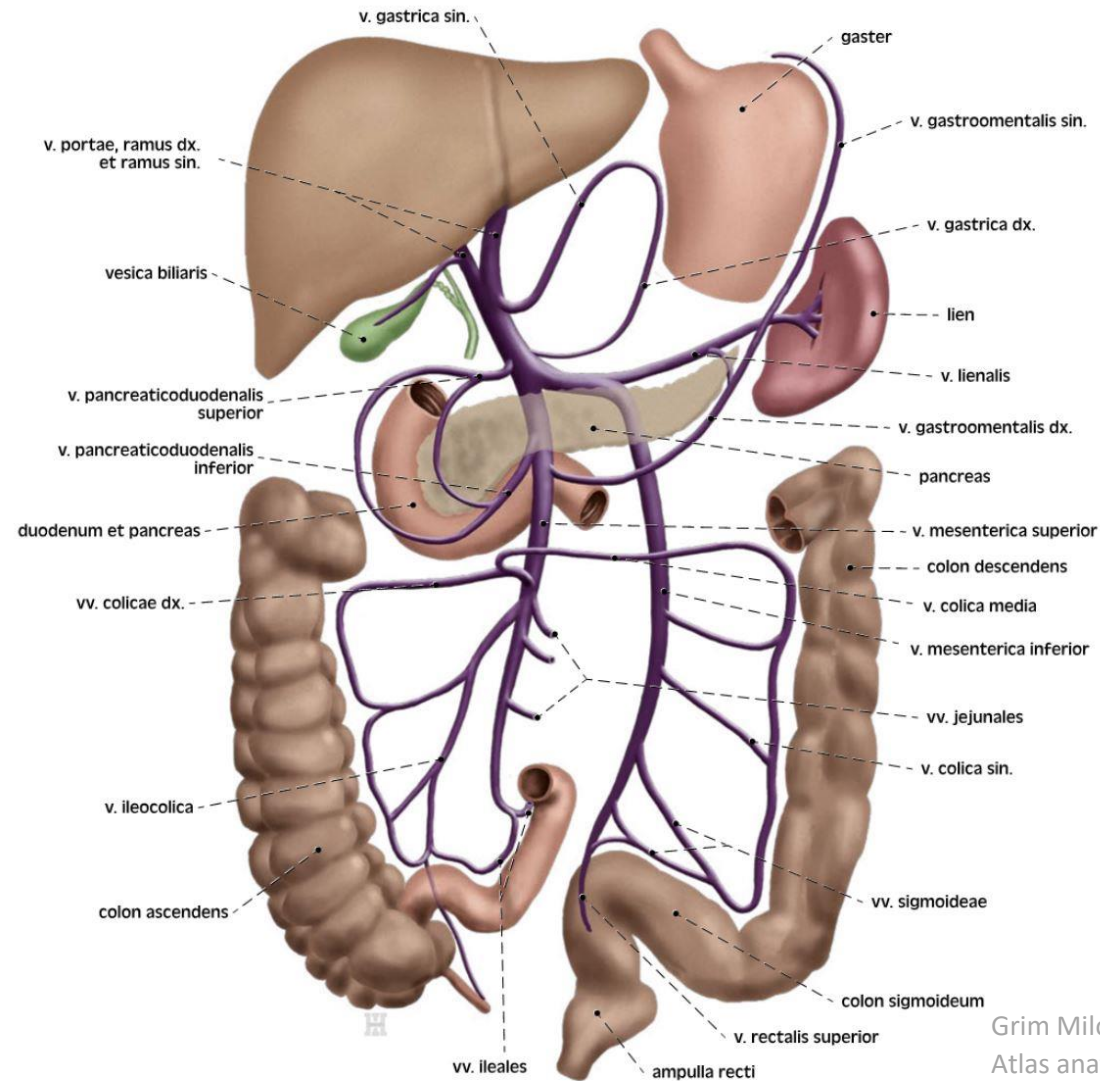
Žilní odtok

- **Vena hepatica dextra, sinistra a intermedia**
 - Do *vena cava inferior*



ANATOMICKÁ STAVBA JATER

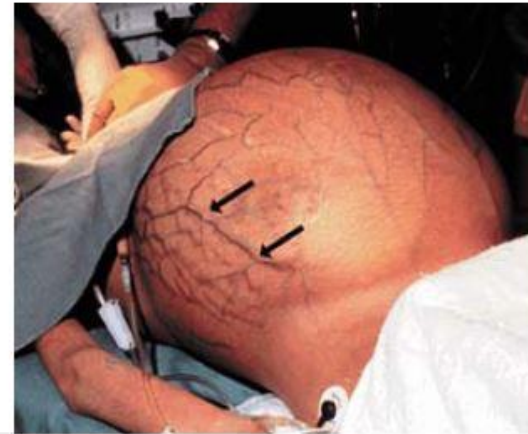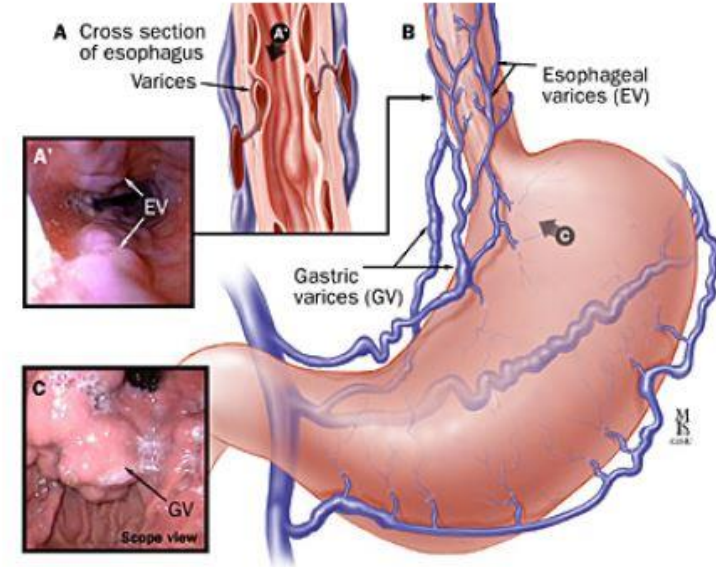
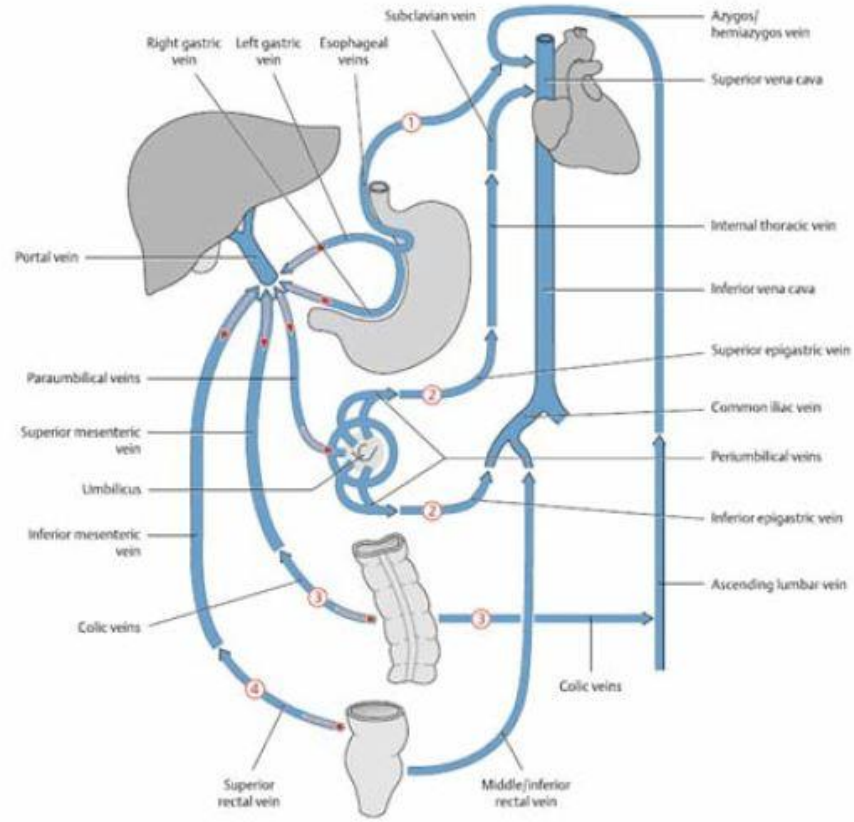
Cévní zásobení – *vena portae*



Grim Miloš, Naňka Ondřej, Helekal Ivan:
Atlas anatomie člověka I. - Atlas of Human
Anatomy I. ISBN: 978-80-247-4012-6, Grada

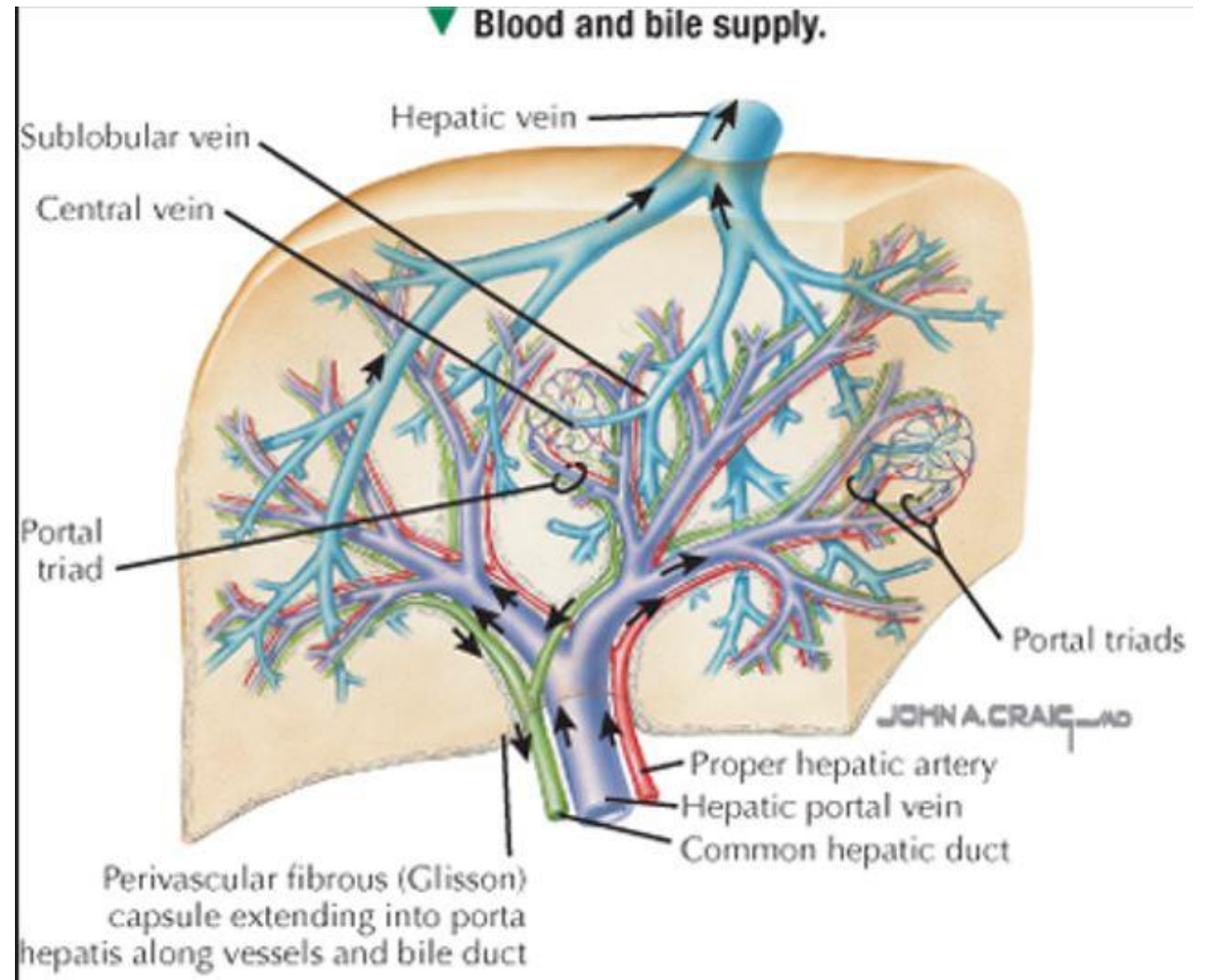
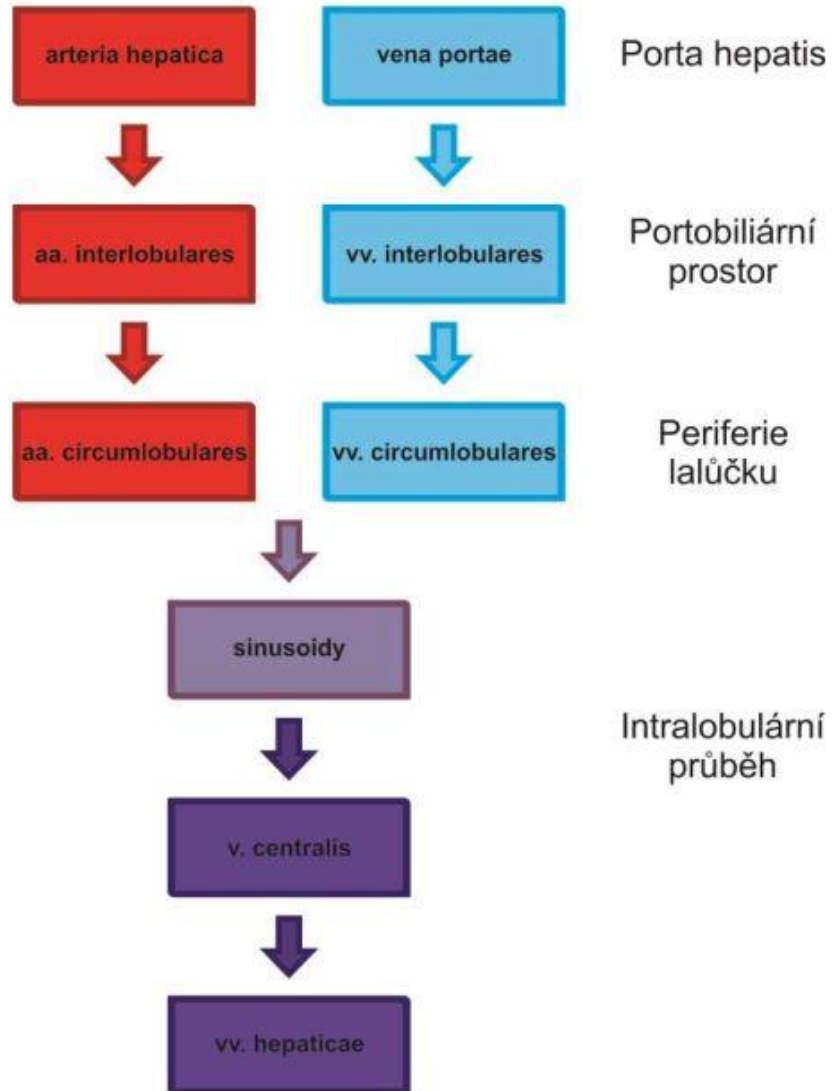
ANATOMICKÁ STAVBA JATER

Portokavální anastomózy



ANATOMICKÁ STAVBA JATER

Cévní zásobení



ANATOMICKÁ STAVBA JATER

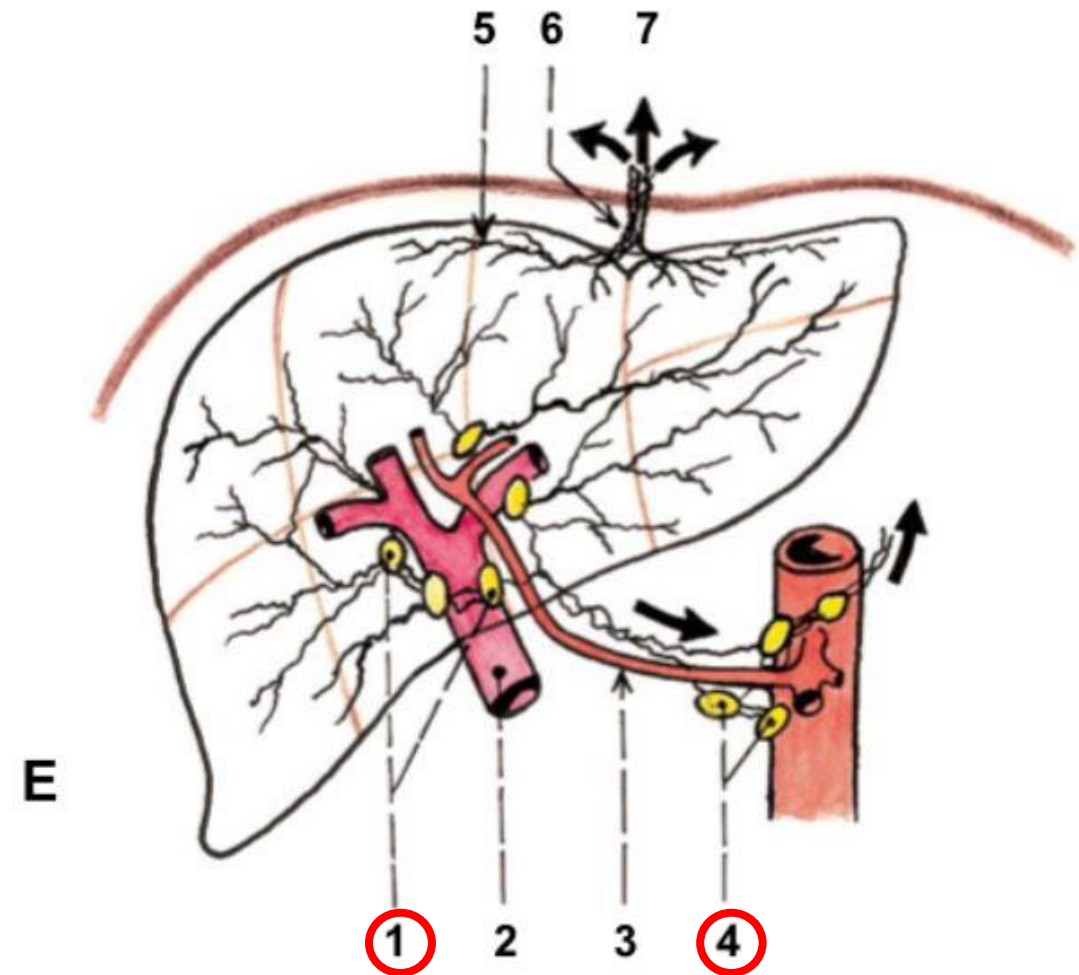
Inervace, Lymfatická drenáž

Inervace

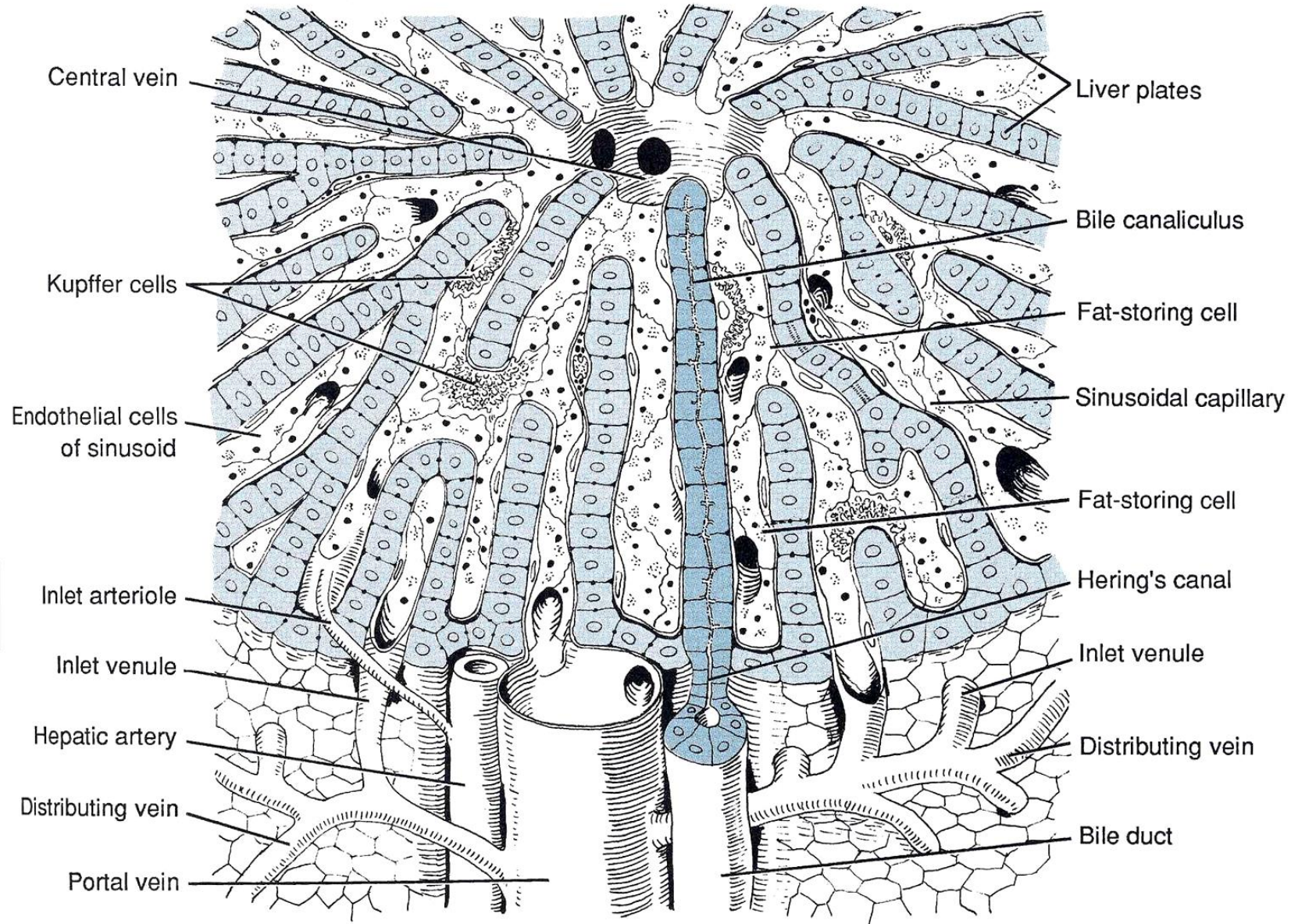
- *N. phrenicus dexter* – viscerosenzitivita
- *N. vagus* – parasympatikus
- *NN. Splanchnici thoracici* – sympatikus

Lymfatická drenáž

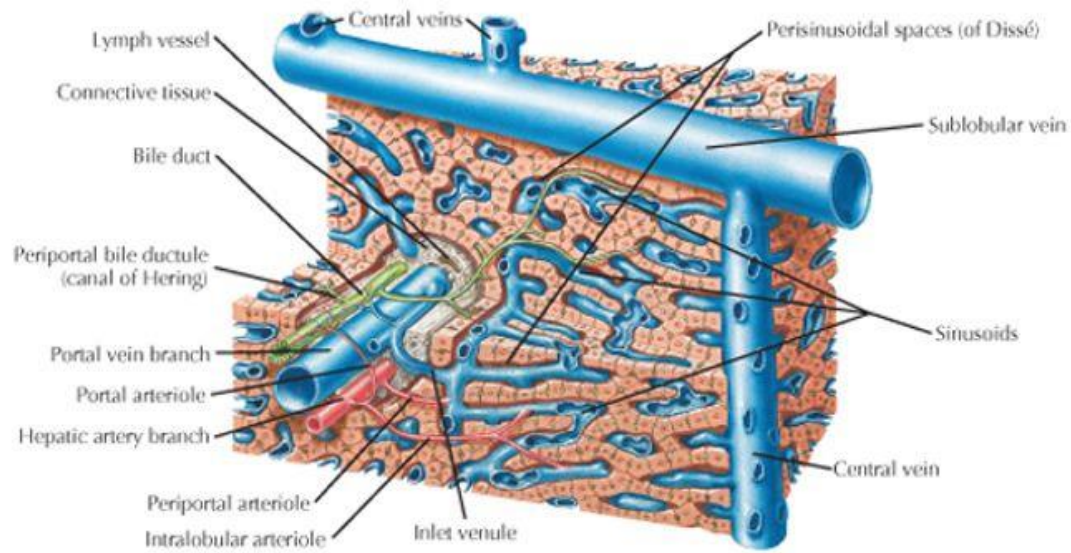
- *Nodi lymphoidei hepatici*
- *Nodi lymphoidei coeliaci*



MIKROSKOPICKÁ STAVBA JATER

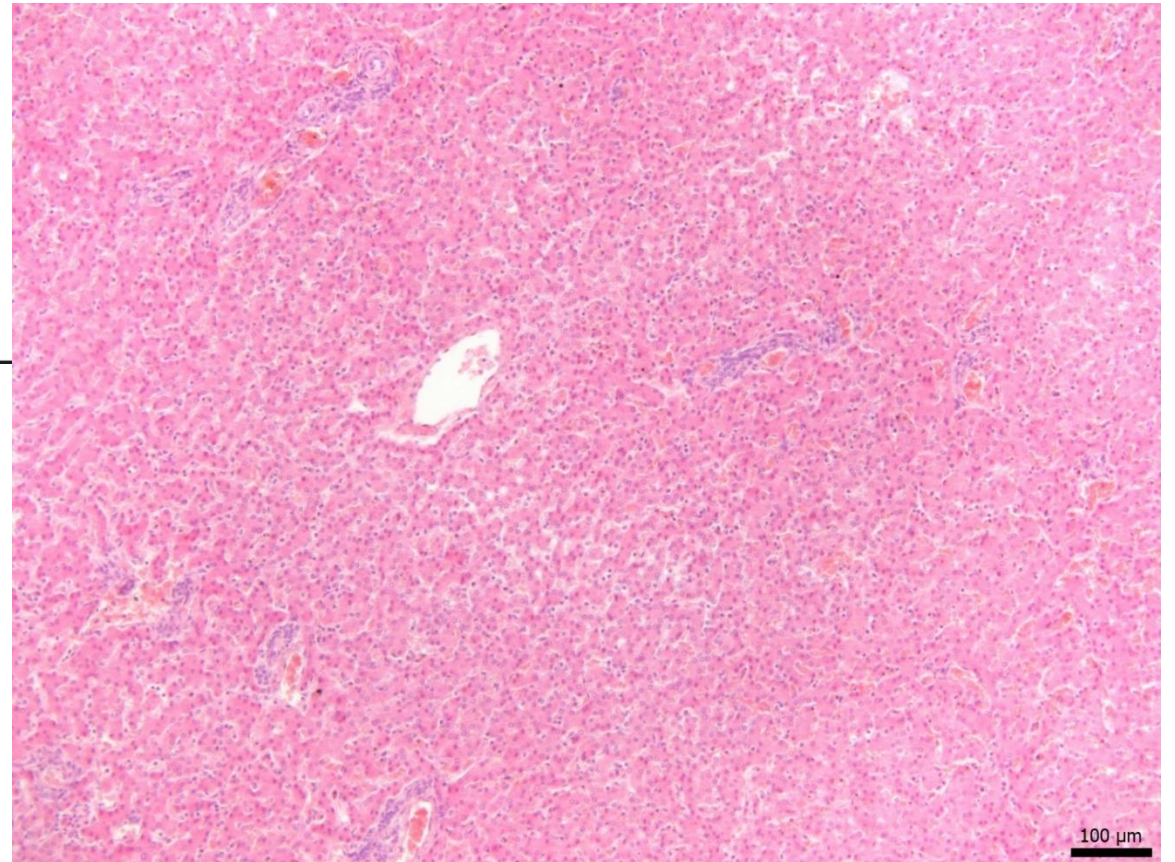


MIKROSKOPICKÁ STAVBA JATER

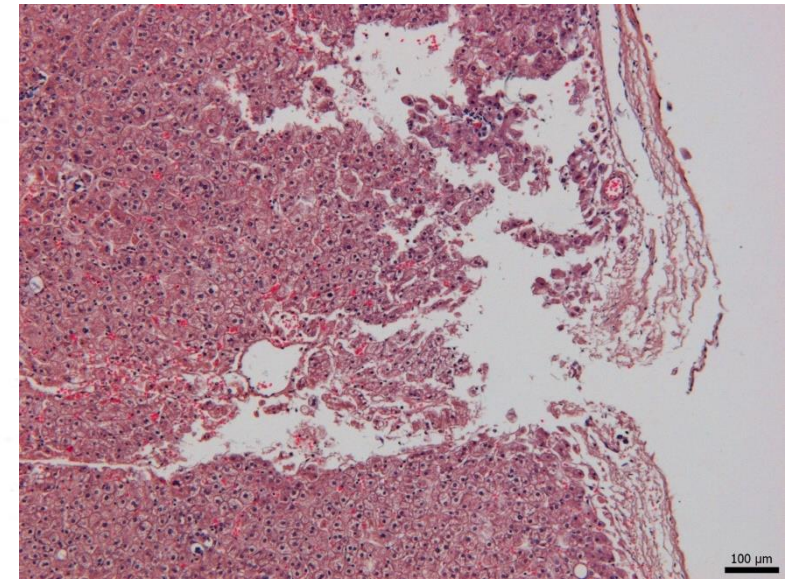
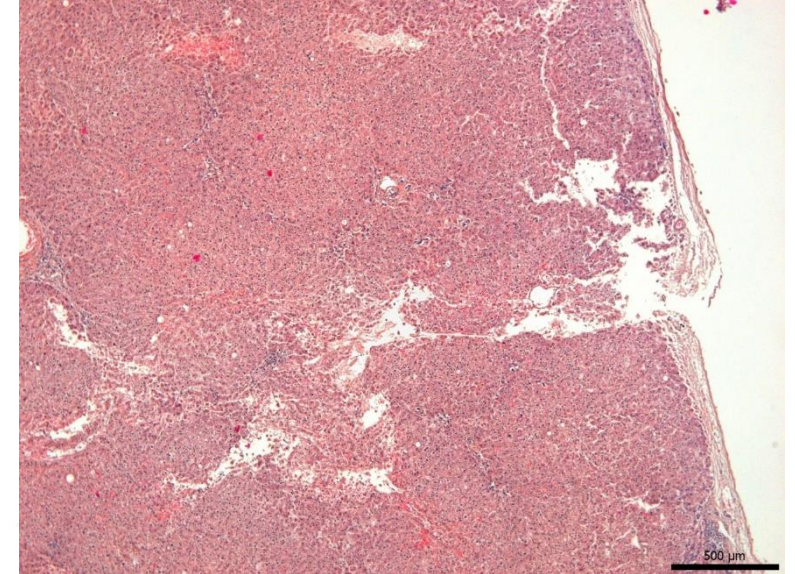
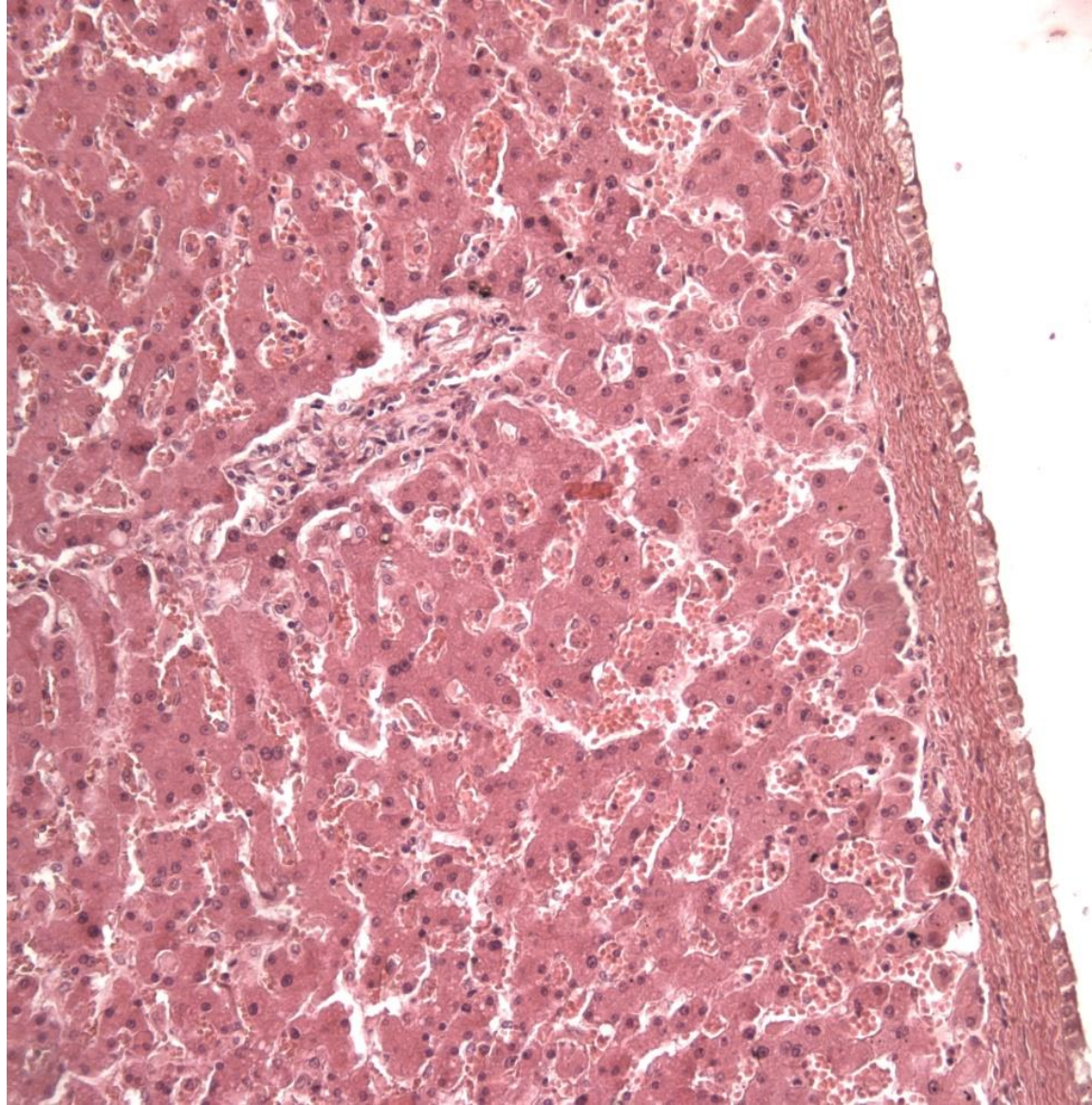
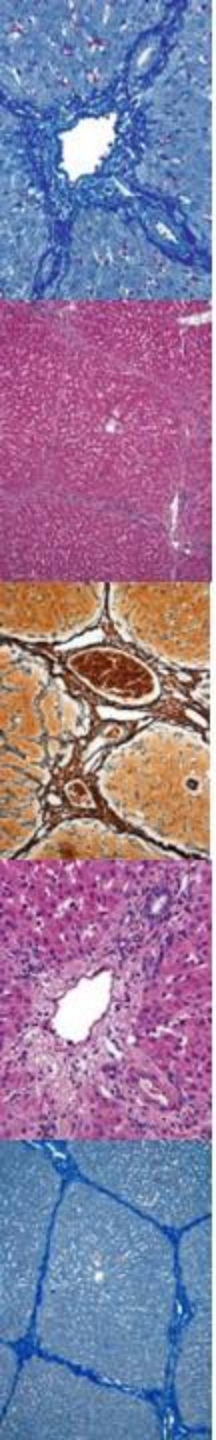


▲ Three-dimensional schematic of liver structure.

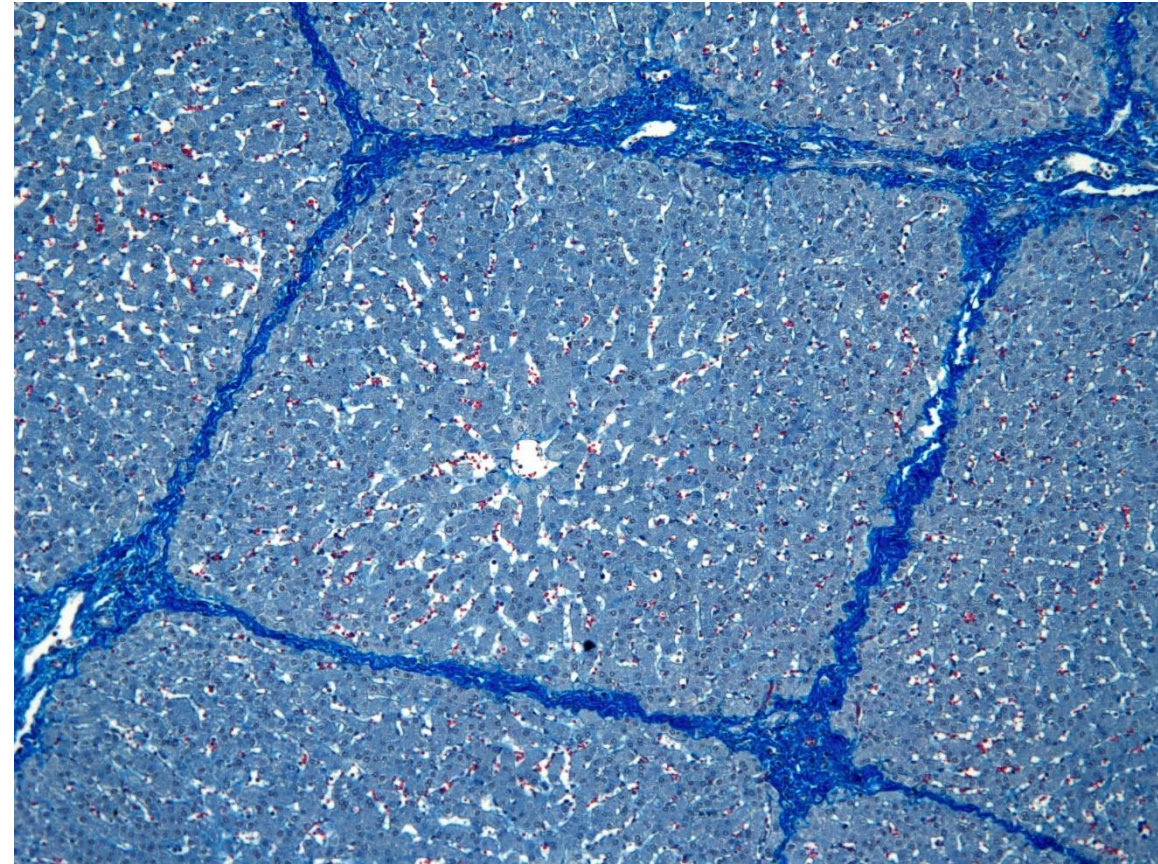
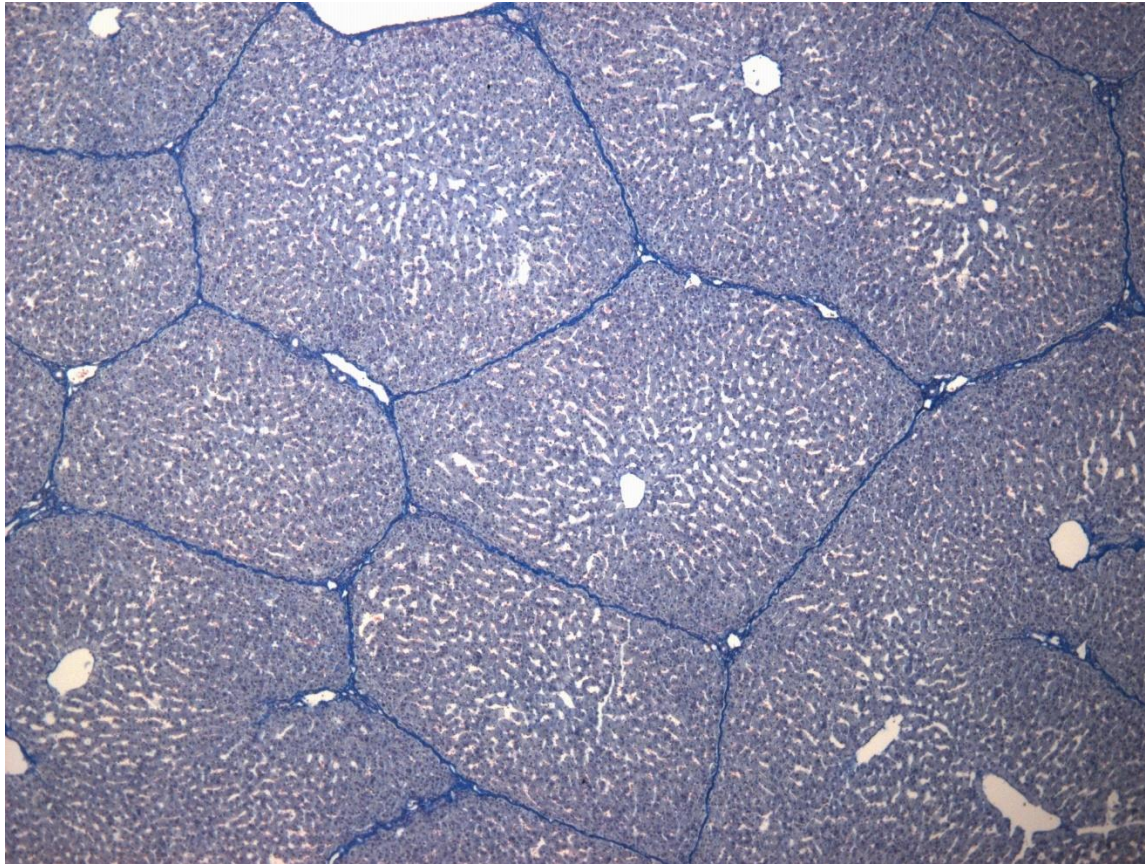
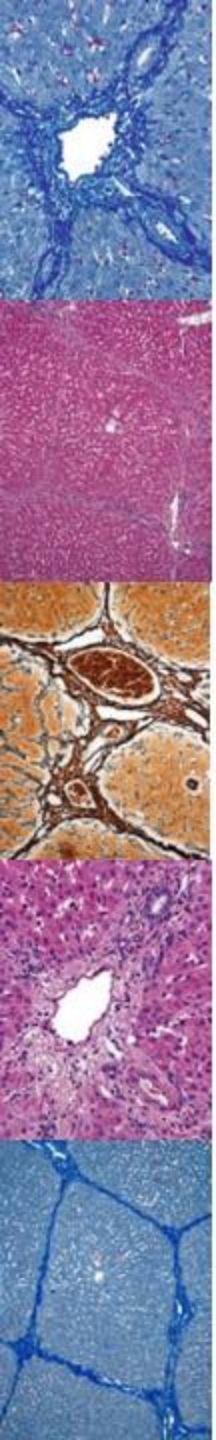
© Elsevier. Ovalle & Nahirney: Netter's Essential Histology - www.studentconsult.com



MIKROSKOPICKÁ STAVBA JATER

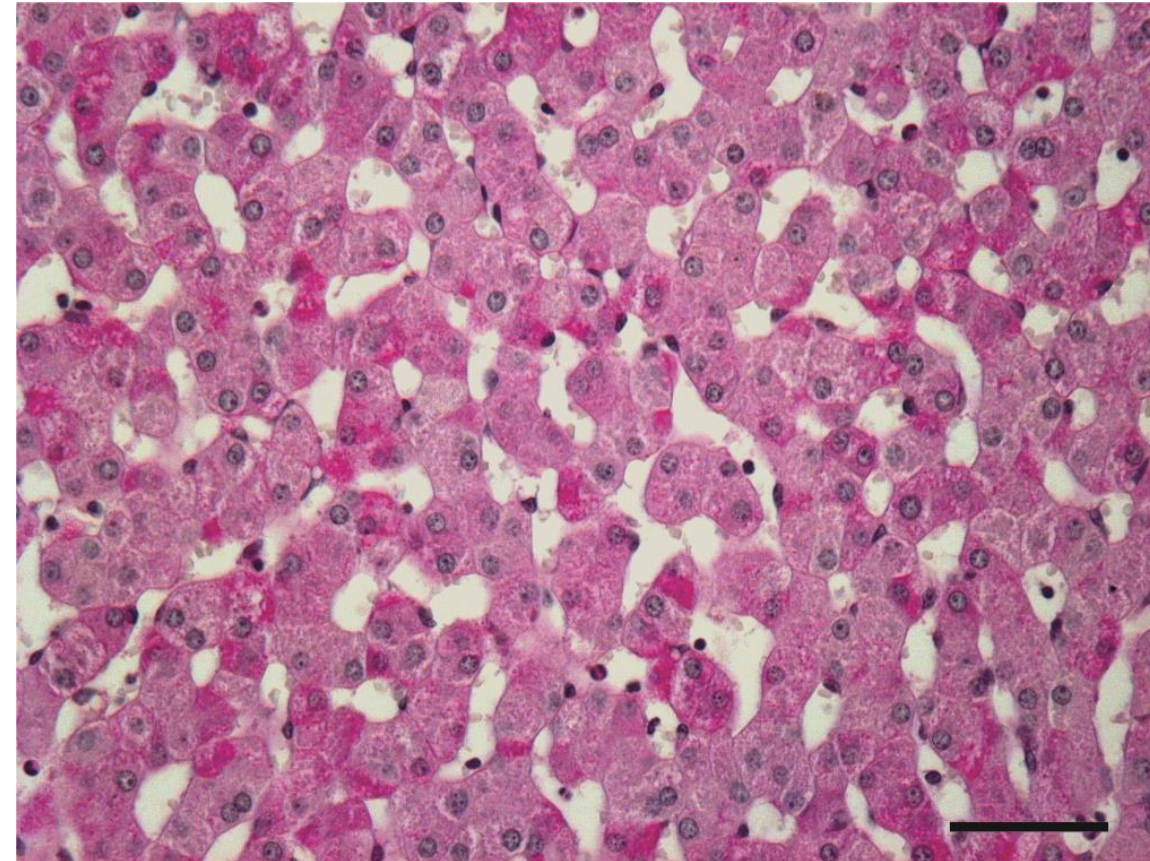
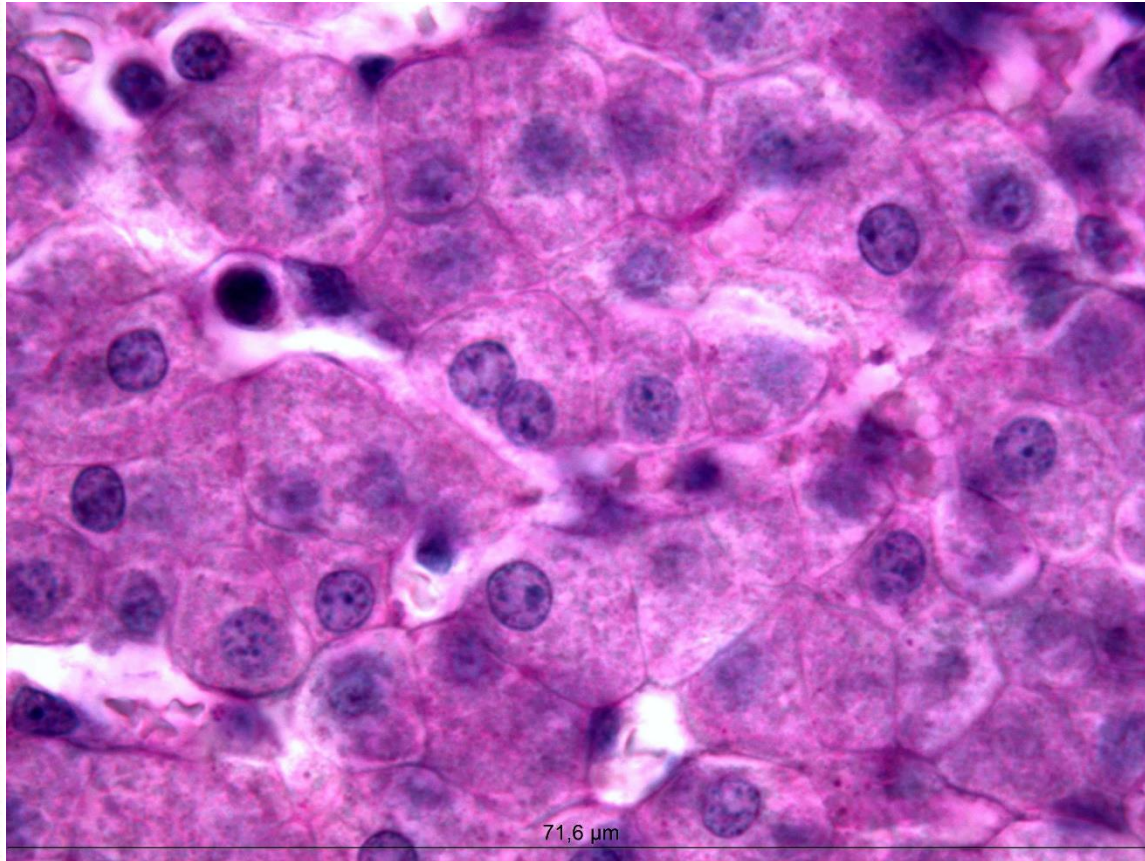

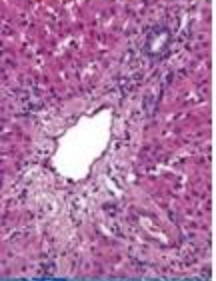
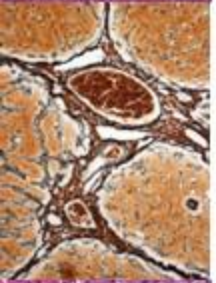
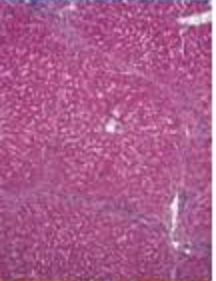
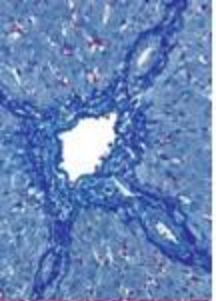


MIKROSKOPICKÁ STAVBA JATER



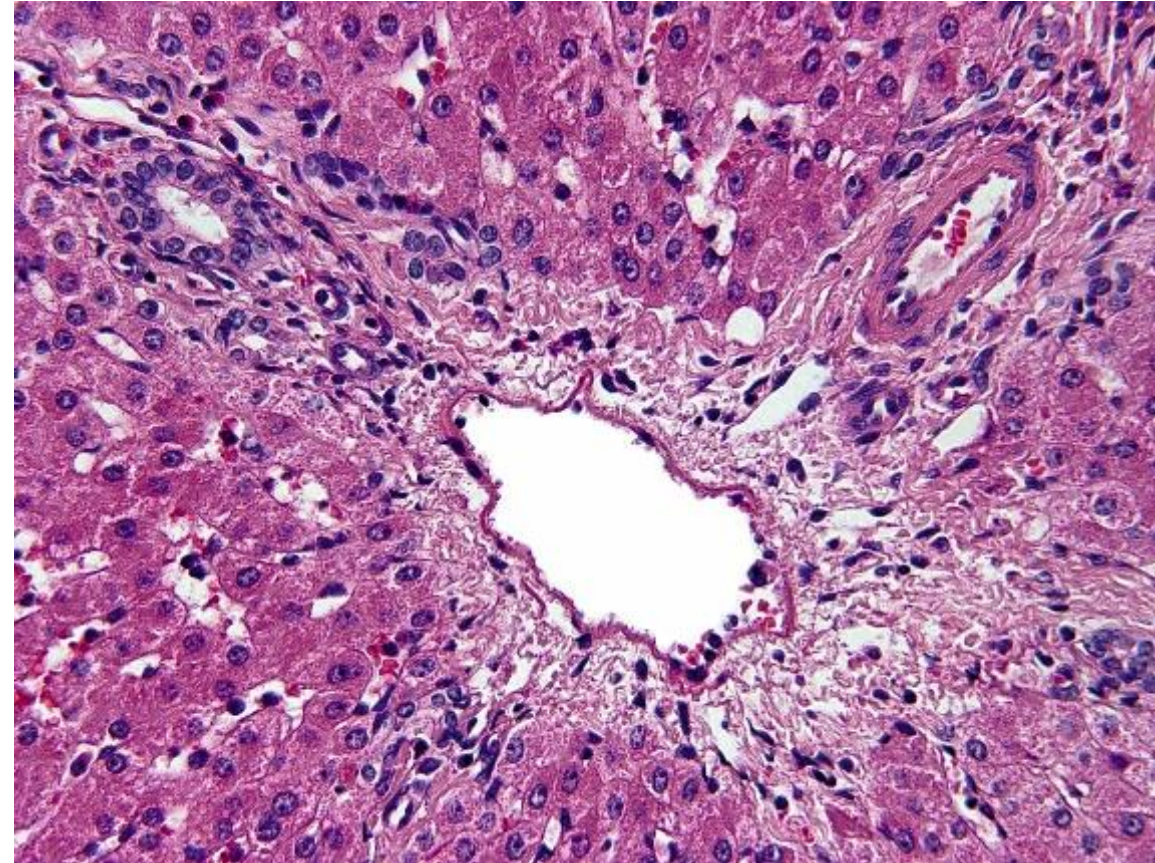
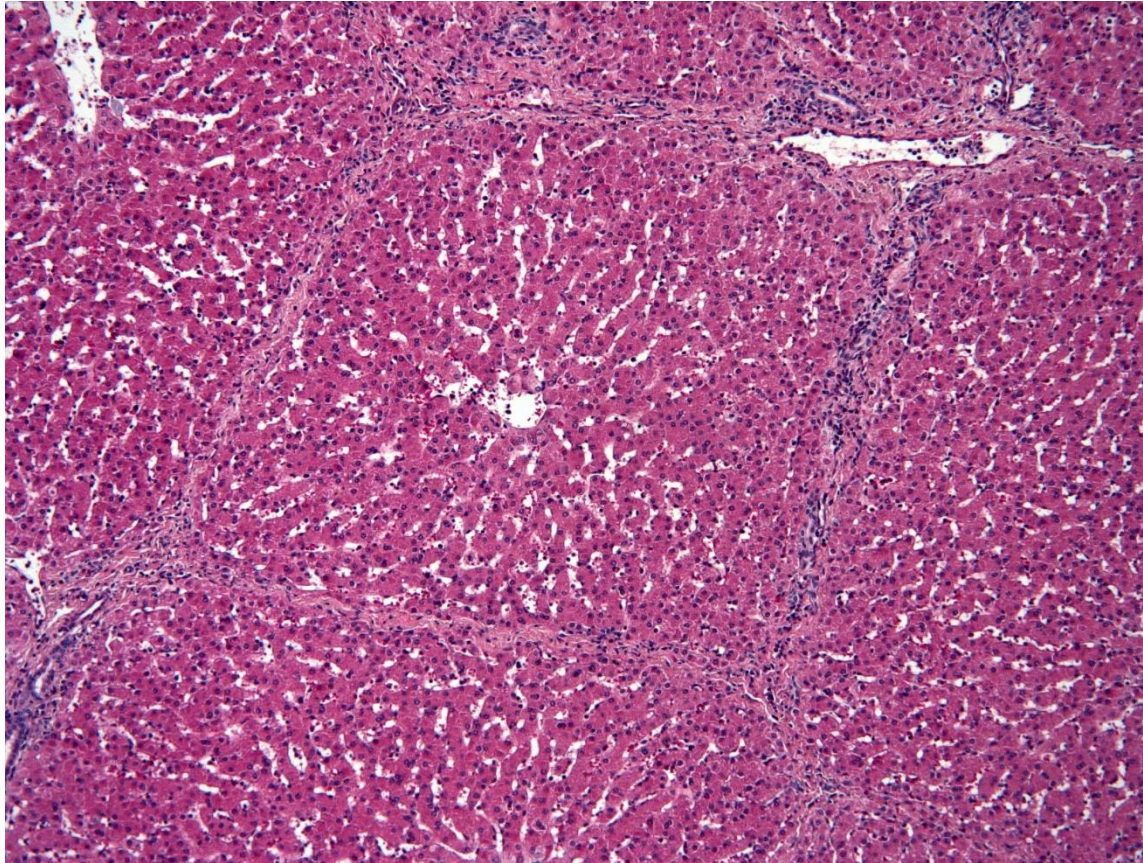

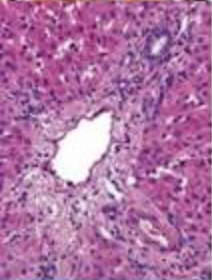
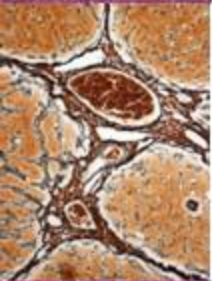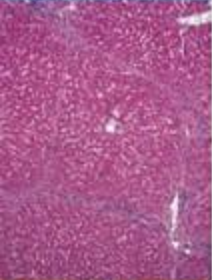
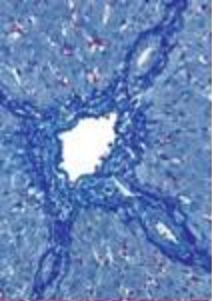
MIKROSKOPICKÁ STAVBA JATER

Trámce hepatocytů – PAS barvení



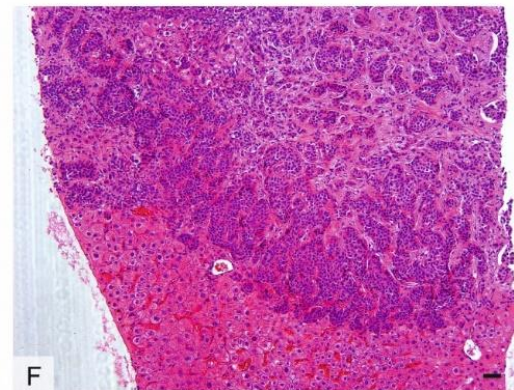
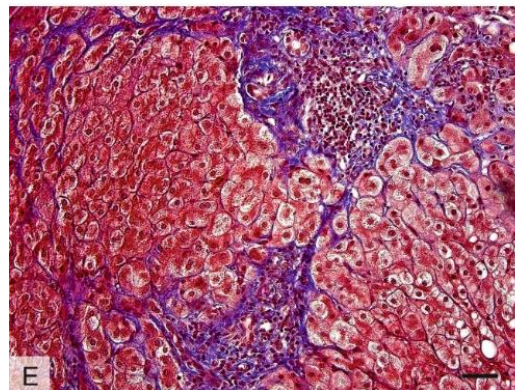
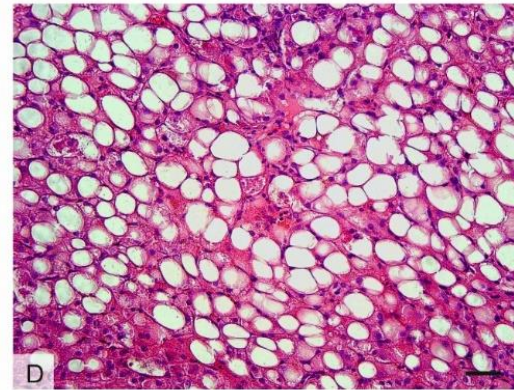
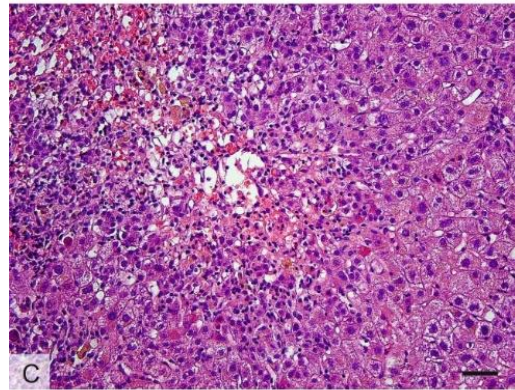
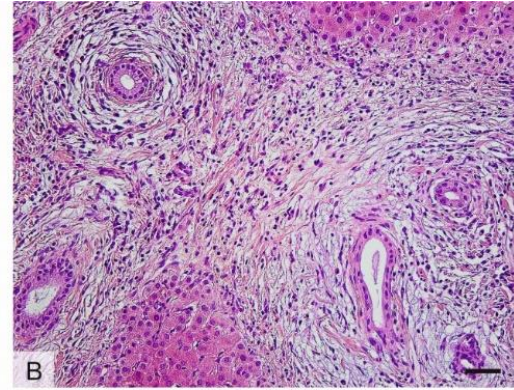
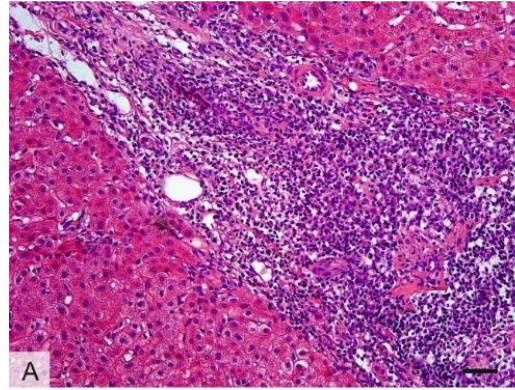
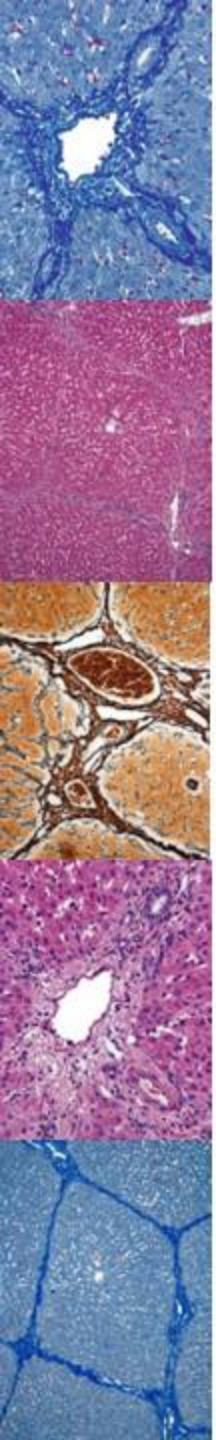
MIKROSKOPICKÁ STAVBA JATER

Portobiliární prostory, *trias hepatica*



MIKROSKOPICKÁ STAVBA JATER

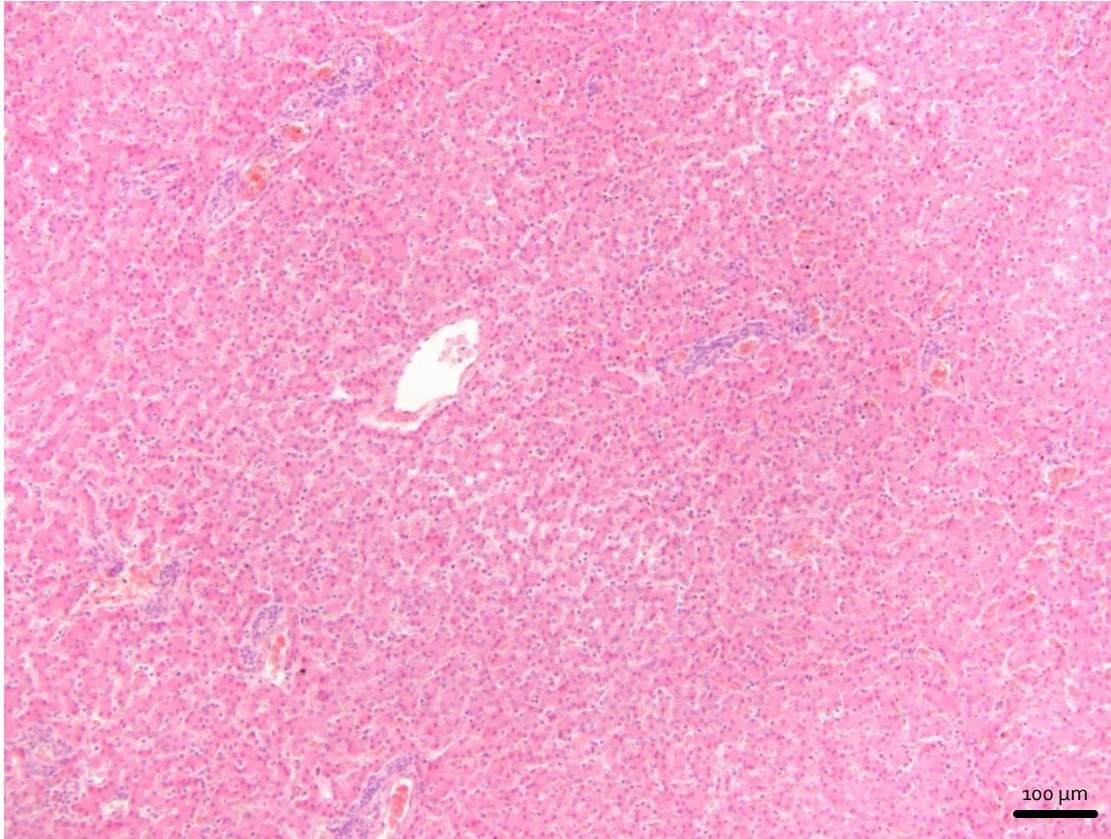
Patologické vzorce



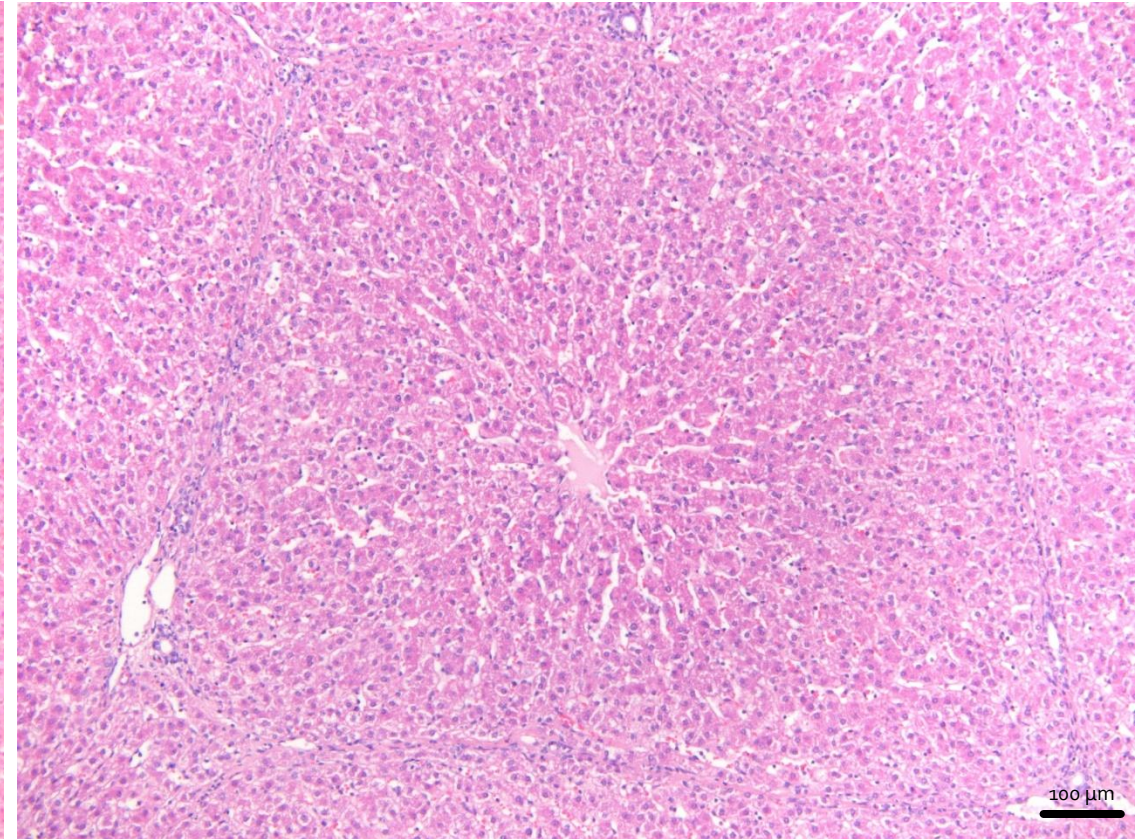
MIKROSKOPICKÁ STAVBA JATER

Členění jaterního parenchymu

Člověk

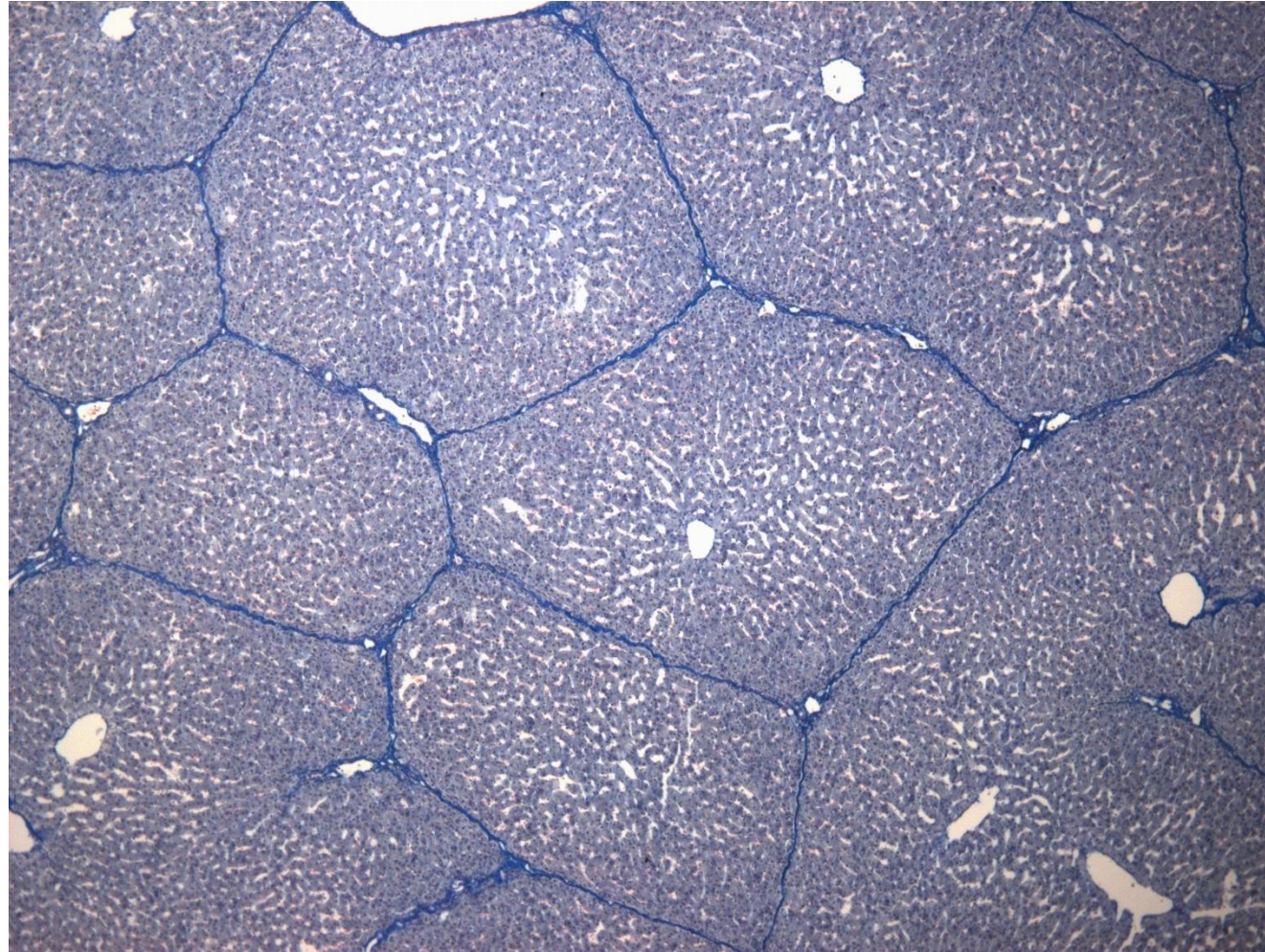
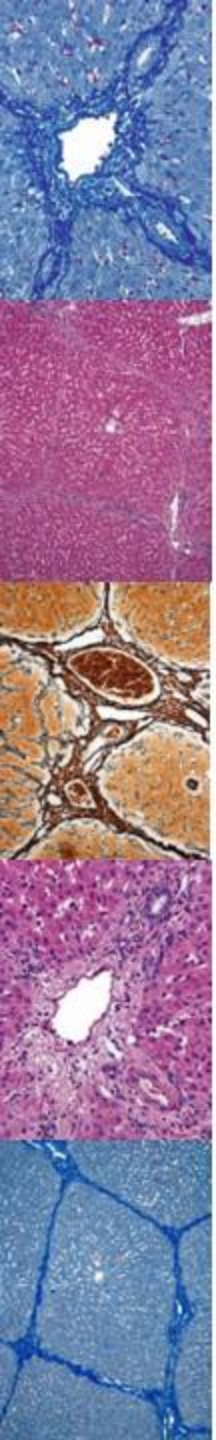


Prase



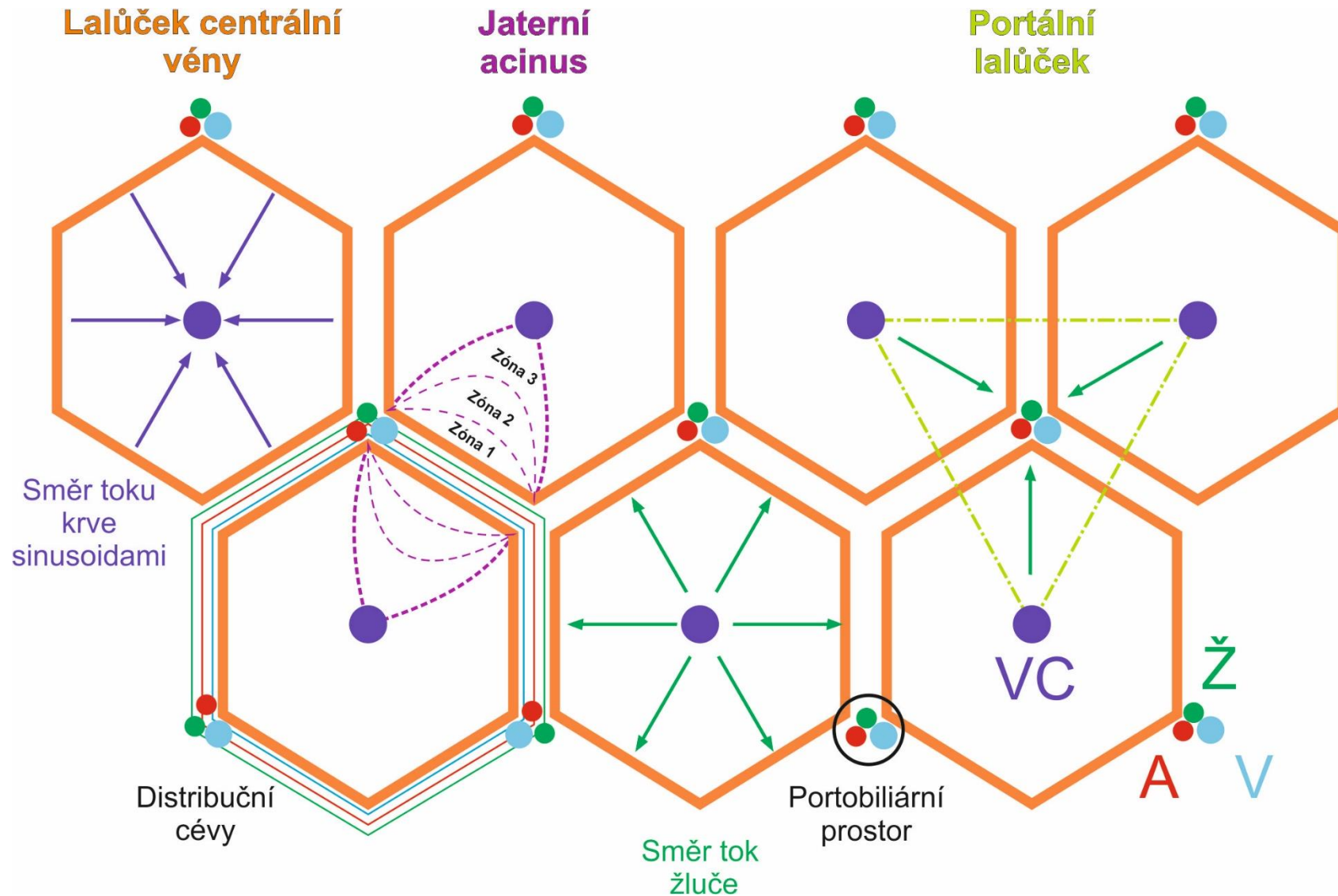
MIKROSKOPICKÁ STAVBA JATER

Členění jaterního parenchymu



MIKROSKOPICKÁ STAVBA JATER

Členění jaterního parenchymu

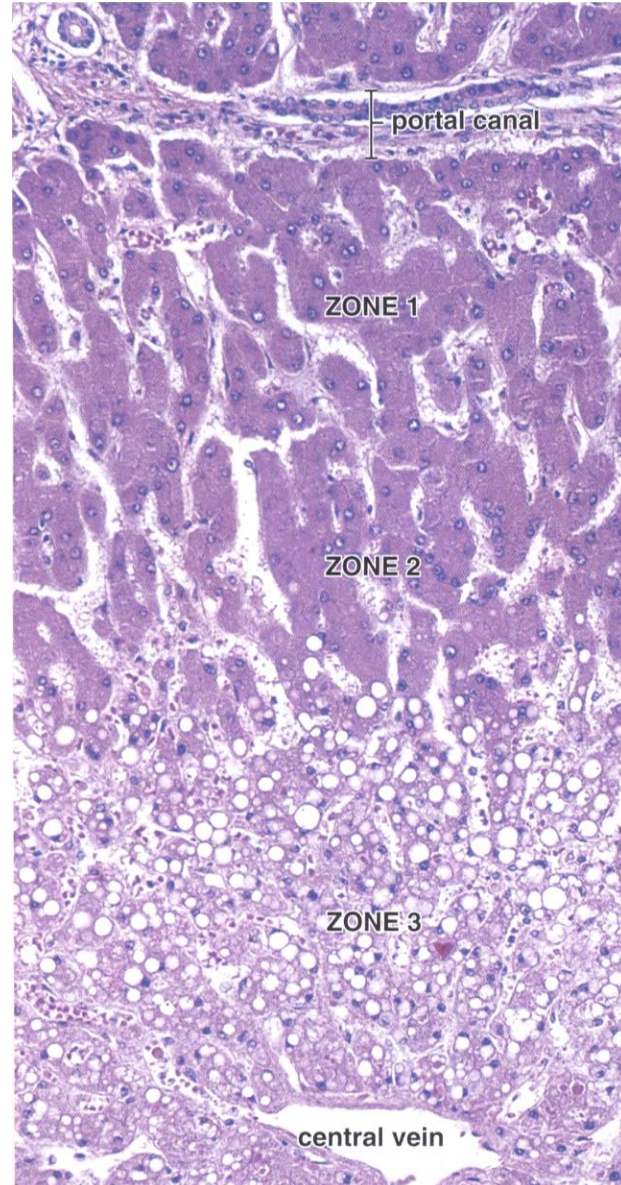


MIKROSKOPICKÁ STAVBA JATER

Členění jaterního parenchymu

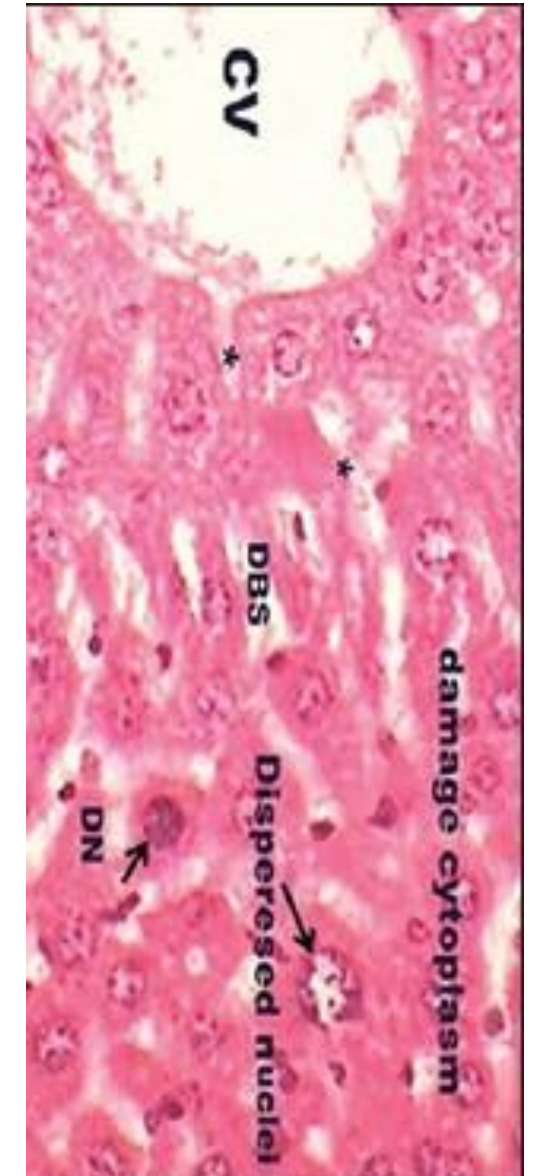
hypoxické
poškození
jaterního
lalůčku

Pawlina, W.:
Histology. A Text and
Atlas, Wolters Kluwer
2016.



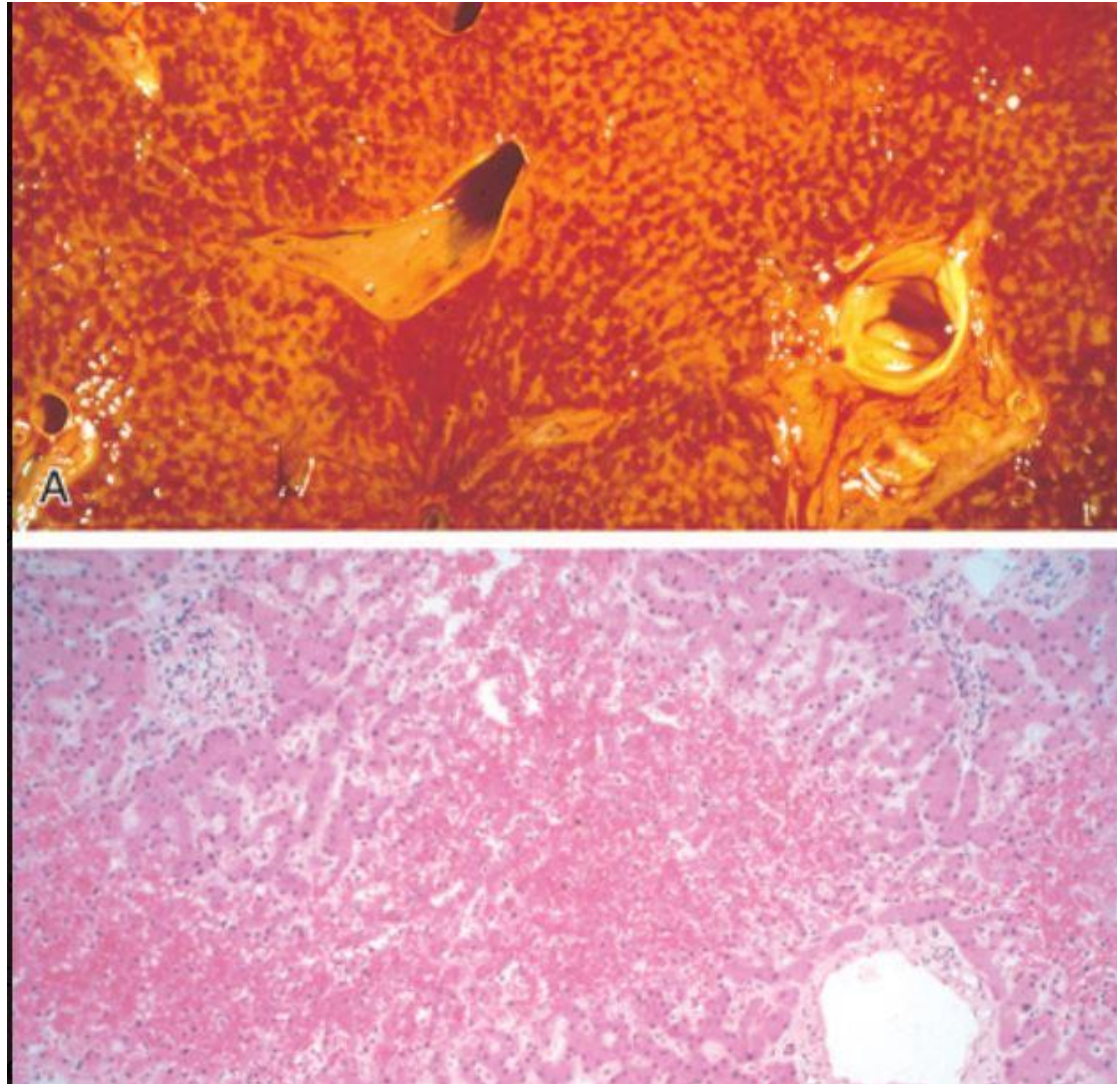
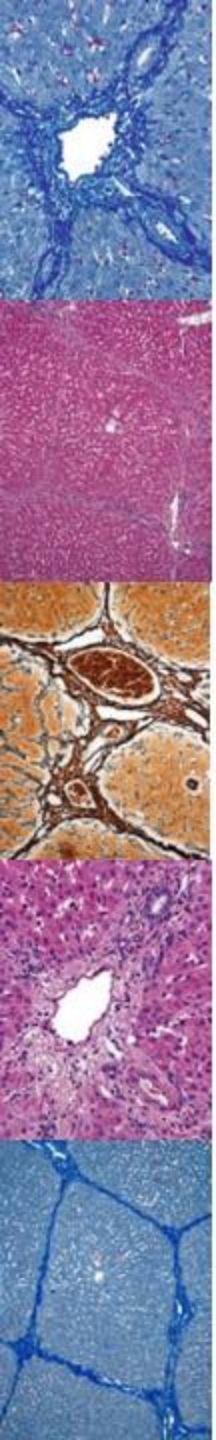
toxické
poškození
jaterního
lalůčku

Sarma, V., Janmeda, P.:
Toxicology International 21
(1), 2014: 37-43.



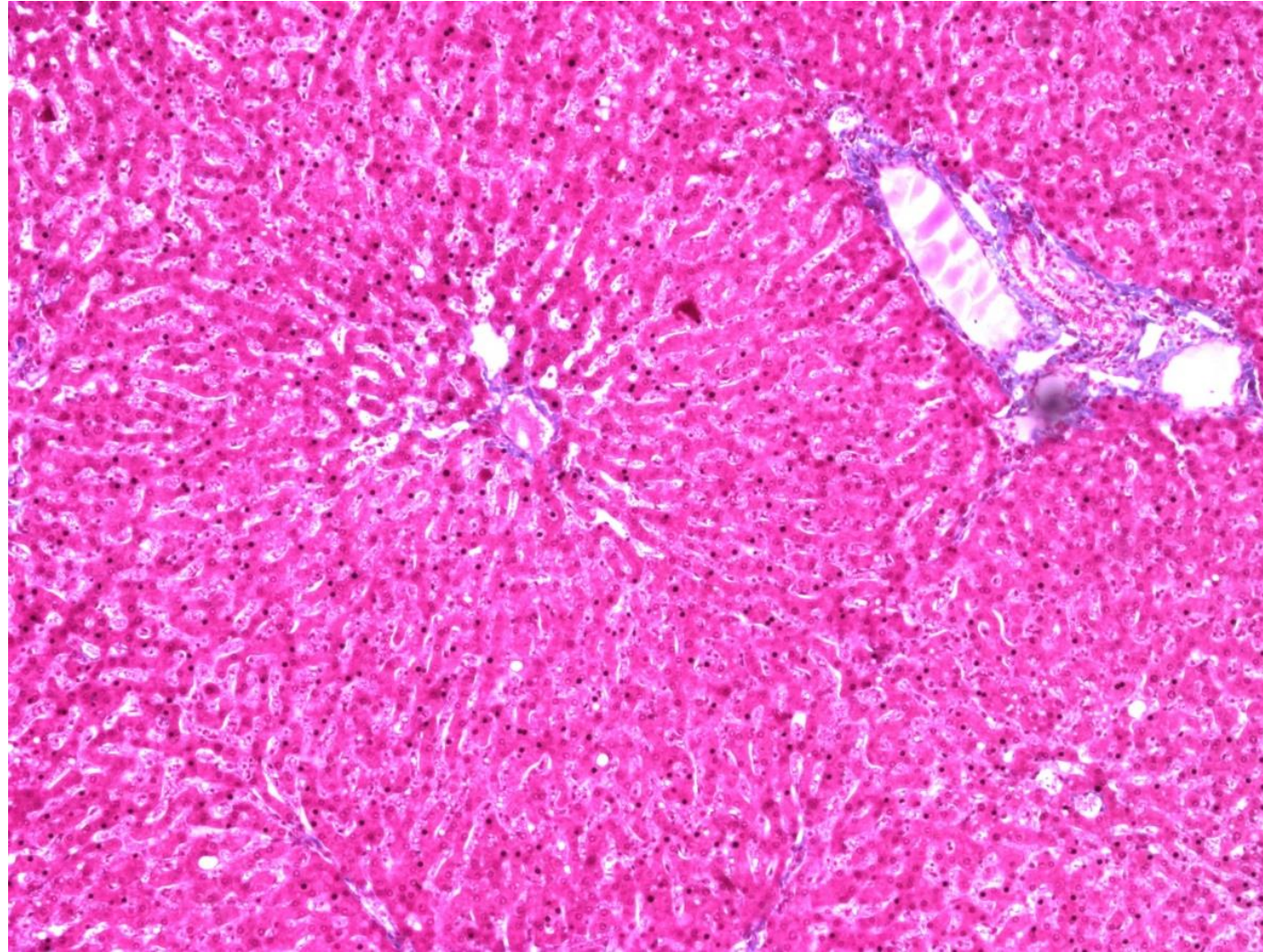
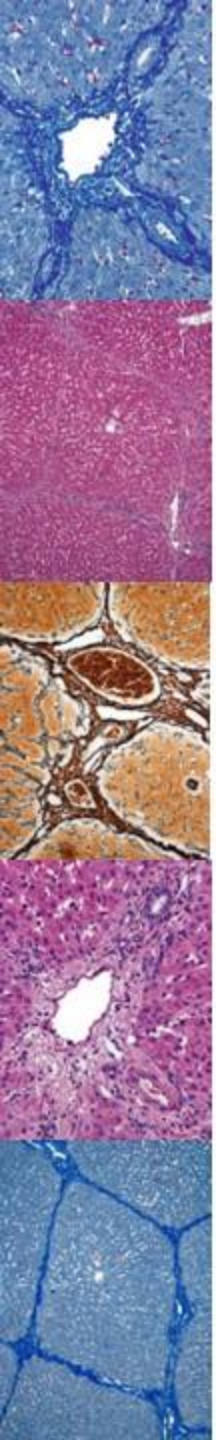
MIKROSKOPICKÁ STAVBA JATER

Členění jaterního parenchymu



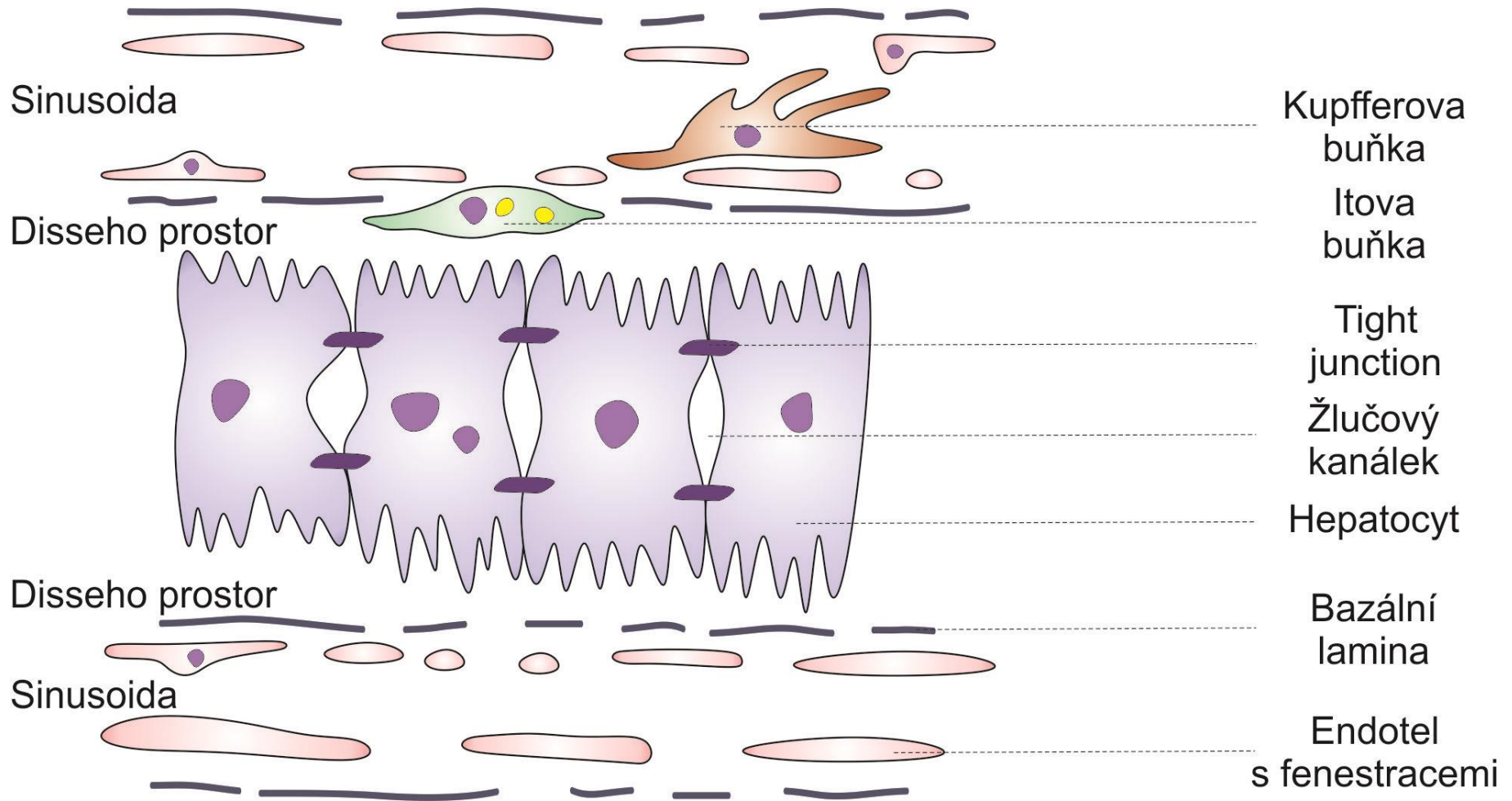
MIKROSKOPICKÁ STAVBA JATER

Detail jaterního parenchymu



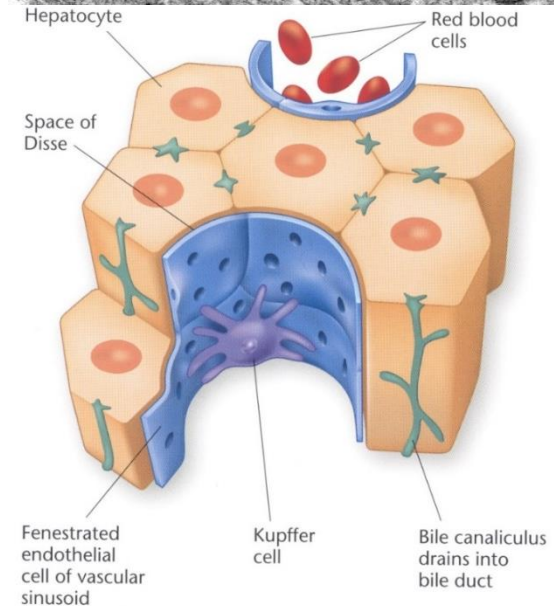
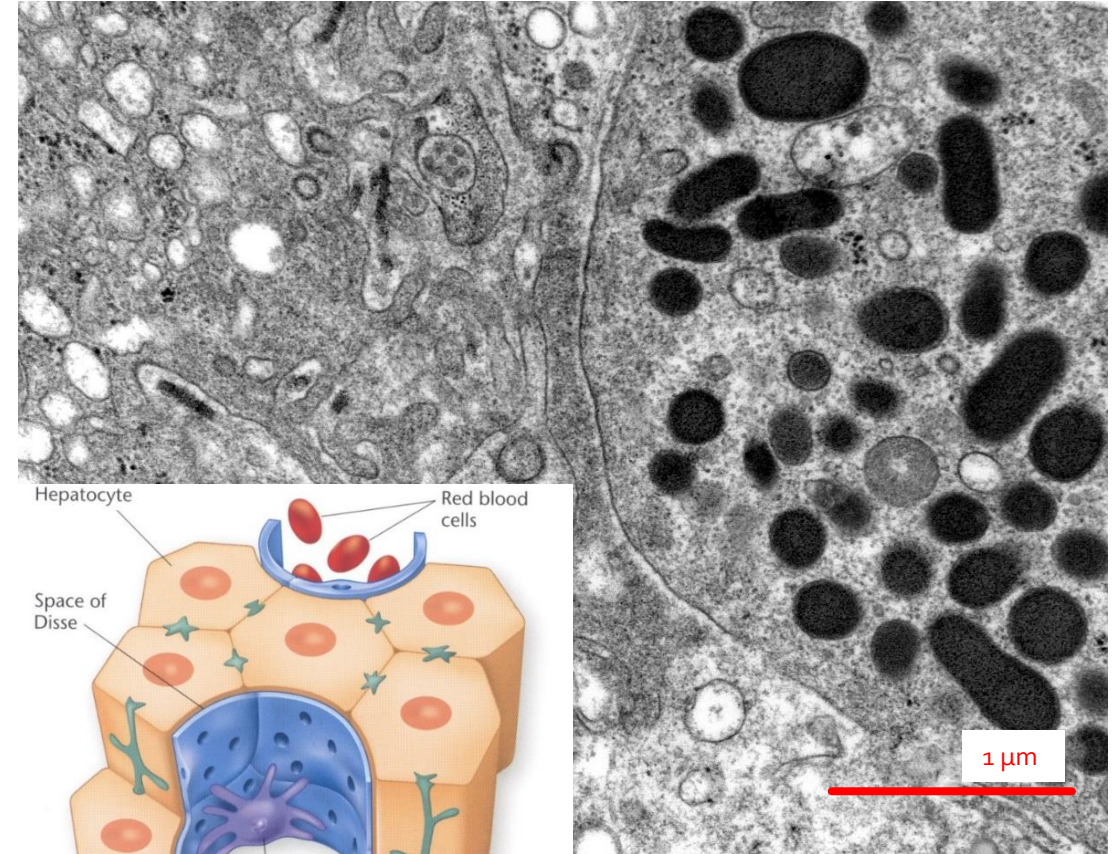
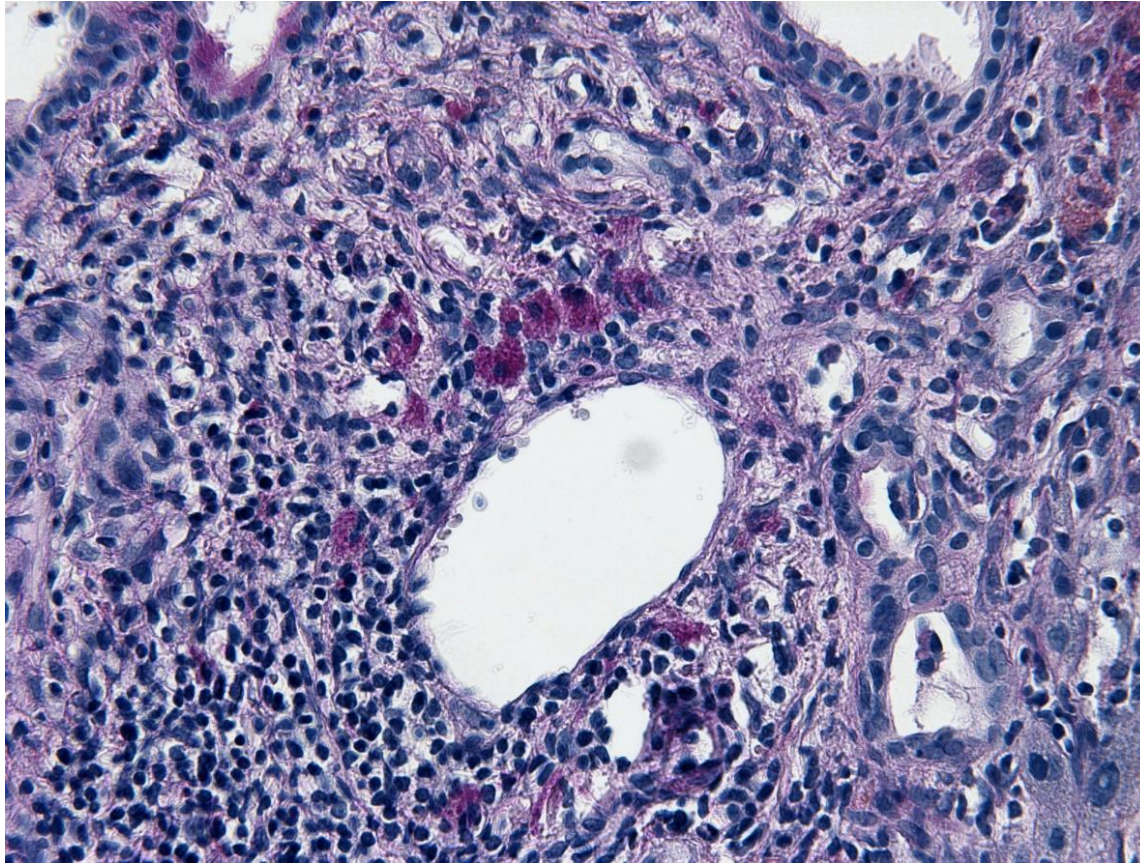
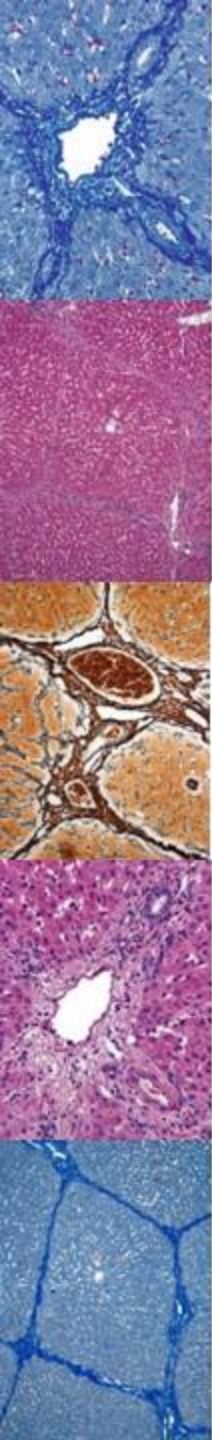
MIKROSKOPICKÁ STAVBA JATER

Detail jaterního parenchymu



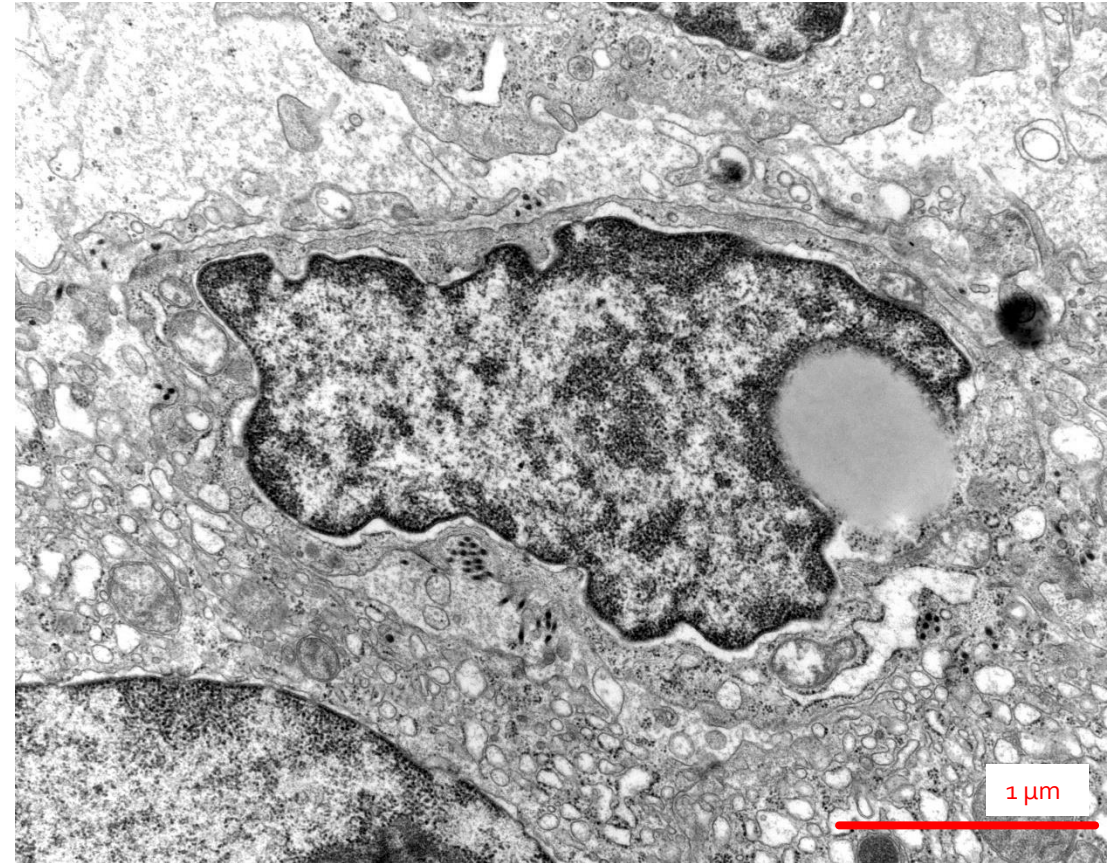
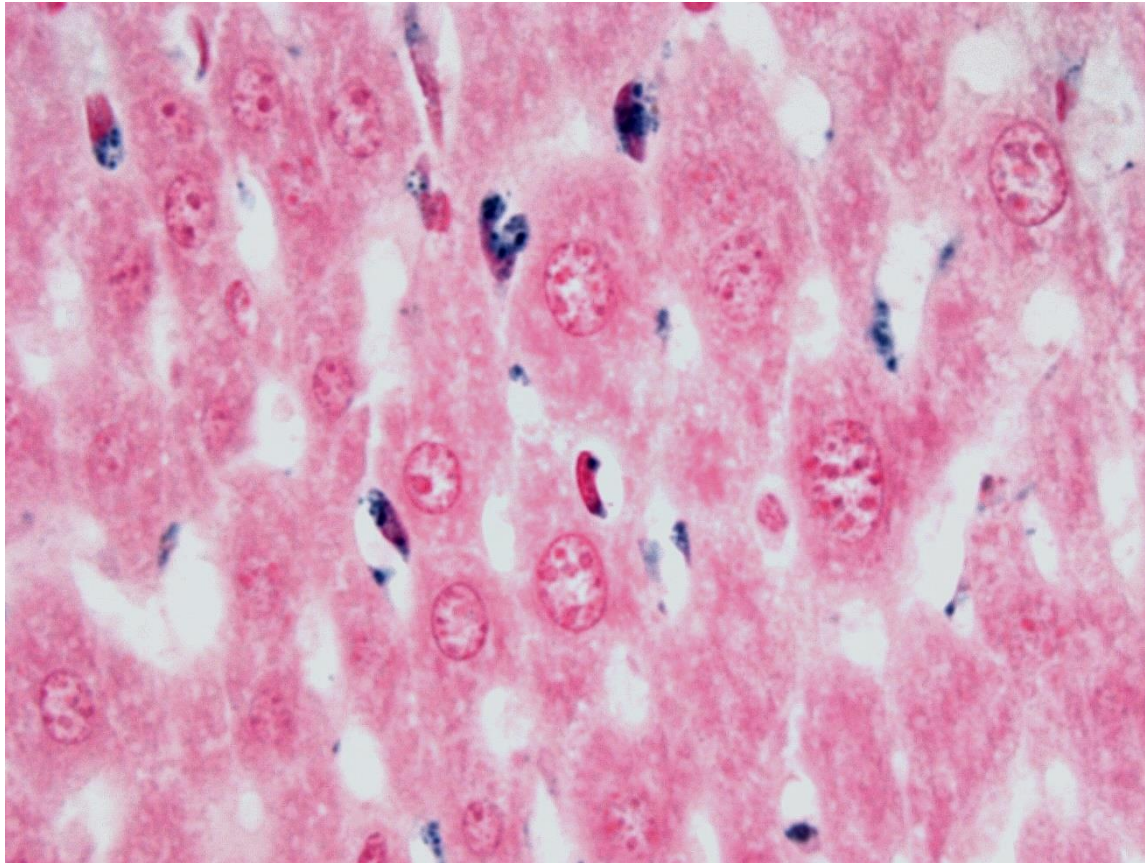
MIKROSKOPICKÁ STAVBA JATER

Detail jaterního parenchymu – Kupfferovy buňky



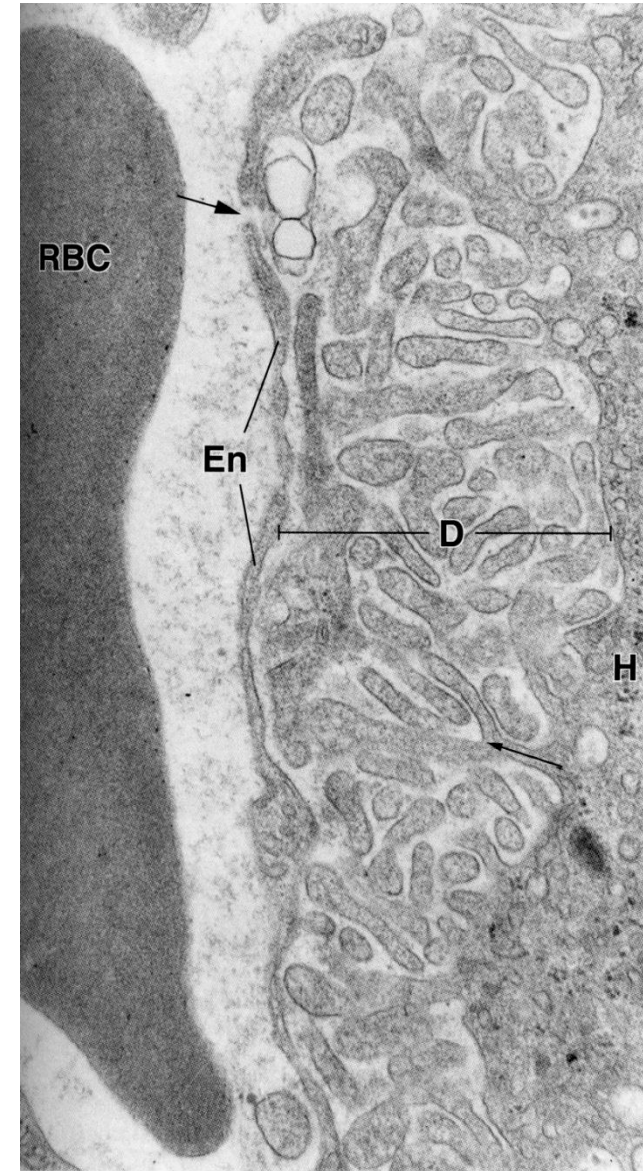
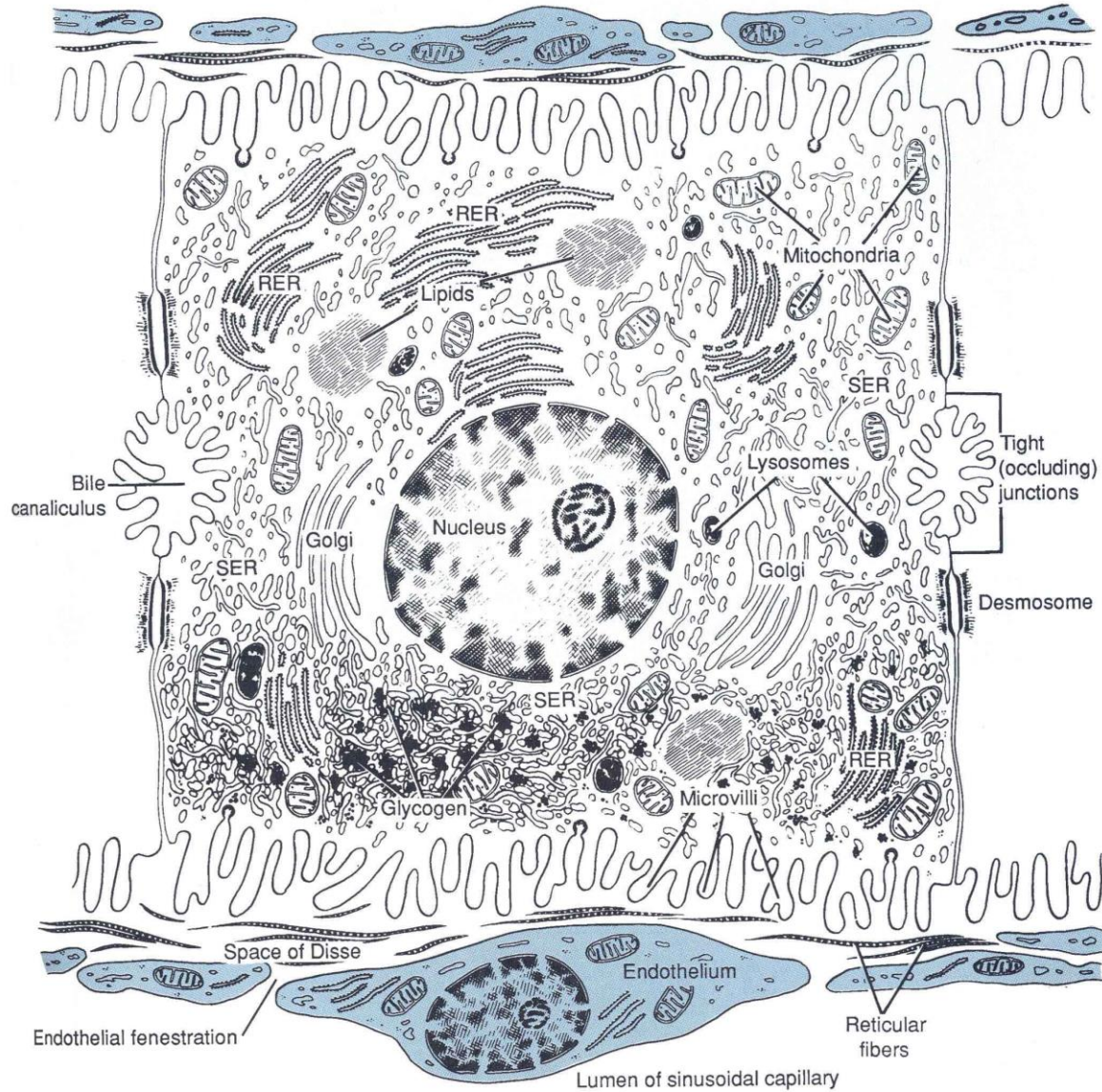
MIKROSKOPICKÁ STAVBA JATER

Detail jaterního parenchymu – Itoovy buňky



MIKROSKOPICKÁ STAVBA JATER

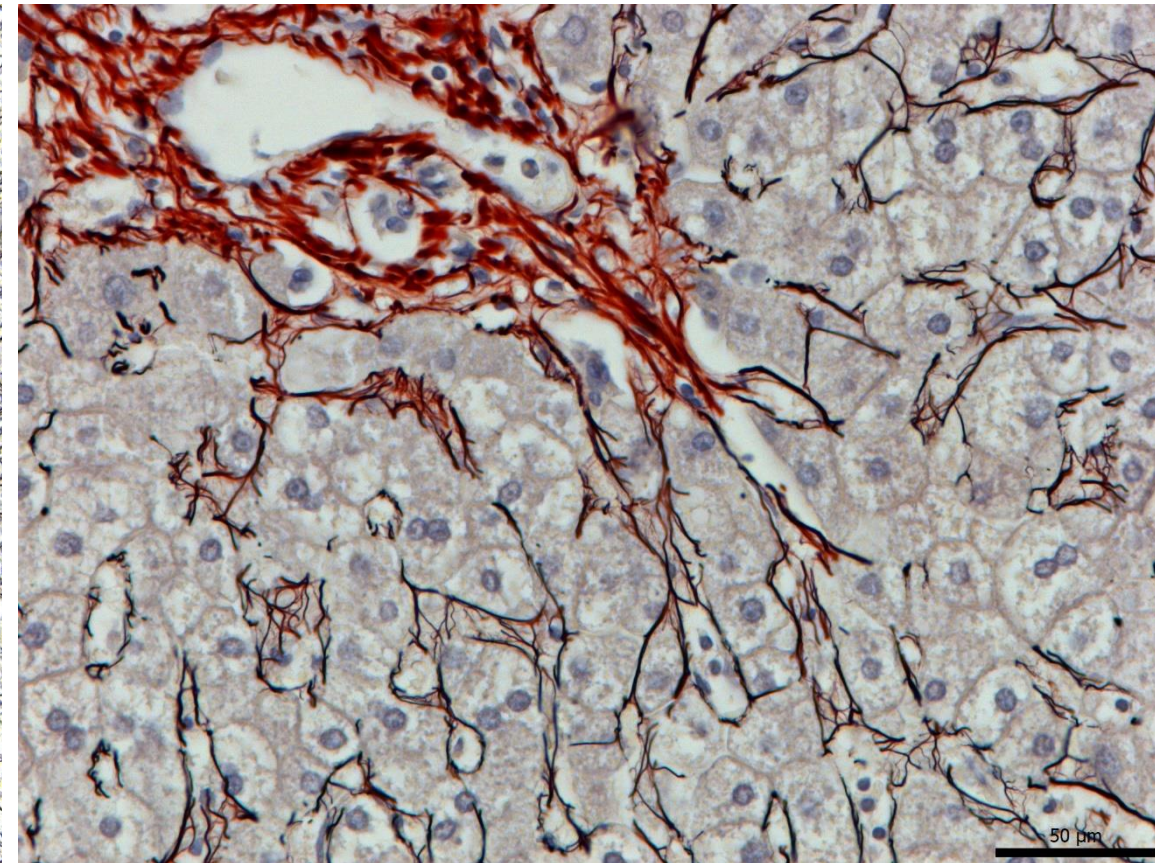
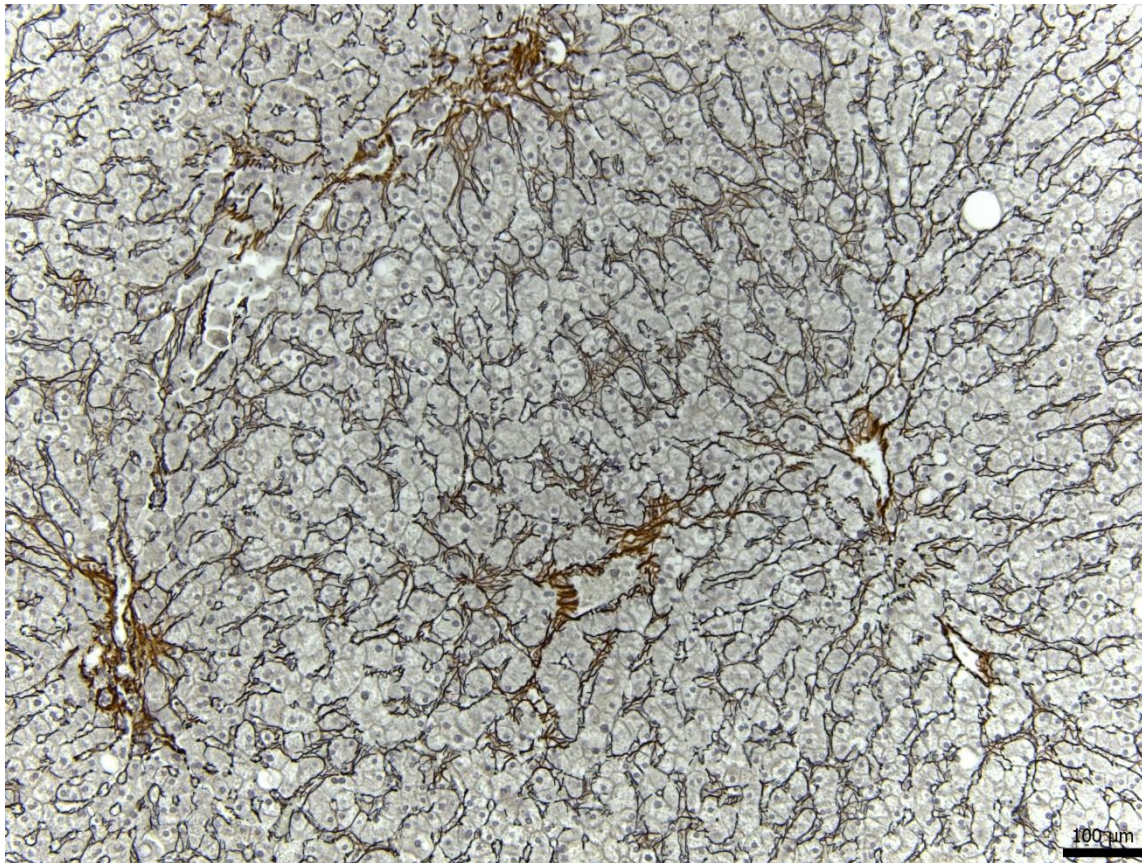

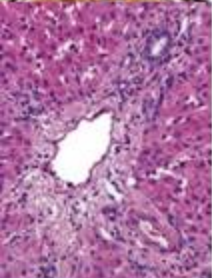
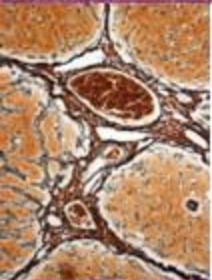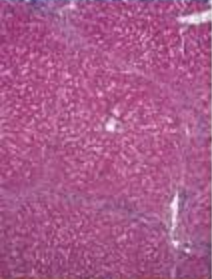
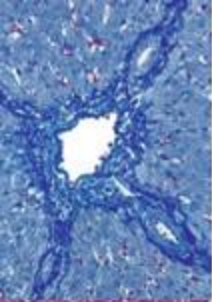
Detail jaterního parenchymu – Disseho prostor



Pawlina, W.: Histology. A Text and Atlas, Wolters Kluwer 2016

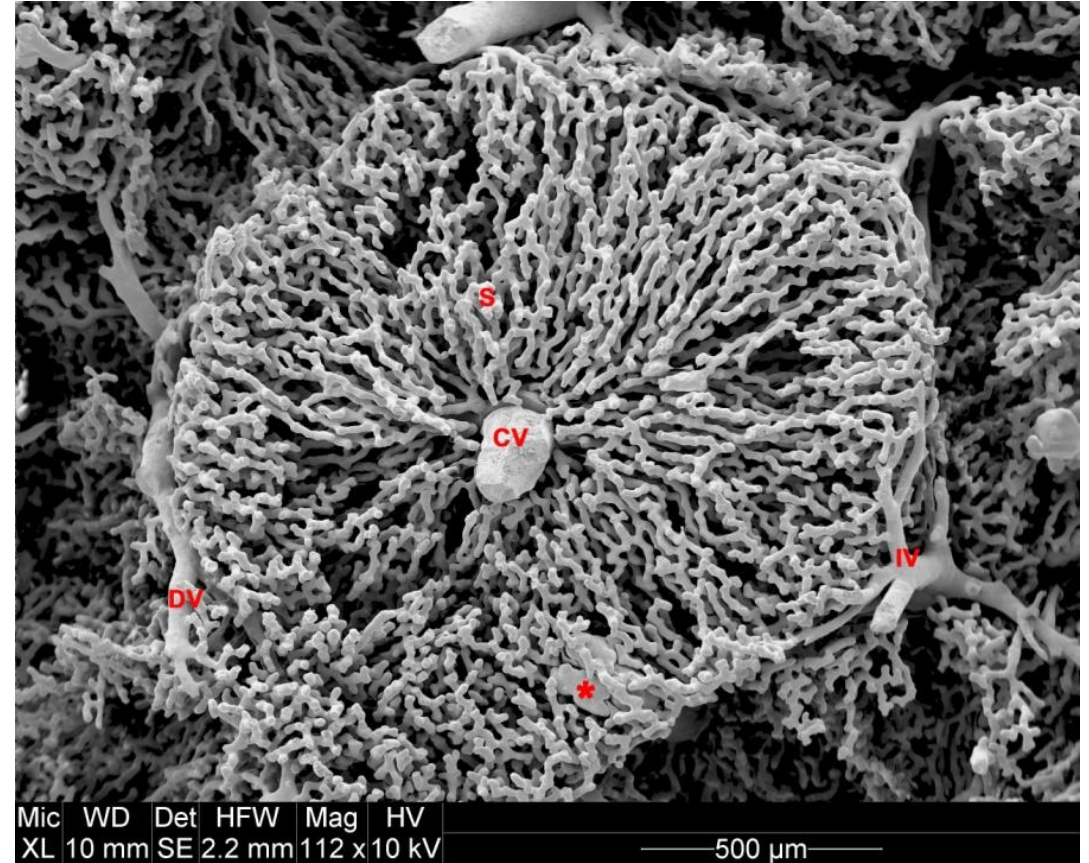
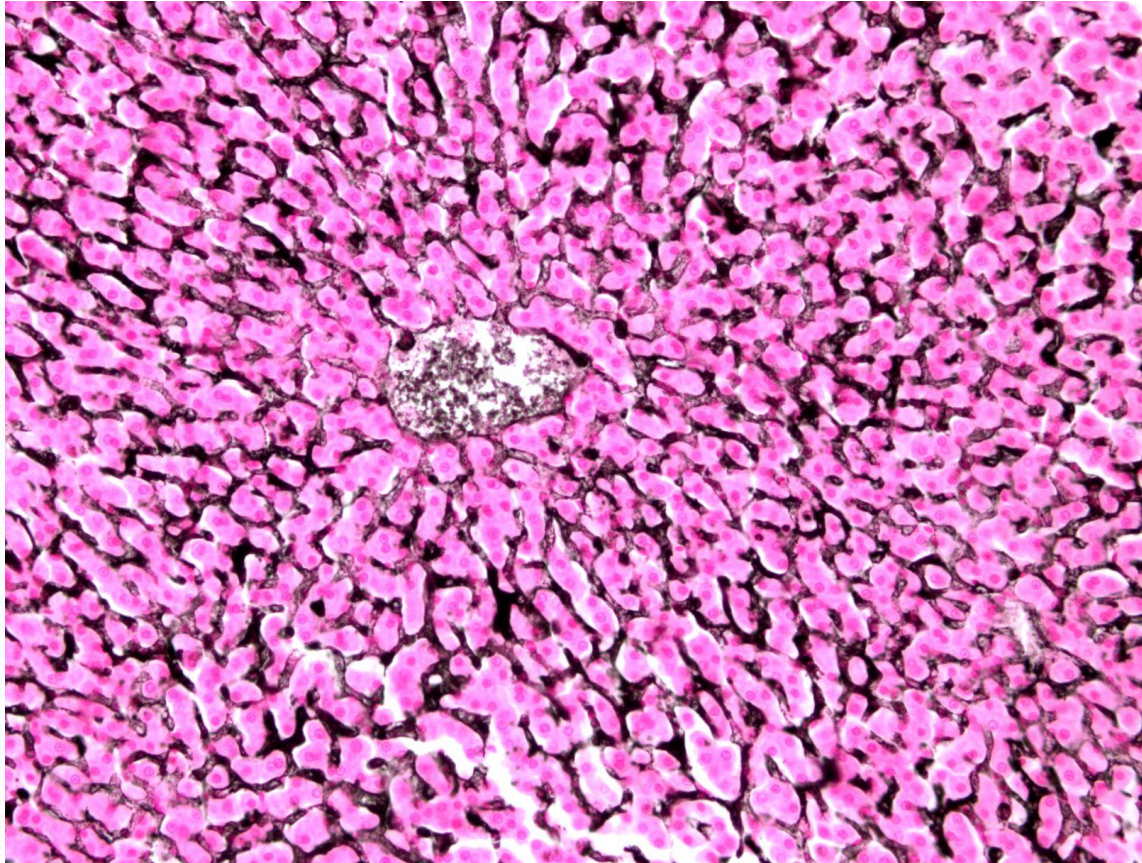
MIKROSKOPICKÁ STAVBA JATER

Detail jaterního parenchymu – Disseho prostor, retikulární vlákna



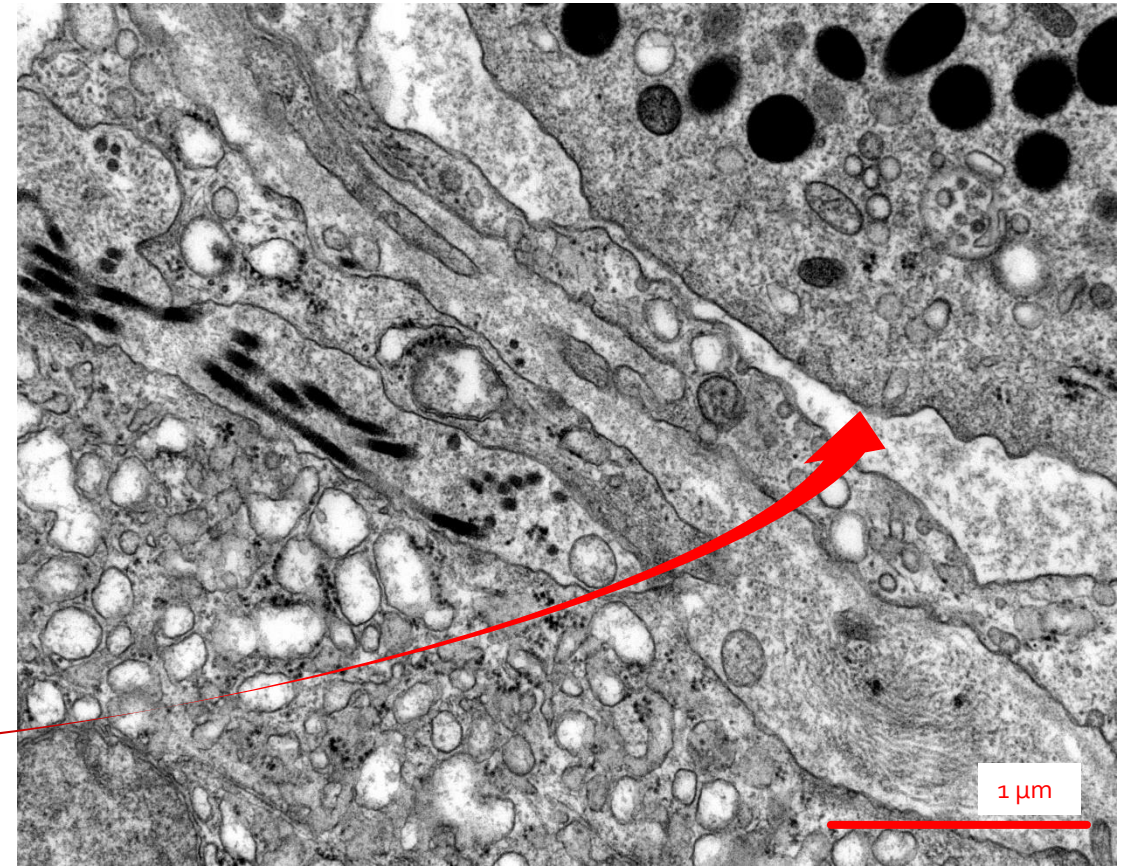
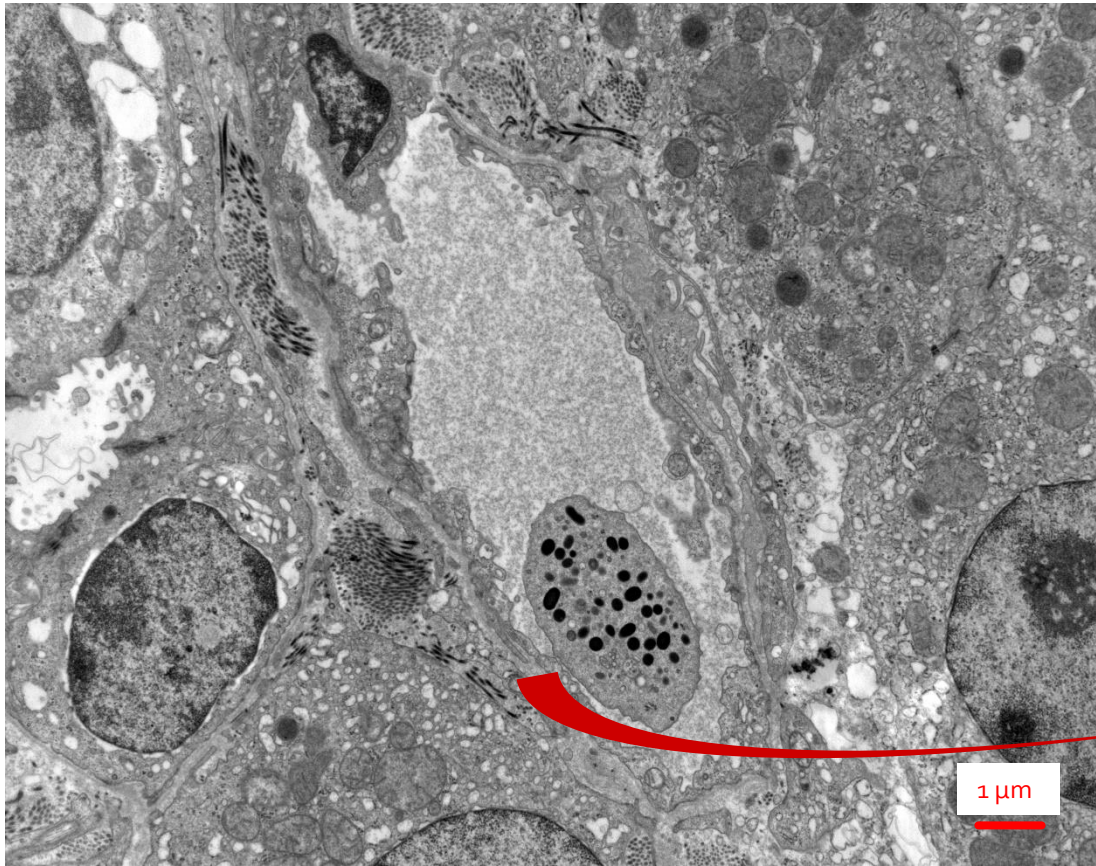
MIKROSKOPICKÁ STAVBA JATER

Detail jaterního parenchymu – jaterní sinusoidy



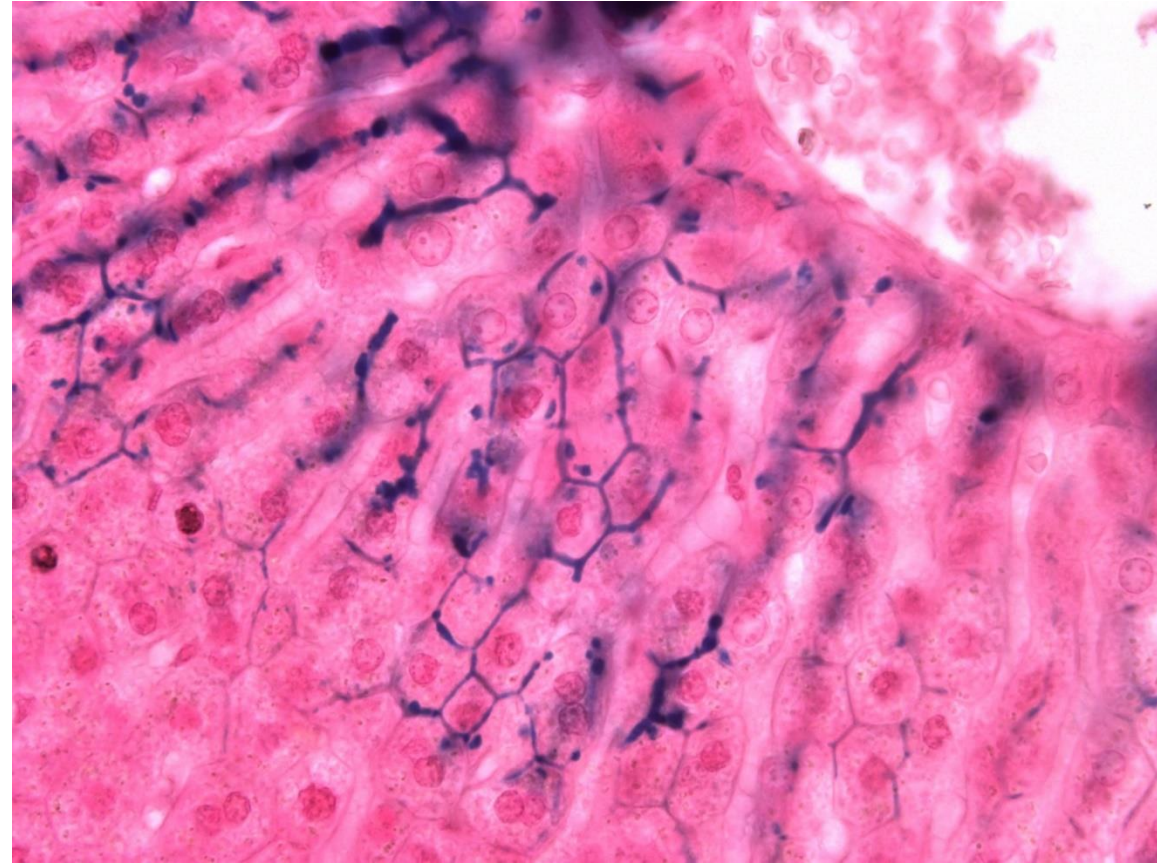
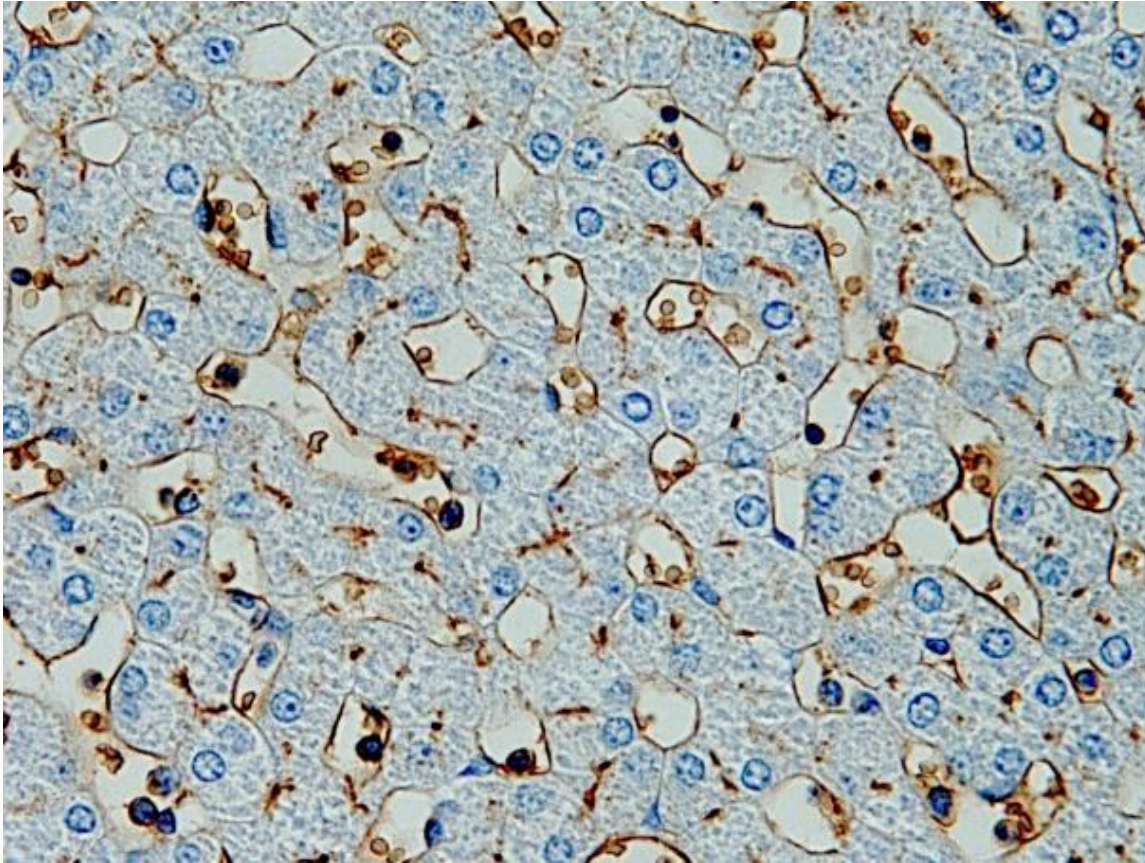

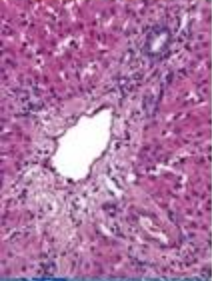
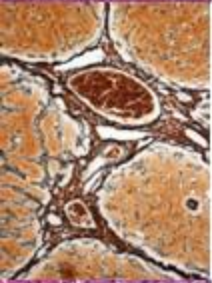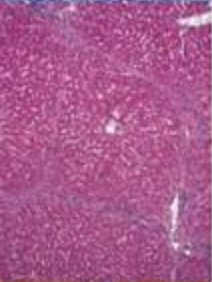
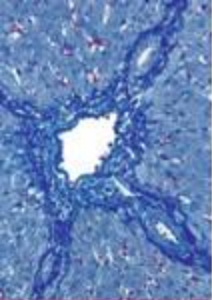
MIKROSKOPICKÁ STAVBA JATER

Detail jaterního parenchymu – jaterní sinusoidy



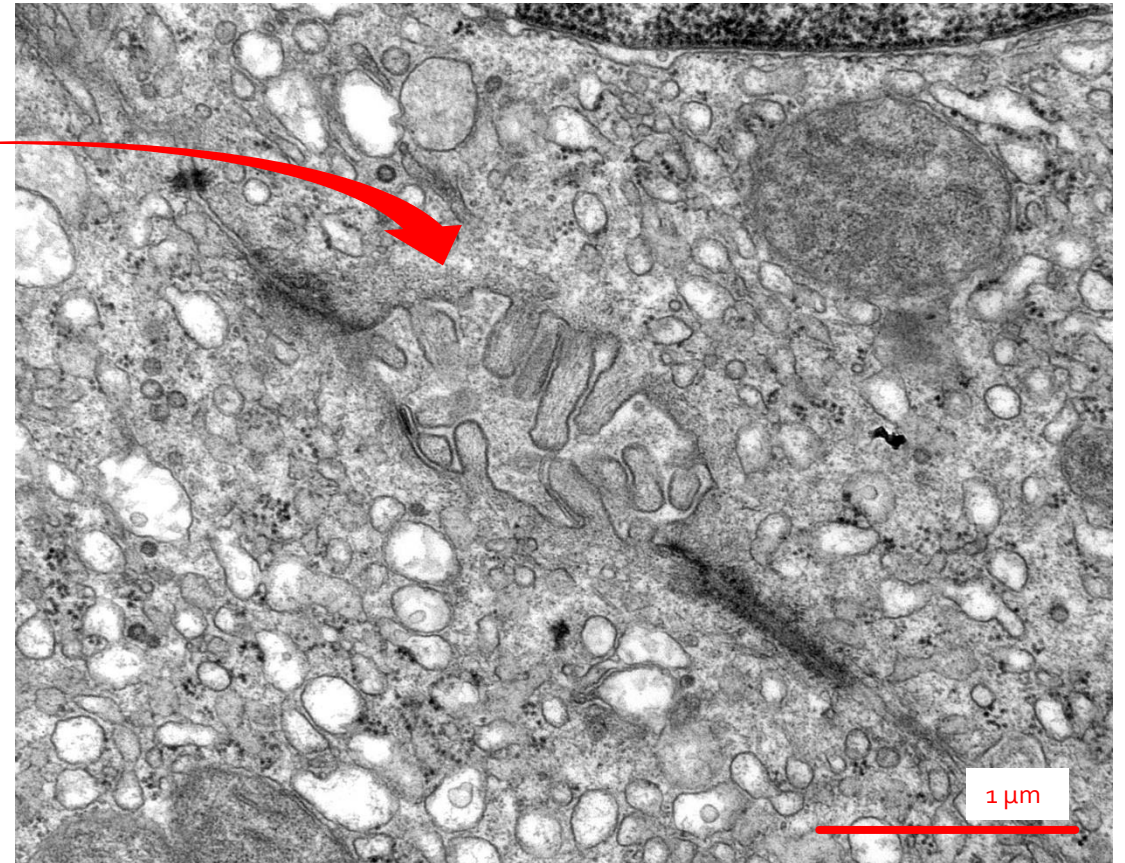
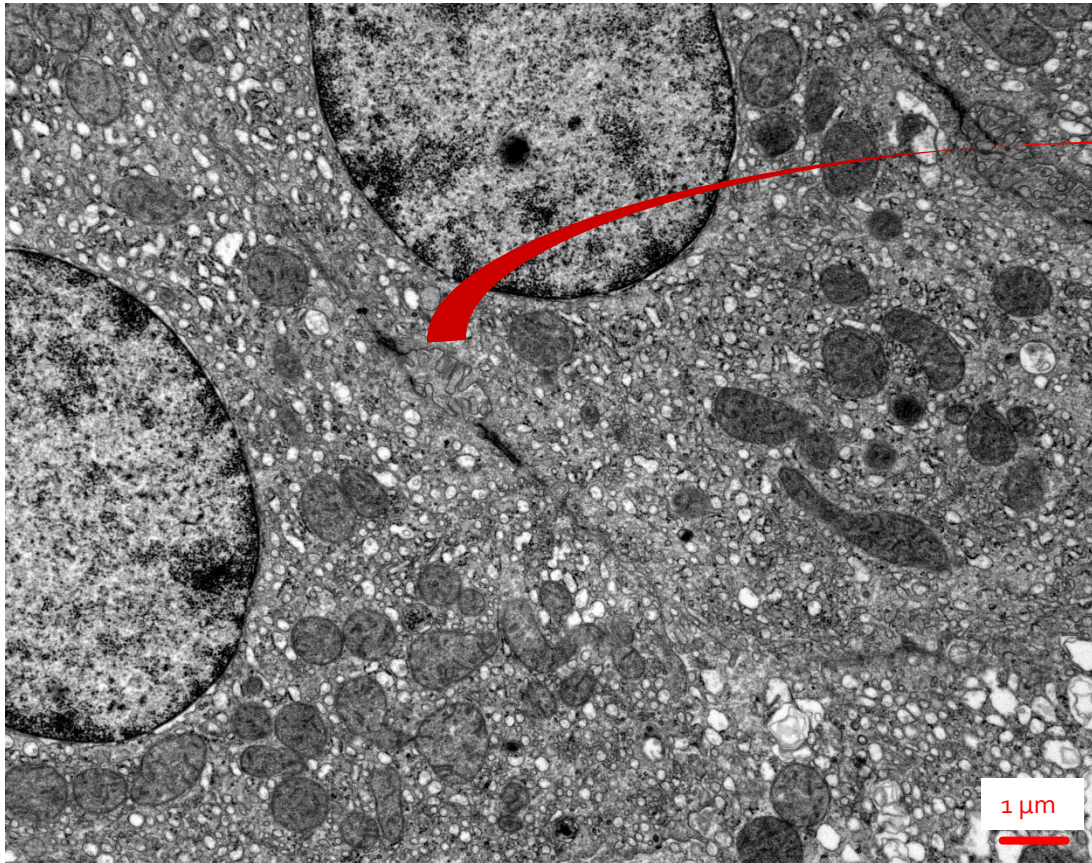
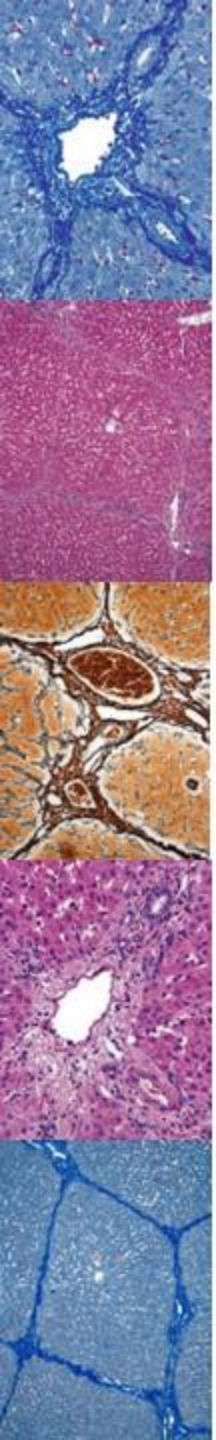
MIKROSKOPICKÁ STAVBA JATER

Detail jaterního parenchymu – canaliculi biliferi



MIKROSKOPICKÁ STAVBA JATER

Detail jaterního parenchymu – canaliculi biliferi



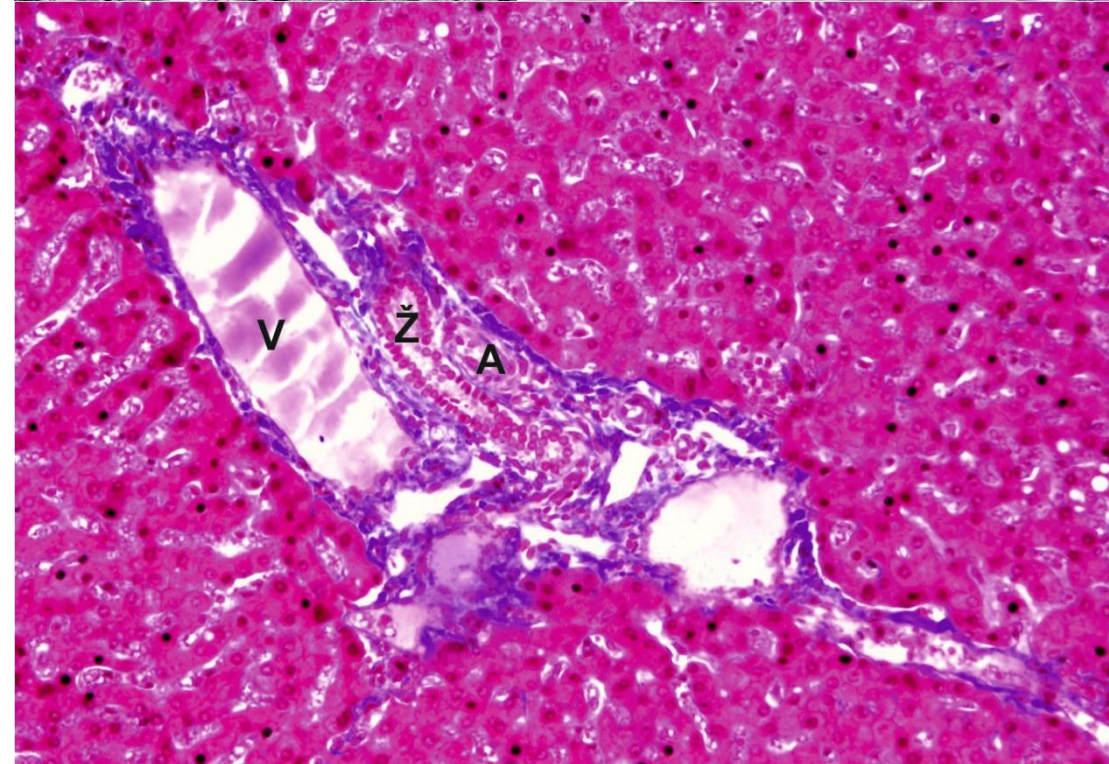
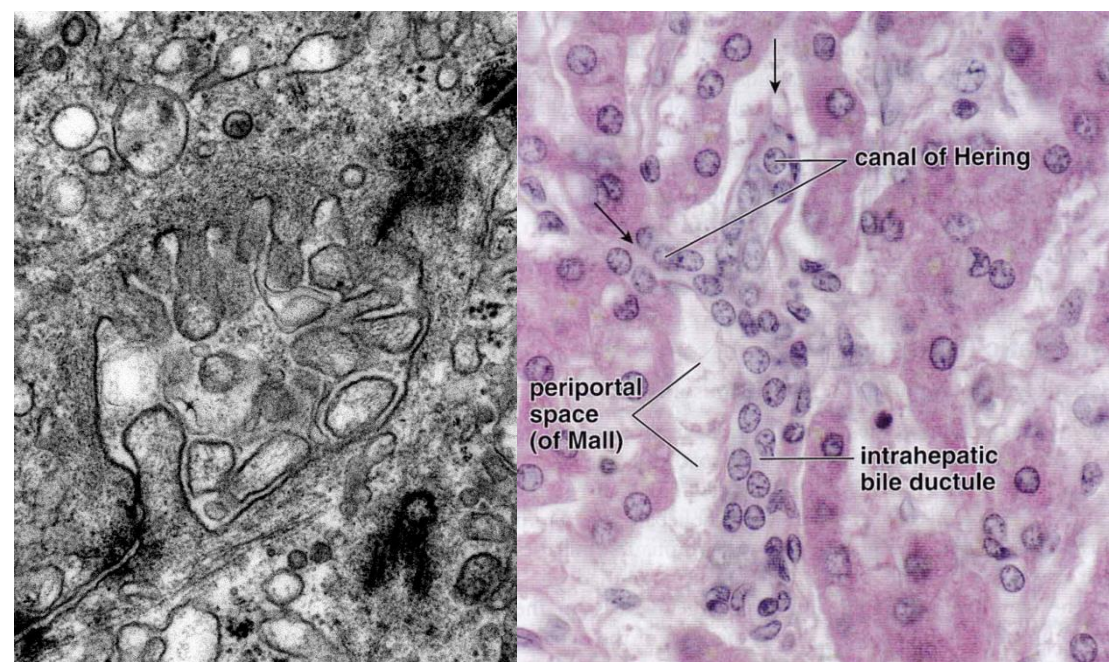
ŽLUČOVÉ CESTY

Intrahepatální

- **Canaliculi biliferi**
 - Membrány přilehlých hepatocytů
- **Canales biliferi = Heringovy kanálky**
 - Vlastní epitelová výstelka
- **Ductus biliferi interlobulares**
 - Trias hepatica
- **Ductus hepaticus dexter at sinister**

Extrahepatální

- **Ductus hepaticus dexter et sinister**
 - Vystupují v *porta hepatis*
- **Ductus hepaticus communis**
 - Spojení předchozích
- **Ductus cysticus**
 - Vývod žlučníku
- **Ductus choledochus**
 - Ústí do duodena na *papilla duodeni major*



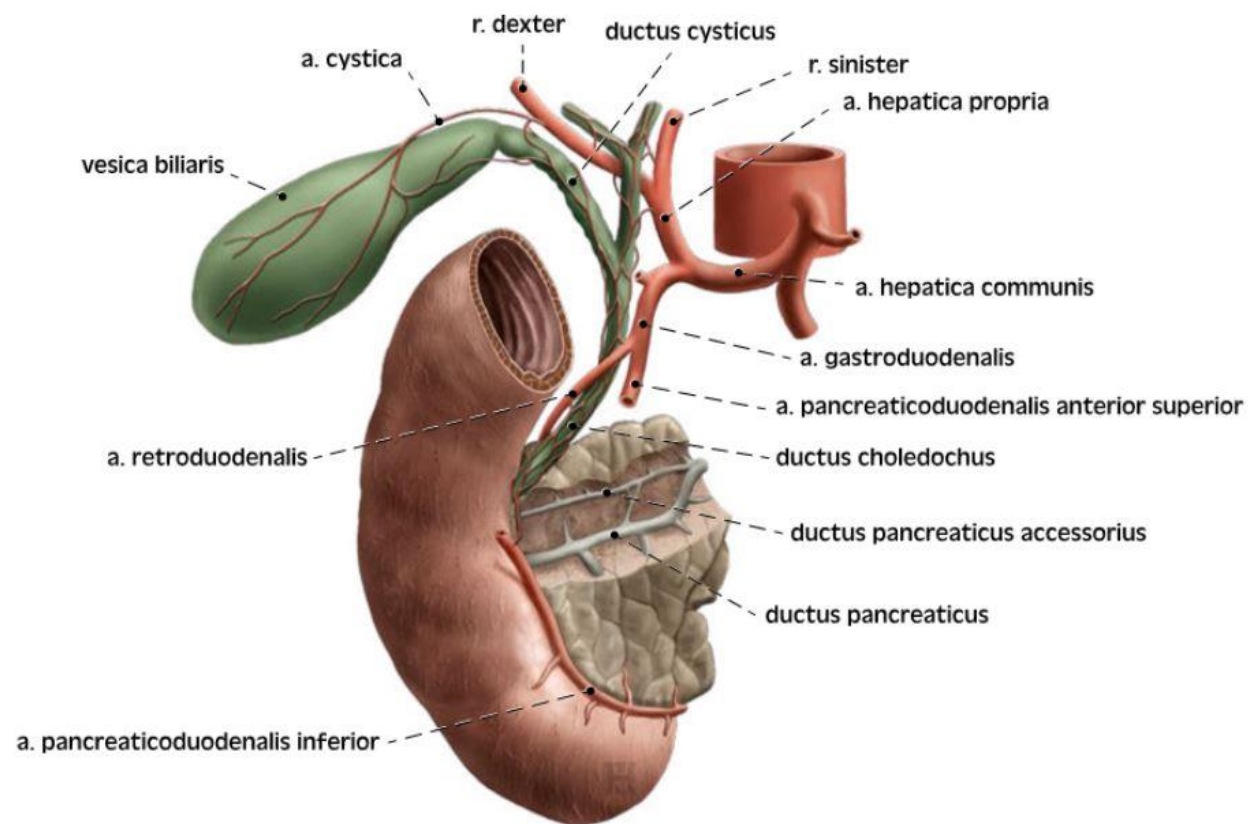
ŽLUČOVÉ CESTY

Intrahepatální

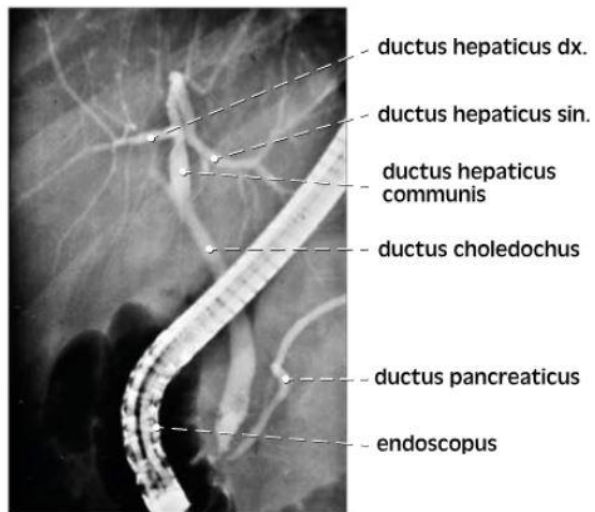
- **Canaliculi biliferi**
 - Membrány přilehlých hepatocytů
- **Canales biliferi = Heringovy kanálky**
 - Vlastní epitelová výstelka
- **Ductus biliferi interlobulares**
 - Trias hepatica
- **Ductus hepaticus dexter at sinister**

Extrahepatální

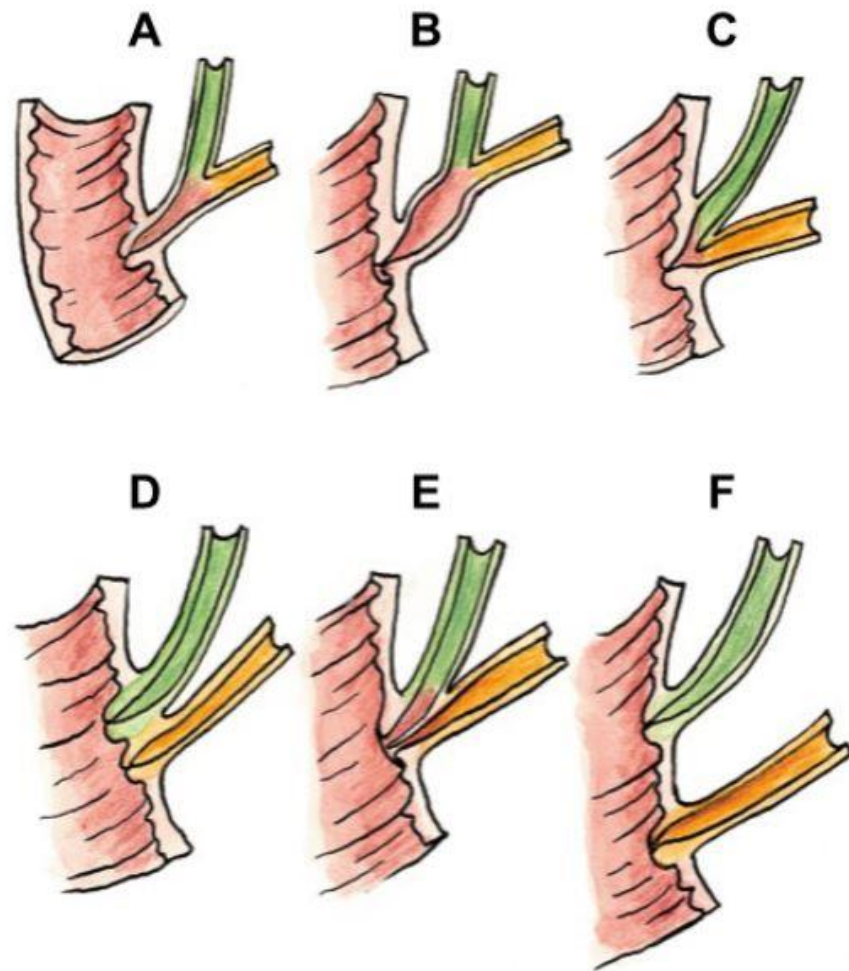
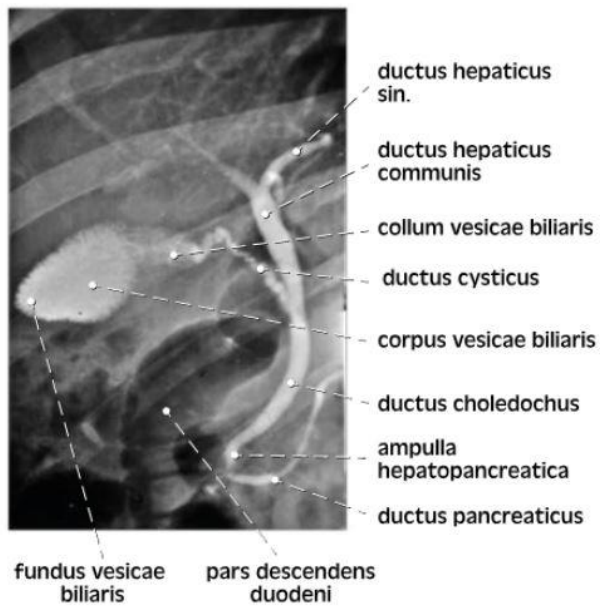
- **Ductus hepaticus dexter et sinister**
 - Vystupují v *porta hepatis*
- **Ductus hepaticus communis**
 - Spojení předchozích
- **Ductus cysticus**
 - Vývod žlučníku
- **Ductus choledochus**
 - Ústí do duodena na *papilla duodeni major*



EXTRAHEPATÁLNÍ ŽLUČOVÉ CESTY



b



Obr. 105. VARIACE ZPŮSOBU VYÚSTĚNÍ DUCTUS CHOLEDOCHUS A DUCTUS PANCREATICUS NA PAPILLA DUODENI MAJOR; schema

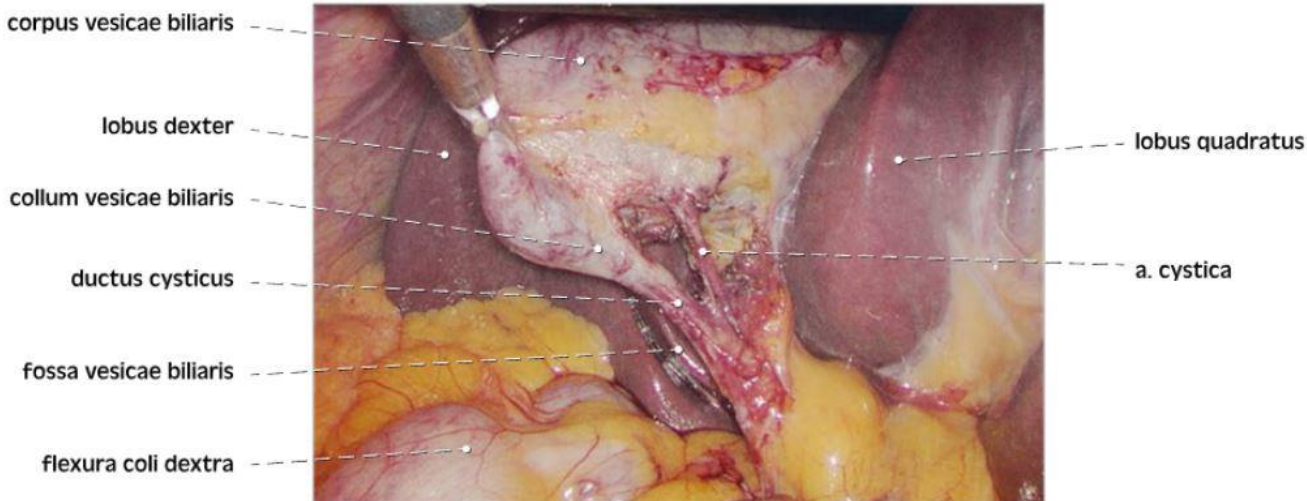
A–C formy společného vústění
 B rozšířená ampulla hepatopancreatica
 D–F formy odděleného vústění

Čihák R, Anatomie 2, Druhé, upravené a doplněné vydání, Grada, 2002

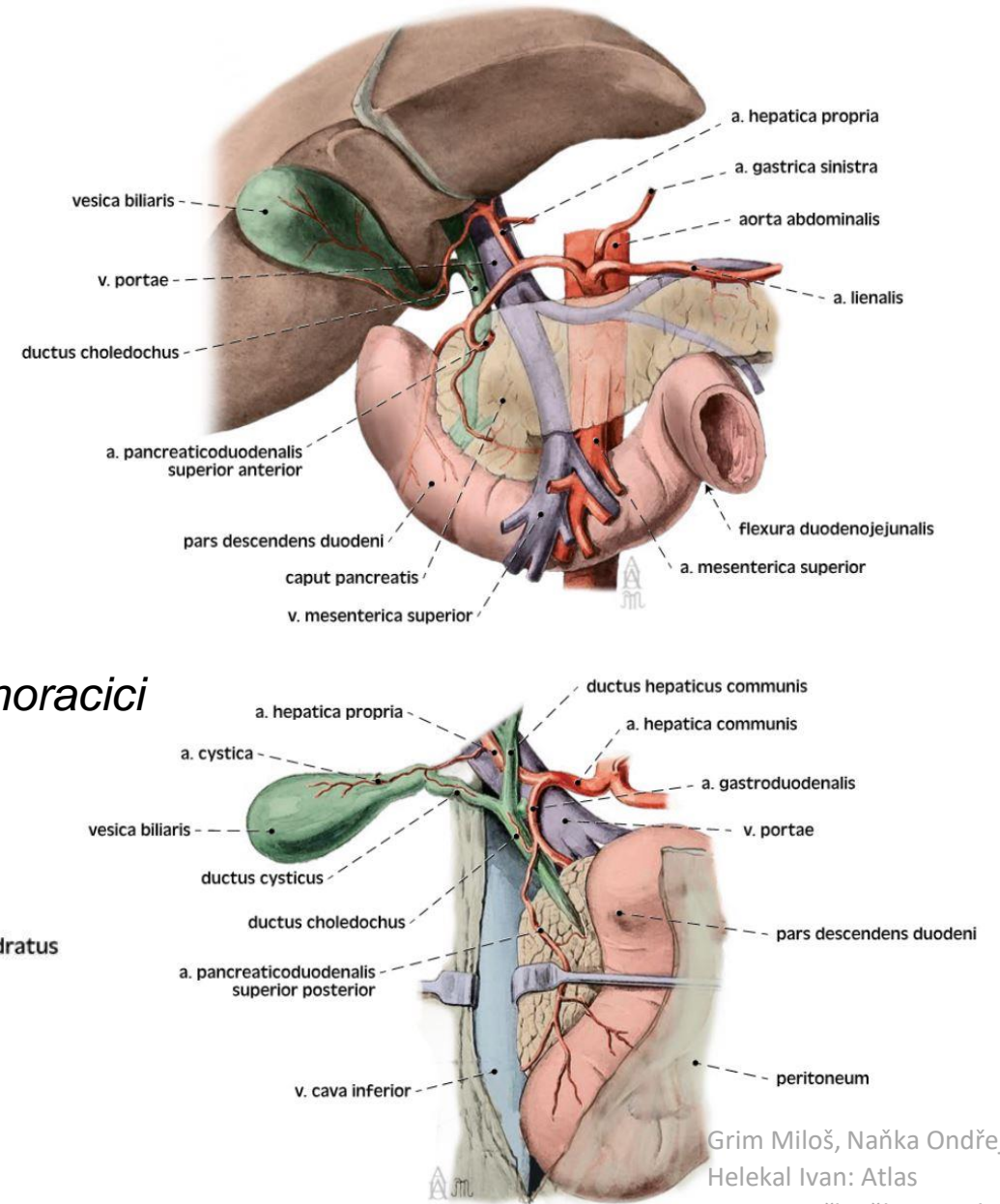
Grim Miloš, Naňka Ondřej,
 Helekal Ivan: Atlas
 anatomie člověka I. - Atlas
 of Human Anatomy I. ISBN:
 978-80-247-4012-6, Grada

STAVBA ŽLUČNÍKU

- intraperitoneální orgán
 - široce přisedlý k játrům („lůžko žlučníku“)
 - trigonum cystohepaticum *Caloti*
- 7-10 cm, objem 30–50 ml
- **4 části:** fundus, corpus, infundibulum, collum
- **Cévy:** *a. cystica* (z r.dexter a. hepaticae propriae)
v. cystica (do vena portae)
- **Inervace:** *n. vagus* (parasymptikus), *nn. splanchnici thoracici* (sympatikus), *n. phrenicus dexter* (viscerosenzitivita)

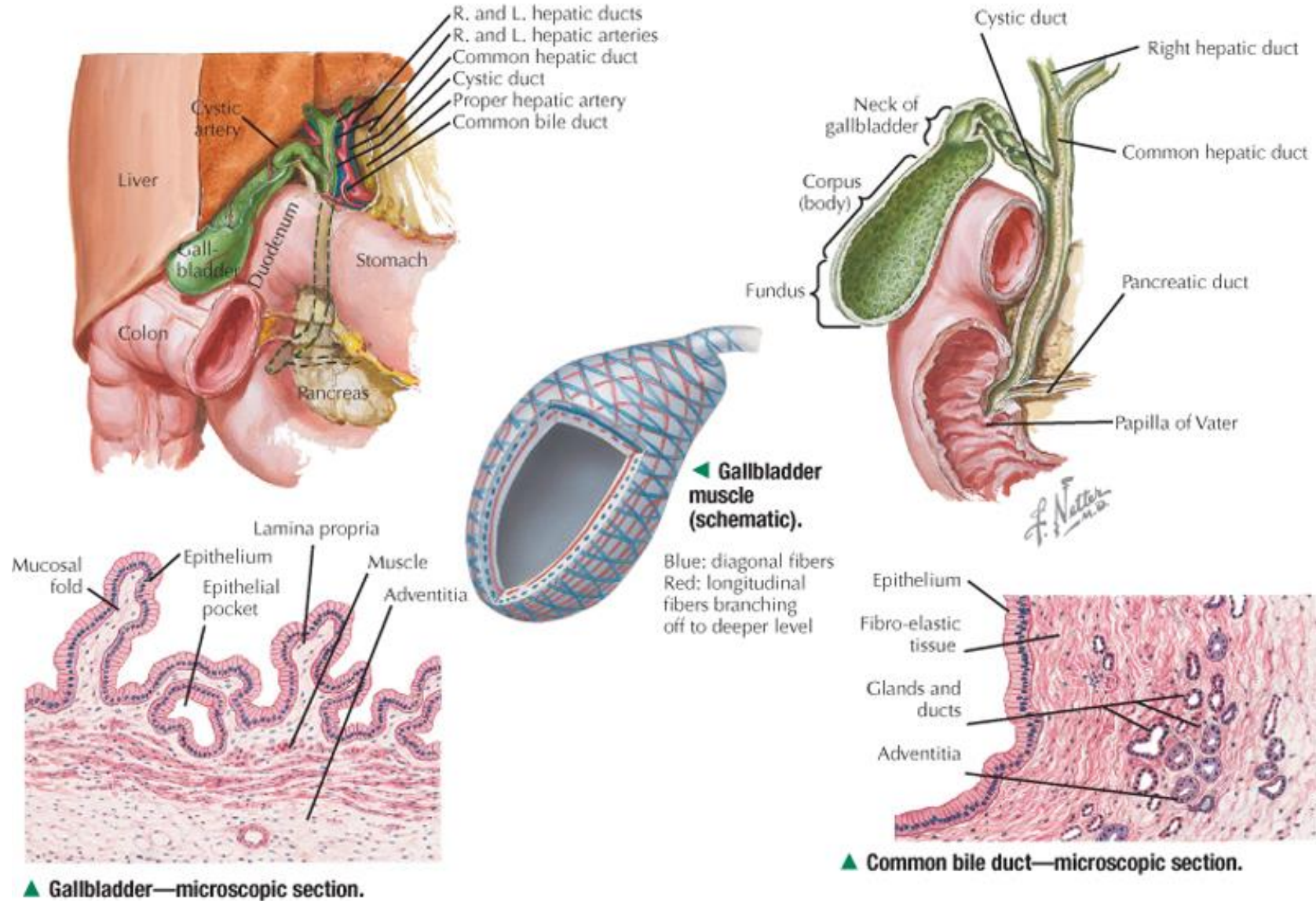


a

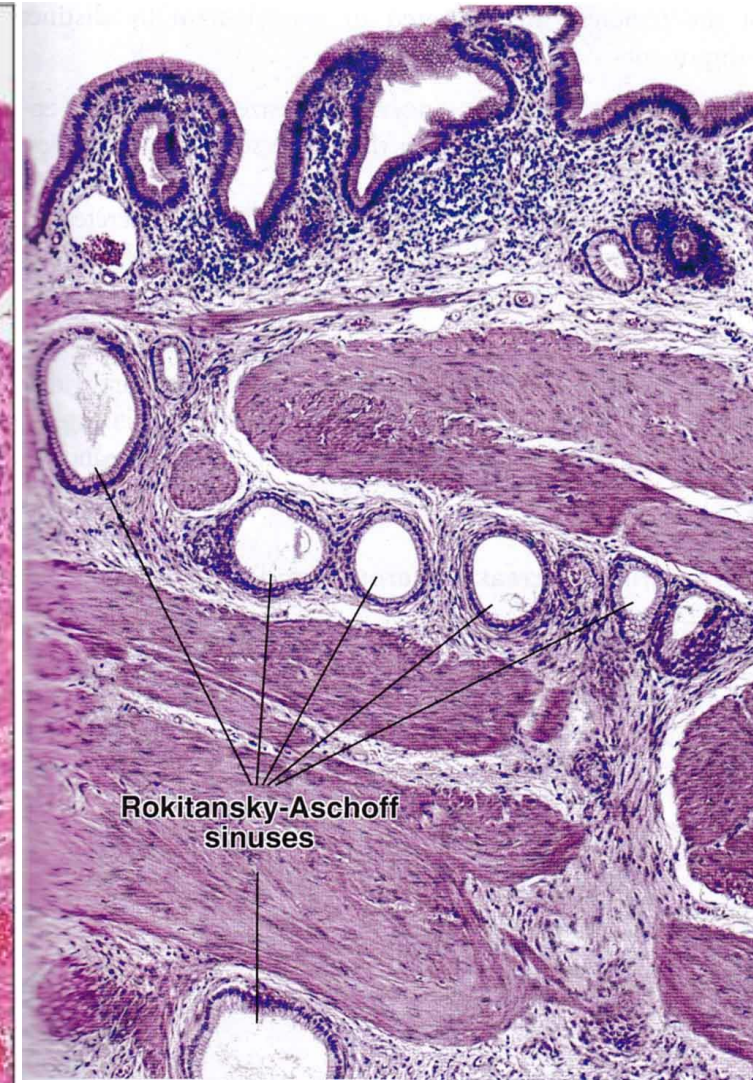
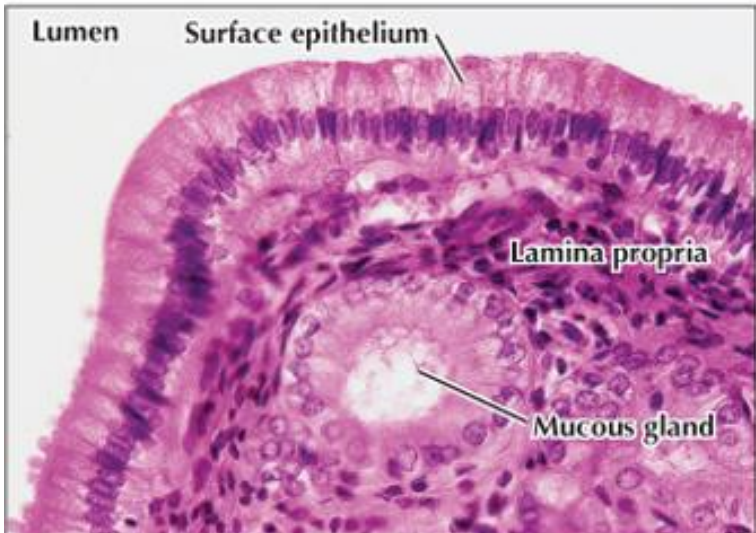
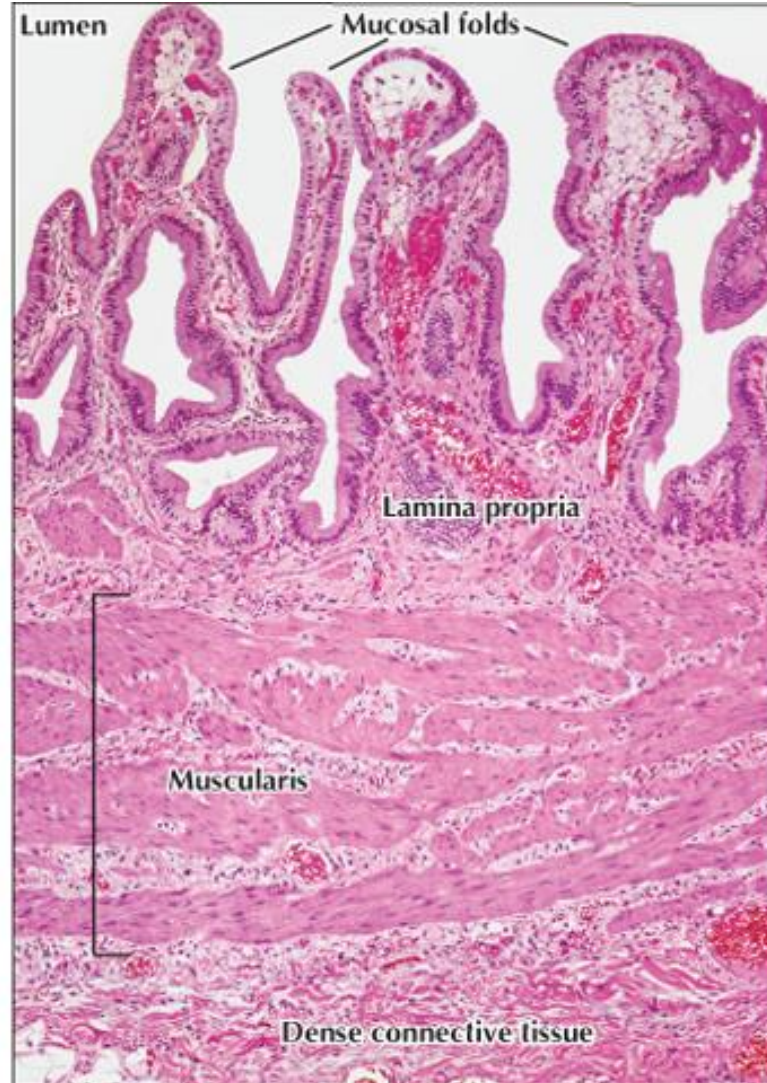
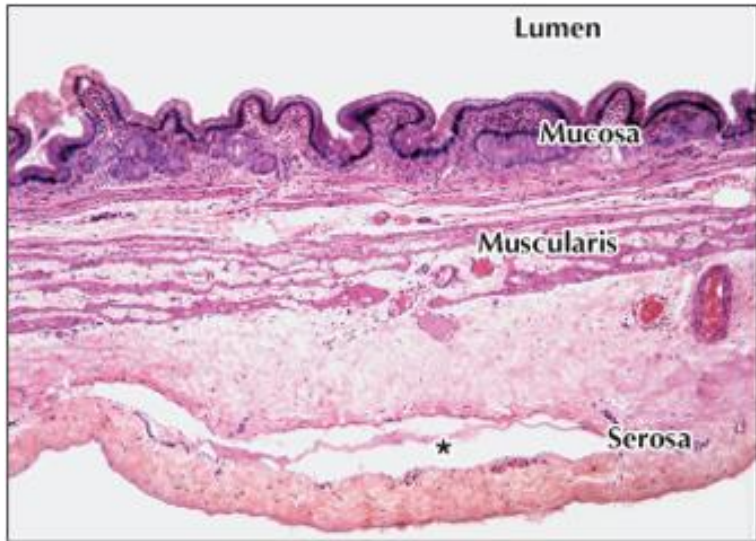


STAVBA ŽLUČNÍKU

▼ Anatomy and histology of the gallbladder and bile ducts.



MIKROSKOPICKÁ STAVBA ŽLUČNÍKU



DĚKUJI VÁM ZA POZORNOST

Anna Malečková

anna.maleckova@lfp.cuni.cz