

Trávicí ústrojí

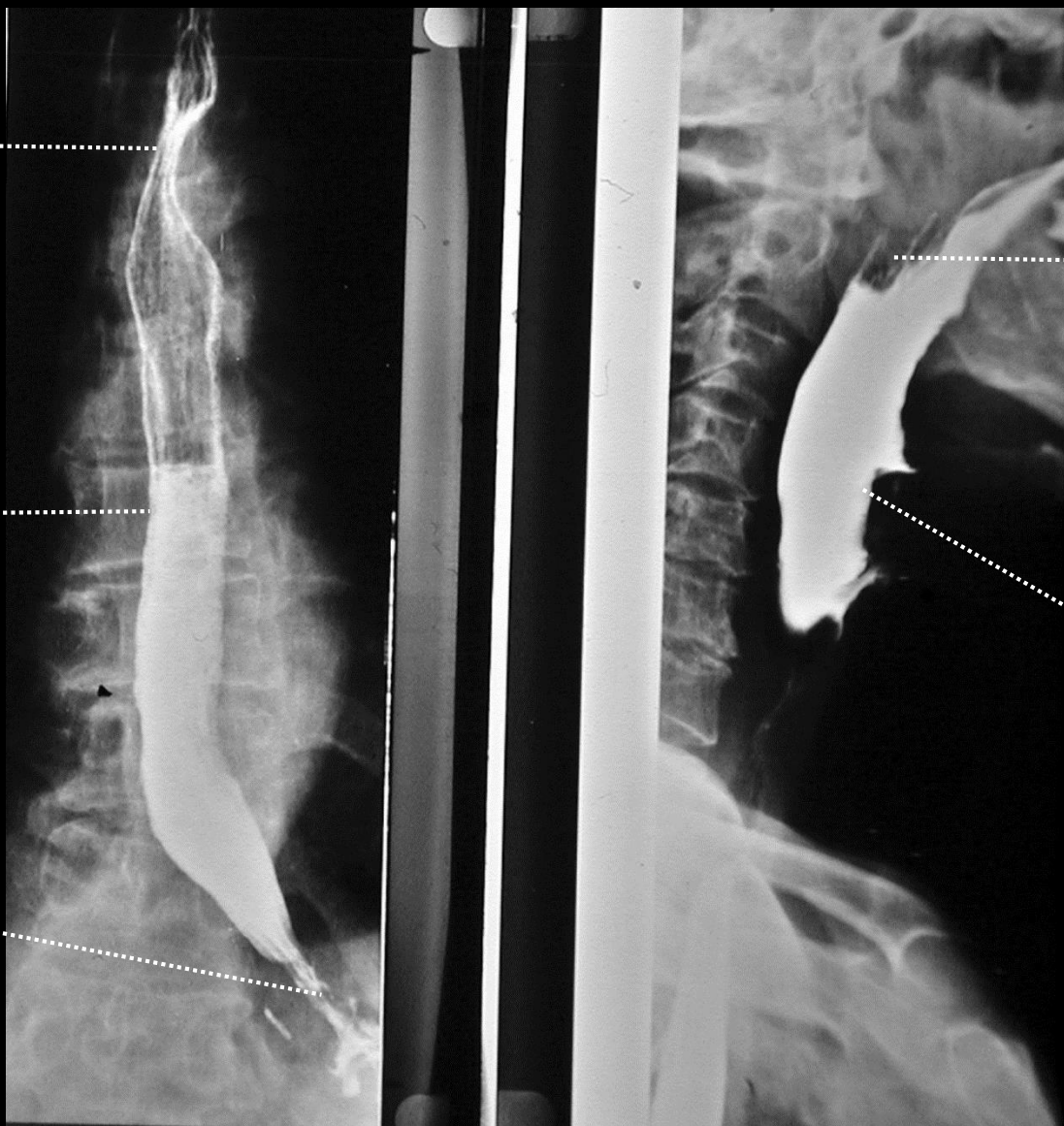Gastrointestinal
system

Jícen – polykací akt (náplň kontrastní látkou)
Oesophagus – X ray (filled with the contrast medium)

constrictio
partis thoracicae
(bronchoaortica)

pars thoracica
oesophagei

constrictio
phrenica



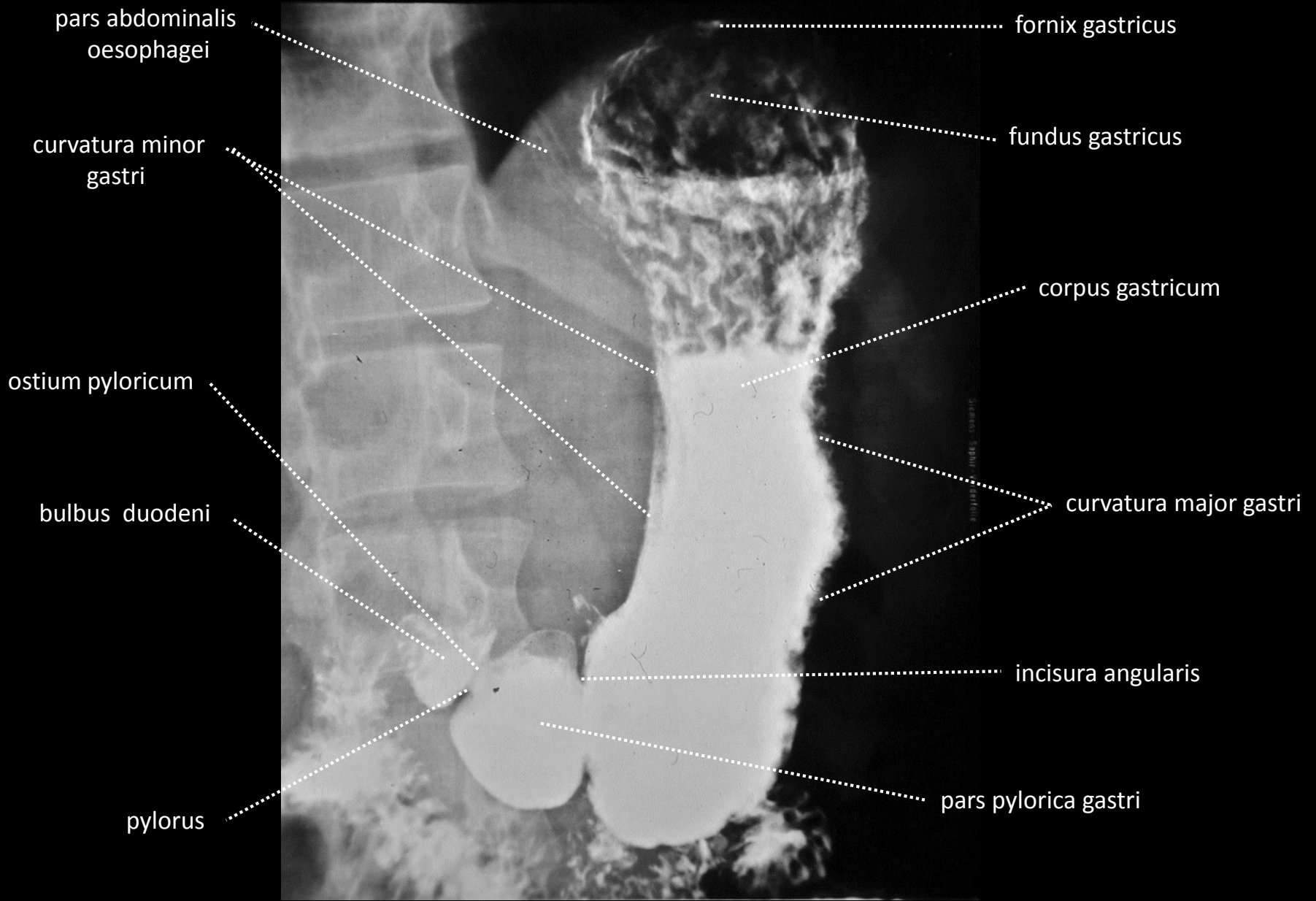
pharynx

pars cervicalis
oesophagei

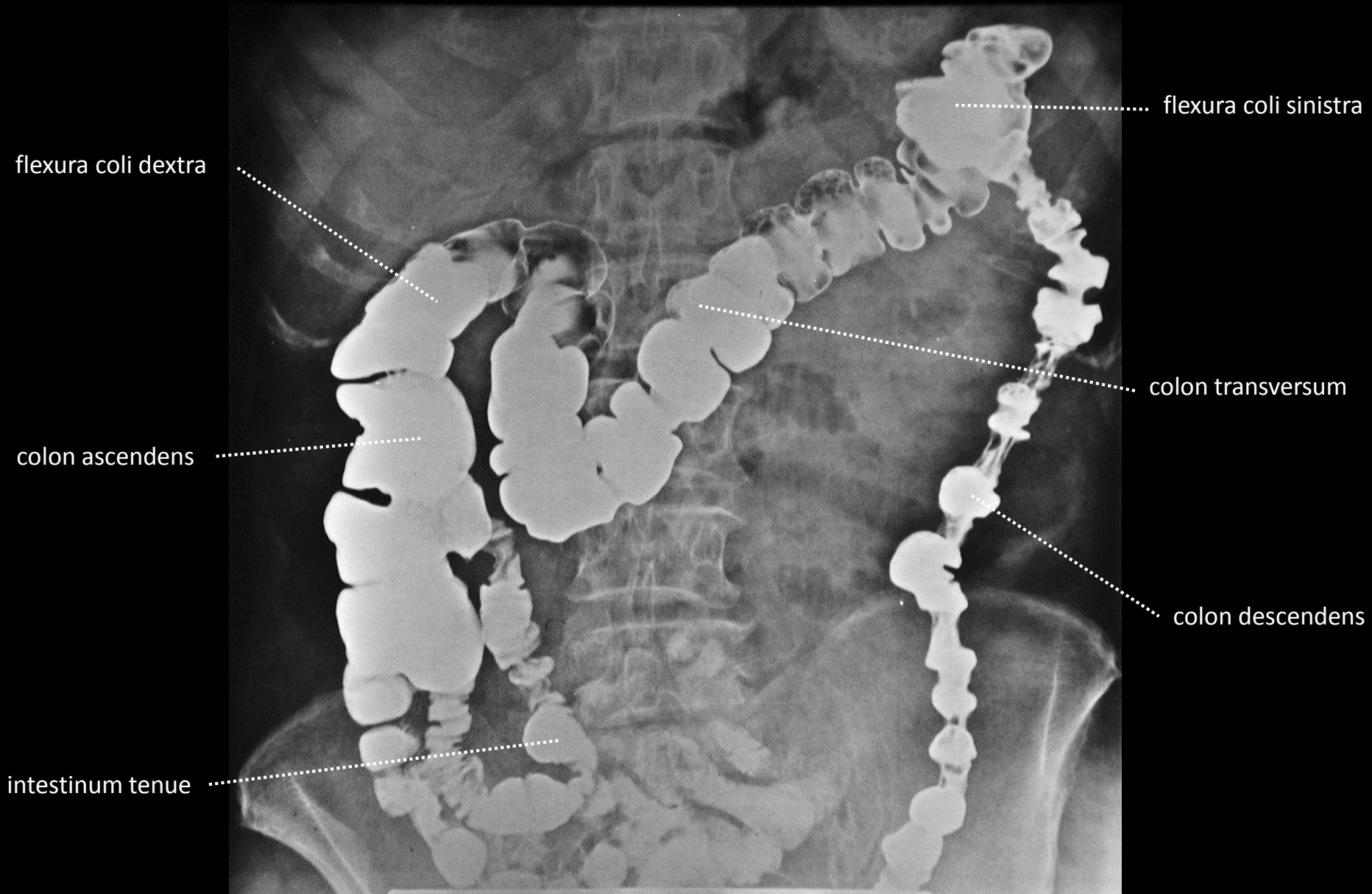
předožadní projekce / anteroposterior projection

boční projekce / lateral projection

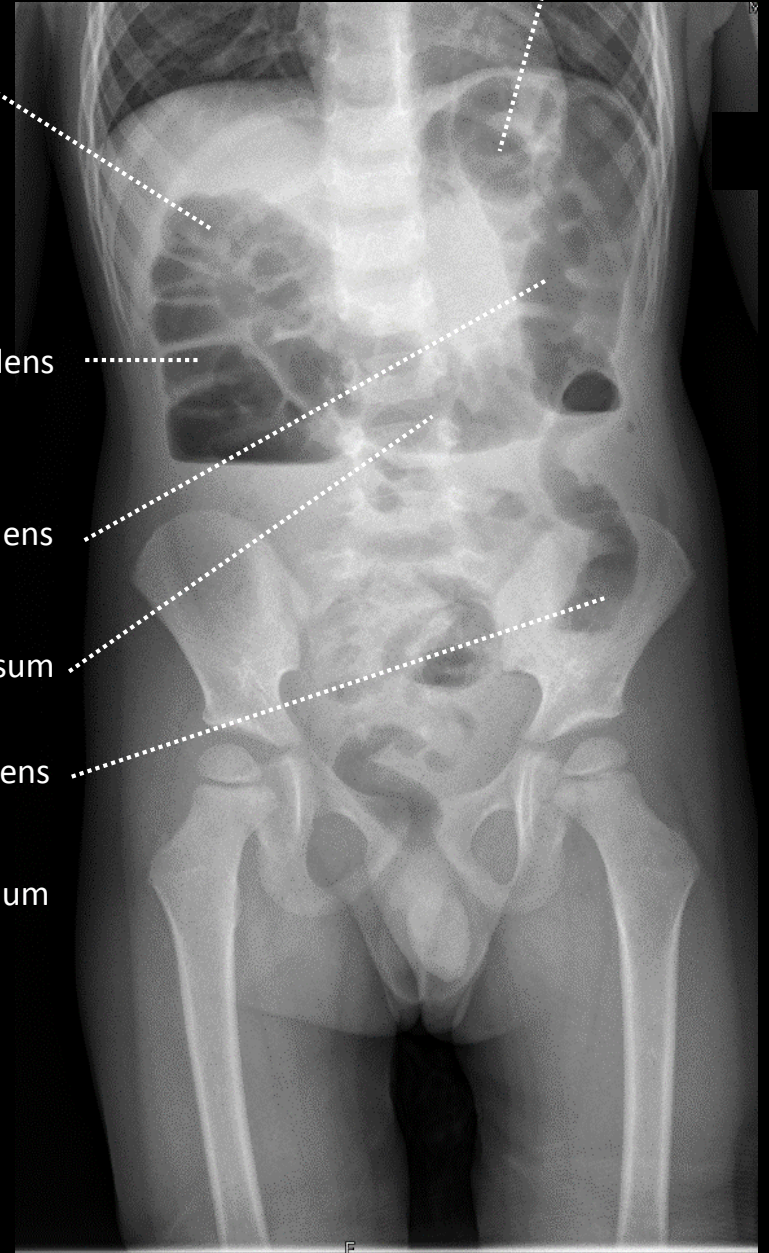
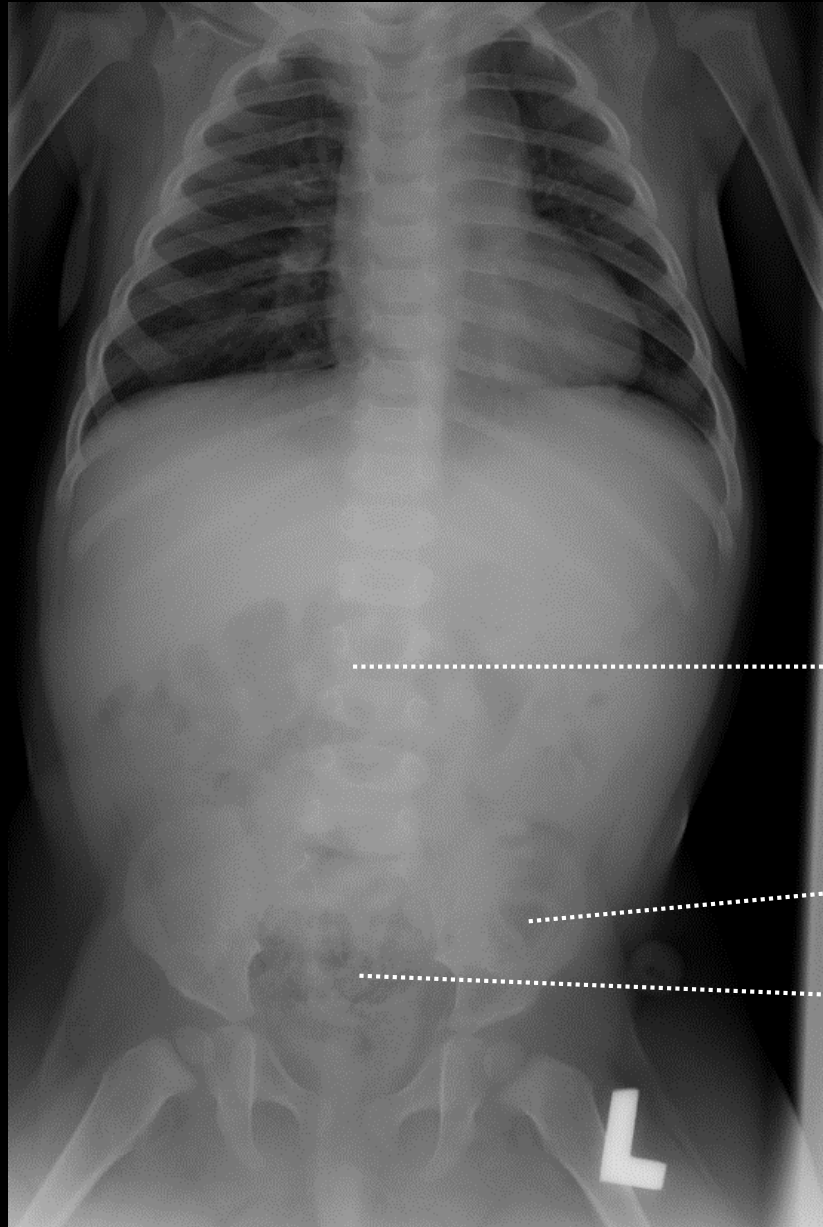
Žaludek – polykací akt (náplň kontrastní látkou) Stomach - X ray (filled with the contrast medium)



Irigrafie (náplň tlustého střeva kontrastní látkou)
Irigography (X-ray of the large intestine with the contrast medium)



Nativní snímek břicha / X-ray of abdomen



flexura coli
dextra

flexura coli sinistra

colon ascendens

colon descendens

colon transversum

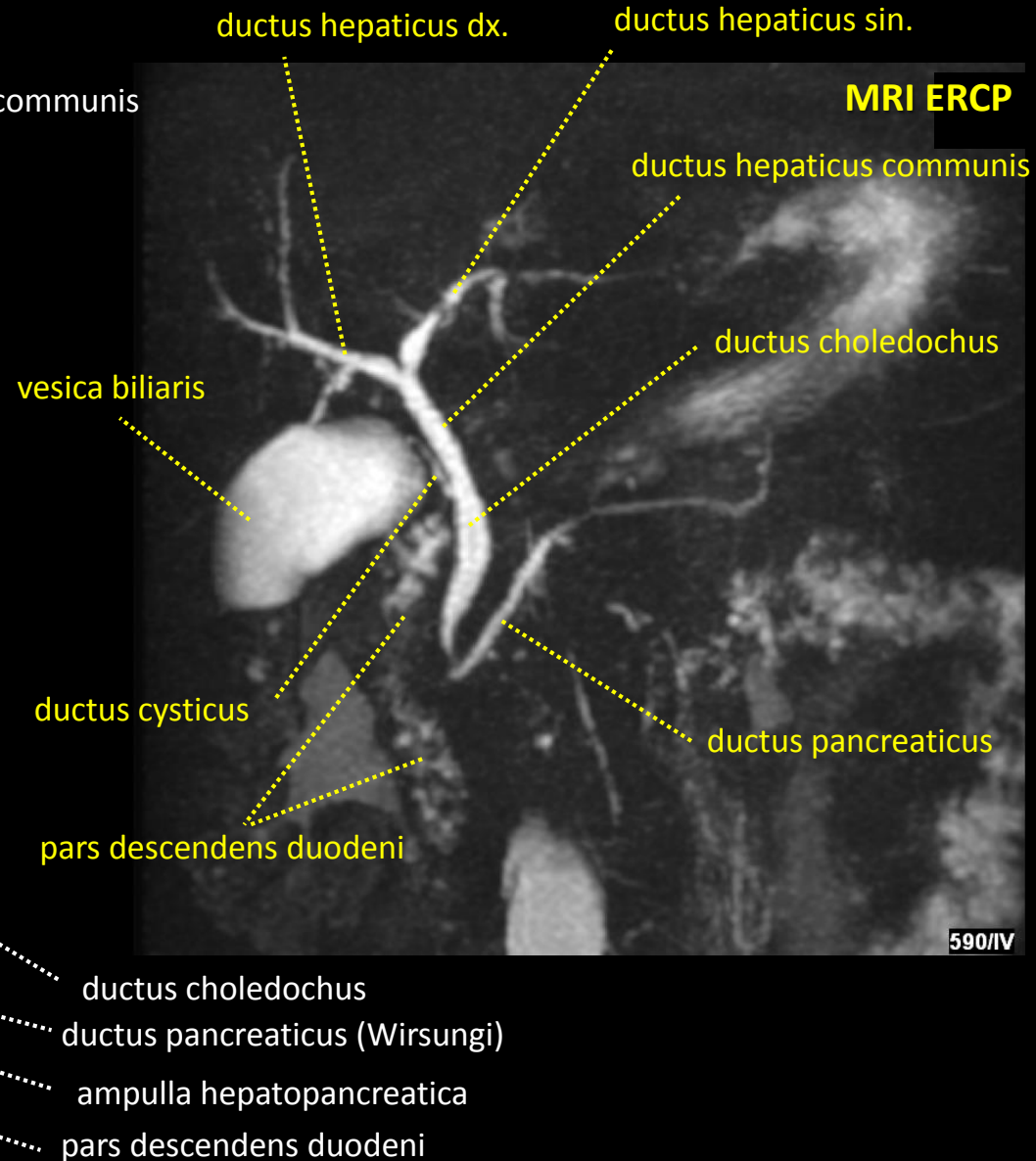
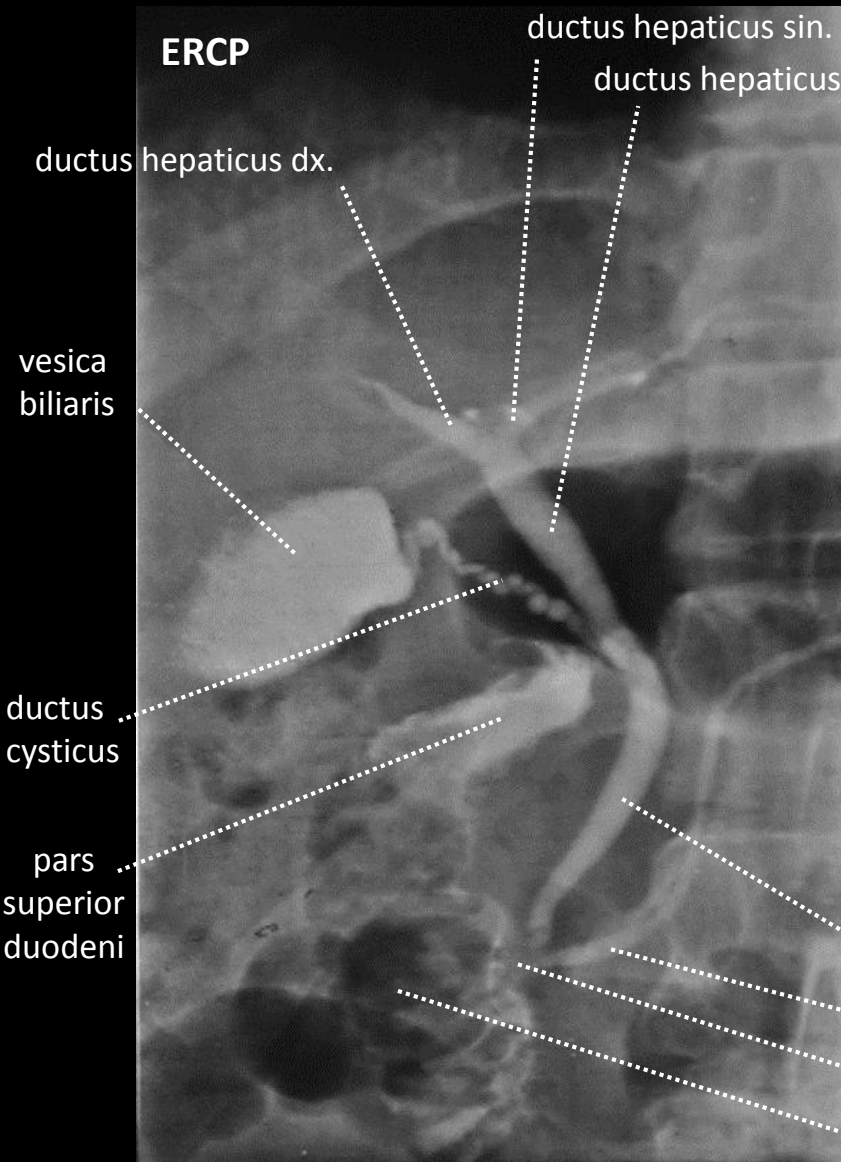
colon descendens

colon sigmoideum

rectum

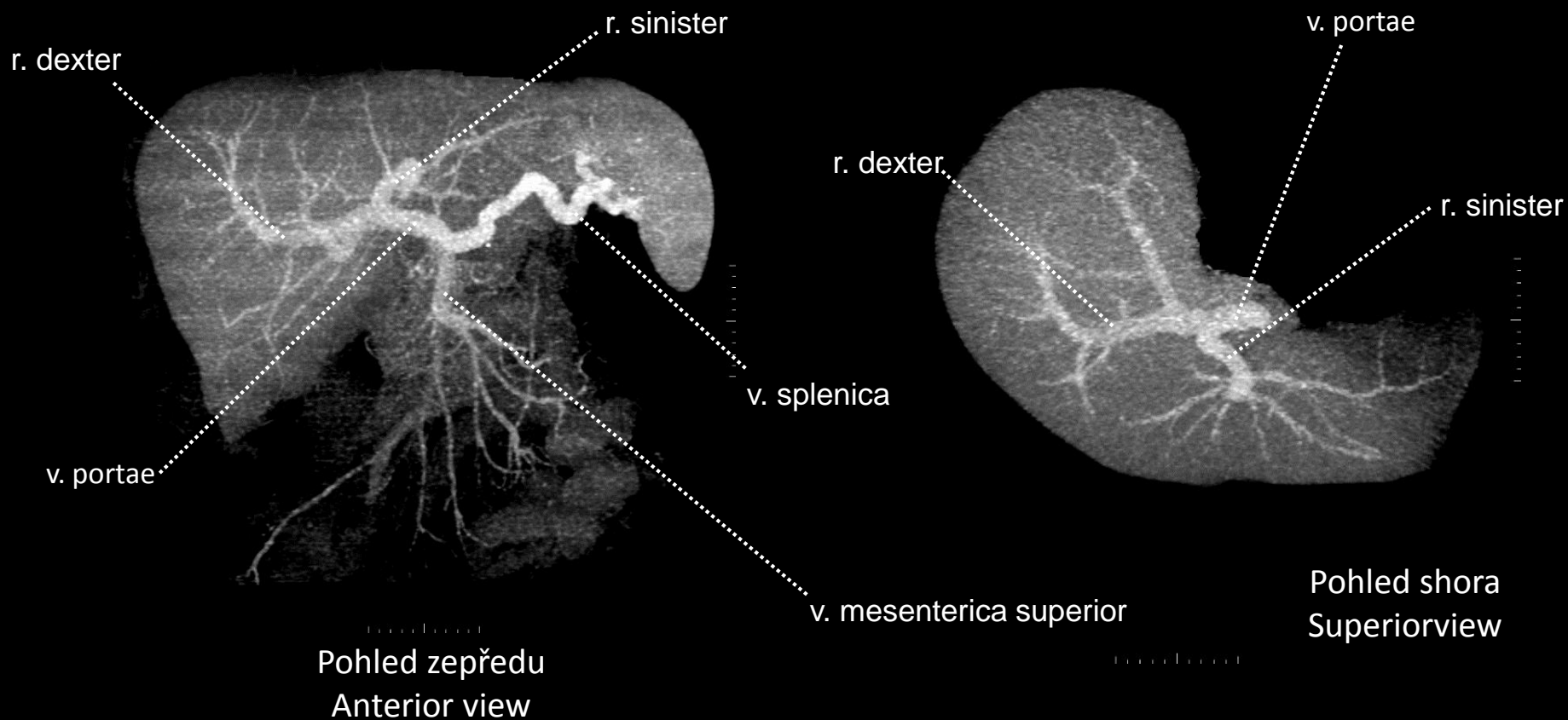
Endoskopická retrográdní cholangiopankreatografie (ERCP)

Endoscopic retrograde cholangiopancreatography (ERCP)



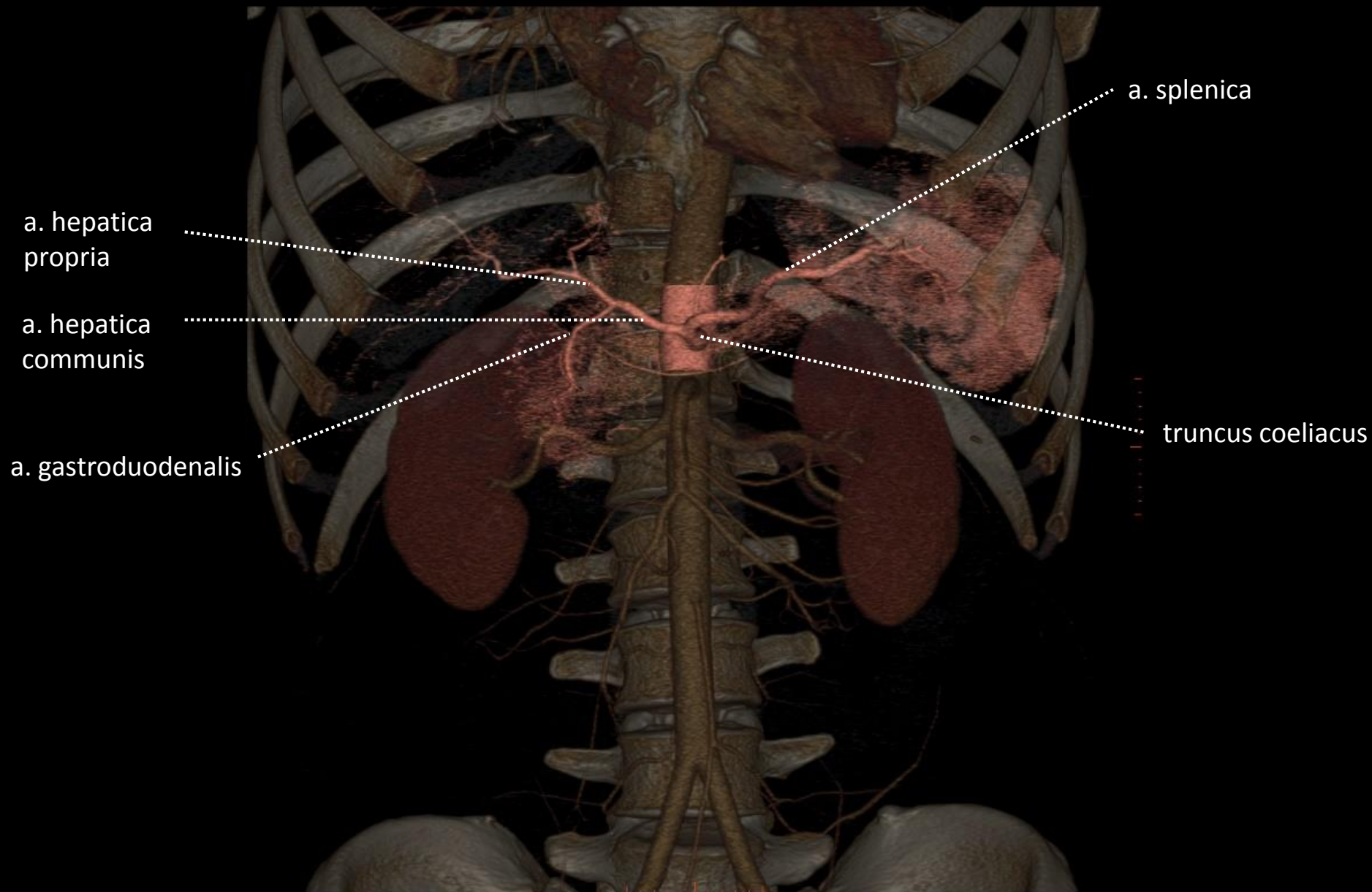
Řečiště a větve v. portae hepatis – *MRI angiografie*

Hepatic portal vein, its tributaries and branches – *MRI angiography*



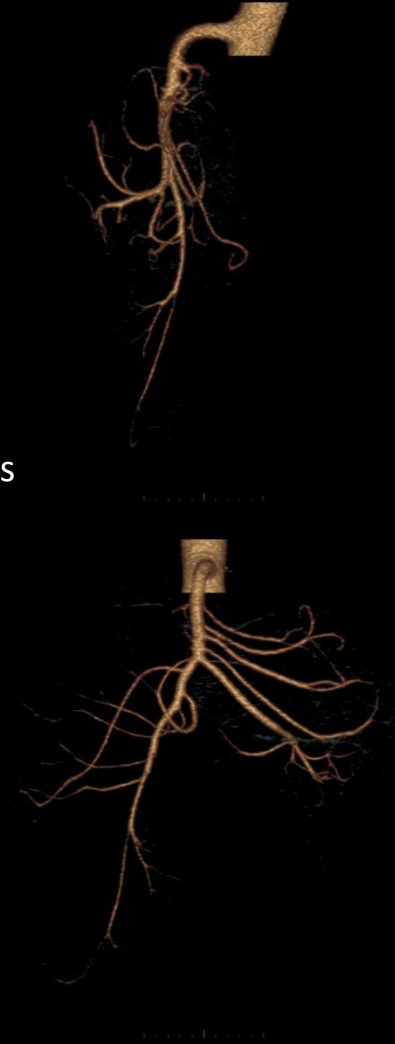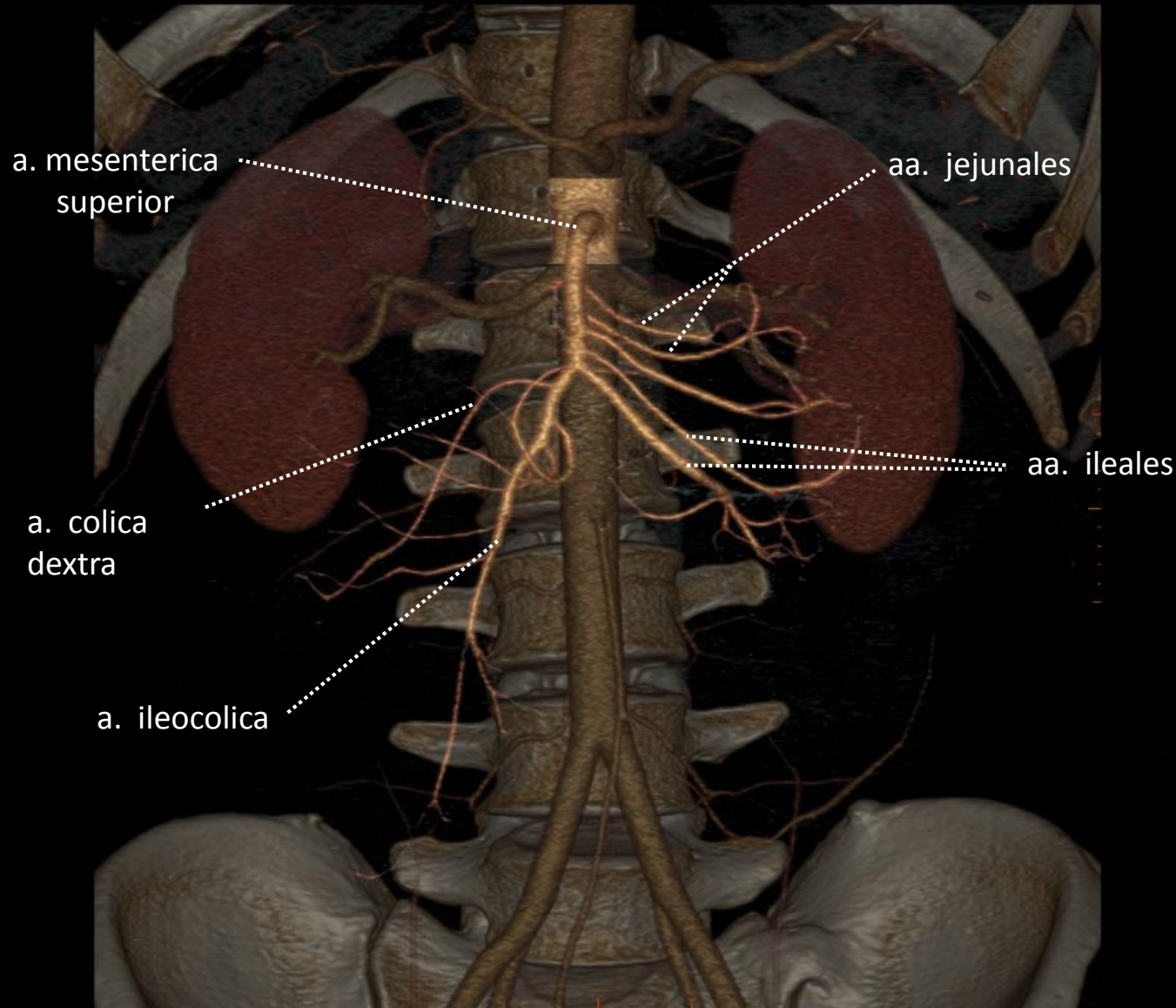
Větve truncus coeliacus – 3D rekonstrukce CT angiografie

Branches of truncus coeliacus – 3D reconstruction of CT angiography



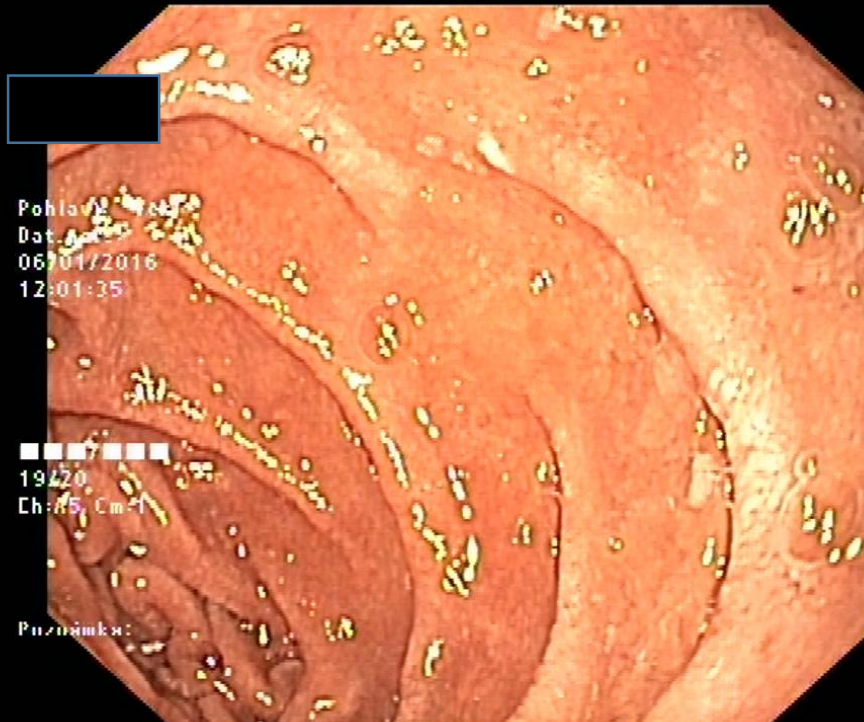
Větve a. mesenterica superior – 3D rekonstrukce CT angiografie

Branches of the a. mesenterica superior – 3D reconstruction of CT angiography

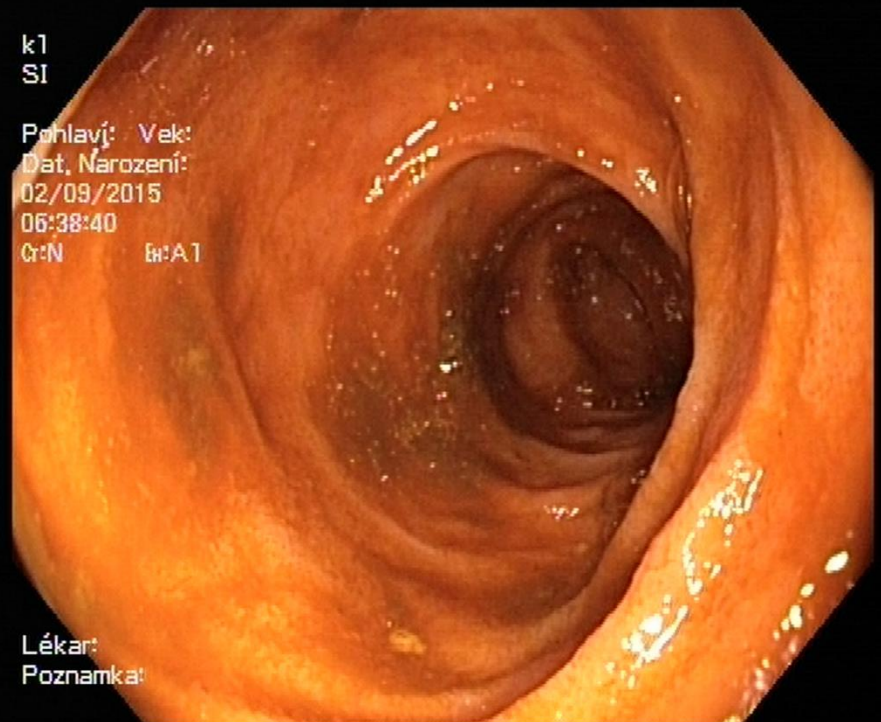


Endoskopie tenkého střeva

Endoscopy of the small intestine



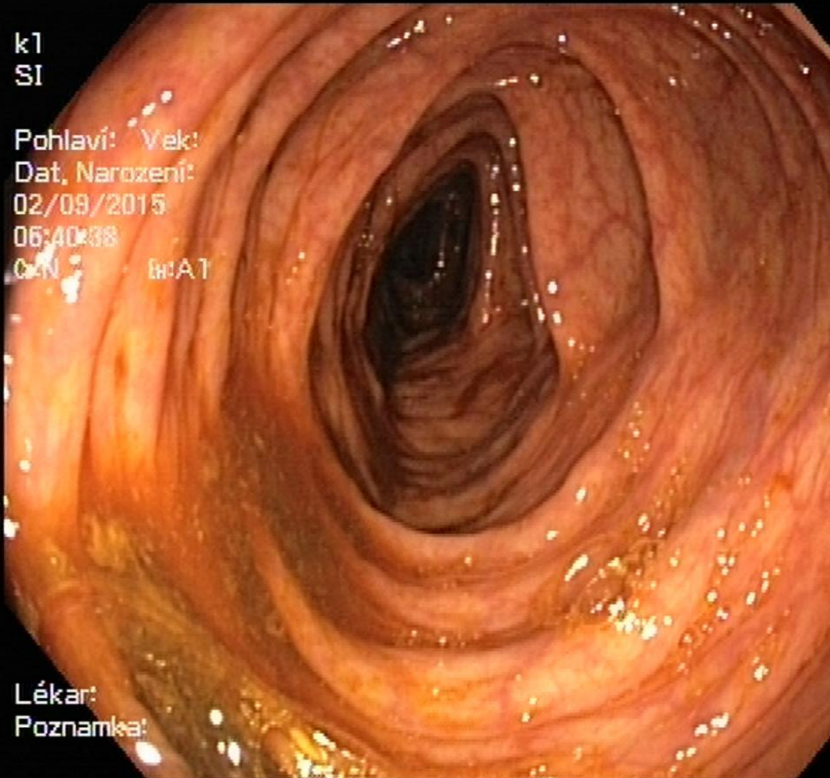
Duodenum – plicae circulares



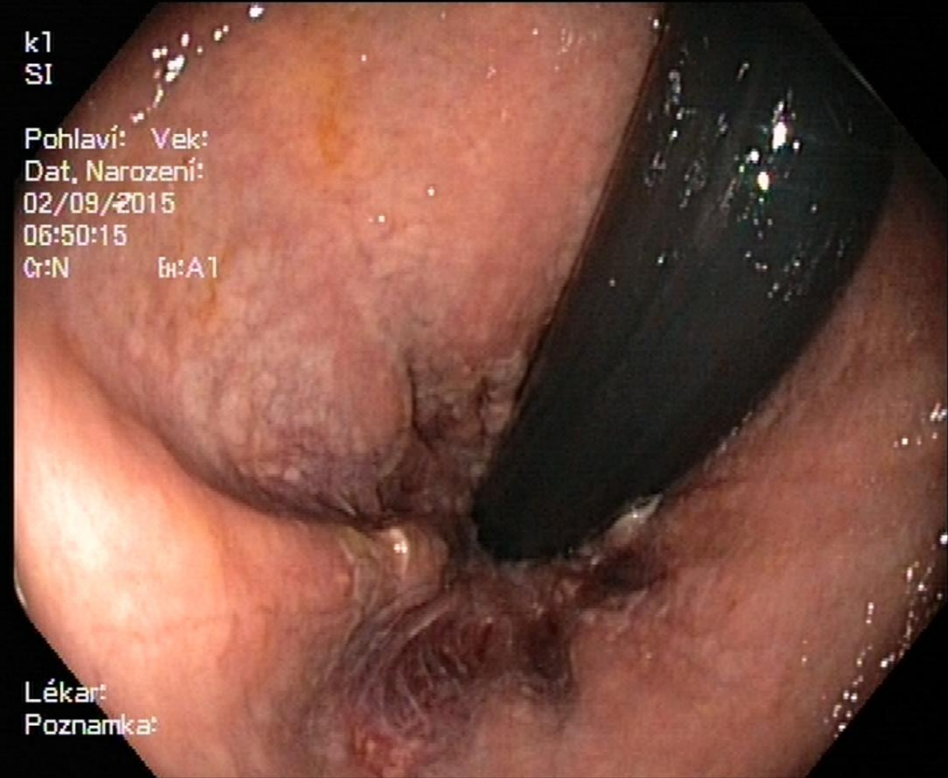
Ileum – plicae circulares

Koloskopie + rectoskopie

Coloscopy + rectoscopy



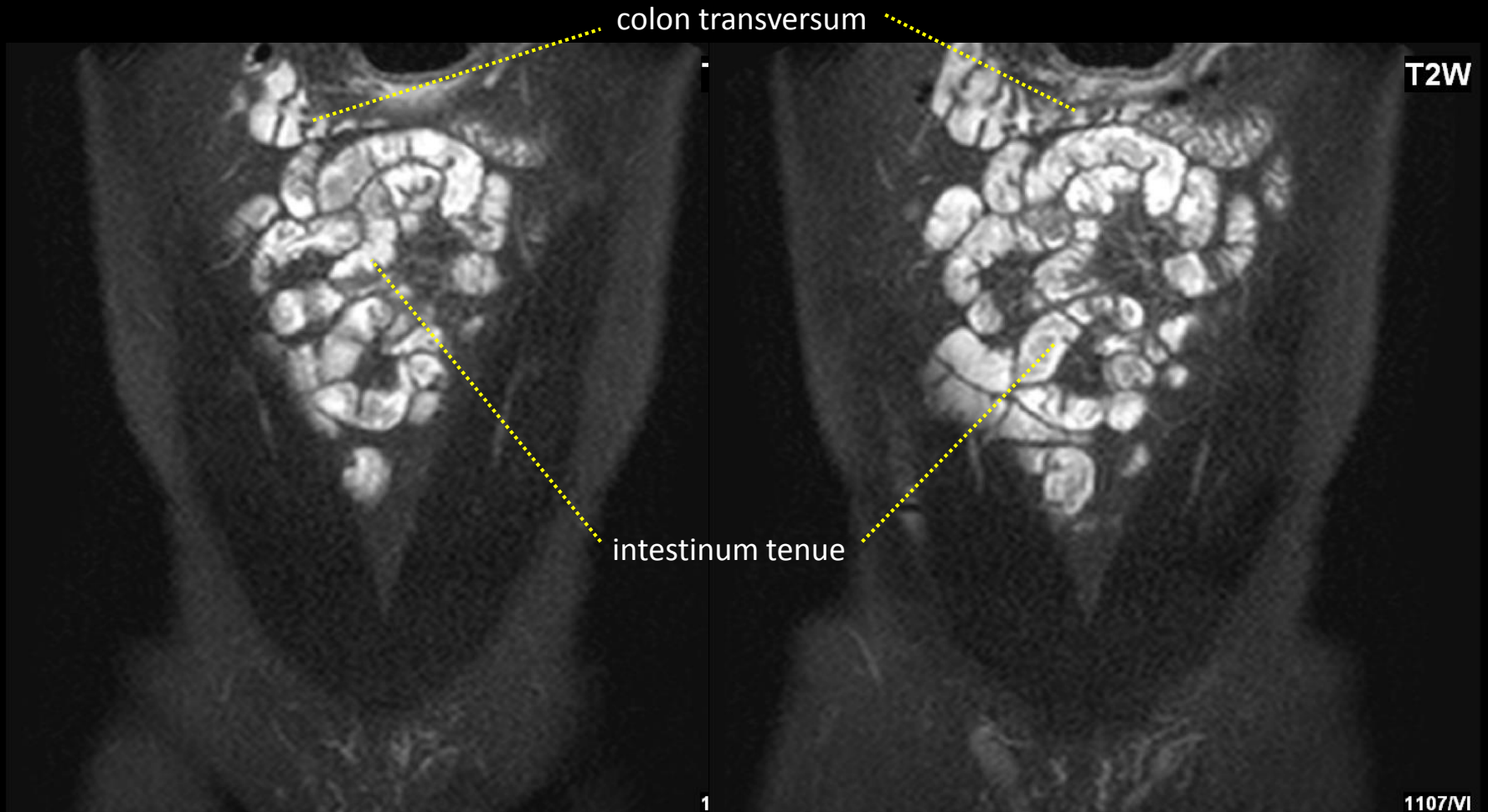Colon – plicae semilunares



Rectum – columnae anales

MR střev MRI of the gut

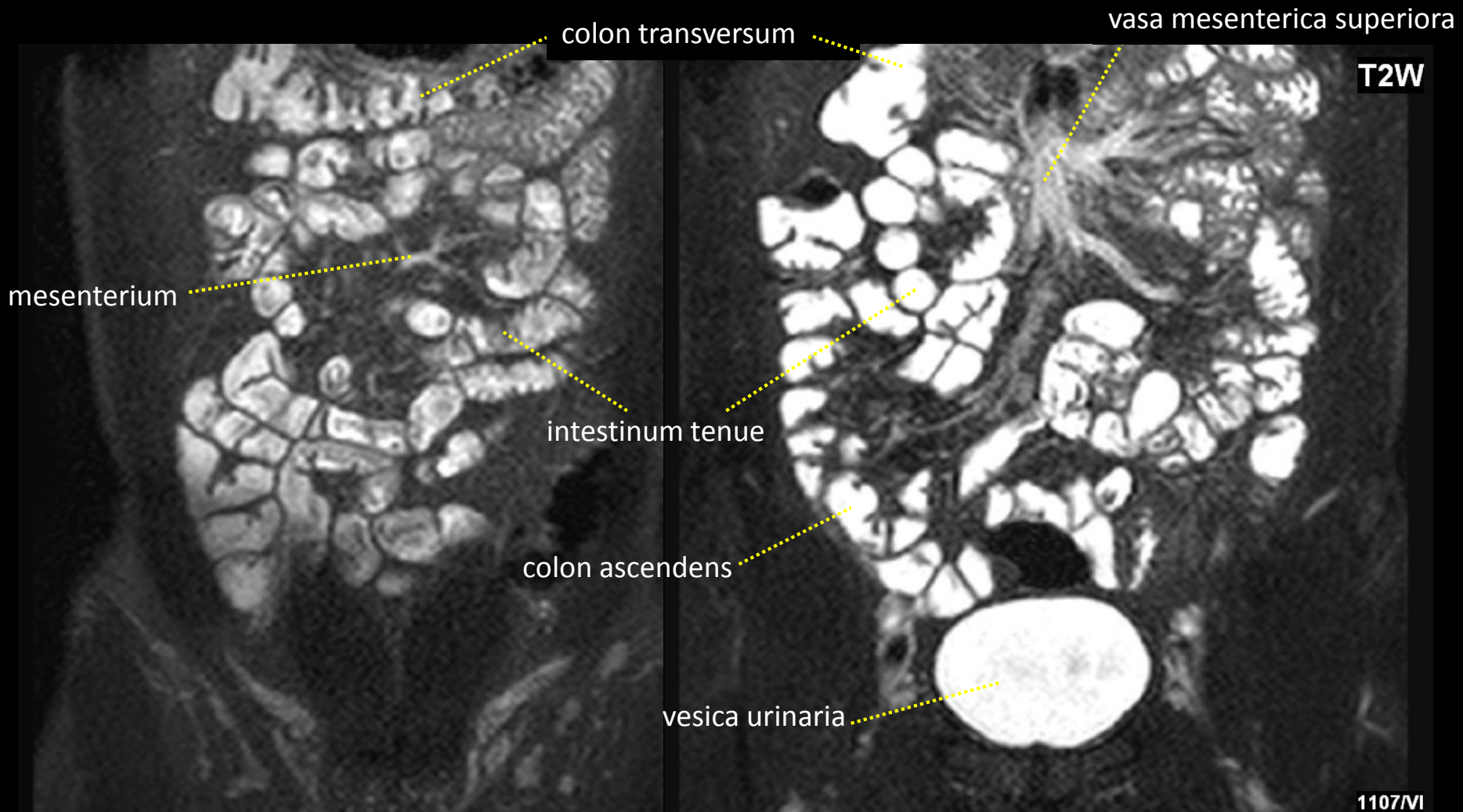
frontální řezy / frontal sections



MR střev

MRI of the gut

frontální řezy / frontal sections



MR břicha

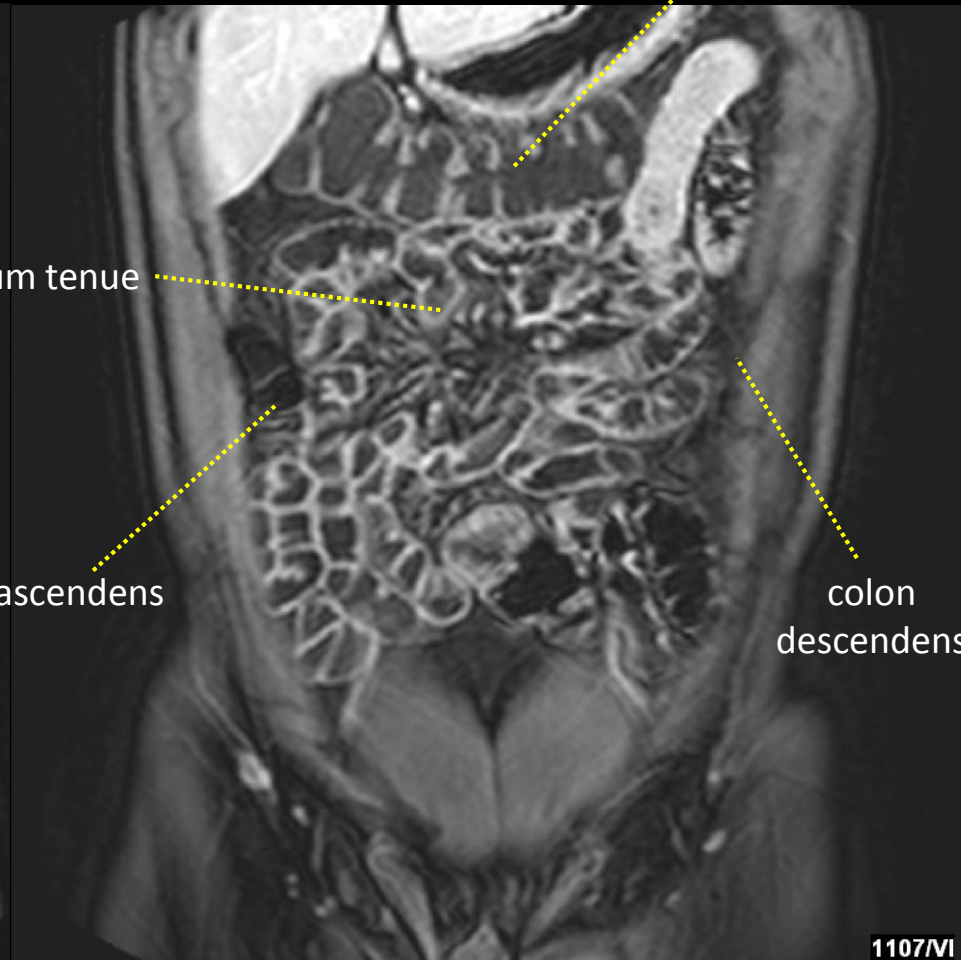
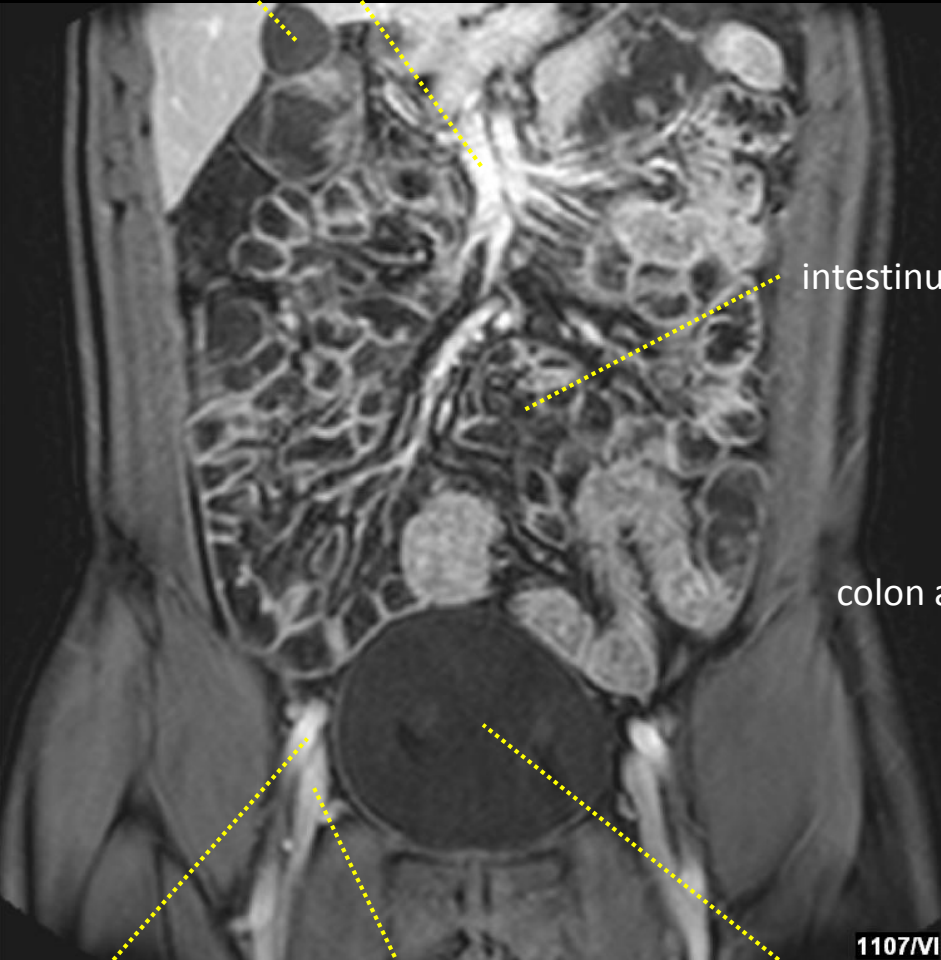
MRI of the abdomen

frontální řezy / frontal sections

vasa mesenterica superior

colon transversum

vesica biliaris



intestinum tenue

colon ascendens

colon descendens

a. femoralis

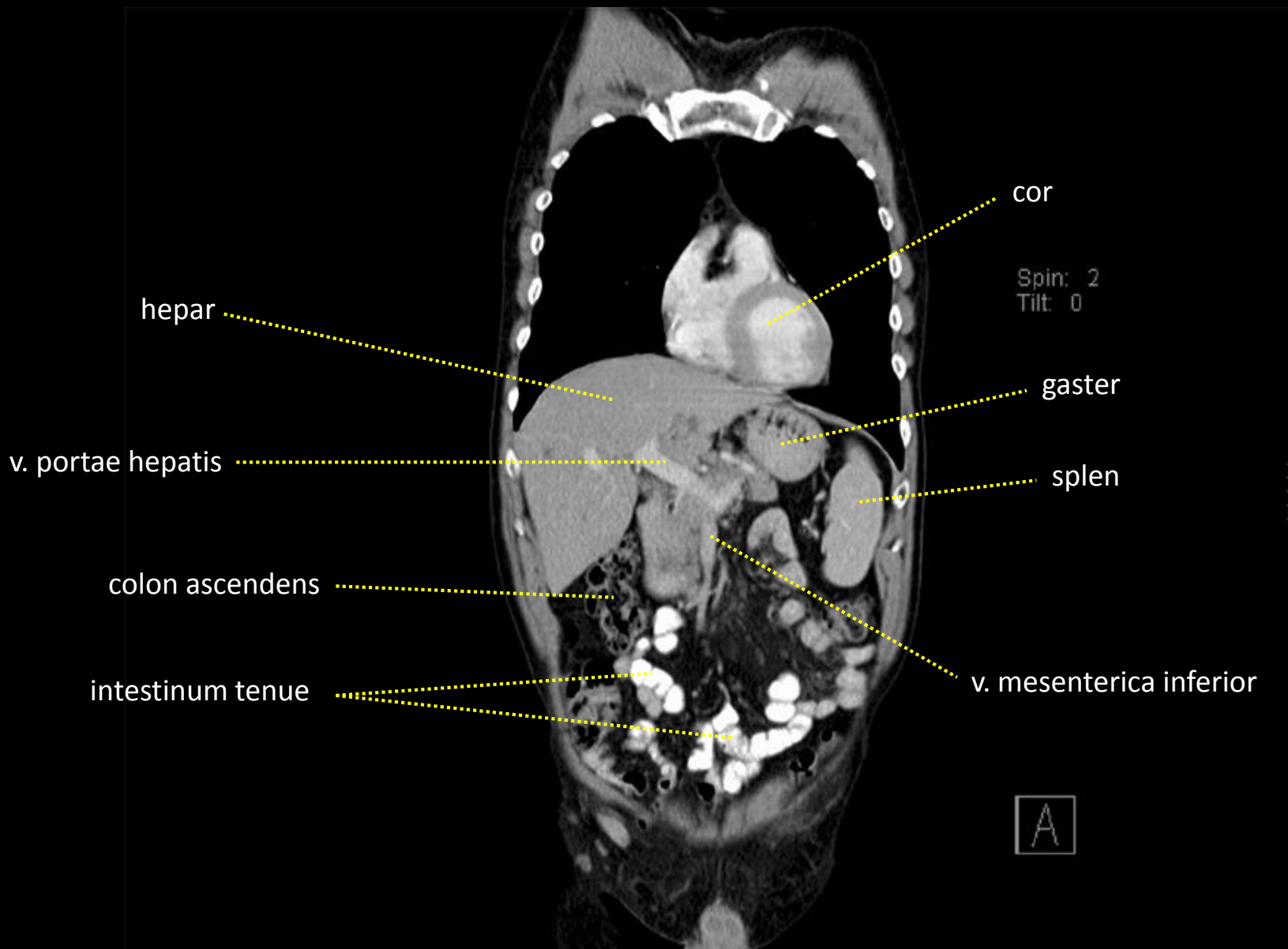
v. femoralis communis

vesica urinaria

CT břicha s kontrastní látkou v cévách i střevech

CT of the abdomen with contrast fluid in the intestine and vessels

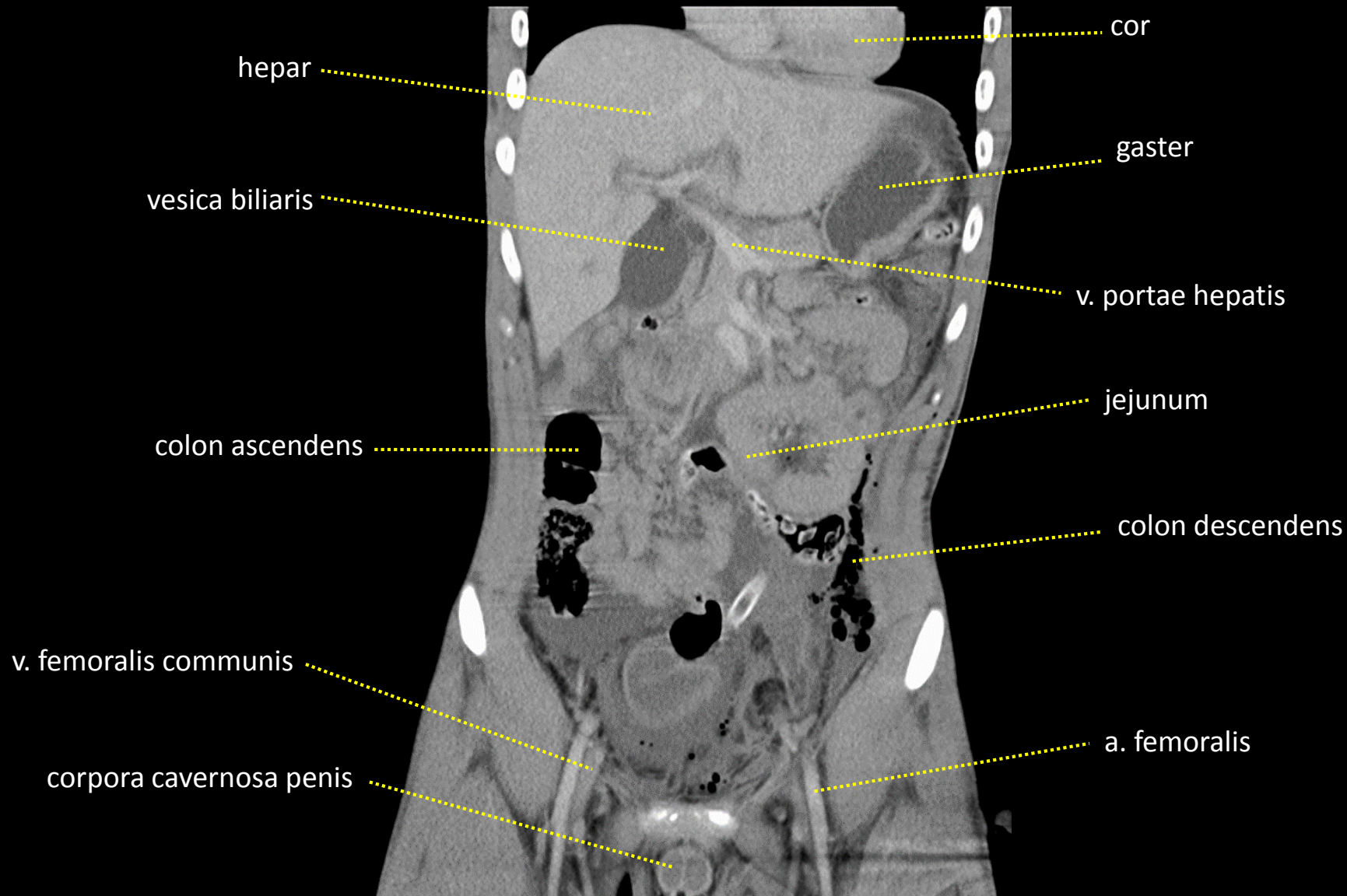
frontální řez / frontal section



CT břicha s kontrastní látkou v cévách i střevech

CT of the abdomen with contrast fluid in the intestine and vessels

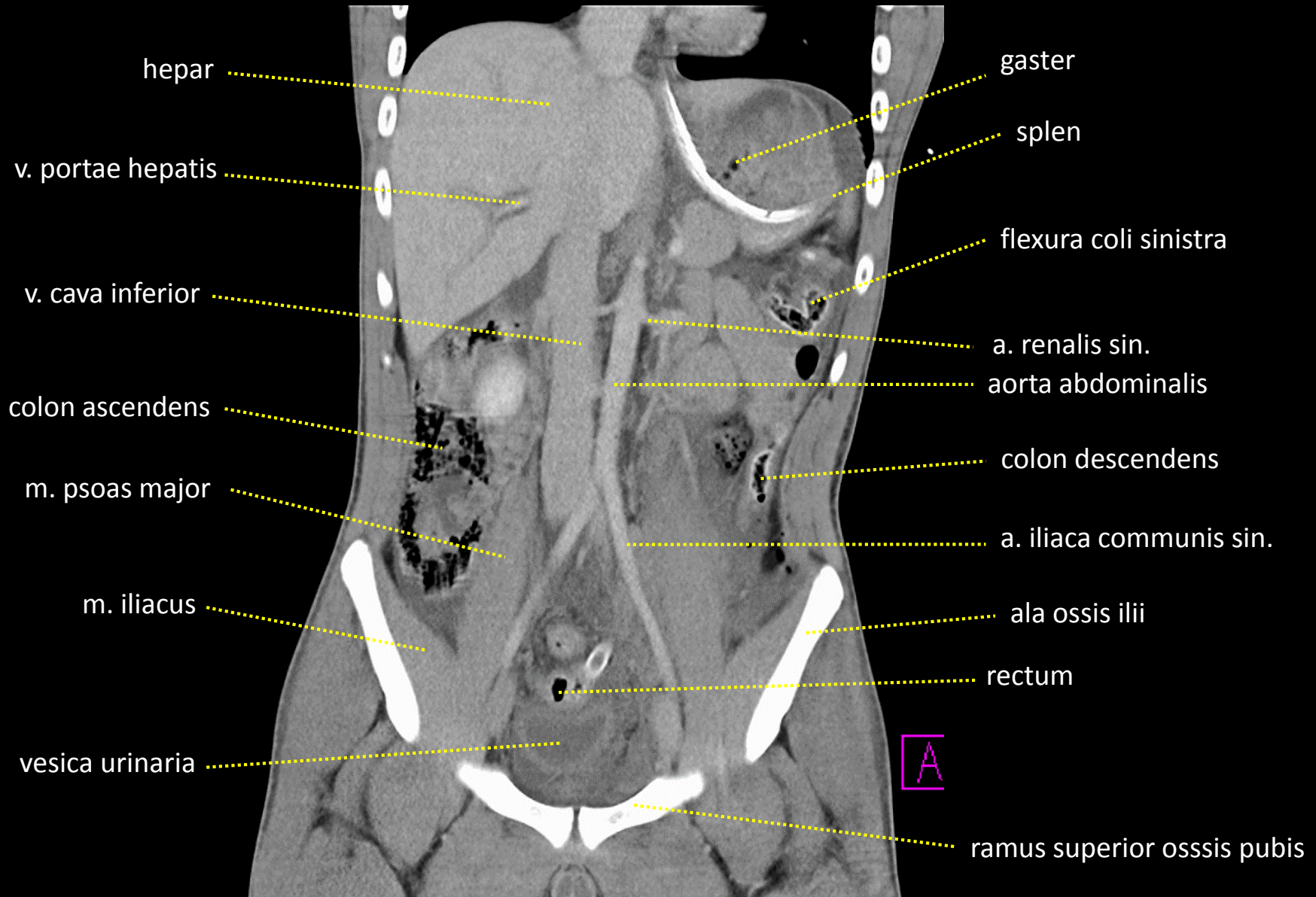
frontální řez / frontal section



CT břicha s kontrastní látkou v cévách i střevech

CT of the abdomen with contrast fluid in the intestine and vessels

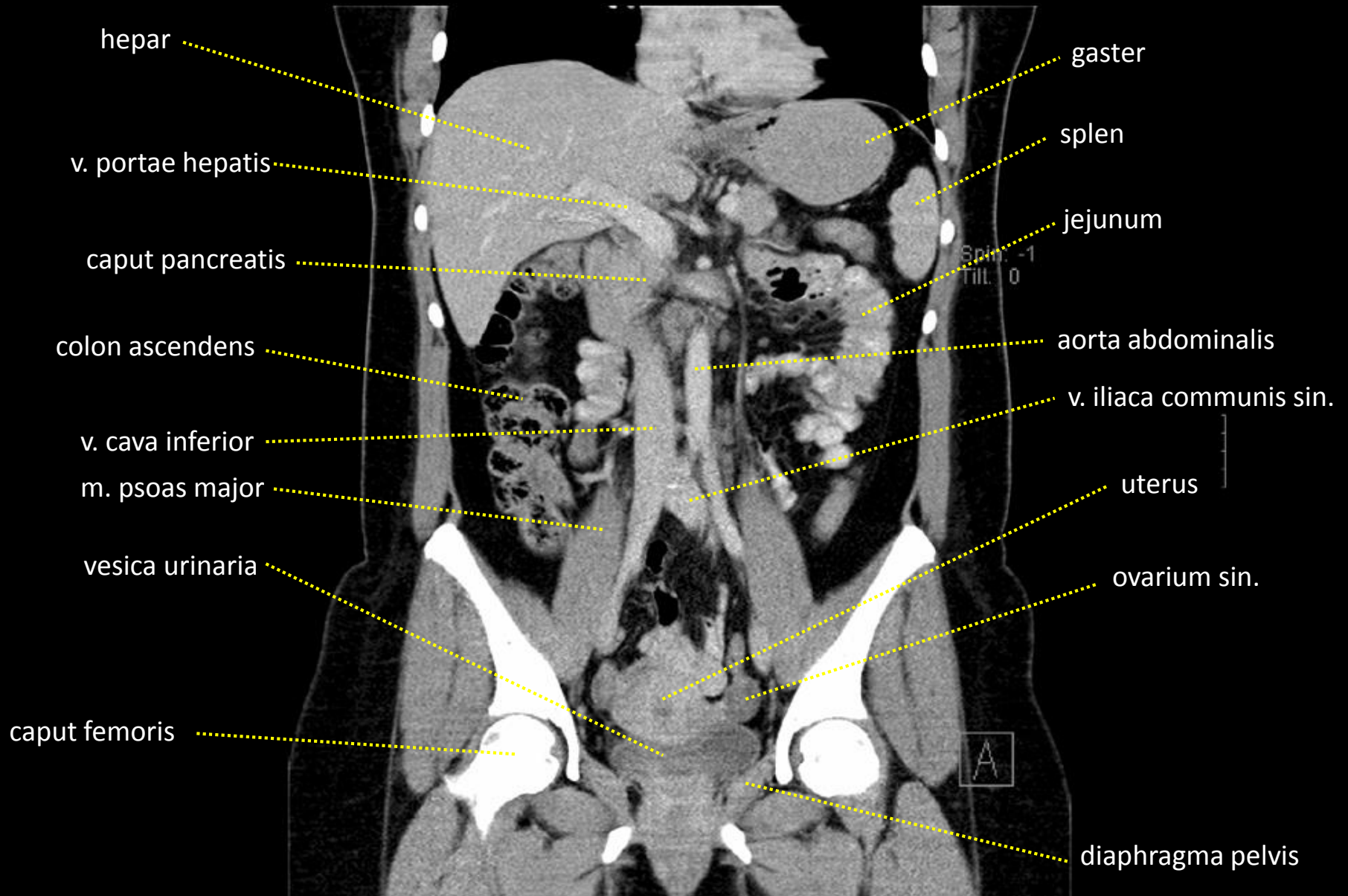
frontální řez / frontal section



CT břicha s kontrastní látkou v cévách i střevech

CT of the abdomen with contrast fluid in the intestine and vessels

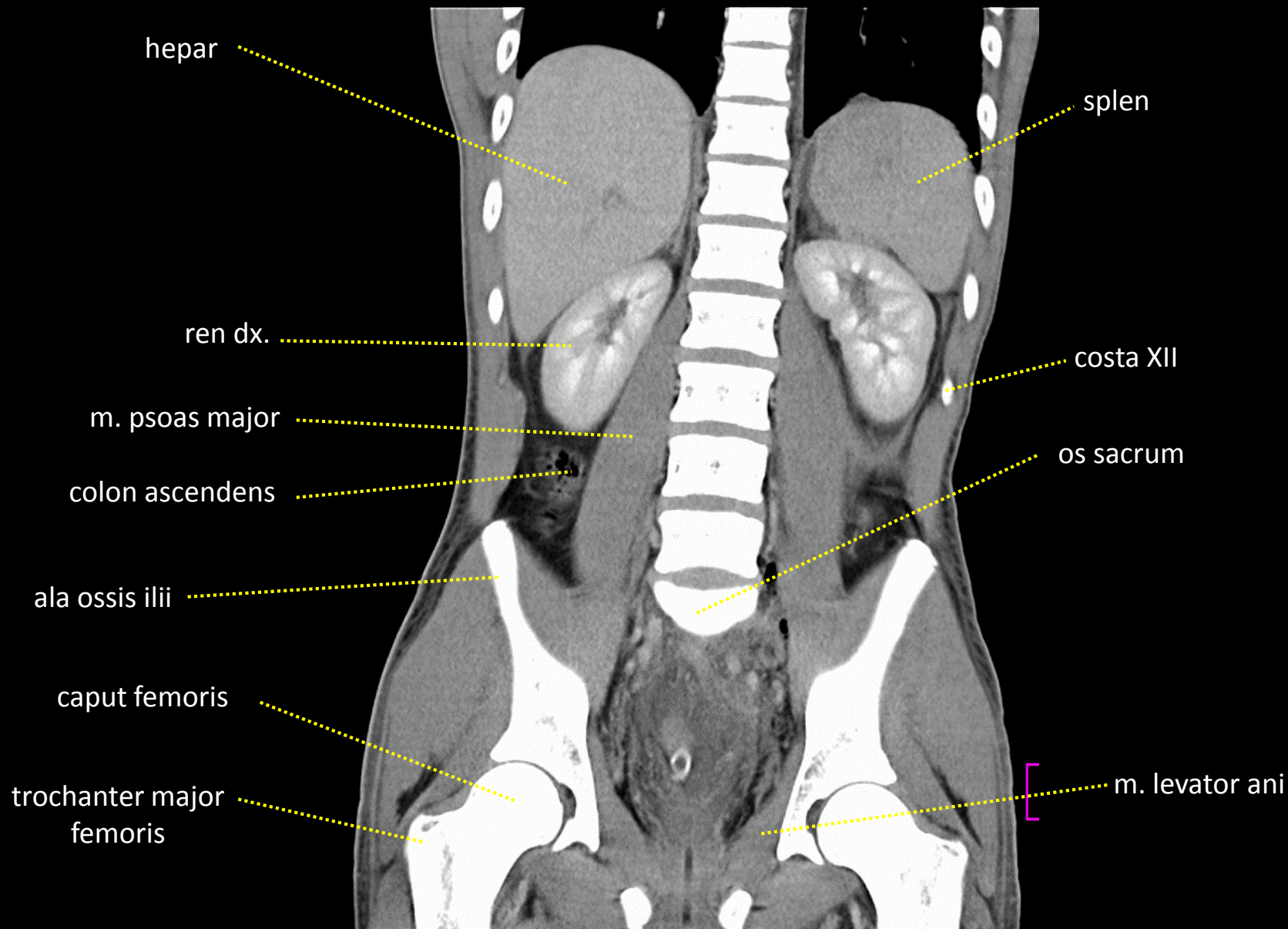
frontální řez / frontal section



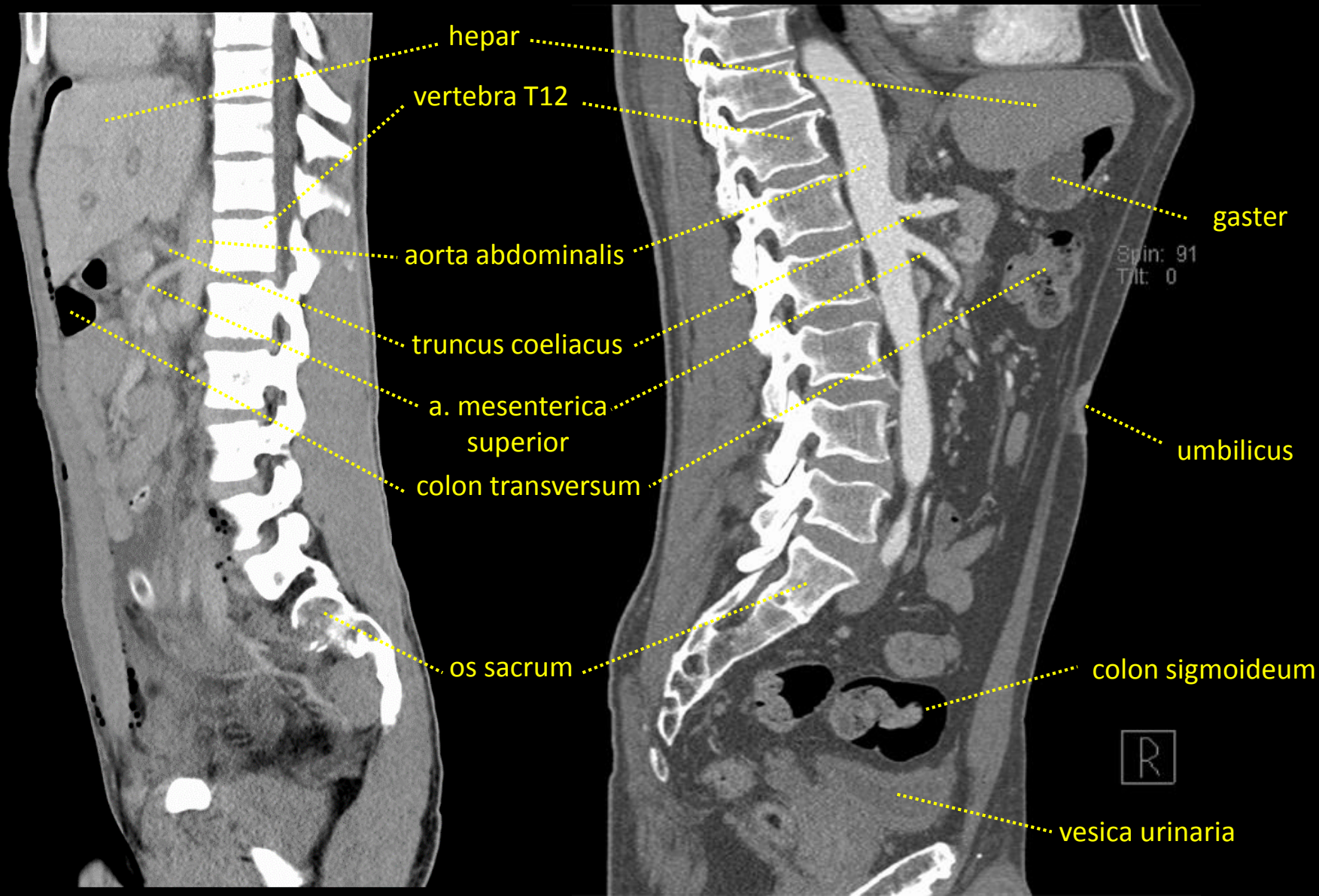
CT břicha s kontrastní látkou v cévách i střevech

CT of the abdomen with contrast fluid in the intestine and vessels

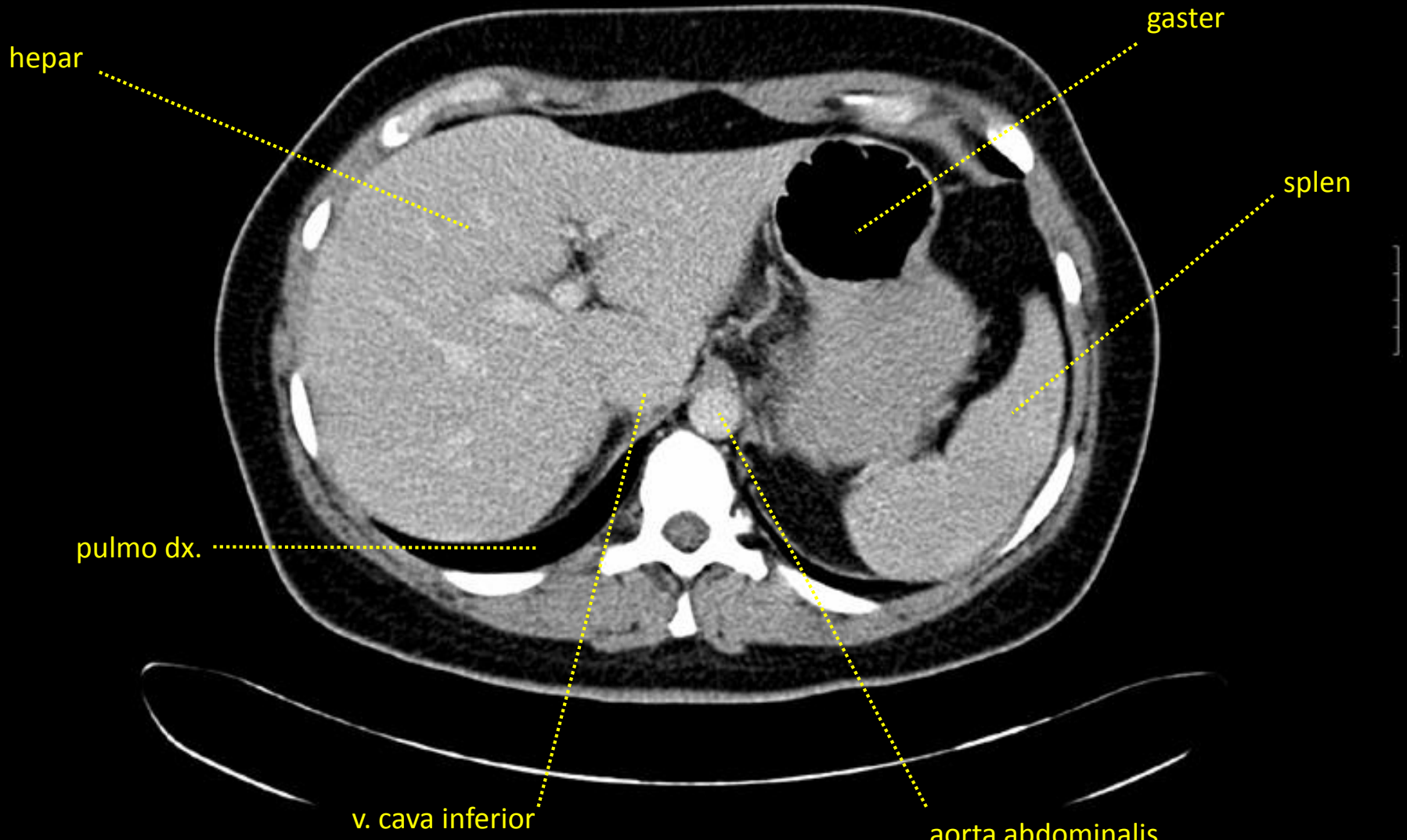
frontální řez / frontal section



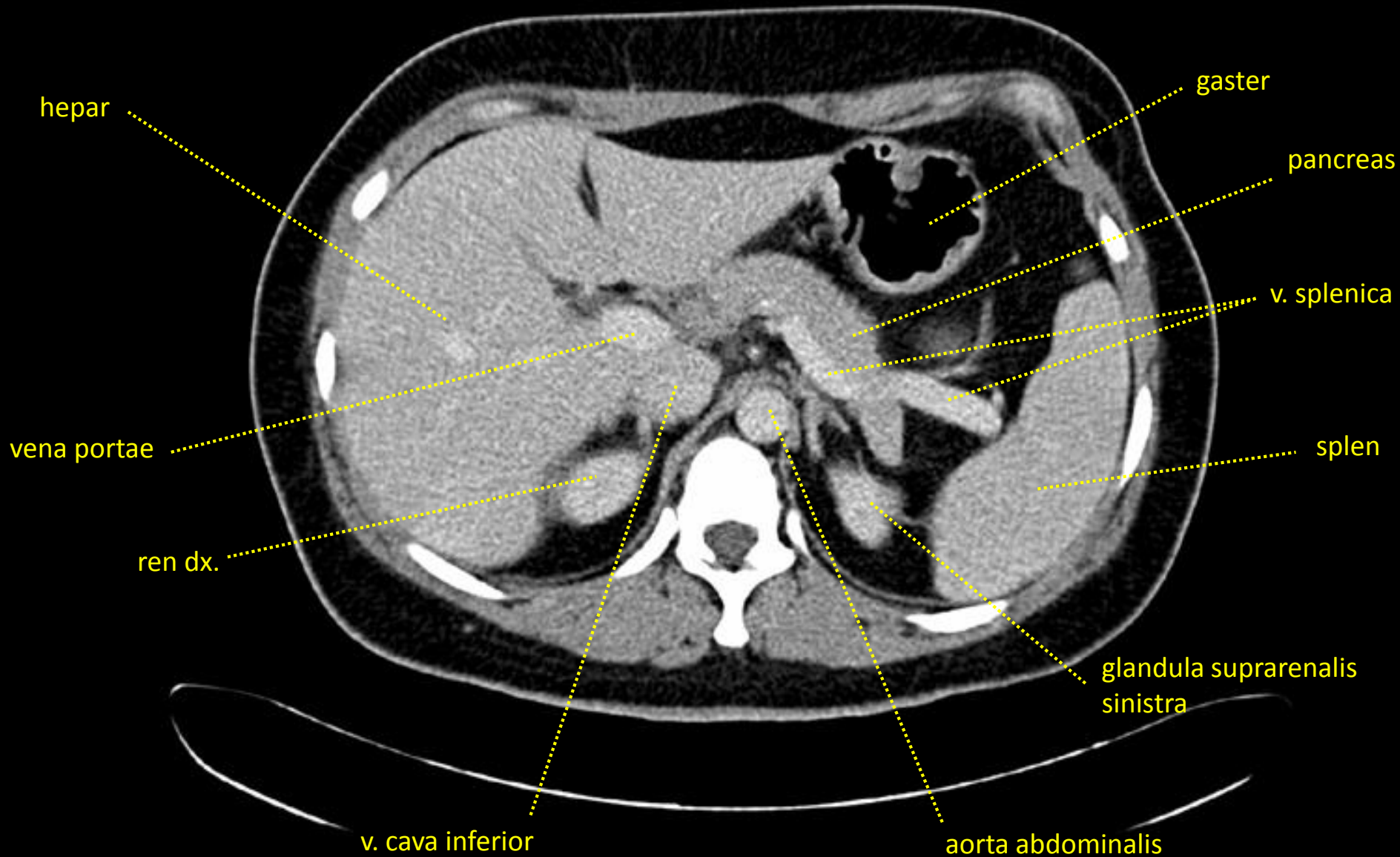
CT břicha s kontrastní látkou v cévách (angioCT) CT of the abdomen with contrast fluid in vessels (angioCT) *sagitální řezy / sagittal sections*



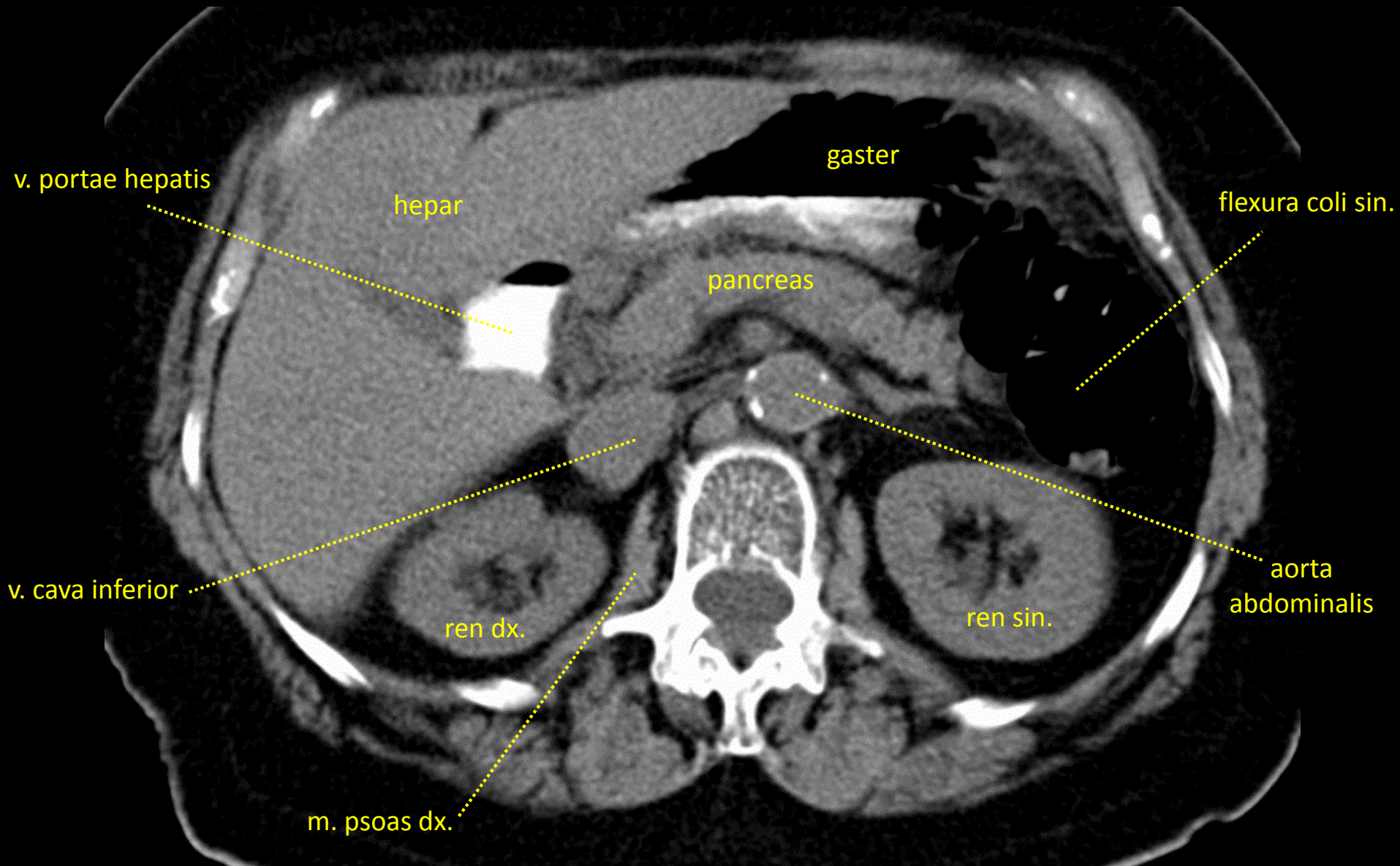
CT břicha s kontrastní látkou ve střevech a cévách
CT of the abdomen with contrast fluid in the intestine and vessels
transverzální řez / transverse section



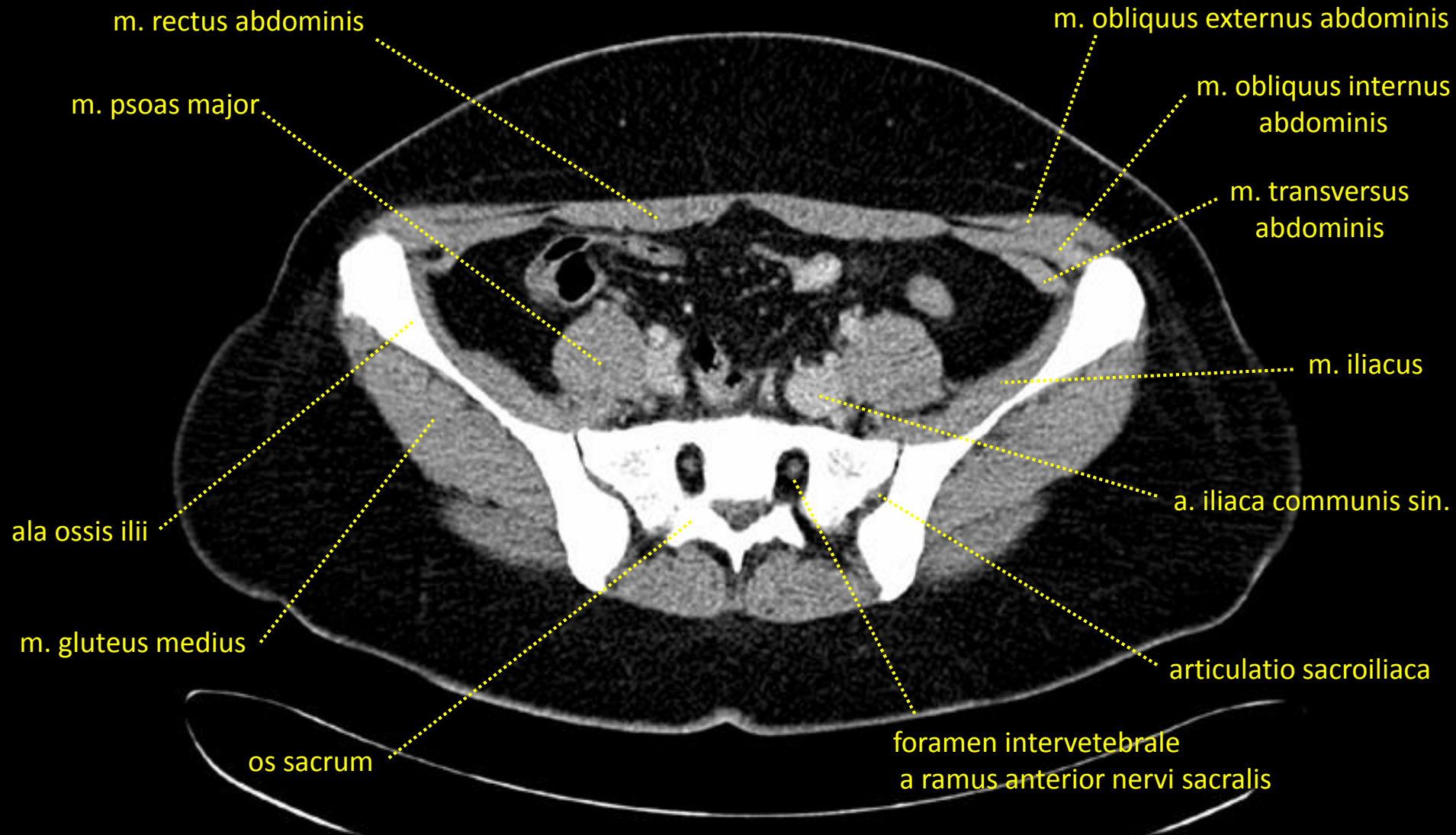
CT břicha s kontrastní látkou ve střevech a cévách
CT of the abdomen with contrast fluid in the intestine and vessels
transverzální řez / transverse section



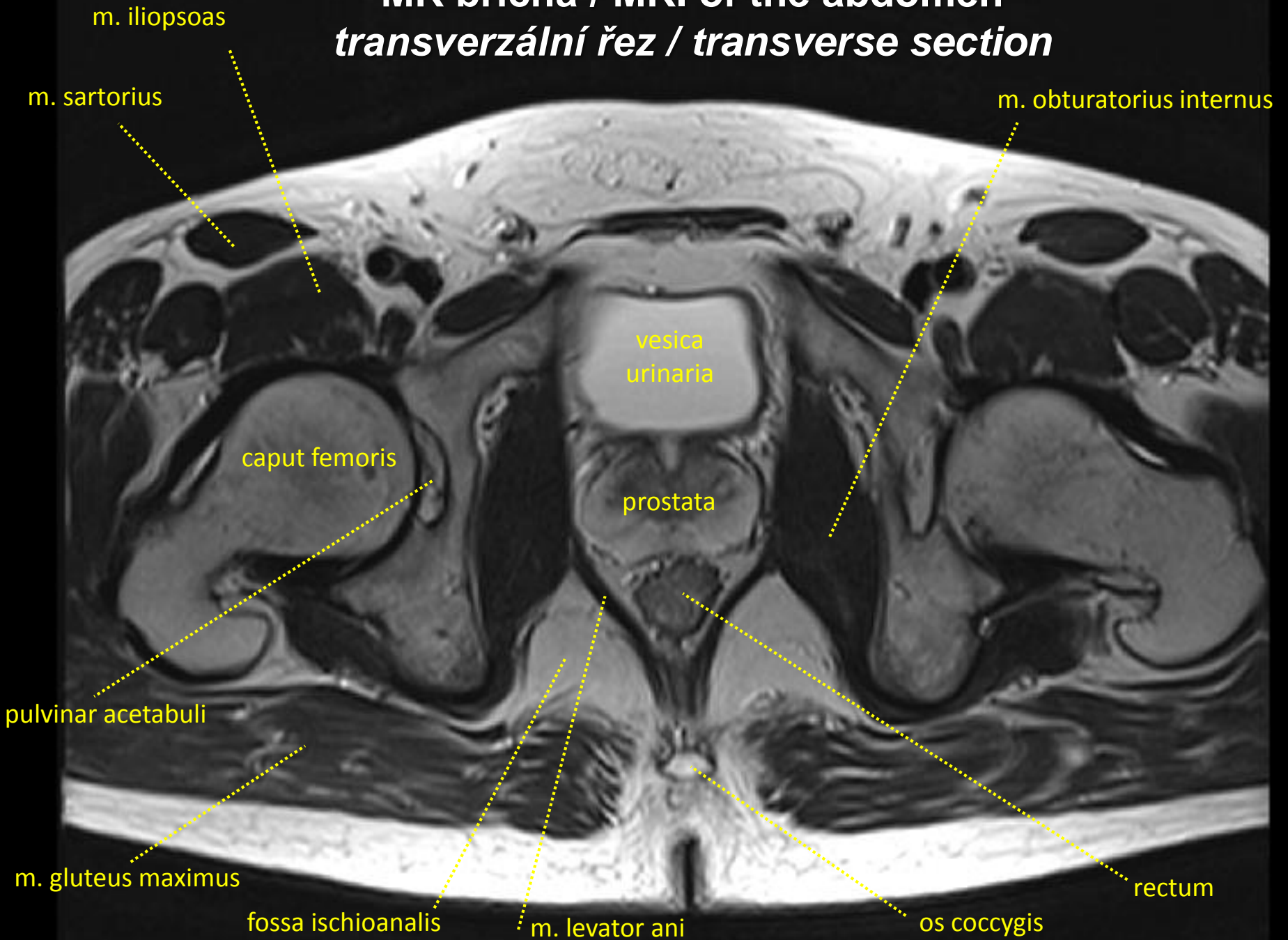
CT břicha s kontrastní látkou ve střevech a cévách
CT of the abdomen with contrast fluid in the intestine and vessels
transverzální řez / transverse section



CT břicha s kontrastní látkou ve střevech a cévách
CT of the abdomen with contrast fluid in the intestine and vessels
transverzální řez / transverse section



MR břicha / MRI of the abdomen *transverzální řez / transverse section*



MR břicha / MRI of the abdomen *sagitální řez / sagittal section*

